

AT MICROFICHE
REFERENCE
LIBRARY
A project of Volunteers in Asia

General Surgery at the District Hospital

Edited by: John Cook, Balu Sankaran,
and Ambrose E.O. Wasunna

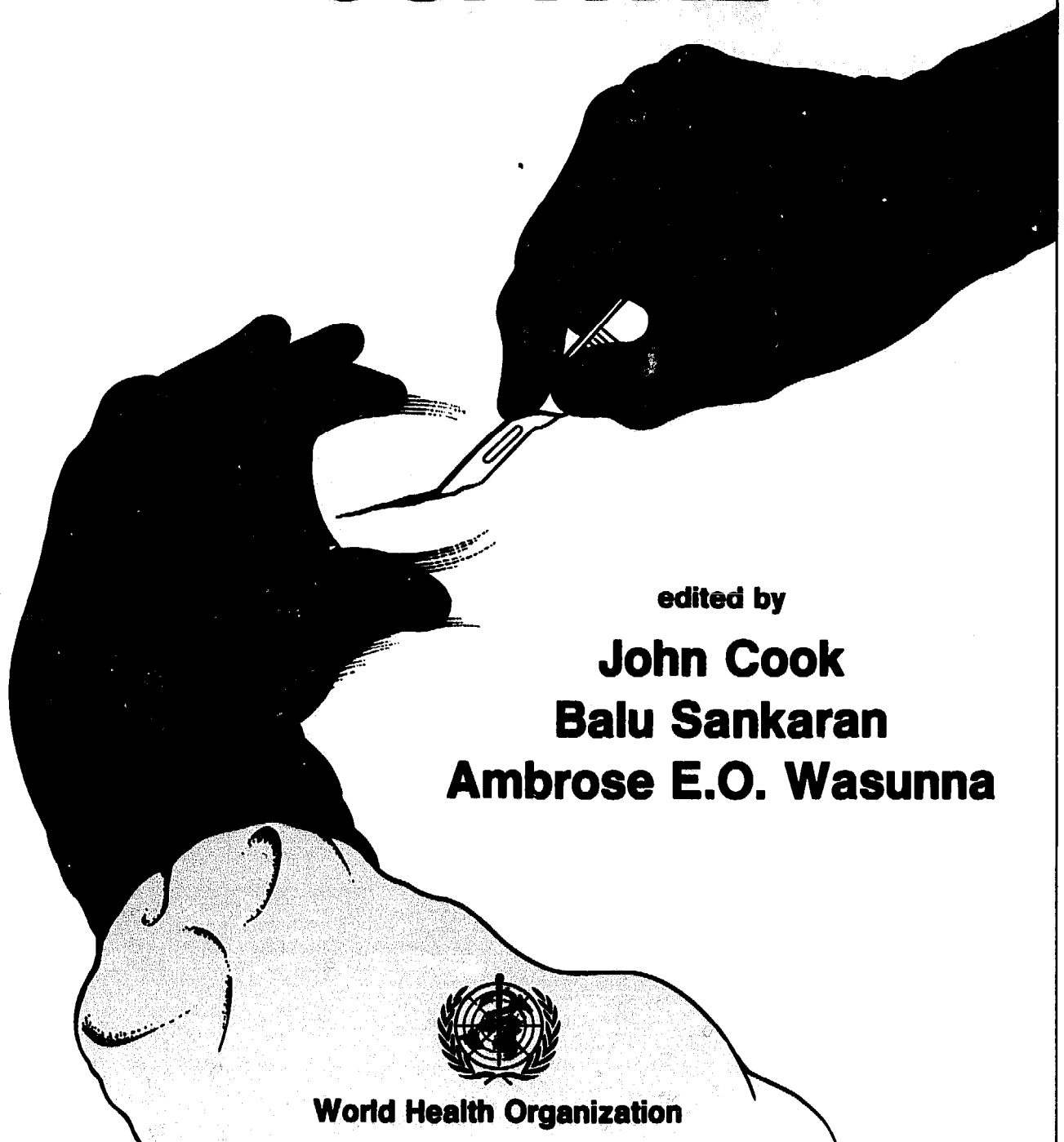
Published by: World Health Organization
Geneva, Switzerland

Available from: WHO
Distribution and Sales Service
1211 Geneva 27
Switzerland

Reproduced with permission.

Reproduction of this microfiche document in any form is subject to the same restrictions as those of the original document.

GENERAL SURGERY AT THE DISTRICT HOSPITAL



edited by

John Cook

Balu Sankaran

Ambrose E.O. Wasunna



World Health Organization

The World Health Organization is a specialized agency of the United Nations with primary responsibility for international health matters and public health. Through this organization, which was created in 1948, the health professions of more than 165 countries exchange their knowledge and experience with the aim of making possible the attainment by all citizens of the world by the year 2000 of a level of health that will permit them to lead a socially and economically productive life.

By means of direct technical cooperation with its Member States, and by stimulating such cooperation among them, WHO promotes the development of comprehensive health services, the prevention and control of diseases, the improvement of environmental conditions, the development of health manpower, the coordination and development of biomedical and health services research, and the planning and implementation of health programmes.

These broad fields of endeavour encompass a wide variety of activities, such as developing systems of primary health care that reach the whole population of Member countries; promoting the health of mothers and children; combating malnutrition; controlling malaria and other communicable diseases, including tuberculosis and leprosy; having achieved the eradication of smallpox, promoting mass immunization campaigns against a number of other preventable diseases; improving mental health; providing safe water supplies; and training health personnel of all categories.

Progress towards better health throughout the world also demands international cooperation in such matters as establishing international standards for biological substances, pesticides, and pharmaceuticals; formulating environmental health criteria; recommending international nonproprietary names for drugs; administering the International Health Regulations; revising the International Classification of Diseases, Injuries, and Causes of Death; and collecting and disseminating health statistical information.

Further information on many aspects of WHO's work is presented in the Organization's publications.

General surgery at the district hospital

edited by

John Cook

Consultant Surgeon
Department of Surgery
Eastern General Hospital
Edinburgh, Scotland

Balu Sankaran

Formerly Director
Division of Diagnostic, Therapeutic and
Rehabilitative Technology
World Health Organization
Geneva, Switzerland

Ambrose E.O. Wasunna

Medical Officer
Clinical Technology
World Health Organization
Geneva, Switzerland
and
Professor of Surgery
University of Nairobi
Nairobi, Kenya

illustrated by

Derek Atherton
and Elisabetta Sacco



**World Health Organization
Geneva
1988**

ISBN 92 4 154235 7

© World Health Organization 1988

Publications of the World Health Organization enjoy copyright protection in accordance with the provisions of Protocol 2 of the Universal Copyright Convention. For rights of reproduction or translation of WHO publications, in part or *in toto*, application should be made to the Office of Publications, World Health Organization, Geneva, Switzerland. The World Health Organization welcomes such applications.

The designations employed and the presentation of the material in this publication do not imply the expression of any opinion whatsoever on the part of the Secretariat of the World Health Organization concerning the legal status of any country, territory, city or area or of its authorities, or concerning the delimitation of its frontiers or boundaries.

The mention of specific companies or of certain manufacturers' products does not imply that they are endorsed or recommended by the World Health Organization in preference to others of a similar nature that are not mentioned. Errors and omissions excepted, the names of proprietary products are distinguished by initial capital letters.

The contributors alone are responsible for the views expressed in this publication.

Printed in Switzerland
88/7648 — Atar — 7000

CONTENTS

Preface	9
Contributors	10
Introductory note	11

Fundamentals of general surgery

1 Basic principles and techniques	15
Asepsis	
Preparation for surgery	
Prevention of transmission of human immunodeficiency virus (HIV)	
Surgical methods and materials	
Wound débridement	
Incision and drainage of abscesses	
Split-skin grafting	
2 Fluid and electrolyte therapy, blood transfusion, and management of shock	36
Fluid and electrolyte therapy	
Blood transfusion	
Shock	

Face and neck

3 Primary care of wounds of the face	49
General principles	
Lip	
Tongue	
Ear and nose	
Cellulitis of the face	
4 Eye	53
Basic principles and procedures for eye surgery	
Ocular trauma	
Extraocular surgery	
Intraocular surgery	
Enucleation of the eye	

5	Ear	72
	Removal of foreign bodies	
	Myringotomy	
	Acute mastoiditis with abscess	
6	Nose	76
	Control of epistaxis	
	Removal of foreign bodies	
7	Teeth and jaws	78
	Extraction of teeth	
	The barrel bandage	
	Fractures of the jaw	
8	Throat	84
	Incision and drainage of peritonsillar abscess	
	Incision and drainage of retropharyngeal abscess	
	Incision and drainage of acute abscess of the neck	

Chest, abdomen, and gastrointestinal tract

9	Chest	89
	Tracheostomy	
	Underwater-seal chest drainage	
	Simple rib fracture	
	Flail chest	
	Pneumothorax	
	Haemothorax	
	Acute empyema	
	Surgical emphysema and mediastinal injuries	
	Incision and drainage of breast abscess	
10	Abdomen (general)	100
	Laparotomy	
	Repair of burst abdomen	
	Abdominal injuries	
11	Stomach and duodenum	113
	Feeding gastrostomy	
	Perforated peptic ulcer	
12	Gallbladder and spleen	119
	Cholecystostomy	
	Ruptured spleen	
13	Small intestine	125
	Resection and end-to-end anastomosis	
	Repair of typhoid perforation of the ileum	

14	Appendix	130
	Acute appendicitis	
	Appendicular abscess	
	Appendicular mass	
15	Colon	135
	Colostomy	
	Sigmoid volvulus	
16	Anus and rectum	141
	Rectal examination	
	Proctoscopy	
	Sigmoidoscopy	
	Haemorrhoids	
	Anal fissure	
	Incision and drainage of perianal and ischiorectal abscesses	
	Rectal prolapse	
17	Herniae	151
	Inguinal hernia	
	Femoral hernia	
	Strangulated groin hernia	
	Umbilical and paraumbilical hernia	
	Epigastric hernia	
	Incisional hernia	

Urogenital system¹

18	Urinary bladder	167
	Drainage	
	Management of ruptured bladder	
19	Male urethra	177
	Urethral dilatation	
	Rupture of the urethra	
20	Male genital organs	181
	Scrotal hydrocele	
	Circumcision	
	Vasectomy	
	Exploration of scrotal contents	

Paediatric surgery

21	General principles for paediatric surgery	193
	Special considerations	
	Cut-down to umbilical vein	

¹For detailed descriptions of obstetric and gynaecological procedures, see *Surgery at the district hospital: obstetrics, gynaecology, orthopaedics, and traumatology* (Geneva, World Health Organization, in preparation).

22	Abdominal wall and gastrointestinal tract	196
	Operative reduction of intussusception	
	Rectal prolapse	
	Relief of strangulated inguinal hernia	
23	Urethra and genital organs	201
	Meatal dilatation	
	Exploration of scrotal contents	
	Treatment of paraphimosis	
	Annex 1 Surgical trays	205
	Annex 2 Essential surgical instruments, equipment, and materials for the district hospital	217
	Index	227

Preface

This handbook is one of three¹ to be published by the World Health Organization for the guidance of doctors providing surgical and anaesthetic services in small district hospitals (hospitals of first referral) with limited access to specialist services. The advice offered has been deliberately restricted to procedures that may need to be carried out by a young doctor with limited experience in anaesthesia, surgery, or obstetrics, using the facilities that can reasonably be expected in such hospitals. Wherever possible, the drugs, equipment, and radiodiagnostic and laboratory procedures described conform with WHO and UNICEF recommendations.

Although the handbooks contain detailed descriptions and illustrations, the advice they offer is no substitute for practical experience. The reader is expected to have been exposed to all the relevant techniques during undergraduate or early postgraduate education. When necessary the text indicates which patients should be referred for specialized care at a higher level, as it is important to developing health services that young doctors and their superiors understand the limitations of practice at the district hospital.

It has, of course, been necessary to be selective in deciding what to include in the handbooks, but it is hoped that any important omissions will be revealed during field testing. WHO would also be pleased to receive comments and suggestions regarding the handbooks and experience with their use. Such comments would be of considerable value in the preparation of any future editions of the books. Finally, it is hoped that the handbooks will fulfil their purpose – to help doctors working at the front line of surgery throughout the world.

The three handbooks have been prepared in collaboration with the following organizations:

Christian Medical Commission
International College of Surgeons
International Council of Nurses
International Federation of Gynaecology and Obstetrics
International Federation of Surgical Colleges
International Society of Burn Injuries
International Society of Orthopaedic Surgery and Traumatology
League of Red Cross and Red Crescent Societies
World Federation of Societies of Anaesthesiologists
World Orthopaedic Concern.

¹Also available: *Anaesthesia at the district hospital*; and in preparation: *Surgery at the district hospital: obstetrics, gynaecology, orthopaedics, and traumatology*.

Acknowledgements

This handbook has been prepared as part of a collaborative activity between WHO and the International Federation of Surgical Colleges, which reviewed and endorsed the draft manuscript and illustrations. The editors acknowledge the valuable suggestions received from Dr G. Isaksson, Lund, Sweden, and Mnene Hospital, Mberengwa, Zimbabwe, and from Mr R.F. Rintoul, Nevill Hall Hospital, Abergavenny, Wales. Acknowledgements are also due to Churchill Livingstone, Edinburgh, the publishers of *Farquharson's textbook of operative surgery* (6th edition, 1978), for permission to adapt the drawings for Figures 13.1D, 16.1A, 18.3C,F, and 18.5A,B.

Contributors

Professor E.A. Badoe, Professor of Surgery, University of Ghana Medical School, Accra, Ghana

Professor R. Carpenter, Professor and Head, Department of Surgery, University of the West Indies, Kingston, Jamaica

Mr J. Cook, Consultant Surgeon, Department of Surgery, Eastern General Hospital, Edinburgh, Scotland

Ms J.S. Garner, Chief, Prevention Activity, Hospital Infections Program, Center for Infectious Diseases, Centers for Disease Control, Atlanta, GA, USA

Dr M. Ijaz-ul-Hassan, Medical Superintendent and Chest Surgeon, Mayo Hospital, Lahore, Pakistan

Dr A.E.O. Wasunna, Medical Officer, Clinical Technology, World Health Organization, Geneva, Switzerland, and Professor of Surgery, University of Nairobi, Nairobi, Kenya

Introductory note

This handbook describes a limited number of surgical procedures. They have been chosen as appropriate for the doctor who does not have a formal surgical training, but who nevertheless has experience, gained under supervision, of all the relevant techniques. With the exception of vasectomy, which may be an important part of national family planning programmes, the procedures included are considered essential for saving life, alleviating pain, preventing the development of serious complications, or stabilizing a patient's condition pending referral. Operations that require specialist skills or that could add unnecessarily to the doctor's workload have been avoided, and simple but standard surgical techniques have been selected whenever possible. Nevertheless, certain procedures that may appear technically difficult (for example resection and anastomosis of the small intestine) are included because they may offer the best chance of saving a patient's life.

**FUNDAMENTALS OF
GENERAL SURGERY**

For details of radiodiagnostic and laboratory techniques and drugs appropriate for the district hospital, the reader is referred to the following WHO publications:

Manual of basic techniques for a health laboratory. 1980.

PALMER, P.E.S. ET AL. *Manual of radiographic interpretation for general practitioners (WHO Basic Radiological System).* 1985.

WHO Technical Report Series, No. 689, 1983 (*A rational approach to radiodiagnostic investigations: report of a WHO Scientific Group on the Indications for and Limitations of Major X-Ray Diagnostic Investigations*).

WHO Technical Report Series, No. 770, 1988 (*The use of essential drugs: third report of the WHO Expert Committee*).

1

Basic principles and techniques

Surgical operations must satisfy three basic conditions: the wound must be inflicted without pain; haemorrhage must be arrested; and the wound must heal. It is especially the ability to ensure wound healing, by means of aseptic treatment, that has given impetus to modern surgery. Indeed, the necessity for asepsis regulates the conduct of surgeons, the "ritual" of operation, the form of instruments, and even hospital design and construction to such an extent that it is often taken for granted. Yet an understanding of the practical details of this system is imperative for any surgeon.

Asepsis

The most important cause of impaired wound healing is infection. Microorganisms reach the tissues during an operation or during changes of dressings or any other minor interference with the surgical wound. They are carried and transmitted by people (including the patient and anyone else who touches the wound or sheds organisms into the surrounding air), inanimate objects (including instruments, sutures, linen, swabs, solutions, mattresses, and blankets), and the air around a wound (which can be contaminated by dust and droplets of moisture from anyone assisting at the operation or caring for the wound).

The aseptic treatment of a wound is an attempt to prevent contamination by bacteria from all these sources, during the operation and throughout the first week or so of healing. Modern methods of preventing infection in "clean" wounds also include the use of surgical techniques designed to make the wound less receptive to bacterial growth: *gentle handling, sharp dissection, good haemostasis, and accurate apposition of the wound edges without tension when the wound is being closed.* Bacteria can never be absolutely eliminated from the operating field, but practicable aseptic measures can reduce the risk of contamination to an acceptable level.

Asepsis is influenced by innumerable details of operating technique and behaviour. The probability of wound infection increases in proportion to the number of breaches of aseptic technique. There is no great difficulty in applying this technique to a single operation, but in practice the surgical team will be gathered for several operations — an operating list. Between operations the theatre floor is cleaned, instruments are resterilized, and fresh linen is provided. Potential breaches of aseptic technique can be minimized by proper ordering of patients on the list so that "clean" operations are done first. The longer the list the greater the chances of error; the risk of wound infection therefore increases as the list proceeds. For this reason, the surgeon should carefully consider the length and order of the list. A list system should not be considered at all without a certain minimum of equipment and a well-trained theatre staff.

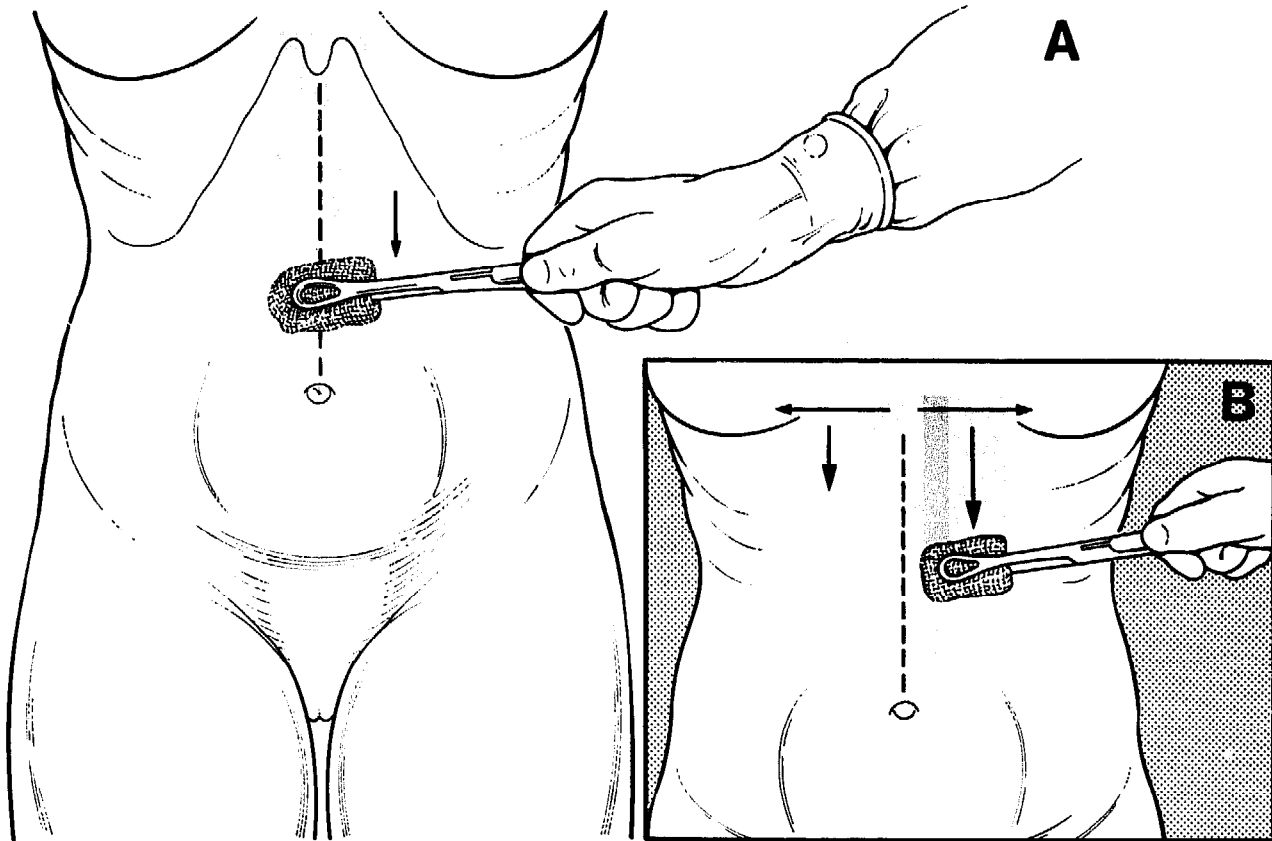


Fig. 1.1. Preparation of the skin with antiseptic solution. Working from the centre of the operating field (A) to the periphery (B).

Certain types of surgery, which are beyond the scope of the practice described here, require an exceptionally strict aseptic routine. But for the most part, safe surgery depends on well-tried and well-understood systems of asepsis, which are practicable in the district hospital. Asepsis depends on personal discipline and careful attention to detail, rather than on antibiotics and complicated equipment. There is no doubt that the level of discipline in operating theatres has declined since the dangers of wound infections have been mitigated by antibiotics. Antibiotics, however, play little part in actually preventing wound contamination. This remains to be achieved by attention to people, inanimate objects, and air.

Preparation for surgery

The patient

The patient's stay in hospital before an operation should be as short as possible. Therefore, any tests and treatment that could prolong the preoperative stay beyond 24 hours should be carried out as outpatient services, if possible. Before the operation, correct gross malnutrition, treat serious bacterial infection, investigate and correct gross anaemia, and control diabetes. As a *routine*, measure the patient's haemoglobin level and test the urine for sugar and protein.

Skin preparation

The patient should bathe the night before an elective operation. Hair in the operative site should not be removed unless it will interfere with the surgical procedure. If it must be removed, clipping is preferable to shaving (which can damage the skin) and should be done as close as possible to the time of operation.

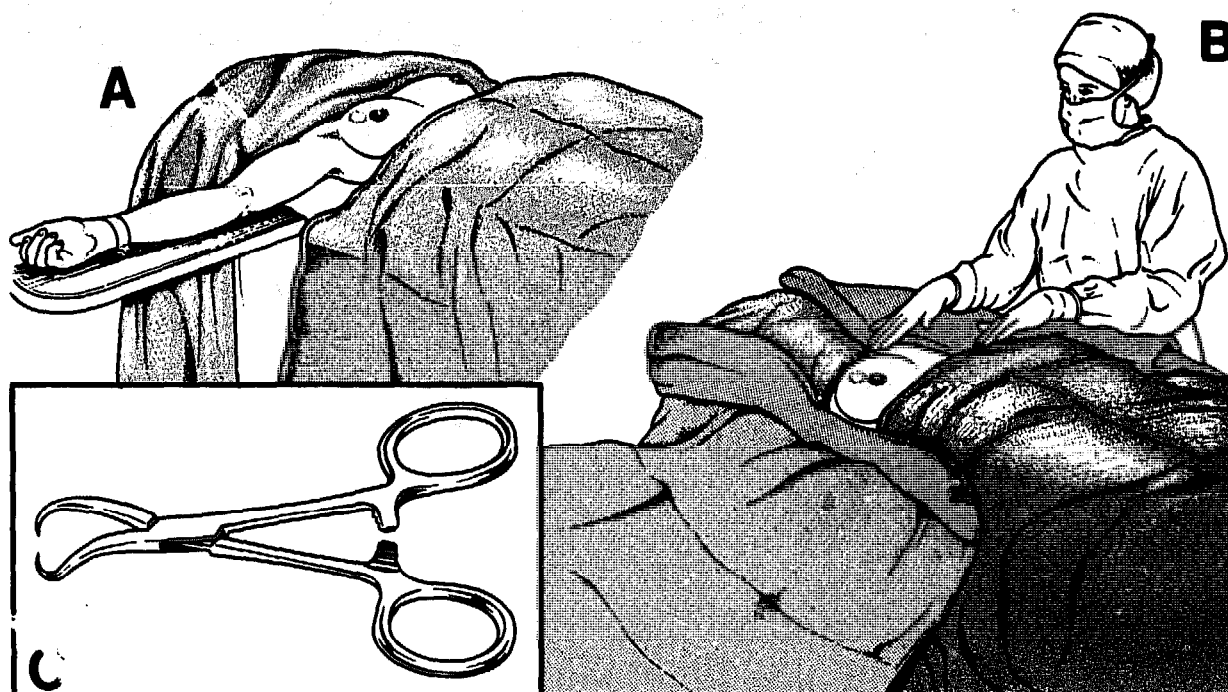


Fig. 1.2. Draping the patient. The operating field is isolated (A, B) and the drapes are secured with towel clips (C) at each corner.

Just before the operation, wash the area around and including the operative site, and prepare the skin with antiseptic solution, starting in the centre and moving out to the periphery (Fig. 1.1). This area should be large enough to include the entire incision and an adjacent working area, so that you can manoeuvre during the operation without touching unprepared skin. Ethanol 70% (by volume) is recommended as an antiseptic, except for delicate skin, such as that of the genitalia and near the eye, and for children; 1% cetrimide (10 g/litre) is an alternative, as is 2.5% iodine in ethanol (25 g/litre).

For major operations involving an incision and requiring the use of the operating room, cover the patient with sterile drapes, leaving no part uncovered except the operative field and those areas necessary for the maintenance of anaesthesia (Fig. 1.2).

Duties towards the patient

It is your duty to discuss with the patient the need for surgery and to explain in simple terms the nature of the proposed operation. Ensure that the patient understands, particularly if the operation involves amputation of a limb, removal of an eye, or construction of a colostomy, or will render the patient sterile, for example hysterectomy for a ruptured uterus. You *must* obtain the patient's (or, if necessary, a close relative's) informed consent for the operation. It is your responsibility to ensure that the side to be operated on is clearly marked; recheck this just before the patient is anaesthetized. Also check that all relevant pre-operative care, including premedication, has been given. The patient's notes, laboratory reports, and radiographs must accompany him or her to the operating room.

The surgical team

Anyone entering the operating room, for whatever reason, should first put on clean clothes, an impermeable mask to cover the mouth and nose, a cap or hood to cover all the hair on the head and face, and a clean pair of shoes or clean shoe-covers.

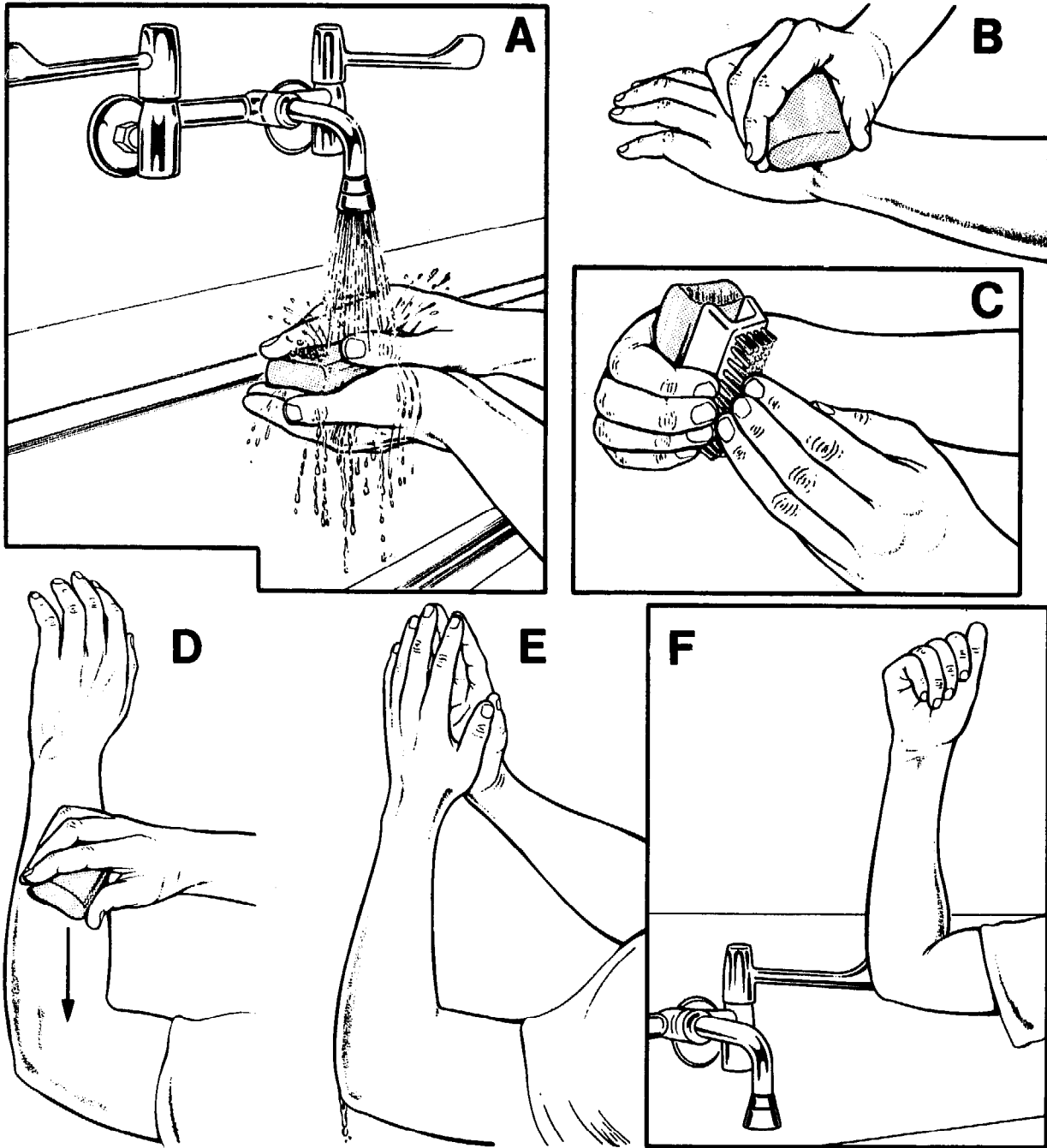


Fig. 1.3. Scrubbing up. Washing with soap and running water (A); further application of soap (B) before scrubbing the fingernails (C); washing the forearms with soap and running water (D); position of hands and forearms at the end of scrubbing to allow water to drip off the elbows (E); turning off the tap with the elbow (F).

Scrubbing up

Before each operation, all members of the surgical team — that is, those who will touch the sterile surgical field, sterile instruments, or the wound — should cleanse their hands and arms to the elbows, using soap, a brush (on the nails and finger tips), and running water (Fig. 1.3). The team should scrub up for at least 5 min before the first procedure of the day, but between consecutive clean operations a minimum of at least 3 min is acceptable.

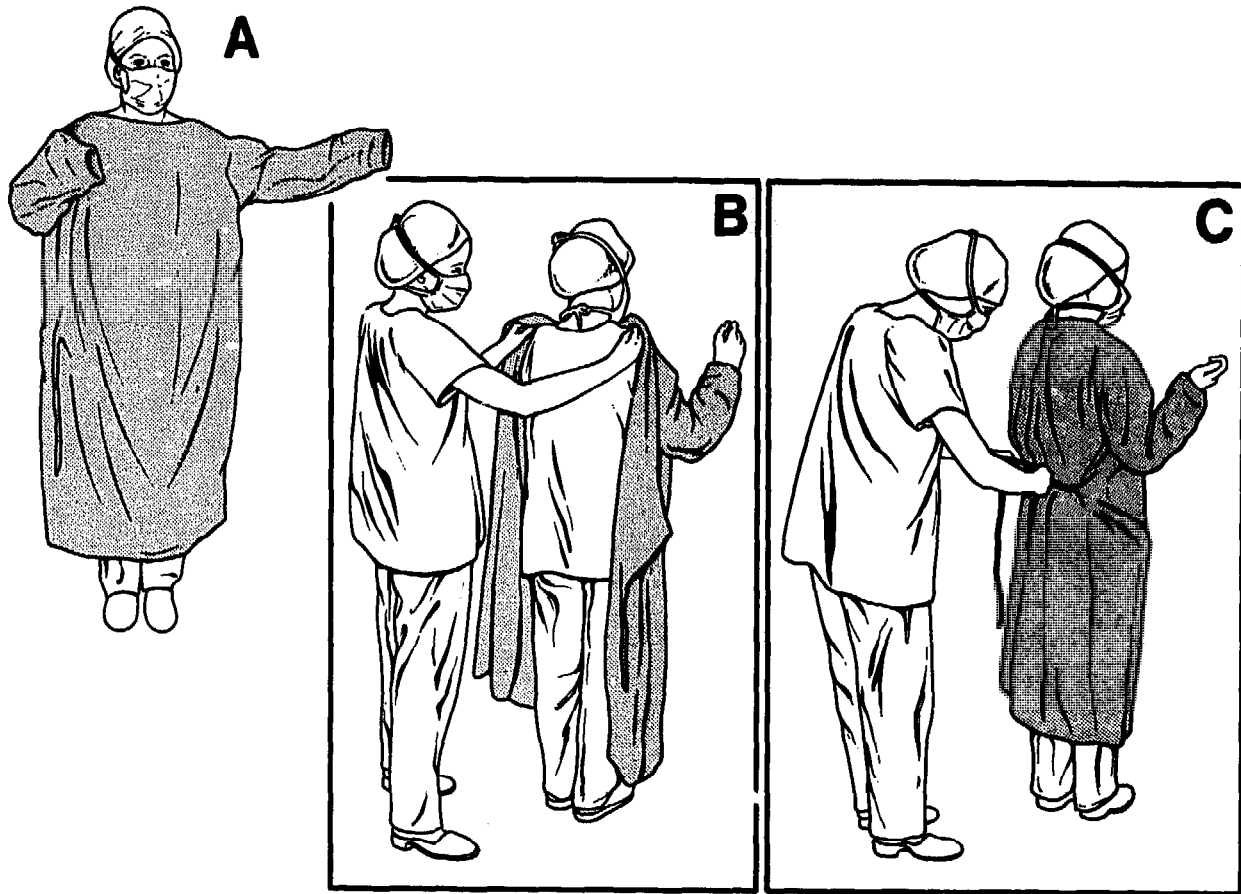


Fig. 1.4. Putting on the sterile gown (A); an assistant adjusts the gown (B) and ties the straps (C).

After scrubbing their hands and drying them with sterile towels, the members of the surgical team should put on sterile gowns and sterile gloves (Fig. 1.4 & 1.5). A glove punctured during the operation should be promptly changed.

The operating room

Keep all doors to the operating room closed, except as needed for the passage of equipment, personnel, and the patient. Keep to a minimum the number of personnel allowed to enter the operating room, especially after an operation has started. Clean the operating room between operations, and more thoroughly at regular intervals, according to procedures established by the hospital. When necessary, the operating room may be disinfected by mopping the floor, swabbing down the walls, and wiping all furniture with a liquid disinfectant, *diluted as recommended by the manufacturer*. Sterilize all surgical instruments and supplies.

Sterilization

The methods of sterilization in wide use are autoclaving, exposure to dry heat, and treatment with chemical antiseptics.

Autoclaving

At the district hospital, sterilization should be largely based on autoclaving (Fig. 1.6A,B). For efficient use, an autoclave demands a trained operator in regular practice and depends heavily on good maintenance. Most autoclaves in current use are too large and too complicated, and carry high maintenance costs. It is therefore hoped that more effort will be put into developing smaller and simpler autoclaves that require little maintenance and are possibly solar-powered, especially for use in isolated rural hospitals in developing countries.

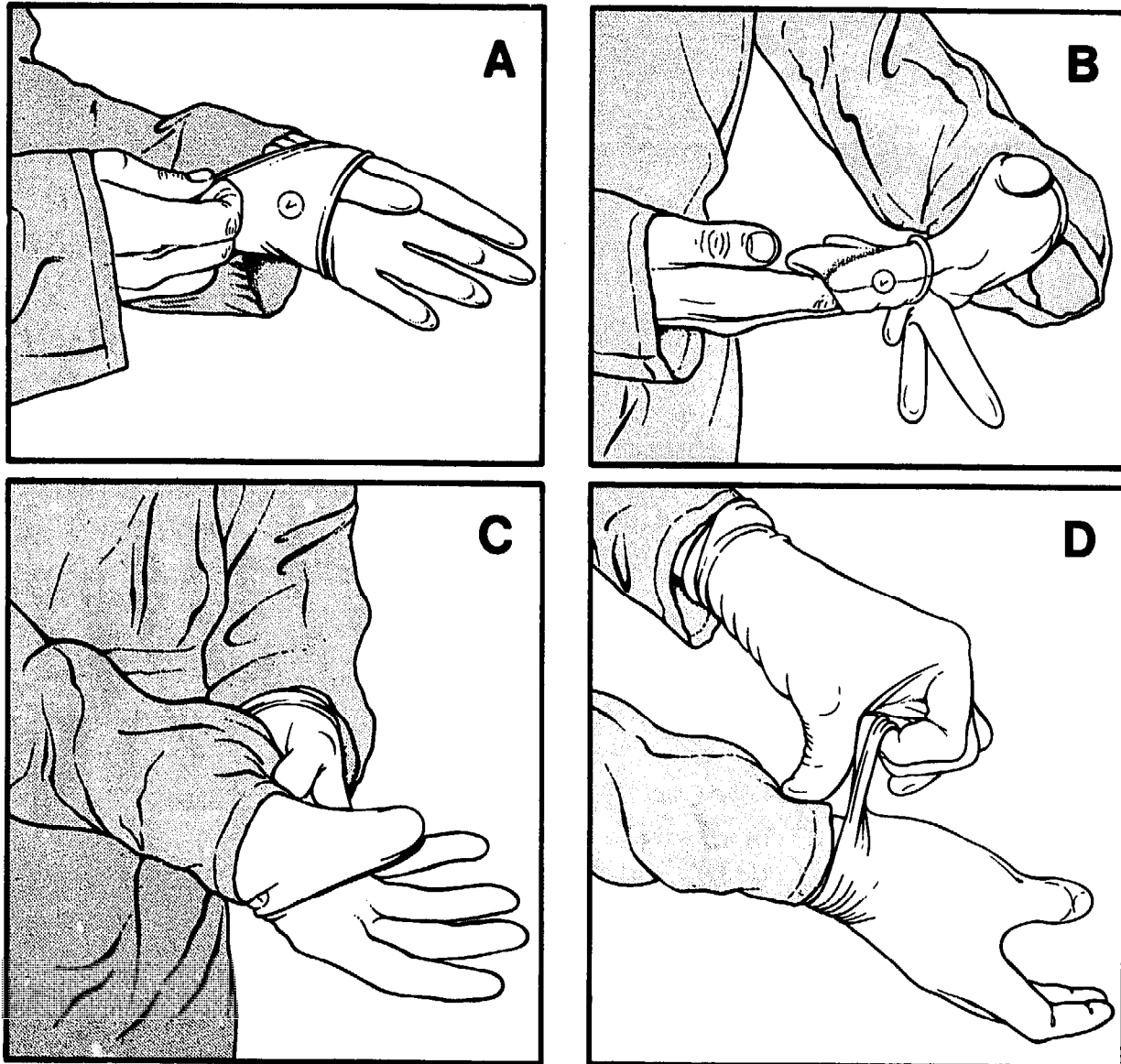


Fig. 1.5. Putting on sterile gloves. Starting with one hand (A) and proceeding to the second (B); folding the sleeves of the gown (C) and tucking them into the gloves (D).

The selection of a suitable autoclave requires serious consideration not only of the cost but also of servicing needs and the expected work-load. Desirable features of an autoclave are a horizontal cylindrical drum, a single circular door, a small chamber capacity, and a short cycle, especially for the post-sterilizing phase. In general, the smaller the capacity, the shorter the whole process and the less the damage to soft materials. It is often more practical to use a small autoclave several times a day than to use a large machine once.

The basic operational criteria for an autoclave are steam at 100.0 kPa (750 mmHg) above atmospheric pressure and a temperature of 120 °C maintained for 15 min (or for 30 min for packs). Appropriate indicators must be used each time to show that sterilization has been accomplished. At the end of the procedure, the outsides of the packs of instruments should have no wet spots, and the moisture retained by each pack should not cause more than a 3% increase in its weight.

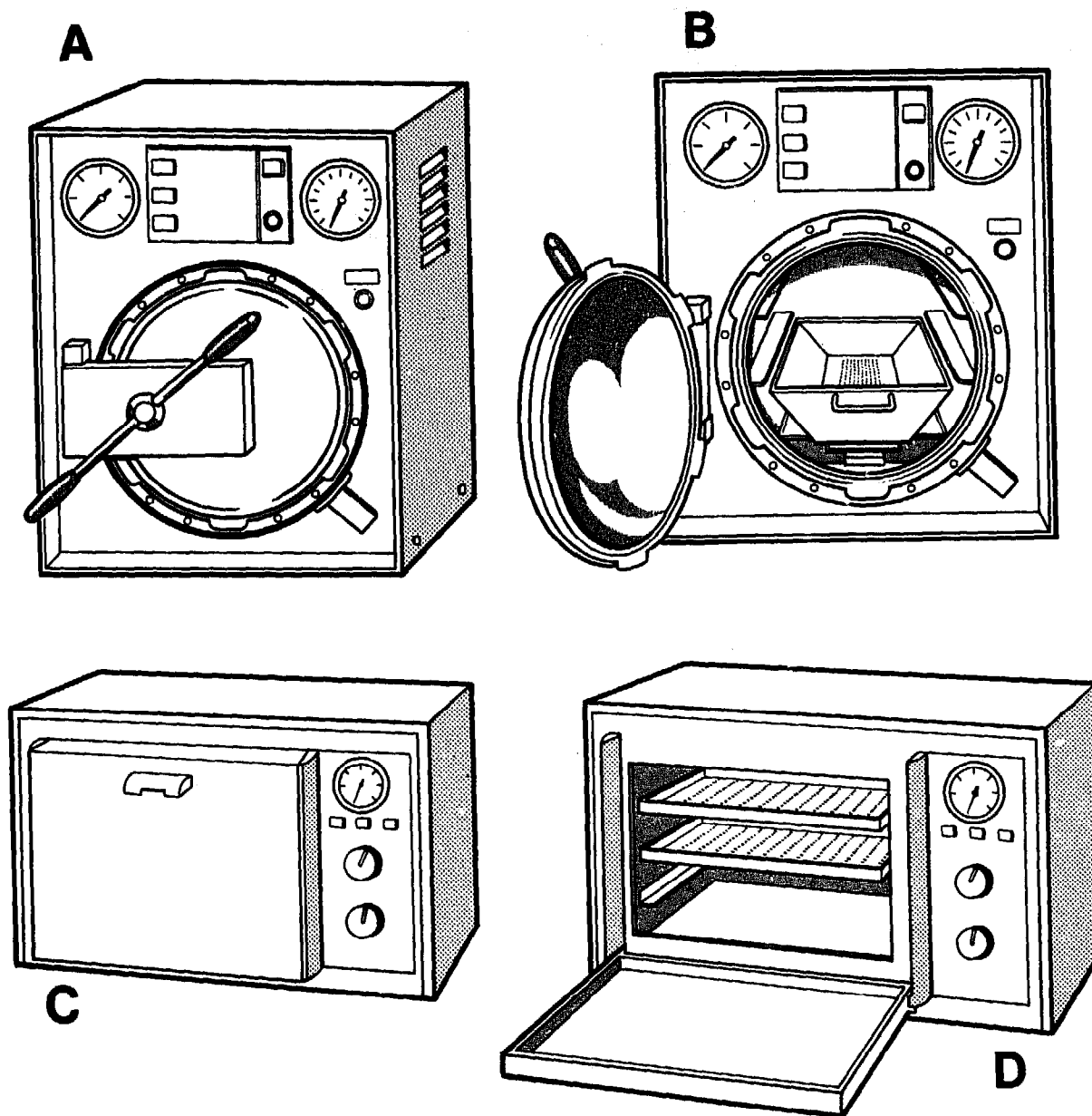


Fig. 1.6. An autoclave (A, B); a hot-air oven (C, D).

Dry heat

Sterilizing by hot air is a poor alternative to autoclaving since it is suitable only for metal instruments and a few natural suture materials. The oven most commonly available is of the type used by bacteriologists to sterilize laboratory glassware (Fig. 1.6C,D). Instruments must be clean and free of grease or oil. They are then sterilized by exposure to a temperature of 170 °C for 2 hours. A fan to circulate the hot air within the oven will improve the efficiency of sterilization.

Other methods

Boiling of instruments is now regarded as an unreliable means of sterilization, and it is not recommended as a routine in hospital practice.

In general, instruments are no longer stored in liquid antiseptic. However, sharp instruments, other delicate equipment, and certain catheters and tubes can be sterilized by exposure to formaldehyde, glutaral (glutaraldehyde), or chlorhexidine. If you are using formaldehyde, carefully clean the equipment and then expose it to vapour from paraformaldehyde tablets in a closed container for 48 hours. Be sure that this process is carried out correctly. Glutaral is a disinfectant that is extremely effective against bacteria, fungi, and a wide range of viruses. Follow manufacturers' instructions for use.

When normal methods of sterilization fail

Failure of an autoclave or a power supply may suddenly interrupt normal sterilization procedures. In such circumstances an antiseptic technique will allow some surgery to continue.

Immerse towels and drapes for 1 hour in a reliable antiseptic such as aqueous chlorhexidine, wring them out, and lay them moist on the skin of the patient. Gauze packs and swabs can be treated similarly, but should be rinsed in diluted (1:1000) chlorhexidine solution before being used in the wound. During the operation, gauze in use should be rinsed from time to time in this solution. Immerse instruments, needles, and natural suture materials in strong antiseptic for 1 hour, and then rinse them in weak antiseptic just before use.

Before entering the operating room, put on a clean, dry surgical gown or apron; if you are a member of the surgical team, pin a moist antiseptic towel over this. Wash gloved hands for 5 min in strong antiseptic and rinse them in a weak solution of the same. If gloves are not available, wash the bare hands for at least 5 min in clean, preferably running water and steep them briefly in 70% ethanol. Allow them to dry before touching the wound.

Prevention of transmission of human immunodeficiency virus (HIV)

All body fluids from a person infected (or suspected of being infected) with HIV should be considered potentially infectious. HIV may be transmitted: (1) by needles or sharp instruments contaminated with blood or body fluids and not properly sterilized; (2) by contact between open wounds, broken skin (for example caused by dermatitis), or mucous membranes and contaminated blood or body fluids; and (3) by transfusion of infected blood or blood products, semen donation, and skin or organ transplantation. The prevention of HIV infection requires special attention to these means of transmission as well as the strict application of aseptic routine.

Most of the small number of reported infections of health workers with HIV have resulted from injuries caused by needles (for example during recapping) and other sharp instruments. After use, disposable needles and scalpel blades should be put into a puncture-proof receptacle, preferably containing a sodium hypochlorite disinfectant. Reusable needles should also be placed in a special container of disinfectant before being cleaned and sterilized.

Surgical gloves prevent transmission of HIV through contact with blood, but there is always the possibility of accidental injury and of a glove being punctured. Thick gloves should therefore be worn when needles and sharp instruments are being cleaned. Where HIV infection is prevalent among patients, needles and instruments should routinely be soaked in a chemical disinfectant for 30 min before cleaning.

Linen soiled by a patient who is or may be infected with HIV should be handled with gloves and should be collected and transported in leak-proof bags. It should be washed with detergent for 25 min at a temperature of at least 71 °C. If this is

not possible, it should be soaked in a hypochlorite disinfectant before washing.

Liquid wastes, such as blood and fluids removed by suction, should be carefully poured down a drain connected to a sewer or into a pit latrine. Otherwise, they should be chemically disinfected. Solid waste should be incinerated or disposed of in a pit latrine; chemical disinfection may be a temporary expedient.

Proper sterilization of all surgical instruments and supplies is crucial in preventing HIV transmission. All viruses, including HIV, are inactivated by steam sterilization (autoclaving) for 20 min at 100 kPa above atmospheric pressure or by dry heat in an oven for 2 hours at 170 °C.

Several points of aseptic routine applicable to members of the surgical team are also particularly relevant to the prevention of transmission of HIV:

- Areas of broken skin and open wounds should be protected with watertight dressings.
- Gloves should be worn during exposure to blood or body fluids and the hands should be washed with soap and water afterwards.
- Frequent use of ethanol or other antiseptics on the hands and arms should be avoided, because it may lead to broken skin.
- Protective glasses should be worn where blood splashes may occur, as during major surgery; if the eyes are inadvertently splashed, they should be washed out as soon as possible with saline.

It should be appreciated that the whole purpose of the aseptic method is to prevent transmission of infection, and that strict attention to every detail of asepsis, with special care to avoid accidental injury during operation, is the best protection against HIV.

Surgical methods and materials

Anaesthesia

It is the anaesthetist's responsibility to provide safe and effective anaesthesia for the patient. The anaesthetic of choice for any given procedure will depend on the anaesthetist's training and experience, the range of equipment and drugs available, and the clinical situation. For a detailed discussion of anaesthetic techniques suitable for the surgical operations described here, see Dobson, M.B., *Anaesthesia at the district hospital* (Geneva, World Health Organization, 1988).

Operative technique

The surgical team should strive to handle tissues gently, to prevent bleeding, to minimize dead space and the amount of devitalized tissue and foreign material in the wound, and to work efficiently to avoid prolonging the operation unnecessarily. Plan the incision to give adequate exposure. Incise the skin with bold sweeps of the belly of the knife, while stretching the skin between the thumb and fingers of the other hand (Fig. 1.7). Control initial oozing of blood from the cut surfaces by pressure over gauze. Individual bleeding vessels may be caught in fine forceps and twisted off or ligated with fine catgut or fine thread (Fig. 1.8). Cut the ligature short. As a routine, use a reef knot, but make a triple knot or a surgeon's knot if additional security is required. Avoid diathermy near the skin. Similarly deepen the wound to reach the target organ, making sure that the wound is laid open along its whole length. A clean knife is commonly used to gain access to a body cavity, for example for incising the peritoneum.

Close the operation wound in layers with catgut, thread, or nylon (but avoid thread in potentially contaminated wounds because it can form a focus for infection). Use different types of sutures as appropriate, for example simple, interrupted, continuous, mattress, or purse-string. Aim to bring the wound edges

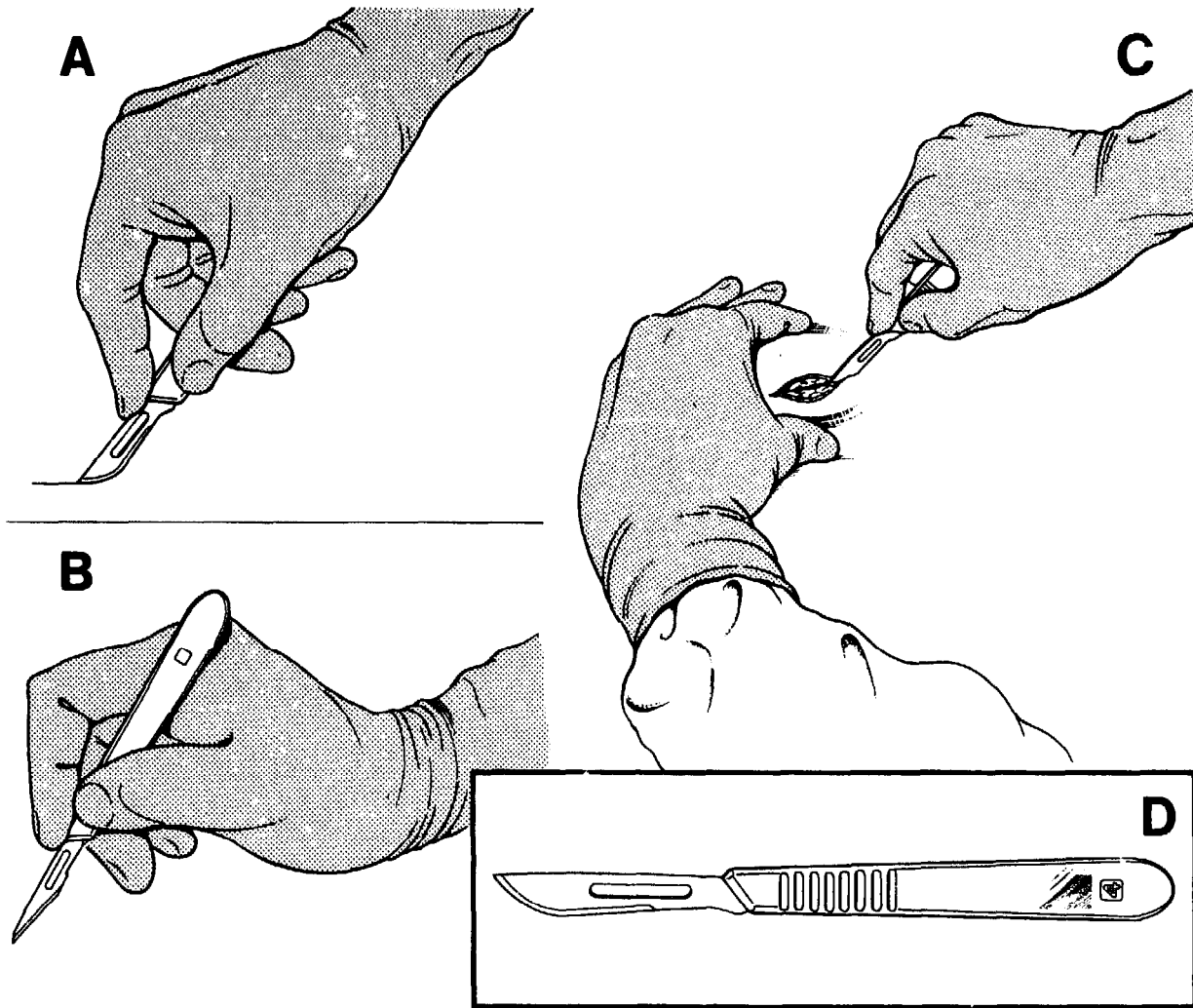


Fig. 1.7. Making an incision. Alternative ways of holding the knife (A, B); stretching the skin between the fingers and thumb (C); a skin knife (D).

together loosely, but without gaps, taking a "bite" of about 1 cm of tissue on either side and leaving an interval of 1 cm between each stitch (Fig. 1.9A–D). Remember that a "suspect" (possibly contaminated) or grossly contaminated wound is best left open and lightly packed with plenty of dry gauze, with sutures inserted for delayed primary closure after 2–5 days (Fig. 1.9E,F).

Suture materials

Sutures and ligatures consist of absorbable or non-absorbable materials. Catgut remains the most popular absorbable material because of its pliability and superior handling qualities. Chromic catgut lasts for 2 or 3 weeks in the tissues and is excellent for ligatures and for approximating tissues, though it is no longer used for closing abdominal wounds and in other situations where prolonged support is needed, because of the rapid loss of tensile strength as it is absorbed. Plain catgut is absorbed in 5–7 days, but is useful when healing is expected within this period, and for suturing the bladder mucosa.

Non-absorbable materials include braided lengths of natural products (such as silk, linen, and cotton) and synthetic monofilaments (such as nylon and polypropamide). Choice among these materials depends on cost, availability, indi-

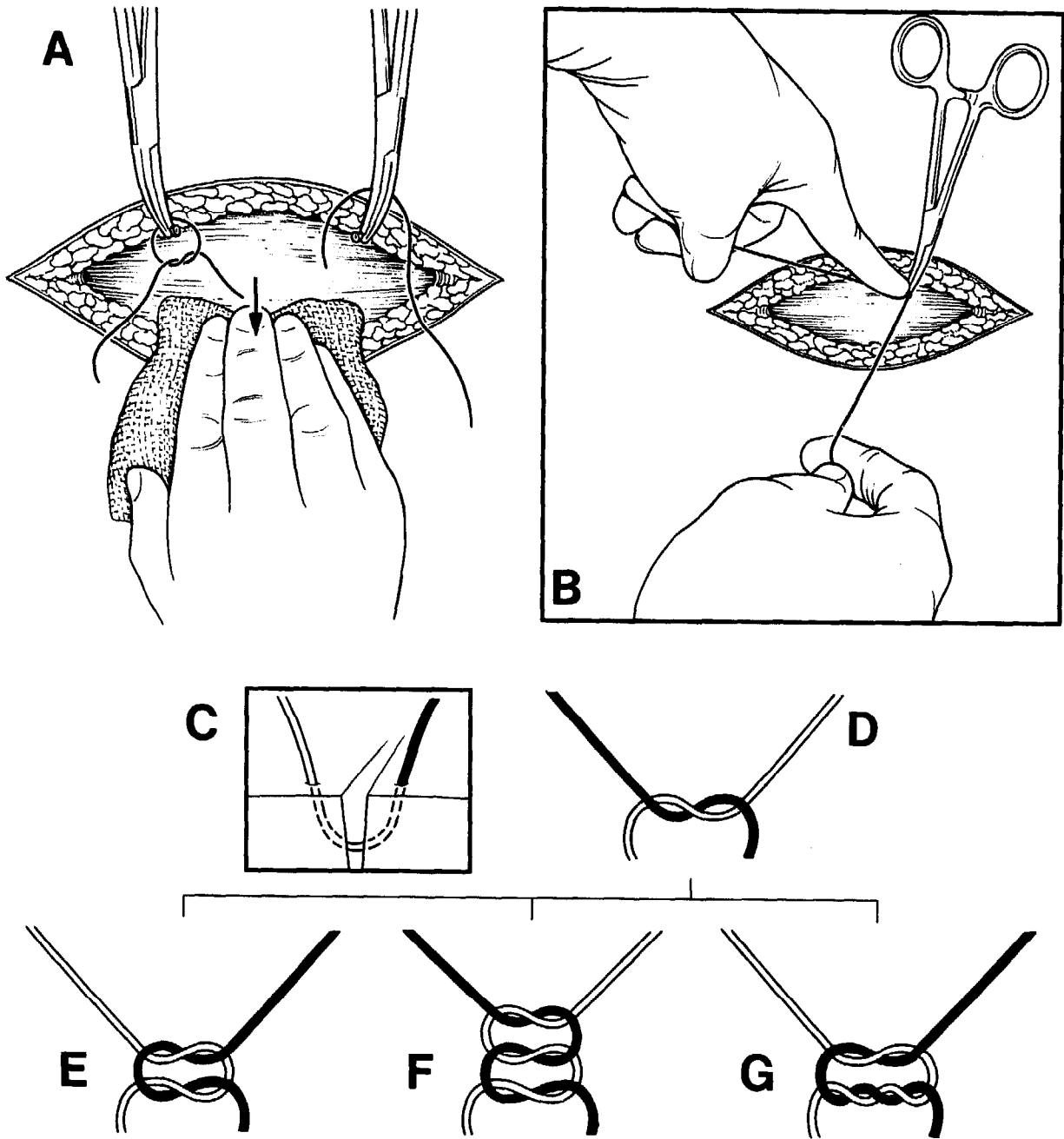


Fig. 1.8. Control of bleeding by ligation and by pressure over gauze (A); the ligature knot is pushed well down (B); suture ready for tying (C); making a knot (D): a reef (square) knot (E); a triple knot (F); a surgeon's knot (G).

vidual preference in handling, security of knots, and the behaviour of the material in the presence of infection. In this book braided materials are referred to as "thread" and synthetic monofilament materials as "nylon".

Never use thread for sutures deep in a wound that may be contaminated. Monofilament nylon, however, may be left in the deeper layers; it is better used as a continuous stitch, as its knots are less secure than those of thread. All varieties of suture material may be used in the skin. Thread is easier to use for

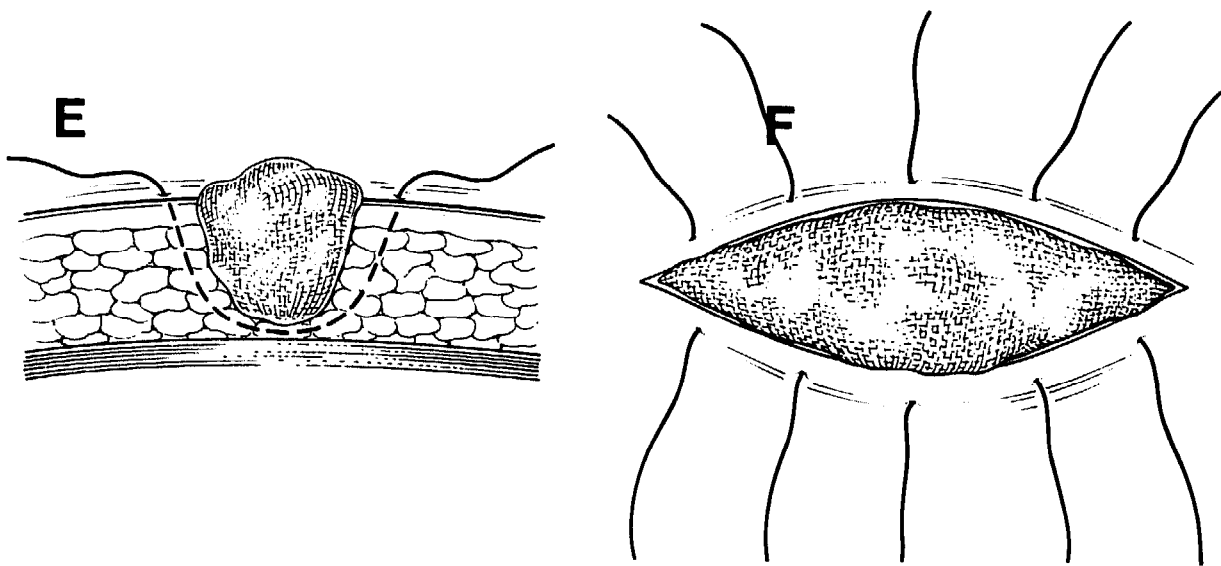
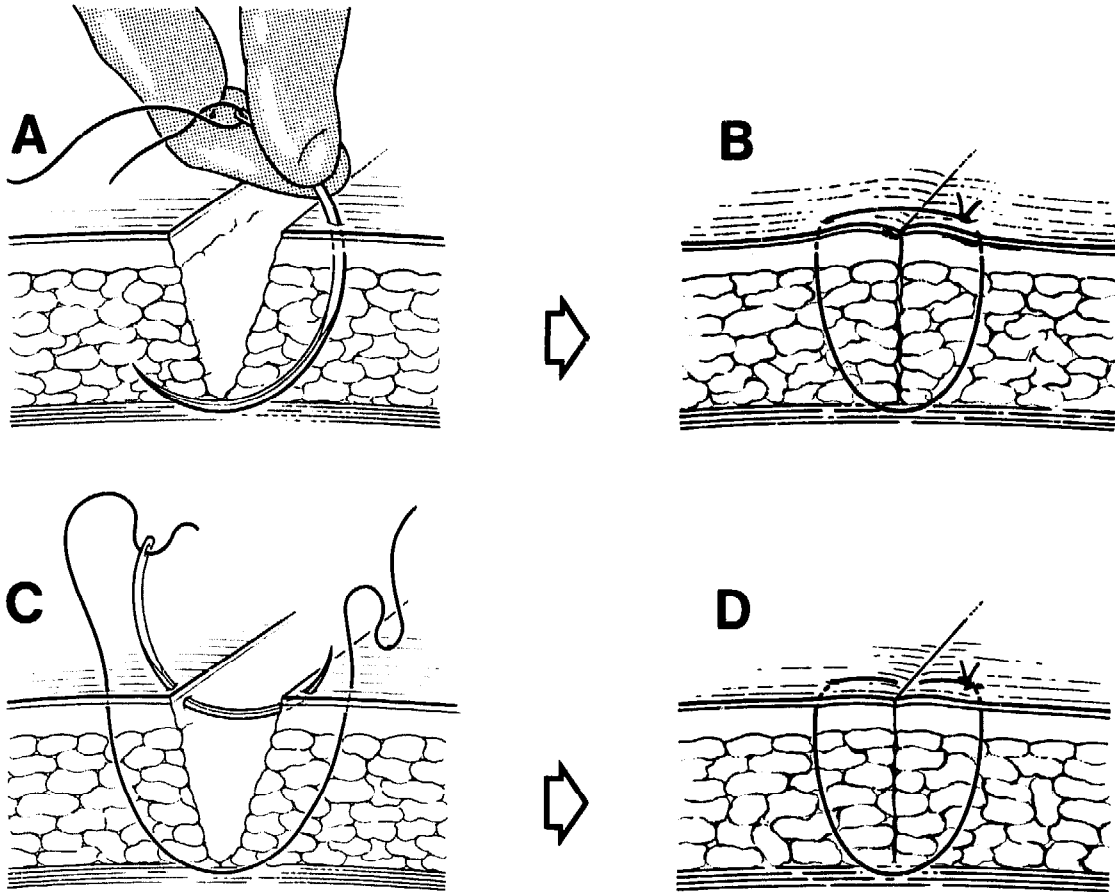


Fig. 1.9. Skin closure. Inserting and tying a simple stitch (A, B); inserting and tying a mattress stitch (C, D); packing a contaminated wound and inserting sutures for delayed primary closure (E, F).

interrupted stitches, while nylon marks the skin least and is convenient for continuous stitches. Use absorbable material in the urinary tract to avoid the encrustation and stone formation associated with non-absorbable sutures.

Size and strength of materials

Sutures are graded according to size on two scales: an old system that runs upwards from 0 to 4 and downwards to about 6/0, and a metric system running from 0 to 8. Most surgeons continue to use the old gauge, and this is referred to throughout the text; a rough conversion table is given below.

<i>Old</i>	6/0	5/0	4/0	3/0	2/0	0	1	2	3	4
<i>Metric</i>	1	1.5	2	2.5	3	4	5	6	7	8

Most common operations can be completed with suture materials between sizes 3/0 and 1. The strength of sutures varies little between the usual materials.

Use of drains

Drains are no substitute for good surgery, but when indicated, they should be retained for no longer than 72 hours. The ideal drainage is by suction, but when this is not available you may substitute a corrugated latex drain running into a closed colostomy bag (Fig. 1.10). When neither suction nor a colostomy bag is available, use a corrugated drain running into gauze dressings, though this is far from satisfactory. India rubber drains should not be used.

Use of antimicrobial drugs

Patients often present with infections requiring treatment with antimicrobial drugs or develop such infections after operation. When antimicrobial treatment is indicated, keep in mind several principles:

Treatment of infections

- systemic rather than topical agents should be used, except for the eye;
- narrow-spectrum antimicrobial drugs directed against specific organisms should be used whenever possible, as broad-spectrum drugs can lead to superinfection and favour the selection of resistant microorganisms;
- the choice of a particular agent from a broad group of antimicrobial drugs should depend on the target microorganism, if known, and its drug sensitivity, and on factors such as the drug's antimicrobial spectrum, record of use in the clinic, safety, efficacy, and potential to favour the selection of resistant organisms;
- cost should determine the choice of drug when microbiological, pharmacological, and other relevant properties are similar for several agents;
- antimicrobial treatment should be discontinued as soon as the patient's clinical condition permits.

Prophylaxis

Parenteral antimicrobial prophylaxis should not be routine, but is recommended for operations associated with a high risk of infection, for example bowel resection. It is also recommended for operations after which infection, although not a frequent problem, can have severe or life-threatening consequences (for example craniotomy). In addition, antimicrobial prophylaxis is essential for patients with valvular heart disease, who are at risk of developing bacterial endocarditis as a result of transient bacteraemia from instrumentation in the mouth or other parts of the body.

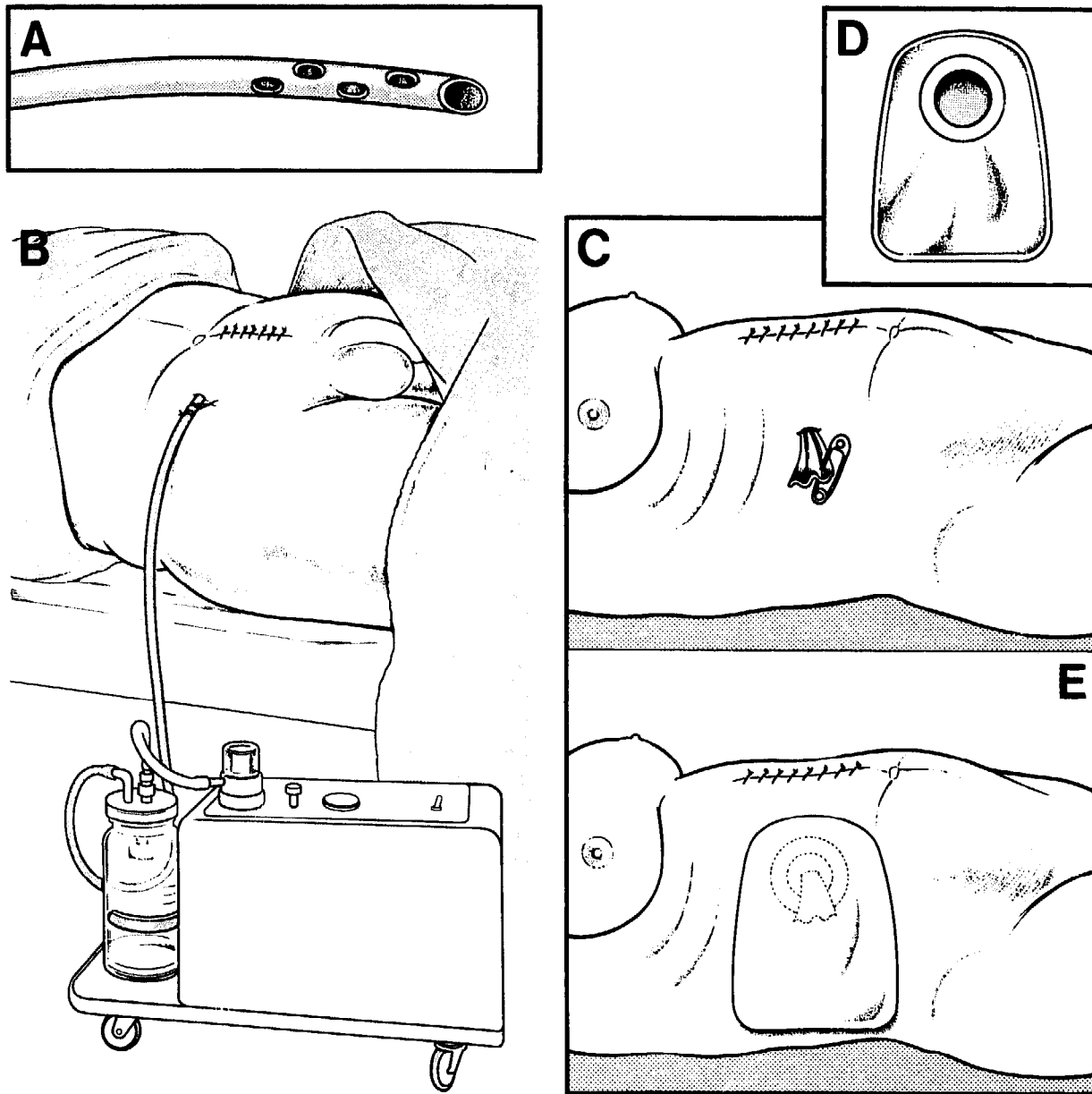


Fig. 1.10. Drainage. Drainage by suction through a tube with several holes (A, B); a corrugated latex drain (C); drainage into a colostomy bag (D, E).

Start parenteral antimicrobial prophylaxis immediately before the operation and continue it for 1–2 days.

Wound care

Generally, do not close wounds by primary suture if they are or may be contaminated, and do not touch an open wound directly with bare, unsterilized hands. A repaired wound can be regarded as sealed after 24 hours, and dressings may then be changed without sterile gloves but with a “no-touch” technique.

Remove dressings over closed wounds if they become wet or if the patient shows signs or symptoms suggestive of infection, for example fever or unusual wound pain. After removing the dressing, inspect the wound for signs of infection and sample any discharge for bacteriological examination.

Records

Keeping accurate records on patients is the doctor's responsibility. Write down all clinical information about the patient immediately after such information is obtained. Indicate the date and time for every record made, and ensure that all records are legible and easily understood. Notes on surgical procedures undertaken, including the findings at operation and instructions on postoperative management, must be recorded without delay at the end of every operation. Specific mention should be made of the operation as being either "clean", "clean-contaminated", "contaminated", or "dirty and infected". This will allow for an evaluation of postoperative wound infection rates. Such evaluation, which should be the regular duty of one member of the hospital team, permits assessment of the application of aseptic routine within the hospital.

Even ward patients who are not seriously ill should be assessed at least once a day and progress notes made, if only to indicate that there has been no change in the patient's condition. On discharging the patient from the ward, record the definitive diagnosis and give instructions about his or her further management as an outpatient. Remember that clinical notes are important for review and discussion to determine how patients (including future patients) should be managed, for insurance and medico-legal purposes, and for research.

Wound débridement

Débridement is a procedure used in the initial management of non-surgical wounds to remove dead tissue and foreign material in order to facilitate healing. Wound toilet and débridement are systematic procedures, applied first to the superficial and then to the deeper layers of tissues. Gentle handling of tissues will minimize bleeding, which can be further controlled by local compression or by ligation of the spurting vessels.

Anaesthesia should be provided as appropriate. If necessary, clip or shave hair from around the wound. Wash the wound with toilet soap and water, irrigate it with physiological saline, and scrub the surrounding area thoroughly (Fig. 1.11A,B). There should be no soap left in the wound. Meticulously remove any loose foreign material such as dirt, grass, wood, glass, or clothing and prepare the skin with antiseptic. It is generally wise to extend the wound longitudinally to reveal the full extent of damage. Excise only a very thin margin of skin from the wound edge (Fig. 1.11C).

Excise all dead tissue from the wound (Fig. 1.11D,E). Dead or devitalized muscle will be dark in colour and will be soft or easily torn and damaged; it will not contract when pinched with toothed forceps or bleed when cut. Remove all adherent foreign material along with the dead muscle. In cases of compound fracture, remove only very small, obviously free fragments of bone, provided that their removal does not affect the stability of the fracture. It is unwise to strip muscle and periosteum from a fractured bone.

Vessels, nerves, and tendons that are intact should be left alone after the wound has been cleansed. Ligate divided vessels regardless of whether they are bleeding. Large vessels that have been damaged and contused may need to be divided between ligatures, but first test the effect on the distal circulation by temporary occlusion of the vessel with tape or rubber clamps.

Loosely appose the ends of divided nerves by inserting one or two fine, black silk stitches through the nerve sheath. Tendon ends may be similarly fixed to prevent further retraction. Formal repair of nerves or tendons is best undertaken later, if possible by a specialist surgeon.

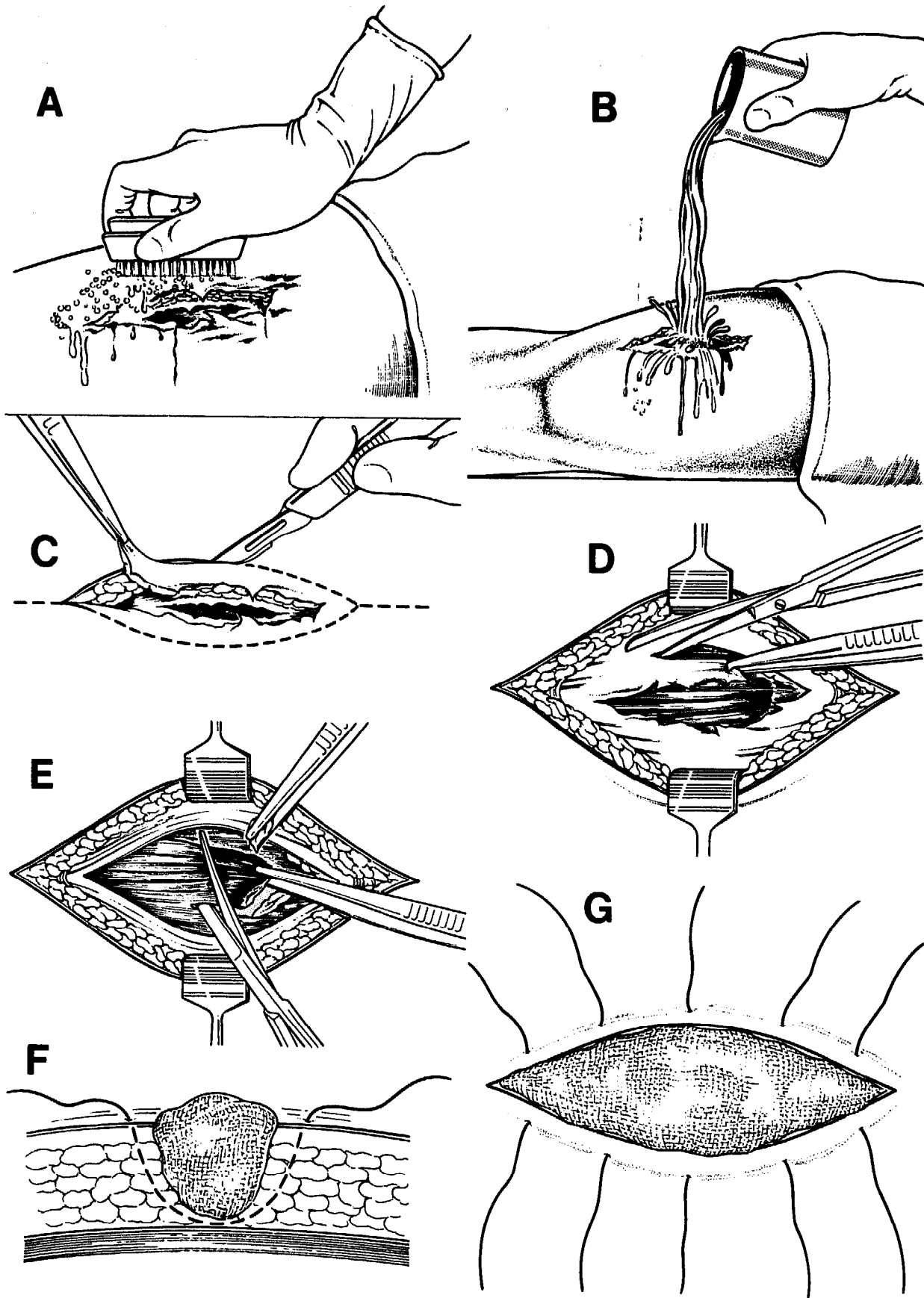


Fig. 1.11. Wound débridement. Washing the wound (A, B); excising a small skin margin (C); excising all dead tissue (D, E); inserting stitches, which are left untied, and packing the wound (F, G).

Generally leave the wound open after débridement, inserting stitches but leaving them untied for delayed primary closure 2–5 days later (Fig. 1.11F,G). Pack the wound lightly with dry, sterile gauze. Always administer tetanus prophylaxis.

Incision and drainage of abscesses

Infections with abscess formation are a major problem in many developing countries. Treatment is often delayed or inadequate. Yet there are few surgical procedures that have as dramatic results, in terms of the patient's satisfaction and confidence in health staff, as the prompt and adequate drainage of an acute abscess.

Incision and drainage of an abscess are indicated if there is evidence of localized pus: throbbing pain; hot, local swelling with tight, shiny skin; and marked tenderness. Fluctuation is the most reliable sign, though it may be absent in a tense or deep abscess. Interference with sleep is a pressing indication for surgery.

For more specific discussion of mastoid, peritonsillar and retropharyngeal, neck, breast, appendicular, and perianal and ischiorectal abscesses, see pages 74, 84, 85, 98, 134, and 148, respectively.

Assessment and preoperative management

If in doubt about the diagnosis, confirm the presence of pus by needle aspiration. (An aneurysm may mimic the features of an abscess, but it pulsates and lies in the line of a major vessel.) Measure the patient's haemoglobin level and test the urine for sugar and protein.

Equipment

See tray for *Incision and drainage of abscess*, Annex 1.

Technique

Prepare the skin with antiseptic, and give a local anaesthetic if necessary. Perform a preliminary needle aspiration to confirm the presence of pus if this has not already been done (Fig. 1.12A).

Make an incision over the most fluctuant or prominent part of the abscess, in a skin crease if possible (Fig. 1.12B). Take a sample of pus for bacteriological examination. Introduce the tip of a pair of sinus or artery forceps into the abscess cavity and open the jaws to improve drainage (Fig. 1.12C). Explore the cavity further with a finger to break down all loculi (Fig. 1.12D).

It may be necessary to extend the incision or convert it into a cruciate form to deroof the abscess completely (Fig. 1.12E,F), but take care not to open up healthy tissues or tissue planes beyond the abscess wall. The abscess cavity can then be cleaned with swabs soaked in saline or antiseptic solution.

Introduce a large corrugated drain, positioning it well into the depth of the cavity. A counter-incision may be necessary to ensure free and dependent drainage. Fix the drain to the edge of the wound or counter-incision with a stitch of 2/0 thread, and mark it with a safety pin before cutting off the excess drain. Dress the wound with several layers of gauze, the gauze of the deeper layers having been first soaked in antiseptic solution and wrung out. Leave the drain in place for about 2 days, until a track has formed through the tissues or until the drainage is minimal. Alternatively, pack the abscess cavity with a ribbon of petrolatum gauze, leaving one end outside the wound, marked with a safety pin. Control excessive bleeding from the cavity by tight packing with dry gauze; this may be removed after about 12 hours and replaced with a petrolatum gauze pack or a drain.

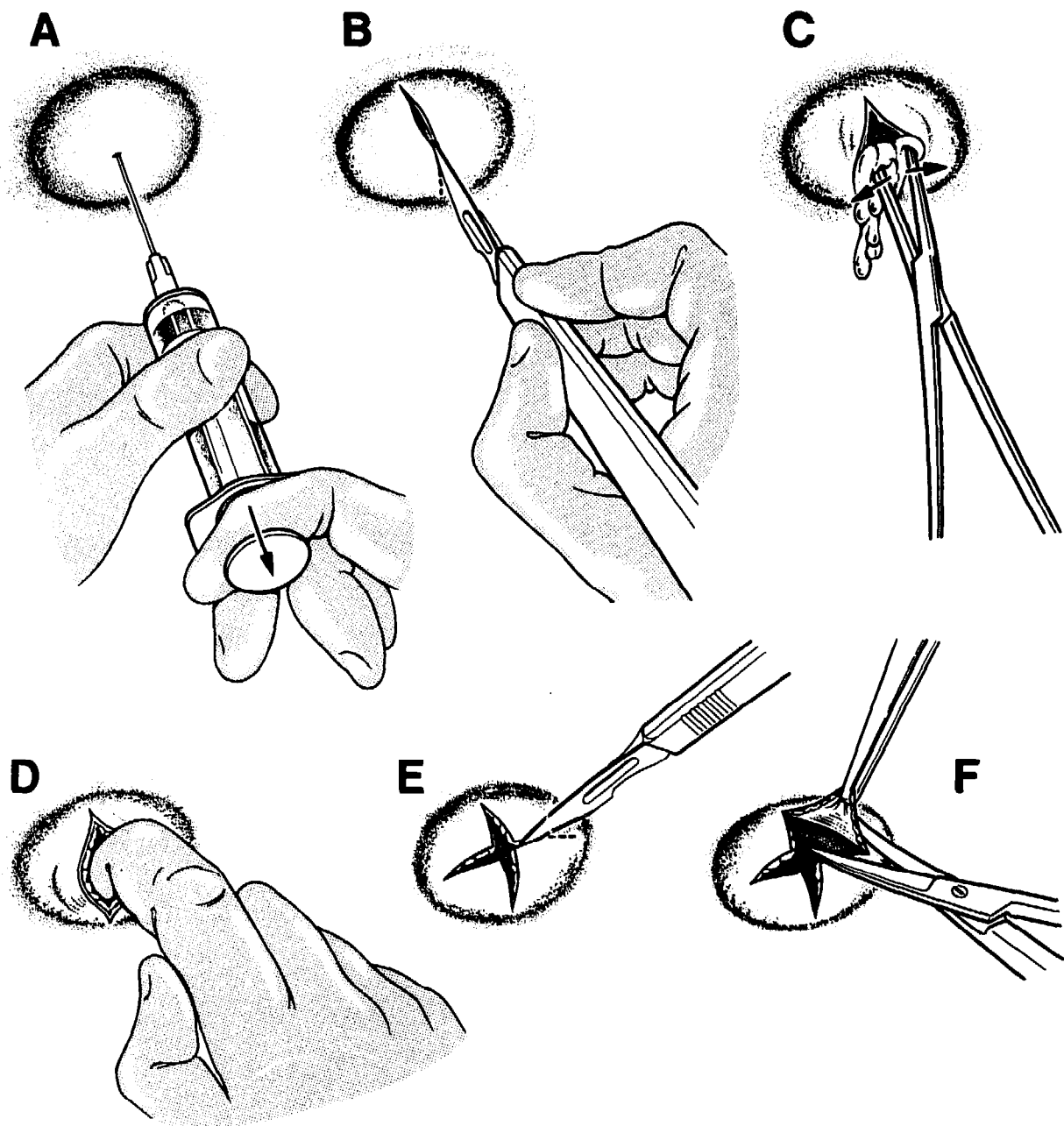


Fig. 1.12. Incision and drainage of abscess. Preliminary aspiration (A); incision (B); introducing the tip of a pair of forceps to improve drainage (C); breaking down loculi with a finger (D); further incision (E); trimming the corners of the cruciate incision to deroof the cavity (F).

Too small an incision and failure to provide free drainage are common mistakes in this procedure, leading to chronicity or recurrence of the abscess. The wound edges must not be allowed to close while the abscess cavity remains.

After-care

Treatment with antibiotics is unnecessary, unless there is evidence of spreading infection with signs of toxicity or unless the abscess is in a region of crucial importance, such as the hand, ear, or throat.

Split-skin grafting

Skin is the best cover for a raw surface caused by, for example, trauma or burns.¹ The recipient area for the graft should have healthy granulation tissue with no evidence of infection.

Equipment See tray for *Skin grafting*, Annex 1.

Technique The patient should be given a general anaesthetic.

The most commonly used donor site is the anterolateral or posterolateral surface of the thigh. First clean the selected donor site with antiseptic and isolate it with drapes. Apply petrolatum or liquid paraffin (mineral oil) to lubricate the area. Hold the assembled skin-grafting knife (Humby) (Fig. 1.13A) in one hand and press the grafting board against the patient's thigh (or alternative donor site) with the other hand. Instruct an assistant to apply counter-traction to keep the skin taut by holding a second board in the same manner. Cut the skin with regular back-and-forth movements while progressively withdrawing the first board ahead of the knife (Fig. 1.13B).

After cutting a length of about 2 cm of skin, inspect the donor area: homogeneous bleeding confirms that the graft is of split-skin thickness; exposed fat indicates that the graft is of full thickness, i.e., too deep, in which case you should check the adjustment of the blade. As the cut skin appears over the blade, instruct an assistant to hold it gently out of the way with non-toothed dissecting forceps. Place the newly cut skin in saline and cover the donor area with a warm wet pack before dressing it with petrolatum gauze. Spread out the cut skin, with the raw surface upwards, on petrolatum gauze (Fig. 1.13C).

If a skin-grafting knife is not available, the graft can be taken with a razor blade held with straight artery forceps. Start by applying the cutting edge of the blade at an angle to the skin but after the first incision lay the blade flat.

Before applying the skin graft, clean the recipient area with saline. Wet the graft frequently with saline to prevent it from drying out. Do not pinch it with instruments. To graft a large piece of skin, first suture it in place at a few points and then continue to place sutures around the edges of the wound. Sutures are not necessary for a small piece of skin.

Haematoma formation under the graft is the most common reason for graft failure. It can be prevented by applying a "bolster" dressing made of moist cotton wool moulded in the shape of the graft and tied over the graft with sutures. As an alternative, make several small perforations in the graft (Fig. 1.13D), or cut the graft into small pieces (postage-stamp grafts) and place them a few millimetres from each other to leave space for bridging during the re-epithelization process.

After-care Hold the graft in place with petrolatum gauze, unless you have already sutured it and applied a bolster dressing. Then apply additional layers of gauze and cotton wool, and finally a firm, even bandage. Leave the graft undisturbed for 2–3 days unless infection or haematoma is suspected. Change the dressing daily or every other day thereafter (a bolster dressing will no longer be needed by this stage), but never leave the grafted area uninspected for more than 48 hours. If the graft is raised, puncture it to release any serum underneath. Otherwise interfere as

¹For further details of the treatment of burns and other forms of trauma, see *Surgery at the district hospital: obstetrics, gynaecology, orthopaedics, and traumatology* (Geneva, World Health Organization, in preparation).

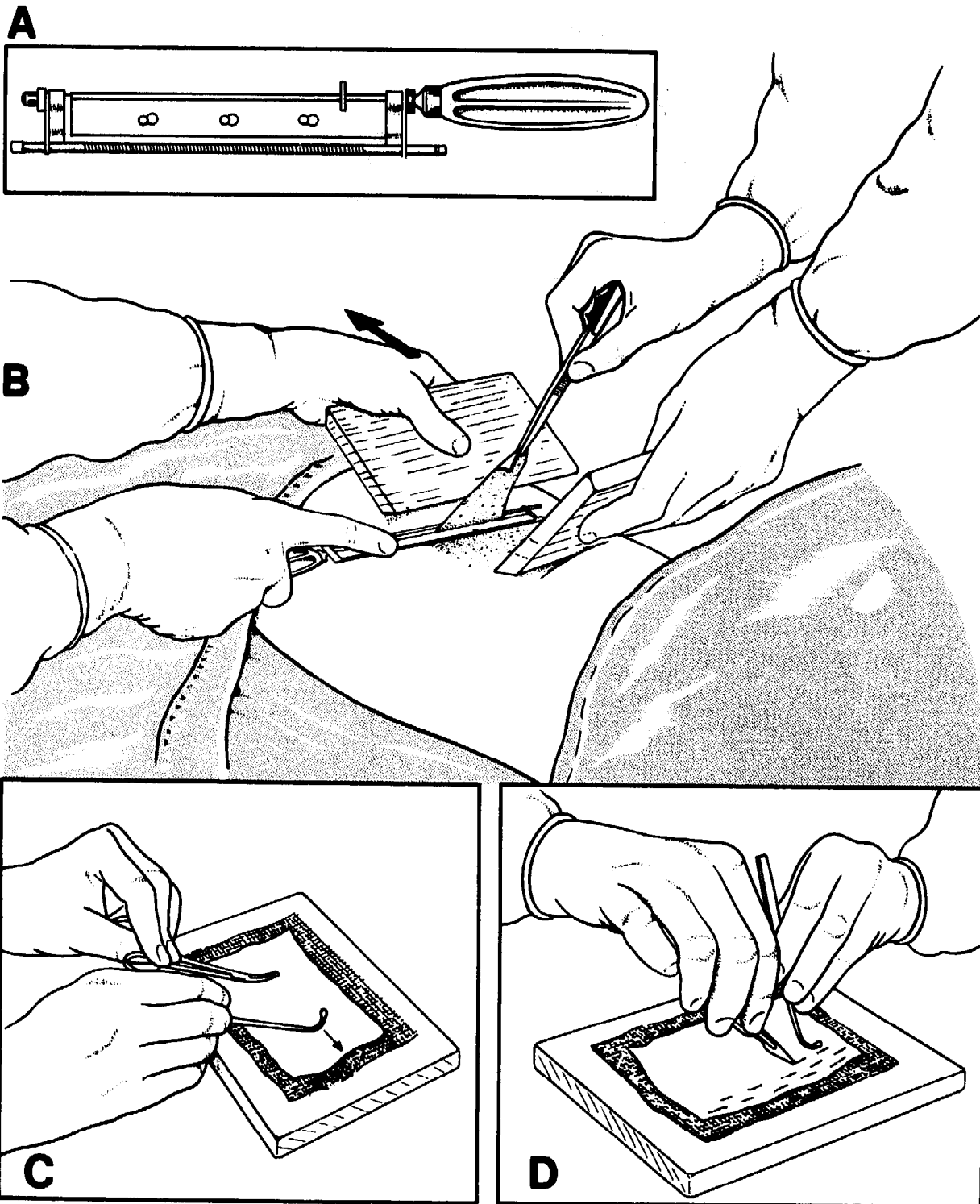


Fig. 1.13. Skin grafting. A skin-grafting knife (Humby type) (A); cutting skin (B); spreading out the cut skin (C); making perforations in the graft (D).

little as possible. It may be possible to expose the graft to the air at this early stage if the area can be protected by splints or mosquito netting, but only if there is adequate nursing supervision. After 7 to 10 days, remove any sutures, wash the grafted area, and lubricate it with liquid paraffin (mineral oil) or petrolatum.

The second week after grafting, instruct the patient in regular massage and exercise of the grafted area, especially if it is located on the hand, the neck, or one of the limbs. These exercises should be continued for at least 9 months. To prevent burn contractures, apply simple splints for flexure surfaces and keep the grafts under tension using whatever means is available. For example, simple tongue depressors can serve as finger splints and plaster of Paris can be used for extremities.

2

Fluid and electrolyte therapy, blood transfusion, and management of shock

Fluid and electrolyte therapy

Normal distribution and composition of body fluid

The amount of water in the healthy body depends on the size, weight (particularly lean body mass), and sex of the individual. Body water is usually expressed as a percentage of body weight and is approximately 60% in men, 50% in women, 65% in children older than one year, and up to 75% in neonates. The water present within the cells, intracellular fluid, accounts for 40% of the body weight in men. The extracellular fluid makes up 20–25% of the body weight in men and 40–50% in neonates, and is subdivided into plasma and interstitial fluid. Physiologically, these three compartments of body water are interdependent (Fig. 2.1).

Plasma contains proteins (chiefly albumin) and ions (mainly sodium, chloride, and bicarbonate). Water and electrolytes move freely between plasma (intravascular compartment) and the interstitial fluid, but plasma proteins enter the interstitial fluid only when the capillary endothelium is damaged, for example as a result of septic shock or burns. The protein in plasma is responsible for the intravascular colloid osmotic pressure, a major determinant of the movement of fluid across the capillary endothelium. Only a small proportion of the body's potassium is present in plasma, but the concentration of potassium ions is crucial to cardiac and neuromuscular function.

Interstitial fluid has an ionic composition similar to that of plasma. If there is a water deficit in the intravascular compartment, water and electrolytes pass from the interstitial compartment to restore the circulating blood volume. Electrolyte solutions, such as physiological (normal) saline and Ringer's lactate solution (Hartmann's solution), can pass into the interstitial space when they are administered intravenously. For this reason, they are effective in raising the intravascular circulating volume for only a short time if there is a deficit of fluid throughout the extracellular compartment. Blood, plasma, and colloids used as plasma substitutes, for example dextran, hydroxyethyl starch, and gelatin solutions (which are known as "plasma expanders"), remain in the intravascular compartment longer and are therefore more effective in maintaining the circulation.

Intracellular fluid has a different ionic composition to extracellular fluid. The main cations are potassium and magnesium, with phosphates and proteins as the major anions.

After intravenous infusion, the water contained in physiological saline tends to remain in the extracellular compartment, but the water contained in glucose solutions is distributed throughout all body fluid compartments, the glucose being metabolized. *Never* give pure water intravenously, as it causes dangerous haemolysis.

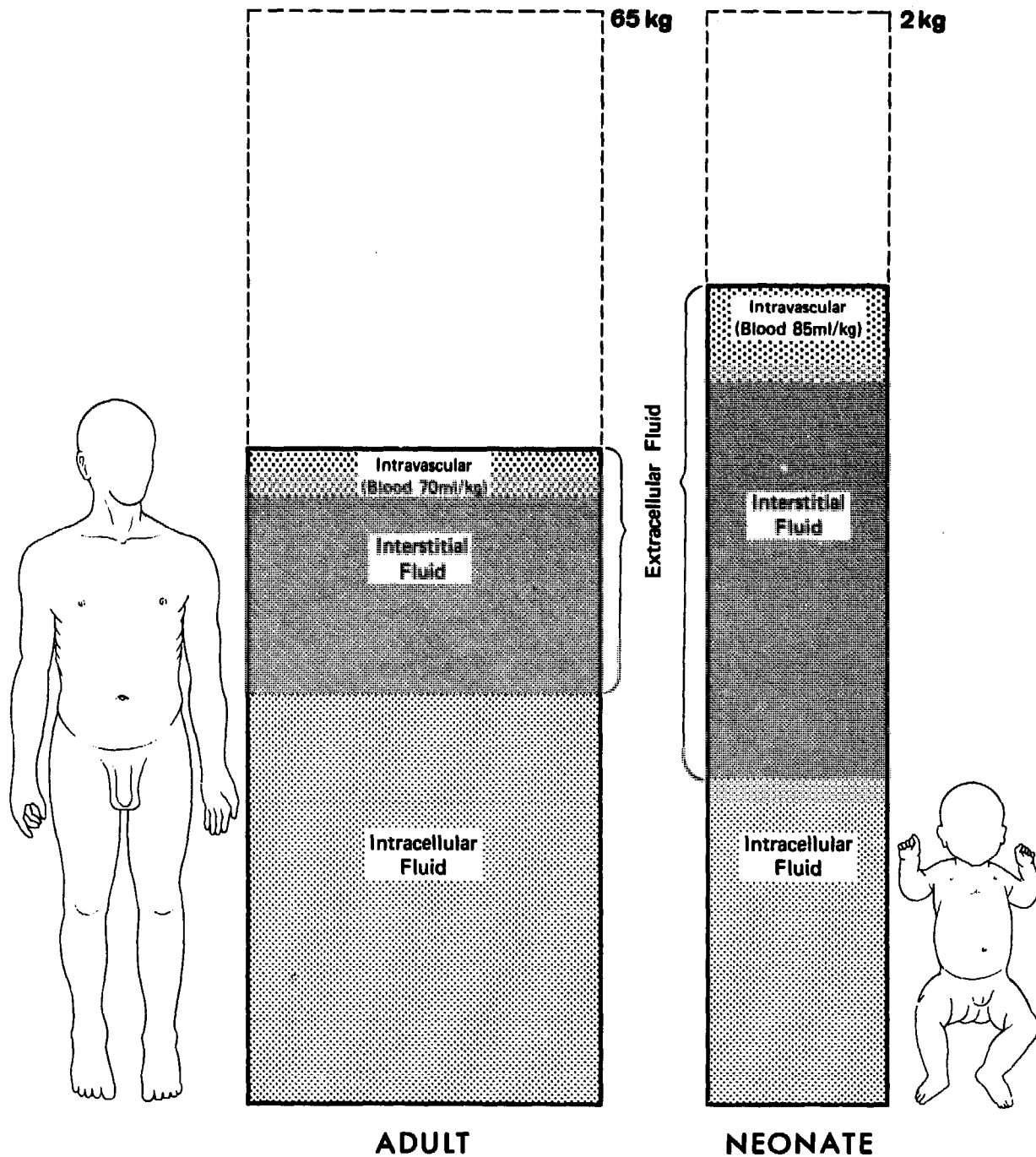


Fig. 2.1. Fluid compartments of the body.

Daily water and electrolyte exchanges

In the normal individual, the amount of water and electrolytes excreted each day balances what is taken in in foods and fluids (Tables 1 & 2). The kidney regulates, to a large degree, the volume and composition of body fluid. To a lesser degree the skin and lungs affect water losses, but do not regulate them.

Acid-base balance

Hydrogen ions (H^+) and large amounts of carbon dioxide (CO_2) are produced during the normal metabolic activity of the body. The hydrogen ions are discharged into body fluids, and the carbon dioxide combines with water to form carbonic acid (H_2CO_3).

The body has extremely efficient mechanisms for buffering acids, but in disease these mechanisms are often disturbed. Of the buffer systems, the bicarbonate/carbonic acid system is the most important, but proteins, and especially

Table 1. Average daily water exchanges (in ml) in an adult male

	Tropical countries	Temperate countries
Loss		
Through lungs and skin	1700	1000
In urine	1500	1500
In faeces (variable)	200	200
Total	3400	2700
Gain		
Water of oxidation	200	200
Net requirement	3200	2500

Table 2. Average daily losses of sodium and potassium (in mmol) in an adult male

	Tropical countries	Temperate countries
Sodium		
Urine	114	80-110
Sweat	16	0
Faeces	10	10
Total	140	90-120
Potassium		
Urine	47	60
Sweat	Negligible	0
Faeces	10	10
Total	57	70

haemoglobin, are also important as intracellular buffers. The normal plasma pH of approximately 7.4 is maintained within narrow limits through these buffering systems, through the control of carbon dioxide elimination by the lungs, and through the regulation of plasma bicarbonate (HCO_3^-) concentration by the kidney.

Disturbances of body-fluid status

Changes in the volume or composition of the body fluids (which may occur before, during, or after surgery) can cause a severe physiological disturbance and should therefore be corrected promptly. The volume changes seen in surgical practice often affect the extracellular fluid. This fluid may be lost not only externally, for example through external haemorrhage, but also internally through sequestration (translocation or redistribution) into injured tissues, as in patients with burns, crush injuries, peritonitis, or an obstructed loop of the bowel. This internal redistribution of the extracellular fluid, at times referred to as fluid loss into the "third space", is often overlooked, yet it can markedly reduce the circulating fluid volume.

How to assess volume depletion

Take a detailed history from the patient or from his or her relatives and make a careful examination to determine the nature and approximate amount of fluid lost; the diagnosis should be mainly clinical. The clinical state of the patient depends on the amount and rate of fluid loss, the underlying or associated disease, and the efficiency of compensatory mechanisms. Reliable tests for determining the amount of fluid lost are not available; in particular, the concentration of sodium ions in the serum can be misleading. Nevertheless, the patient's blood can yield useful information: the blood urea concentration may

Table 3. Mass concentration of components of a solution of oral rehydration salts (ORS)

Component	g/litre
Sodium chloride	3.5
Trisodium citrate, dihydrate ^a	2.9
Potassium chloride	1.5
Glucose, anhydrous ^b	20.0

^a Or sodium hydrogen carbonate (sodium bicarbonate) 2.5 g.

^b Or glucose, monohydrate 22.0 g; or sucrose 40.0 g.

Table 4. Substance concentration of components of a solution of oral rehydration salts (ORS)

Component	mmol/litre
Sodium	90
Potassium	20
Chloride	80
Citrate ^a	10
Glucose ^b	111

^a Or bicarbonate 30 mmol/litre.

^b Or sucrose 117 mmol/litre.

be elevated if there is an uncorrected deficit of extracellular fluid, and the severity of dehydration (loss of water and electrolytes) may be indicated by the haemoglobin concentration or erythrocyte volume fraction. The dehydrated patient is usually thirsty with a dry mouth, sunken eyes, and reduced skin elasticity; the blood pressure may be low, associated with a small pulse pressure and tachycardia. If the fluid loss is acute and severe, the patient may develop hypovolaemic shock. Urinary output may be low and the relative density (specific gravity) of the urine high.

Treatment of fluid imbalance

If the patient is suffering fluid loss but with minimal signs, administer fluids orally, unless contraindicated; a solution of oral rehydration salts (ORS) in water is suitable for this (Tables 3 & 4). In patients with burns, oral rehydration salts are a useful supplement to fluids given intravenously. The ideal solution to infuse is one whose composition most closely resembles that of the fluid lost. Replace the fluid already lost, administer fluid for daily maintenance, and anticipate and replace any continuing unusual losses. Remember that patients receiving fluid and electrolyte therapy, except those with diarrhoea, are not likely to pass faeces, so daily requirements must be adjusted accordingly. Table 5 shows the main features of the commonly available replacement fluids.

In patients suffering fluid loss and showing obvious signs, it is convenient to begin replacement by infusing a balanced salt solution such as physiological saline (containing sodium chloride at 9 g/litre) or Ringer's lactate solution. In hot countries, water loss is proportionally greater than electrolyte loss, so infuse balanced salt solutions with caution and consider infusing 5% glucose (50 g/litre) as well. Insert a bladder catheter and measure the hourly urinary output and its relative density (specific gravity). Adjust the rate of infusion and the total amount of fluid in accordance with the patient's response, as indicated by the trend in the symptoms and signs, and in particular by the hourly urinary output and the jugular venous pressure. The ideal urinary output is at least 0.5 ml/kg of body weight per hour. Record clinical observations and assess the effect of therapy hourly. Establish a fluid input/output chart, and give clear, written

Table 5. Commonly available replacement fluids

Fluid	Ions (mmol/litre)			Carbo- hydrate (g/litre)	Energy con- tent (kJ [kcal _m])	Uses
	Na ⁺	Cl ⁻	K ⁺			
Blood ^a	140	100	4	5-8	NA	Blood loss
Physiological saline (9 g/litre) ^b	154	154	0	0	0	Blood/extracellular fluid loss
Hartmann's solution (Ringer's lactate solution) ^c	131	112	5	NA	NA	Blood/extracellular fluid loss
Glucose 50 g/litre	0	0	0	50	837 [200]	Dehydration
Glucose/saline (glucose 40 g/litre + sodium chloride 1.8 g/litre)	31	31	0	40	669 [160]	Maintenance of electrolyte and water balance
Sodium bicarbonate 84 g/litre	1000	0	0	0	0	Acute acidosis
Dextran 70 in physiological saline	144	144	0	0	0	Intravascular replacement
Polygeline	145	150	0	0	669 [160]	Intravascular replacement

^a Also contains Ca²⁺ at 2.3 mmol/litre.

^b The same as a 0.9% solution.

^c Also contains Ca²⁺ at 3 mmol/litre and lactate at 28 mmol/litre, which is converted to bicarbonate and is therefore useful for correcting acidosis.
NA, not applicable.

instructions about the infusion programme; it is preferable to update these instructions every 6-8 hours rather than only once a day, as losses and requirements may change rapidly.

Treatment of electrolyte imbalance

Hypernatraemia (an excess of sodium ions in the serum, which can be confirmed by a blood test) may be caused by infusion of excessive quantities of saline or by tube feeding without sufficient water supplementation. Associated clinical features are restlessness, tachycardia, dry, sticky mucous membranes, and often an elevated body temperature. Correct hypernatraemia by salt restriction and an intravenous infusion of 5% glucose in water.

Hyponatraemia may follow the intravenous infusion of large volumes of salt-free fluids, such as glucose solutions. It can also follow oral or rectal administration of large amounts of water or other salt-free fluids. It is a recognized complication of water enema in infants and children, especially in those with Hirschsprung's disease, and any form of enema in children and infants should therefore be avoided. The affected patient is lethargic and hypertensive, with tachycardia and cold extremities; oliguria or even anuria is present. Treat hyponatraemia by restricting the patient's water intake. Do not give hypertonic saline infusions in an attempt to "normalize" the level of serum sodium.

Imbalances of serum potassium concentration have more serious clinical consequences than those of serum sodium concentration. Potassium is crucial to cardiac and neuromuscular functions, and its level in serum (3.5-4.5 mmol/litre) varies with the acid-base status and renal function of the individual. Hyperkalaemia may occur after severe trauma (including burns and surgical operations) and in patients suffering from acidosis, various catabolic states, and acute renal failure. Although the patient may complain of nausea, vomiting, abdominal colic, and diarrhoea, the symptoms are a poor guide to hyperkalaemia. The electrocardiogram usually has a peaked T wave, a widened QRS complex, and a depressed S-T segment; dysrhythmias are more likely than usual and may lead to cardiac arrest. Give specific treatment intravenously, in the following sequence:

- 20 ml of a 10% (100 g/litre) solution of calcium gluconate, over a period of 20 min;
- 100 mmol (8.4 g) of sodium bicarbonate in solution (in an acidotic patient this will encourage the entry of potassium ions into cells);
- 100 ml of a 50% (500 g/litre) glucose solution, with insulin at 1 International Unit for every 5 g of glucose.

Recovery of cardiac function is usually prompt with this treatment. If the patient's hyperkalaemia is due to acute renal failure, refer the patient immediately after resuscitation, if possible. If referral is not possible, begin peritoneal dialysis.

Hypokalaemia often results from prolonged administration of diuretics or excessive losses of fluid through the gastrointestinal tract, for example in cases of prolonged diarrhoea or vomiting. The patient has flaccid limbs, reduced tendon reflexes, and paralytic ileus. The electrocardiogram shows a flat T wave and a depressed S-T segment. An adequate urine output (0.5 ml/kg of body weight per hour) must be established before correction of the potassium deficit is started. Potassium is given as potassium chloride mixed in the drip fluid: add 40 mmol of the salt to 1 litre of either saline or 5% glucose. Infuse this fluid very slowly so as to deliver not more than 40 mmol of potassium per hour, and estimate the serum potassium concentration after giving every 40 mmol. The bottle of fluid containing potassium chloride must be clearly labelled. Never give a concentrated solution of a potassium salt by direct intravenous injection.

Blood transfusion

Transfusion with whole blood is generally indicated in cases of acute, severe blood loss amounting to over 15% of blood volume. However, the decision to proceed with transfusion should be taken only after careful consideration of the risk of transfusing blood contaminated with infectious agents, including human immunodeficiency viruses.

It is not necessary to replace all lost blood with blood. To reduce the requirement for whole blood after acute blood loss, infuse plasma expanders such as dextran, hydroxyethyl starch, and gelatin solution, if available. These plasma expanders, however, cannot transport oxygen. They can also interfere with the cross-matching of blood, so blood samples should be taken before infusion.

If anaemia is recognized before surgery, it is best to investigate the cause and treat it appropriately. But in an emergency you may have to correct the anaemia by slow transfusion, preferably with packed red cells. Take particular care with haemostasis during the operation. Measure the blood loss and replace this with whole blood. If you anticipate a loss of more than 500 ml during the operation, group and cross-match donor blood in advance.

Technique

Clearly record the reasons for transfusion. Also record the history of previous transfusions, as well as any reactions to these. If the patient is a woman, record the history of any previous pregnancies, including miscarriages, stillbirths, or infants who suffered from haemolytic disease of the newborn. Finally, record the patient's current or last known haemoglobin level.

Take 10 ml of venous blood from the patient with a dry syringe, and allow it to clot in a dry, sterile specimen bottle or tube clearly labelled with the date and the patient's name, hospital number, and ward. Venepuncture may be difficult in

infants, so use a heel stab instead, and allow 10–20 drops of blood to drip into a sterile tube. Except in emergencies, make requests for grouping and cross-matching of blood at least 24 hours before the proposed transfusion. This will help avoid errors and will allow time to obtain blood and carry out any tests indicated by the patient's condition.

Ideally the blood used for transfusion should match the patient's own blood group. To avoid risks to future pregnancies or transfusions, always use Rh-compatible or Rh-negative blood for premenopausal female patients. If there is difficulty in obtaining blood, especially in an emergency, apply the following rules:

- Group A patient: ideally give blood group A, but you may give group O.
- Group B patient: ideally give blood group B, but you may give group O.
- Group AB patient: ideally give blood group AB, but you may give group A, B, or O (in that order of preference).
- Group O patient: give only blood group O.

Even if these rules are followed, it is still important to cross-match the serum of the patient against the red cells of the donor (compatibility test) to make sure that the blood is safe to give.

Store blood for transfusion in a special refrigerator at 4–6 °C until the time for transfusion. There is an increased risk of sepsis if the blood is artificially warmed; it will reach room temperature as it passes down the giving set. Do not transfuse blood if it is purple, if the plasma layer is pink, or if the date of transfusion is more than 21 days from the date of donation. Always use a giving set with a filter, and start transfusion slowly until about 200 ml have been given. For an anaemic patient use a slow transfusion rate throughout the procedure, but do not allow longer than 4–6 hours per unit of blood because of the risk of sepsis in blood kept at room temperature. Limit the transfusion of whole blood to 20 ml/kg of body weight for infants weighing less than 25 kg and to 10 ml/kg for neonates (up to 1 year old).

Complications

The manifestations of transfusion reactions vary, but pyrexia (at times with rigor) is common, and the patient may develop oliguria or anuria after a severe reaction. If a reaction occurs, stop the transfusion at once and investigate the cause. The reaction may be due to incompatibility between blood-group antigens and antibodies (ABO incompatibility); transfusion of haemolysed blood (for example blood older than 21 days); transfusion of infected blood; transfusion of blood containing allergens; accidental injection of air with the blood (causing air embolism); overloading of the circulation; or transfusion of blood containing (non-ABO) antigens or antibodies incompatible with the antibodies or antigens of the patient.

Certain diseases can be transmitted in the blood. They include malaria, syphilis, trypanosomiasis, leishmaniasis, viral hepatitis, and acquired immunodeficiency syndrome (AIDS). Always test for syphilis, and in endemic areas also make blood films to check for malaria, trypanosomiasis, and infection with *Leishmania donovani*. It is hoped that appropriate screening tests for viral hepatitis and for AIDS will soon be widely available.

Autotransfusion

Autotransfusion, i.e., using the patient's own blood for transfusion, is a convenient, useful, and safe procedure in cases of massive internal bleeding. The main

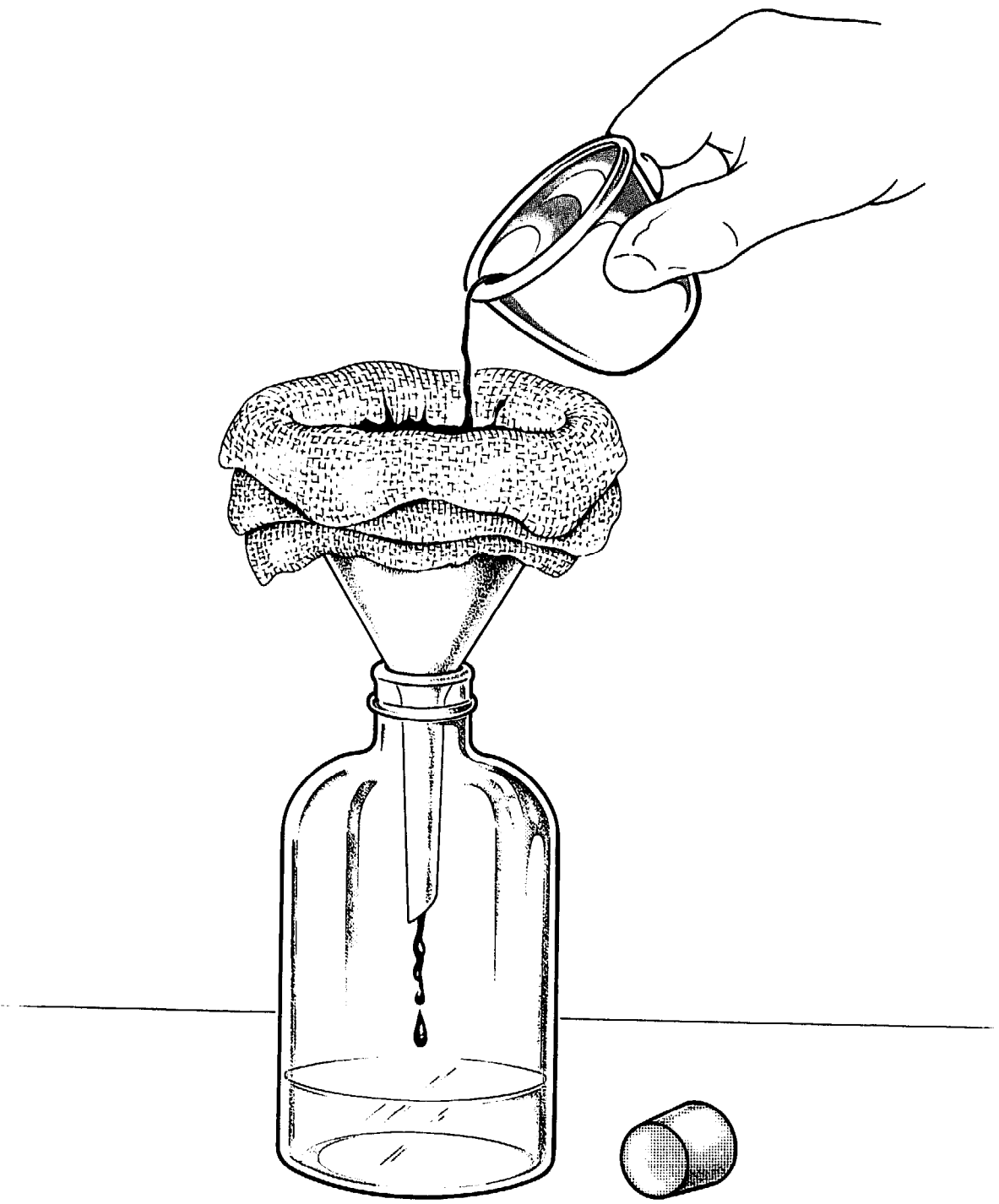


Fig. 2.2. Filtration of blood (for autotransfusion) into a collecting bottle containing anticoagulant.

indication for autotransfusion is a ruptured spleen or a ruptured ectopic pregnancy, although it can also be used in the case of a large haemothorax. The blood is collected from the peritoneal (or pleural) cavity, filtered, and mixed before use with citrate to prevent coagulation.

Equipment

Specific equipment requirements are two or three sterile, 0.5-litre bottles with stoppers, each containing 60 ml of 3.8% sodium citrate (38 g/litre) or 120 ml of "acid-citrate-glucose" solution (containing trisodium citrate dihydrate, citric acid monohydrate, and glucose); a large sterile funnel with eight layers of sterile gauze for filtering; and a sterile gallipot or jug.

- Technique** Scoop out blood from the abdominal cavity with a gallipot (do not use a sucker), filter it through the gauze in the funnel, and allow it to drain into the collecting bottle (Fig. 2.2). Mix it gently with the anticoagulant by tilting the bottle from side to side. If any clot particles drain through, refilter the blood. Then stopper the bottle. The blood is now ready for transfusion into the patient.
- Contraindications** Do not use this procedure for blood that has been in the abdominal cavity for more than 24 hours, or if the blood is or may be contaminated, as for example in a patient with bowel trauma.
- Complications** Complications are unlikely provided that sterility is maintained throughout autotransfusion. Rarely the blood may become haemolysed or contaminated. Contaminated blood can give rise to septic shock or even septicaemia.

Shock

Shock is a useful clinical diagnosis, but it lacks a clear pathophysiological basis. Some degree of hypovolaemia is usually present, as after haemorrhage or the loss of other body fluids, for example because of acute burns. The patient suffering from hypovolaemic shock is often anxious; the pulse is rapid and thready, the blood pressure low, and the skin cool and clammy; and the extremities are often cyanotic. In addition, the patient's urinary output is reduced. Normovolaemic shock may occur as a complication of massive sepsis. In most cases its features are similar to those of hypovolaemic shock, but sometimes the patient is confused, with an increased (rather than reduced) peripheral blood flow, as indicated by warm, pink, and oedematous extremities.

- Management** Treat or control the cause of shock: arrest haemorrhage from wounds by firm pressure over a sterile dressing, and incise and drain an abscess without delay. Simultaneously begin the correction of circulatory and metabolic disturbances.

Delay in restoring the circulating volume of a patient with hypovolaemic shock can rapidly cause severe irreversible damage to the kidney and the brain. Therefore, insert a wide-bore cannula or the largest available needle (for example 14-gauge/2.0 mm) into a large vein in the cubital fossa or into the external jugular vein, and immediately start infusion of physiological saline or Ringer's lactate solution, since these fluids are usually readily available. (The infusion solution may be changed later, if necessary, ideally to the fluid that most closely resembles the fluid lost, and the infusion may be transferred to the long saphenous vein when there is time for a surgical "cut-down" at the ankle.) Elevate the patient's legs to increase venous return, but do not lower the trunk and head, as this impairs breathing. Measure and record the patient's pulse rate and blood pressure every 30 min.

Insert a catheter into the bladder to measure the hourly urinary output. This variable and the jugular venous pressure (estimated clinically) are indicators of the patient's fluid status and cardiac output (unless there is cardiac failure). Continue fluid replacement until the urinary output is at least 0.5 ml/kg of body weight per hour and the jugular venous pressure indicates adequate filling of the venous circulation.

Metabolic acidosis due to circulatory failure will subside if fluid replacement is adequate.

If no urine is draining, first check that the catheter is not blocked by measuring the circumference of the abdomen and performing bladder washout. Provided that the bladder catheter is patent, persistent anuria in a patient with restored

FACE AND NECK

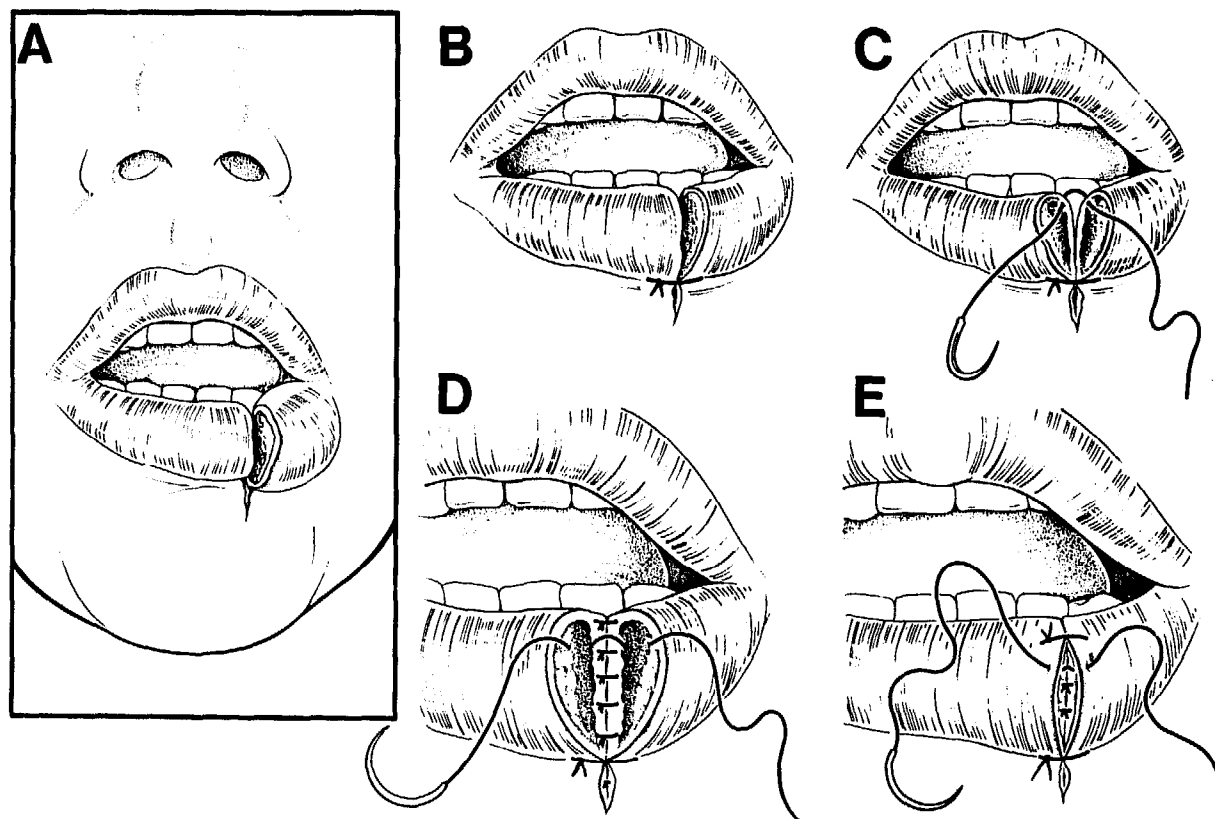


Fig. 3.1. Repairing a lip wound. The wound (A); the key suture ensures anatomical alignment (B); repair in layers: mucosa (C), muscle (D), and skin (E).

Lip

Lip injuries are common. It is safe not to suture small lacerations of the buccal mucosa, but advise the patient to rinse the mouth frequently with salt water, particularly after every meal.

For an isolated laceration of the lip that requires suturing (Fig. 3.1A), local anaesthesia is usually adequate. Proper anatomical alignment is essential for wounds that cross the vermilion border. Achieve this by planning the first stitch to join the border accurately (Fig. 3.1B). This region may be distorted by swelling caused by local anaesthetic, so to ensure accuracy, premark the border with gentian violet.

After this key suture has been inserted, repair the rest of the wound in layers, starting with the mucosa and progressing to the muscles and finally the skin (Fig. 3.1C,D,E). Use fine, interrupted sutures of 4/0 or 3/0 chromic catgut for the inner layers and thread or monofilament nylon for the skin.

Tongue

Most wounds of the tongue require no suturing and heal rapidly, but you may need to suture lacerations with a raised flap in either the lateral border or the dorsum of the tongue (Fig. 3.2). Suture the flap to its bed with 4/0 or 3/0 buried, catgut stitches. Local anaesthesia is usually sufficient.

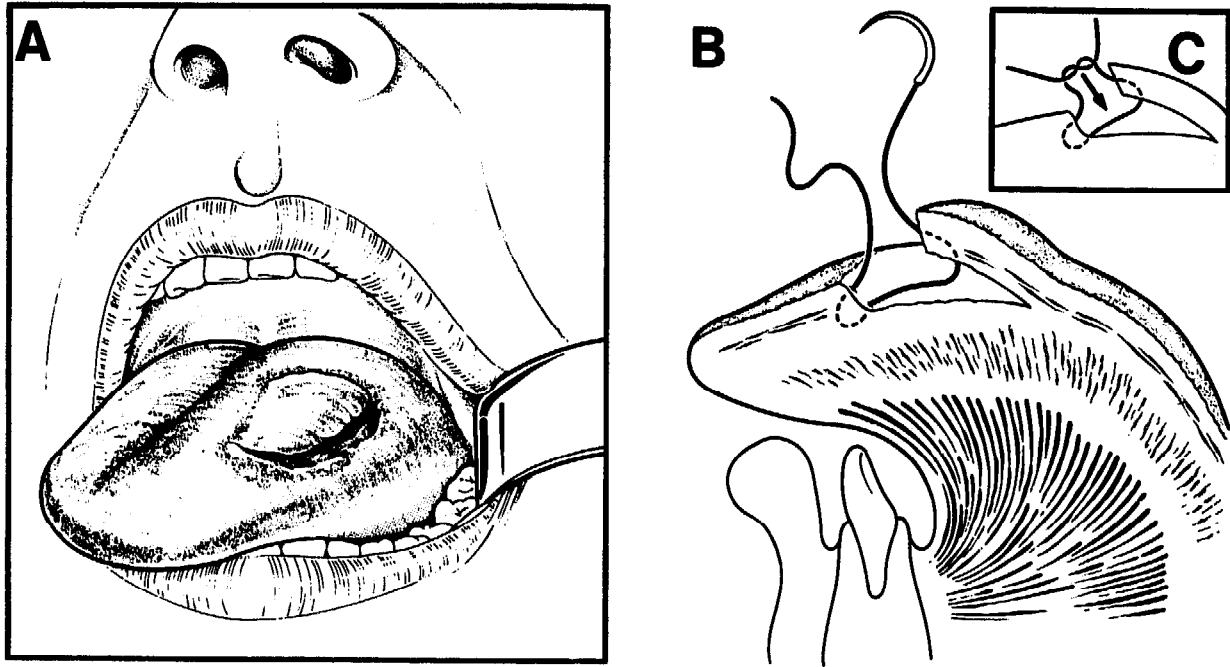


Fig. 3.2. Repairing a laceration of the tongue. The wound, with flap (A); suture of the flap to its bed (B); the knot is buried as the suture is tied (C).

Instruct the patient to rinse the mouth regularly with salt water, until healing is complete.

Ear and nose

The three-dimensional curves of the pinna and the presence of cartilage can present difficulties in the repair of ear injuries. The wounds are commonly irregular, with cartilage exposed by loss of skin. Use the folds of the ear as landmarks to restore anatomical alignment.

After the patient has been anaesthetized, as appropriate, close the wound in layers with fine sutures, using catgut for the cartilage. Dressing is important: the pinna should be supported on both sides by moist cotton pads and firmly bandaged to reduce haematoma formation (Fig. 3.3).

Make every attempt to cover exposed cartilage either by wound suture or by split-skin graft (see page 33).

The principles of repair of ear lacerations also apply to wounds of the nose.

Complications

Wounds of the ear and nose may result in deformities or necrosis of the cartilage.

Cellulitis of the face

Cellulitis of the face, which can be a complication of facial wounds, carries the serious risk of cavernous-sinus thrombosis, so the patient's initial response to treatment with antibiotics is best observed in hospital. The organisms responsible are likely to be penicillin-sensitive. The patient must resist squeezing or otherwise manipulating any infected foci on the face, even if such foci are small.

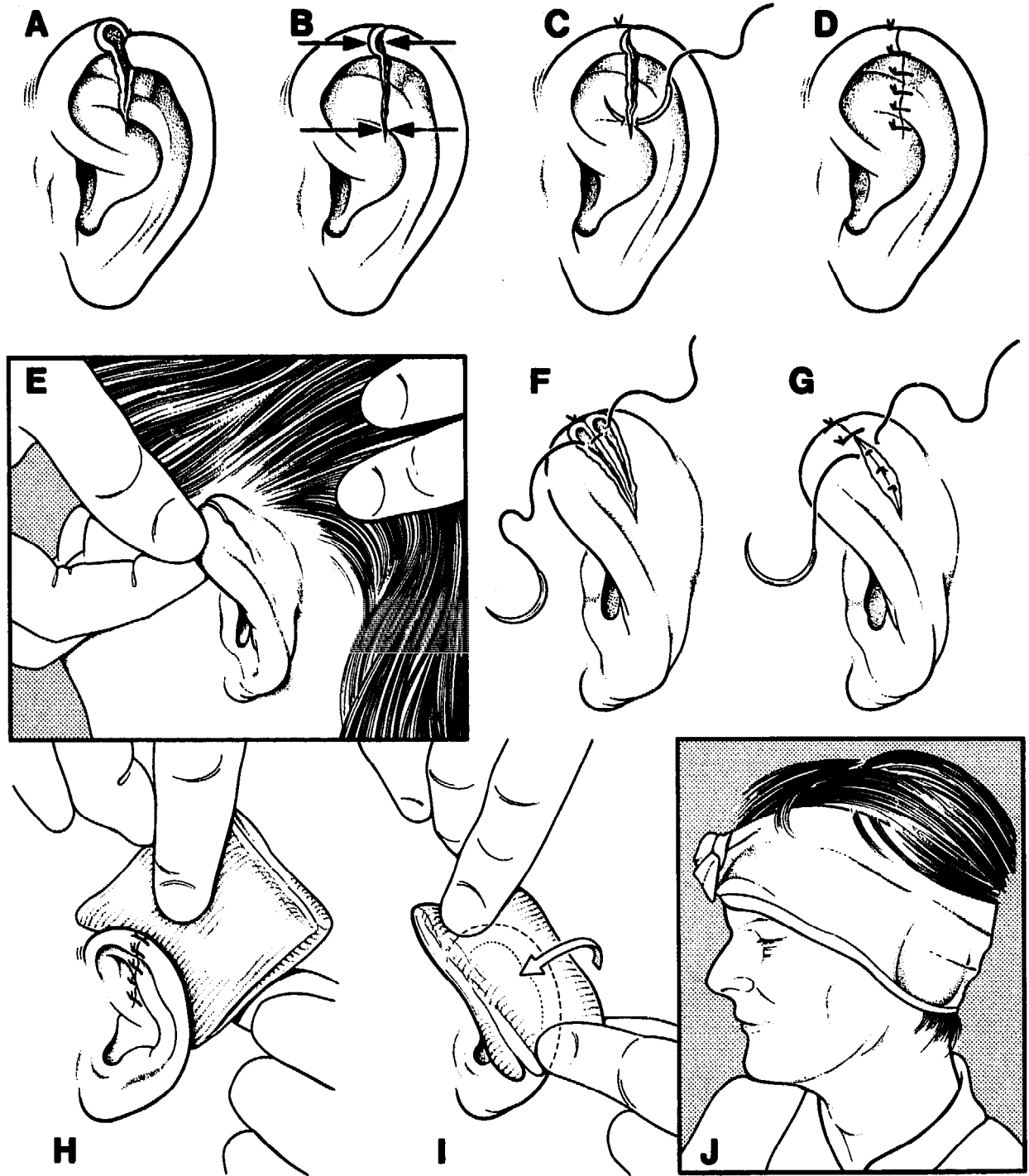


Fig. 3.3. Repairing a laceration of the ear. The laceration (A); anatomical alignment (B); skin suture of the anterior surface (C, D); the laceration as seen from the back, after suture of the anterior surface (E); suture of the cartilage (F); completing skin suture (G); dressing the wound (H-J).

If severe oedema suggests involvement of the cavernous sinus, attempt to prevent thrombosis by administering heparin, 5000 International Units every 8 hours by subcutaneous injection.

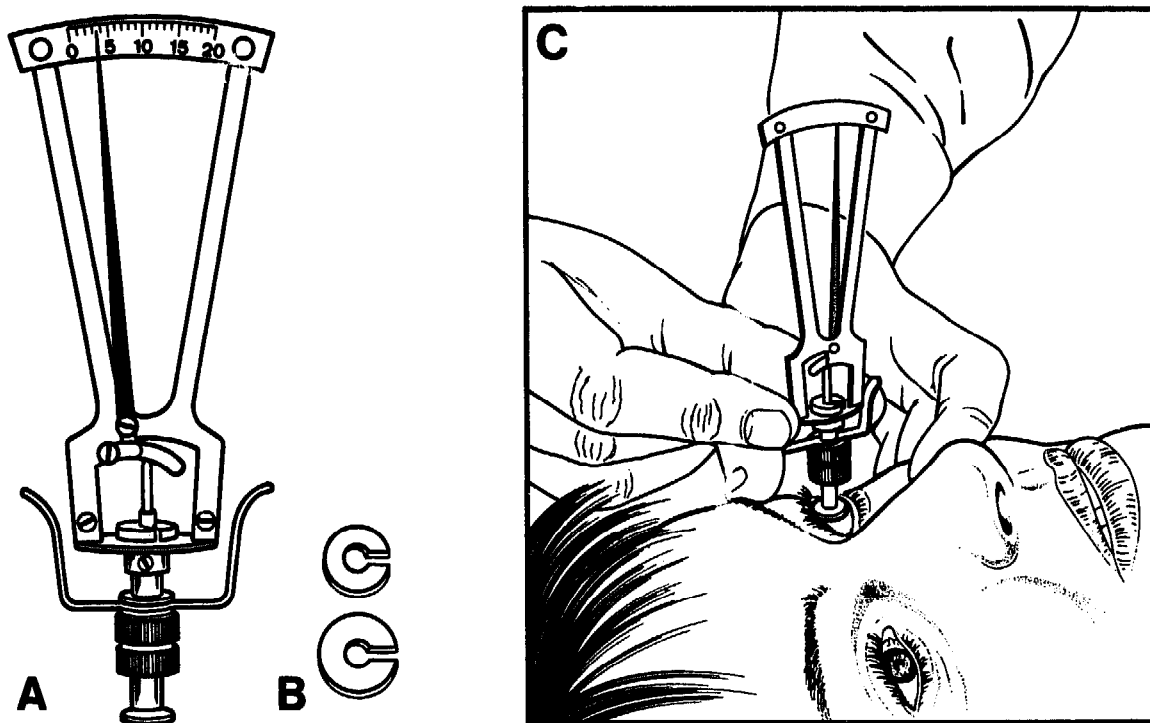


Fig. 4.1. Measuring intraocular pressure. Schiötz tonometer (A); additional weights (B); separating the lids and applying the tonometer to the cornea (C).

Care of instruments

Most instruments used for eye surgery are delicate and should therefore be handled with special care. Clean all instruments after surgery and sterilize them before re-use. Sterilize sharp instruments using appropriate chemical solutions such as chlorhexidine and glutaral; sterilize other instruments using an autoclave or dry heat. In an emergency, instruments may be sterilized by immersion in 70% ethanol for 1 hour.

Anaesthetic techniques

General anaesthesia is normally recommended for major intraocular surgery, for example for enucleation of the eye, and for children. Otherwise conduction (regional) anaesthetic techniques are usually suitable.

Always instil anaesthetic eye drops, for example tetracaine 0.5% (5 g/litre), before surgery.

Facial block

To produce facial block for intraocular surgery, inject lidocaine into the area 2 cm in front of and below the tragus of the ear (Fig. 4.2A,B). As an alternative, infiltrate the supraorbital and infraorbital branches of the facial nerve by injection along the orbital margins (Fig. 4.2C).

Retrobulbar block

The purpose of retrobulbar block is to anaesthetize the eye and also to prevent its movement. Use this block only for major intraocular surgery, and only if general anaesthesia is not available and the patient is already in grave danger of going blind. Always be aware of the possible complications of this technique. Retrobulbar block is to be particularly avoided if the patient has perforating injuries of the eye, as it can cause a dangerous increase in the volume of orbital contents, which may cause tissues to extrude from the eye.

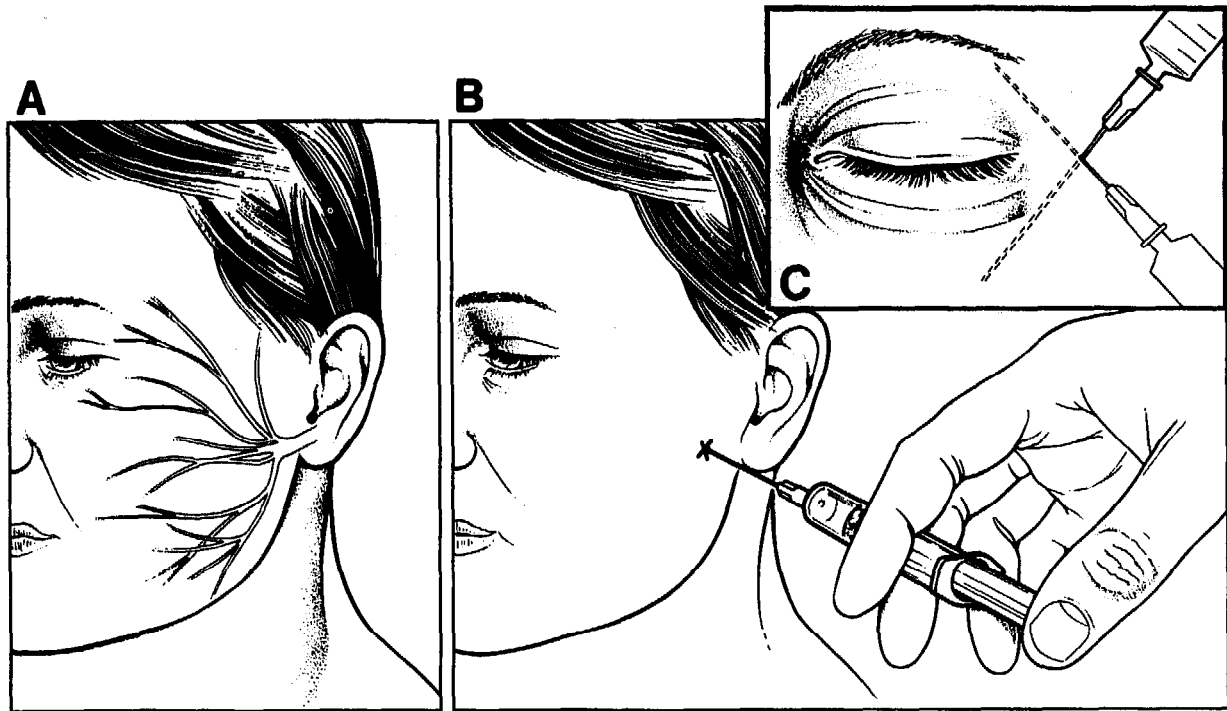


Fig. 4.2. Facial block. The facial nerve and its branches (A); injecting local anaesthetic in front of and below the tragus of the ear (B); as an alternative, injecting local anaesthetic along the orbital margins (C).

Retrobulbar block is effected by injecting 2.5 ml of 2% (20 g/litre) lidocaine into the cone formed by the rectus muscles. With the patient supine, palpate the orbit of the eye to locate the lower outer border. Introduce a 23-gauge, 2.8 cm needle vertically at this point (Fig. 4.3A). Penetrate the skin and then the orbital septum; resistance will be encountered as the needle passes through each of these two layers. Once the tip of the needle is lying below and behind the globe, angle the needle in the direction of the junction between the roof and the medial wall of the orbit (Fig. 4.3B,C). Introduce it further and penetrate the muscle layer, which will be indicated by a slight resistance. Draw back the plunger of the syringe (to make sure that the tip of the needle is not in a vein) and inject the local anaesthetic. It should flow freely. Resistance may mean that the tip of the needle is lodged in the sclera, in which case move the tip of the needle slightly from side to side until it is disengaged.

If the needle has accidentally entered a vein, resulting in haemorrhage and a rapid swelling of the orbit, abandon the procedure. Delay the operation for at least 1 week, after which it can be performed with the patient under either a repeat retrobulbar block or, preferably, general anaesthesia.

Postoperative care

Postoperative care for the patient who has undergone extraocular surgery is quite simple: change the dressing the day after surgery and apply tetracycline 1% eye ointment daily for about 1 to 2 weeks. Remove sutures as indicated, after about 5–14 days.

After intraocular surgery, the patient should remain in hospital for at least 5 days. Strict immobilization is usually unnecessary, but the patient should avoid physical strain during the week following surgery. Dress the eye daily and apply appropriate topical medication. Remove conjunctival sutures after a week and corneoscleral sutures after about 3 weeks.

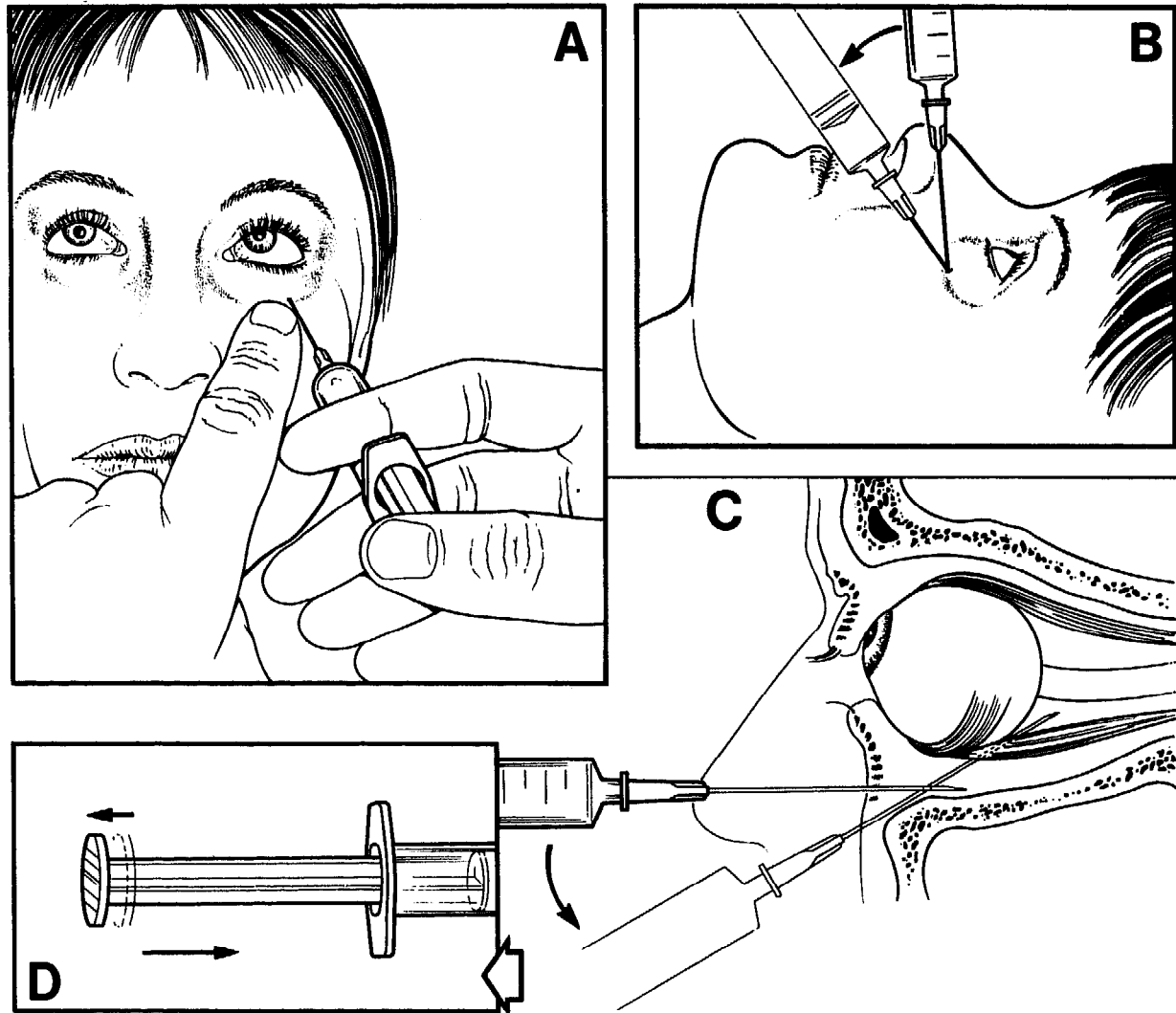


Fig. 4.3. Retrolubar block. Palpating the lower orbital margin and introducing the needle perpendicularly, close to its outer corner (A); angling the needle towards the junction of the roof and the medial wall of the orbit behind the globe (B, C); drawing back the plunger as the needle penetrates the muscle (D).

Postoperative complications

Possible postoperative complications of intraocular surgery include infections, prolapse of the iris, flattening of the anterior chamber, and intraocular haemorrhage. The patient who develops any of these will require prolonged hospitalization. Further management will depend upon the complication, but may include systemic or local administration of antibiotics, revisional surgery (with or without excision of the iris) with suturing, pressure-bandaging, or immobilization to re-establish the anterior chamber and reduce intraocular bleeding.

In cases of postoperative infection, such as active corneal infection with hypopyon, a subconjunctival injection of gentamicin (20 mg) may be given daily until there is improvement. Use a 2 ml syringe with a small hypodermic needle. First anaesthetize the conjunctiva with tetracaine drops, and then lift it slightly with the tip of the needle. Give the injection in the lower half of the bulbar conjunctiva (Fig. 4.4).

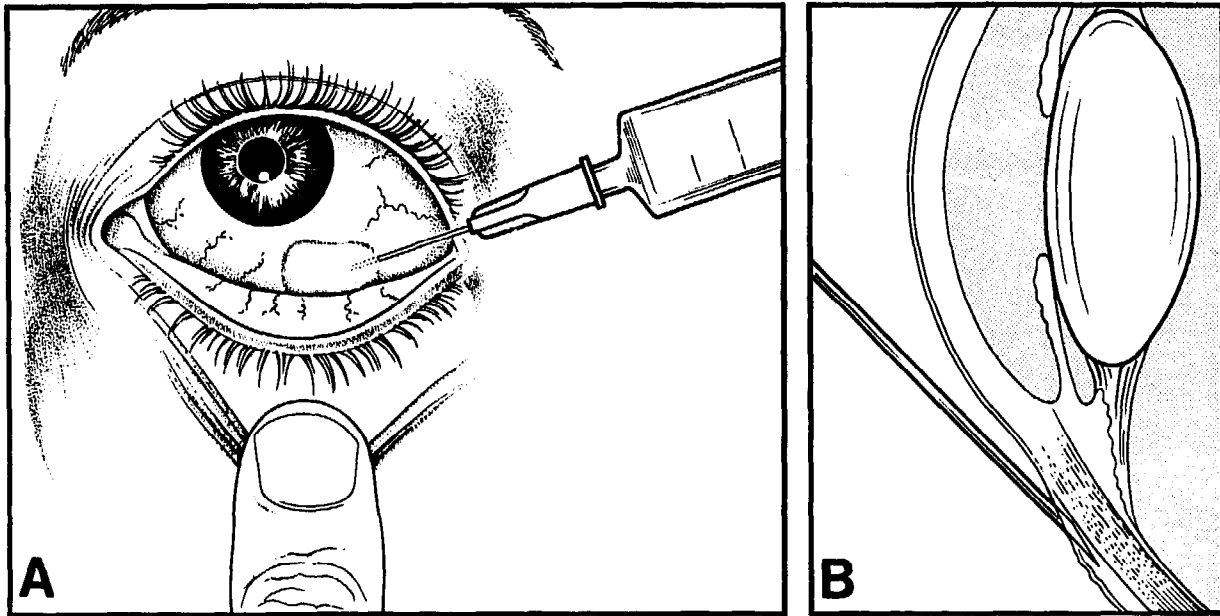


Fig. 4.4. Subconjunctival injection into the lower half of the bulbar conjunctiva with a small hypodermic needle.

Ocular trauma

Eye injuries are common and are an important cause of blindness. Early diagnosis and proper treatment are imperative if blindness is to be prevented.

Superficial injuries

Equipment See tray for *Tarsorrhaphy*, Annex 1, and add 2% sodium fluorescein, an eye spud, a 27-gauge needle, a syringe (2 ml) with a small hypodermic needle, and several cotton-tipped applicators.

Technique Superficial injuries of the eyelid, conjunctiva, or cornea do not require surgical intervention. Providing that no foreign body is present, copiously irrigate the eyelid and eye with sterile physiological saline and apply tetracycline 1% eye ointment. Dress the eyelid and eye with a simple sterile eye pad, with the eyelids closed. Leave the dressing in place for 24 hours, and then re-examine the eye and eyelids. If the injury has resolved or is improving, continue applying tetracycline 1% eye ointment three times daily for 3 days. Otherwise inject gentamicin subcutaneously and arrange to refer the patient.

Small foreign bodies may be embedded superficially in the conjunctiva or cornea. If a foreign body is embedded in the conjunctiva, wash it out with sterile saline or, after administering a topical anaesthetic, wipe it away with a sterile, cotton-tipped applicator. Eversion of the lid may be necessary to expose the foreign body. If you suspect a corneal foreign body, first instil two drops of 2% sodium fluorescein to make the foreign body (or breach of the epithelium) easier to detect. Remove a superficial corneal foreign body with an eye spud or a 27-gauge needle, and then manage the eye as for a superficial injury.

If the cornea remains infiltrated after removal of a foreign body, instil atropine 1% eye drops or ointment once daily, apply tetracycline 1% eye ointment every 8 hours, and give a subconjunctival injection (Fig. 4.4) of gentamicin 20 mg daily (after applying a topical anaesthetic) for 3 days. Refer patients with corneal

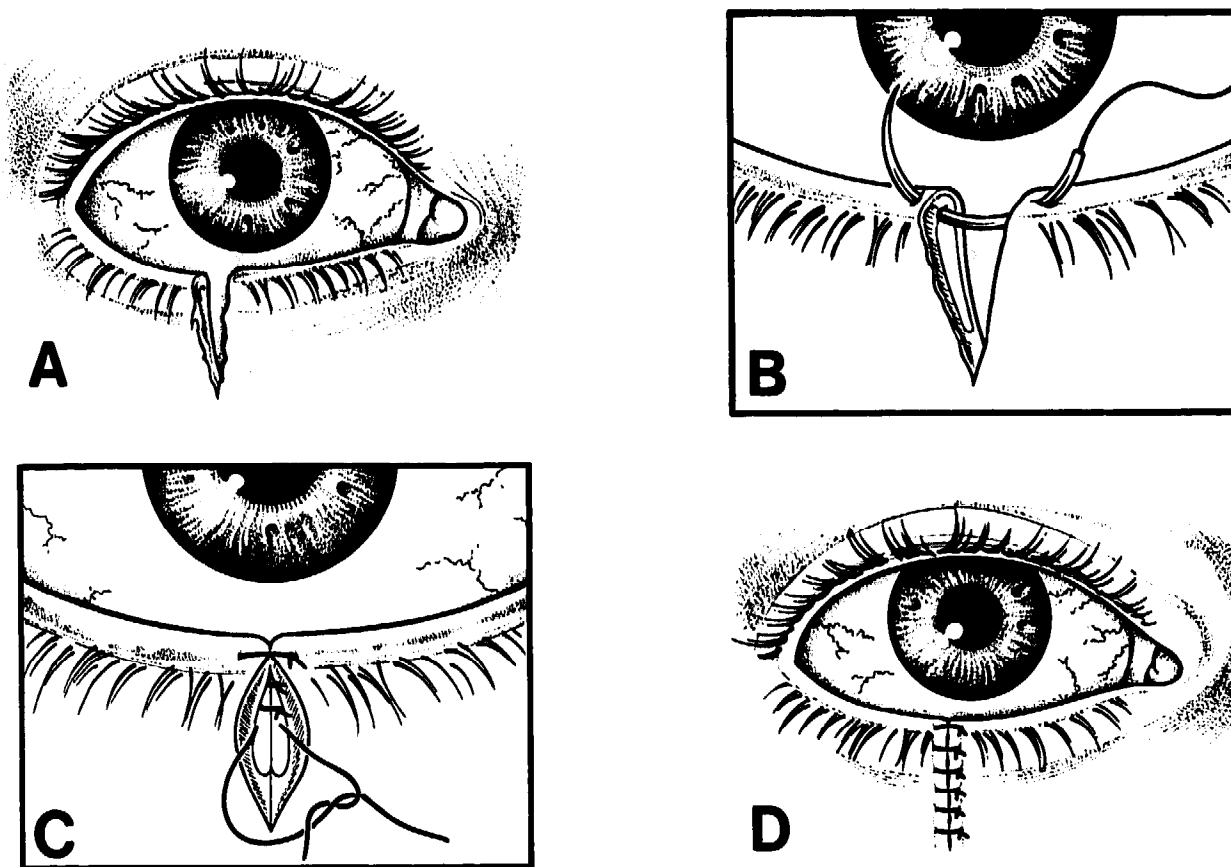


Fig. 4.5. Repairing a laceration of the eyelid. Laceration (A); inserting the key suture to align the lid margin (B); suturing the conjunctiva and tarsus (C, the knots are tied away from the eyeball); suturing the skin and muscle (D).

foreign bodies that cannot be removed and patients who show no decrease of corneal infiltration after 3 days of treatment.

Admit to hospital any patient with inflammation of the globe with hyphaema (blood in the anterior chamber). Place the patient at complete rest, with sedation if required, and patch both eyes. If intraocular pressure is elevated, as indicated by a total hyphaema or pain, administer acetazolamide 250 mg orally every 6 hours. Examine and dress the eye daily. If the hyphaema has not clearly improved in 5 days, refer the patient.

Lacerations and penetrating injuries

The patient should be anaesthetized as appropriate.

Equipment

See tray for *Cataract operation*, Annex 1, and add 6/0 thread and catgut.

Eyelids

Make every attempt to preserve tissue, but carry out wound toilet and, if necessary, débridement. Do not shave the brow or invert hair-bearing skin into the wound. If the laceration involves the eyelid margin, place an intermarginal suture behind the eyelashes; precise alignment of the wound margins is essential (Fig. 4.5A,B). Carry out the repair in two layers: the conjunctiva and tarsus with 6/0 catgut, and the skin and muscle (orbicularis oculi) with 6/0 thread (Fig. 4.5C,D). Tie suture knots away from the eyeball.

Lacerations involving the inferior lacrimal canaliculus require canalicular repair, so the patient should be referred for specialized surgical management. If this is impossible, repair the lid margin and laceration as described above.

Immunize the patient against tetanus with tetanus toxoid and give penicillin systemically.

Globe

Manage perforation of the cornea without iris prolapse and with a deep anterior chamber by applying atropine 1% eye drops or ointment and by administering gentamicin, either in 1% eye drops or as a subconjunctival injection of 20 mg (after a topical anaesthetic has been applied). Dress the injured eye with a sterile pad and examine it daily.

After 24 hours, if the anterior chamber remains formed, apply atropine 1% and tetracycline 1% eye ointment daily for another week. If the anterior chamber is flat, apply a pressure bandage for 24 hours. If there is no improvement, suture the cornea after applying a topical anaesthetic.

A patient with perforation of the cornea with iris incarceration and with a deep anterior chamber should be treated in the same way.

Manage corneal or corneoscleral laceration with prolapse of the iris, lens, or vitreous body by excising the prolapsed intraocular elements (with the patient anaesthetized as appropriate) and then closing the corneal and corneoscleral wounds with 8/0 thread. If possible, refer the patient to an ophthalmologist. If referral is not possible, treat the patient postoperatively with atropine 1% drops or ointment and with gentamicin 20 mg injected subconjunctivally (after a topical anaesthetic has been applied). Dress the injured eye with a sterile pad and shield for 24 hours. Change the dressing and apply atropine 1% and tetracycline 1% eye ointment daily for 1 week. Remove the sutures after about 1 month.

Posterior rupture of the globe is to be suspected if there is low intraocular pressure and poor vision. Instil atropine 1%, protect the injured eye with a sterile pad and shield, and refer the patient to an ophthalmologist.

If, on the basis of X-ray and clinical examinations, you suspect the presence of an intraocular foreign body, apply atropine 1%, dress the eye with a sterile pad and shield, and refer the patient to an ophthalmologist.

All patients with injuries to the globe should be immunized against tetanus.

Extraocular surgery

Removal of chalazion

Chalazion is a chronic inflammatory granuloma or cyst, usually the size of a small pea, within one of the tarsal glands of the eyelid. Surgery is indicated if the swelling is long-standing and does not respond to local medical treatment. The condition sometimes recurs in adjacent glands.

Equipment

See tray for *Removal of chalazion*, Annex 1.

Technique

After establishing topical anaesthesia with 0.5% tetracaine, inject 1–2 ml of 2% lidocaine around the chalazion through the skin. Apply the chalazion clamp with the solid plate on the skin side and the fenestrated plate around the cyst, tighten the screw, and evert the lid. Incise the cyst at right angles to the lid margin and remove its contents with the curettes (Fig. 4.6). Remove the clamp and apply pressure on the lid until bleeding stops. Apply tetracycline 1% eye ointment, and dress the eye with a pad and bandage. Apply ointment daily until the conjunctiva is healed (about 5 days). It is usually unnecessary to re-examine the patient unless there is a recurrence.

Tarsorrhaphy

Tarsorrhaphy is the surgical joining of the upper and lower eyelids to close the eye partially, as a temporary protection to the cornea. Tarsorrhaphy is indicated in cases of facial nerve paralysis or when there is a loss of corneal sensation.

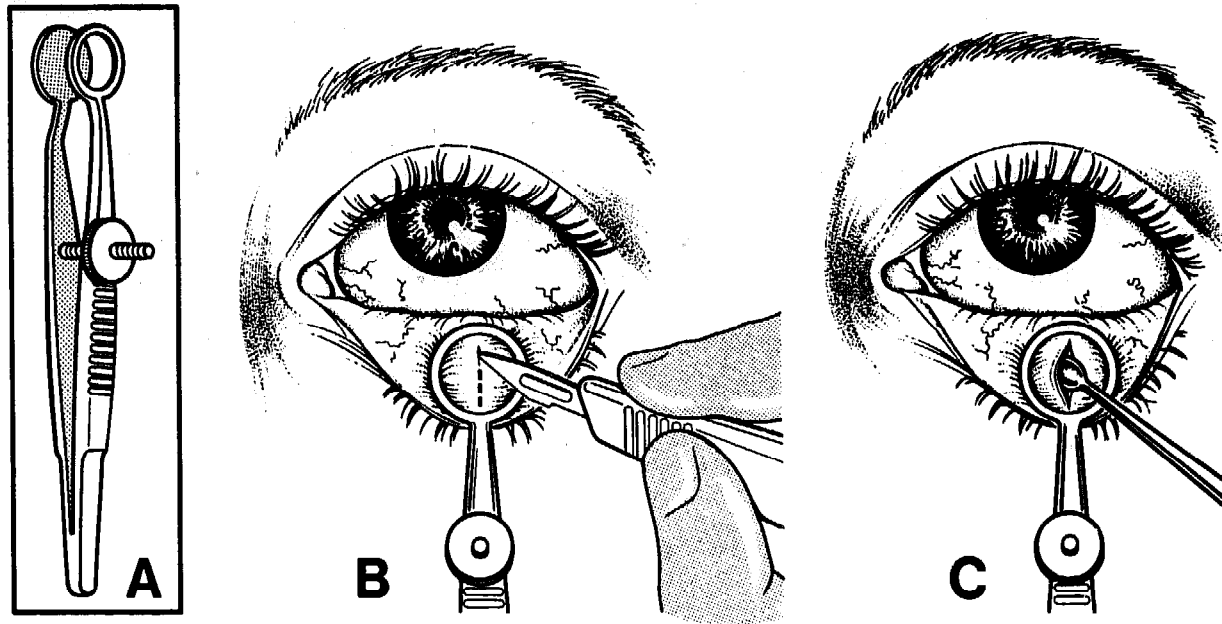


Fig. 4.6. Excision of chalazion. Chalazion clamp (A); incising the cyst after applying the clamp (B); removing the contents with a curette (C).

Equipment See tray for *Tarsorrhaphy*, Annex 1.

Technique First determine the length of join required (Fig. 4.7A). After administering a topical anaesthetic, infiltrate each lid with 2 ml of 2% lidocaine. Incise to a depth of 2 mm along the grey line of both lid margins in the lateral canthus (Fig. 4.7B). Join the two lids by inserting mattress sutures of 4/0 thread passed through rubber tubing about 5 mm below the lash line (Fig. 4.7C,D). Apply a sterile eye pad and secure it with adhesive tape. Remove the sutures when the lids have united, after about 14 days.

Apply tetracycline 1% eye ointment daily until the stitches are removed.

Opening a tarsorrhaphy

Once the tarsorrhaphy is no longer needed, the eye may be opened. After administering a topical anaesthetic, infiltrate the upper and lower lids with 2% lidocaine. Pass one blade of a pair of scissors posterior to the adhesion and one anterior, and separate the lids with a single cut.

Treatment of trichiasis and entropion

Trichiasis is a condition in which the eyelashes grow inwards and irritate the eye. In entropion the lid margin is also inverted, and rubs on the cornea (Fig. 4.8A). The most important and common cause of these conditions in many developing countries is trachoma, usually affecting the upper eyelid; other features of trachoma may also be apparent, for example pannus formation.

Equipment See tray for *Treatment of entropion*, Annex 1.

Technique In cases of trichiasis, epilation can give temporary relief, but surgery may become necessary if the condition progresses to entropion. There are various techniques for surgically correcting entropion. The procedure described here is simple and widely used, and closely resembles the one described by Trabut, for which standard instrument sets are available.

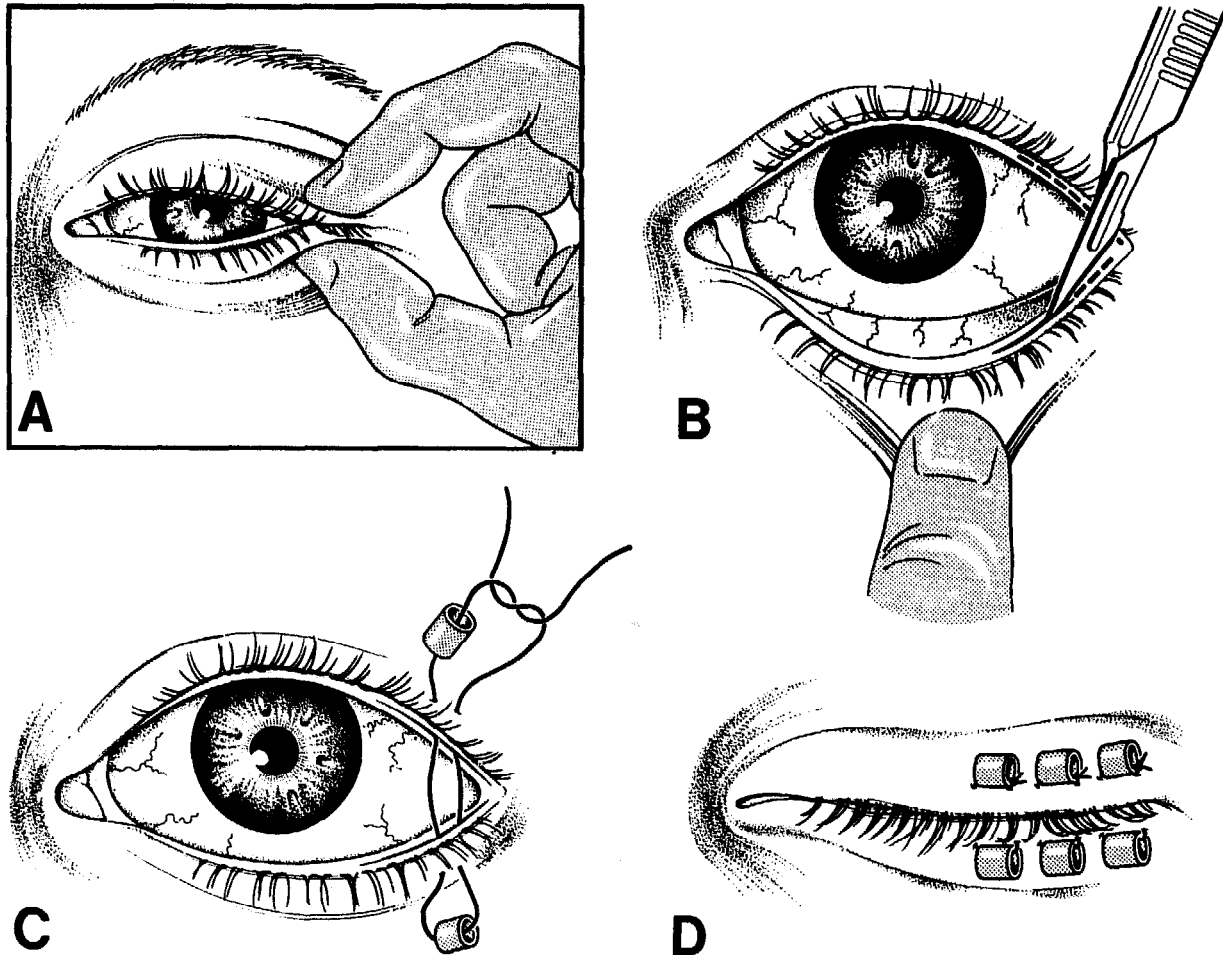


Fig. 4.7. Tarsorrhaphy. Estimating the length of join required (A); incising along the grey line of the lid margin (B); joining the lids with mattress sutures passed through short pieces of rubber tubing (C, D; about three stitches are usually sufficient).

Clean the eyelids with sterile saline and apply drapes. Administer a topical anaesthetic and infiltrate 2 ml of 2% lidocaine (1 ml at each of two points) midway between the lid margin and the eyebrow (Fig. 4.8B). Next evert the lid and hold the tarsal surface exposed with forceps. Make an incision in the palpebral conjunctiva, approximately 2 mm from the lid margin (Fig. 4.8C); a supporting plate (or eyelid clamp) will facilitate this. Raise the larger tarsal plate as a flap from the lid by undercutting as far back as the insertion of the levator palpebrae muscle; also undercut the smaller segment to the lid margin (Fig. 4.8D,E). It is important to incise and undercut the tarsal plate in the entire lash-bearing part of the lid. Now insert two mattress sutures of 4/0 thread through the skin and the larger tarsal flap, and make a knot at the skin surface (Fig. 4.8F-I). Leave the distal tarsal flap unstitched. Apply a sterile eye pad, followed by another pad and a bandage.

After-care

Apply tetracycline 1% eye ointment daily for 2 weeks. Remove sutures after 8 days. Inpatient care is necessary for patients who have had simultaneous operations on both eyes.

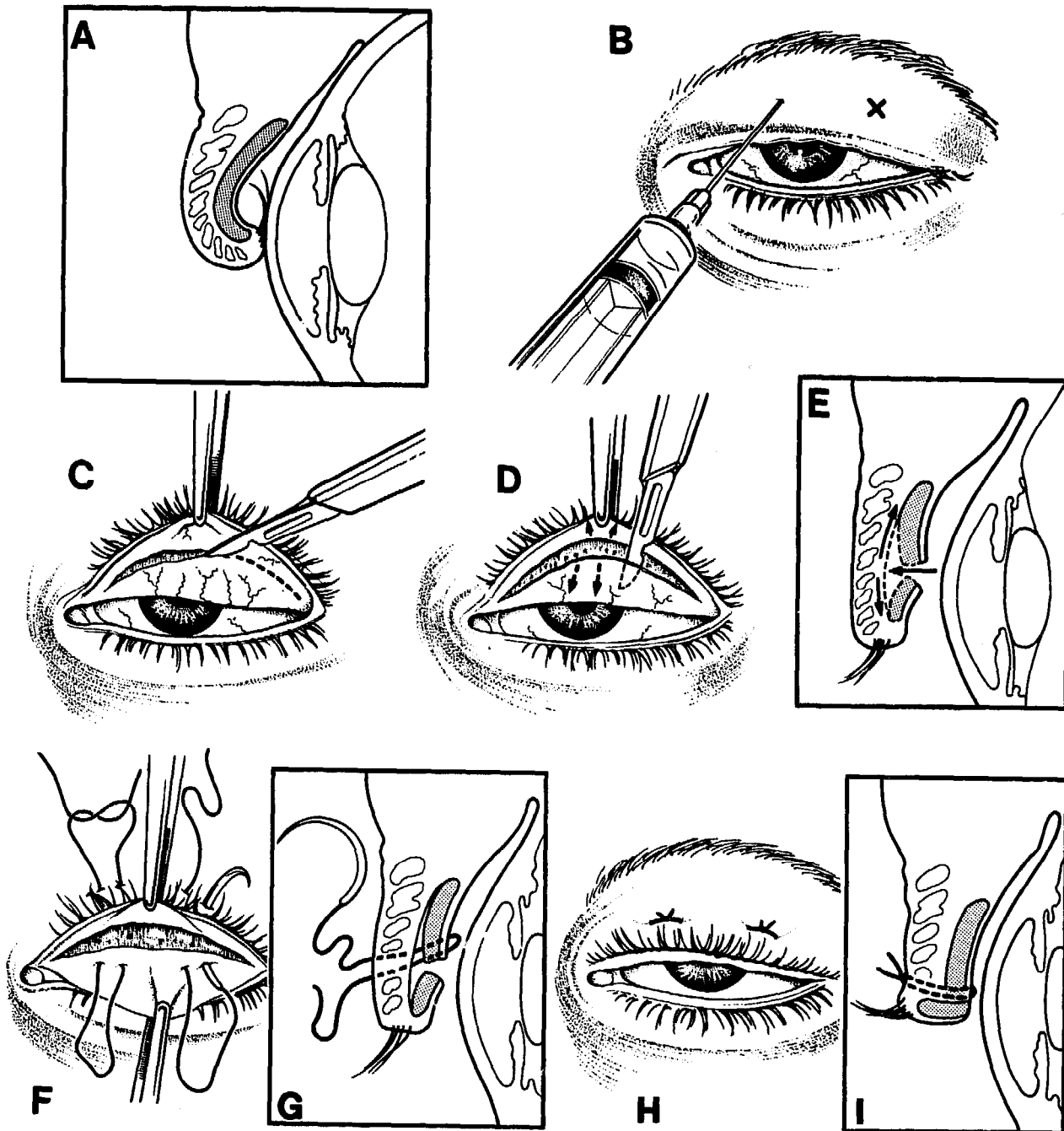


Fig. 4.8. Correction of entropion. Entropion (A); infiltrating the lid margin with local anaesthetic at two points (B); incising the palpebral conjunctiva of the everted lid (C) and raising flaps of tarsal plate (D, E); inserting two mattress sutures through the skin and the proximal (larger) tarsal flap (F, G); tying the stitches (H, I).

Excision of pterygium

A pterygium is an overgrowth... on to the cornea caused by a chronic degenerative change in the conjunctiva. It is triangular, with its base at the limbus and its apex pointing towards the centre of the cornea (Fig. 4.9A). Advanced pterygium can lead to loss of vision.

Small pterygia should be left alone. Only where the pterygium extends to the central optical zone of the cornea should surgery be considered. Surgical results,

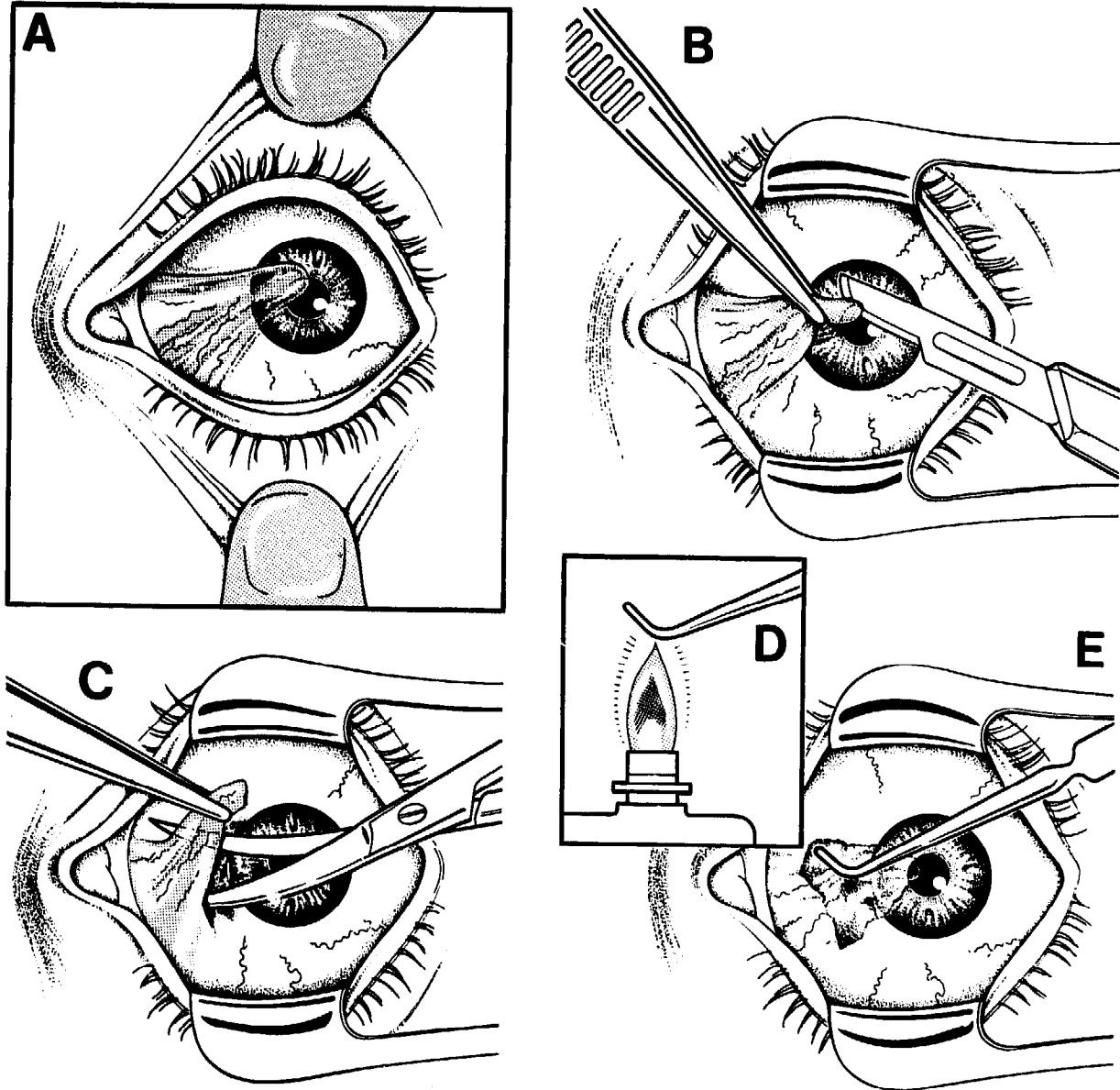


Fig. 4.9. Excision of pterygium. Characteristic shape and site of a pterygium (A); freeing the head of the pterygium from the cornea with a pterygium knife (B); excising the pterygium with conjunctival scissors (C); hot-point cautery (D) is used to stop bleeding from the bare area of the sclera (E).

however, are generally poor and recurrences are frequent, so patients whose pterygia require excision should be referred. If referral is impossible, proceed as follows.

Equipment See tray for *Excision of pterygium*, Annex 1.

Technique Apply 0.5% tetracaine topically and infiltrate the subconjunctiva with 1 ml of 2% lidocaine.

Grasp the neck of the pterygium and free its head from the corneal surface using the pterygium knife (Fig. 4.9B). Excise the freed pterygium with the conjunctival

scissors 4 mm from the limbus (Fig. 4.9C), leaving a bare area of sclera. Stop any bleeding with hot-point cautery (Fig. 4.9D,E). Apply tetracycline 1% eye ointment and dressings. Continue daily application of the ointment and of fresh dressings for 1 week. If there is a recurrence after surgery, the patient must be referred.

Intraocular surgery

Cataract extraction

Although cataract extraction may be performed in district hospitals, it should be done only by general practitioners who have received the necessary training or by ophthalmic surgeons through an "outreach" programme. The following description is intended solely as an *aide-mémoire* for persons who have previous experience of the operation.

Cataract is an opacity of the crystalline lens of the eye. Minor lens opacities are extremely common, but more extensive lens opacities interfere with light passing through the crystalline lens and therefore reduce vision. Most cataracts occur in the elderly; they are usually classified as "senile" cataracts and their causes are unknown. Congenital cataract, which affects infants and young children, can cause lifelong blindness if left untreated. However, surgical treatment is more difficult than for senile cataract, and patients suffering from congenital cataract should therefore be referred. Also refer patients with cataracts secondary to trauma and those with cataracts complicating other ocular or systemic diseases, for example corneal opacity.

Serious visual impairment due to bilateral senile cataract that interferes with the patient's daily activities is the main indication for surgery at the district hospital. It is not necessary to operate on unilateral cataract if there is useful vision in the other eye. If both eyes are badly affected, operate first on the eye with the poorer vision. In general, operate only on patients over 50 years of age.

Diagnosis

The criteria for diagnosis of cataract are a history of progressive loss of vision and an absence of or a markedly diminished red reflex from the fundus of the eye, as viewed with an ophthalmoscope.

Assessment and preoperative management

If surgery is indicated, first take the history of the illness and assess the patient's vision, particularly as to accurate light projection. Examine the eye, including the reaction of the pupil to light. Check the red reflex and determine the intraocular pressure. Carefully wash the patient's face when he or she is admitted to hospital. Apply tetracycline 1% eye ointment and atropine 1% every 8 hours to the eye to be operated on, up to the time of surgery. This treatment should be started at the latest 24 hours before operation. In addition, give acetazolamide 250 mg orally 8 hours and 2 hours prior to surgery.

Equipment

See tray for *Cataract operation*, Annex 1.

Technique

Intracapsular cataract extraction (extraction of the cataract within its capsule) is recommended here, as extracapsular cataract extraction is technically more difficult and prone to complications such as corneal damage, infection, and opacification of the posterior capsule.

After sedating the patient, produce facial block by the injection of 2–3 ml of lidocaine 2% into the temporal portion of the upper and lower lids over the orbital rims, and inject a further 2 ml of lidocaine into the retrobulbar area. Achieve topical anaesthesia with one drop of tetracaine 0.5%. To help lower intraocular pressure, massage the closed eye with a finger for 1 min.

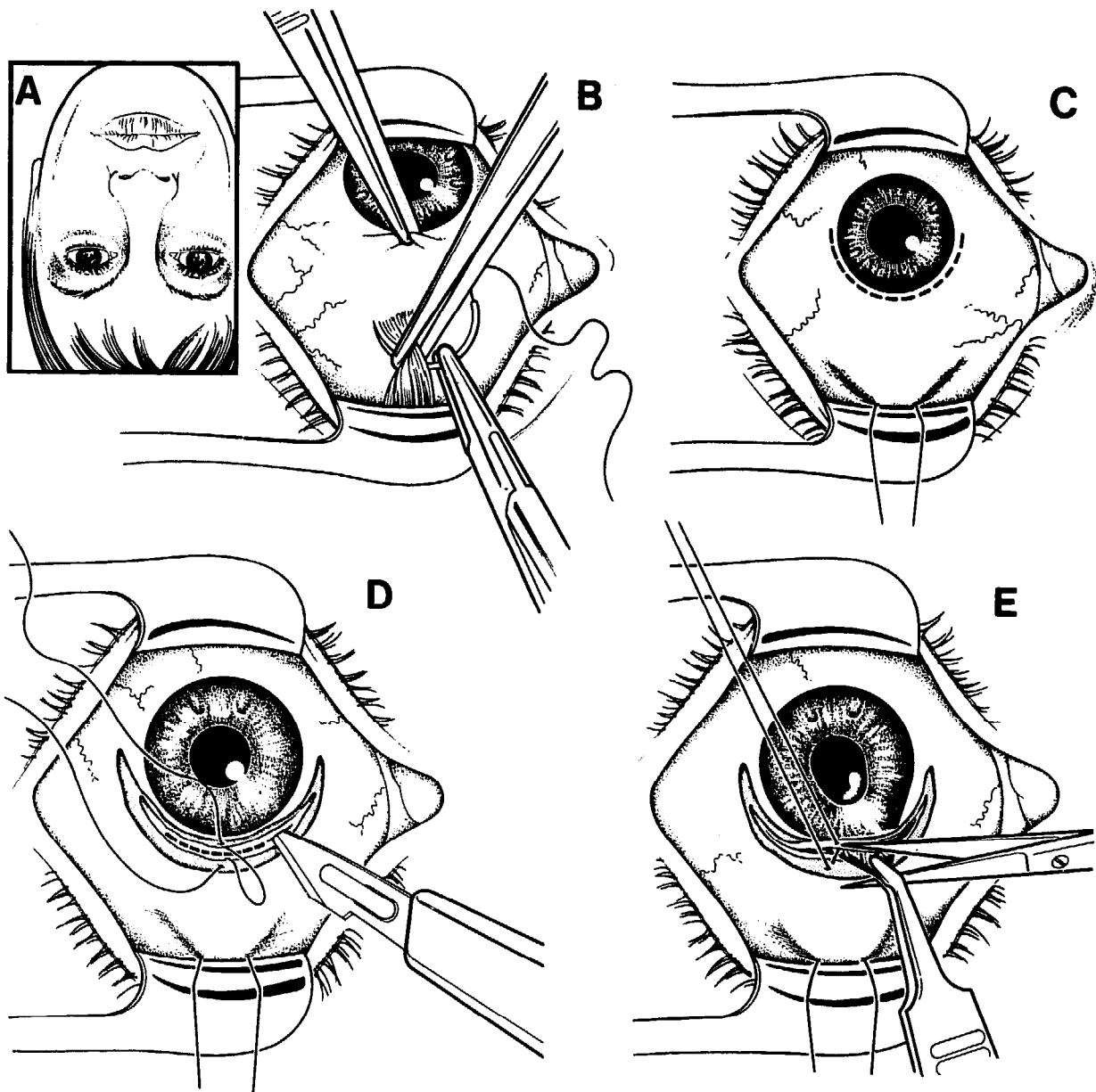


Fig. 4.10. Intracapsular extraction of cataract. Position of the patient (A, as seen by the surgeon at the head of the table); turning the eye down and passing a suture beneath the superior rectus tendon (B); site of conjunctival incision (C); incising along the limbus and inserting a suture across the groove (D); excising a small piece of the iris (E).

Clean the ocular adnexa and face with 1% cetrimide and drape the surgical field with sterile towels. Irrigate the surface of the eye and fornices with sterile saline.

Stand at the head of the operating table, so that the patient's face appears upside-down (Fig. 4.10A). Insert an eyelid speculum for lid retraction. With toothed forceps, grasp the conjunctiva at the edge of the cornea in the region of 12 o'clock,¹ and turn the eye down (away from you). With another pair of forceps,

¹To interpret references to 12 o'clock, 9 o'clock, etc., imagine a clock face superimposed on the patient's cornea, with 12 o'clock nearest the patient's supraorbital margin.

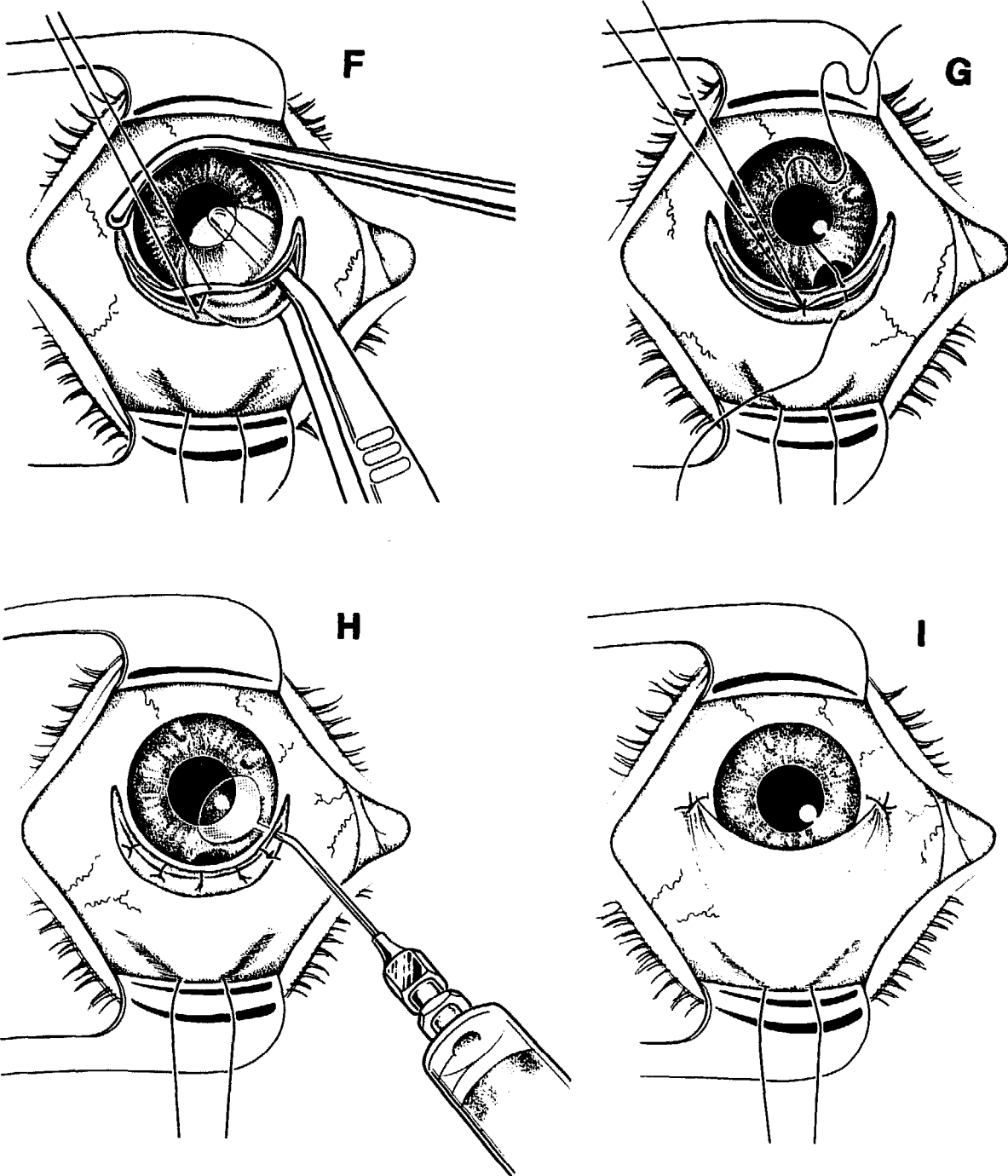


Fig. 4.10. Intracapsular extraction of cataract (*continued*). Extracting the lens (F); tying the preplaced suture and inserting further sutures to close the corneoscleral incision (G); reforming the anterior chamber by injecting a small air bubble (H); drawing the conjunctival flap down over the wound and anchoring it (I).

grasp the superior rectus tendon through the conjunctiva, about 8 mm behind the first pair of forceps. Lift the tendon from the globe and pass a piece of 3/0 thread beneath the tendon, taking care not to puncture the sclera (Fig. 4.10B). Clip the suture to the drape above the eye so as to rotate the eye downwards and away from you. (Do not clip it too tightly.) Incise the conjunctiva at the limbus from 9 to 3 o'clock (Fig. 4.10C), and then separate it from the limbus with conjunctival scissors. Achieve haemostasis with hot-point cautery.

Make an incision perpendicular to the surface of the globe from 10 to 2 o'clock along the limbus, cutting through one-half to two-thirds of the depth of the corneoscleral tissue; insert an 8/0 thread suture across the groove at 12 o'clock and loop it aside (Fig. 4.10D). Open the anterior chamber with a No. 11 blade or keratome, and extend the corneoscleral section along the groove using corneal scissors.

Ask an assistant to lift the cornea gently with the looped suture, while you grasp the iris at its base at 12 o'clock, with iris forceps. Gently withdraw the iris outside the incision and excise a small piece at its base with iris scissors, to form a peripheral iridectomy (Fig. 4.10E). Avoid routine intraocular irrigation, but keep the cornea moist. As your assistant gently lifts the cornea, extract the lens by grasping the anterior lens capsule at 6 o'clock with capsule forceps and pulling it out while applying light pressure with a muscle hook at the inferior limbus (Fig. 4.10F). If the lens capsule ruptures, remove the lens nucleus with capsule forceps or a vectis while you apply pressure at the limbus at 6 o'clock and posteriorly to the wound at 12 o'clock. Wash out the remaining lens material with sterile saline.

In the event of prolapse of the vitreous body, the anterior chamber may be freed of vitreous material by either aspiration or excision, followed by sponging.

Draw down and tie the preplaced suture, and place at least four additional 8/0 thread sutures at regular intervals to close the corneoscleral incision (Fig. 4.10G). Through a cannula on a syringe, inject just enough air behind the cornea to reform the anterior chamber (Fig. 4.10H). Draw the conjunctival flap down over the cornea and anchor it at 3 o'clock and 9 o'clock using 8/0 thread (Fig. 4.10I).

Remove the superior rectus suture and inject gentamicin 20 mg subconjunctivally. If gentamicin is not available, crystalline benzylpenicillin 12 mg (20 000 units) may be given. Apply tetracycline 1% eye ointment in the inferior fornix, and dress the eye with a sterile pad and shield.

After-care

After 24 hours, at the first change of dressing, carefully inspect the eye for evidence of early postoperative complications such as a cloudy cornea (due to oedema), a shallow anterior chamber, or hyphaema.

Administer atropine 1% eye drops and tetracycline 1% eye ointment daily for 5 days. Add hydrocortisone 1% eye ointment from the second postoperative day. The patient may be discharged after 5 days. Hydrocortisone application can normally be continued for another 2-3 weeks, but only if treatment can be supervised. The patient should make postoperative follow-up visits at 2 weeks, 6 weeks, and 6 months.

Remove the corneoscleral sutures after 2-3 weeks, with the patient under topical anaesthesia if necessary, and provide spectacles for aphakia at 6 weeks.

Complications

If the patient develops a shallow anterior chamber with air behind the iris, fully dilate the pupil with atropine so that air may re-enter the anterior chamber.

If there is a shallow anterior chamber with a suspected wound leak or a gaping wound, apply a pressure bandage for 2 days. If the wound is obviously leaking, place additional corneoscleral sutures, preferably with the patient under general anaesthesia.

If hyphaema develops, pad the eye bilaterally and prescribe bed-rest for 5 days.

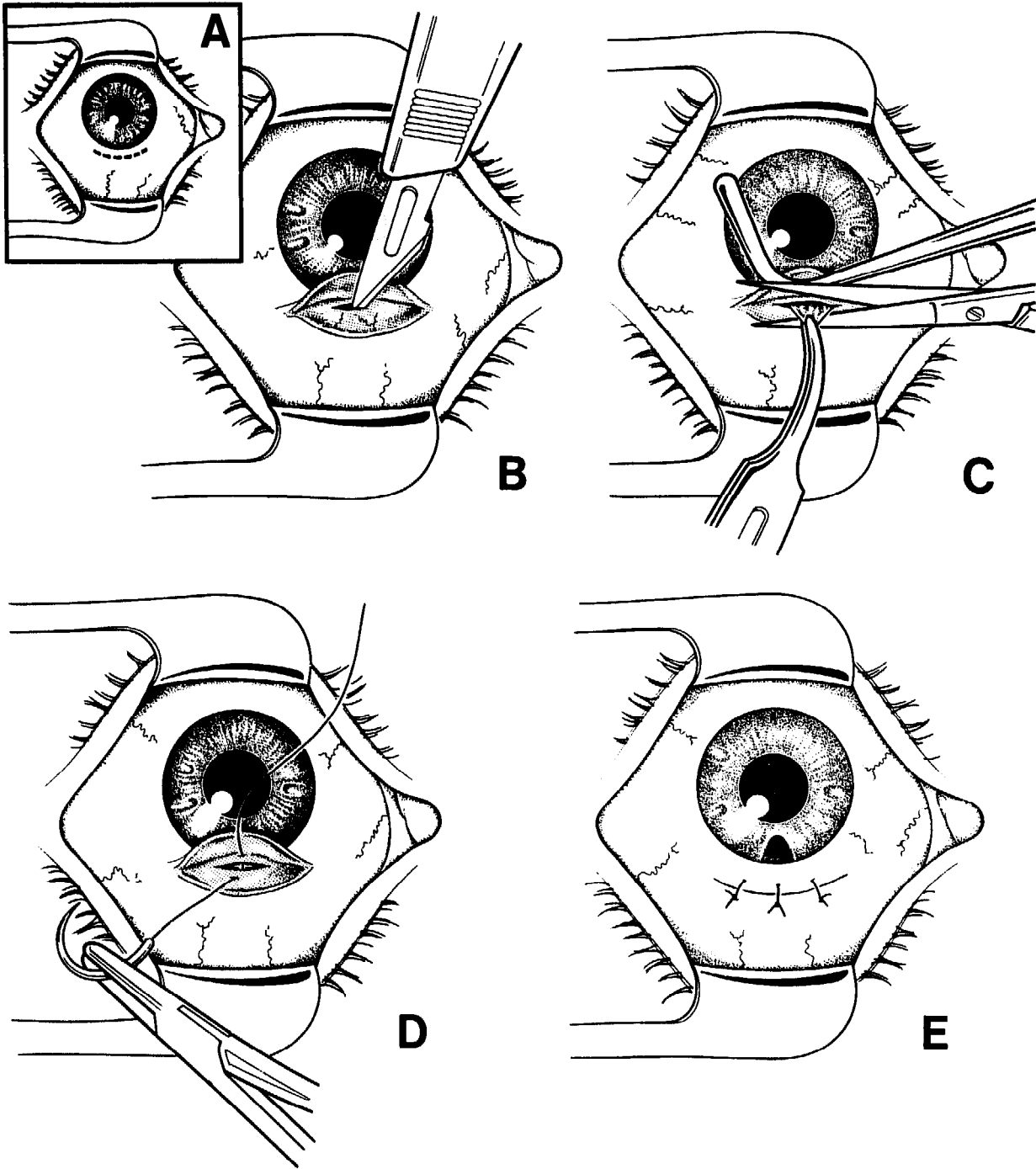


Fig. 4.11. Peripheral iridectomy for acute angle-closure glaucoma. Site of incision above the upper limbus (A, as seen by the surgeon at the head of the table); opening the anterior chamber by incision in the corneoscleral junction (B); excising the prolapsed part of the iris (C); closing the corneoscleral wound (D); the conjunctival flap is replaced and sutured (E).

If there is prolapse of the iris, excise the iris and resuture the corneoscleral wound, preferably with the patient under general anaesthesia.

In case of infection, administer a topical anaesthetic and inject gentamicin or penicillin subconjunctivally.

Treatment of acute angle-closure glaucoma

Acute angle-closure glaucoma is an ocular surgical emergency, and its management should be prompt, with the aim of lowering intraocular pressure rapidly by a course of drugs. Immediate management is followed by surgery (peripheral iridectomy). Administer acetazolamide orally in an initial dose of 500 mg, followed by 250 mg every 6 hours. Instil one drop of pilocarpine 2% into the affected eye every minute for 5 min, then every 15 min for 1 hour, and then hourly until the tension is controlled. Give suitably flavoured glycerol 1 g/kg of body weight orally daily.

It is best to refer the patient, but if this is impossible, undertake curative surgery after intraocular pressure has been reduced to less than 25 mmHg (3.33 kPa).

Equipment See tray for *Cataract operation*, Annex 1.

Technique Prepare the patient as recommended for cataract surgery, but do not use atropine.

Stand at the head of the operating table, so that the patient's face appears upside-down. Make a 10 mm incision in the conjunctiva, 4 mm above and parallel to the upper limbus (Fig. 4.11A). Undercut the conjunctiva and reflect it onto the cornea. Achieve haemostasis with hot-point cautery.

Using a No. 11 blade, make a 4 mm incision perpendicular to the surface of the globe in the region of 12 o'clock in the corneoscleral junction. Deepen the incision to open the anterior chamber (Fig. 4.11B). Gently depress the conjunctival flap over the cornea, thus causing a small peripheral part of the iris to be prolapsed through the incision. Excise the prolapsed part of the iris (Fig. 4.11C), and then gently return the rest of the iris to its original position. Close the corneoscleral wound with a single 8/0 thread suture (Fig. 4.11D). Replace the conjunctival flap and suture it with two to three stitches of 8/0 thread (Fig. 4.11E).

Apply homatropine 2% eye drops, tetracycline 1% ointment, and a sterile eye pad to the eye. Continue to give the patient acetazolamide 250 mg every 6 hours for 2 days.

As acute angle-closure glaucoma is often a bilateral disease, the patient should be referred for investigation and, if necessary, treatment of the other eye. Until referral, give the patient pilocarpine 1% eye drops to instil daily into the untreated eye.

Enucleation of the eye

Enucleation of the eye is the surgical removal of the entire globe.

The prospect of losing an eye can have a devastating emotional impact on both the patient and his or her relatives. The decision should be taken only after a very careful consideration of the state of the affected eye, when all efforts to save the eye have failed, and when the eye is clearly useless. Seek the opinion of an ophthalmologist, whenever possible. If this is not possible, consider enucleation only for painful eyes with long-standing, obvious, and complete blindness (no perception of light). Always give a careful explanation of what is involved to the patient and relatives concerned, and obtain the patient's written consent to surgery. In cases of ocular trauma, always attempt to repair the globe and then refer the patient to an ophthalmologist.

Equipment See tray for *Enucleation of the eye*, Annex 1.

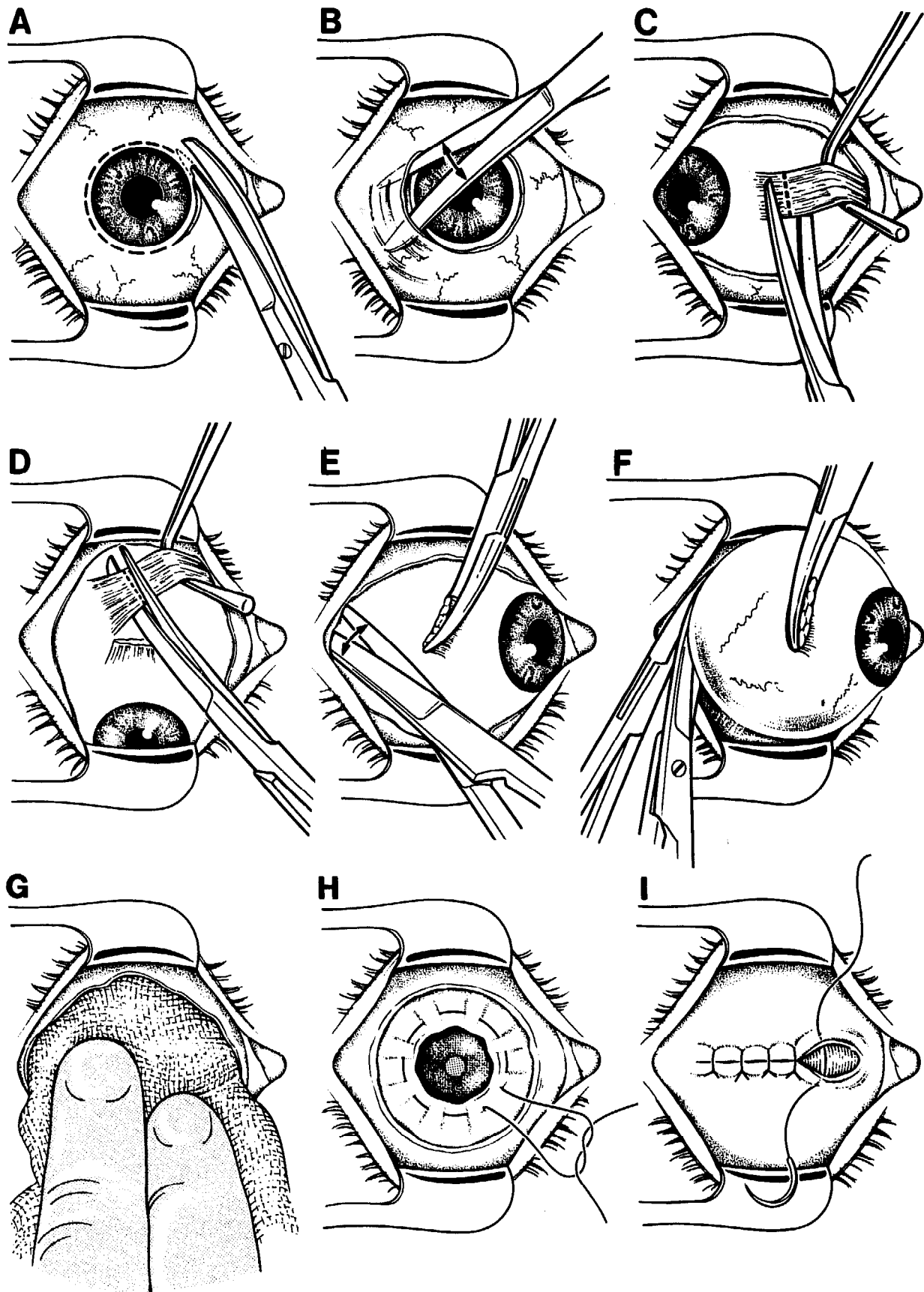


Fig. 4.12. Enucleation of the eye. Incising the conjunctiva all around the limbus (A); dissecting the conjunctiva and the fascial sheath from the sclera (B); identifying and cutting the rectus muscles, leaving a small fringe on the globe (C); identifying and cutting the tendons of the oblique muscles (D); freeing the globe from the fascial sheath (E); identifying, clamping, and dividing the optic nerve (F); applying pressure over gauze after removing the globe (G); closing the fascial sheath with a purse-string suture (H); suturing the conjunctiva (I).

General anaesthesia is preferable, but retrobulbar block with infiltration anaesthesia of the eyelids is an alternative. Also give a topical anaesthetic.

Technique

Stand at the head of the operating table, so that the patient's face appears upside-down. Incise the conjunctiva with scissors all around the limbus (Fig. 4.12A). Lift the conjunctiva and fascial sheath (Tenon's capsule) from the sclera by blunt dissection with scissors (Fig. 4.12B). Identify the rectus muscles and isolate them with a muscle hook. Cut each muscle, leaving a small fringe on the globe (Fig. 4.12C). Next identify and isolate the tendons of the superior and inferior oblique muscles with a muscle hook and cut them (Fig. 4.12D). With a steady hold on the fringe of the medial or lateral rectus to stabilize the eye, free the globe from the fascial sheath by blunt dissection (Fig. 4.12E). Identify and clamp the optic nerve with curved forceps. Cut the nerve between the globe and the forceps with enucleation scissors, but do not tie off the nerve (Fig. 4.12F). Apply pressure over gauze until all bleeding is stopped (Fig. 4.12G). Close the fascial sheath with a purse-string suture of 4/0 chromic catgut (Fig. 4.12H), and suture the conjunctiva with interrupted 5/0 or 6/0 plain catgut (Fig. 4.12I). Apply tetracycline 1% eye ointment, a sterile eye pad, and a pressure bandage.

After-care

Administer analgesics to relieve pain, and apply tetracycline 1% eye ointment daily for at least 8 weeks. The patient can later be referred for the fitting of a prosthesis.

5

Ear

Removal of foreign bodies

Children often insert foreign bodies, such as beans, peas, rice, beads, fruit seeds, or small stones, into their ears. Accumulated ear wax can be confused with foreign bodies and is common in both adults and children.

Equipment See tray for *Removal of foreign body from the ear*, Annex 1.

Techniques Administer a basal sedative before proceeding.

Syringing the ear will remove most foreign bodies, although it should be avoided if the foreign body absorbs water, for example grain or seeds. A foreign body can also be removed by gentle suction through a soft rubber tube introduced into the ear to rest against the object (Fig. 5.1A,B). The procedure is simple, painless, and usually effective.

As an alternative, an aural curette or hook may be passed beyond the foreign body and then turned so that the foreign body is withdrawn by the hook (Fig. 5.1C,D). This requires a gentle technique and a quiet patient; children should therefore first be adequately sedated or be given a general anaesthetic.

A mobile insect in the ear is, at the very least, irritating. Before removing the insect by syringing, immobilize it by irrigating the ear with glycerol.

To remove accumulated ear wax, syringe the ear with a warm, weak solution of sodium bicarbonate. If the wax remains, instruct the patient to instil glycerol drops several times a day for 1–2 days before you attempt further syringing.

Myringotomy

Myringotomy is the incision of the tympanic membrane, usually to drain pus from the middle ear. The main indication for myringotomy is acute otitis media when there is severe intractable pain despite treatment with analgesics, a markedly bulging membrane, a poor response to 24–48 hours of antibiotic therapy, features suggestive of early mastoiditis (swelling and tenderness), or facial nerve palsy. Relief of pain after this operation is often immediate and dramatic.

Assessment and preoperative management

Measure the patient's haemoglobin level and test the urine for sugar and protein. Obtain a radiograph of the mastoid bones to check for possible mastoiditis, and take a sample of the discharge from the ear for bacteriological examination. Continue treatment with analgesics and antibiotics.

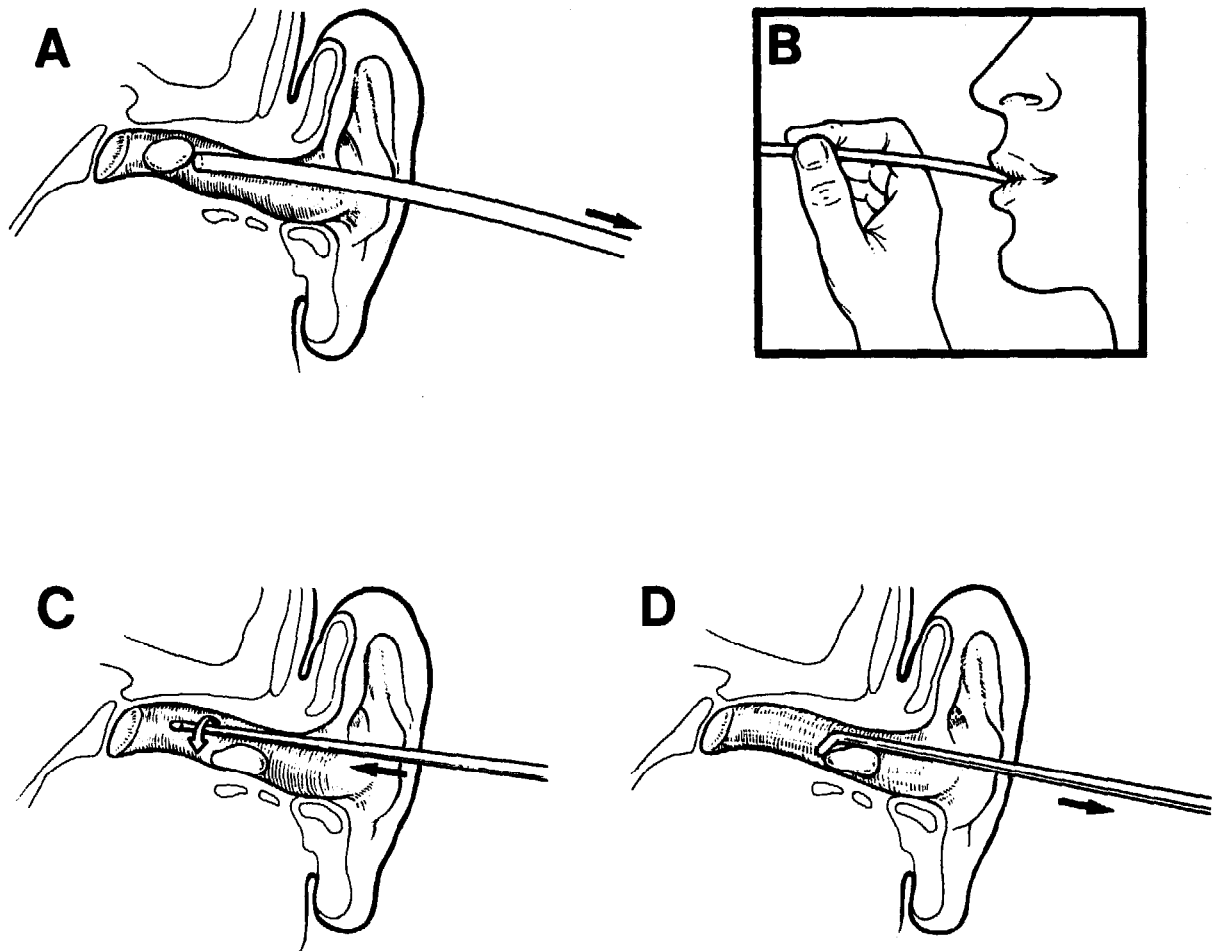


Fig. 5.1. Removal of a foreign body from the ear. Removal by suction (A, B); removal using a hook (C, D).

Equipment See tray for *Myringotomy*, Annex 1.

Technique General anaesthesia may be used, but local anaesthesia is often adequate. Sedate children before administering a local anaesthetic. Prepare the skin of the pinna and the external auditory canal with an antiseptic solution and, if local anaesthesia has been chosen, infiltrate the external canal with 1% lidocaine. Insert a speculum and view the bulging membrane (Fig. 5.2A). Using a scalpel with a partially covered blade, make a curved incision in the antero-inferior quadrant of the membrane to let the pus drain (Fig. 5.2B,C), and take a sample for bacteriological examination. Clean the ear and apply a cotton-wool dressing.

After-care Continue the administration of antibiotics and analgesics. Keep the auditory canal dry, and change the dressing when necessary.

Acute mastoiditis with abscess

This condition is usually a complication of acute otitis media.

The patient, usually a child, complains of fever and of pain in the affected ear, with disturbed hearing. There may be a discharge from the ear. Characteristically

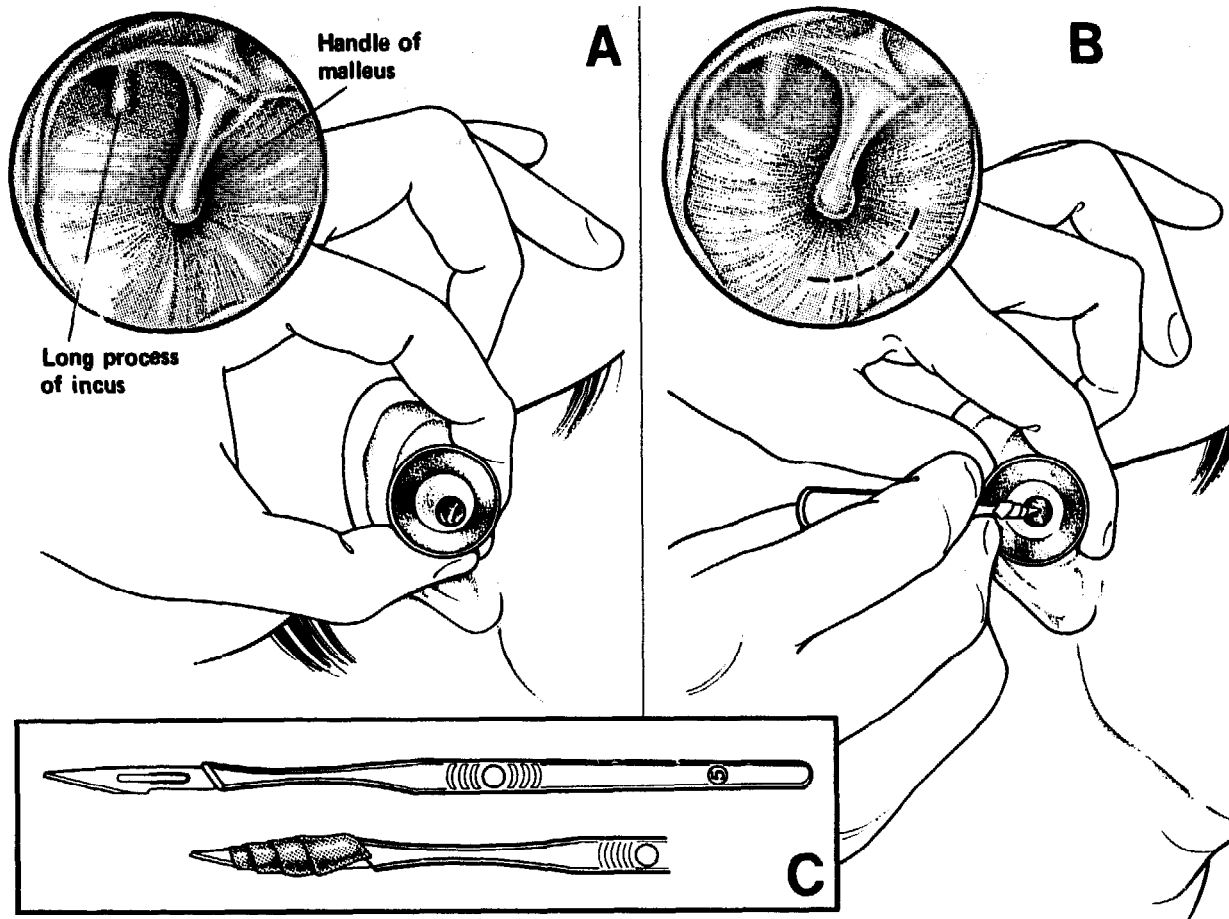


Fig. 5.2. Myringotomy. The tympanic membrane as seen through an auriscope (A); incising the membrane (B) using a scalpel with a partially covered blade (C).

there is a tender swelling in the mastoid area, which pushes the pinna forward and out.

Treatment

Although the ideal treatment is exposure of the mastoid air cells, this operation is usually beyond the scope of the doctor at the district hospital, who should treat the patient only to relieve immediate pain and tension by simple incision and drainage of the abscess down to the periosteum. The patient should then be referred.

Assessment and preoperative management

Measure the patient's haemoglobin level and test the urine for sugar and protein. A radiograph of the mastoid bones (both sides to allow for comparison) will show clouding of the affected bone. If there is a discharge from the ear, take a sample for bacteriological examination. Treat the patient with analgesics and antibiotics.

Drainage of mastoid abscess

Equipment

See tray for *Incision and drainage of abscess*, Annex 1.

Technique A general or local anaesthetic should be given, in addition to basal sedation. Make a curved incision over the most fluctuant part of the abscess or, if this is not obvious, at about 1.5 cm behind the pinna. Deepen the incision to the periosteum or until pus is found. Take a sample of pus for bacteriological examination and establish free drainage. Apply petrolatum gauze or a small, corrugated drain, and dress the area with gauze.

After-care Continue the administration of antibiotics and analgesics, and change dressings as necessary. Remove the drain after 24–48 hours.

6

Nose

Control of epistaxis

Epistaxis (nosebleed) often occurs from the plexus of veins in the anterior part of the nasal septum (Fig. 6.1A). In children it is commonly due to nose-picking. Other causes include trauma, the presence of a foreign body, Burkitt's lymphoma, and nasopharyngeal carcinoma.

Equipment See tray for *Control of epistaxis*, Annex 1.

Technique With the patient in a sitting position, administer a mild sedative. Remove any blood clots from the nose and throat. Pinch the nose between fingers and thumb or with a clothes-peg, while applying ice-packs to the nose and forehead. This usually stops the bleeding within 10 min. Should bleeding continue, pack the nose with cotton wool, soaked in ice-cold water and wrung out, and repeat the above procedure.

Rarely bleeding may continue even after this treatment. If this happens, apply pressure to the nasopharynx either by packing it with gauze ribbon or, more effectively, by inserting a Foley balloon catheter. If you decide on the latter method, lubricate the catheter, and pass it through the nose until its tip reaches the oropharynx. Withdraw it a short distance to bring the balloon into the nasopharynx. Inflate the balloon with water, just enough to exert an even pressure but not to cause discomfort (5–10 ml of water is usually adequate for an adult, but use no more than 5 ml for a child). Gently pull the catheter forward until the balloon is held in the posterior choana (Fig. 6.1B). The balloon should flatten slightly as this is done. The catheter can then be secured to the forehead or cheek in the same manner as a nasogastric tube. It can be removed after 48 hours.

Removal of foreign bodies

Children often insert foreign bodies into the nose. Visualize the foreign body, determine its nature, and ascertain its position before making any attempt to remove it.

Equipment See tray for *Removal of nasal foreign body*, Annex 1.

Technique First sedate the patient and then proceed gently. The best method of removing a foreign body depends upon its nature. To remove a foreign body with rough

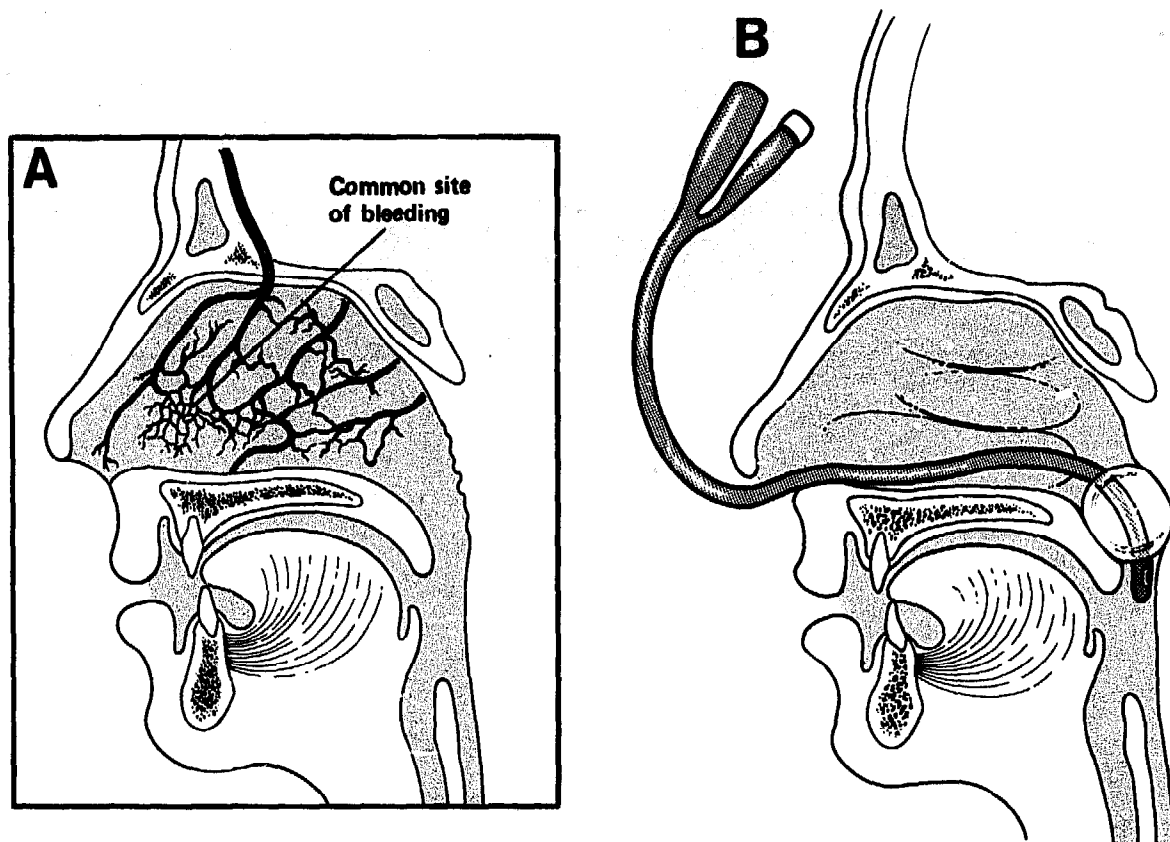


Fig. 6.1. Epistaxis. A common site of bleeding (A); controlling the bleeding with a Foley catheter (B).

surfaces, use angled forceps, or pass a hook beyond the foreign body, rotate the hook, and then draw out the object in front of the hook. Other types of foreign body can be withdrawn by suction, through a soft rubber tube introduced into the nose to rest against the object.

7

Teeth and jaws

Extraction of teeth

Extraction is the best way to drain an apical abscess when there are no facilities for treatment of the root canal. Otherwise, a tooth should be removed only if it cannot be preserved, if it is loose and tender, or if it causes uncontrollable pain.

Immediate first-aid treatment for dental pain can be afforded by cleaning the painful socket or cavity and applying oil of cloves; pack a painful socket with cotton wool soaked in oil of cloves and a tooth cavity with a paste of oil of cloves and zinc oxide.

Assessment and preoperative management

Identify the offending tooth. Take appropriate precautions if the patient is suffering from any other medical conditions such as valvular disease of the heart (which would require prophylactic antibiotic cover), bleeding disorders, or diabetes. It may be helpful to obtain a radiograph of the jaw. Check the patient's haemoglobin level and test the urine for sugar.

Explain the procedure to the patient and obtain permission to remove the tooth.

Equipment

See tray for *Extraction of teeth*, Annex 1.

Dental forceps are designed to fit the shape of the teeth including their roots; accordingly, forceps come in sets of six appropriate shapes, but the inexperienced operator will find it simpler to rely on one pair of universal forceps for the upper jaw and one for the lower (Fig. 7.1A–D). Remember that the upper molars have three roots, two buccal and one palatal, whereas the lower molars have two, one mesial and one distal. The upper first premolars have two roots side by side, one buccal and one palatal. All the other teeth are single-rooted.

Technique

Local infiltration analgesia should usually be sufficient for extraction of all but the lower molars, which may require a mandibular nerve block. Occasionally general anaesthesia may be appropriate.

Administer a sedative to children and anxious adults. Seat the patient in a chair with a back high enough to support the head. After the patient has rinsed the mouth, swab the gum with 70% ethanol. To effect local infiltration anaesthesia, insert a 25-gauge, 25 mm needle at the junction of the mucoperiosteum of the gum and the cheek, parallel to the axis of the tooth (Fig. 7.1E). Advance the needle 0.5 to 1 cm, level with the apex of the tooth, just above the periosteum.

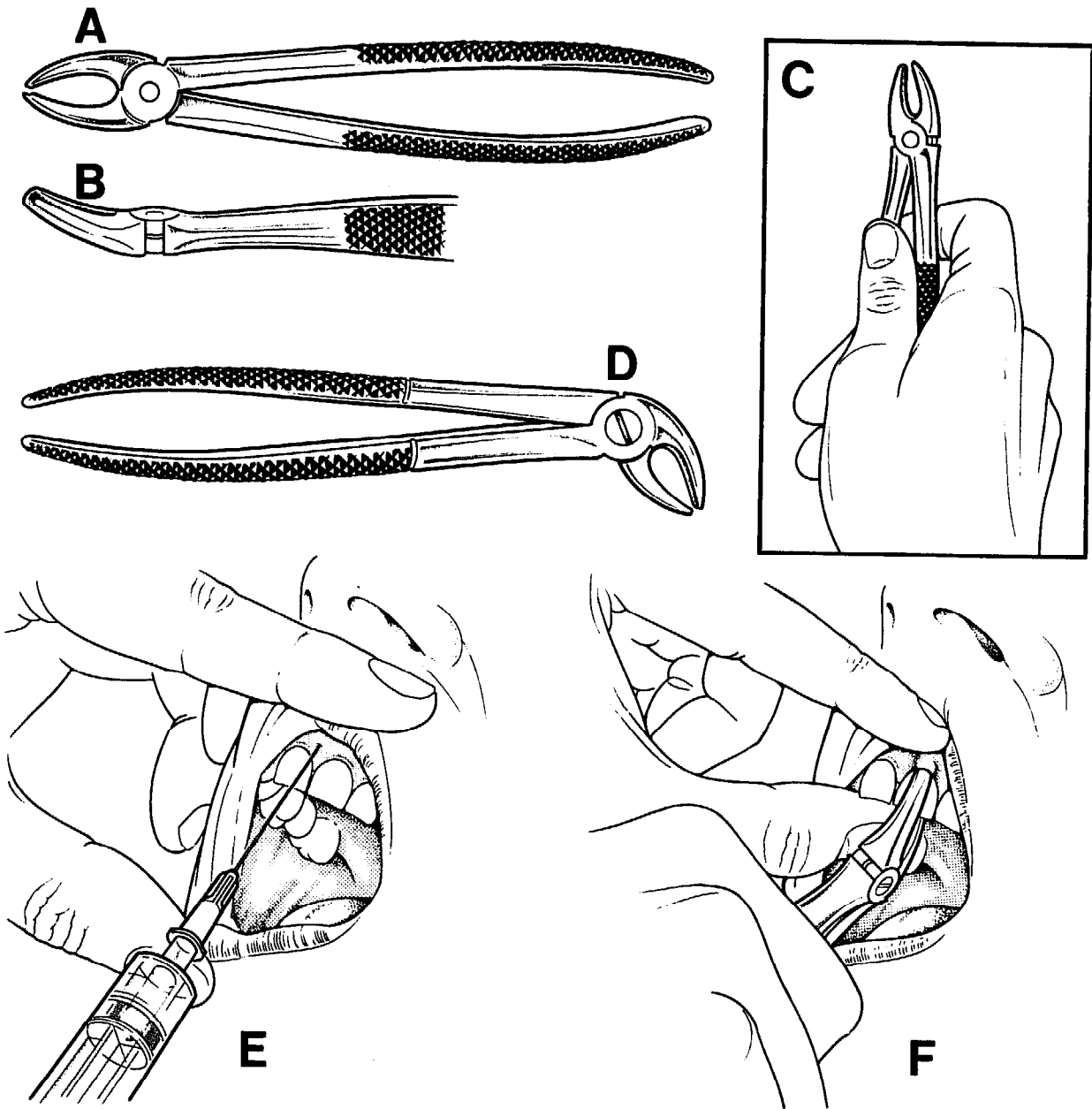


Fig. 7.1. Extraction of teeth. Upper universal forceps from above (A), from the side (B), and as held in the hand (C); lower universal forceps (D); injecting local anesthetic (E); extraction (F).

The bevel of the needle should face the tooth. Infiltrate the tissues with 1 ml of lidocaine and epinephrine and repeat the procedure on the other side of the tooth. Wait at least 5 min and confirm the onset of numbness before handling the tooth.

If you are right-handed, stand behind and to the right of the patient when extracting lower right molar or premolar teeth. Face the patient, to the patient's right, when working on all other teeth. Separate the gum from the tooth with a straight elevator. While supporting the alveolus with the thumb and finger of your other hand, apply the forceps to either side of the crown, parallel with the long axis of the root. Position the palatal or lingual blade first. Push the blades of

the forceps up or down the periodontal membrane on either side of the tooth, depending on which jaw you are working on (Fig. 7.1F). The secret of successful extraction is to drive the blades of the forceps as far up or down the periodontal membrane as possible.

Firmly grip the root of the tooth with the forceps and loosen the tooth with gentle rocking movements from buccal to lingual or palatal side. If the tooth does not begin to move, loosen the forceps, push them deeper, and repeat the rocking movements. Avoid excessive lateral force on a tooth, as this can lead to its fracture.

Carefully inspect the extracted tooth to confirm its complete removal. A broken root is best removed by loosening the tissue between the root and the bone with a curved elevator. After the tooth has been completely removed, squeeze the sides of the socket together for a minute or two and place a dental roll over the socket. Instruct the patient to bite on it for a short while.

After the patient has rinsed the mouth, inspect the cavity for bleeding. Repair lacerations and arrest profuse bleeding that will not stop, even when pressure is applied, with mattress sutures of 0 catgut across the cavity. Warn the patient not to rinse the mouth again for the first 24 hours or the blood clot may be washed out, leaving a dry socket (with the risk of alveolar osteitis). The patient should rinse the mouth frequently with saline during the next few days.

A simple analgesic may be needed when the effects of the local anaesthetic have worn off. It is worth warning the patient against exploring the cavity with a finger, explaining that the numbness is temporary and will last only for an hour or so. Haemorrhage after dental extraction is a common emergency and can usually be controlled by simple pressure over the socket or, if necessary, by suturing the gum. Haemostatic substances have little advantage over simple pressure. If gross dental sepsis occurs, administer penicillin for 48 hours and consider giving tetanus toxoid, if necessary.

The barrel bandage

The barrel bandage (vertical jaw-bandage) is a useful, temporary support for the fractured mandible and can also serve to maintain pressure on a bleeding tooth socket. Take a length (about 150 cm) of a bandage 7.5 cm wide made of a non-elastic material such as cotton. Find the middle of the bandage length and place it under the patient's chin. Bring the ends to the top of the head and tie them, making the first loop of a reef knot (Fig. 7.2A). Loosen and separate the loop, placing one half over the forehead and the other half behind the occiput (Fig. 7.2B). Take the ends from just in front of the ears up to the top of the head, and tie them securely with a reef knot (Fig. 7.2C,D).

Fractures of the jaw

Fractures of the maxilla require specialist care, but mandibular fractures can often be treated in the district hospital. Fractures of the ramus and the condyle of the mandible are usually closed and require little reduction. Fractures of the body of the mandible are usually compound, through the alveolar margin, and necessitate immobilization, which can be achieved by direct wiring between the teeth on either side of the fracture or by interdental wiring between the two jaws (providing that the upper jaw is stable).

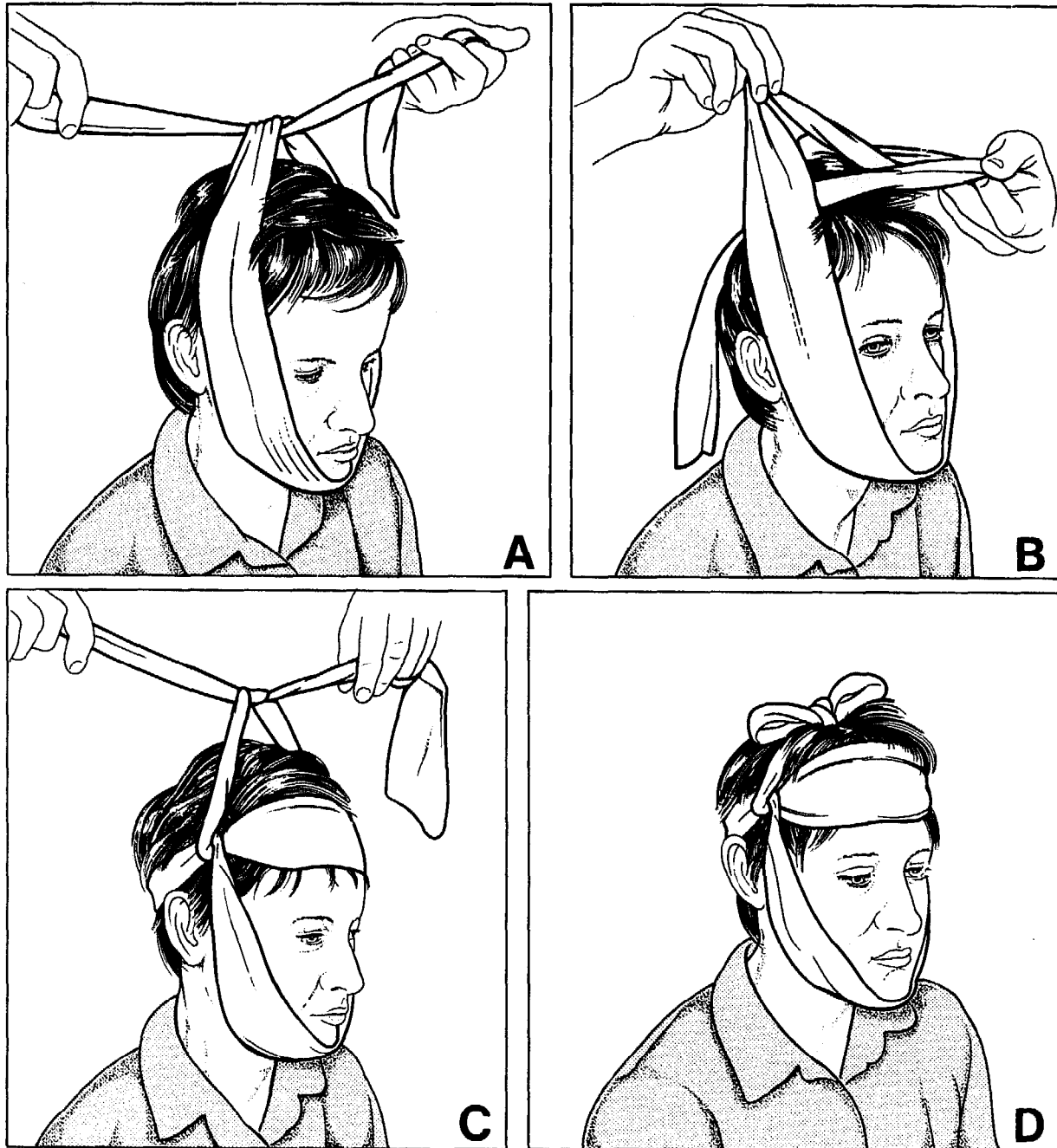


Fig. 7.2. Application of a barrel bandage.

Diagnosis and treatment

If the patient presents with a suspected mandibular fracture, note any altered dental occlusion and, if necessary, confirm the fracture by X-ray examination. Check for other injuries, and decide on the priorities for treatment. Keeping the airway clear is most important; the patient should therefore be nursed lying on the side or in a sitting position with the head well forward. Give penicillin and tetanus toxoid.

With the maintenance of a clear airway and the administration of antibiotics, the patient's condition can be expected to improve considerably in the first 24 hours.

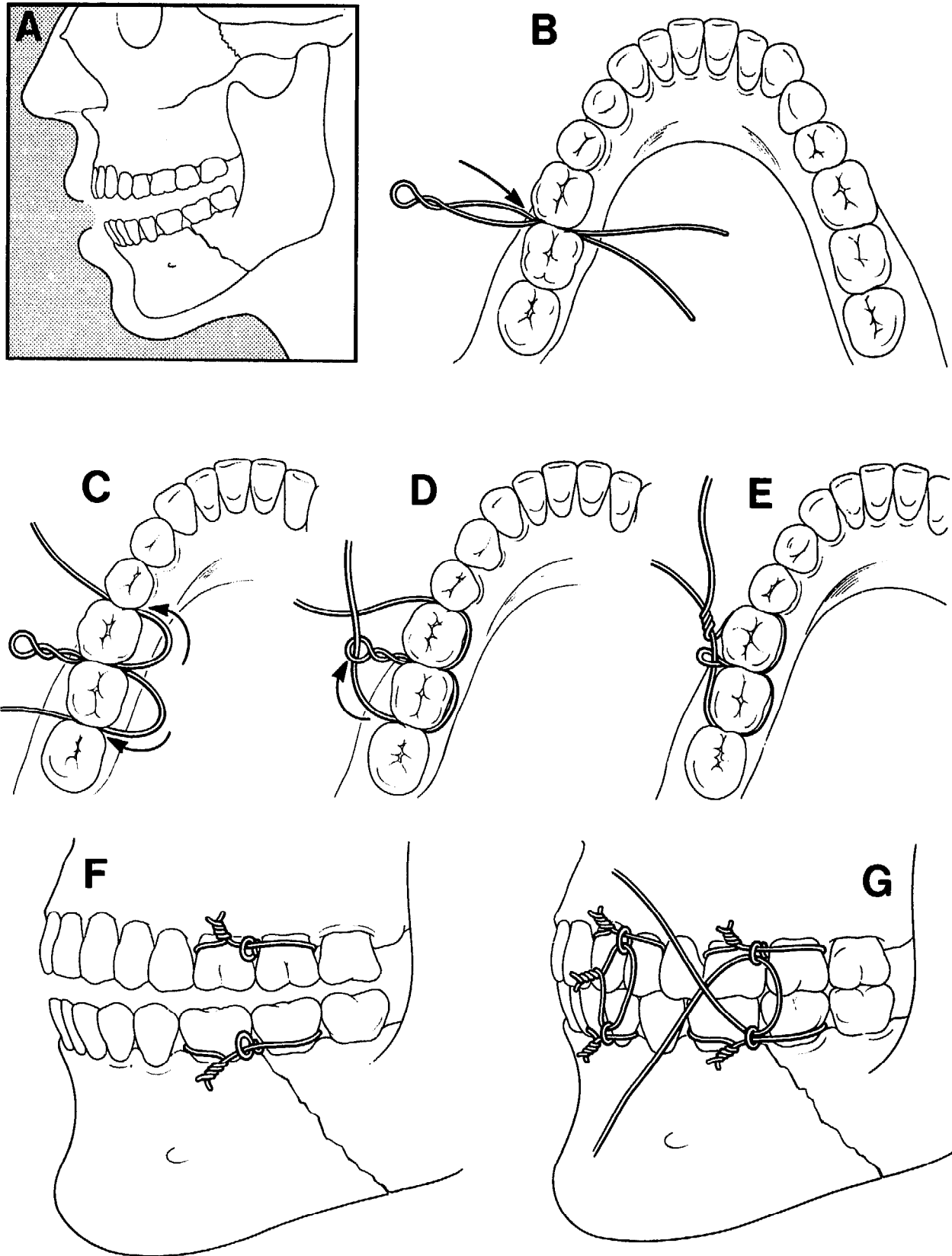


Fig. 7.3. Treatment of mandibular fracture by interdigital wiring. The fracture line across the mandible (A); inserting the looped wire between the healthy teeth on either side of the fracture (B); bringing the ends of the wire back around the teeth (C), inserting one end through the loop (D), and twisting the ends together (E); the procedure is repeated on the upper jaw (F); the jaws are then wired together, additional teeth having been wired together if necessary (G).

The only urgent indication for wiring a mandibular fracture is instability of a comminuted fracture through the incisors. In this instance, the tongue may need to be held forward temporarily by a stitch through its tip and the teeth wired immediately. Otherwise wiring can be delayed until the patient's condition is stable.

Interdental wiring of the jaws

Equipment See tray for *Interdental wiring*, Annex 1.

Technique After sedating the patient, you may gently insert interdental eyelets without anaesthesia, but nerve block (of the inferior alveolar nerve) and infiltration anaesthesia are much preferred. General anaesthesia is an alternative but, should the patient present with an airway that is difficult to manage or with a full stomach, it will be extremely hazardous if the anaesthetist is inexperienced.

Clean the patient's mouth. Examine the jaws for any obvious wounds, which should be sutured. Locate the fracture (Fig. 7.3A) and reduce it as far as possible. If there is any doubt about the viability of a tooth in the fracture line, remove it. The method of wiring the jaw will depend on the state of the remaining teeth. Choose the nearest two healthy teeth, one on each side of the fracture line, and pass a 16 cm length of wire (twisted to make an eyelet on the buccal side) between them from the buccal to the lingual side (Fig. 7.3B). Pass the ends back to surround the teeth, carrying one end through the eyelet and then tightening it by twisting it against its fellow (Fig. 7.3C–E). Cut the excess wire short and bend it away from the lip to lie flush along the jaw. Repeat the procedure on a matching pair of teeth in the upper jaw (Fig. 7.3F). Fix the mandible to the maxilla by wiring the upper and lower eyelets together immediately or, if there are any worries about the patient's airway at the end of anaesthesia, at a later session (Fig. 7.3G). Additional teeth may be wired together if necessary.

After-care The jaw should be kept immobilized until the fracture unites: 6 weeks for an adult but only 3–4 weeks for a child. During this time, the patient should continue to brush the teeth regularly, except perhaps for the first few days when the mouth can be gently syringed. The patient's diet must, of course, be fluid or semi-solid.

8

Throat

Non-emergency operations on the throat (in particular tonsillectomy) should not be attempted at the district hospital.

Incision and drainage of peritonsillar abscess

Peritonsillar abscess (quinsy) is a complication of acute tonsillitis. The patient develops a rapidly progressing pain in the throat which radiates to the ear of the same side and soon becomes unbearable. The neck is held rigid, and there is associated fever, dysarthria, dysphagia, drooling of saliva, trismus, and foul breath. Clinical examination will confirm fever and will usually reveal cervical lymphadenopathy on the side of the lesion. Local swelling causes the anterior tonsillar pillar to bulge and displaces the soft palate and uvula towards the opposite side. The overlying mucosa is inflamed, sometimes with a small spot already discharging pus. Keep in mind the possibility of diphtheria or glandular fever.

Assessment and preoperative management

Measure the patient's haemoglobin level and test the urine for sugar and protein. Administer antibiotics and analgesics.

Equipment

See tray for *Incision and drainage of peritonsillar/retropharyngeal abscess*, Annex 1.

Technique

Administer a basal sedative and place the patient in a sitting position with the head supported. Surface anaesthesia is preferable and will avoid the risk of inhalation of the abscess contents, which can occur under general anaesthesia. Spray the region of the abscess with 2–4% lidocaine. *Never* use ethyl chloride for this purpose, as the amount absorbed by the patient cannot be properly monitored.

Keep the tongue out of the way with a large tongue depressor or ask an assistant to hold it out between a gauze-covered finger and thumb as you proceed. Perform a preliminary needle aspiration (Fig. 8.1A), and then incise the most prominent part of the swelling near the anterior pillar (Fig. 8.1B). Introduce the point of a pair of artery forceps or sinus forceps into the incision, and open the jaws of the forceps to improve drainage (Fig. 8.1C). Provide suction, if necessary.

After-care

Instruct the patient to gargle with warm salt water several times a day for about 5 days. Continue the administration of antibiotics for 7–10 days and analgesics for as long as necessary.

Incision and drainage of retropharyngeal abscess

This abscess occurs mainly in children, with tuberculosis as the underlying disease. It is usually a complication resulting from infection of the adenoids or

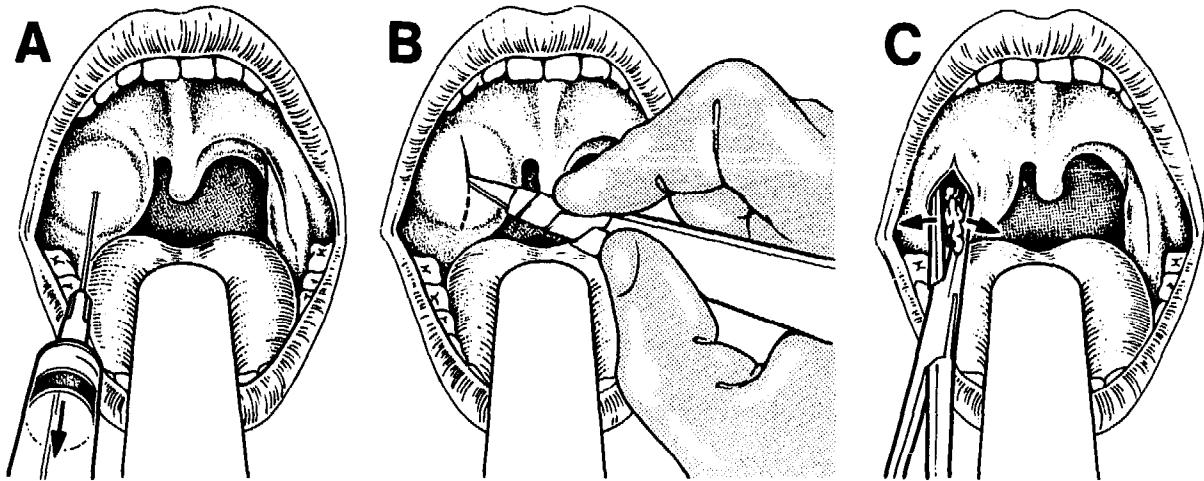


Fig. 8.1. Incision and drainage of peritonsillar abscess. Preliminary aspiration (A); incision (B); drainage (C).

the nasopharynx. The child refuses nourishment, has a changed voice and cry, is generally irritable, and suffers from croup and fever. The neck is held rigid and breathing is noisy. In the early stages of the abscess, physical examination of the pharynx may detect no abnormality but, as the condition progresses, a swelling appears in the back of the pharynx.

Assessment and preoperative management

A lateral radiograph of the soft tissue will reveal a widening of the retropharyngeal space. X-ray the chest and the cervical spine to check for tuberculosis. Measure the patient's haemoglobin level and test the urine for sugar and protein. It is also useful to obtain white-cell and differential white-cell counts, determine the erythrocyte sedimentation rate, and test the skin reaction to tuberculin (Mantoux test).

Administer antibiotics and analgesics. A patient suffering from tuberculosis will require further treatment.

Equipment

See tray for *Incision and drainage of peritonsillar/retropharyngeal abscess*, Annex 1.

Technique

Administer a basal sedative with the patient lying down and the head of the table lowered. Spray the back of the throat with local anaesthetic and instruct an assistant to steady the patient's head. Keep the tongue out of the way with a depressor.

A strictly midline swelling is more likely to be tuberculous and should be aspirated, not incised. If the swelling is elsewhere, incise the summit of the bulge vertically. Introduce the tip of pair of sinus or artery forceps and open the jaws of the forceps to facilitate drainage. Provide suction. Take a specimen of pus for bacteriological tests, including culture for *Mycobacterium tuberculosis*.

After-care

Instruct the patient to gargle regularly with warm salt water. Continue the administration of antibiotics and analgesics.

Incision and drainage of acute abscess of the neck

Some abscesses in the neck are deeply situated or arise from lymph nodes, and require a careful and possibly extensive surgical dissection with the patient under

general anaesthesia. However, because the neck is a complex and important anatomical region, surgical intervention at the district hospital is not recommended, unless the abscess is acute and clearly pointing, when the surgical procedure is limited to simple incision and drainage. In children, an abscess of the neck should be treated by repeated aspiration before it points.

Assessment and preoperative management

Once the diagnosis has been confirmed by aspiration, carefully examine the patient's mouth and throat, particularly the tonsils, to exclude a primary focus.

Measure the patient's haemoglobin level, test the urine for sugar and protein, and obtain a white-cell and differential white-cell count. If tuberculosis is suspected, especially in children, obtain a chest radiograph and test the skin reaction to tuberculin (Mantoux test).

Equipment

See tray for *Incision and drainage of abscess*, Annex 1.

Technique

A small, superficial abscess may be evacuated by aspiration using a syringe with a wide-bore needle.

Large abscesses of the neck require incision and drainage under general anaesthesia. Place the incision in a crease, centred over the most prominent or fluctuant part of the abscess. Spread the wound edges with a pair of sinus or artery forceps to facilitate drainage. Take a sample of pus for bacteriological tests, including an examination for tuberculosis. Remove any necrotic tissue, but avoid undue probing or dissection. Insert a soft corrugated drain and a few stitches to bring the wound edges loosely together around it. The drain may be removed in 24–48 hours. Hold dressings of gauze swabs in place with adhesive tape.

After-care

Ensure that the patient gargles regularly with salt water, and provide analgesics, as necessary. Should a discharge from the wound persist (as evidenced by sinus formation), refer the patient.

**CHEST, ABDOMEN,
AND GASTROINTESTINAL TRACT**

9

Chest

Tracheostomy

The indications for tracheostomy at the district hospital are acute obstruction of the airway, anticipated difficulty in managing the airway, and the need to transport an unconscious patient.

Equipment See tray for *Tracheostomy*, Annex 1.

Technique Place the patient supine on a table or bed. Extend the neck by placing a sandbag (or a rolled towel for infants and children) under the shoulders (Fig. 9.1A). Prepare the skin with antiseptic, and infiltrate local anaesthetic into the skin from the suprasternal notch along the midline to the thyroid cartilage (Fig. 9.1B). Palpate the cricoid cartilage to ascertain its position (Fig. 9.1C), and make a midline incision between its inferior border and the superior margin of the suprasternal notch (Fig. 9.1D,E). Separate the strap muscles from the midline by blunt dissection (Fig. 9.1F) to expose the trachea with the thyroid isthmus lying anterior to it. Retract the isthmus either upwards or downwards, or divide it between artery forceps and ligate the ends (Fig. 9.1G,H). Divide and retract the pretracheal fascia (Fig. 9.1I) to expose the second and third tracheal cartilages. Then lift and steady the trachea with small skin-hook retractors.

In infants and children, make a transverse intercartilaginous incision between the second and third rings (Fig. 9.1J). Avoid excising a piece of the trachea. (The incision will open further as you extend the neck over the rolled towel.)

In adults, excise a small, rounded segment of the trachea (Fig. 9.1K). The size of the resulting hole should conform to that of the tracheostomy tube.

Aspirate secretions from the trachea at this stage (Fig. 9.1L), and again after insertion of the tube.

Insert the tracheostomy tube set, remove the obturator, and loosely stitch the skin with interrupted 2/0 thread (Fig. 9.1M,N). In children, remove the rolled towel from under the shoulders before stitching the skin. A linen tape can be passed behind the neck to join the wings of the tube and hold it in place (Fig. 9.1O). Dress the wound with a single layer of gauze swab.

When placing the tracheostomy tube in the trachea, ensure that it enters the lumen accurately and completely. Assess and confirm the patency of the inserted tracheostomy tube using the bell attachment of a stethoscope. If there is a normal flow of air through the tube, a loud blast will be heard with each expiration. With incomplete obstruction, the noise will be softer and shorter, accompanied by a wheeze or whistle. If the tube has been placed pretracheally or if it is completely blocked with secretions, no sound will be heard. Remove and replace the tube if there is any doubt about its position or patency.

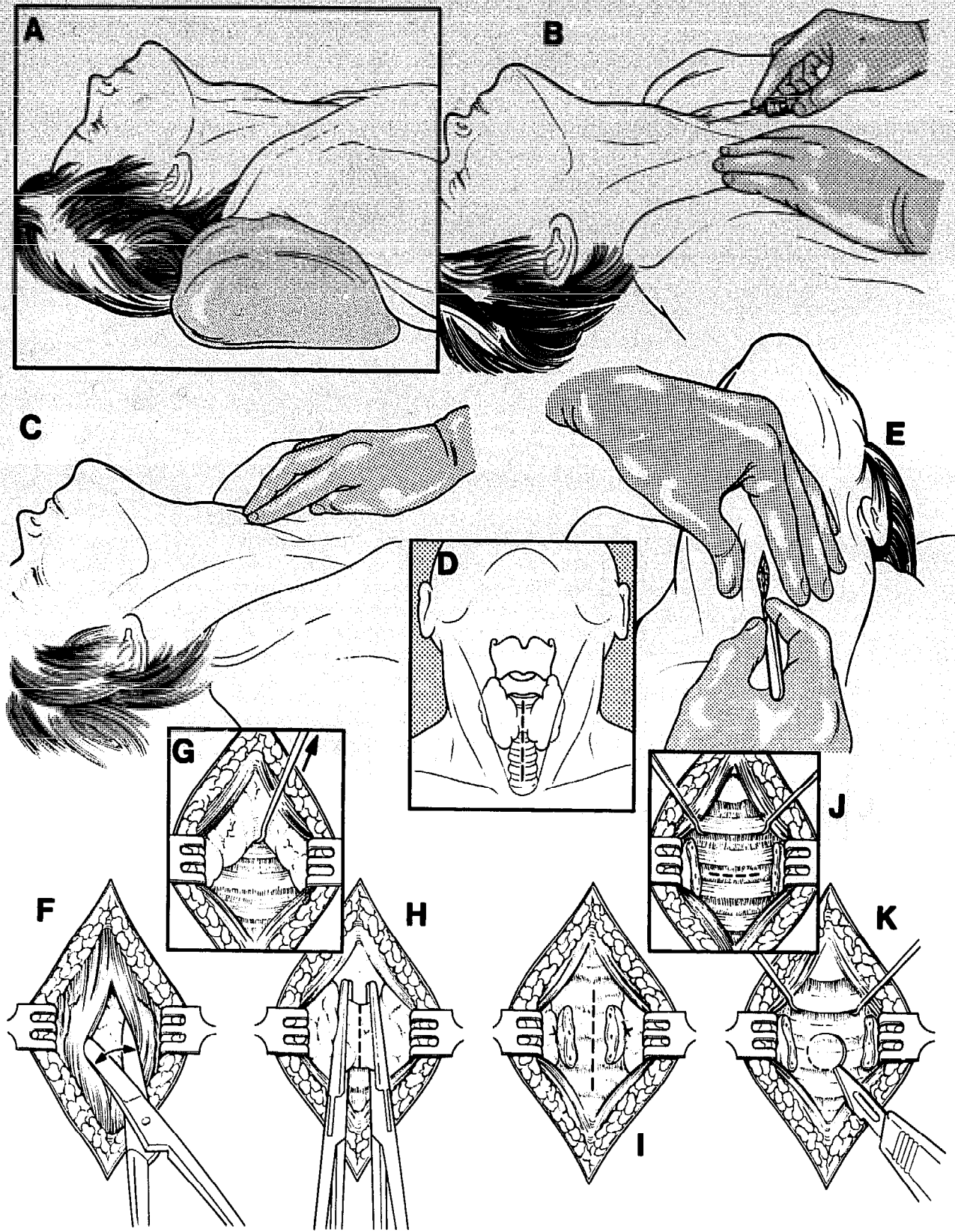


Fig. 9.1. Tracheostomy. Position of the patient with the neck extended (A); infiltrating the skin with local anaesthetic (B); palpating the cricoid cartilage (C); site of incision (D) and making the incision (E); separating the strap muscles by blunt dissection (F); retracting or dividing the thyroid isthmus between clamps (G, H); site of division of the pretracheal fascia (I); site of intercartilaginous incision in children (J); excising a small rounded segment of the trachea in adults (K).

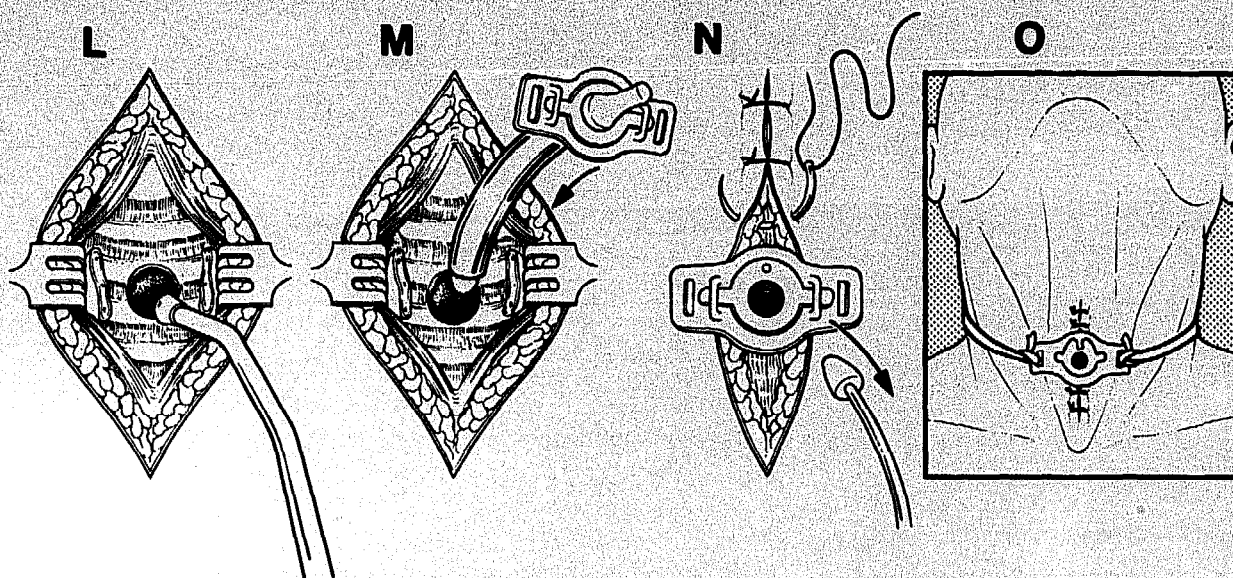


Fig. 9.1. Tracheostomy (continued). Aspirating secretions (L); inserting the tube (M); removing the obturator and suturing the skin (N); fixing the tube (O).

After-care

Aspirate secretions from the tracheobronchial tree regularly using a sterile catheter passed down through the tracheostomy tube. Avoid irritating the bronchi, which could stimulate coughing. The air around the patient should be kept warm and humid by means of a humidifier. When necessary, instil small amounts of sterile physiological saline into the bronchi to soften the mucus. Change the inner tracheostomy tube at regular intervals. Should the outer tube be dislodged, reinsert it immediately and check its position by both clinical examination and chest radiography. Always have a spare tube available.

Refer the patient for further treatment if indicated.

Complications

Complications include early postoperative bleeding, infection, surgical emphysema, atelectasis, and crust formation. Stenosis of the trachea is a possible late complication.

Underwater-seal chest drainage

Indications for underwater-seal chest drainage at the district hospital are pneumothorax, haemothorax, haemopneumothorax, and acute empyema.

Equipment

See tray for *Underwater-seal chest drainage*, Annex 1.

Before beginning the procedure, check the equipment to confirm that each piece fits properly into the next.

Technique

Prepare the skin with antiseptic and infiltrate the skin, muscle, and pleura with 1% lidocaine at the appropriate intercostal space, usually the fifth or sixth, in the midaxillary line (Fig. 9.2A,B). Note the length of needle needed to enter the

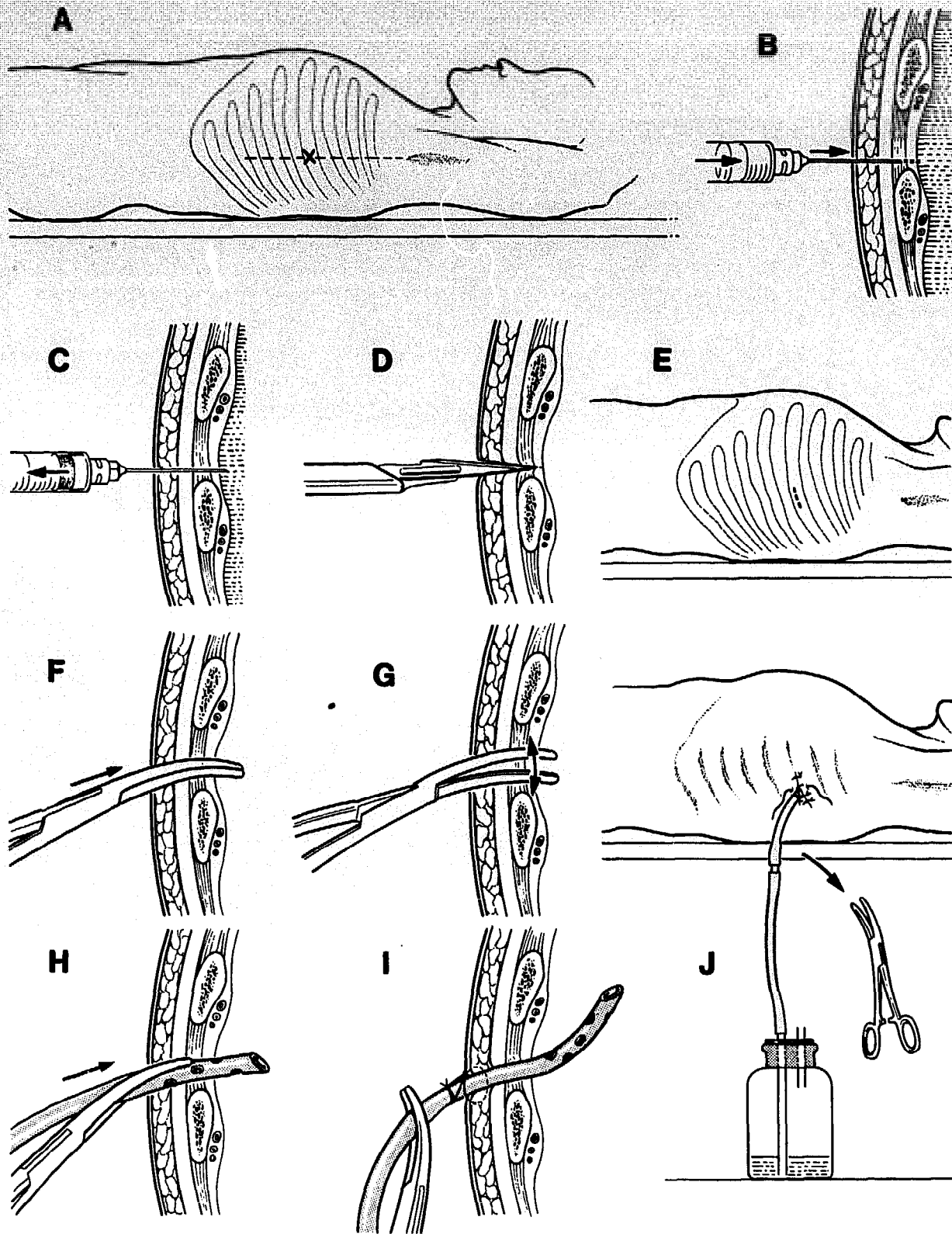


Fig. 9.2. Underwater-seal chest drainage. Site for insertion of the tube (A); infiltrating all layers of the chest wall at the proposed site with local anaesthetic (B); aspirating fluid from the pleural cavity (C); making a small incision (D, E); enlarging the incision and penetrating the pleural space with forceps (F, G); introducing and fixing the tube (H, I); underwater-seal drainage bottle connected (J, note the untied stitch).

pleural cavity; this information may be useful later when you are inserting the drain. Aspirate fluid from the chest cavity to confirm your diagnosis (Fig. 9.2C). Make a small transverse incision just above the rib, to avoid damaging the vessels under the lower part of the rib (Fig. 9.2D,E). In children, it is advisable to keep strictly to the middle of the intercostal space.

Using a pair of large, curved artery forceps, penetrate the pleura and enlarge the opening (Fig. 9.2F,G); employ the same forceps to grasp the tube at its tip and introduce it into the chest (Fig. 9.2H,I). Close the incision with interrupted skin sutures, using one stitch to anchor the tube. Leave an additional suture untied adjacent to the tube for closing the wound after the tube is removed. Apply a gauze dressing. Connect the tube to the underwater-seal drainage system, and mark the initial level of fluid in the drainage bottle (Fig. 9.2J).

After-care Place a pair of large artery forceps by the bedside for clamping the tube when changing the bottle. The drainage system is patent if the fluid level swings freely with changes in the intrapleural pressure. Persistent bubbling over several days suggests a bronchopleural fistula and is an indication for referral.

Change the connecting tube and the bottle at least once every 48 hours, replacing them with sterile equivalents. Wash and disinfect the used equipment to remove all residue before it is resterilized.

If there is no drainage for 12 hours, despite your "milking" the tube, clamp the tube for a further 6 hours and X-ray the chest. If the lung is satisfactorily expanded, the clamped tube can then be removed.

To remove the tube, first sedate the patient and then remove the dressing. Clean the skin with antiseptic. Hold the edges of the wound together with fingers and thumb over gauze while cutting the skin stitch that is anchoring the tube. Withdraw the tube rapidly as an assistant ties the previously loose stitch.

Simple rib fracture

Diagnosis The diagnosis of rib fracture is suggested by a history of trauma, followed by a localized, sharp chest pain that increases on breathing. Confirm the diagnosis by physical examination and chest radiography, which will also provide information on suspected intrathoracic injuries.

Treatment A simple rib fracture can be extremely painful. Administer analgesics first, but if pain persists, proceed with an intercostal nerve block. In cases of single rib fracture with no complications, strapping of the chest wall may help.

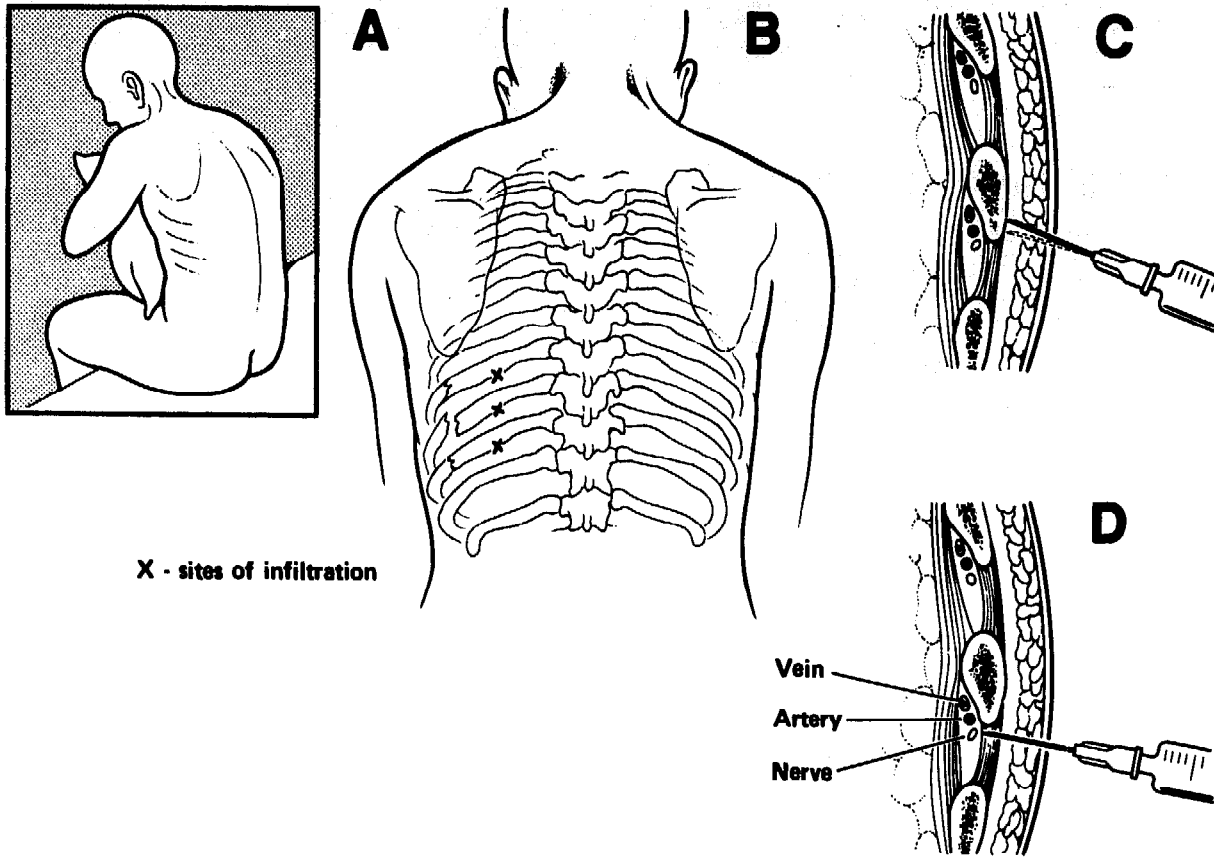
Intercostal nerve block

Equipment See tray for *Intercostal nerve block*, Annex 1.

Technique Administer a basal sedative.

Instruct the patient to sit up holding a pillow pinned between the chest and arms. Prepare the skin over the paravertebral area corresponding to the posterior end of the fractured rib and the two adjacent ribs.

Make a small skin wheal with 1% lidocaine with epinephrine (or 0.25% bupivacaine with or without epinephrine) at the inferior margin of the neck of the



X - sites of infiltration

Fig. 9.3. Intercostal nerve block for rib fracture. Position of the patient (A); sites of infiltration with local anaesthetic (B); "walking" the needle downwards until its tip slips below the edge of the rib (C, D).

fractured rib, about four finger-breadths from the rib's dorsal spinous processes (i.e., close to the angle). Advance the needle until it reaches the rib border and inject a small amount of local anaesthetic. Then "walk" the needle slowly downwards to allow it to slip below the edge of the rib (Fig. 9.3). Advance the needle a further 2-3 mm and inject 2.5 ml of local anaesthetic. Repeat the procedure on the two adjacent ribs.

After-care Repeat the block once or twice a day depending on the patient's response. Encourage the patient to cough and breathe deeply.

Complications Pneumothorax is a potential but rare complication.

Flail chest

Flail chest results from the isolation of a segment of the chest wall by the fracture of one or more ribs in at least two sites, which leaves the segment without support. In cases of bilateral fracture of the costochondral junctions, the flail segment is in the anterior part of the chest, involving the sternum.

The patient has "paradoxical" respiration on the injured side (the ribs moving inwards rather than outwards on inspiration), which reduces ventilation and gives rise to atelectasis and hypoxia. The severity of these problems is directly related to the size and degree of movement of the flail segment.

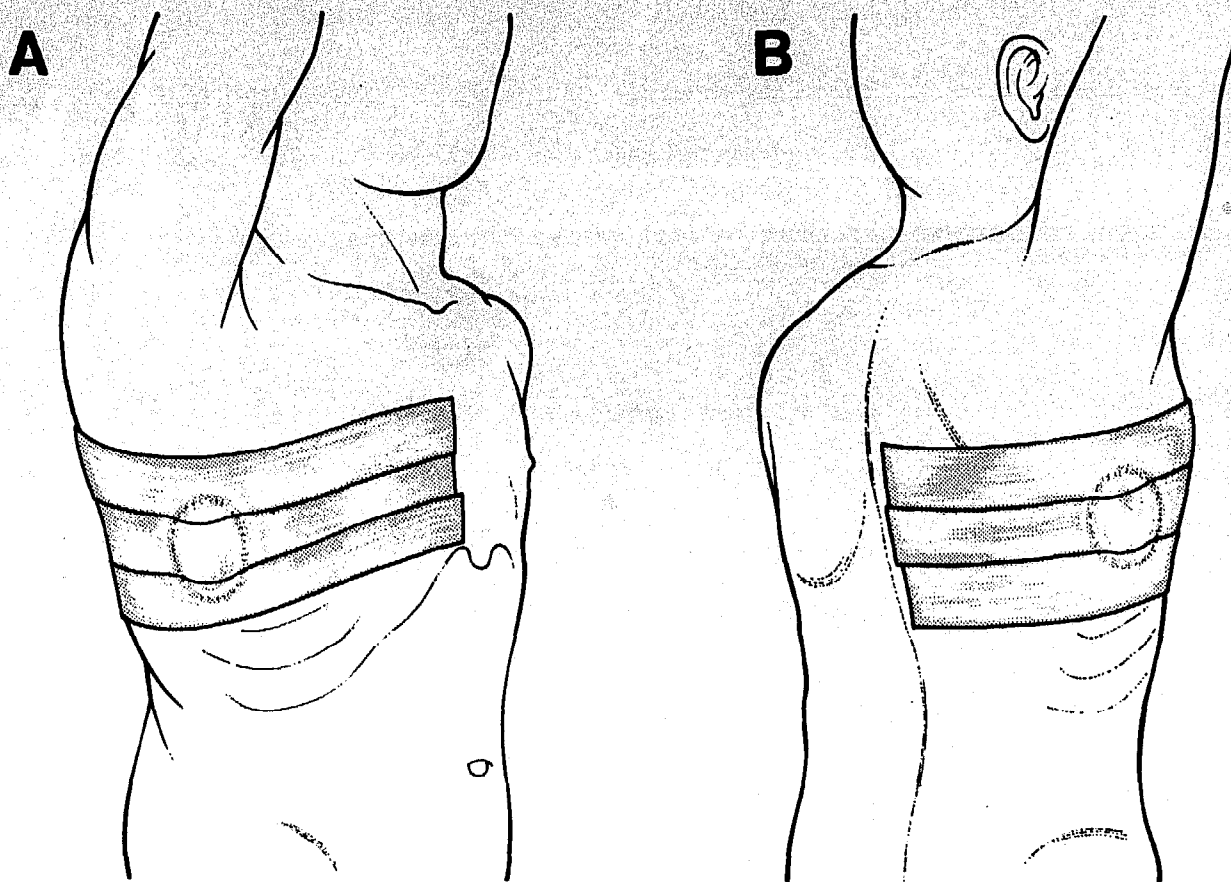


Fig. 9.4. Fixing a small flail segment of the chest with a pad secured by adhesive tape. The tape extends from the midline anteriorly (A) to the midline posteriorly (B).

The patient may have associated intrathoracic injuries, rendering the condition more serious. If severe and progressive respiratory failure results, the patient can be managed only by active resuscitation and referral.

Treatment

Fix a small flail segment by securing a piece of rolled gauze or a small pad of plaster of Paris over the segment with adhesive tape (Fig. 9.4).

For a patient with a large flail segment and a marked disturbance of ventilation, endotracheal intubation is an essential part of resuscitation before referral. In severe cases, intermittent positive pressure ventilation may be necessary, provided for example by a self-inflating bag. As an alternative to positive pressure ventilation, fix the flail segment by applying traction to a nylon suture passed around a rib in the affected segment or to a towel clip attached to a rib. Treat any haemopneumothorax with an underwater-seal intercostal drain.

In all cases, treat hypovolaemic shock if present, administer an intercostal nerve block and analgesics, and give an appropriate prophylactic antibiotic.

Pneumothorax

Pneumothorax is the presence of air in the pleural cavity. It may be "open" or "closed", depending on the presence or absence of a wound through the chest wall. A pneumothorax is classified according to its cause: traumatic, spontaneous, or iatrogenic.

The site of the leak may act as a valve, allowing air to enter, but not escape, causing "tension" pneumothorax. Tension pneumothorax and open (sucking) pneumothorax both require emergency surgical treatment.

Diagnosis The clinical features of pneumothorax are chest pain, which is often referred to the shoulder, restlessness or dyspnoea, and tympanitic sounds on percussion, with an absence of breath sounds. In tension pneumothorax the mediastinum shifts to the uninjured side of the chest, and the patient may suffer subcutaneous emphysema.

Most patients with open pneumothorax have associated haemothorax.

A chest radiograph is useful, but not immediately necessary.

Treatment If the patient has an open pneumothorax, act immediately to occlude the wound, using any available dressing, and then insert an underwater-seal intercostal drain. Treat the patient for hypovolaemic shock before débridement and suture of the wound.

Tension pneumothorax is best treated by underwater-seal chest drainage. However, in an emergency, a needle-puncture in the second intercostal space, anteriorly in the midclavicular line, will provide immediate relief. Subsequently insert an underwater-seal intercostal drain.

After-care Administer analgesics, prophylactic antibiotics, and tetanus prophylaxis, and prescribe breathing exercises for the patient.

Haemothorax

Haemothorax is the presence of blood in the pleural cavity. Usually the result of chest injury, it is commonly associated with pneumothorax, rib fracture, or other thoracic injuries. Bleeding occurs from the traumatized lung or, more often, from intercostal vessels.

Diagnosis The patient is usually restless and in pain, and may have marked dyspnoea. If much blood has been lost, the patient is pallid with a rapid pulse and low blood pressure. The area of the chest over the haemothorax is dull to percussion, and there is an absence of breath sounds. The trachea may have shifted to the opposite side of the chest.

A chest radiograph should confirm the presence of fluid in the pleural cavity. The radiograph may, however, be difficult to interpret, especially in the presence of severe or extensive lung contusion. In such cases, a diagnostic tap with a needle and syringe is valuable. Investigate other suspected injuries in order of priority.

Treatment Insert an underwater-seal intercostal drain. The chest tube should have several holes in its intrathoracic section, so that its tip can be pushed high up into the chest to allow blood (and any air) to escape. Observe the patient closely for signs of hypovolaemic shock.

After-care Maintain free drainage. Measure the amount of blood in the drainage bottle regularly. Continuing blood drainage beyond 500 ml in 24 hours or more than 100 ml/hour is an indication for referral. If the haemothorax is large, consider autotransfusion.

Administer analgesics, prophylactic antibiotics, and tetanus prophylaxis, and prescribe breathing exercises for the patient.

Acute empyema

Thoracic empyema is the presence of pus in the pleural cavity. It can complicate lung, mediastinal, or chest-wall infections and injuries. Rarely it may be due to the extension of a subphrenic or liver abscess. Many different organisms, often in combination, may be responsible for the infection. These include staphylococci, streptococci, coliform bacteria, tubercle mycobacteria, and even amoebae (from a liver abscess).

An empyema is either acute or chronic. It can invade adjacent tissues, the diaphragm, or the chest wall with discharge of pus. As a result, metastatic abscesses may occur in other organs.

Diagnosis

Obtain a chest radiograph and a white-cell count, measure the patient's haemoglobin level, and test the urine for sugar and protein.

Prompt diagnosis and treatment are essential for acute empyema. Its characteristic features are chest pain, fever, and an irritating, dry cough. The affected area is dull to percussion, with an absence of or markedly reduced breath sounds. A chest radiograph shows evidence of fluid in the pleural cavity. There may be additional features relating to the underlying disease. Perform a diagnostic needle aspiration, and take sample of pus for examination for the infecting organisms.

In the patient with chronic empyema, the above signs and symptoms are minimal or absent. Possible features are finger clubbing, mild chest discomfort or pain, and a cough. The patient is in poor general health, and may have several complications of chronic sepsis, including metastatic abscess and amyloidosis. The inflamed pleura is thickened and loculated. As it is not possible to drain the pleural cavity adequately by underwater-seal intercostal drainage (which is indicated for acute empyema), the patient should be referred.

Treatment

At the district hospital, treat only patients with acute empyema. Treat a small empyema by aspiration, repeated as necessary. Treat a moderate or large empyema by underwater-seal intercostal drainage.

After-care

Give antibiotics systemically; do not instil them into the pleural cavity. Administer analgesics and start the patient on breathing exercises. If there is evidence of loculation or failure of lung expansion, refer the patient.

Surgical emphysema and mediastinal injuries

Subcutaneous surgical emphysema is usually a complication of rib fracture when the lung has been punctured and a tension pneumothorax has developed, which forces air out through the fracture site into the subcutaneous and peribronchial tissues. The crepitation resulting on palpation of the affected tissues is both characteristic and diagnostic. A variable amount of swelling is usually present. Diagnosis is clinical, but chest radiographs can be useful in revealing associated chest lesions, such as rib fracture or pneumothorax. Evidence of gas in the soft tissues of the chest wall and at the root of the neck can also be seen in radiographs.

Subcutaneous emphysema usually resolves gradually after treatment of the underlying pneumothorax by underwater-seal chest drainage. Rarely the emphysema may be massive, involving the head and neck in addition to the chest wall, and associated with respiratory distress. If this occurs, insert an underwater-seal intercostal drain and make multiple deep subcutaneous incisions in the root of the neck in the region of the suprasternal notch to allow the air to escape.

Traumatic perforation of the trachea, the bronchus, or the oesophagus can lead to mediastinal emphysema, which usually extends to the neck. In such cases, perform a tracheostomy and make a collar incision in the root of the neck. If pneumothorax is also present, insert an underwater-seal intercostal tube. Refer all patients with mediastinal injuries.

Incision and drainage of breast abscess

In developing countries, breast abscesses are extremely common in women during breast-feeding. The causative organism, usually *Staphylococcus aureus*, gains entry through a cracked nipple. While *S. aureus* is almost always sensitive to penicillin in women who deliver at home or in small health institutions, it is often resistant in those who have given birth in larger institutions where antibiotics have been abused.

Assessment and preoperative management

The features of a breast abscess are painful, tender swelling of the affected breast and often fever. The skin of the area is shiny and tight. Many patients present with an advanced abscess in which the overlying skin has broken down and the pus is discharging. In the early stages the swelling is usually tense, and fluctuation is unusual. The most important consideration in differential diagnosis is inflammatory carcinoma of the breast. If you are in doubt about the diagnosis, perform a needle aspiration to confirm the presence of pus.

Measure the patient's haemoglobin level and test the urine for sugar and protein.

Equipment See tray for *Incision and drainage of abscess*, Annex 1.

Technique The patient should be given a general anaesthetic. Prepare the skin of the affected breast with antiseptic and drape the patient.

Make a radial incision over the most prominent or fluctuant part of the abscess (Fig. 9.5A). Introduce the tip of a pair of sinus or artery forceps or a pair of scissors to widen the opening and allow the pus to escape (Fig. 9.5B). Extend the incision if necessary. Take a specimen of pus for bacteriological tests, including examination for tuberculosis.

Introduce a finger into the cavity to break down all loculi, converting the lesion into a single, large cavity (Fig. 9.5C). Clean the cavity with gauze previously soaked in antiseptic. Insert a large corrugated drain through the wound (Fig. 9.5D), or through a counter-incision if necessary for dependent drainage (Fig. 9.5E). Apply an initial layer of petrolatum gauze, followed by several layers of gauze dressing. If much drainage is anticipated, cotton wool may be applied over the gauze dressing.

After-care If the patient has been breast-feeding an infant, she should continue this unless the child is of the age to be weaned. The child may feed from the affected breast, but if this is painful for the mother, she may gently express the milk from the breast instead. Give analgesics as required, but antibiotic treatment is usually unnecessary. Change dressings as necessary, and remove the drain within 48 hours.

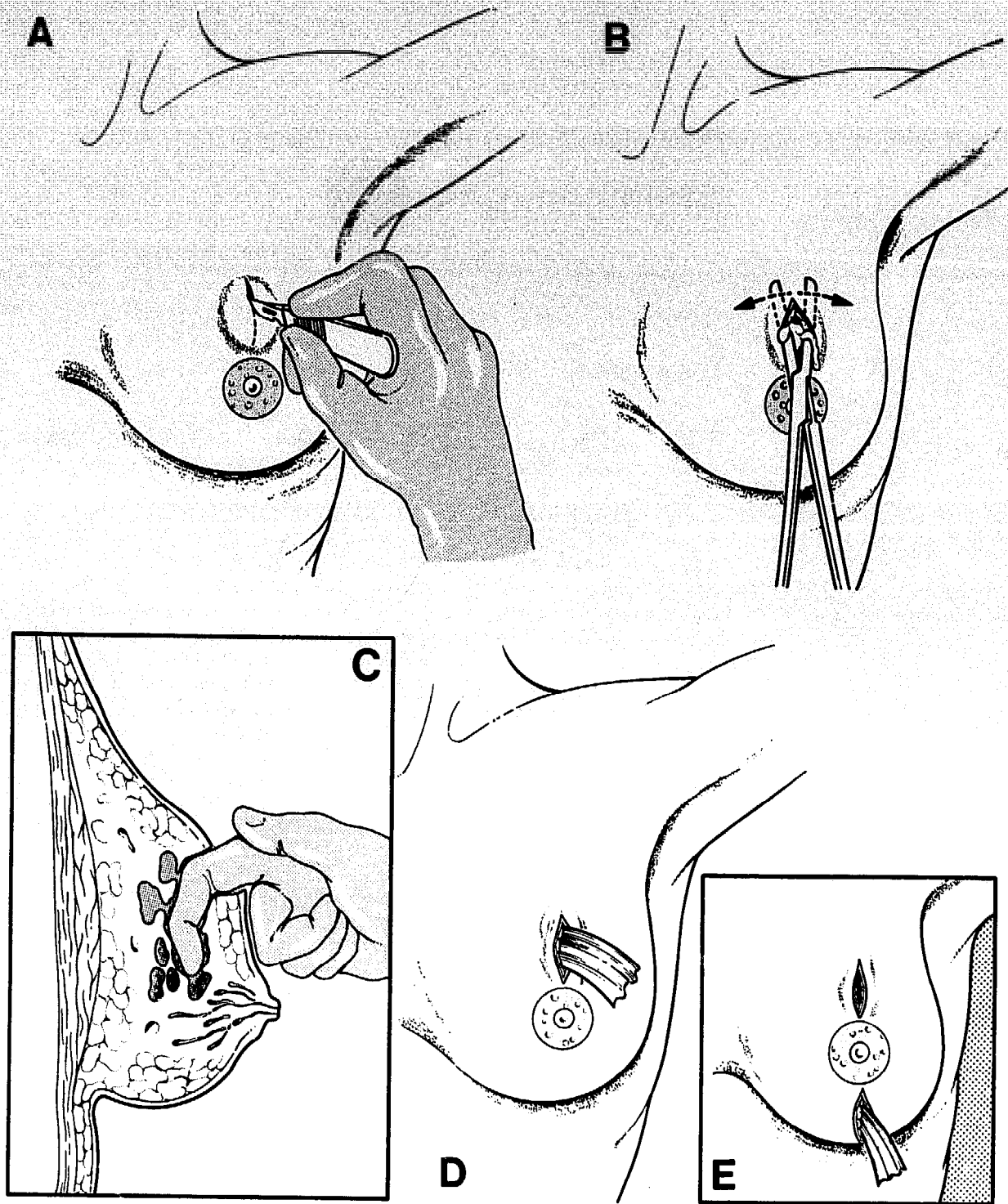


Fig. 9.5. Incision and drainage of breast abscess. Incision (A); introducing the tip of a pair of forceps to improve drainage (B); breaking down loculi with a finger (C); inserting a corrugated drain (D); a counter-incision may be made to establish dependent drainage (E).

Abdomen (general)

Laparotomy

Laparotomy is used to expose the abdominal organs for surgery. It can also allow the surgeon to confirm a preoperative diagnosis in a patient presenting with an "acute abdomen". Laparotomy should be avoided, however, if the patient has suspected acute pancreatitis.

The two incisions for laparotomy with which a surgeon should be thoroughly familiar are the midline and the paramedian incisions. If necessary, further exposure can be achieved by extending either incision or, rarely, by making a supplementary transverse incision. Of these two incisions, the midline is particularly recommended, as it is technically simpler and takes less time to make and close.

Incisions in the upper abdomen are employed for operations on the gallbladder, stomach, duodenum, spleen, and liver, whereas incisions in the lower abdomen are used for patients with intestinal obstruction or pelvic problems (mainly obstetric and gynaecological). If you are in doubt about the diagnosis, you may use a short paraumbilical incision and extend it up or down in the midline, as indicated.

The upper midline incision

Because an upper midline incision does not cause much bleeding, it can be made quickly — an important consideration in emergencies. It provides good exposure of the stomach, duodenum, gallbladder, left half of the liver, lesser sac of the peritoneum, and pancreas. If better exposure is needed, the incision may be extended downwards around or even through the umbilicus.

The disadvantage of the upper midline incision is that it generally offers poor exposure of the spleen and the colon, although operation on these organs is possible if the incision is suitably extended.

Equipment See tray for *Laparotomy*, Annex 1.

Technique Insert a nasogastric tube and empty the patient's stomach. A general anaesthetic should be given.

Secure the patient to the operating table in a supine position. Apply a surgical diathermy pad to the sacral area or lower limb. Prepare the skin with antiseptic, from the level of the nipples down to the pubic region and to the flank on either side. Apply sterile drapes, exposing the region between the xiphisternum and the umbilicus.

Incise the skin in the midline between the xiphoid process and the umbilicus (Fig. 10.1A). Carry the incision down to the subcutaneous layer and to the loose

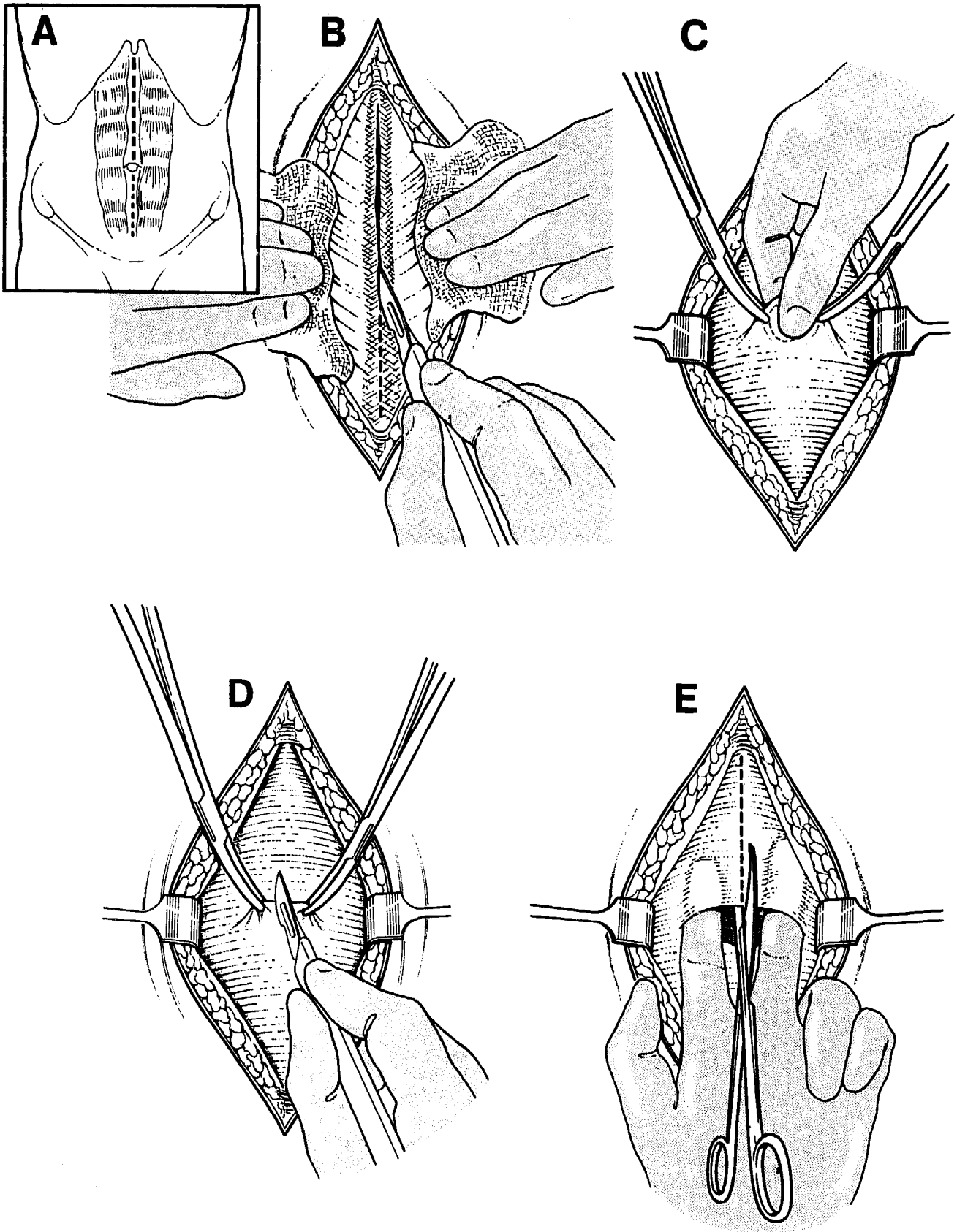


Fig. 10.1. The upper midline incision for laparotomy. Site of incision (heavy broken line), which can be extended (light broken line) if necessary (A); dividing the linea alba (B); lifting and dividing the peritoneum (C-E).

tissue over the linea alba. Control bleeding with gauze swabs held against the wound edge. Ligate any persistent bleeding points. Display the linea alba with its longitudinal line of decussating fibres and incise it strictly in the midline, thereby exposing the extraperitoneal fat and peritoneum (Fig. 10.1B).

Exercise care if the incision is through a previous laparotomy scar, as the gut may be adherent to the undersurface of the abdominal wall and thus liable to injury. Clear the extraperitoneal fat laterally by swab and blunt dissection, securing vessels as necessary. In fat people, this layer is often thick, while the underlying peritoneum is thin and "friable".¹

Lift the peritoneum, making it into a "tent" by holding it with artery or tissue forceps on either side of the midline. Squeeze the tent between the fingers and thumb to free any gut on the undersurface, and make a small opening with a knife (Fig. 10.1C,D). If the peritoneum opens up readily, steady the undersurface with the index and middle fingers and extend the opening with scissors (Fig. 10.1E). The peritoneal incision can then be extended to the full length of the wound.

Examine the abdominal contents to confirm your diagnosis.

- If there is a welling-up of greenish fluid and gas, suspect perforation of the stomach or duodenum. Examine these organs.
- If there is free blood in the peritoneum and the patient has a history of trauma, suspect injury to the liver, spleen, or mesentery. If the patient is female with no history of trauma, suspect a ruptured ectopic pregnancy.
- If there is a purulent exudate, suspect appendicitis, diverticulitis, or perforation of the gut.
- If there is a distended loop of bowel, suspect intestinal obstruction or paralytic ileus.
- If there are free bowel contents and gas in the peritoneum, suspect bowel perforation.

Systematically inspect and palpate the abdominal organs, except in an emergency (for example in a patient with a ruptured spleen or a perforated peptic ulcer) when the immediate threat to life must be contained first. Defer palpation of any obvious tumours and of infected or possibly infected regions until the rest of the abdomen has been examined. When you are dealing with infection, the extent of inspection and palpation must be restricted.

An appropriate operation can now be carried out, if indicated by the pathological findings.

At the end of the operation, close the wound in layers. Use several pairs of large artery forceps to hold the ends and edges of the peritoneal incision, and close the peritoneum together with the overlying extraperitoneal fat with a continuous suture of 0 chromic catgut on a round-bodied needle (Fig. 10.2A). Relaxation of the abdominal wall (provided by a muscle relaxant drug) is necessary at this stage to keep the intestine within the abdominal cavity. In the presence of intestinal distension, this may be a considerable problem. In such cases, a malleable copper spatula may be placed under the wound to confine the gut (Fig. 10.2B).

¹In surgical practice, a friable tissue is one that has the consistency of wet blotting paper and disintegrates easily.

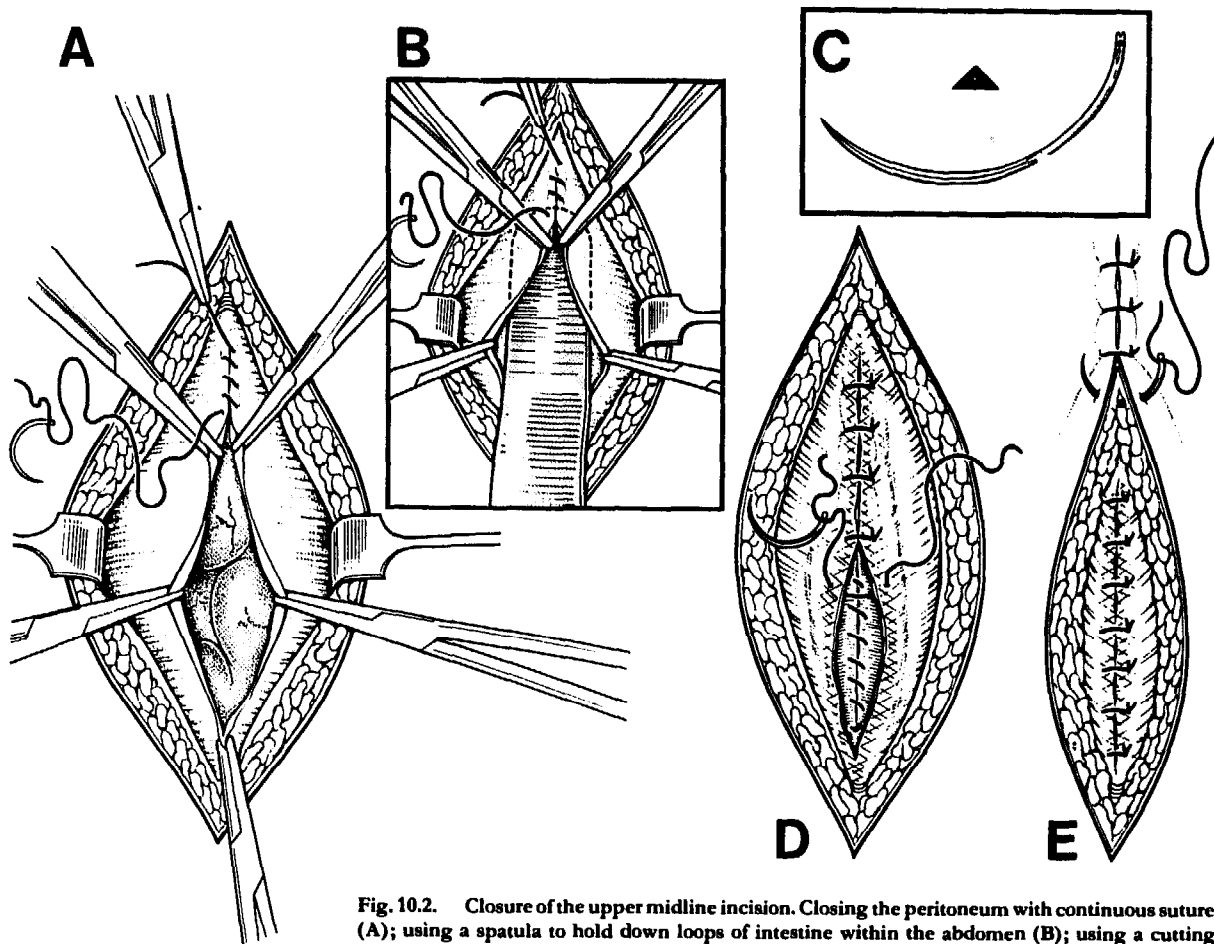


Fig. 10.2. Closure of the upper midline incision. Closing the peritoneum with continuous suture (A); using a spatula to hold down loops of intestine within the abdomen (B); using a cutting needle (C, shown also in cross-section) to suture the linea alba (D) and finally the skin (E).

Close the linea alba with interrupted 0 thread or continuous monofilament nylon on a cutting needle (Fig. 10.2C,D), but in the presence of infection or gross contamination, use a loose continuous stitch of No. 1 nylon and avoid thread. Close the skin with interrupted stitches of 2/0 thread (Fig. 10.2E). Regardless of the method of suturing, it is essential to insert the needle at least 1 cm from the wound edge and to place the suture loops about 1 cm apart.

If closing the abdomen is difficult, check the adequacy of anaesthesia and relaxation of the abdominal wall and empty the stomach with a nasogastric tube. Use interrupted simple all-layer (tension) sutures to close the wound (see page 106).

In fat patients, stitching of the subcutaneous fat with 2/0 plain catgut may be necessary. Before closing the wound, always ensure sound haemostasis, remove any haematoma, and clean the wound thoroughly.

Use only one or two layers of gauze for dressing. Do not dress the wound tightly or use a sealing tape over the dressing in a hot and humid climate.

The upper paramedian incision

The upper paramedian incision may be made on either side of the midline and is the incision of choice when the rectus muscles are widely separated (divarication). Made on the patient's right, it provides good exposure of the duodenum or stomach and can be used for operations on the gallbladder. It can be extended by a longitudinal or a transverse incision.

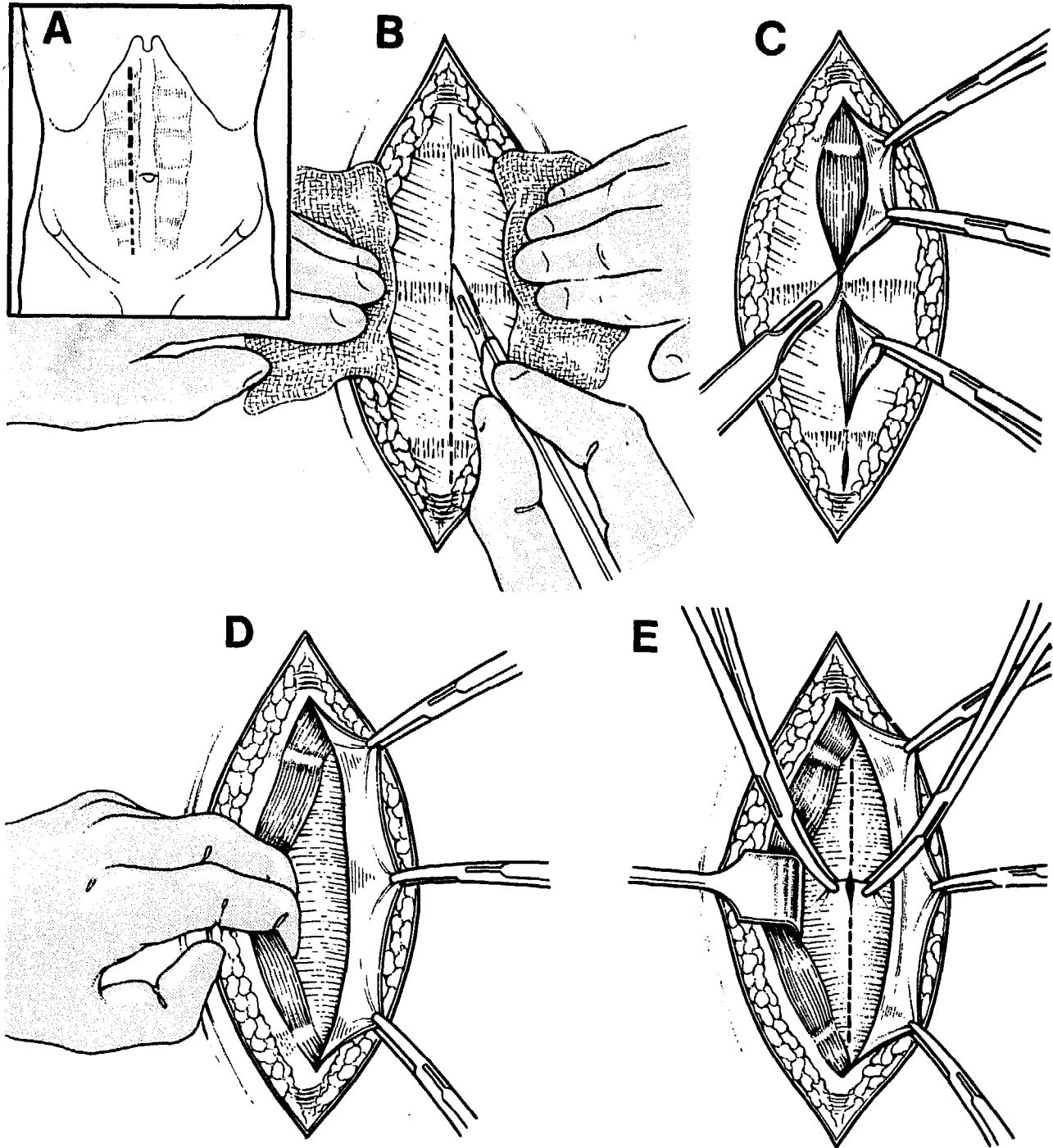


Fig. 10.3. The paramedian incision for laparotomy. Site of incision (heavy broken line), which can be extended (light broken line) if necessary (A); incising the anterior rectus sheath (B); dissecting the sheath off the muscle (C); reflecting the rectus muscle laterally (D); dividing the posterior rectus sheath (E).

The disadvantages of the upper paramedian incision are that, for the inexperienced surgeon, it is more difficult to make than the midline incision; that the procedure takes longer than laparotomy with a midline incision; and that it provides only poor exposure of the organs on the opposite side.

Equipment See tray for *Laparotomy*, Annex 1.

Technique Insert a nasogastric tube and empty the patient's stomach. A general anaesthetic should be given.

Make an incision longitudinally from the xiphoid process to the umbilicus at about 2 cm from the midline (Fig. 10.3A), and then deepen it until the anterior rectus sheath is exposed. Effect haemostasis with gauze held against the wound edge, using diathermy or ligatures to control any persistent bleeding.

Incise the anterior rectus sheath longitudinally, leaving a medial margin of about 2 cm, but do not incise the underlying muscle (Fig. 10.3B). Instruct your assistant to hold up the medial edge of the rectus sheath using several pairs of artery forceps to provide an upward and medial retraction (Fig. 10.3C). In this way, the three areas of adherence of the sheath to the anterior surface of the muscle (at the top end, at the umbilicus, and half-way between the two) will become apparent. Proceed carefully, as blood vessels course through these areas of adherence (tendinous intersections).

Dissect the sheath off the muscle. Use the back of a scalpel handle or the back of a pair of dissecting forceps, closed curved scissors, or the fingers to release the medial border of the muscle. This allows the muscle to be retracted and slid laterally, to expose the posterior rectus sheath (Fig. 10.3D). A few small vessels may need to be divided and ligated between the posterior sheath and the back of the muscle.

Lift the exposed posterior sheath, making it into a tent by holding it, medially and laterally, with two pairs of Allis or artery forceps, and incise the sheath in between while squeezing the tent to displace the underlying gut (Fig. 10.3E). Deepen the incision to include the peritoneum, making the opening large enough to admit the index and middle fingers. Use these fingers to hold up the undersurface of the peritoneum, while extending the incision with scissors to the full length of the wound by cutting in between the fingers. If the falciform ligament prevents a clear view of the interperitoneal structures, it should be divided between clamps and ligated.

Inspect and palpate the abdomen and viscera, as detailed on page 102, and carry out any necessary surgery.

At the end of the operation, close the incision in three layers. Stitch the peritoneum, any extraperitoneal fat, and the posterior rectus sheath together in one layer with a continuous 0 chromic catgut. Reposition the rectus muscle and stitch the anterior rectus sheath with continuous monofilament nylon or interrupted 0 chromic catgut or thread. And finally, suture the skin with interrupted 2/0 thread or nylon stitches, taking precautions as described on page 103.

Use only one or two layers of gauze for dressing. Do not dress the wound tightly or use sealing tape over the dressing in a hot and humid climate.

Lower abdominal incisions Midline or paramedian incisions of the lower abdomen can be closed in the same way as upper abdominal wounds.

Wound drainage Drainage is indicated when there is a risk of haematoma formation or serous fluid collection in the wound or when there has been gross wound contamination. The best form of wound drainage in such cases is achieved by leaving the skin and subcutaneous fat unstitched. Close the peritoneum with catgut and the linea alba or rectus sheath with continuous No. 1 nylon. Insert skin stitches, but leave them untied for delayed primary closure.

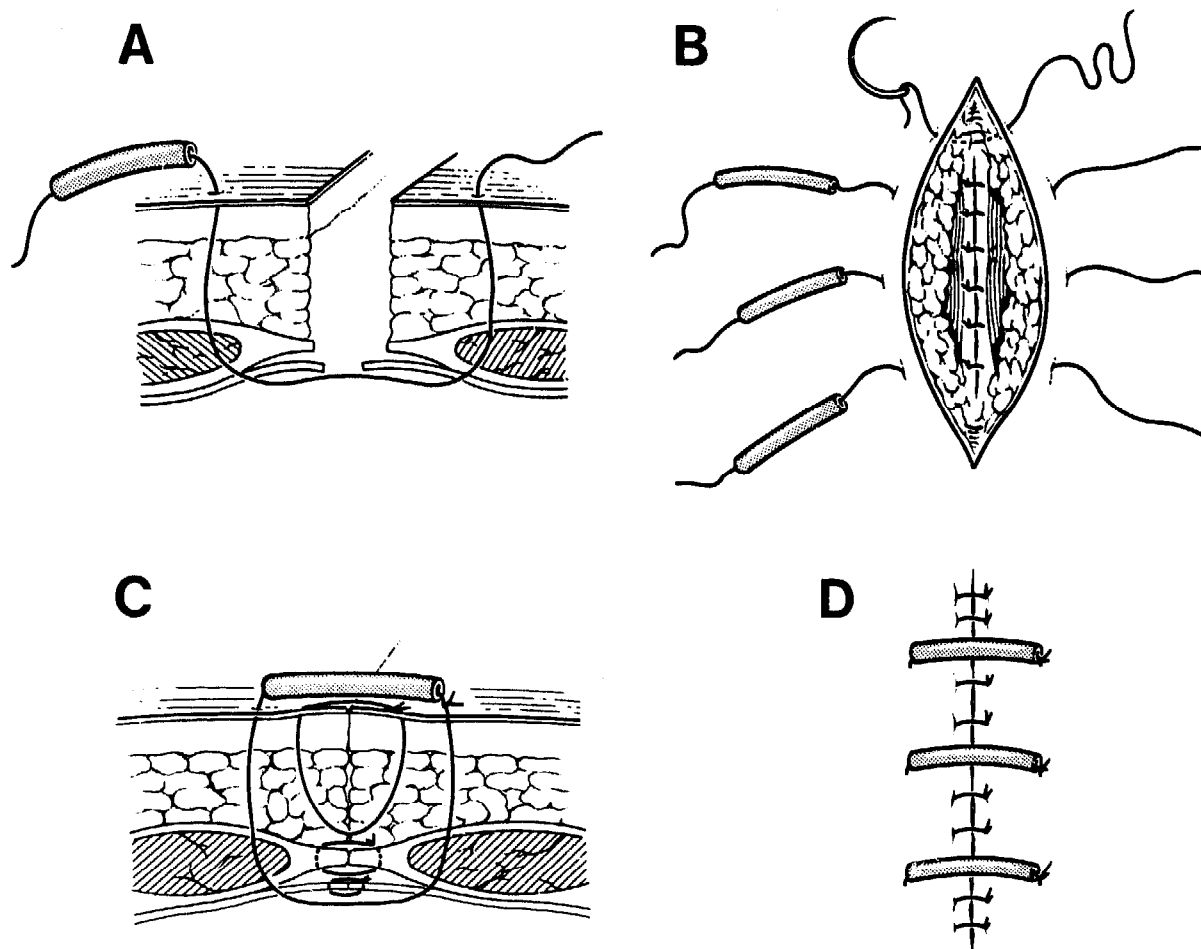


Fig. 10.4 Tension sutures for abdominal wounds. Inserting all-layer tension stitches (A); layered closure of all layers below the skin is completed (B) before the skin is closed and the tension sutures are tied (C, D).

Tension sutures

Tension sutures are indicated in patients debilitated as a result of malnutrition, old age, or advanced cancer, when healing is likely to be impaired, and in patients suffering from conditions associated with increased intra-abdominal pressure, for example obesity, asthma, or chronic cough. Monofilament nylon is a suitable material. Insert the tension sutures through the entire thickness of the abdominal wall before closing the peritoneum, leaving them untied at first (Fig. 10.4A). They may be simple (through-and-through) or mattress in type. Insert a continuous peritoneal suture to take up the tension sutures, and continue to close the wound in layers (Fig. 10.4B). When skin closure is complete, tie each tension suture after threading it through a short length of plastic or rubber tubing (Fig. 10.4C,D); the sutures should not be tied under tension. Do not remove them for at least 14 days.

Repair of burst abdomen

A burst abdomen is a postoperative, abdominal wound dehiscence. It is often caused by conditions in the patient that either retard healing or are associated with increased intra-abdominal pressure (as listed above in the section on tension sutures), but it can also be the unfortunate result of poor surgical technique in wound closure. Rarely, a burst abdomen occurs without obvious reason.

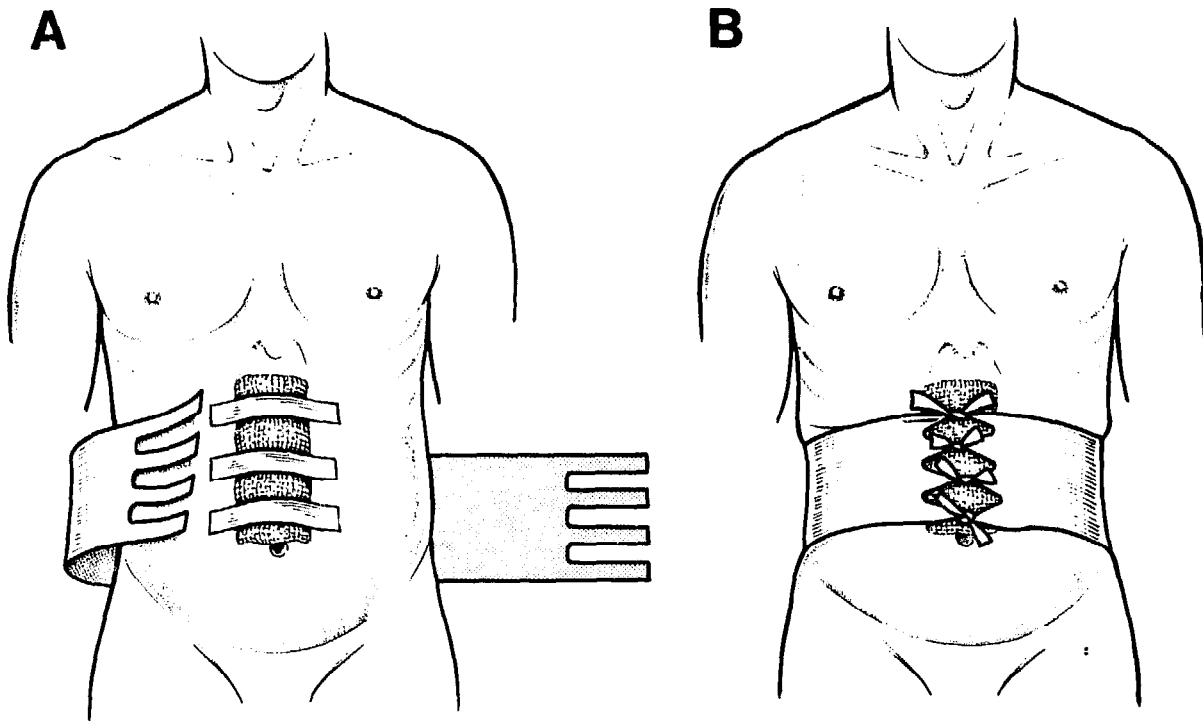


Fig. 10.5. Abdominal binder.

Most patients experience the moment of the rupture as a sensation of something giving way, often during the act of coughing or defecation. This is followed by the appearance of thin blood-stained fluid from the surgical wound — the most important warning sign. In cases of complete rupture, the omentum or intestine appears in the wound. Hypovolaemic shock and pain are unusual.

Preoperative management

First allay the anxiety of the patient and any relatives present. Sedate the patient and cover or, if necessary, bind the abdomen with a sterile towel. While making arrangements for emergency surgical repair, insert a nasogastric tube and begin intravenous infusion of an appropriate fluid. If the wound is infected, administer antibiotics.

Equipment

See tray for *Laparotomy*, Annex 1, and add strong (No. 1 or No. 2) monofilament nylon or thread, and tubing for tension sutures.

Technique

The patient should be given a general anaesthetic with a muscle relaxant. Clean the wound and the surrounding skin together with any prolapsed gut and omentum with cetrimide. (Never use iodine or alcohol on the gut or omentum.) Drape the patient and carry out wound débridement to remove all fragmented tissues and previous stitches.

Insert tension sutures, as described on page 106, and tie them one by one to close the wound in one layer. Do not attempt to suture the peritoneum or other layers separately. Support the abdominal wall with a clean sheet or binder (Fig. 10.5).

After-care

Control predisposing conditions, for example asthma or chronic cough. Maintain nasogastric suction to keep the stomach empty and to decompress the upper

gastrointestinal tract. Continue intravenous infusion of appropriate fluids. If there is infection, continue the administration of antibiotics. As the patient recovers, he or she may be gradually weaned off this regimen. Recovery is indicated by the patient feeling better and by the return of bowel sounds, the passage of flatus, a reduction in the volume of gastric aspirates, an adequate urinary output, and a normal pulse, blood pressure, and temperature.

Remove the stitches after 14 days.

Complications

The patient's chances of survival are largely determined by the predisposing condition. Incisional hernia is a possible complication.

Abdominal injuries

General principles

Penetrating injuries include gunshot wounds and wounds induced by stabbing with sharp objects, for example knives or spears. A penetrating abdominal wound is an indication for exploratory laparotomy, regardless of the physical signs or the apparently superficial nature of the wound. Signs of hypovolaemia or of peritoneal irritation may be minimal or absent immediately after a penetrating injury involving the abdominal viscera. Probing the wound may be misleading, as the probe can fail to traverse a track that has been distorted by altered muscle tone or by a change in the patient's position. First resuscitate the patient and then perform an emergency exploratory laparotomy, this being the only way of ensuring that no serious or potentially serious injury is overlooked.

Penetrating injuries

Blunt injuries

Blunt injuries occur most commonly as a result of traffic accidents or assault. Assessing the need for laparotomy is more difficult than for patients with penetrating injuries. In the presence of hypovolaemia, examine the chest and other possible sites of blood loss, for example the area around pelvic or femoral fractures.

When a patient has sustained a blunt abdominal injury, exploratory laparotomy is indicated in the presence of any of the following:

- abdominal tenderness with rigidity;
- pain and tenderness in either hypochondrium, especially if the pain is referred to the shoulder and if there is associated blood loss;
- free abdominal gas, as seen on a plain radiograph;
- failure to pass urine, with local signs maximal in the suprapubic area, suggesting rupture of the bladder.

Initial management

When a patient presents with abdominal injuries, first establish a clear airway and arrest any external bleeding. Resuscitation may be necessary, but should not unduly delay operation. Make a thorough physical examination. Establish base-line observations of vital signs, set up an intravenous line, and infuse an appropriate fluid. Insert a nasogastric tube and begin suction. Even if the patient's condition appears to be satisfactory, take a blood sample for haemoglobin measurement, grouping, and cross-matching. X-ray the chest, abdomen, pelvis, and any other injured parts of the body.

Prepare the patient for emergency laparotomy if this is indicated. Insert a bladder catheter and examine the urine for blood, sugar, and protein. Chart the patient's

urinary output. Administer analgesics and, if the patient has penetrating wounds, antibiotics and tetanus prophylaxis as well.

Make no attempt to reduce any gut or omentum protruding through the wound. Cover it with a sterile towel while you prepare to operate.

Proceed with laparotomy if indicated.

Laparotomy and repair of injuries

Equipment

See tray for *Laparotomy*, Annex 1, and add several large round-bodied needles.

Technique

The patient should be given a general anaesthetic. Make a generous midline or right/left paramedian incision; this can be further extended below the umbilicus, if necessary. Defer débridement and suture of the injury wound until the end of the operation. Apply pressure over warm, moist packs to control bleeding areas temporarily, keeping in mind that the source of bleeding is likely to be near a large clot. Arrest any brisk bleeding temporarily with forceps, provided that the bleeding vessel can be clearly identified. If the blood is not contaminated by either gut contents or urine, consider autotransfusion. Control spillage of gut contents by temporarily occluding any perforations with light tissue forceps or with intestinal occlusion clamps.

Thoroughly clean the abdominal cavity with abdominal packs and warm saline. Inspect the organs systematically, beginning with the small intestine and progressing to the large intestine and rectum, the bladder and uterus, the stomach and duodenum, the liver, the spleen, and finally the pancreas and kidneys (including the retroperitoneal area). Note each injury as it is detected, but plan the appropriate surgical procedure only after you have made a complete assessment.

Stomach

Trim any ragged wound edges in the stomach. Then suture the wound in two layers, carefully invaginating the mucosa.

Small intestine

Close small punctures of the small intestine with purse-string suture, invaginating the mucosa. Close larger wounds transversely with two layers of interrupted invaginating stitches (Fig. 10.6). The wound edges may first require trimming. When several wounds lie close together or when repair would narrow the gut unacceptably, resect the damaged loop and make an end-to-end anastomosis (see page 125). Also resect gut made ischaemic by a tear in the mesentery.

Right colon

Injury of the right colon requires resection of the entire right colon and exteriorization of the two open ends as a transverse colostomy and an ileostomy. Make no attempt to repair this type of injury.

Transverse colon

Exteriorize the site of injury as a colostomy.

Descending colon

Mobilize the colon, exteriorizing the site of injury and converting it into a colostomy. Drain both the paracolic gutter and the pelvis.

Rectum

Repair an injury to the rectum in two layers and construct a sigmoid colostomy. Drain the left side of the abdomen and the pelvis.

Spleen

Splenectomy is the standard treatment for injuries to the spleen, but consider preserving the spleen in certain cases (see page 121).

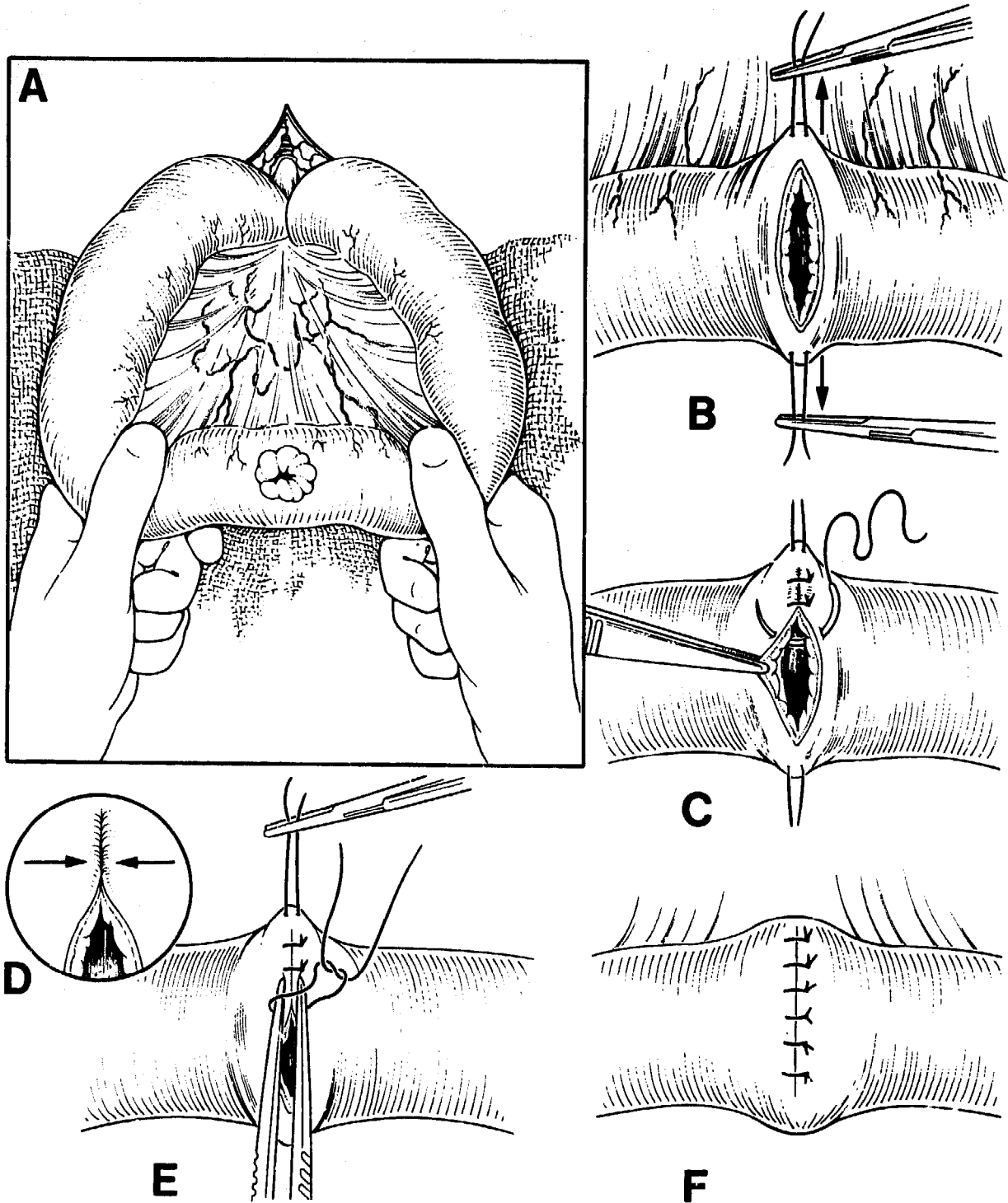


Fig. 10.6. Closure of a wound in the small intestine. The wound (A); pulling the gut transversely by stay sutures (B); inserting the first layer of invaginating stitches to include all layers of the gut wall (C); an alternative method of inserting stitches, while maintaining the wound edges in apposition (D, E); a second layer of stitches completes the repair (F).

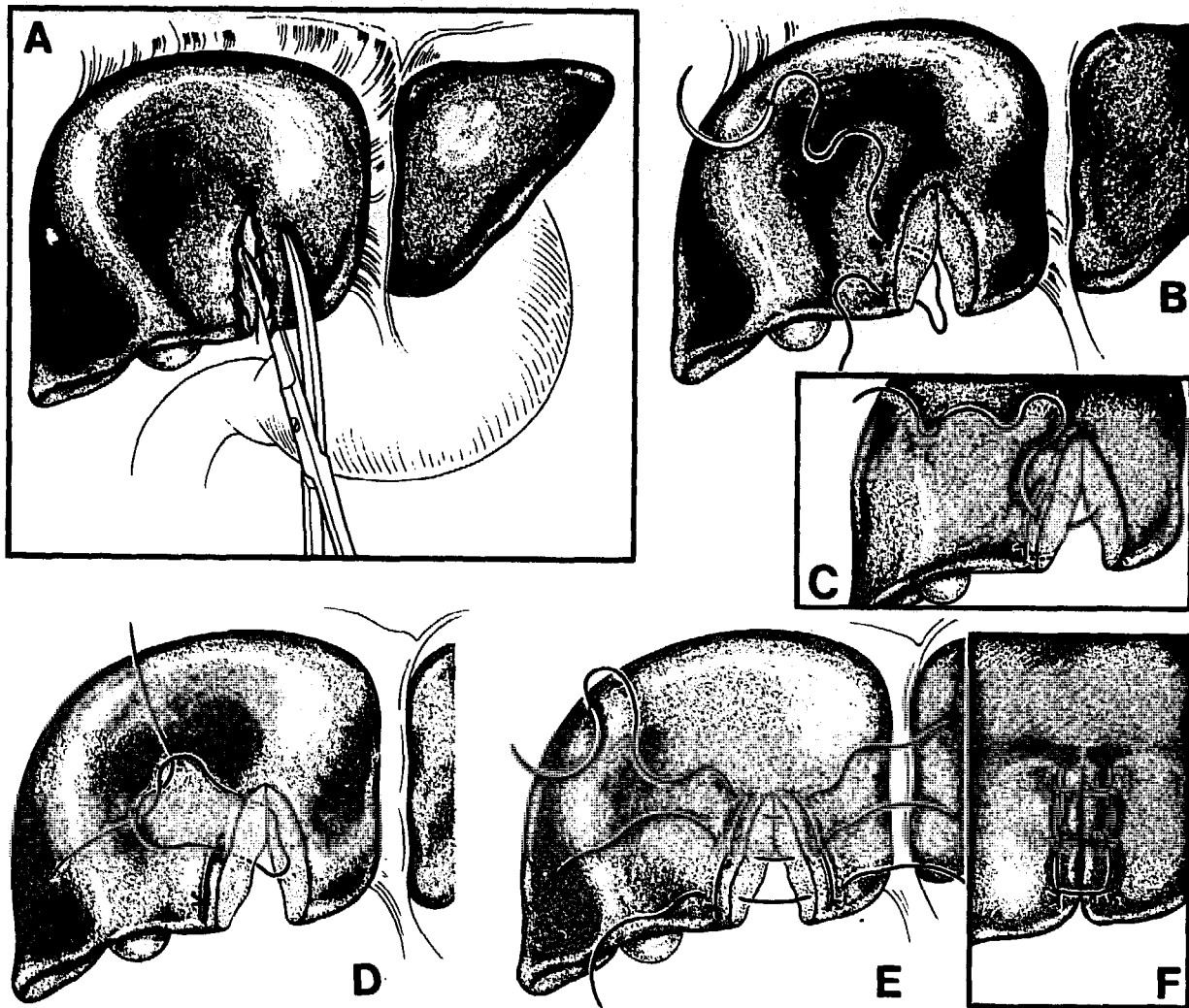


Fig. 10.7. Suture of a laceration of the liver. Excising non-viable liver tissue (A); inserting overlapping mattress sutures on both sides of the wound (B-E) and stitching the two sides together (E, F).

Liver

Small wounds of the liver may have stopped bleeding by the time of operation and should then be left alone. For larger wounds or tears, remove all devitalized tissue and suture the area with mattress sutures of 0 chromic catgut carried on a large, round-bodied needle (Fig. 10.7). If a laceration cannot be sutured, pack it with a long gauze roll, soaked in warm saline and wrung out. Bring one end of the roll out through a separate wound. A liver pack is usually removed in several stages after about 48 hours, if necessary with the patient under general anaesthesia for a short time. A large drain is indicated in all patients with liver injuries, to be removed also after about 48 hours. Make arrangements for referral as soon as the patient's condition permits.

Pancreas

Injury to the pancreas can be confirmed by opening the lesser sac through the gastrocolic (greater) omentum. The only safe procedure is to put a drain down to the site of injury. The drain should traverse the lesser sac and come out in the flank. Make arrangements for referral as soon as the patient's condition permits.

Retroperitoneal haematoma A retroperitoneal haematoma should not be opened or disturbed.

Bladder and urethra Management of rupture of the bladder and urethra is detailed in chapters 18 and 19.

Kidney Do not expose the kidney unless life-threatening bleeding is indicated by continued gross haematuria. Stop the bleeding at the site of the tear by stitching or transfixion. Refer the patient without delay.

Stomach and duodenum

Feeding gastrostomy

Gastrostomy is indicated when feeding through a nasogastric tube is hazardous or impossible, for example in patients with oesophageal burns or obstruction or with oesophageal atresia. Gastrostomy enables the patient to be nourished pending referral.

Clinical findings, and hence the laboratory tests to be requested, will depend upon the underlying condition.

Equipment See tray for *Laparotomy*, Annex 1, and add a pair of intestinal tissue-holding forceps and a Foley catheter (18–22 Ch.).

Technique Make an upper midline laparotomy incision of about 8–10 cm and inspect the abdomen. Pick up the anterior wall of the body of the stomach with intestinal tissue-holding forceps. Insert two circular rows of purse-string, 2/0 chromic catgut or thread sutures to enclose a section of the gastric wall of 1.0–1.5 cm diameter. Make an incision through the centre of this area, just large enough to admit the catheter (Fig. 11.1A,B). Ligate or coagulate the submucosal vessels immediately before incising the mucosa.

Make a separate stab wound in the patient's left upper quadrant, and through this introduce the tip of a Foley catheter (size 18–22 Ch.) into the abdominal cavity, guiding it into the stomach through the gastric opening (Fig. 11.1C). Distend the catheter balloon with not more than 5 ml of water and tie the purse-string sutures, beginning with the inner one. With a pair of forceps, bring the ends of the sutures out along the catheter to the skin surface to be tied off and cut later (Fig. 11.1D,E).

Now pull the catheter to bring the balloon close to the gastric mucosa, which will at the same time draw the gastrostomy site against the undersurface of the abdominal wall (Fig. 11.1F). Pass the ends of the sutures through the skin edge with a cutting needle. Tie one pair of ends against each other around the tube, thus anchoring it, and use the other pair to close the stab wound (Fig. 11.1G–I).

Close the abdominal wound and dress it with sterile gauze. Dress the stab wound with a single layer of dry, sterile gauze.

Perforated peptic ulcer

The main sites of peptic ulceration are the duodenum and the stomach. In most populations, duodenal ulcer is more common than gastric ulcer. The main complications of peptic ulcer are bleeding, penetration with perforation, and obstruction, for example of the pylorus.

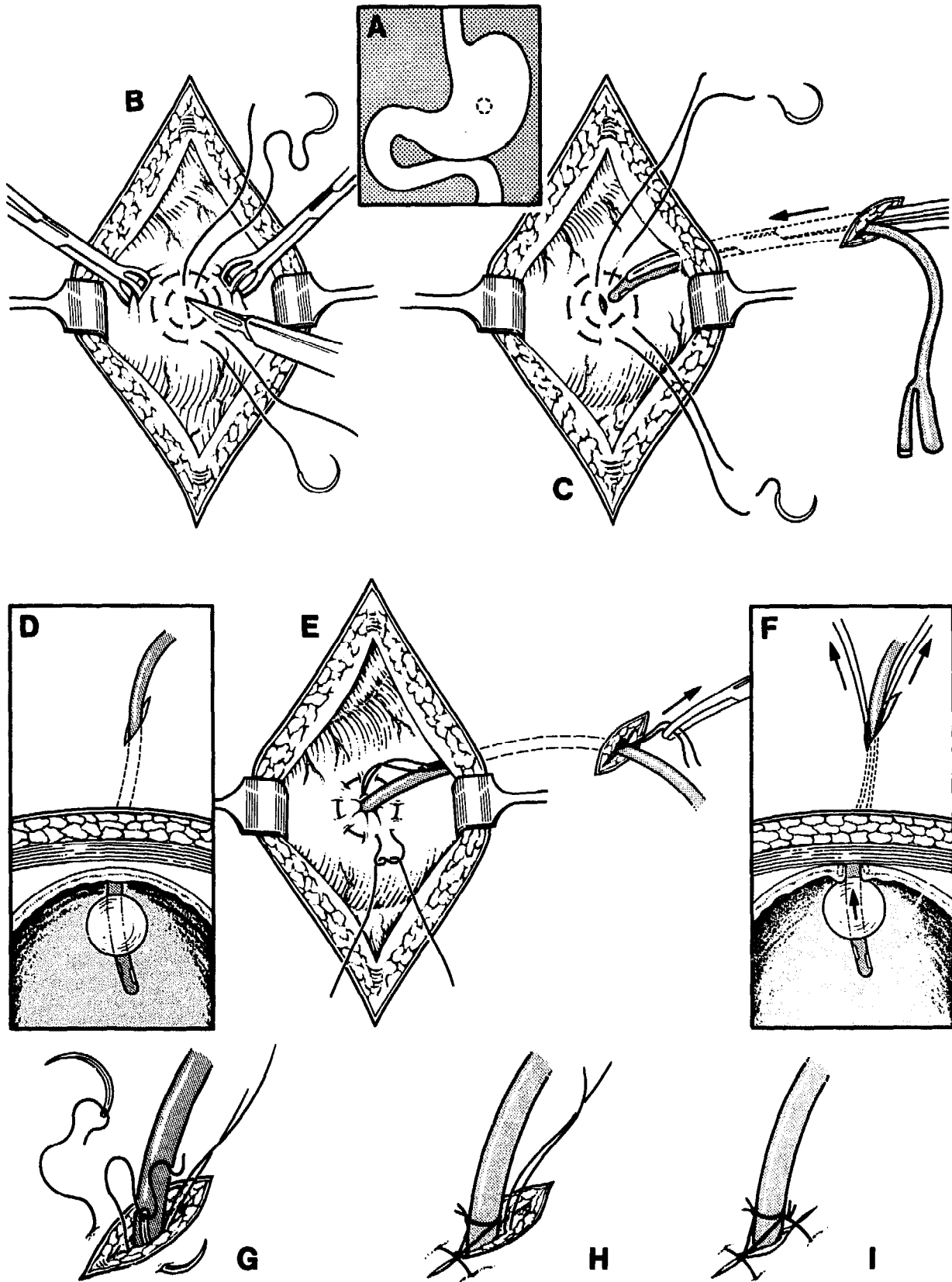


Fig. 11.1. Feeding gastrostomy. Site for introduction of the catheter (A); incising the stomach wall, after inserting purse-string sutures (B); introducing the catheter (C); position of the tip of the catheter within the stomach (D); fixing the catheter to the stomach wall (E, F) and to the skin (G, H); closing the stab wound (I).

Perforating duodenal ulcers are usually located anteriorly, while perforating stomach ulcers can occur either anteriorly or posteriorly. Occasionally a gastric ulcer is malignant. The hazardous effects of perforation are due to peritonitis. Initially this is chemical, caused by spillage of the acidic gastric contents and of duodenal fluid into the peritoneal cavity. Bacterial inflammation occurs about 12 hours after spillage. For this reason, the prognosis is greatly influenced by the time interval between perforation and surgical closure.

Diagnosis

The characteristic history includes a sudden onset of severe abdominal pain. Some patients compare the experience to a severe stab or blow in the abdomen, and most are able to give the precise time of the episode. Surprisingly, prodromal symptoms are usually absent. Patients rarely give a history suggestive of the disease, although some may already know that they have a peptic ulcer. After the acute episode, the patient experiences an intense burning pain, mainly in the upper abdomen. The body is held rigid and the patient finds any movement extremely painful.

The major physical signs are in the abdomen, which does not move with respiration but has a board-like rigidity and is extremely tender. Bowel sounds may be markedly reduced or absent. Later the abdomen becomes distended and silent. The patient may show signs of hypovolaemic shock.

A plain abdominal radiograph will usually show free gas in the abdominal cavity. Obtain the radiograph with the patient in a left lateral decubitus position or standing, if possible, when the gas will show between the right lobe of liver and the diaphragm.

The differential diagnosis should include acute pancreatitis and acute cholecystitis.

Treatment

A perforated peptic ulcer is an indication for emergency operation. The aims are to close the perforation, which will halt further contamination of the peritoneal cavity, and to remove the irritant fluid by suction and peritoneal lavage, which will also minimize bacterial inflammation.

A delay in operation will adversely affect the prognosis, particularly if the delay continues beyond 6 hours from the time of the perforation. Other factors affecting prognosis are the patient's age, his or her nutritional status and health before the episode, and the degree of contamination of the peritoneal cavity.

Repair of perforated ulcer

Assessment and preoperative management

Administer morphine immediately, preferably intravenously. Once pain is controlled, pass a nasogastric tube and aspirate the stomach contents. Begin an intravenous infusion of saline and resuscitate the patient as far as possible before proceeding to surgery. An intravenous dose of a broad-spectrum antibiotic should be given 1 hour before operation and regularly for the next 24 hours.


Measure the patient's haemoglobin level and test the urine for sugar and protein. Take blood for grouping, though blood transfusion is not usually necessary.

Equipment

See tray for *Laparotomy*, Annex 1.

Effective suction is essential in this operation, even if provided only by foot pump and suction bottle. Prepare 1 litre of warm sterile saline for peritoneal lavage, adding 1 g of tetracycline to this solution just before use.

Fig. 11.2. Repair of a perforated duodenal ulcer. Site of the midline incision (A); identifying the perforation and aspirating fluid (B); inserting sutures (C); tying the sutures to close the perforation (D) and then again over a tag of the omentum (E).



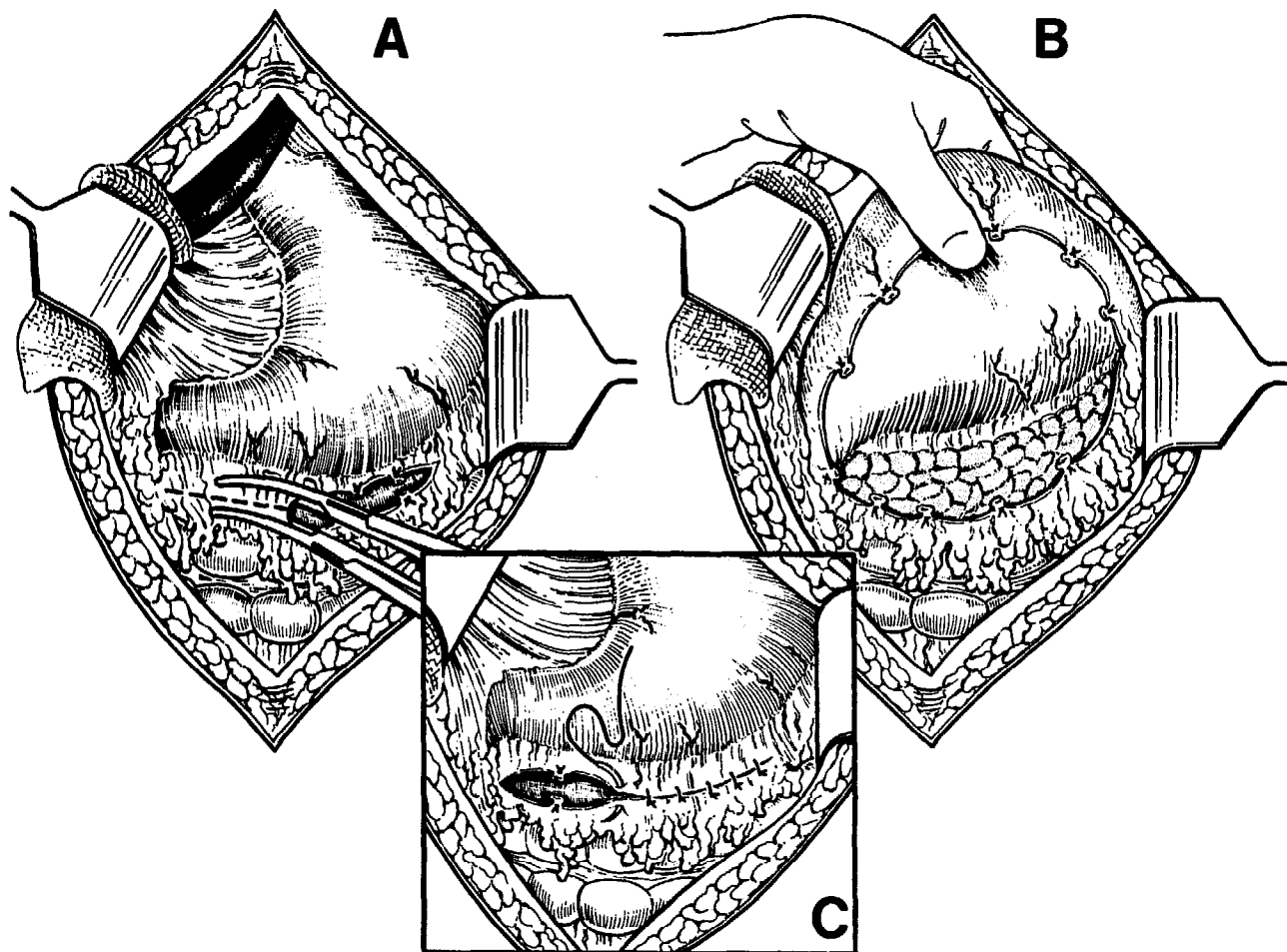


Fig. 11.3. Checking for a perforated posterior peptic ulcer. Dividing the greater omentum to open the lesser sac (A); inspecting the posterior wall of the stomach (B); repairing the omentum after closing the perforation (C).

Technique

The patient should be given a general anaesthetic, preferably with a muscle relaxant. Insert a nasogastric tube, and aspirate the stomach contents. Open the abdomen through an upper midline incision (Fig. 11.2A). Remove all fluid and food debris from the peritoneal cavity using suction and warm moist abdominal packs. Gently retract the liver upwards, draw the stomach to the left by gentle traction over a warm pack, and identify the perforation. Continue to aspirate fluid as necessary (Fig. 11.2B). Note the appearance of the gut wall adjacent to the perforation; scarring suggests a chronic ulcer. If a perforation is not obvious, check the posterior wall of the stomach by opening the lesser sac of the peritoneum (Fig. 11.3A,B).

Insert three 2/0 chromic catgut stitches in the long axis of the duodenum or stomach so that the middle stitch passes across the perforation itself, taking the full thickness of the gut wall about 5 mm from the edge of the perforation. The upper and lower stitches should take a generous seromuscular "bite" of the gut. Tie off the sutures loosely, leaving the ends long (Fig. 11.2C,D). Draw a tab of adjacent omentum across the perforation and tie the three stitches over it (Fig. 11.2E). Repair the greater omentum if you have divided it to locate a posterior perforation (Fig. 11.3C).

Thoroughly cleanse the peritoneal cavity with the prepared warm saline containing tetracycline. Also cleanse the areas of the peritoneum most likely to be

contaminated, especially the subphrenic spaces and pelvic peritoneum, using gauze packs. After a satisfactory toilet there is no great advantage in draining the peritoneum, but if in doubt, leave a tube drain below the right lobe of the liver, bringing it out through a lateral stab wound in the abdominal wall. Further applications of antibiotic to the peritoneum are unnecessary. Close the wound in layers, except in cases of gross contamination when it is preferably left partially open for delayed primary closure 2-5 days later.

After-care

Continue nasogastric aspiration and the intravenous administration of fluids, and maintain an accurate fluid-balance chart. The insertion of an indwelling bladder catheter may be necessary. Observe the patient's blood pressure, pulse, respiration, and temperature regularly. Give antibiotics and analgesics; this is best done intravenously if the patient is receiving fluids via a drip. If a drain has been inserted, remove it 24-48 hours after the operation.

The patient may be gradually weaned off the above regimen. Recovery is indicated by the patient feeling better and by the return of bowel sounds, the passage of flatus, a reduction in the volume of gastric aspirates, an adequate urinary output, and a normal pulse, blood pressure, and temperature. When the patient is able to eat normally, begin treatment for peptic ulcer.

After successful treatment of the perforation, regularly re-examine the patient as an outpatient. The results of the operation are variable: some patients, particularly those with perforated acute ulcers, may not experience any further symptoms; others may continue to suffer; and a few may show symptoms of severe ulcer, requiring referral for elective surgery.

12

Gallbladder and spleen

Cholecystostomy

At the district hospital, the only indication for cholecystostomy is severe acute cholecystitis with a distended gallbladder that is in danger of rupturing.

Diagnosis is made during a laparotomy for "acute abdomen". The gallbladder will be inflamed, red, oedematous, distended, and possibly coated with a film of exudate. It may contain stones. If the gallbladder is very tense and appears likely to rupture, proceed to cholecystostomy. Otherwise close the abdomen and refer the patient after he or she has recovered from the attack of cholecystitis.

Start treatment with antibiotics and analgesics once cholecystitis has been diagnosed.

Equipment See tray for *Laparotomy*, Annex 1, and add a Foley balloon catheter, a 20 or 50 ml syringe with a wide-bore needle, a pair of Desjardin forceps, and a sterile, closed drainage system.

Technique When severe acute cholecystitis is encountered during an operation and the gallbladder is in danger of rupturing, proceed to cholecystostomy. The gallbladder should be packed off with gauze (Fig. 12.1A) to prevent spillage of infected bile into the peritoneal cavity. Insert two purse-string 2/0 chromic catgut stitches into the fundus (Fig. 12.1B). Aspirate the infected bile with a needle and syringe to empty the gallbladder (Fig. 12.1C), and then incise the fundus with a pointed knife in the centre of the purse-string sutures (Fig. 12.1D) and apply suction (Fig. 12.1E). Any easily accessible stones can be extracted with the aid of a pair of Desjardins or other suitable forceps (Fig. 12.1F); this procedure is facilitated by "milking" the gallbladder towards the fundus.

Introduce the tip of a Foley catheter through a stab wound in the abdominal wall and from there into the gallbladder (Fig. 12.1G). Tie the purse-string sutures, the inner one first, leaving the ends long, and inflate the balloon (Fig. 12.1H,I). Bring the ends out through the abdominal wall along with the catheter and anchor them to the stab wound. In this way, the gallbladder wall at the site of the cholecystostomy is brought to lie against the undersurface of the abdominal wall, deep to the stab wound.

Close the laparotomy incision. Then close the stab wound and tie the catheter securely in position with the ends of the second purse-string suture. Connect a sterile, closed drainage system to the catheter.

After-care Continue to give the patient antibiotics and analgesics. Nasogastric suction and the intravenous administration of fluids are necessary for 2-3 days after the

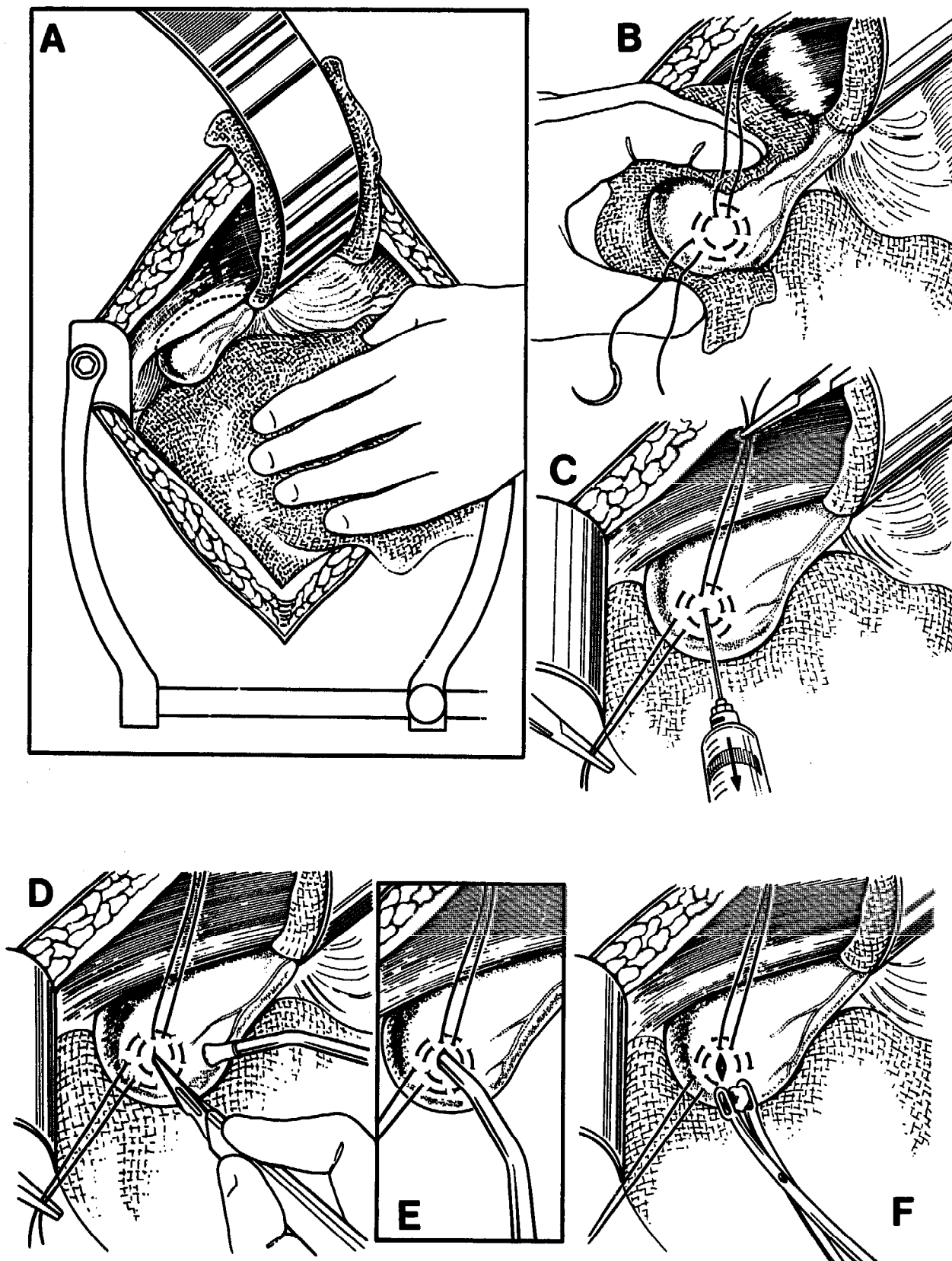


Fig. 12.1. Cholecystostomy. Exposing the gallbladder (A); inserting two purse-string sutures (B); aspirating the infected bile (C); incising the gallbladder in the centre of the area enclosed by the purse-string sutures (D); suction (E); removing any loose stones (F).

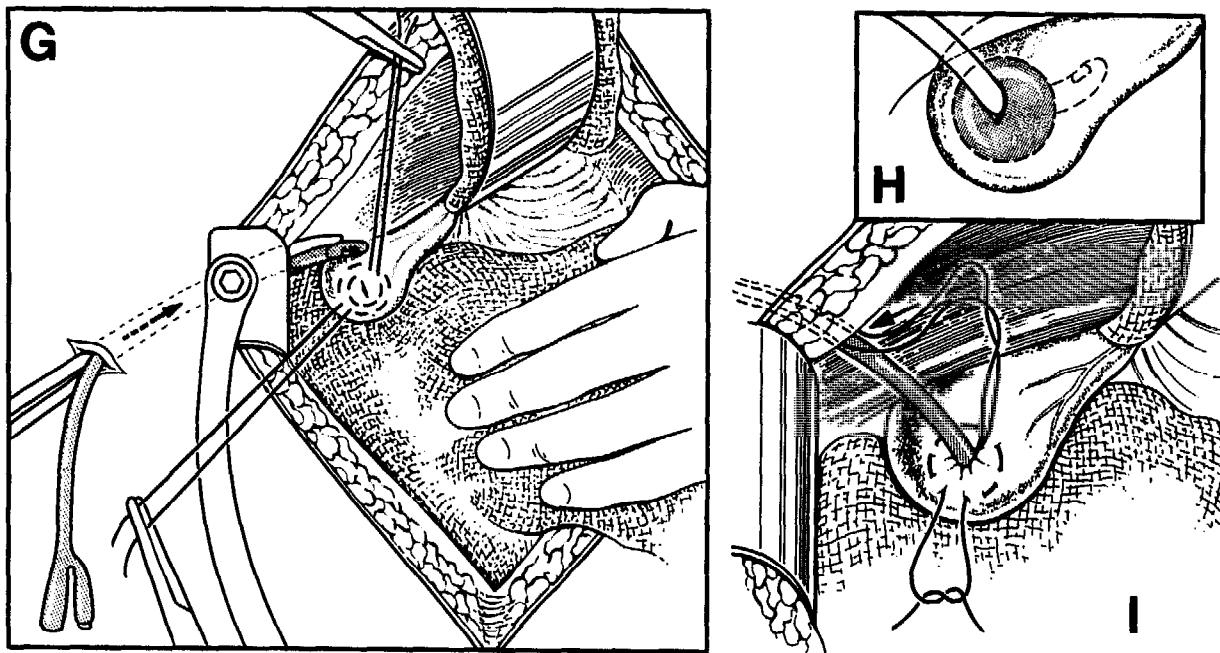


Fig. 12.1. Cholecystostomy (*continued*). Introducing the tip of a Foley catheter into the gallbladder (G, H); tightening the purse-string sutures against the tube and using the ends to fix the catheter (I).

operation. After 10 days clip off the cholecystostomy catheter for increasing periods of time. If there is no pain or leakage of bile around the tube when it has been closed for 24 hours, the catheter may be removed safely. The sinus to the gallbladder generally closes rapidly thereafter. If necessary, however, the cholecystostomy catheter may be left in position.

Arrange for the patient to be referred for elective cholecystectomy about 6 weeks after the initial operation.

Ruptured spleen

In tropical countries, enlargement of the spleen due to malaria or kala-azar (visceral leishmaniasis) is common. The affected spleen is liable to be injured or to rupture as a result of even trivial trauma.

Diagnosis and treatment

The patient with a ruptured spleen usually has a history of trauma, though the trauma may have gone unnoticed until the symptoms of rupture developed. Laceration of the spleen can be associated with multiple injuries, for example as a result of a traffic accident, or with localized trauma. Pain is often present in the left upper abdomen and may be referred to the left shoulder. The patient may also complain of nausea and vomiting.

Physical examination reveals some degree of hypovolaemia. Abdominal tenderness and rigidity are maximal in the splenic area, where a diffuse mass may be evident. A chest radiograph may show fracture of one or more of the left lower ribs, while an abdominal radiograph may reveal a shadow in the upper left quadrant, displacing the gastric air bubble medially.

If you suspect rupture of the spleen, proceed to splenectomy if the patient is hypovolaemic, but if the patient is in a stable state and does not need immediate blood replacement, consider conservative management. This should consist of careful observation, bed-rest, intravenous infusion of a colloid (and blood if indicated), administration of analgesics, and nasogastric intubation and suction. Should the patient's condition deteriorate, abandon conservative management in favour of laparotomy and possible splenectomy.

Delayed rupture can occur at any time from a few days to 3 weeks after a spleen injury. It is rare in infants and children, but adults who have received non-operative treatment for their spleen injury should be watched for up to 3 weeks in or near hospital.

Splenectomy

The only indication for splenectomy at the district hospital is rupture.

Assessment and preoperative management

Take blood samples for estimation of haemoglobin content and erythrocyte volume fraction, and begin intravenous infusion of saline. Administer analgesics and attend to other injuries in order of priority. Insert a nasogastric tube and begin suction.

Equipment

See tray for *Laparotomy*, Annex 1, and add four sterile 500 ml bottles, each containing 60 ml of 3.8% sodium citrate, in preparation for possible autotransfusion.

Technique

The patient should be given a general anaesthetic with a muscle relaxant. Place the patient supine with a pillow or sandbag under the left lower chest. Open the abdomen through a long midline incision (Fig. 12.2A).

Collect blood for autotransfusion, if feasible, and remove clots from the abdominal cavity. If bleeding continues, squeeze the splenic vessels between the thumb and fingers (Fig. 12.2B), or apply intestinal occlusion clamps. Assess the extent of the splenic injury and inspect the other organs. To examine the hilum of the spleen, it may be necessary to open the lesser sac through the gastrocolic omentum.

At this point, the decision should be made whether or not to preserve the spleen. If bleeding has stopped, it is best not to disturb the area. A small tear with little bleeding can be controlled with 0 catgut mattress sutures and then the abdomen can be closed. This procedure is particularly advisable in infants and children because splenectomy can impair immune responses.

If it is not possible to preserve the spleen, begin mobilization by lifting it into the wound and dividing the taut lienorenal ligament with scissors (Fig. 12.2C). Extend the division to the upper pole. Apply a large occlusion clamp to the adjoining gastrosplenic omentum (containing the short gastric vessels) and divide the omentum between large artery forceps (Fig. 12.2D,E). Ligate the short gastric vessels well away from the gastric wall with 0 thread. Dissect the posterior part of the hilum, identifying the tail of the pancreas and the splenic vessels. Ligate these vessels three times, if possible ligating the artery first, and divide them between the distal pair of ligatures (Fig. 12.2F,G). Now divide the remaining gastrosplenic omentum between several clamps and, finally, divide the anterior layer of the lienorenal ligament.

Make every effort to follow these steps, though this may be difficult when a spleen is badly lacerated. Avoid blind application of forceps and mass ligation of the tissues in the splenic hilum, but if you cannot identify the splenic vessels, you may transfix and ligate the hilum piecemeal, taking care not to include the tail of the pancreas. Drain the bed of the spleen through a lateral stab wound. Then close the abdomen in layers.

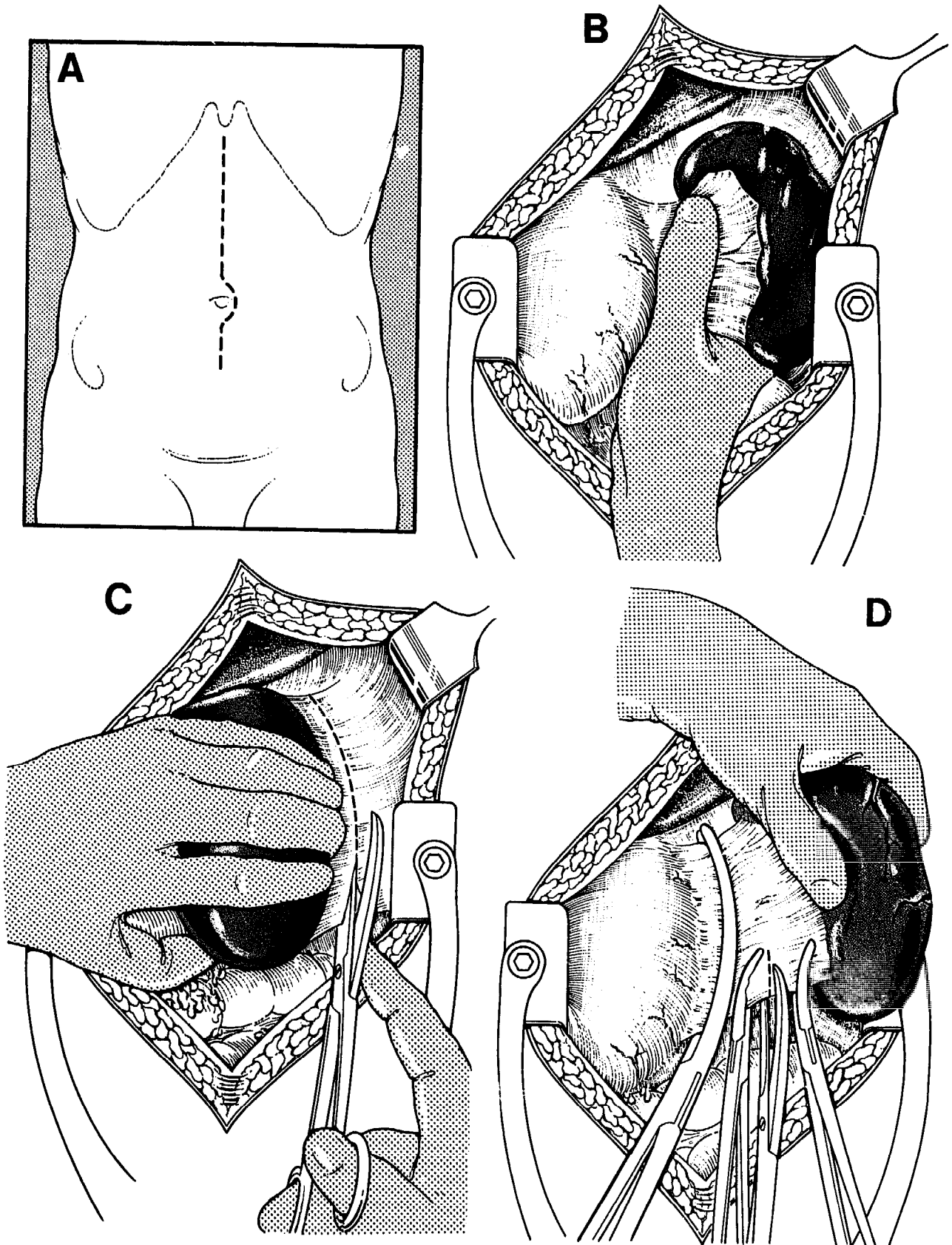


Fig. 12.2. Splenectomy. Site of incision (A); temporary control of bleeding by squeezing the splenic vessels between the thumb and fingers (B); mobilizing the spleen by division of the lienorenal ligament (C); dividing the gastrosplenic omentum between pairs of artery forceps (D).

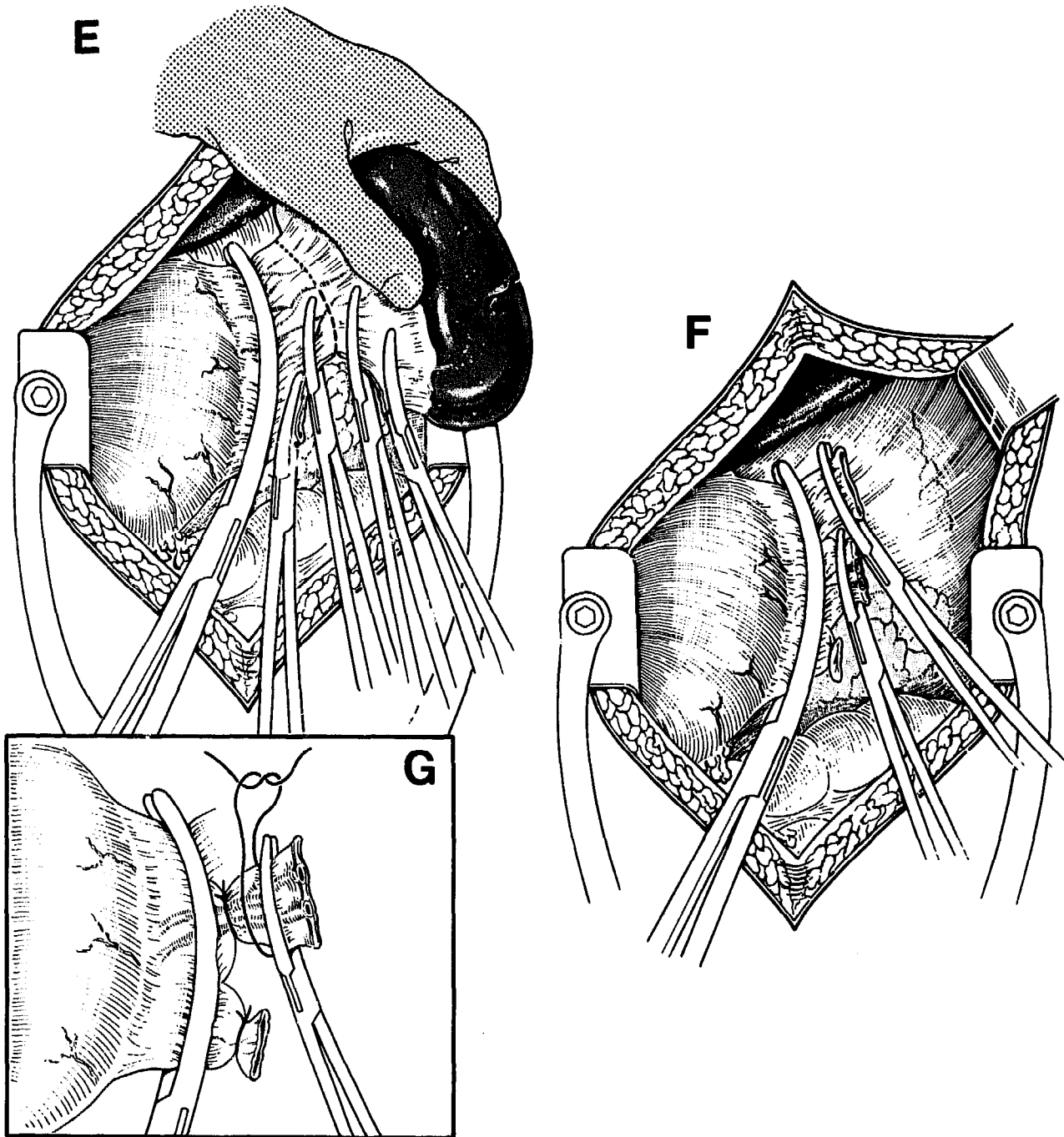


Fig. 12.2. Splenectomy (*continued*). Continuing to divide the gastrosplenic omentum between pairs of artery forceps (E); the splenic vessels are then clamped, divided, and ligated (F, G).

Complications

Complications in the early postoperative period include bleeding and acute gastric dilatation. Control dilatation by nasogastric suction. Later complications include wound infection and even dehiscence, pancreatitis, subphrenic abscess, and deep venous thrombosis. A long-term complication, especially in children, is the reduction of immunity.

13

Small intestine

Resection and end-to-end anastomosis

At the district hospital, the only indications for resection of the small intestine and end-to-end anastomosis are gangrene of the small intestine as a complication of intestinal obstruction, multiple traumatic perforations in a short segment of the intestine, and a tear of the mesentery with ischaemia of a loop of intestine. A decision to resect and anastomose the intestine will therefore be taken during laparotomy or a hernia operation. In the latter case, it is preferable to make a laparotomy incision before proceeding with resection.

Equipment See tray for *Laparotomy*, Annex 1, and add a half-circle atraumatic needle.

Technique The decision to resect part of the small intestine should be taken only after you have inspected the entire gut. A non-viable loop of intestine will be black or deep blue without peristalsis, and the mesenteric veins of the loop will appear thrombosed. There will be no arterial pulsation, and the serosa will have lost its shiny appearance.

Resection Determine the extent of the loop to be resected, including a generous margin of about 2–3 cm of healthy gut on either side (Fig. 13.1A). Hold up the loop so that you can see the mesenteric vessels against the light. Plan to divide the mesentery of the loop in a V-fashion or separate it from the intestinal wall, depending upon the length of the mesentery. Isolate the mesenteric vessels by making blunt holes in the mesentery on either side of each vessel. Doubly ligate each vessel and then divide it between the ligatures (Fig. 13.1B,C). Continue dividing the mesentery until you have isolated the section of gut to be resected.

Apply crushing clamps to both ends of the isolated loop and gently “milk” the normal bowel above and below the loop to move the contents away from the planned points of resection. Once these sections of gut have been emptied, apply light occlusion clamps to the bowel 3–4 cm beyond the crushing clamps. Under the loop of bowel, place a swab that has been soaked in a bland antiseptic, such as cetrimide or acriflavine, and wrung out. Holding the knife blade against one of the crushing clamps, divide the gut (Fig. 13.1D). Clean the exposed part of the lumen and discard the used swab immediately. Temporarily release the occlusion clamp and check to see whether the cut ends of the bowel bleed freely. If so, reapply the clamp. If not, resect the bowel further until it bleeds freely, since the success of the procedure depends upon a good supply of blood to the cut ends of the bowel. Apply the same procedure to the section of gut between the second pair of clamps.

End-to-end anastomosis A sound anastomosis is essential, requiring a careful two-layer technique. Make the anastomosis with continuous sutures of 2/0 chromic catgut on a half-circle

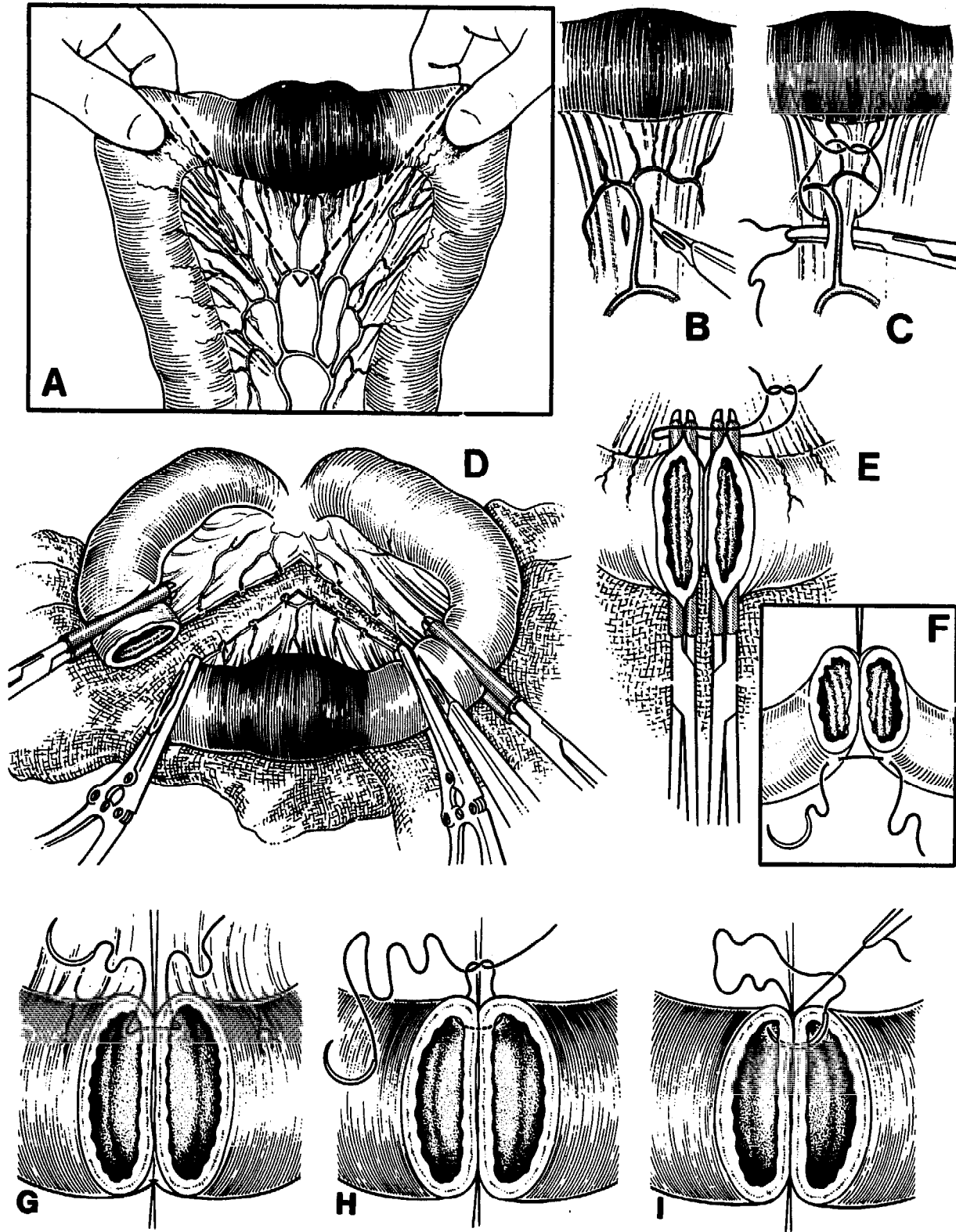


Fig. 13.1. Resection and end-to-end anastomosis of the small intestine. Gangrenous loop of intestine with line of resection (A); ligating the mesenteric vessels (B, C); resection (D); apposition of the two ends (E); inserting stay sutures (F); beginning the anastomosis with a posterior, continuous, all-coats suture (G-I).

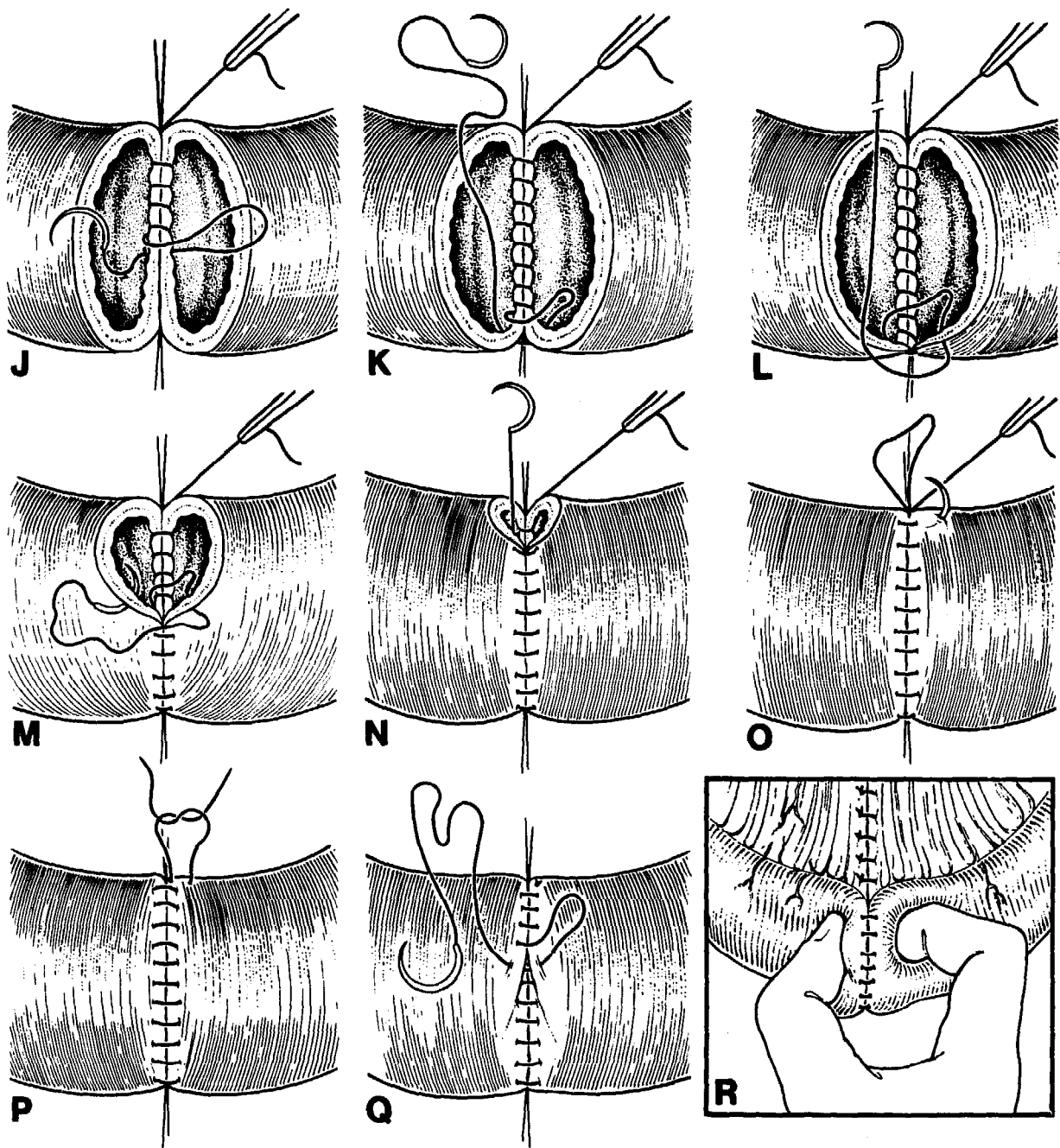


Fig. 13.1. Resection and end-to-end anastomosis of the small intestine (*continued*). Continuing the posterior all-coats suture (J); carrying the suture on to the anterior wall (K-P); burying the first layer of sutures with a second (Q); checking the patency and size of the anastomosis after closing the opening in the mesentery (R).

atraumatic needle. First bring together the occlusion clamps and hold them in position to appose the cut ends of the bowel (Fig. 13.1E). Check the proper orientation of the gut and steady the tissues by joining the cut ends with sero-muscular stay-sutures of 2/0 chromic catgut at either end of the planned anastomosis (Fig. 13.1F).

Begin the anastomosis by inserting the inner layer of sutures. Start at one corner of the bowel, knotting the suture to anchor it (Fig. 13.1G,H). Leave one end long enough to be held with artery forceps. Carry along the other end with the needle as a continuous "over-and-over" stitch, taking up the full thickness of the wall of both gut ends (Fig. 13.1I,J). At the end of the posterior line, pass the needle and catgut out from the mucosa to the serosa on one side and then back from the serosa to the mucosa on the other (Fig. 13.1K). Invert the corner by applying traction in the axis of the suture line, and carry the all-coats stitch back along the anterior wall as an "under-and-under" stitch to invaginate the edge of the bowel (Fig. 13.1L-N). Continue the stitch right back to its origin and knot it to the end that has been left long (Fig. 13.1O,P). The occlusion clamps can now be removed.

Start a new continuous suture near the stay stitch at one or other end of the anastomosis. Bring this along one side of the anastomosis, picking up serous and muscle coats of both pieces of bowel, while covering the previous all-coats suture (Fig. 13.1Q). Tie the continuous suture, if you wish, to the second stay suture, and then turn the bowel over and continue the seromuscular stitch along the other side of the anastomosis back to its origin. Tie it to the long end of the all-coats suture or to the stay suture; then cut the ends of this and the stay sutures. Close the opening in the mesentery with interrupted stitches of 2/0 catgut, taking care not to puncture the blood vessels. Check the adequacy of the stoma by palpation: it should admit at least the tip of the thumb and finger (Fig. 13.1R). Then close the laparotomy incision.

Repair of typhoid perforation of the ileum

In areas of high incidence of typhoid, a preoperative diagnosis of typhoid perforation of the ileum can be expected. Otherwise the diagnosis is likely to be made during laparotomy for peritonitis. Perforations are most likely to occur in the antimesenteric border of the ileum. They may be multiple, so it is important to examine the whole ileum.

Equipment See tray for *Laparotomy*, Annex 1.

Technique Perform a laparotomy with the patient under general anaesthesia.

Bring the affected loop of ileum out of the wound (Fig. 13.2A). "Freshen" the edges of the perforation by trimming, if necessary, and close it transversely with interrupted 2/0 chromic catgut (Fig. 13.2B,C). Insert a further layer of continuous suture of the same material to bury the first suture line (Fig. 13.2D).

Typhoid ulcers that are likely to perforate present as whitish patches on the antimesenteric border of the bowel (Fig. 13.2A). Such lesions should be oversewn with continuous 2/0 chromic catgut (Fig. 13.2E).

Aspirate the peritoneal exudate and insert a drain into the lower abdomen. Close the abdomen in layers, unless the wound is grossly contaminated, when the skin and the subcutaneous fat should be left unstitched for delayed primary closure.

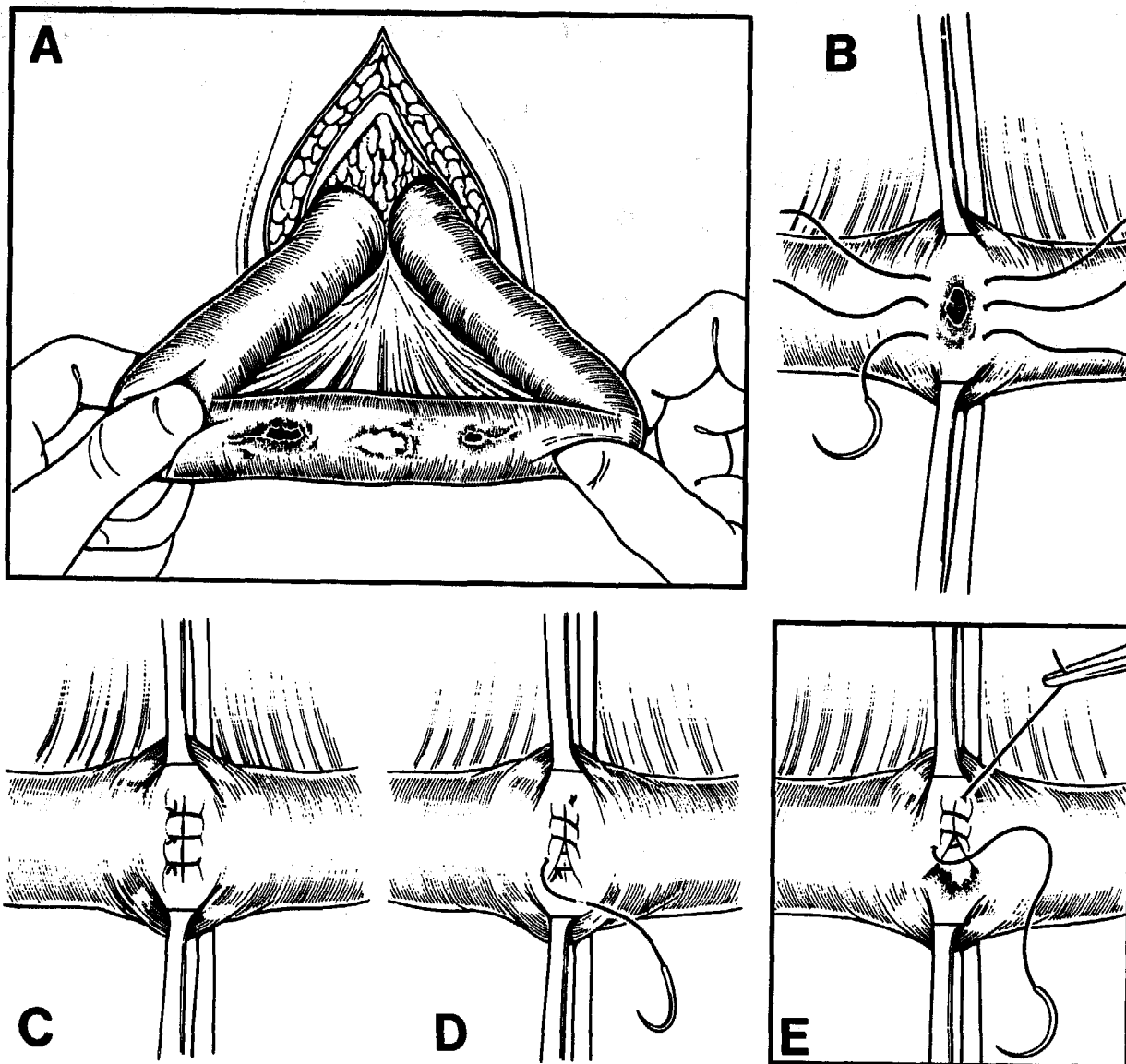


Fig. 13.2. Suture of typhoid perforations of the ileum. A loop of the ileum with two perforations and an area of likely perforation (A); inserting sutures for transverse closure of the perforation after freshening the edges by trimming (B); suturing the perforation in two layers (C, D); oversewing an area of likely perforation with one layer of suture (E).

14

Appendix

Acute appendicitis

In acute appendicitis, the appendix becomes inflamed owing to bacterial invasion of its wall, usually distal to an obstruction of the lumen. Obstruction may be due to faecaliths, seeds, or worms in the lumen; to invasion of the wall by parasites such as amoebae or schistosomes; or even to lymphoid hyperplasia from viral infection. The condition spreads, producing local peritonitis that, without treatment, may progress to abscess formation, gangrene of the appendix, or perforation and general peritonitis.

The appendix may be subject to recurrent attacks of acute but less severe inflammation. The term "recurrent appendicitis" is sometimes used to refer to this condition, though the existence of a truly chronic form of the disease is doubtful.

Diagnosis

The patient presents with a rapidly progressive, central abdominal colic, which soon settles to a burning pain in the right iliac fossa. He or she usually experiences anorexia, nausea, vomiting, and fever. The most important signs are progressive tenderness with rigidity localized in the right iliac fossa. Rectal examination may indicate tenderness on the right side.

Differential diagnosis should include urinary tract infection, renal or ureteric calculi, ruptured ectopic pregnancy, pelvic inflammatory disease, twisted ovarian cyst, ruptured ovarian follicle, mesenteric adenitis, and the early stages of measles.

Measure the patient's haemoglobin level, test the urine for sugar, protein, and red cells, and obtain white-cell and differential white-cell counts.

Treatment

Acute appendicitis is a surgical emergency; the appendix must be removed.

Appendectomy

Preoperative management

Administer analgesics to relieve pain. If the patient has been vomiting, insert a nasogastric tube, aspirate the stomach contents, and begin intravenous infusion of an appropriate fluid while you make arrangements to operate.

Equipment

See tray for *Appendectomy*, Annex 1.

Technique

Before anaesthesia is induced, make a mark on the patient's skin over McBurney's point¹ or over the point of maximal tenderness, if this elsewhere.

¹McBurney's point lies one-third of the way along a line from the anterior superior iliac spine to the umbilicus.

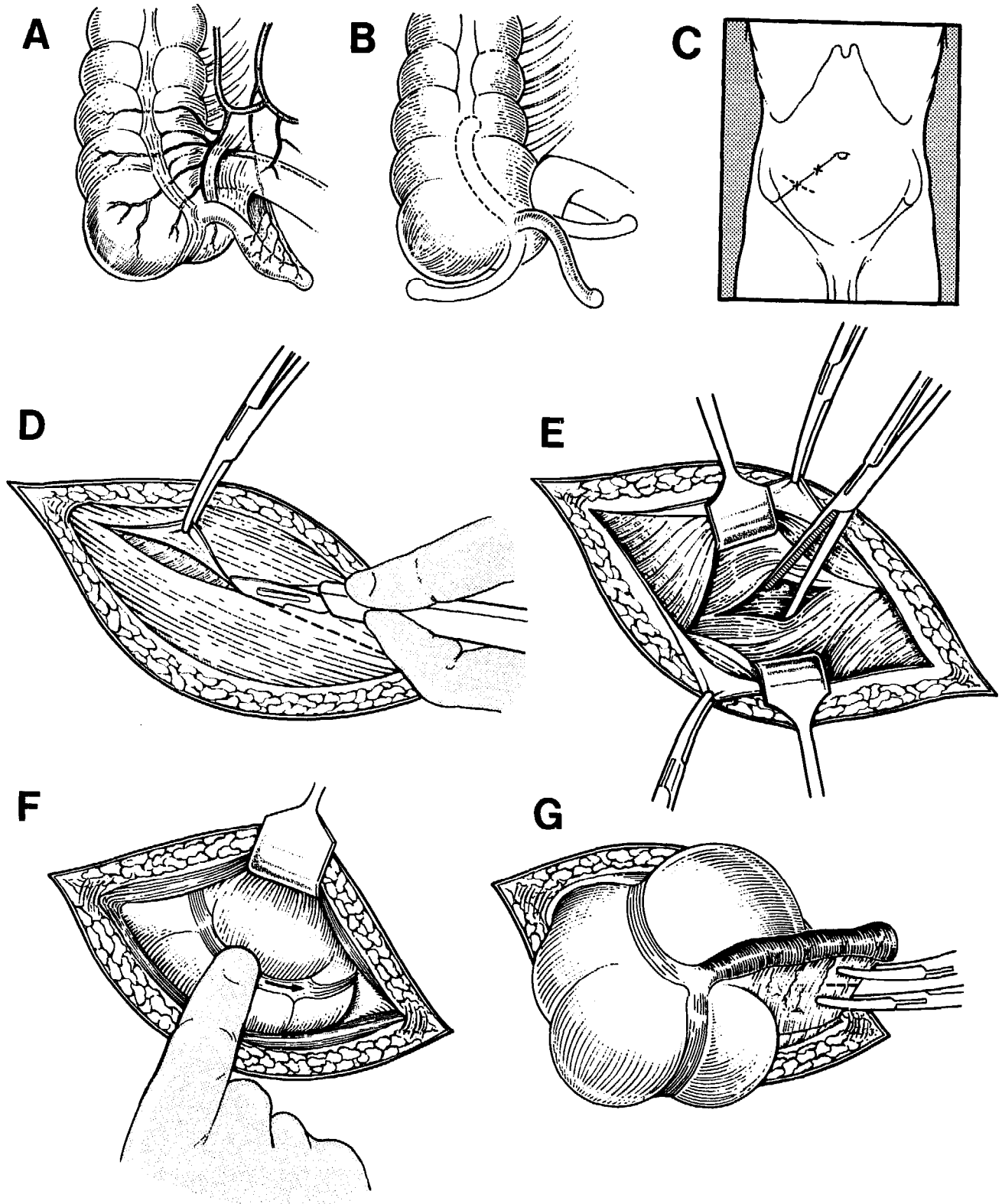


Fig. 14.1. Appendicectomy. For details see page 132.

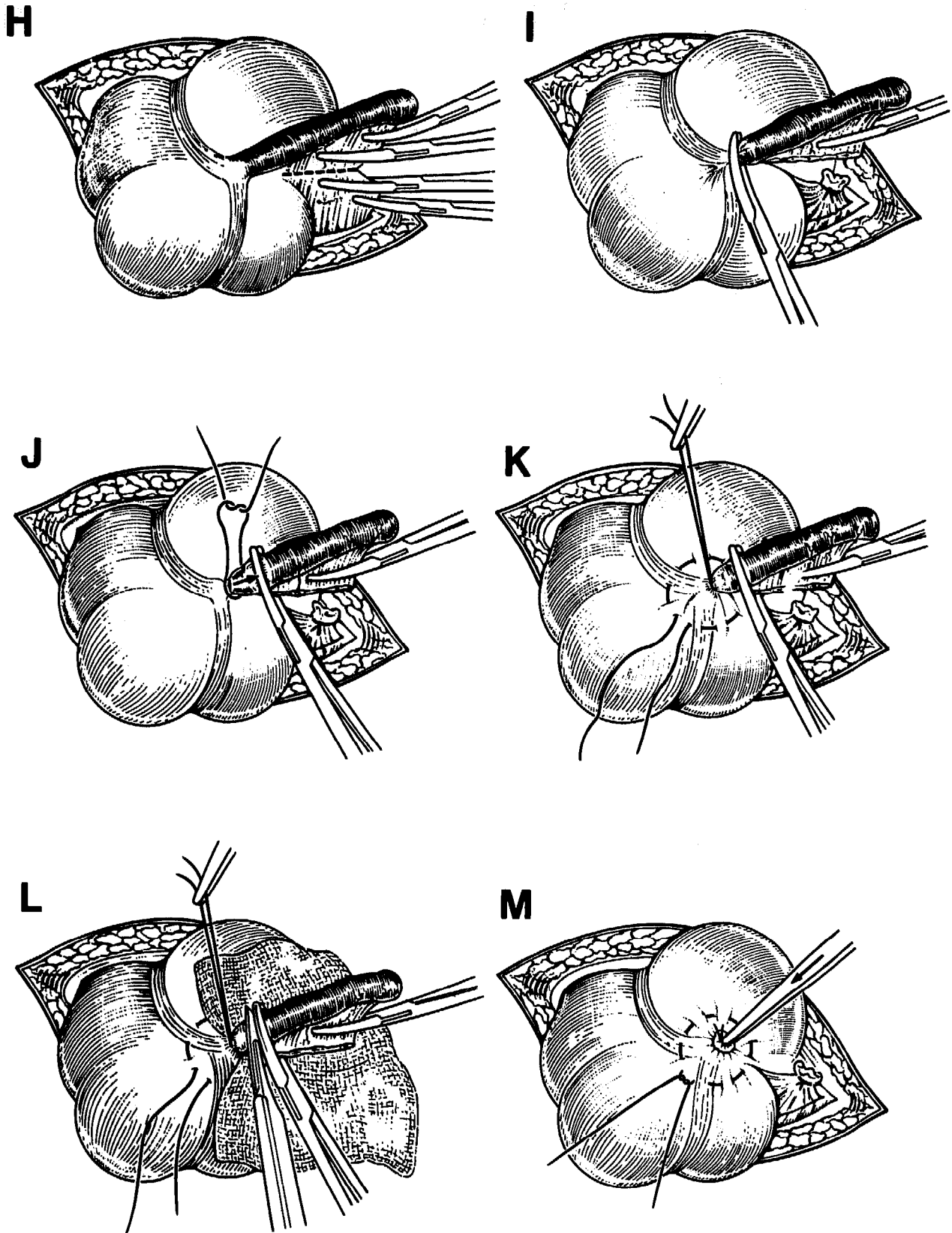
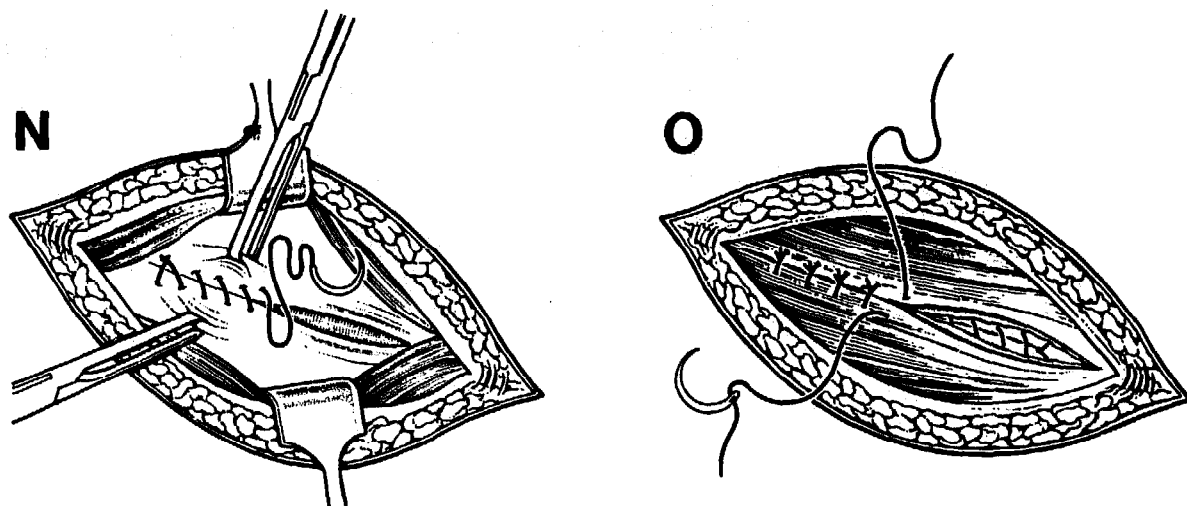


Fig. 14.1. Appendectomy. Anatomy in the region of the appendix (A); possible variations in the position of the appendix (B); centring the incision over McBurney's point (C); incision of the external oblique aponeurosis (D); separating the muscles along the lines of their fibres (E); using the tanniae coli to locate the appendix (F); removing the appendix, starting with the division of the mesoappendix (G-L); invaginating the stump (M); closing the wound (N, O).



The patient should then be given a general anaesthetic with a muscle relaxant and should be placed in a supine position. Centre an 8–10 cm incision in a crease over the point you have marked on the skin (Fig. 14.1C). Deepen the incision to the level of the external oblique aponeurosis, and cut through this in line with its fibres (Fig. 14.1D). Split the underlying muscles along the lines of their fibres using blunt dissection with scissors and large straight artery forceps (Fig. 14.1E). Make a “gridiron” incision by splitting and retracting the muscle layers until the extraperitoneal fat and the peritoneum are exposed in the wound. Lift the peritoneum with two pairs of artery forceps to form a tent and squeeze this with the fingers, to displace and thus avoid injury to any underlying viscera. The peritoneum can now be incised between two pairs of artery forceps.

Aspirate any free peritoneal fluid, and take a specimen for bacteriological culture. If the appendix is visible, pick it up with non-toothed forceps (with care, as the inflamed appendix is friable) and deliver it into the wound. The position of the appendix will be variable (Fig. 14.1A,B), so it is most easily located by following the taeniae coli to the base of the caecum and then lifting both caecum and appendix into the wound (Fig. 14.1F). Blunt dissection may be necessary to expose the base of the appendix.

Divide the mesoappendix, which contains the appendicular artery, between artery forceps close to the base of the appendix. Ligate it with 0 chromic catgut (Fig. 14.1G–I). Clamp the base of the appendix to crush the wall and reapply the clamp a little further distally (Fig. 14.1I,J). Ligate the crushed appendix with 2/0 chromic catgut. Cut the ends of the ligature fairly short and hold them with forceps to help invaginate the appendix stump. Insert a purse-string suture of 2/0 catgut in the caecum around the base of the appendix (Fig. 14.1K). Divide the appendix between the ligature and the clamp, and invaginate the stump as the purse-string is tightened and tied over it (Fig. 14.1L,M).

Close the wound in layers, using continuous or purse-string 2/0 chromic catgut suture for the peritoneum; interrupted 0 chromic catgut stitches for the split muscle fibres; interrupted or continuous 0 chromic catgut stitches for the external oblique aponeurosis; and finally interrupted 2/0 nylon for the skin (Fig. 14.1N,O). If there is any doubt about the severity of inflammation or a possibility of wound contamination, close the external oblique aponeurosis with No. 1 nylon and lightly pack the skin and subcutaneous layers with dry gauze for delayed primary closure.

The problems encountered by the inexperienced doctor performing appendectomy often result from *too small an incision*, which leads to inadequate exposure of the operating field. If delivery of the appendix and caecum through the wound is difficult, enlarge the incision by opening the edge of the rectus sheath medially or by cutting the fibres of the internal oblique and the transversus abdominis muscles laterally in the line of the incision.

If the appendix is adherent and retrocaecal, the caecum should be mobilized and the appendix excised in a retrograde manner: ligate and divide the base of the appendix first, invaginate the stump, ligate the vessels, and then remove the appendix.

Appendicular abscess

Appendicular abscess is a complication of acute appendicitis. The patient experiences lower abdominal pain, maximal on the right side, and fever. Locally there is a tense, tender, globular, and possibly fluctuant mass. Needle aspiration may confirm the presence of pus.

Carry out the blood and urine tests specified for patients with acute appendicitis.

Treat the abscess by incision and drainage as an emergency. Appendectomy may later be necessary, but because postinflammatory scarring is likely to make the operation more difficult, the patient should be referred.

Appendicular mass

An appendicular mass is an inflammatory swelling of the appendix, caecum, omentum, and distal part of the terminal ileum. It is accompanied by a variable degree of inflammation of the local abdominal wall. A loop of small intestine may also be involved. The condition can either resolve slowly or spread with increased inflammation, pus formation, and peritonitis.

The patient suffers fever and pain localized in the right iliac fossa, where there is a rounded, firm, and tender mass. The overlying skin may be inflamed.

Carry out the blood and urine tests specified for patients with acute appendicitis.

Treatment

The aim of treatment is to rest the bowel and allow the inflammation to resolve. Conservative management consists of bed-rest and the administration of analgesics, antibiotics, and fluids. Start by giving clear fluids orally (or intravenously if the patient is nauseated or vomits), and then give fluid feeds as the patient's condition improves.

A satisfactory response to treatment will be indicated by the patient's general state: an improved appetite, the passage of flatus and stool, and the return of a normal pulse and temperature. The appendicular mass will become smaller, less tender, and better delineated.

If the patient's condition grows worse, abandon conservative management. Perform a needle aspiration and, if pus is present, incise and drain the abscess. If no pus is found, either perform a laparotomy to make a diagnosis or refer the patient.

15

Colon

Colostomy

A colostomy is an artificial opening in the colon through which the intestine is made to discharge its contents at the skin surface. There are three main types:

- the loop colostomy, in which there is an opening in an exteriorized loop of colon (Fig. 15.1A);
- the double-barrelled colostomy, in which the two ends of colon remaining after resection have been brought to the skin surface, adjacent to each other (Fig. 15.1B);
- the end (terminal) colostomy, in which only the proximal cut end of the colon opens at the skin surface, the other end having been closed and left within the abdomen (Fig. 15.1C).

There are only a few indications for establishing a colostomy at the district hospital. A loop colostomy can be used to exteriorize an injured piece of colon or to relieve distal obstruction caused by a carcinoma or, in infants, by anorectal atresia or Hirschsprung's disease. A double-barrelled or terminal colostomy may be indicated after resection of a gangrenous loop of colon, for example in patients with sigmoid volvulus.

Equipment For a planned procedure in neonates and infants suffering from anorectal atresia or Hirschsprung's disease, use the tray for *Minor paediatric operations*, Annex 1. Otherwise use the tray for *Laparotomy*, Annex 1. Add to both trays a catheter or a short length of polythene tubing, a piece of glass rod, and a colostomy bag if available.

Technique The site of the colostomy should normally be decided at laparotomy, with the patient under general anaesthesia.

Loop colostomy The colostomy incision is made separately from the main wound. Make a grid-iron incision (see page 133) in the quadrant of the abdomen nearest to the loop to be exteriorized. The incision should be large enough to accommodate the loop of colon comfortably. The greater omentum can usually be used as a guide to help you find the transverse colon, though in Hirschsprung's disease in children, the sigmoid colon may be so enlarged that it presents in the right upper abdomen.

Bring out the loop of colon without kinking or twisting it (Fig. 15.2A). Make an opening in the mesocolon just large enough to admit a piece of glass rod. Push the

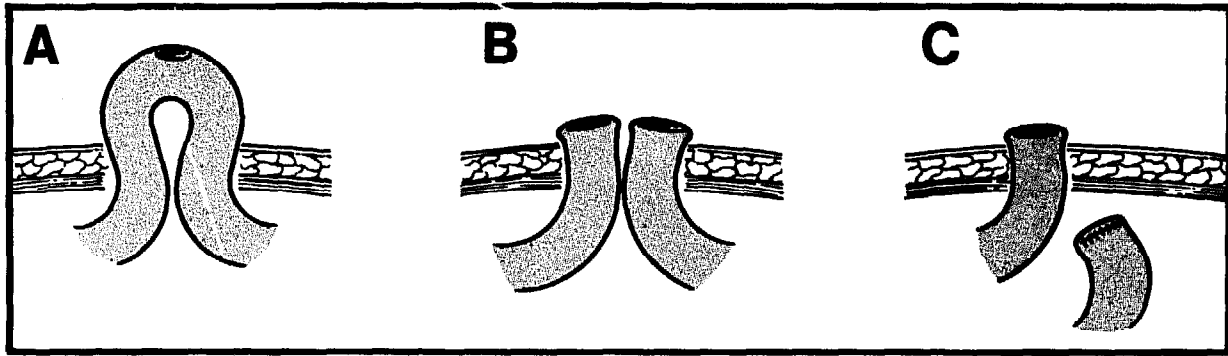


Fig. 15.1. Types of colostomy. Loop colostomy (A); double-barrelled colostomy (B); end colostomy (C).

rod half-way through the opening and attach its ends to the ends of a piece of polythene tubing (Fig. 15.2B,C). As an alternative, insert a catheter through the mesocolon and join the ends with sutures of 2/0 thread. Close the wound around the exteriorized loop of gut (Fig. 15.2C).

The opening in the colon may be made immediately, provided that extreme care is taken to prevent mechanical contamination of the wound. However, it is better to defer making the opening for 8–24 hours, when there is less risk of wound contamination. Make a cruciate incision in the apex of the loop either with a knife or by diathermy (Fig. 15.2D). Pack petrolatum gauze and gauze swabs around the colostomy. If the colostomy is made immediately, apply a further thick layer of gauze or cotton wool over the petrolatum gauze.

Double-barrelled colostomy

Resect the gangrenous loop of colon as described for resection of the small intestine (see page 125). Mobilize the remaining colon, if you have not done this earlier, so that the limbs to be used for the colostomy lie without tension. Bring the two clamped ends of bowel out through a stab wound or gridiron incision and keep them clamped until the laparotomy incision has been closed (Fig. 15.3A). Then remove the clamps and fix the full thickness of the gut edge to the margin of the stab or gridiron wound, approximating mucosa to skin edge with interrupted stitches of 2/0 catgut (Fig. 15.3B,C). If a bag is not available, cover the colostomy with generous padding.

End colostomy

End colostomy is useful if, after a gangrenous loop of colon has been resected, the distal stump is too short to exteriorize, for example after the sigmoid colon and proximal rectum have been removed because of volvulus.

Bring out the proximal end of colon through a stab wound or gridiron incision (Fig. 15.4A). Close the distal stump of colon without further attempt at mobilization using two layers of stitches: an inner, continuous all-coats stitch of 2/0 chromic catgut covered by an outer, seromuscular layer of interrupted 2/0 thread (Fig. 15.4B–F). Drop this end of bowel back into the pelvis. Finally, stitch the proximal end to the margin of the stab wound or gridiron incision.

After-care

Refer all patients for further management and closure of the colostomy. The doctor at the district hospital is unlikely to be involved in the long-term care of such patients, but colostomy bags, if available, can greatly ease even the short-term management of a stoma.

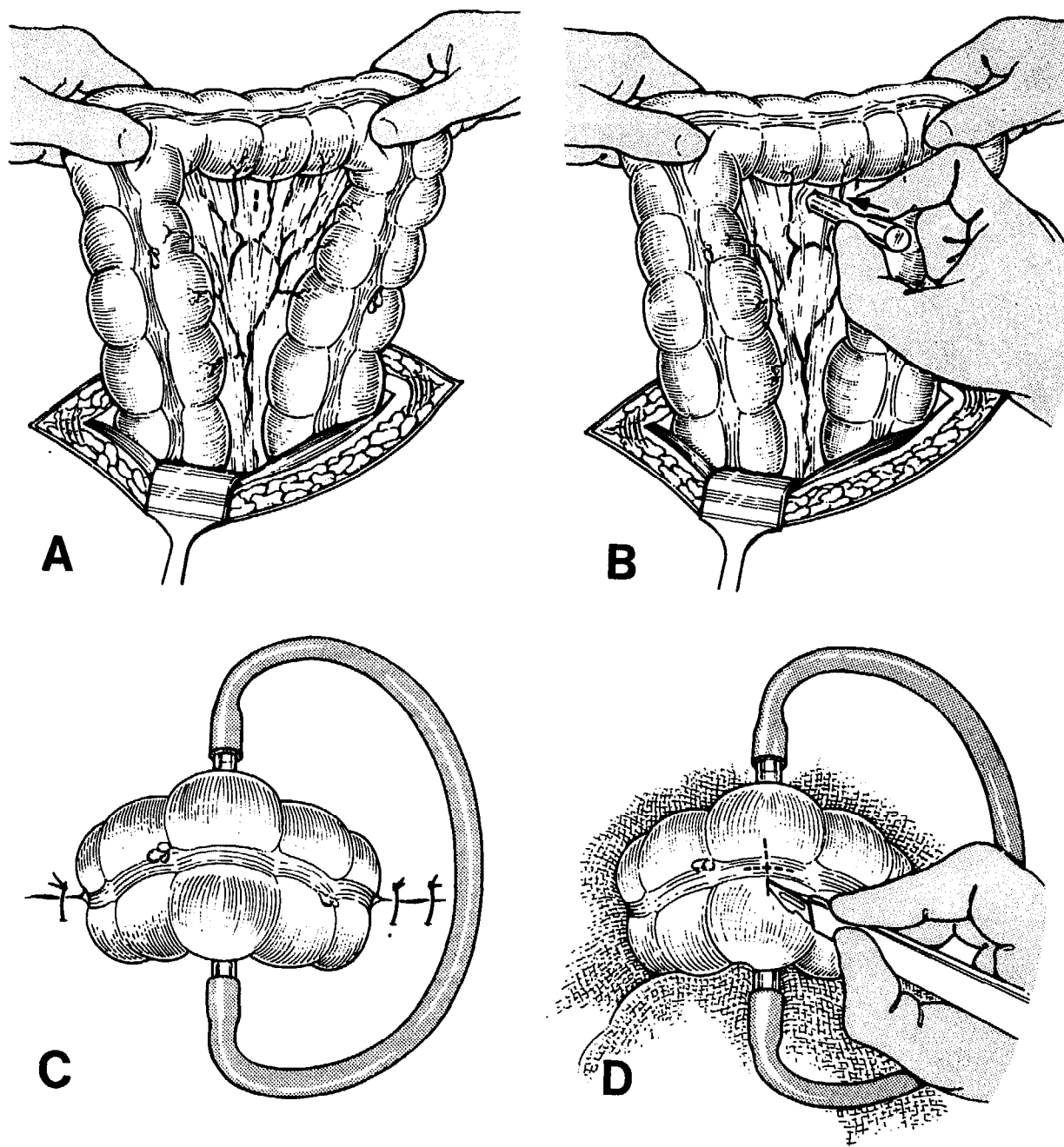


Fig. 15.2. Loop colostomy. Delivering the loop through the wound (A); passing a glass rod through the mesocolon (B); joining the ends of the rod with a rubber tube and closing the wound (C); opening the colon (D).

Sigmoid volvulus

Volvulus is the rotation of a loop of bowel on its mesenteric axis, resulting in a partial or complete obstruction of the lumen (Fig. 15.5A). The most common loop affected is the sigmoid colon. The disease may be acute or subacute and is often recurrent.

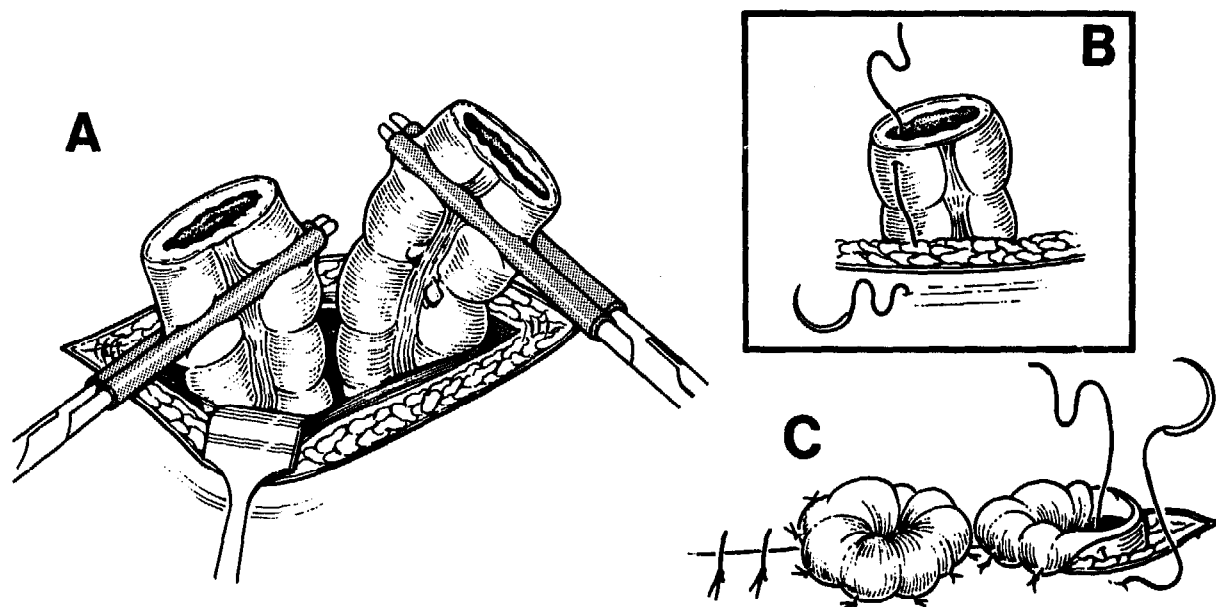


Fig. 15.3. Double-barrelled colostomy. Bringing out the two ends of the colon through a small incision (A); suturing the cut margins of the colon to the skin edge and closing the wound (B, C).

Diagnosis

The patient with acute volvulus experiences a sudden onset of abdominal pain associated with absolute constipation and rapidly progressive abdominal distension. The obstruction is total and, if unrelieved, can progress rapidly to strangulation and gangrene. Nausea and vomiting are late symptoms. The distended abdomen is tympanitic and may have features of peritonitis. Hypovolaemic shock may also be present. The anus and rectum are empty.

The patient with subacute volvulus presents several days or weeks after the start of the disease. He or she experiences abdominal discomfort, rather than pain, with associated gross abdominal distension, visible peristalsis, and audible bowel sounds. There is little or no constitutional disturbance. The anus and rectum are empty. The patient may give a history of previous similar attacks.

If either acute or subacute volvulus is suspected, the most important investigation is a radiographic examination (Fig. 15.5B). Obtain a plain, abdominal radiograph with the patient supine. In cases of subacute volvulus, it will show gross distension of the affected loop of bowel with a loss of haustrations, the dilated loop pointing towards the pelvis in the form of a "bird's beak". Also measure the patient's haemoglobin level and test the urine for sugar and protein.

Preoperative management

Preoperative management consists of the administration of fluids intravenously and nasogastric intubation with suction. In acute cases, resuscitation may be necessary.

Treatment

Acute volvulus is an indication for emergency laparotomy. Untwist the volvulus and, if the bowel is viable, instruct an assistant to pass a rectal tube into the sigmoid colon as you guide it along the distended colon. Fix the tube to the buttocks and close the abdominal wound. The tube should be removed after 3–4 days. In cases of gangrene of the colon, perform resection with double-barrelled or end colostomy (see page 136). After the patient's recovery, arrange for referral for elective colectomy or closure of the colostomy, as appropriate.

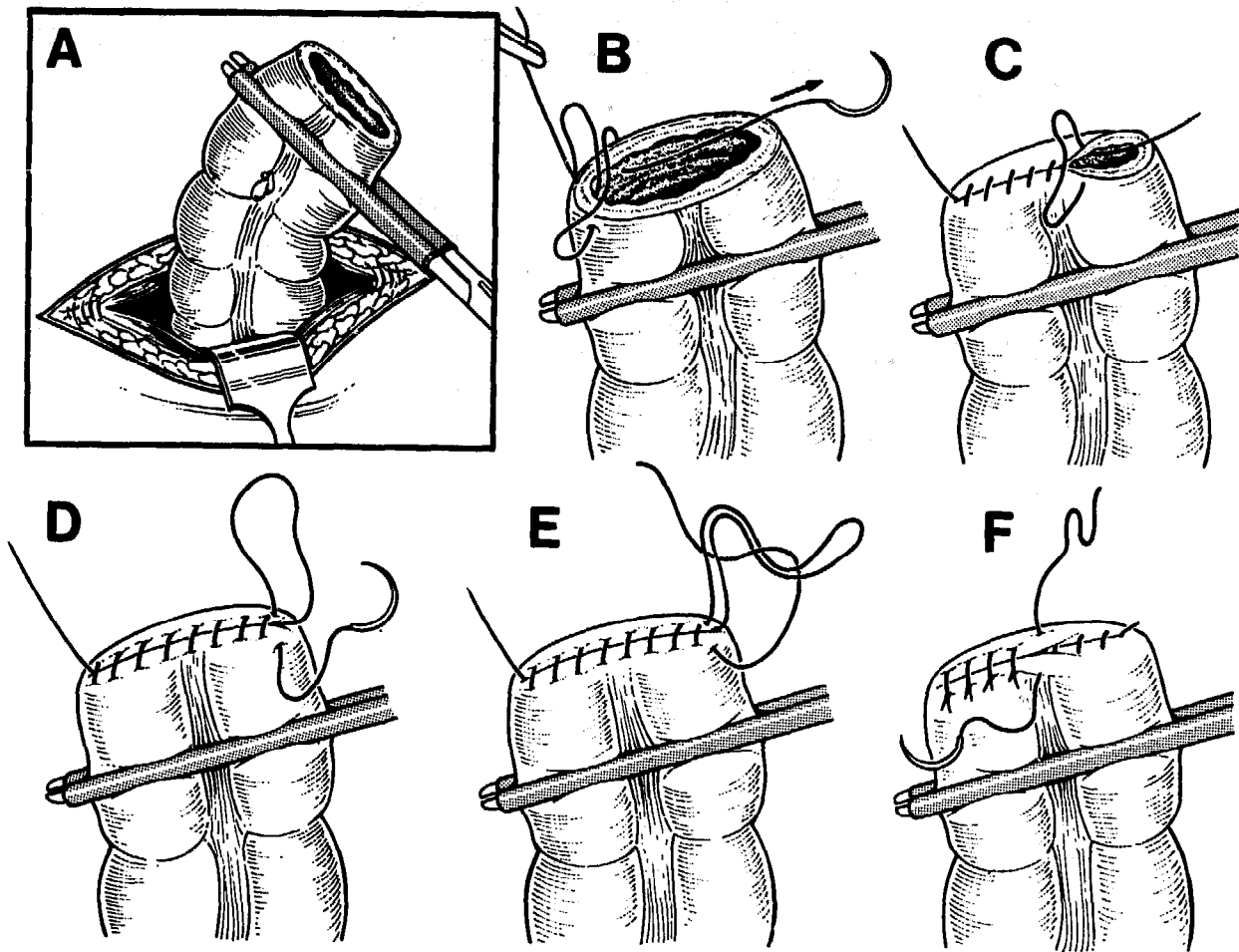


Fig. 15.4. End colostomy. Bringing the proximal stump of colon out through a stab wound (A); closing the distal stump in two layers through the main wound: inserting the first layer of all-coats, continuous suture (B-E), and burying the first layer by inserting a second layer of interrupted sutures (F).

Subacute volvulus does not require emergency reduction, but there should be no delay in treatment. Reduction by rectal tube should be attempted first. Carry out this procedure in the operating room with readiness to perform laparotomy if necessary.

Non-operative reduction of subacute volvulus

Equipment

See tray for *Sigmoidoscopy*, Annex 1, and add a long, large-bore, rectal tube and a large bucket.

Technique

Administer a basal sedative. An anaesthetic should not be given, since the patient's reaction to pain, should the scope be incorrectly placed, is a protection against traumatic perforation of the bowel wall. Put on a waterproof apron and place the patient face down in a knee-elbow position (which may itself cause derotation of the bowel) or in a left lateral position. Without using force, pass the well-lubricated sigmoidoscope as high as it can go into the colon (see page 145). Lubricate the rectal tube and introduce it through the sigmoidoscope until it meets the obstruction marking the lower part of the twisted loop. Gently rotate the tube, allowing its tip to slip into the distal limb. Keep your face well aside

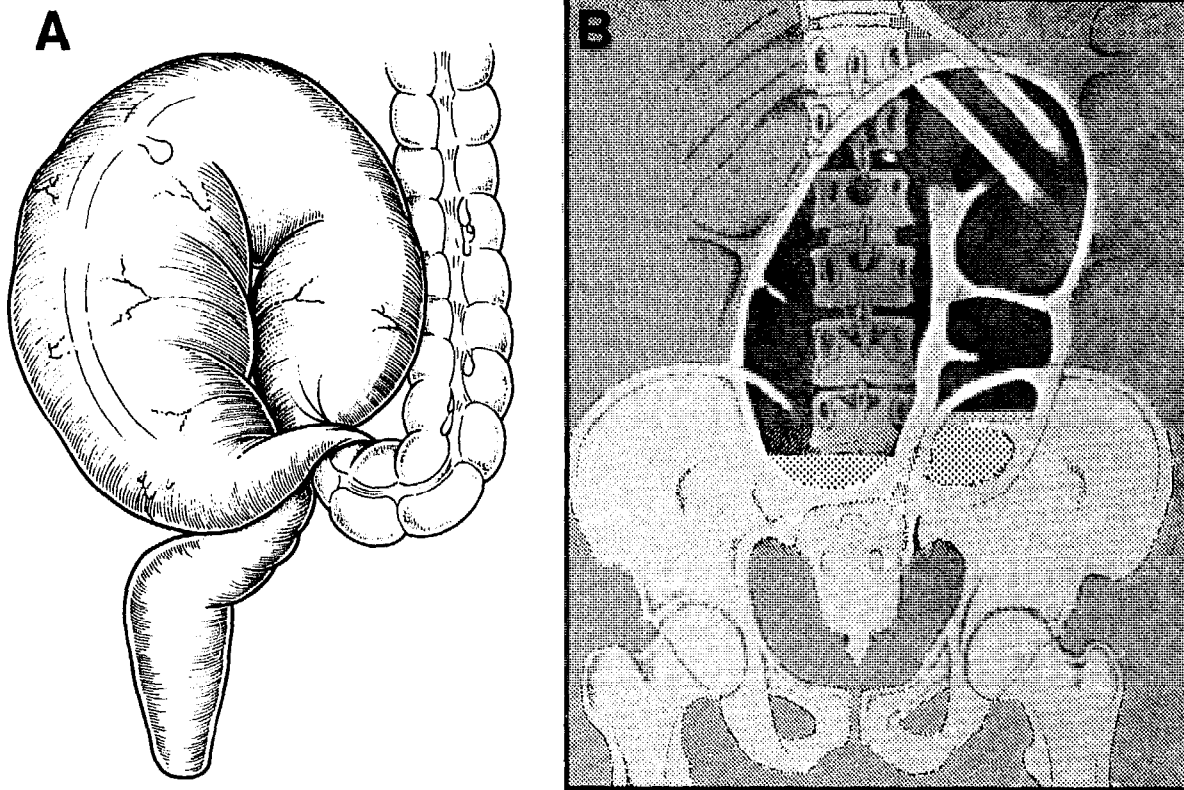


Fig. 15.5. Sigmoid volvulus. A clockwise twist (A); the radiographic appearance (B).

from the tube and the sigmoidoscope at this stage, as successful entry into the volvulus will be evidenced by a sudden profuse outpouring of foul-smelling liquid faeces mixed with gas.

After decompression, withdraw the sigmoidoscope, but leave the rectal tube in position strapped to the perineum and buttock. It should be retained in this position for 3–4 days, if possible. Should the tube be expelled, gently reintroduce it without using the sigmoidoscope. Indeed, sigmoidoscopy is not essential even for the initial introduction of the tube, though it facilitates the procedure.

Should this manoeuvre fail to untwist the volvulus, perform laparotomy immediately.

After-care After recovery, refer the patient for elective sigmoid colectomy.

Anus and rectum

Rectal examination

Digital examination of the rectum (Fig. 16.1) is unpleasant for the patient and extra trouble for the doctor, so it is often omitted from a physical examination — to the patient's disadvantage. The rectum must be examined if the patient has a disturbance of bowel motion such as diarrhoea, constipation, or tenesmus; a history of passing blood, melaena, or mucus through the rectum; discomfort or pain on defecation; or a history of anal swelling or of a feeling of incomplete defecation. Rectal examination should also be performed if the patient is undergoing a full medical check-up, or has gastrointestinal symptoms or signs (even if these are located in the upper abdomen), urinary symptoms (as in prostatic disease), or pyrexia of unknown origin.

Equipment See tray for *Rectal examination (digital)*, Annex 1.

Technique Considerable tact is often needed to convince adults of the necessity for this type of examination. For this reason, the rectal examination should come at the end of the physical examination, which will give the patient time to develop confidence in the doctor. For female patients, it should follow the vaginal examination. Before proceeding, explain the purpose and nature of the examination to the patient. Emphasize that it does not usually hurt.

If the patient has a painful anal condition, apply lidocaine gel to the anal verge before examination. Rarely, regional or general anaesthesia may be necessary for an adequate assessment. If the patient is in pain and cannot cooperate during the examination, the findings may be unreliable.

Place the patient on a couch or bed in a left lateral position (or in a right lateral position if you are left-handed), with the hips fully flexed and both knees drawn up towards the chest. The patient's trunk should be inclined, but not bent, with the buttocks at the edge of the bed and projecting just beyond it (Fig. 16.1D).

Glove the index finger or hand and gently part the buttocks to inspect the perianal region, the natal cleft, and the anal margin. A tightly closed anus suggests spasm, probably due to a painful anal condition. Palpate any lesions in this area. If necessary, apply anaesthetic gel to the anal verge and, after a few minutes, gently introduce a small amount just into the anus. To distract the patient, instruct him or her to take deep breaths with the mouth open as you slowly introduce your lubricated, gloved finger into the anus with the palmar surface turned posteriorly.

Palpate the posterior anal wall and any anal contents against the curve of the sacrum. Rotate the finger anteriorly to allow the tip to detect any bulge or tenderness suggestive of a pelvic abscess (Fig. 16.1E,F). The prostate in the male

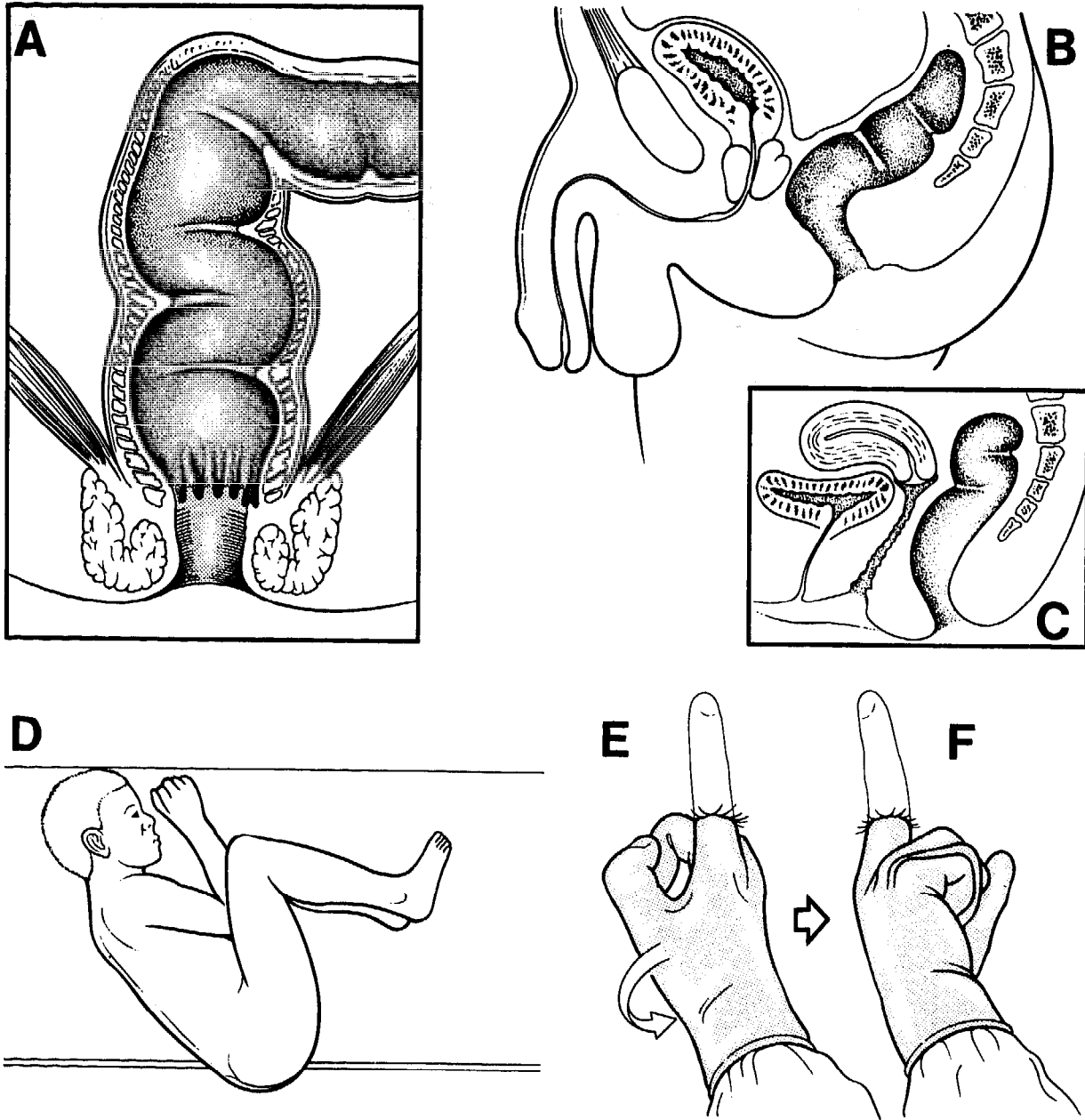


Fig. 16.1. Rectal examination. Anorectal anatomy (A) with the adjacent structures in the male (B) and female (C); position of the patient (D); movement of the finger during palpation of the posterior and anterior anal walls (E, F).

and the cervix in the female will be palpable anteriorly, against the anorectal wall. Determine the degree of mobility of the mucosa over the underlying tissues and structures. Withdraw the finger and inspect it for stains from anal contents, for example stool, mucus, or blood. Take specimens for examination.

On withdrawal of the examining finger there may be passage of watery or mucoid faeces. This is particularly noticeable in patients with Hirschsprung's disease, when there can be a gush of profuse, foul-smelling, liquid faeces.

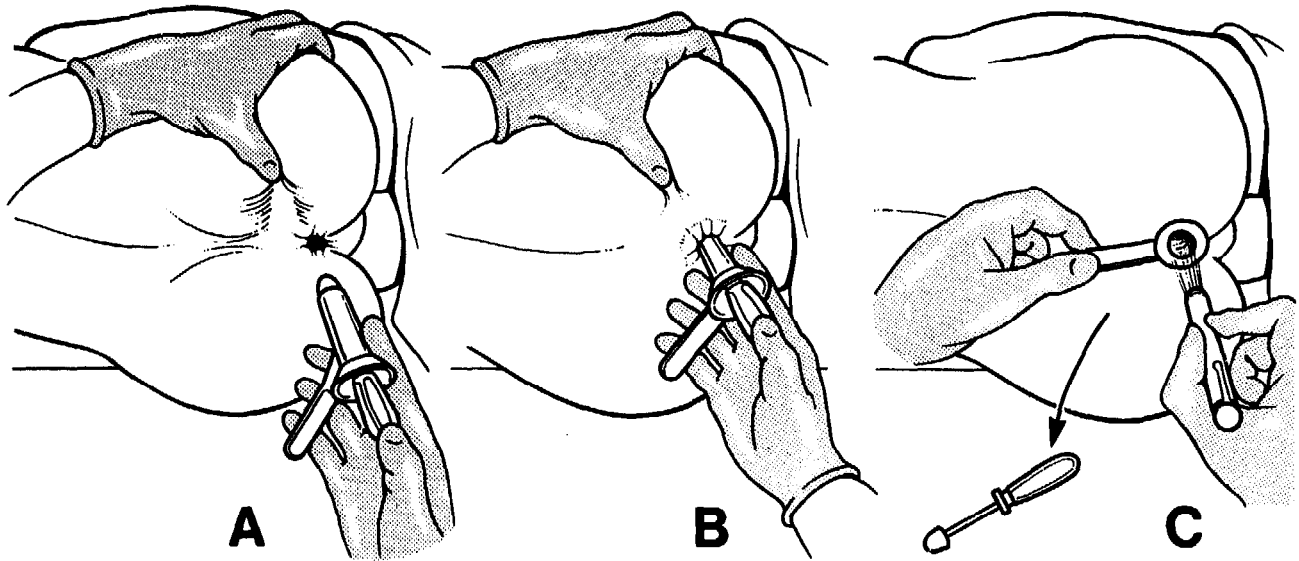


Fig. 16.2. Proctoscopy.

Proctoscopy

The indications for proctoscopy are the same as those for digital rectal examination. The advantage of proctoscopy is that it enables one to view the whole of the anal canal, although only a small part of the rectum is visible at its lower end. Technically, the procedure is really an "anoscopy". Tissue for biopsy may be obtained through the proctoscope if reliable facilities for specimen examination exist.

Equipment See tray for *Proctoscopy*, Annex 1. Good lighting is essential.

Technique It is helpful to obtain the patient's confidence and cooperation. Talk to him or her throughout the examination. Explain the procedure and its purpose, emphasizing that it should cause no discomfort. Do not administer an enema unless the patient is constipated or unless sigmoidoscopy is also required.

Perform a preliminary digital examination. Then, with the patient in the same position, proceed to the proctoscopy to view any lesions that you have just felt. Lubricate and introduce the proctoscope, holding the handle with the fingers and pressing the thumb firmly on the head of the obturator (Fig. 16.2A). This grip will keep the two parts of the instrument assembled. The handle should point posteriorly.

While you introduce the scope to its full length (Fig. 16.2B), instruct the patient to take deep breaths with the mouth open. Remove the obturator and direct the light into the scope (Fig. 16.2C). Mop away or remove any faecal material, mucus, or blood. Align the scope so that the lumen of the gut just beyond is clearly visible. Slowly withdraw the instrument while maintaining its alignment in the gut so that you can view any mucosal lesions, including haemorrhoidal masses or polyps. Note the appearance of the mucosa and assess its integrity. If reliable facilities for specimen examination exist, take a biopsy sample from any obviously or possibly abnormal area under direct vision using special biopsy

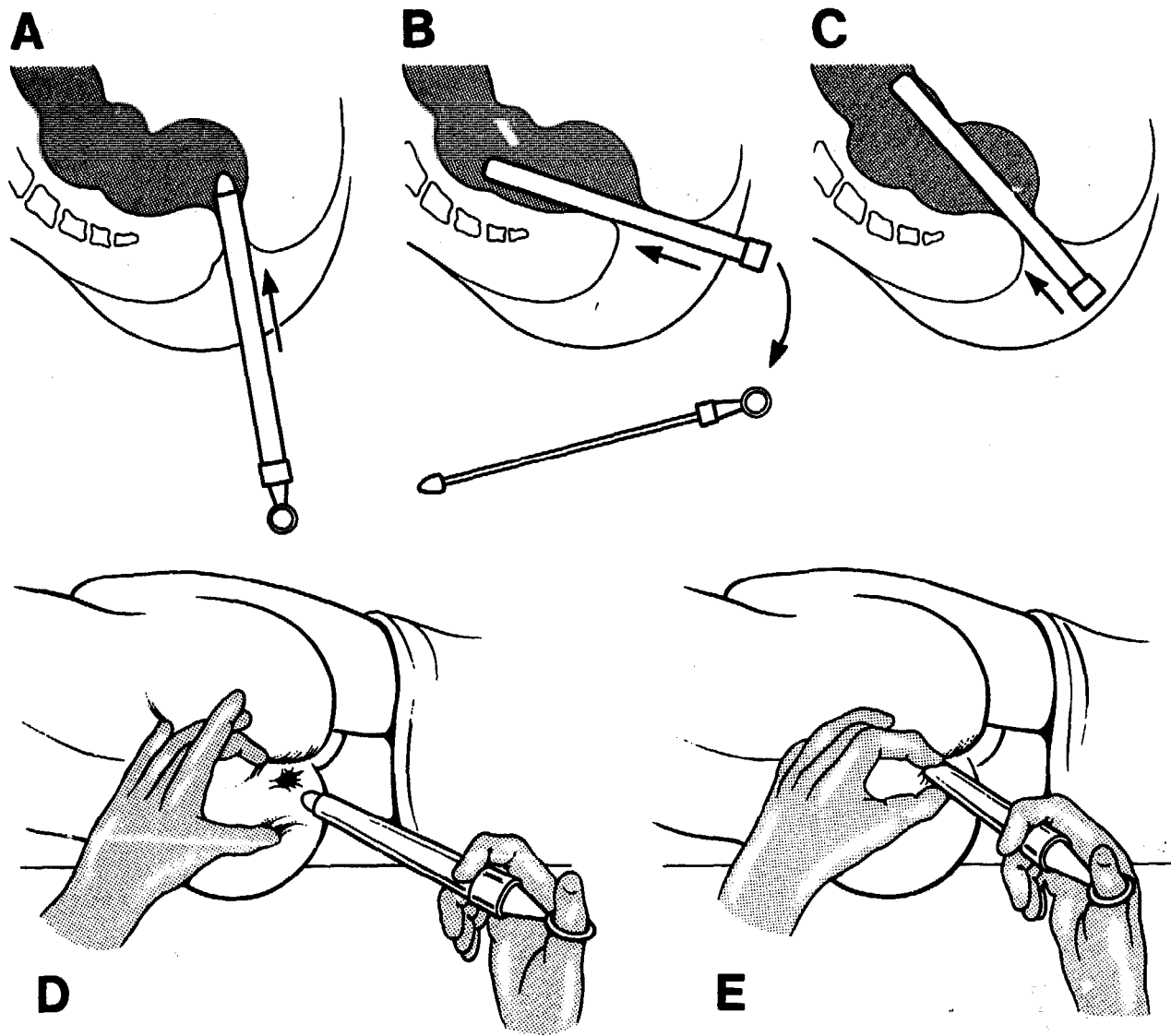


Fig. 16.3. Sigmoidoscopy. Schematic representation of the procedure (A-C); position of the patient and direction of the scope in the early stages of examination (D, E).

forceps. Remove the tissue sample through the proctoscope.¹ Remember that taking a biopsy sample from the rectal mucosa causes some discomfort and that removal of tissue from the anal lining can produce severe pain. At this examination, tissue should not be taken from a haemorrhoidal mass or any other lesion that appears to be vascular.

¹Immediately after removal from the patient, the tissue sample should be fixed by total immersion in formaldehyde saline (10 ml of 37% formaldehyde solution + 90 ml of physiological saline); fixation takes about 48 hours. A plastic, capped bottle with a wide mouth is a suitable container. Write the name of the patient, the site of origin of the biopsy sample, and the date of collection in pencil on a stiff piece of paper, and place this in the specimen bottle. Secure the cap of the bottle with adhesive tape, and place the bottle in a metal tube (or box) together with a summary note containing particulars of the patient, his or her clinical state, the tentative diagnosis, the type of tissue sent, and the investigation requested. Place the tube in a wooden or cardboard box, packed well with non-absorbent cotton wool, and dispatch it. If properly prepared, the biopsy sample will not deteriorate even if it is a long time in transit.

Sigmoidoscopy

Sigmoidoscopy is indicated in patients who have symptomatic colorectal disease but in whom proctoscopy has proved inconclusive or has not revealed any abnormalities. It is also indicated when abnormalities have been detected at proctoscopy, but when additional lesions are suspected, for example in patients with polyposis, or when a biopsy sample from the rectal mucosa is required for the diagnosis of schistosomiasis. In cases of amoebic colitis, sigmoidoscopy is useful in assessing the response of proctocolitis to treatment. It can also facilitate the introduction of a flatus tube to decompress and reduce sigmoid volvulus.

Equipment See tray for *Sigmoidoscopy*, Annex 1.

Technique This examination normally follows a rectal examination and a proctoscopy. Administer a preliminary enema or perform bowel washout. If the patient has "obstinate" constipation, administer a mild laxative 1–2 days before the examination. Check the equipment, particularly the light-head, the eyepiece fitting (window), and the inflation pump (bellows) to ensure that they fit together and that enough light reaches the end of the scope.

In its initial stages, sigmoidoscopy is similar to proctoscopy (Fig. 16.3A), but then the sigmoidoscope is pointed backwards and upwards as it is advanced (Fig. 16.3B,C). Lubricate the sigmoidoscope generously before you start and introduce it with the obturator in position. Hold the obturator firmly to prevent its being dislodged backwards (Fig. 16.3D,E).

After introducing the sigmoidoscope about 10 cm, remove the obturator (Fig. 16.3B). Should there be any obstruction before the sigmoidoscope has been inserted 10 cm, remove the obturator at this point. Then attach the eyepiece, which usually carries the light source and pump connections. To view the gut wall and the bowel lumen, introduce a little air and align the scope. Gently advance the instrument, keeping it accurately within the lumen of the bowel (Fig. 16.3C). Introduce air at intervals to open up the bowel lumen gradually beyond the scope. Should the view be obscured at any time by rectal contents, remove the eyepiece and evacuate the material using dental rolls held firmly with biopsy forceps.

Progressively change the direction of the scope to keep within the lumen. Do not advance the scope unless the lumen of the bowel is in view. The rectosigmoid junction may be difficult to traverse, so the procedure should not be rushed. The junction may relax, if the difficulty is due to spasm, but if it does not relax, make no further attempts to advance the scope.

Never use force in introducing the scope, or in using forceps to take a biopsy specimen from the wall of the bowel, since injury or even perforation of the rectal wall can result. If the patient experiences discomfort during the examination, check for proper alignment of the sigmoidoscope, release air by removing the eyepiece or by disconnecting the pump tubing, and then reassemble the instrument and continue the examination.

Further examination is possible while you withdraw the scope. If necessary, reintroduce the scope and repeat the examination. At the end of each examination, let out the air from the gut before withdrawing the scope.

Haemorrhoids

Diagnosis The main symptoms of haemorrhoids are bleeding on passing stool and prolapse of the varicose masses. Pain is not a significant feature. Haemorrhoids are graded

according to whether they prolapse and, if so, whether the prolapsed mass reduces spontaneously or must be replaced manually. Rectal examination, proctoscopy, and sigmoidoscopy are necessary in diagnosing haemorrhoids and in checking for any associated rectal conditions, for example carcinoma of the rectum.

The main complications of haemorrhoids are anaemia and thrombosis.

Measure the patient's haemoglobin level, and test the urine for sugar and protein. Examine the patient's stool for parasites.

Treatment Many patients benefit from conservative management in the form of a high-fibre diet — to encourage regular, soft, bulky motions — and the local application of an analgesic ointment or suppository.

Patients whose haemorrhoids prolapse (and either return spontaneously or can be replaced) and patients in whom the above regimen has failed to give adequate relief can be treated by manual dilatation of the anus. This is the only form of surgical treatment recommended at the district hospital.

Manual dilatation of the anus

Before proceeding, empty the rectum by administering an enema.

Equipment See tray for *Sigmoidoscopy*, Annex 1.

Technique The patient should be given a general anaesthetic, but without a muscle relaxant, so that you can use the tone in the anal sphincter to judge the extent to which it should be stretched. Perform a digital and then proctoscopic examination to confirm the presence of haemorrhoids (Fig. 16.4A,B).

The success of the treatment depends largely on adequate dilatation of the anus in the region of the "constricting bands". This is achieved by applying pressure with the fingers, but to avoid over-dilatation and other complications, use no more than four fingers; do not employ any instruments. First insert the index and middle fingers of the left hand into the anus and press against the wall to assess the degree of constriction caused by the bands in the anal wall (Fig. 16.4C). Now dilate the anus by inserting the right index finger and pressing it against the anal wall in the opposite direction to the other two fingers (Fig. 16.4D). Insert the middle finger of the right hand and repeat the procedure. Finally insert into the anus a sponge or gauze swab, soaked in a non-irritating antiseptic or saline and wrung out, or a piece of petrolatum gauze. Leave one end of the sponge or gauze protruding.

After-care Administer analgesics when indicated. Give the patient a mild laxative, such as liquid paraffin (mineral oil), to encourage the regular passing of soft, bulky stools. Instruct the patient to sit in warm water, preferably in which some salt has been dissolved, for about 15–30 min at least once a day for 14 days. Treatment with laxatives can be discontinued after about 30 days.

Complications Complications can include haematoma formation, incontinence, and mucosal prolapse. Provided that no more than four fingers are used for dilatation, no significant complications should arise.

Perianal haematoma Perianal haematoma is usually associated with considerable pain. The inflamed area is tense, tender, and easily visible upon inspection of the anal verge as a small, tender swelling about the size of a pea.

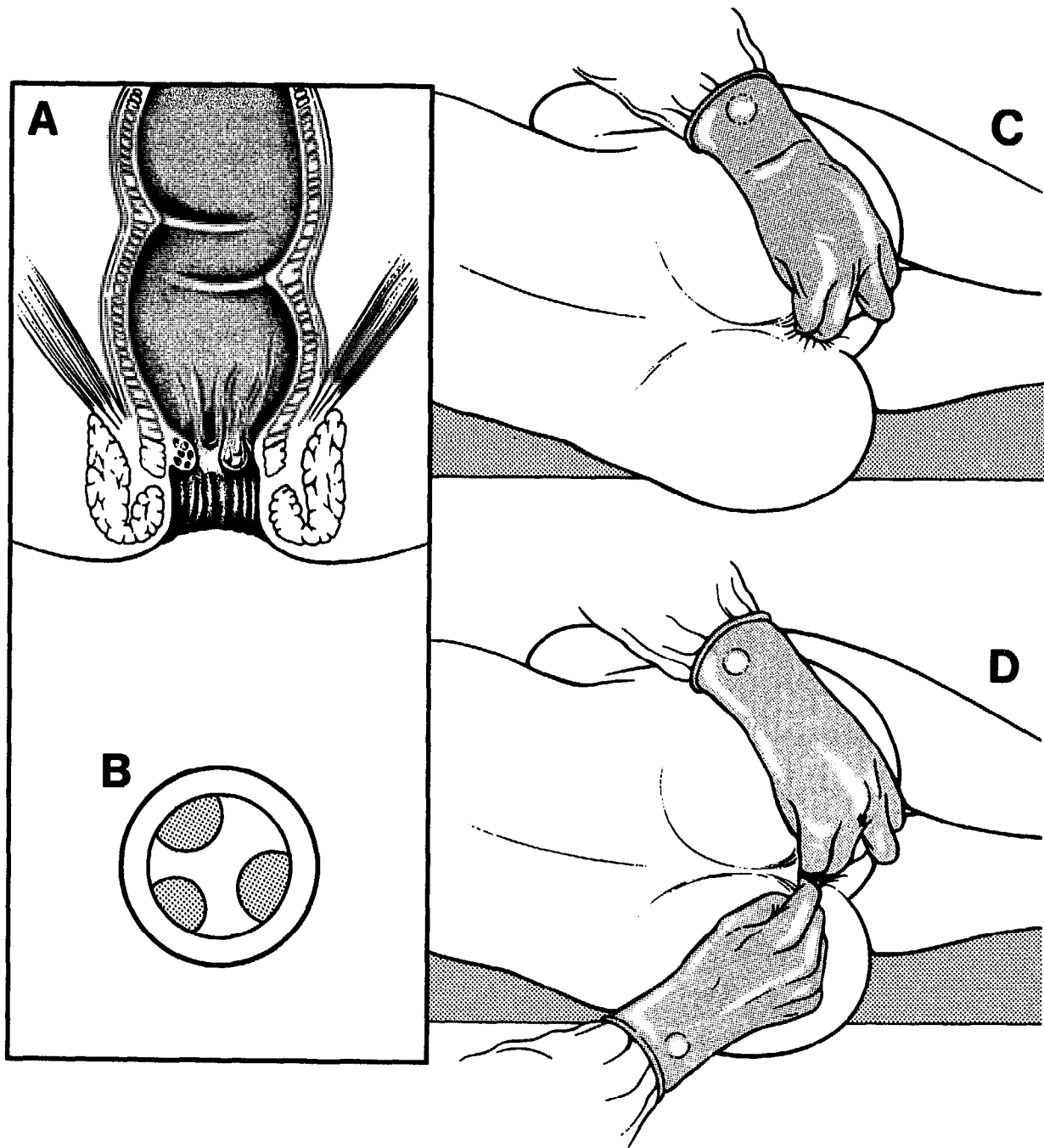


Fig. 16.4. Haemorrhoids. Anatomical site (A); site of haemorrhoidal masses as seen at proctoscopy (B); treatment by dilatation using no more than four fingers (C, D).

Management consists mainly of relieving the pain by local or oral administration of analgesics and by helping the patient to avoid constipation. The lesion will resolve slowly over several days or weeks. Meanwhile the haematoma may spontaneously rupture through the overlying skin, discharging blood clots and providing some pain relief. In the early stages of haematoma formation, surgical evacuation of the clot under local anaesthesia can rapidly relieve pain and discomfort.

Anal fissure

An anal fissure is a tear in the mucosa of the lower anal canal, which is usually associated with intense pain, especially during and just after defecation. Hard stools precipitate and aggravate the condition. Anal fissures can be associated with certain colonic diseases, especially granulomata.

Diagnosis The anus is tightly closed by spasm, so that the application of a local anaesthetic gel or occasionally even general anaesthesia is necessary to allow an adequate examination. The fissure may be acute or chronic, the latter having fibrotic margins.

Measure the patient's haemoglobin level, and test the urine for sugar and protein. Examine the patient's stool for parasites.

Treatment Conservative management is recommended, especially for an acute fissure. It should include prescription of a high-fibre diet and administration of a local anaesthetic ointment or suppository.

A chronic fissure can be treated by manual dilatation of the anus, as described for haemorrhoids.

Incision and drainage of perianal and ischiorectal abscesses

Anorectal abscess is a common and painful condition. It is classified according to its location: perianal, ischiorectal, intersphincteric, submucous, or pelvic. Of these, the first two are the most common, affecting men more often than women.

Assessment and preoperative management

The main symptom is throbbing anal pain. Most patients are unable to sit as a result. A perianal abscess presents as an extremely tender, inflamed, localized swelling at the anal verge (Fig.16.5A). An ischiorectal abscess is indicated by tenderness with a diffuse indurated swelling in the ischiorectal fossa. Fluctuation in either lesion is unusual at an early stage. In patients with perianal abscess, tenderness on rectal examination will be confined to the anal margin, whereas in patients with ischiorectal abscess, there will be deep tenderness.

Measure the patient's haemoglobin level, and test the urine for sugar and protein. If you are in doubt about the diagnosis, perform a diagnostic aspiration.

Begin parenteral antibiotic treatment and administer analgesics. Prepare the patient for incision and drainage of the abscess.

Equipment See tray for *Incision and drainage of abscess*, Annex 1.

Technique The patient should be given a general anaesthetic and be placed in the lithotomy position.

Centre a cruciate incision over the most fluctuant or prominent part of the abscess (Fig. 16.5B). Take a sample of pus for bacteriological examination. Introduce a finger to break down all loculi, and excise the corners of the incision

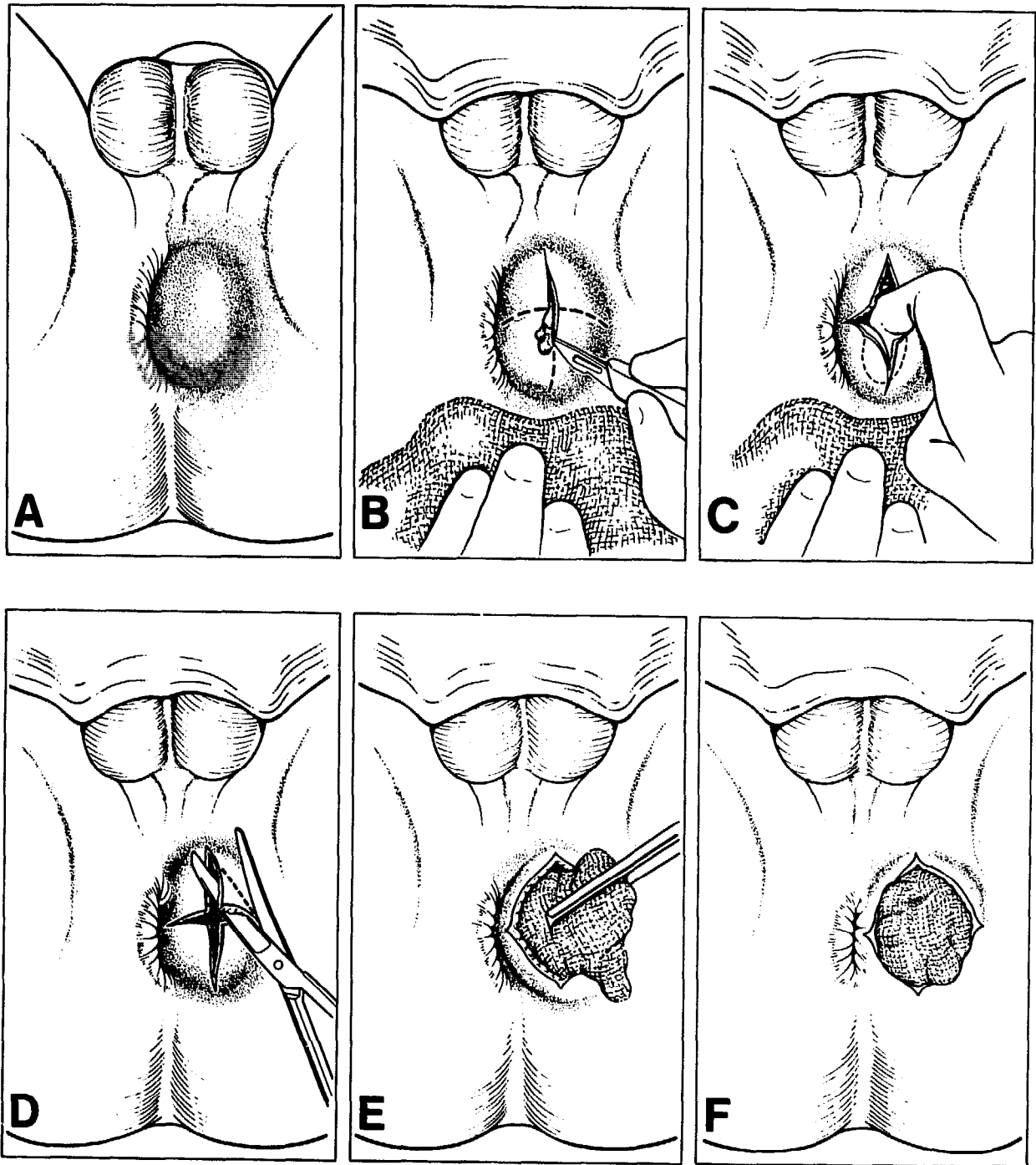


Fig. 16.5. Incision and drainage of perianal abscess. The abscess (A); making a cruciate incision (B); breaking down all loculi to improve drainage (C); trimming the corners of the incision (D); packing the abscess cavity (E, F).

to deroof the cavity completely (Fig. 16.5C,D). Clean the cavity with gauze soaked in a mild antiseptic and wrung out. Pack the cavity loosely with petrolatum gauze, leaving it protruding slightly (Fig. 16.5E,F). Cover the wound with gauze soaked in a mild antiseptic and wrung out, then cotton wool, and finally a T-bandage.

After-care Instruct the patient to bathe the area by sitting in warm saline for 15–30 min twice a day until the wound is healed, and to change the petrolatum pack or gauze after each bath. Do not allow the wound edges to close prematurely. Administer a mild laxative, such as liquid paraffin (mineral oil), daily and continue antibiotic treatment for 5 days. Analgesics are rarely needed after the first 72 hours.

Recurrence of the abscess is often due to inadequate drainage, to premature healing of the skin wound, or to the presence of an anal fistula. Patients with this last condition should be referred.

Rectal prolapse

Adults presenting with rectal prolapse should be referred (for children see page 197).

Herniae

Inguinal hernia

Inguinal hernia is more common in men than in women. There are many hernia sufferers in developing countries who could benefit from elective surgery to avoid the most important complication of hernia — strangulation. Without surgical treatment, strangulation can result in death. Ideally, a hernia should be diagnosed and treated by elective surgery at the district hospital before it becomes enlarged or strangulated. Treatment by the use of a truss is not recommended, as it cannot prevent strangulation.

Hernia repair, though usually straightforward, can be difficult, particularly when the hernia is recurrent or strangulated, but also when the hernia is simple, but large. For this reason, repair of recurrent herniae should not be attempted at the district hospital, except in emergency cases when the hernia is strangulated, and patients with simple hernia should be referred if the swelling is too large to be held in one hand. Also refer obese patients and patients with additional conditions requiring treatment, for example prostatic enlargement.

Inguinal hernia can be indirect or direct. An indirect hernia enters the inguinal canal through the internal ring, while a direct hernia does not. A hernia that reaches the scrotum is almost always indirect.

Diagnosis

Take the patient's history, noting any possible predisposing factors such as chronic cough, dysuria due to urethral stricture or prostatic enlargement, or manual work involving heavy lifting.

The general examination should include a careful assessment of the respiratory, cardiovascular, and urinary systems. Carry out a local examination with the patient both standing and lying down. The hernia presents as a soft swelling in the groin that becomes more prominent when the patient stands up, coughs, or strains; it is manually reducible or reduces itself when the patient assumes a horizontal position. An expansile impulse is evident when the patient coughs. Test for indirect hernia by blocking the internal inguinal ring with a finger and then asking the patient to cough. If the hernia still appears, it is of the direct type. Apart from producing a groin swelling, inguinal hernia may give rise to discomfort or pain.

A strangulated hernia has different features: the patient complains of pain and vomiting; the hernia is tense, tender, and irreducible; and there is no detectable impulse when the patient coughs. The patient may also have features of hypovolaemia.

Always examine the opposite inguinal region and all other orifices where herniae can develop.

Differential diagnosis	Femoral hernia, which is less common, will have its neck below and lateral to the pubic tubercle, whereas the neck of an inguinal hernia will be above and medial to the tubercle. Testicular swelling and hydrocele can be differentiated from an inguinoscrotal hernia in that the superior margins of the former lesions can be palpated in the upper part of the scrotum. These swellings also cannot be reduced and there is no detectable impulse when the patient coughs.
Surgical repair	Patients for elective hernia repair should be selected carefully. Inform a patient who has been doing heavy manual work that the hernia can recur unless heavy work is stopped or unless the patient does not return to work for at least 6 weeks after the operation. Measure the patient's haemoglobin level, and test the urine for sugar and protein.
Assessment and preoperative management	Strangulated hernia is an indication for emergency surgery. In a patient with strangulated hernia, first insert a nasogastric tube and aspirate the stomach contents. Take blood samples for grouping and cross-matching, measure the patient's haemoglobin level, and test the urine for sugar and protein. Administer analgesics and give fluids intravenously.
Equipment	See tray for <i>Hernia operation</i> , Annex 1.
Technique	The technique described here for the repair of inguinal herniae applies to male patients. In female patients the procedure is similar but less complex.
Indirect hernia	<p>The aim of the operation is to reduce the hernia, excise its sac, and repair any defect in the abdominal wall. Just before the patient is anaesthetized, confirm the diagnosis and note on which side of the body the hernia is located. Once anaesthesia has been established, make an incision in the inguinal region in a skin crease 1–2 cm above the inguinal ligament, centring it midway between the deep ring and the pubic symphysis. As an alternative, the incision can be made about 1–2 cm above and parallel to the inguinal ligament, extending from just lateral to the deep ring to the pubic tubercle (Fig. 17.1A). Divide and ligate the veins in the subcutaneous tissue.</p> <p>At this point, the external oblique aponeurosis will be displayed with its fibres running in a downward and medial direction. Incise the aponeurosis along its fibres, holding the cut margins with forceps. Use these forceps to lift and retract the edges while extending the incision to the full length of the wound (Fig. 17.1B,C). (The process of extending the wound also opens the external ring.) Identify the ilio-inguinal nerve and protect it during surgery by holding it away from the operating field.</p> <p>Using blunt dissection (Fig. 17.1D), deliver the spermatic cord together with the hernial sac as one mass and pass a finger around it. Secure the mass with tape or gauze. Using sharp and blunt dissection, separate the sac from the cord (vas deferens and vessels) layer by layer (Fig. 17.1E). Extend the dissection to the neck of the sac at the internal ring, thus exposing the extraperitoneal fat. Open the sac between two pairs of small forceps and confirm its communication with the abdominal cavity by introducing a finger into the opening (Fig. 17.1F).</p> <p>Twist the sac to ensure that it is empty (Fig. 17.1G). Transfix the neck with 2/0 thread, hold the ligature, and excise the sac (Fig. 17.1H–J). Inspect the stump to be sure that it is adequate to prevent partial slipping of the ligature. When the ligature is finally cut, the stump will recede deeply within the ring and out of view.</p> <p>The aim of the repair procedure (Bassini) is to strengthen the posterior inguinal wall by stitching the conjoined muscle and tendon to the inguinal ligament. The process also narrows the internal ring.</p>

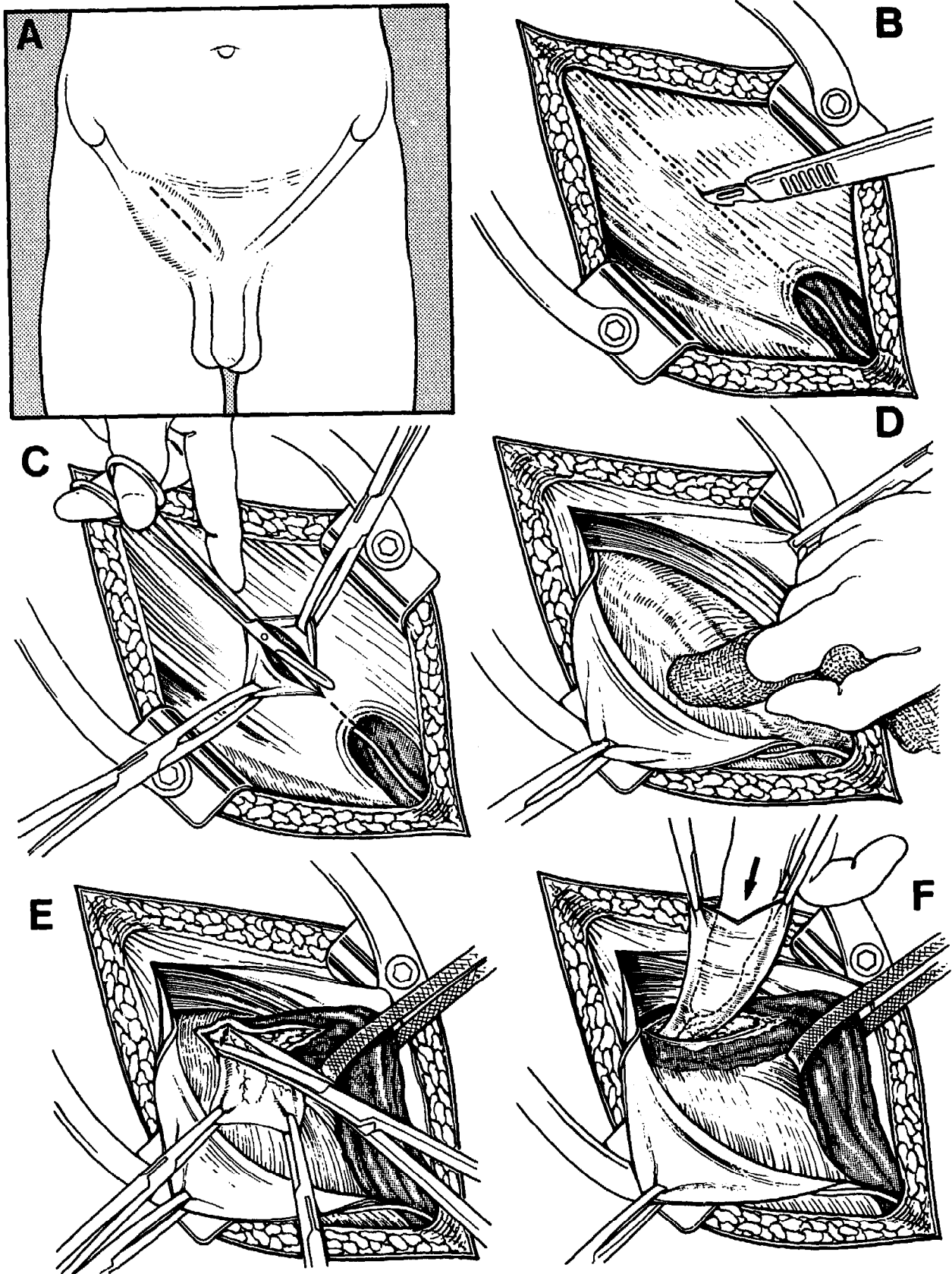


Fig. 17.1. Repair of indirect inguinal hernia. Site of incision (A); incising the external oblique aponeurosis in the direction of its fibres (B, C); delivering the hernial sac and spermatic cord by blunt dissection (D); separating the sac from the cord by combined blunt and sharp dissection (E); opening the sac (F).

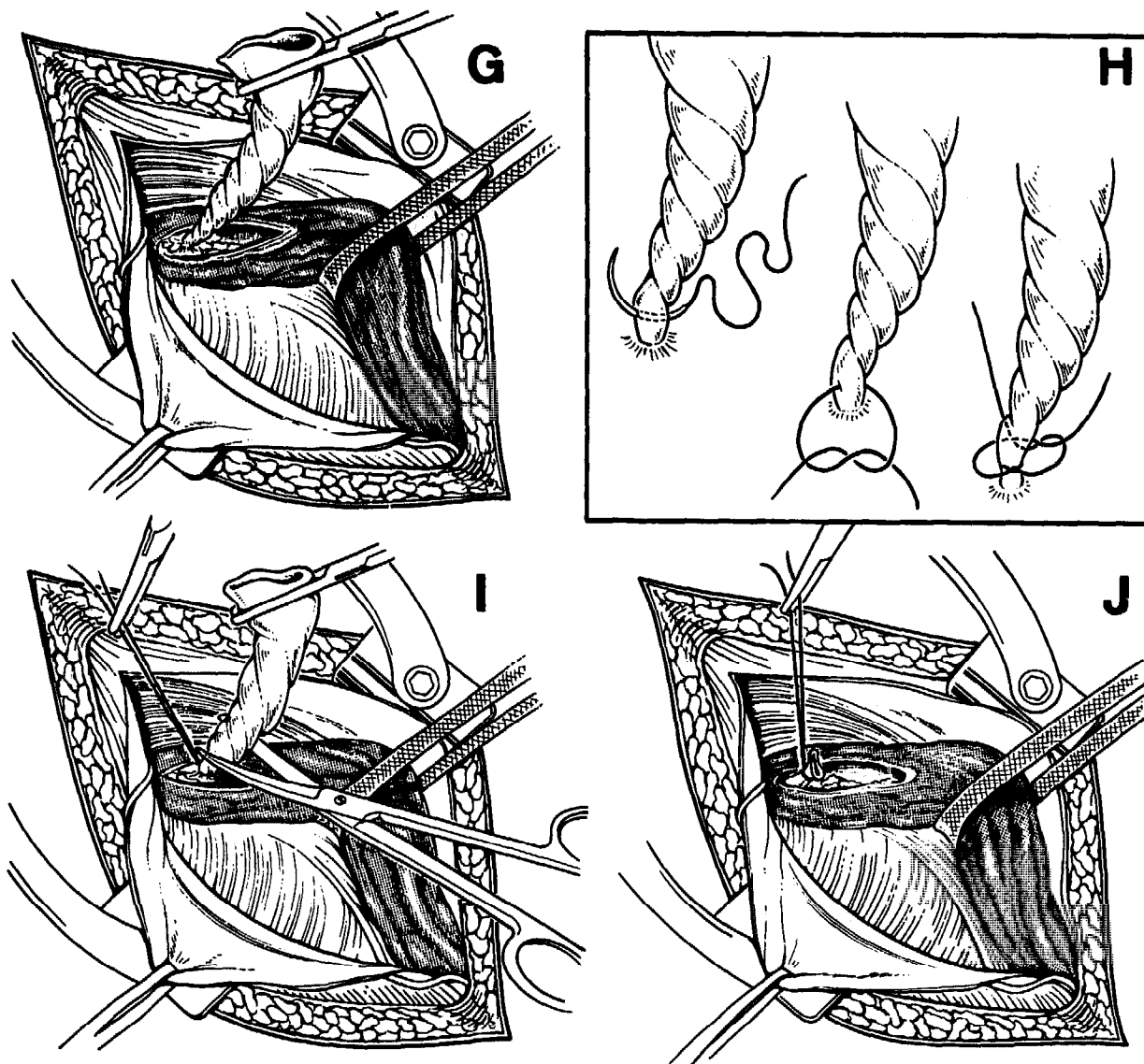


Fig. 17.1. Repair of indirect inguinal hernia (continued). Emptying the sac by twisting (G); transfixing and excising the sac (H-J).

Begin the repair medially using No. 1 thread. The stitches should be inserted through the inguinal ligament at different fibre levels, as the fibres tend to split along the line of the ligament. Insert the first stitch to include the pectineal ligament (Fig. 17.1K); insert the next stitch through the conjoined tendon and the inguinal ligament; and continue laterally to insert stitches in this manner. Leave the stitches untied until all have been inserted (Fig. 17.1L). Test the final stitch adjacent to the ring before you start to tie the stitches; it should just allow the tip of the little finger to be passed through the ring along the cord. Then tie the stitches, beginning medially, and cut the loose ends (Fig. 17.1M). As the final stitch is tied, adjust its tension so that the internal ring just admits the tip of your little finger (Fig. 17.1N). Finally, check the soundness of the repair, inserting additional stitches where necessary.

Close the external oblique aponeurosis with continuous 0 chromic catgut or interrupted 0 thread (Fig. 17.1O). Stitch the skin with interrupted 2/0 thread

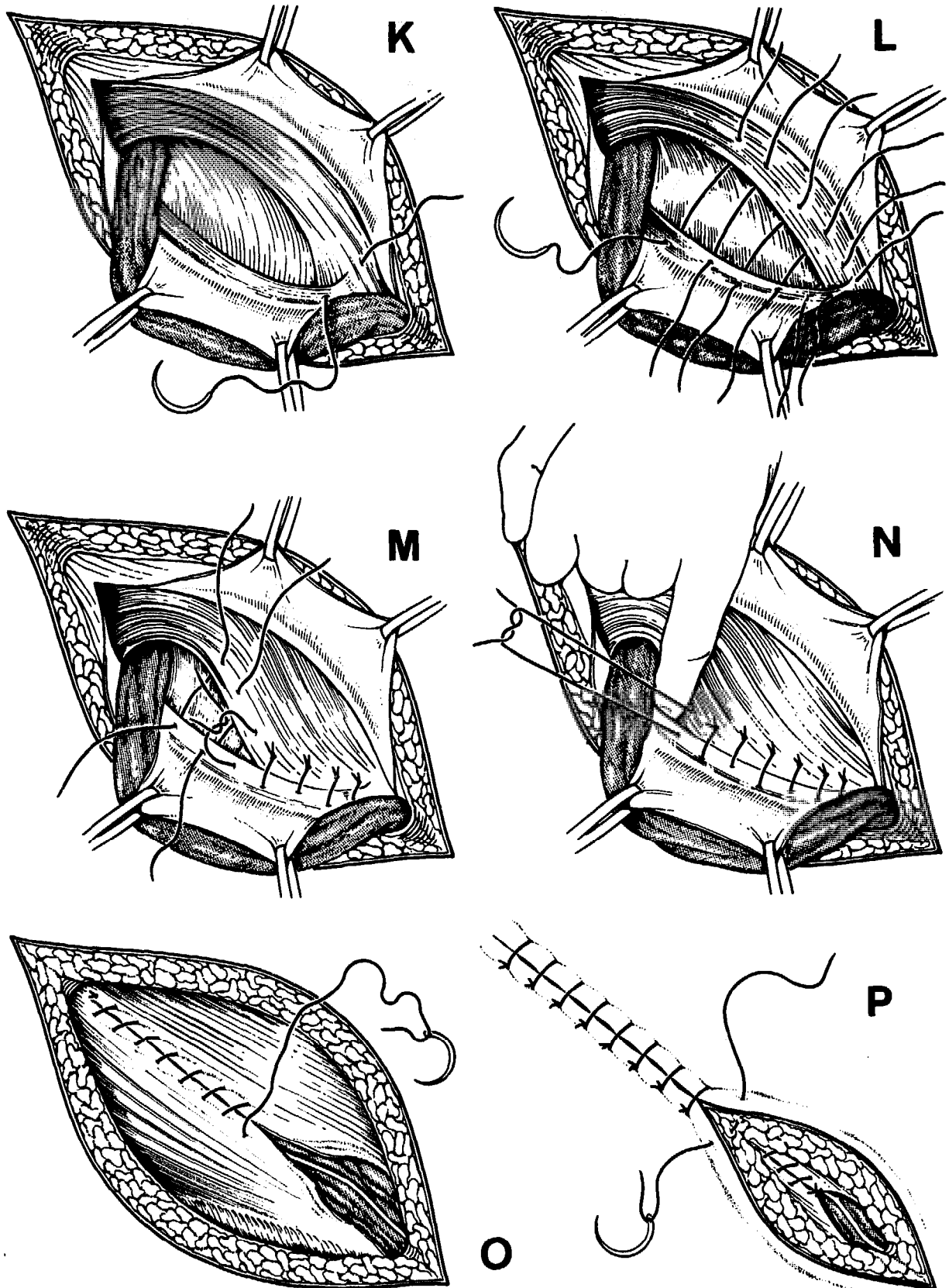


Fig. 17.1. Repair of indirect inguinal hernia (*continued*). Inserting repair sutures so that the first stitch includes the conjoint tendon and the pectineal ligament (K); stitching the inguinal ligament to the conjoint tendon and muscle (L); tying the stitches, beginning medially after all have been inserted (M); the internal ring should just admit the tip of the little finger (N); closing the wound (O, P).

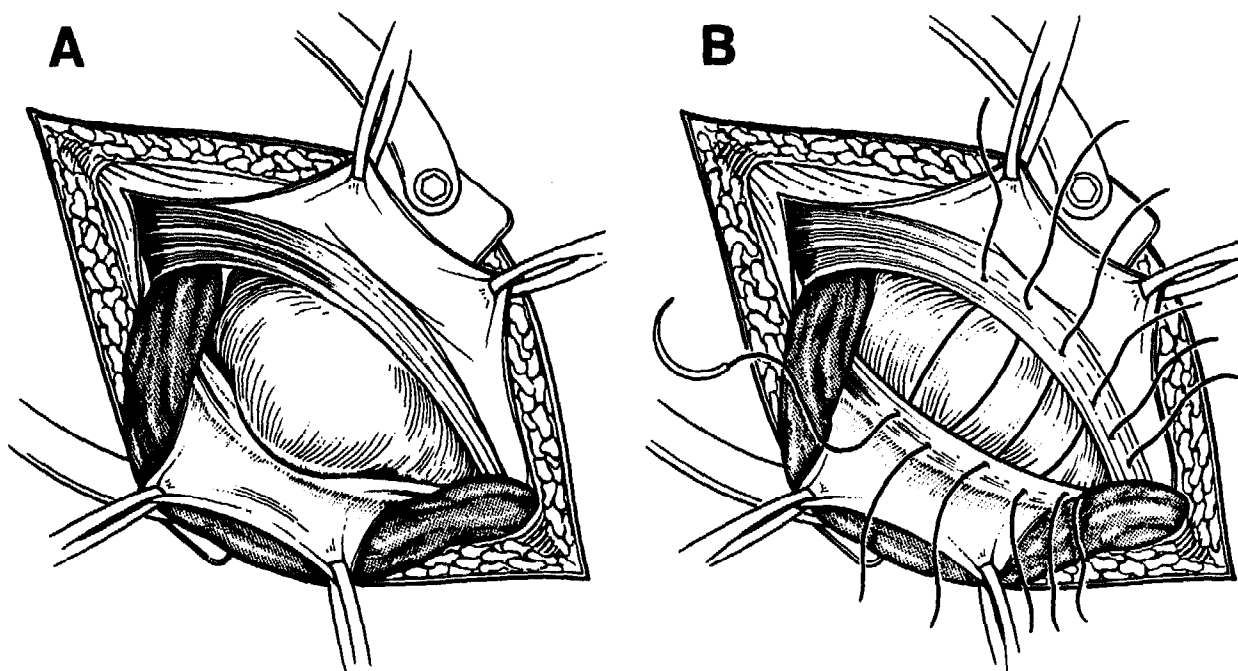


Fig. 17.2. Repair of direct inguinal hernia. The hernia is apparent through the bulging posterior inguinal wall (A); inserting a series of stitches between the inguinal ligament and the conjoint tendon and muscle so that the first stitch includes the pectineal ligament (B).

(Fig. 17.1P). Apply a layer of gauze dressing and hold it in place with adhesive tape.

Direct hernia

A direct hernia will appear as a bulge, often covered by fascia transversalis and with a wide neck in the posterior inguinal wall (Fig. 17.2A). Once recognized at operation, the hernia should be reduced, but the sac should not be opened or excised. Cover the reduced sac by completing the repair of the posterior wall of the inguinal canal as described above for indirect hernia (Fig. 17.2B).

Sliding hernia

A sliding hernia can be encountered in either groin. It is not easy to make a preoperative, clinical diagnosis, but the hernia will become apparent once you open the inguinal canal and the hernial sac. In cases of sliding hernia, part of the gut will appear to be adherent to the inside wall of the sac (Fig. 17.3A) — the caecum and appendix if the hernia is in the right groin, and the sigmoid colon if the hernia is on the left. The colon or caecum (depending on where the hernia is located) actually forms part of the posterior wall of the hernial sac. Rarely the bladder slides to one side.

Excise most of the sac, leaving a rim below and lateral to the bowel (Fig. 17.3B). Close the sac with a purse-string suture (Fig. 17.3C,D). While tying the suture, push the hernial mass up within the deep inguinal ring. If the hernia fails to reduce completely, make a curved incision below and lateral to the caecum to allow the mass to slide back (Fig. 17.3D). The skin incision may have to be extended laterally to improve access. Repair the posterior inguinal wall as described for indirect hernia.

Inguinoscrotal hernia

Attempts to excise the scrotal part of the sac can predispose the patient to developing scrotal haematoma, so it may be safer to transect the sac in the inguinal canal and deal with the proximal part as described for indirect inguinal hernia. For the distal cut edge, merely ensure haemostasis.

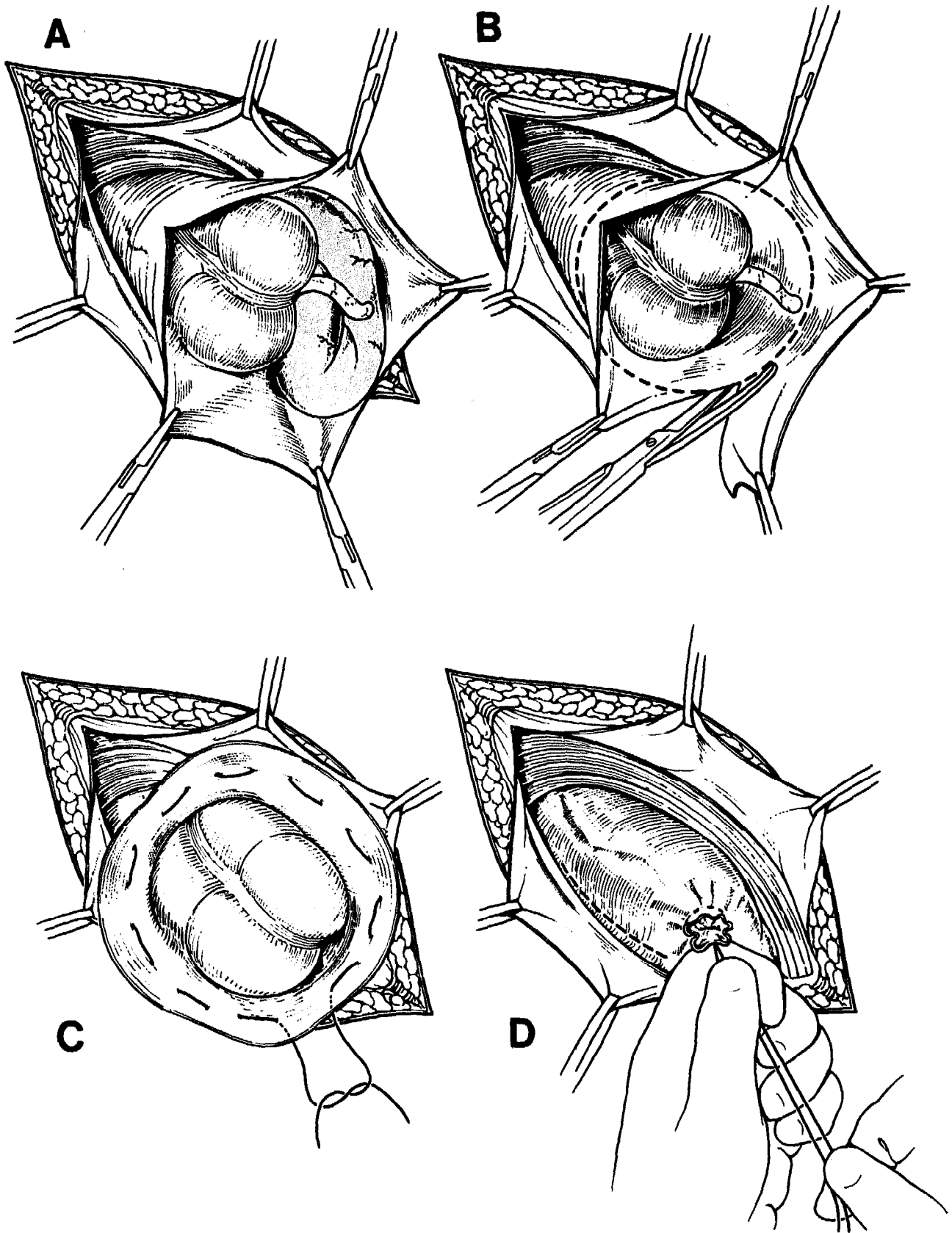


Fig. 17.3. Repair of sliding hernia. The caecum appears adherent to the inside wall of the sac (A); excising the sac (B); inserting and tying a purse-string suture (C, D; dotted line shows site for extra incision to allow mobilization of the caecum).

Recurrent hernia Operate to repair a recurrent hernia only if the hernia is strangulated and the patient's life is in danger; otherwise, refer the patient. Because of previous operations, the inguinal anatomy is often distorted, which complicates repair and makes further recurrence likely.

Open the inguinal canal and relieve the obstruction. Inspect the hernia to assess the viability of the bowel, and proceed accordingly (see section on strangulated groin hernia, page 160). Define tissue planes as clearly as possible by dissection and repair the weak posterior wall of the inguinal canal as described above for indirect hernia. If tissue planes cannot be defined clearly enough for an effective repair, close the wound and refer the patient for elective repair.

Complications The most important complication of hernia repair is recurrence. Numerous factors contribute to recurrence, including a raised intra-abdominal pressure, inadequate previous repair, haematoma, and wound infection.

Femoral hernia

This hernia occurs through the femoral canal and is more common in women than in men. The neck of the hernia lies below and lateral to the pubic tubercle. Inguinal hernia is the main possibility to consider in differential diagnosis. Femoral hernia is far less common than inguinal hernia, but it is an important condition to recognize because it can pass readily to strangulation without complete bowel obstruction, only part of the circumference of the bowel being caught in the femoral canal.

Preoperative investigations should be the same as for inguinal hernia.

Surgical repair

Equipment See tray for *Hernia operation*, Annex 1.

Technique The patient should be given a general or spinal anaesthetic. Centre the incision in the groin over the hernia in a crease about 2 cm below the inguinal ligament (Fig. 17.4A). Deepen the incision through the cribriform fascia, maintaining haemostasis throughout the procedure. The extraperitoneal fat covering the hernial sac will appear under the cribriform fascia. To expose the neck of the hernia, separate the fat from the sac by blunt dissection (Fig. 17.4B).

Define the margins of the femoral canal, but carefully avoid sharp dissection in the region of the lateral margin near the femoral vein. Keep all dissection activity close to the neck of the hernial sac. Open the lateral part of the fundus of the sac between two pairs of forceps (Fig. 17.4C), inspect its contents, and confirm its communication with the abdominal cavity by introducing a finger into the opening. Reposition the contents of the sac in the abdominal cavity (Fig. 17.4D). Excise and transfix the empty and isolated sac at its neck using 2/0 chromic catgut (Fig. 17.4E). Leave an adequate stump, to avoid slipping of the ligature. Inspect the stump and then cut the suture, allowing the stump to recede into the pelvis.

Close the femoral canal with interrupted 0 thread by stitching the inguinal ligament to the pectineal ligament laterally and to the lacunar ligament medially (Fig. 17.4F). Be sure to avoid the femoral vein in the lateral part of the wound. Close the cribriform fascia with 2/0 chromic catgut and the skin with 2/0 interrupted thread (Fig. 17.4G,H). Then apply a single layer of gauze dressing.

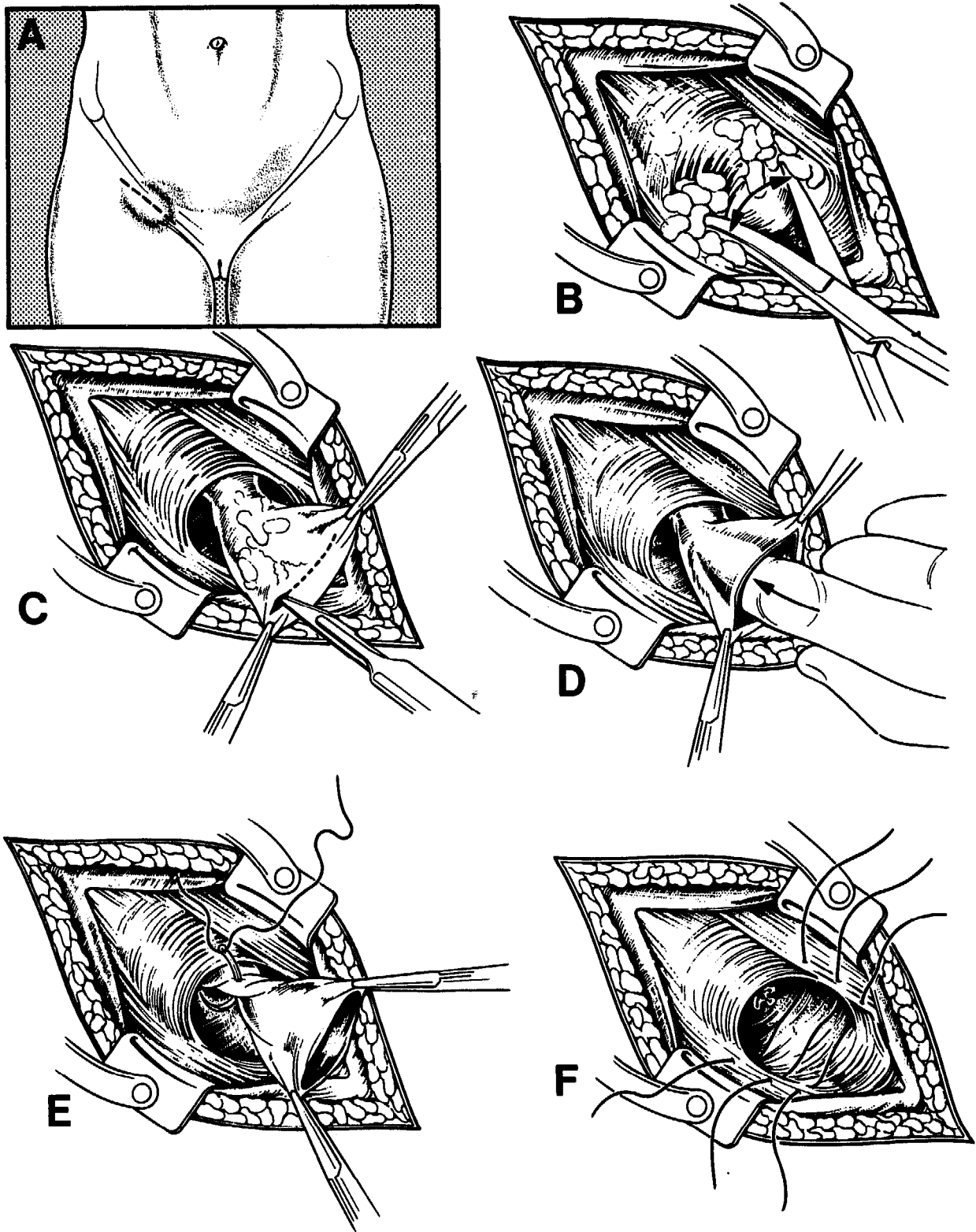


Fig. 17.4. Repair of femoral hernia. Site of incision in the groin crease (A); separating the extraperitoneal fat from the hernial sac (B); opening the lateral part of the fundus of the sac (C); exploring the sac and reducing its contents (D); transfixing the neck of the sac (E); after excision of the sac, the femoral canal is closed with a series of stitches between the inguinal ligament and the pectineal and lacunar ligaments (F).

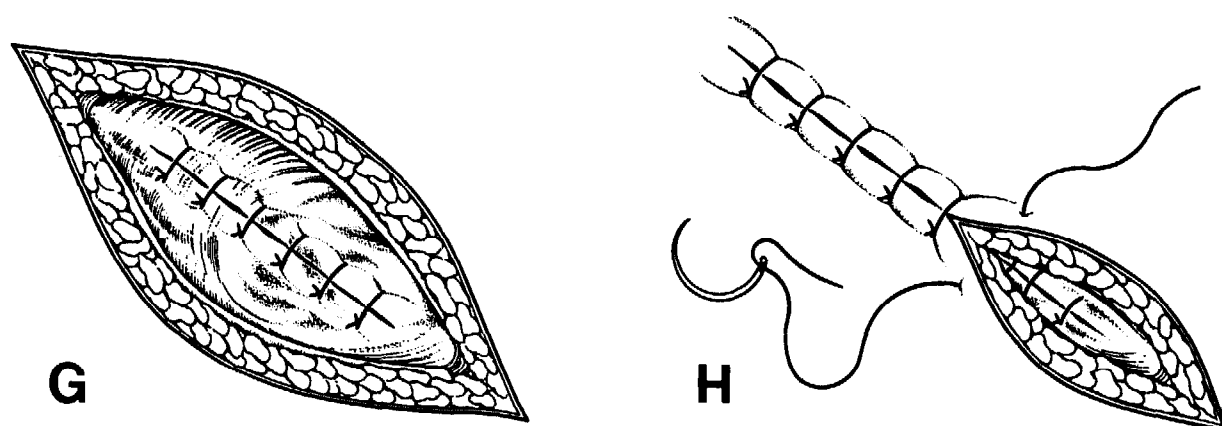


Fig. 17.4. Repair of femoral hernia (continued). Closing the wound (G, H).

Strangulation with gangrene

If a strangulated loop of intestine is found to be gangrenous, it must be resected and an anastomosis constructed. This procedure, particularly the anastomosis, may be difficult via the groin incision, so that an additional lower paramedian laparotomy may be necessary. The femoral canal should be repaired as described above.

Strangulated groin hernia

Patients with strangulated groin hernia should receive immediate treatment to relieve the obstruction.

Surgical repair

Equipment

See tray for *Hernia operation*, Annex 1.

Technique

The patient should be anaesthetized, and an appropriate incision made. Open the hernial sac and aspirate any serous or blood-stained fluid. Take a specimen for bacteriological examination. Carefully inspect the contents of the sac (gut or omentum) for viability, giving particular attention to the constriction rings.

Apply warm, wet packs to the gut for a few minutes. Gangrenous or non-viable gut will be black or deep blue without peristalsis. The mesenteric veins of the loop will appear thrombosed. There will be no arterial pulsation, and the serosa will have lost its shiny appearance. Resect any gangrenous loop of bowel and make an end-to-end anastomosis (see page 125). Then excise the hernial sac and complete the repair as appropriate.

Alternative management

Operation for strangulation can be difficult in children, in patients with recurrent herniae, and in those with large, inguinoscrotal herniae. The following alternatives to standard management may be useful at the district hospital.

Non-operative reduction

Consider non-operative reduction for patients who present early and who have no significant constitutional disturbance or signs of inflammation in the region of the hernia. Management consists of the administration of analgesics, bed-rest, and sedation with diazepam given intramuscularly or intravenously. If the patient is an adult, raise the foot of the bed to aid reduction; if the patient is a child, lift the child's bottom. Failure of reduction within 4 hours is an indication for operation. Observe the patient for at least 12 hours after a successful non-operative reduction.

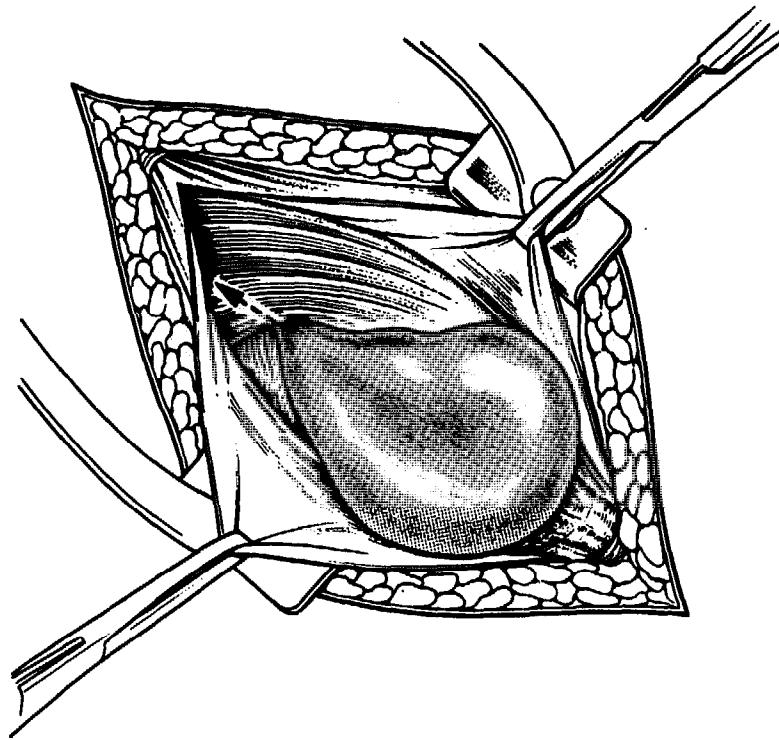


Fig. 17.5. Treatment of strangulated inguinal hernia in an adult by simple division (dotted line) of the obstructing internal ring, if the gut is viable.

Simple division of the obstructing ring

It may sometimes be prudent simply to divide the obstructing ring, making no further repair (Fig. 17.5). This procedure is advisable in children, but can also be of use in adults with strangulated recurrent or inguinoscrotal herniae. The obstructing ring in children is often the external inguinal ring, while in adults it is usually the internal ring. All such patients should then be referred for definitive surgery.

Umbilical and paraumbilical hernia

Umbilical hernia is common in children but usually closes spontaneously; surgical closure of the defect is therefore rarely necessary. Surgical repair of umbilical (and paraumbilical) hernia is, however, indicated in adults, since strangulation is always a possibility.

Surgical repair

Equipment

See tray for *Hernia operation*, Annex 1.

Technique

The patient should be given a general anaesthetic. Make a transverse incision over the hernia, sparing the umbilicus (Fig. 17.6A).

Clearly define the neck of the sac as it emerges through the linea alba and make an opening in the neck (Fig. 17.6B,C). Check for adhesions between the herniated mass and the inside of the sac using a finger. Complete the division of the neck of the sac while protecting its contents. Carefully examine the contents of the sac (the gut and omentum) and reduce them (Fig. 17.6D,E). If the herniated mass consists of omentum alone you may divide it in small segments between artery forceps and transfix the remaining tissue. Excise the sac (with any attached omentum) from under the skin at this stage or after repair of the defect (Fig. 17.6I).

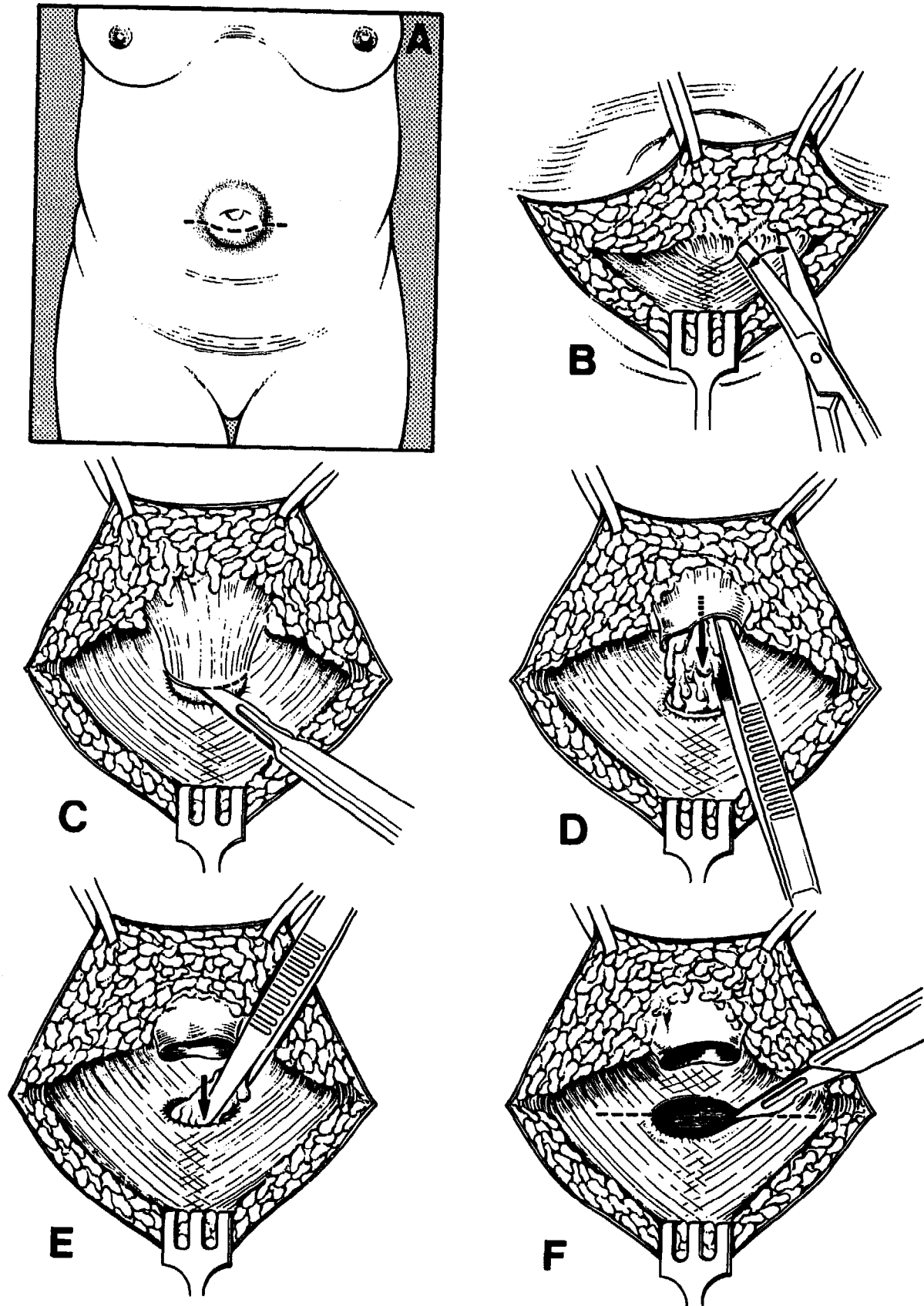


Fig. 17.6. Repair of paraumbilical hernia. Transverse incision (A); dissection to define the herniated mass (B); opening the sac at its neck (C) and reducing the contents (D, E); enlarging the defect laterally (F).

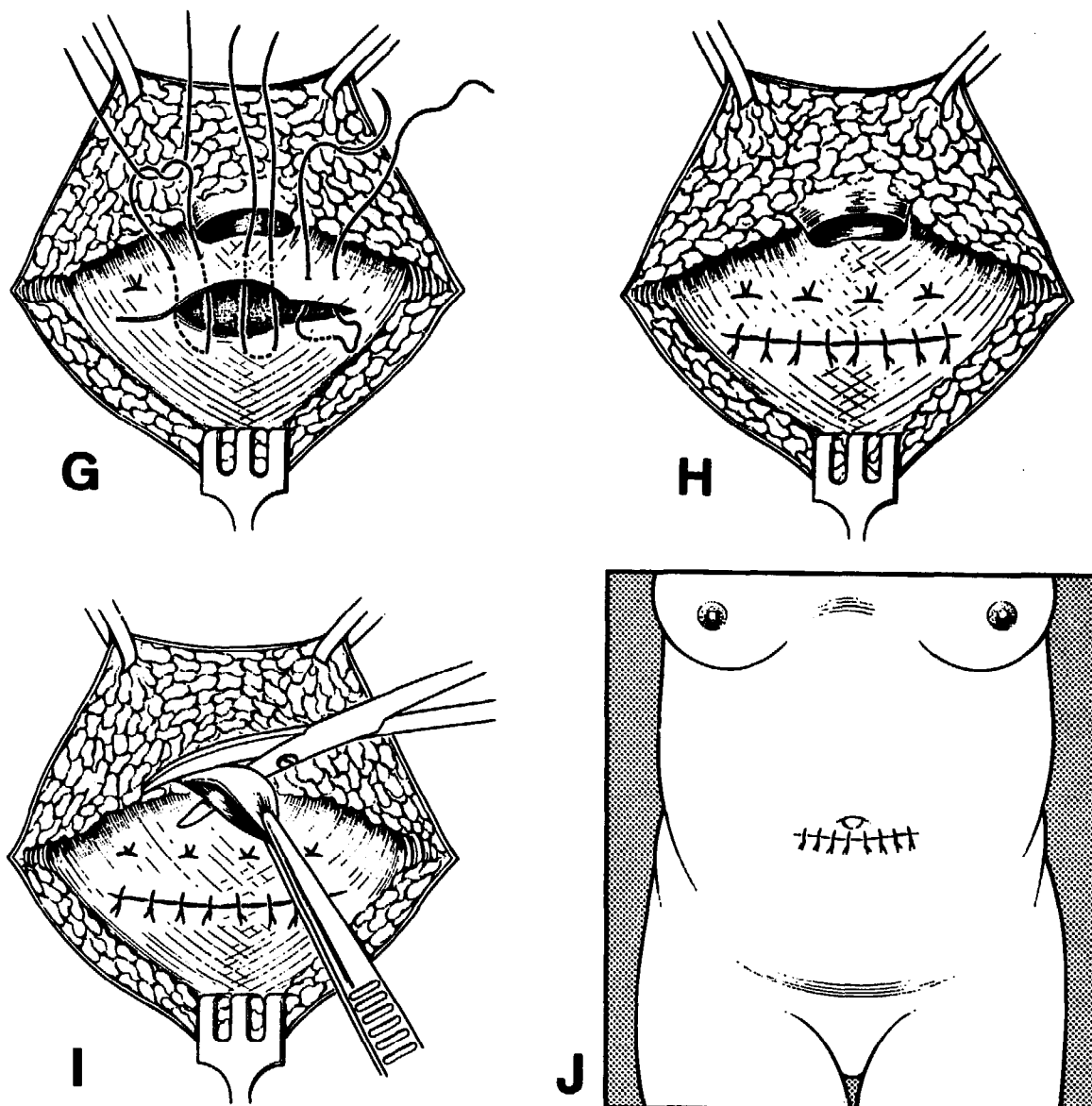


Fig. 17.6. Repair of paraumbilical hernia (*continued*). Repair of the defect by overlapping the edges (G, H); excising the sac together with extraperitoneal fat from the undersurface of the skin (I); closing the wound (J).

Using blunt dissection clearly define the fibrous margins of the defect and enlarge it laterally (Fig. 17.6F). Make the repair by inserting mattress stitches of 0 thread through all layers of the wound so that the edges overlap (Fig. 17.6G); the peritoneum need not be closed separately. Apply a further row of stitches to approximate the overlapping edge to the linea alba (Fig. 17.6H). Complete closure by stitching the skin with 2/0 thread (Fig. 17.6J). Then apply a single layer of gauze dressing.

Use the same procedure in children, but make a curved incision above or below the umbilicus. Small defects can be closed by purse-string suture.

Epigastric hernia

Epigastric hernia appears through a defect in the linea alba and is usually found in the midline between the xiphisternum and the umbilicus.

Diagnosis Symptoms of epigastric hernia vary, presenting a diagnostic problem. The patient may discover a subcutaneous swelling. He or she may complain of epigastric pain radiating to the back, especially after meals, and of heartburn, vomiting, flatulence, and indigestion.

Local examination reveals one or more subcutaneous, firm, rubbery, or soft epigastric swellings of variable tenderness. The swelling(s) may be reducible.

It is important to exclude gallbladder disease, pancreatitis, and especially peptic ulcer and hiatus hernia before you accept the diagnosis of an epigastric hernia. Indeed, epigastric hernia may coexist with one of these conditions. The local features can also be confused with those of other subcutaneous soft-tissue swellings, particularly lipoma and fibroma.

Surgical repair

Assessment and preoperative management

Preoperative investigations should be the same as for inguinal hernia.

Equipment See tray for *Hernia operation* or for *Laparotomy*, Annex 1. The choice of tray should depend on the type of incision to be made.

Technique The patient should be given a general anaesthetic. If intra-abdominal lesions have been excluded and the hernia is single, make a transverse incision over the swelling. Otherwise make a midline laparotomy incision and open the abdomen.

If you have made a transverse incision, dissect the herniated fatty mass down to its neck and make an opening in the neck. Reduce the peritoneal contents in the hernial sac and excise both the sac and the extraperitoneal fat. Define the fibrous margins of the defect and make the repair as described for paraumbilical hernia.

If laparotomy is necessary, open the abdomen through a midline incision, simultaneously opening up the epigastric hernia and any other midline herniae. Excise the fatty hernial mass. Inspect and palpate the abdominal viscera. Then close the wound, as described for laparotomy, page 102. As this incision is closed, the hernial defect is also repaired.

Incisional hernia

Patients with incisional hernia should normally be referred. Rarely, the hernia strangulates. If this happens, operate to save the patient's life by relieving the obstruction, rather than to effect a sound repair. Close the incision as well as possible and refer the patient for repair.

UROGENITAL SYSTEM

18

Urinary bladder

Drainage

Acute retention of urine is an indication for emergency drainage of the bladder. Common causes are stricture of the male urethra or the complications of stricture; prostatic disorders (benign hypertrophy, carcinoma, prostatitis, or abscess); fractured pelvis with rupture of the urethra; and paraplegia, notably that associated with a fractured spine.

If there is chronic retention of urine, bladder drainage is not urgent, but can be useful for measuring the volume of residual urine or treating renal failure associated with retention. Patients suffering chronic retention should generally be referred.

There are three methods of draining the bladder: urethral catheterization, suprapubic puncture, and cystostomy. Urethral catheterization or bladder puncture is usually sufficient, but cystostomy may become necessary for the removal of a bladder stone or foreign body, or for more prolonged drainage, for example after rupture of the posterior urethra or if there is a urethral stricture with complications.

Urethral catheterization in the male patient

Urethral catheterization is the most commonly used method of bladder drainage. Only the procedure for the male patient is described here; catheterization is much simpler in the female patient because the urethra is very short.

Equipment

See tray for *Bladder catheterization*, Annex 1.

Technique

First reassure the patient that catheterization is atraumatic and usually painless. Explain the procedure, and administer a basal sedative. Proper skin preparation is essential, especially since suprapubic puncture may become necessary if catheterization fails. In addition to taking the usual aseptic precautions, clip the hair of the pubis and external genitalia. Wash the area with soap and water, retracting the prepuce to clean the furrow between it and the glans. Put on sterile gloves and, with sterile swabs, apply a bland antiseptic to the skin of the genitalia. Isolate the penis with a perforated sterile towel. Instil lidocaine gel into the urethra and retain it for about 5 min.

Check the integrity of the Foley catheter balloon and then lubricate the catheter with sterile liquid paraffin (mineral oil). If you are right-handed, stand to the patient's right, hold the penis vertically and slightly stretched with the left hand, and introduce the Foley catheter gently with the other (Fig. 18.1B). At 12–15 cm, the catheter may stick at the angle of the bulb of the penis, in which case angle it downwards to allow it to enter the posterior urethra. A few centimetres further, there may be resistance caused by the external bladder sphincter, which

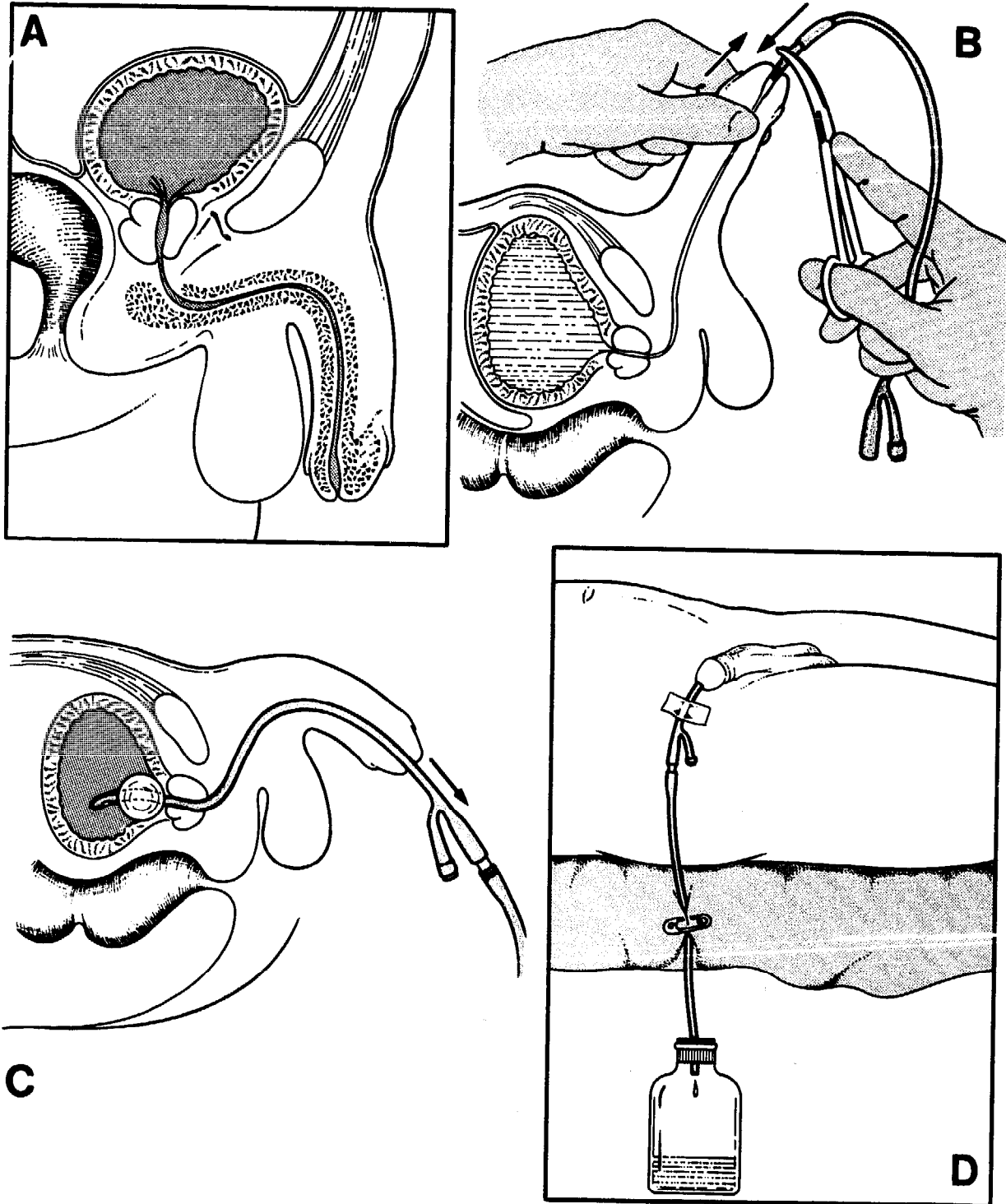


Fig. 18.1. Urethral catheterization in the male patient. Anatomy of the lower urinary tract (A); stretching the penis as the catheter is introduced (B); withdrawing the catheter until the inflated balloon abuts on the bladder neck (C); closed drainage is established (D).

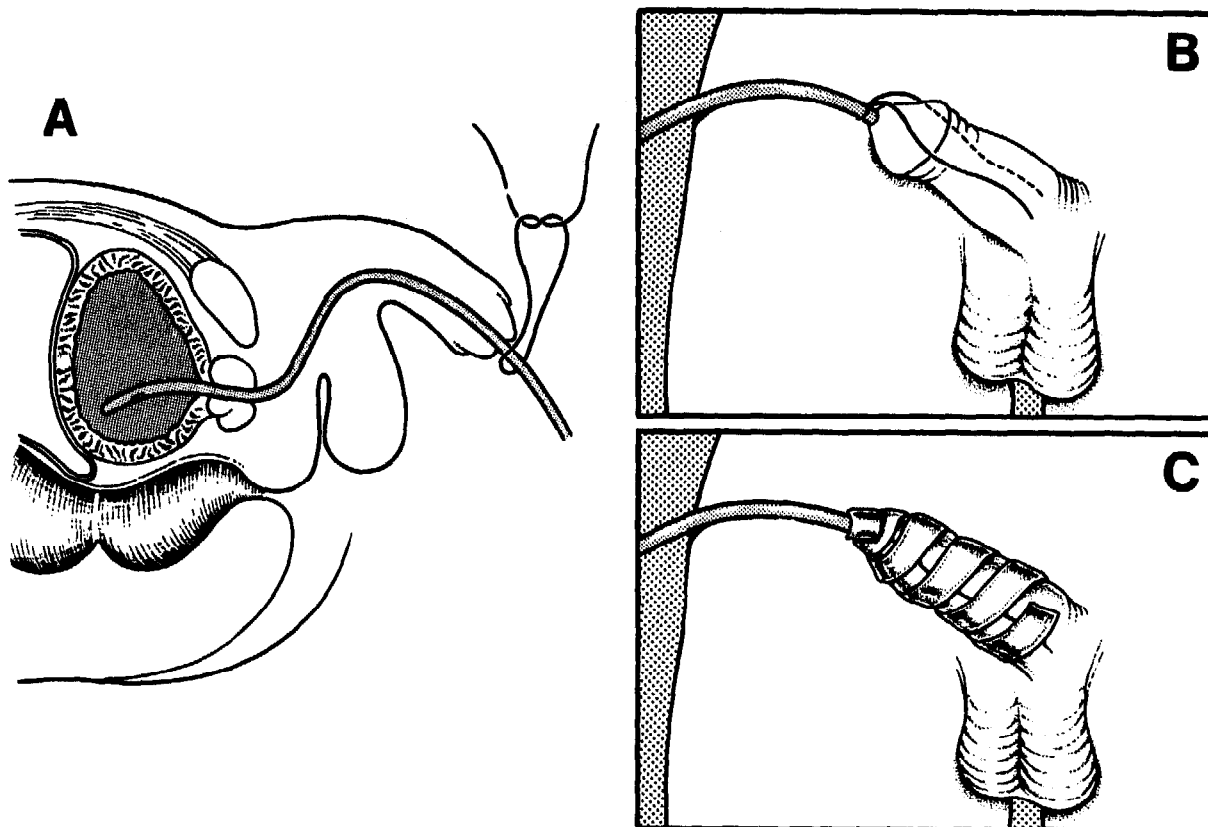


Fig. 18.2. Fixation of a non-balloon catheter with ligature and strapping.

can be overcome by a gentle push. Urine escaping through the catheter confirms entry into the bladder.

If the catheter fails to pass the bulb of the penis and the membranous urethra, try a semi-rigid coude catheter, or test the urethra with medium-size bougies and try the balloon catheter again.

Pass a coude catheter in three stages: with one hand hold the penis stretched, and with the other hold the catheter parallel to the fold of the groin; introduce the catheter into the urethra, and bring the penis to the midline against the patient's abdomen as the "beak" of the catheter approaches the posterior urethra; finally position the penis horizontally between the patient's legs as the catheter passes up the posterior urethra over the lip of the bladder neck. At this point, urine should flow from the catheter.

If you fail to pass a catheter, abandon this method in favour of suprapubic puncture. Forcing a catheter can create a false passage, causing urethral bleeding and intolerable pain, and increasing the risk of infection.

Fixation of the catheter

If you are using a Foley catheter, inflate the balloon with 10–15 ml of air or sterile water. Partially withdraw the catheter until its balloon abuts on the bladder neck (Fig. 18.1C). If the catheter has no balloon, knot a ligature around the catheter just beyond the external meatus and carry the ends along the body of the penis, securing them with a spiral of strapping brought forward over the glans and the knot (Fig. 18.2).

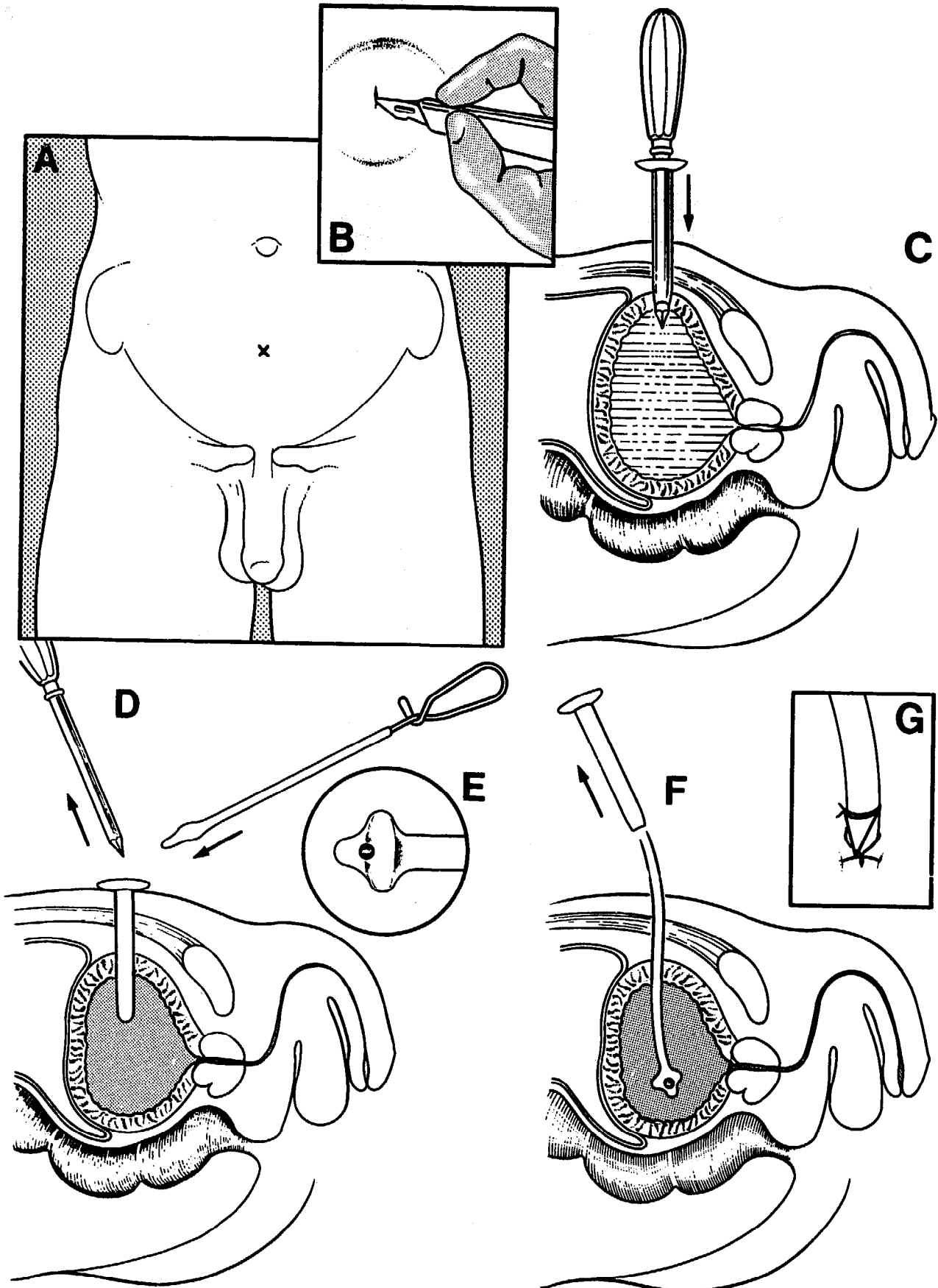
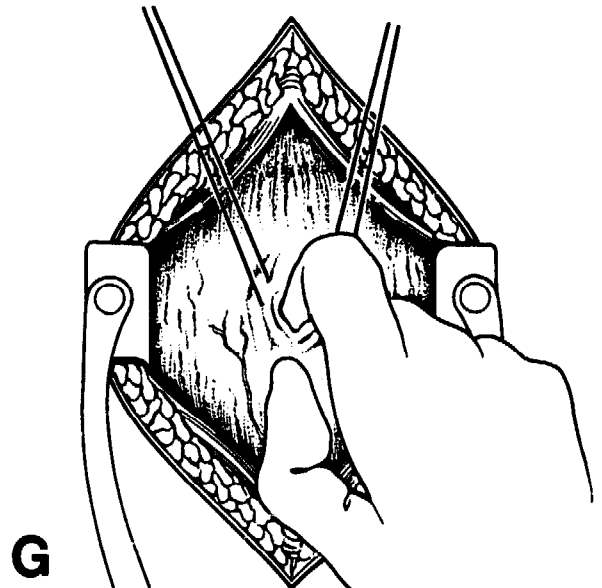
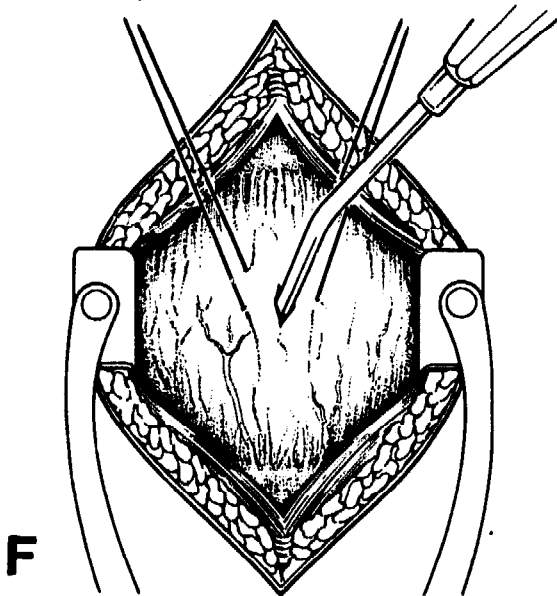
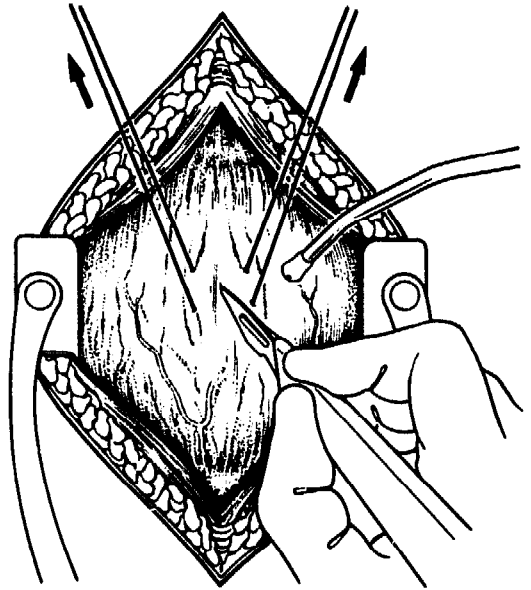
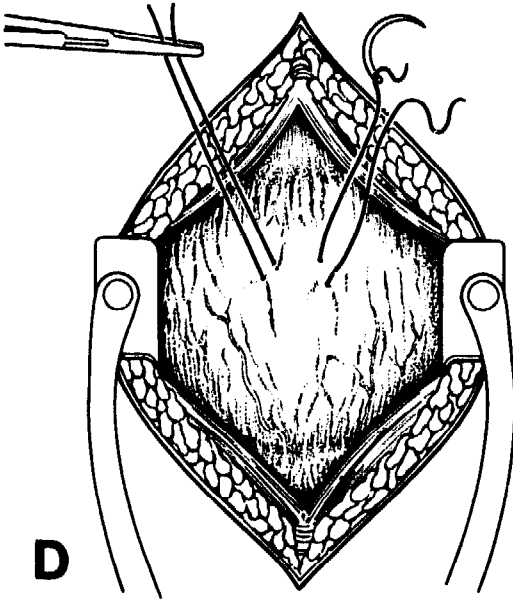
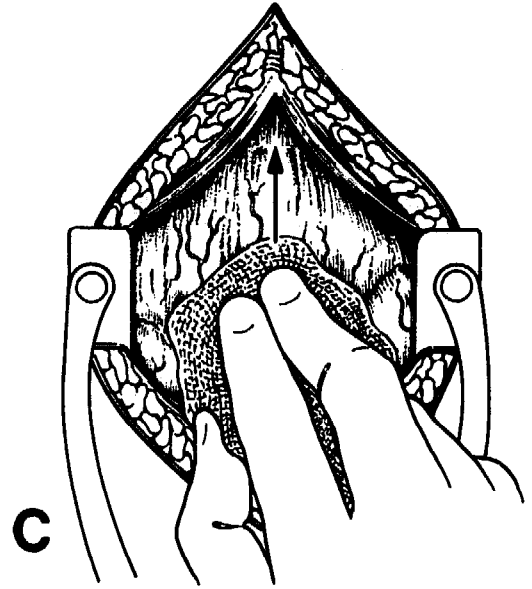
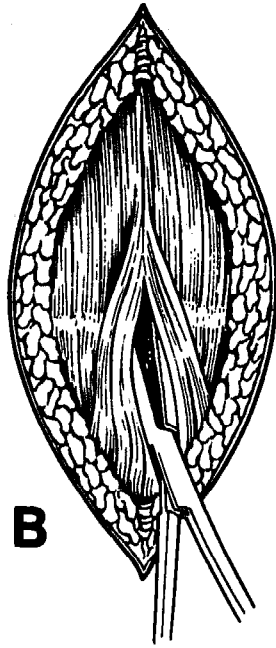
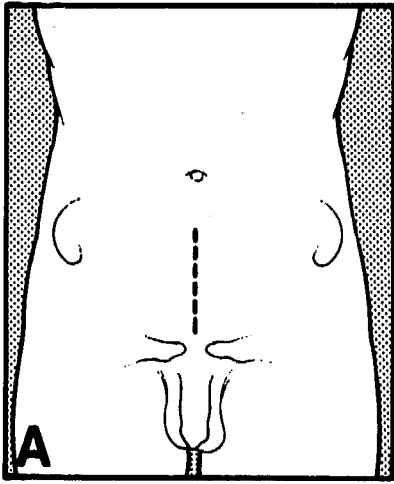


Fig. 18.3. Bladder puncture with trocar and cannula. Site of puncture (A); making a small incision after injecting local anaesthetic (B); introducing the trocar and cannula through the abdominal wall into the bladder (C); withdrawing the trocar and inserting a de Pezzer catheter stretched over an introducer (D); head of the de Pezzer catheter before stretching (E); withdrawing the cannula (F); the catheter is fixed with the skin stitch used to close the wound (G).

After-care	<p>Administer a urinary antiseptic such as co-trimoxazole (sulfamethoxazole + trimethoprim).</p> <p>Always decompress a distended bladder slowly. Connect the catheter through a closed system to a disposable plastic bag or to a sterile bottle (Fig. 18.1D). The penis and catheter should be strapped laterally to the abdominal wall; this will avoid a bend in the catheter at the penoscrotal angle and help to prevent compression ulceration. Change the catheter if it becomes blocked or infected, or as otherwise indicated, but allow the urethra to rest for an hour or so before the new catheter is inserted. To prevent calculus formation in recumbent patients, who frequently have urinary infections (especially in tropical countries), ensure a generous fluid intake.</p>
Suprapubic puncture	<p>Bladder puncture may become necessary if urethral catheterization fails.</p>
Equipment	<p>See tray for <i>Suprapubic puncture</i>, Annex 1.</p>
Technique	<p>Assess the extent of bladder distension by inspection and palpation.</p> <p>If you are proceeding to suprapubic puncture immediately after catheterization has failed, remove the perforated sheet that was used to isolate the penis and centre the opening of a new sheet over the midline above the pubis.</p> <p>Simple puncture with a wide-bore intramuscular needle connected to a 50 ml syringe will afford the patient immediate relief, but the puncture must be made again after some hours if the patient does not pass urine.</p> <p>It is preferable to perform a suprapubic puncture with a trocar and cannula, and subsequently to insert a de Pezzer catheter. Raise a wheal of local anaesthetic in the midline, midway between umbilicus and pubis, and then continue with deeper infiltration. Once anaesthesia is accomplished, make an incision with the point of a scalpel (Fig. 18.3A,B). Introduce the trocar and cannula and advance them vertically with care (Fig. 18.3C). After meeting some resistance they will pass easily into the cavity of the bladder, as confirmed by the flow of urine when the trocar is withdrawn from the cannula. Introduce the de Pezzer catheter well into the bladder (Fig. 18.3D,E). Once urine flows freely from the catheter, withdraw the cannula (Fig. 18.3F). Fix the catheter to the skin with the stitch used to close the wound (Fig. 18.3G) and connect it to a bag or bottle. Take care that the catheter does not become blocked, especially if the bladder is grossly distended. If necessary, clear the catheter by syringing with saline.</p> <p>This type of drainage allows later investigation of the lower urinary tract, for example by urethrocytography, to determine the nature of any obstruction.</p>
Suprapubic cystostomy	<p>The purpose of suprapubic cystostomy is to expose and, if necessary, allow exploration of the bladder; to permit insertion of a large drainage tube, usually a self-retaining catheter; or to allow more prolonged drainage than is possible after urethral catheterization or suprapubic puncture.</p>
Equipment	<p>See tray for <i>Laparotomy</i>, Annex 1, and add a sterile, closed drainage system, a de Pezzer or Foley catheter, and lidocaine 1%.</p>
Technique	<p>If in poor condition, the patient should be given a local anaesthetic, for example 30–40 ml of 1% lidocaine for layer-by-layer infiltration of the tissues. Otherwise general anaesthesia is preferable.</p>



Place the patient supine. Centre a midline suprapubic incision between the umbilicus and the symphysis pubis (Fig. 18.4A), and divide the subcutaneous tissues. Achieve haemostasis by forcipressure and ligation. Open the rectus sheath, starting in the upper part of the wound. Continue dissection with scissors to expose the gap between the muscles (Fig. 18.4B). (In the lower part of the incision the pyramidalis muscles will obscure this gap.) Finally, expose the extraperitoneal fat.

Carry the incision in the linea alba down to the pubis, splitting the pyramidalis muscles. With a finger, break through the prevesical fascia behind the pubis; then sweep the fascia and peritoneum upwards from the bladder surface (Fig. 18.4C). Take care not to open the peritoneum. The distended bladder can be recognized by its pale pink colour and the longitudinal veins on its surface. On palpation, it has the resistance of a distended sac. Insert a self-retaining retractor to hold this exposure.

Insert stay sutures of No. 1 catgut into the upper part of the bladder on either side of the midline (Fig. 18.4D). Puncture the bladder between the sutures and empty it by suction (Fig. 18.4E,F). Explore the interior of the bladder with a finger to identify any calculus or tumour (Fig. 18.4G). Note the state of the internal meatus, which may be narrowed by a prostatic adenoma or a fibrous ring.

If the bladder opening must be enlarged to allow you to remove a loose stone, open it 1–2 cm inferiorly, inserting a haemostatic stitch of 2/0 catgut in the cut edge if necessary. Close the extended incision partially with one or two stitches of No. 1 chromic catgut, picking up only the bladder muscle. Inspect the interior of the bladder for retained swabs before you introduce the de Pezzer catheter.

For insertion of the catheter, hold the edges of the incision with two pairs of tissue forceps, making sure that the mucosa is included so that the catheter does not slip beneath the mucosa. If you are using a de Pezzer catheter, stretch its head with forceps and introduce the catheter into the bladder between the two pairs of tissue forceps (Fig. 18.4H). If you are using a Foley catheter, introduce it into the bladder and inflate the balloon. Insert a purse-string suture of 2/0 chromic catgut in the bladder muscle to ensure a water-tight closure around the tube (Fig. 18.4I) or, if you have made an extended incision in the bladder, secure the catheter with the final stitch need to close the incision.

If drainage is to be continued for a long period, fix the bladder to the abdominal wall so that the catheter can be changed. Otherwise, omit this step to allow more rapid healing of the bladder wound. To fix the bladder, pass the traction stitches in the bladder wall out through the rectus sheath (Fig. 18.4J). Tie them together after closing this layer.

Close the linea alba with 0 chromic catgut and the skin with 2/0 thread (Fig. 18.4K,L). Connect the tube to a sterile, closed drainage system. Dress the wound every second day until it is healed.

Management of ruptured bladder

Bladder rupture, usually due to trauma, can be extraperitoneal or intraperitoneal (Fig. 18.5A,B). Extraperitoneal rupture is most commonly associated with a fracture of the pelvis, resulting in extravasation of urine. Intraperitoneal rupture is often caused by a direct blow to the bladder or a sudden deceleration of the patient when the bladder is distended, for example in a road traffic accident. Intraperitoneal rupture presents as an "acute abdomen".

Any patient with rupture of the bladder should be referred within 24 hours. If this is not possible, undertake to close the rupture and to drain the bladder with a

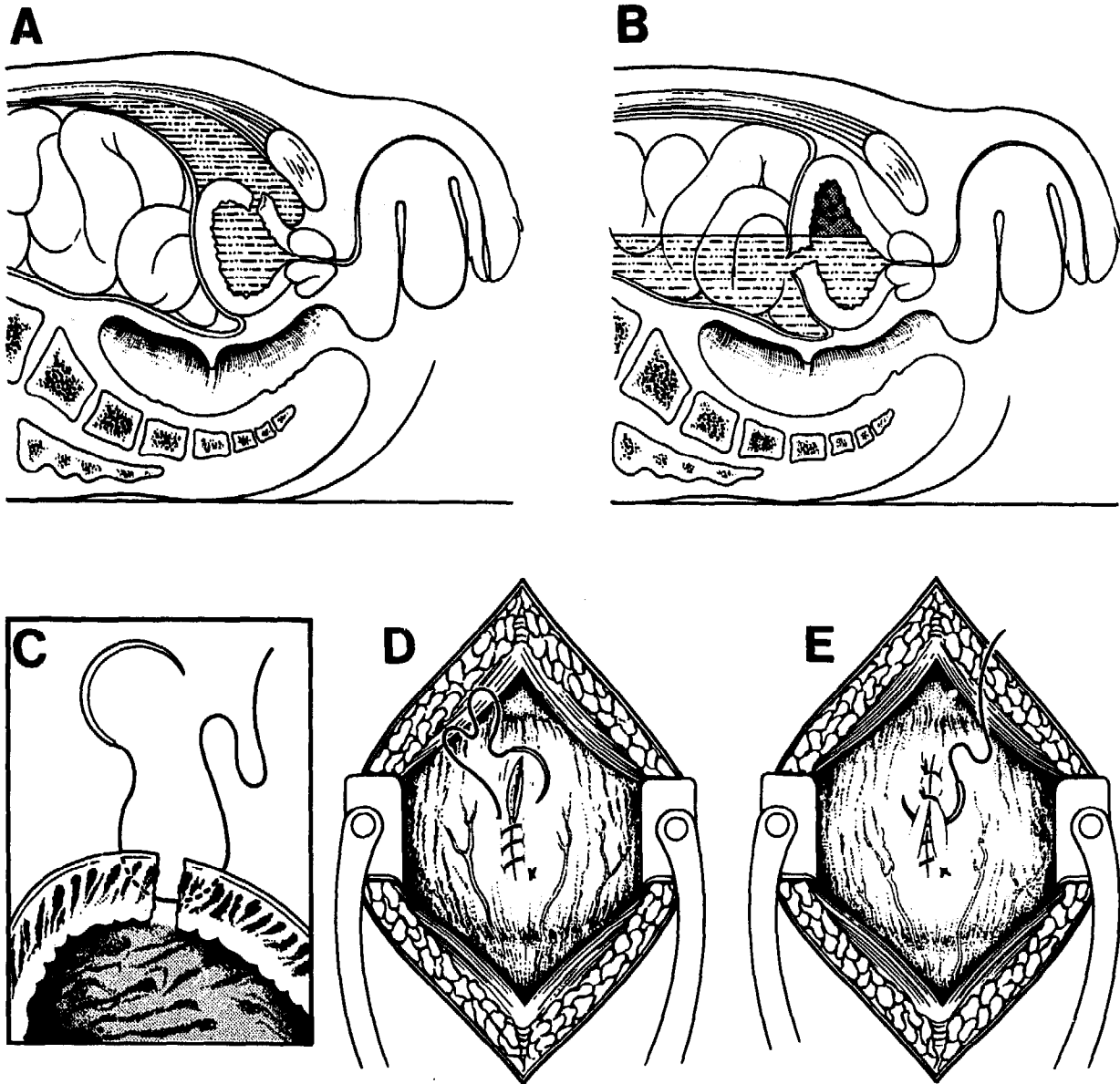


Fig. 18.5. Management of ruptured bladder. Extraperitoneal rupture (A); intraperitoneal rupture (B); repairing an intraperitoneal tear with seromuscular stitches, taking care not to include the mucosa (C, D); burying the first layer of seromuscular stitches with a second (E).

urethral catheter in patients with intraperitoneal rupture, and to construct a suprapubic cystostomy in patients with extraperitoneal rupture.

Assessment and preoperative management

The patient usually has a history of trauma, and complains of inability to void urine or of passing only small quantities of urine or drops of blood. The patient suffers suprapubic pain with tenderness and rigidity. The skin of this area may show evidence of bruising. In cases of extraperitoneal rupture, extravasation into the suprapubic tissues may be evident.

X-ray the pelvis, determine the patient's haemoglobin level and erythrocyte volume fraction, and carry out other tests as indicated. Resuscitate the patient, if necessary, before surgery.

Equipment See tray for *Laparotomy*, Annex 1, and add a Foley catheter.

Technique The patient should be given a general anaesthetic with a muscle relaxant. Expose the bladder as in the initial stages of cystostomy. Cautiously aspirate any blood or urine in the retropubic space, but leave the area unexplored, as uncontrollable bleeding can result.

In a patient with intraperitoneal rupture the bladder will be empty. The site of the tear is usually in the fundus of the bladder. Open the peritoneum, inspect the site of the rupture, and aspirate the fluid in the peritoneal cavity. Introduce a Foley catheter into the bladder through the urethra and then suture the tear with two layers of seromuscular stitches of 0 chromic catgut. *Do not include the mucosa in the first layer* (Fig. 18.5C–E). After inspecting the other viscera, close the abdomen.

Extraperitoneal rupture is usually associated with bladder distension and extravasation, which become obvious when you expose the bladder. Open the bladder, and look for the site of the tear. It may be difficult to find, but if it is clearly visible, close it from within with 2/0 plain catgut and insert a suprapubic catheter. If no tear is apparent, simply insert a suprapubic catheter. Close the opening in the bladder to construct a suprapubic cystostomy, as described on page 171. Insert a corrugated drain into the retropubic space and close the wound in layers.

After-care Administer antibiotics for the first 5 days and give adequate fluids to maintain the urinary output. A corrugated drain can be removed after 24–48 hours.

Clamp the catheter for increasing periods of time, beginning on about the fifth day. The patient with a suprapubic catheter may start passing urine during this period, in which case the catheter should be removed. In cases of intraperitoneal rupture, remove the urethral catheter after about 2 days of intermittent clamping, provided that no problems result.

The patient may still require treatment for any associated injuries, such as fracture of the pelvis.

Male urethra

Urethral dilatation

Urethral stricture is still a common problem in certain parts of the world. The condition can be treated by regular dilatation of the urethra with bougies, but this procedure can be dangerous if the doctor is inexperienced. Every doctor destined for service in an isolated post must therefore be properly trained to pass bougies.

Before proceeding with dilatation, measure the patient's haemoglobin level and test the urine for sugar and protein.

Equipment See tray for *Urethral dilatation*, Annex 1. Several different types of bougies are available (Fig. 19.1F). Curved bougies are tapering metal rods adapted to the curves of the male urethra; straight bougies, also made of metal, have a blunt tip and are generally only slightly tapered; filiform bougies have a smaller diameter and are made of softer material.

Technique Administer a basal sedative before beginning the procedure and start antibiotic treatment, to be continued for 3 days. Carefully clean the glans and meatus, and prepare the skin with a bland antiseptic. Instil lidocaine gel into the urethra and retain it for 5 min. Drape the patient with a perforated towel to isolate the penis.

If the stricture is highly irregular, begin by introducing a filiform bougie; leave it in the urethra and continue to insert filiform bougies until one passes the stricture (Fig. 19.1A–D). Then progress to dilatation with straight bougies (Fig. 19.1E). If the stricture is less irregular, begin with a medium-size straight or curved bougie and gradually work up in size. For a postinflammatory stricture that starts in the anterior urethra, always introduce a straight bougie first; this will minimize the risk of urethral damage (Fig. 19.1G). Continue dilatation with straight bougies of increasing size, and finally introduce a curved bougie. Remember that the smallest sizes of metal bougies are the most likely to lacerate the urethra.

Introduce a curved bougie in three stages (Fig. 19.1H–J):

- bring the bougie parallel to the crease of the groin and hold the penis taut;
- while raising the taut penis to the midline towards the patient's abdomen, slip the bougie into the posterior urethra and let it progress by its own weight;

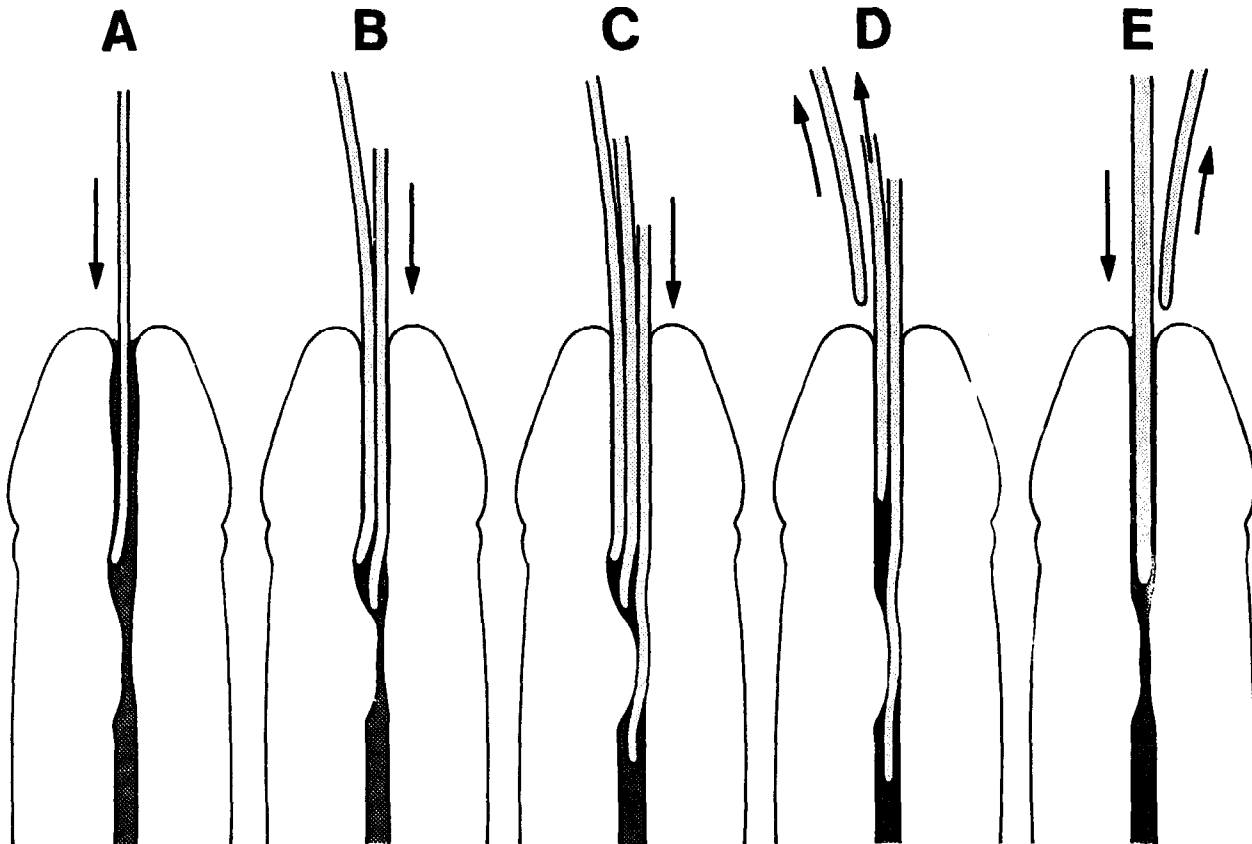


Fig. 19.1. Urethral dilatation in the male patient. Dilatation of an irregular stricture using filiform bougies (A, B); once a filiform bougie passes through the stricture (C, D), progressive dilatation can be started (E).

- finally, bring the penis down to the midline horizontally between the patient's legs, as the curve of the bougie carries it up the posterior urethra and over the neck of the bladder.

Initially, dilate the patient's urethra at least twice a week, using two or three sizes of bougie successively at each session. Begin with the smallest size and stop at about 24 Ch. If there is urethral bleeding, skip a session to give the mucosa time to heal. Perform follow-up dilatation weekly for 4 weeks, twice monthly for 6 months, and then every month.

Complications

Complications can include trauma with bleeding and even the formation of a false passage. Minimize the possibility of bacteraemia, septicaemia, and septic shock by ensuring asepsis and by the use of antibiotics.

Rupture of the urethra

Patients with rupture of the urethra should be referred, though initial treatment may have to be given at the district hospital.

Diagnosis

The patient usually has a history of either a blow to the perineum or a pelvic fracture, with subsequent development of urethral haemorrhage. Haemorrhage

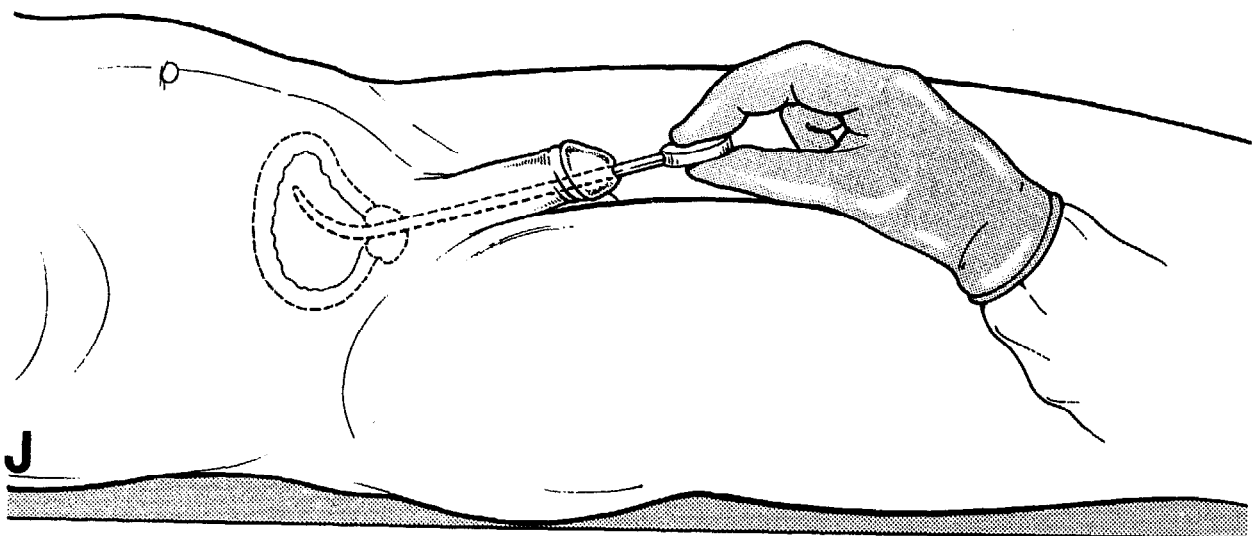
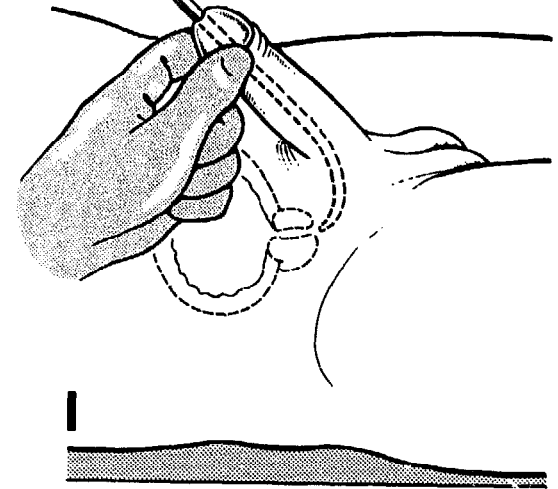
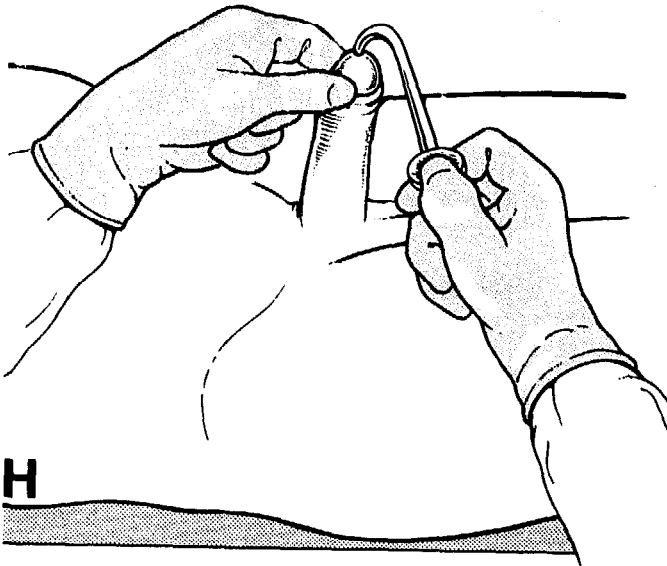
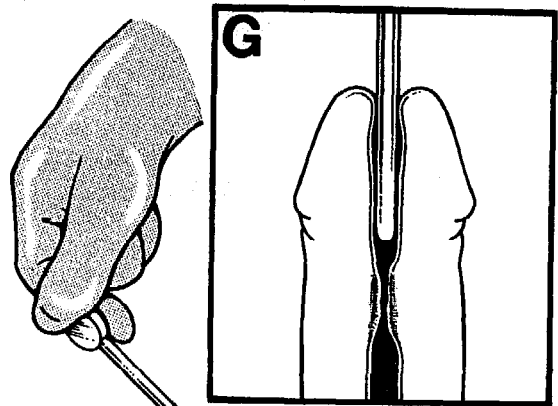
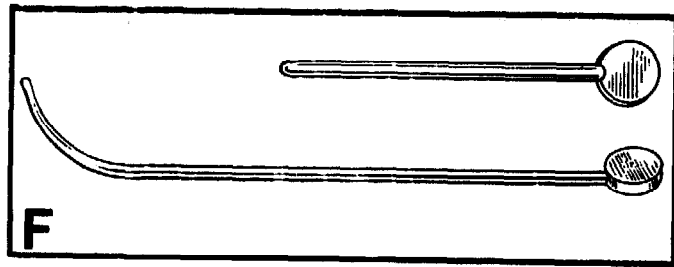


Fig. 19.1. Urethral dilatation in the male patient (continued). A straight and a curved bougie (F); dilatation of an anterior stricture with a straight bougie (G); dilatation with a curved bougie (H-J).

can appear in the form of a few drops of blood at the meatus, rather than profuse bleeding. The perineum and penis become swollen with haematoma and there is acute retention of urine.

Examine the patient for possible concomitant injuries.

Measure the patient's haemoglobin level and X-ray the pelvis. A urethrogram, obtained after 20 ml of a contrast material (of the type usually given intravenously) has been instilled into the urethra, can be useful in determining whether the rupture is partial or complete. However, this information will not influence treatment at the district hospital and is therefore not immediately required. Avoid diagnostic catheterization.

Treatment

Resuscitate and reassure the patient. Administer analgesics. Discourage him from attempting to pass urine.

Prepare the skin of the lower abdomen and perineum. If the bladder is obviously distended, perform a suprapubic cystostomy (see page 171). If there is an open perineal wound or if the perineal haematoma has become so tense as to require incision, open and then lightly pack the perineal haematoma during suprapubic cystostomy. Refer the patient as soon as possible.

Maintain the patient on a high fluid intake. Administer antibiotics for 5 days after the operation.

Male genital organs

Scrotal hydrocele

Scrotal hydrocele is an abnormal accumulation of fluid in the tunica vaginalis sac (Fig. 20.1A). The swelling that results is often enormous and always uncomfortable.

In adults, the hydrocele fluid is located entirely within the scrotum; the surgical treatment described here is straightforward, even for the doctor without formal training in surgery, and the operation is relatively safe for the patient. In children, however, the hydrocele communicates with the peritoneal cavity and is often associated with a hernia; the treatment described in this section is therefore inappropriate.

Diagnosis

Palpation will confirm that the swelling is scrotal; it will be soft or tense, and fluctuant, and may mask the testis and epididymis. A transillumination test will be positive. If you are in doubt about the diagnosis, perform aspiration. The hydrocele fluid is often the colour of normal urine. After aspiration, palpation of the testis and the epididymis will be possible.

Diagnosis can be difficult when there is a hydrocele and a hernia on the same side. However, an inguinoscrotal hernia can be distinguished because it is softer, and is partially or completely reducible, and an impulse will be detectable when the patient coughs. Lymphoedema of the scrotum, which should also be considered in differential diagnosis, is characterized by thickened skin.

Treatment

Aspiration is not recommended as a method of treatment, as the relief it provides is only temporary, and repeated aspirations risk infection of, or trauma to, the testis. Injection of sclerosants is also not recommended, as it can cause painful inflammation without effecting a cure. Surgery remains the most effective form of treatment. Of the various alternative operations, eversion of the tunica vaginalis is one of the simplest, though recurrences are still possible.

Wash the skin and treat any lesions, for example wounds made by traditional healers, with saline dressings. The presence of skin lesions is not a contraindication to surgical treatment as long as there are healthy granulations with little or no infection. Administer tetanus prophylaxis.

Eversion of the tunica vaginalis

Before surgery, measure the patient's haemoglobin level and test the urine for sugar and protein.

Equipment

See tray for *Minor operations*, Annex 1.

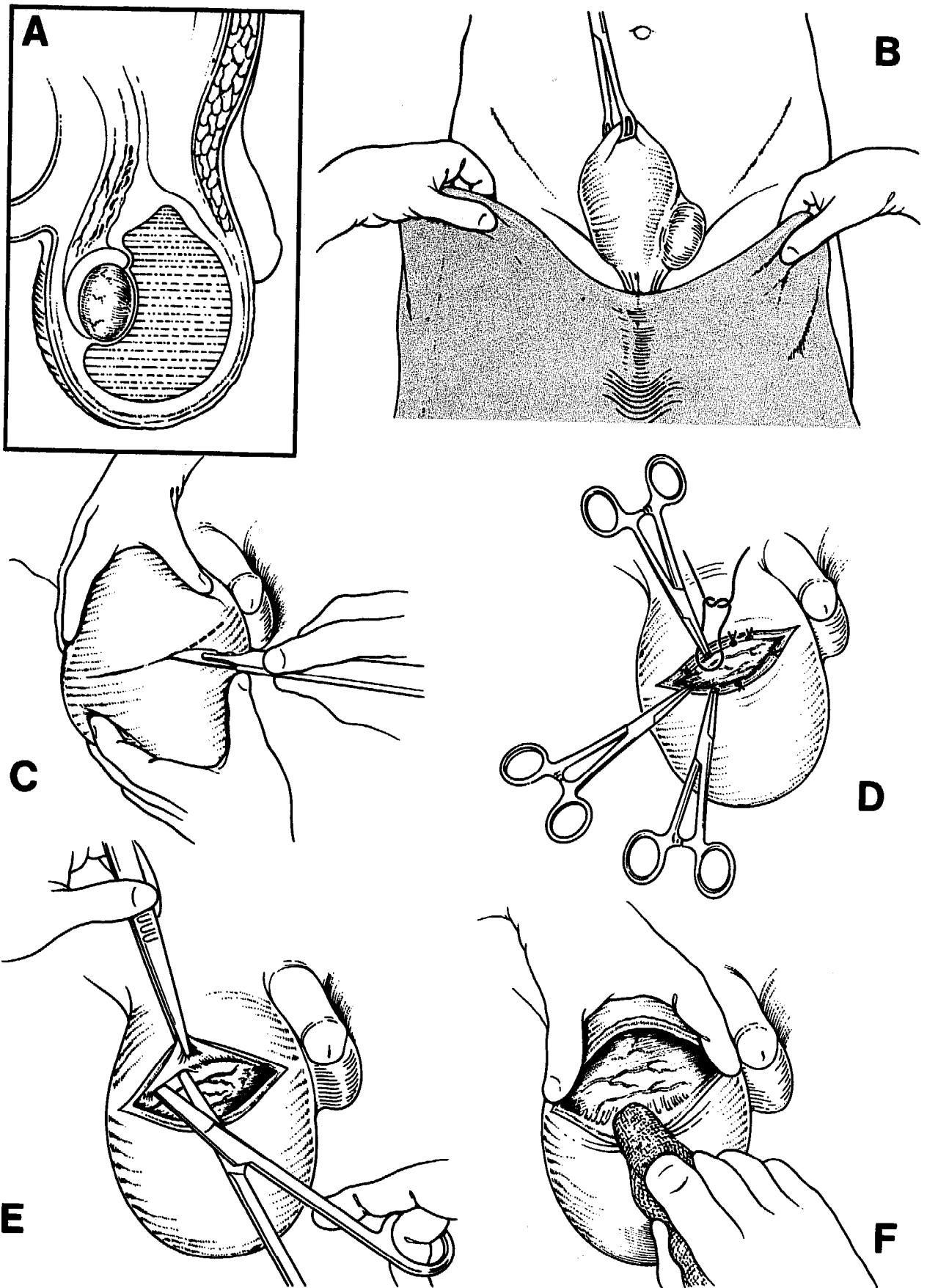


Fig. 20.1. Treatment of hydrocele by eversion of the sac. Anatomical site of the hydrocele within the scrotum (A); draping (B); incision in a skin crease as the hydrocele is held tense (C); ligating the vessels of the scrotal wall (D); blunt dissection between the sac and its fibrous coverings (E, F).

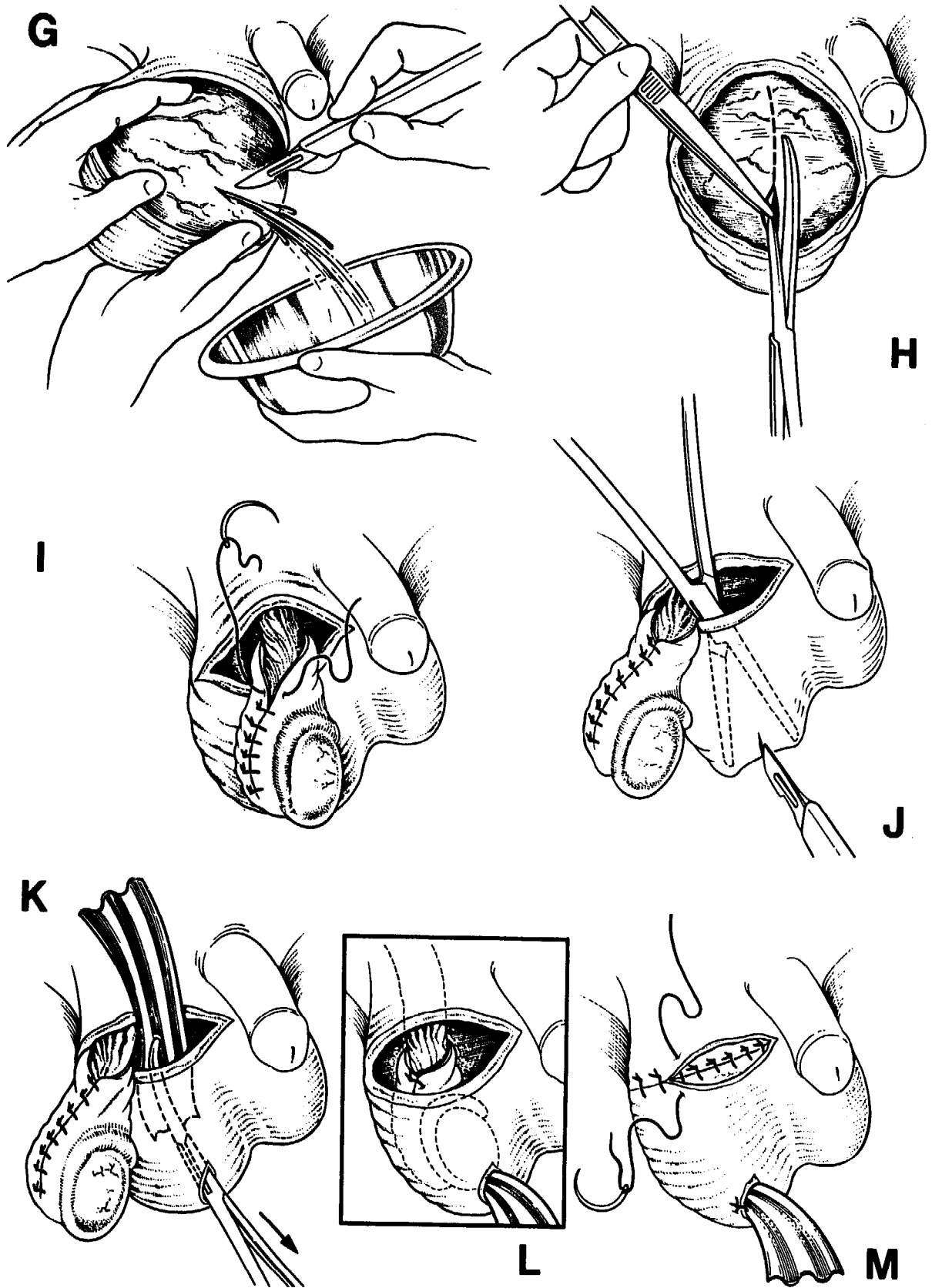


Fig. 20.1. Treatment of hydrocele by eversion of the sac (*continued*). Puncturing the sac (G) and enlarging the opening (H); everting the testis through the incision and reuniting the edges of the sac behind the cord and epididymis (I); inserting a corrugated drain (J, K); repositioning the testis within the scrotum (L); closing the wound (M).

Technique Ideally, the patient should be given a general anaesthetic. It is also possible to use infiltration anaesthesia, produced by injecting 1% lidocaine at the neck of the scrotum into the tissues of the cord and along the line of the incision. Spinal anaesthesia is a convenient and effective alternative.

Lay the patient supine and prepare the skin widely with a bland antiseptic. Place a sterile towel under the scrotum (Fig. 20.1B). (Elevating the scrotum with tissue forceps will facilitate this.) Then stand on the side of the lesion with an assistant opposite.

As the assistant presses on the hydrocele to render it tense, make an oblique incision over the hydrocele in a skin crease (Fig. 20.1C). Continue incising through the layers of the scrotal wall down to the tunica vaginalis. This can normally be recognized by a lattice of fine blood vessels in a thin translucent membrane, although sometimes the membrane will have been thickened by previous infection or trauma. Ligate all vessels encountered with 2/0 chromic catgut (Fig. 20.1D).

By means of blunt dissection with scissors, find a plane of cleavage between the sac and the fibrous coverings. With gauze and scissors, continue separation to the termination of the spermatic cord, where it is attached to the hydrocele (Fig. 20.1E,F). If the sac is inadvertently opened, catch the edges of the opening with forceps and introduce a finger into the sac to stretch it and the overlying tissues as an aid in dissection.

Puncture the sac and instruct your assistant to collect the jet of fluid in a dish as you squeeze the swelling (Fig. 20.1G). Catch the edge of the hole with forceps and slit the sac vertically with scissors, after making sure that the epididymis is not adherent to its posterior surface (Fig. 20.1H).

Evert the testis and the epididymis through the hole, and inspect them for tuberculosis, schistosomiasis, and cancer (which would necessitate referral of the patient). Then reunite the edges of the everted sac behind the cord and epididymis with a few interrupted stitches of 2/0 chromic catgut (Fig. 20.1I). Maintain careful haemostasis throughout; it is important to stop even the slightest bleeding, to minimize the risk of haematoma formation.

Insert a corrugated drain, bringing it out inferiorly through a counter-incision, and fix it to the skin with a stitch (Fig. 20.1J,K).

Replace the testis and the cord. Close the dartos muscle with interrupted 2/0 chromic catgut and the skin with interrupted 2/0 thread (Fig. 20.1L,M). Apply a compression dressing of gauze and then a T-bandage.

After-care Support the scrotum in an elevated position. Remove the drain after 24–48 hours.

Complications Possible complications include haematoma formation, infection, and recurrence. If haematoma develops despite every care having been taken to stop bleeding during surgery, remove a few stitches from the wound, open the edges with a pair of large artery forceps, and express the clots from the wound. This procedure may need to be repeated over several days. Antibiotics do not always prevent infection; if it does occur, give appropriate antibiotic therapy and drain the wound. Even with treatment, however, an infection may take up to 2 months to clear.

Circumcision

Circumcision in the male patient is the surgical resection of the prepuce. It is indicated in cases of phimosis, paraphimosis, and recurrent balanitis, and when there has been an injury to the foreskin.

The purpose of the operation is to resect the prepuce obliquely at the level of the corona of the glans, allowing the glans to be fully exposed while preserving enough of the frenulum to permit erection.

Preoperative investigations are not required unless physical examination suggests that the patient is anaemic or suffering from a major illness.

Equipment See tray for *Minor operations*, Annex 1. The ligatures and sutures used throughout the procedure should be of 3/0 chromic catgut.

Technique Conduction anaesthesia can be used for circumcision, but general anaesthesia is preferable. Infiltration of the prepuce with local anaesthetic simply obscures the line of section. Nerve block, accomplished by injecting 1% lidocaine at the base of the penis on either side of the midline, just beyond the pubis, is a useful supplement to a general anaesthetic. However, if used without general anaesthesia, nerve block must be reinforced by further infiltration of the underside of the penis between the corpus spongiosum and the corpora cavernosa.

Prepare all the external genitalia with a bland antiseptic. If the prepuce can be retracted, carefully clean the glans and the preputial furrow with soap and water. If the prepuce cannot be retracted, gently stretch the preputial opening by inserting the blades of a pair of artery forceps and slowly opening them until the area can be properly cleaned (Fig. 20.2A). Break down any fine adhesions between the glans and prepuce, and replace the prepuce. Isolate the penis with a perforated towel.

Take hold of the prepuce dorsally in the midline with two pairs of forceps and cut down between the forceps with scissors until the blades nearly reach the corona (Fig. 20.2B-E). Check that the lower blade really is lying between the glans and prepuce and has not been inadvertently passed up the external meatus. Then excise the prepuce by extending the dorsal slit obliquely around on either side to the frenulum, and trim the inner preputial layer, leaving at least 3 mm of mucosa (Fig. 20.2F,G).

Catch the cut edges of the frenulum and the bleeding artery of the frenulum with a catgut suture, leaving the suture long as a traction stitch to steady the penis (Fig. 20.2H). Insert a similar traction stitch to unite the edges of the prepuce dorsally (Fig. 20.2I). Catch and tie any bleeding vessels on either side of the raw area. Unite the edges of the prepuce with interrupted stitches and cut the stitches short (Fig. 20.2J,K).

After-care Dress the penis in loose layers of petrolatum gauze covered with dry gauze. Retain this dressing for 24 hours, thereafter providing only protection from rubbing against clothes, until healing is complete. The stitches will separate in 10-15 days.

Complications The most serious complication of operation is haematoma due to failure to secure the artery of the frenulum sufficiently or to dehiscence of the stitches as a result of an early morning erection (which can be avoided by administration of a sedative).

Vasectomy

Vasectomy is a method of contraception. Make it clear to the patient that the operation is irreversible and that its effects are permanent (do not mention the

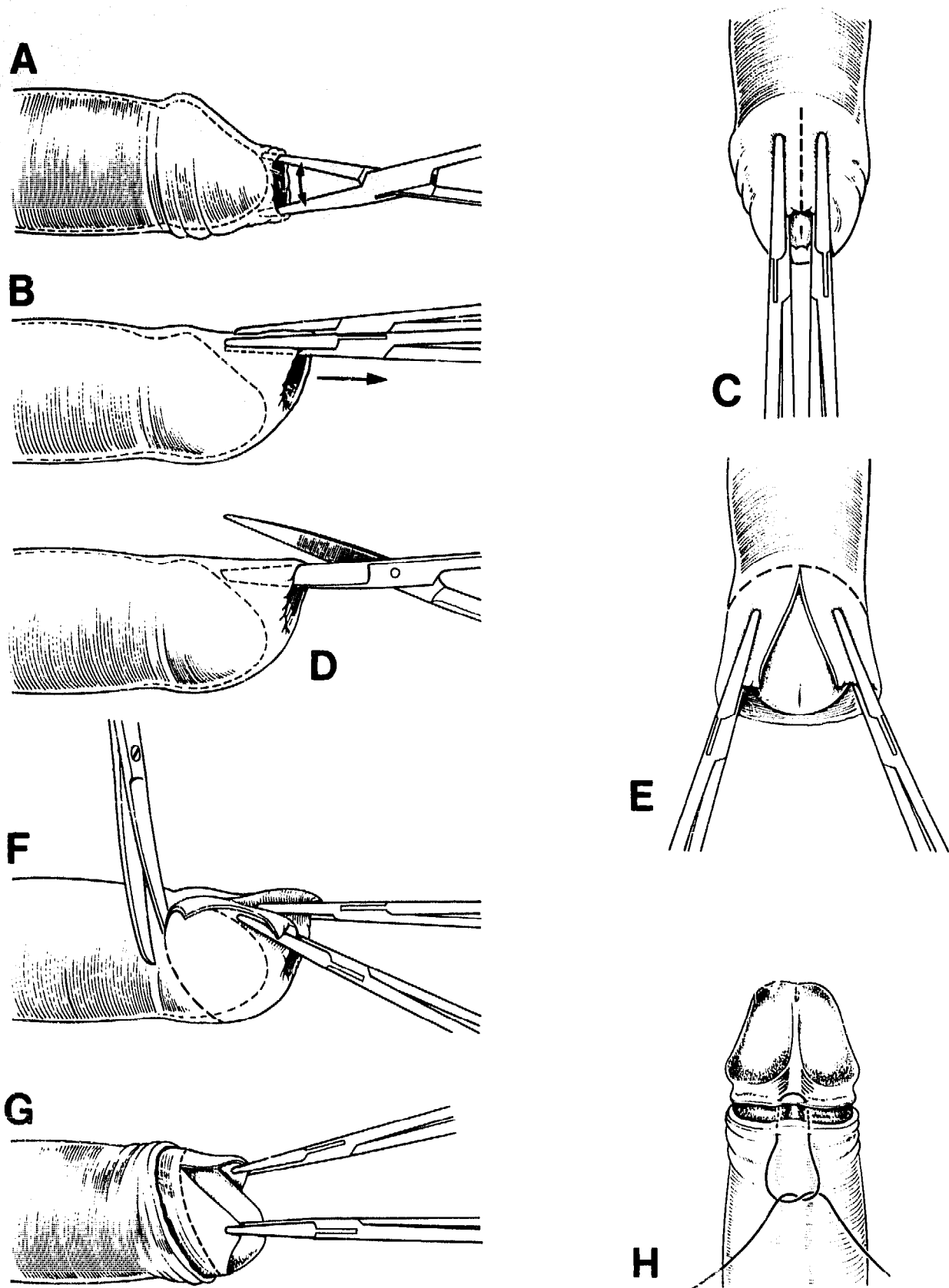


Fig. 20.2. Male circumcision. Stretching the opening of the prepuce (A); holding the prepuce with two pairs of forceps (B) and cutting down the midline dorsally (C-E); excising the prepuce (F); inner layer of the prepuce to be trimmed (G, dotted line); ligating the artery of the frenulum (H).

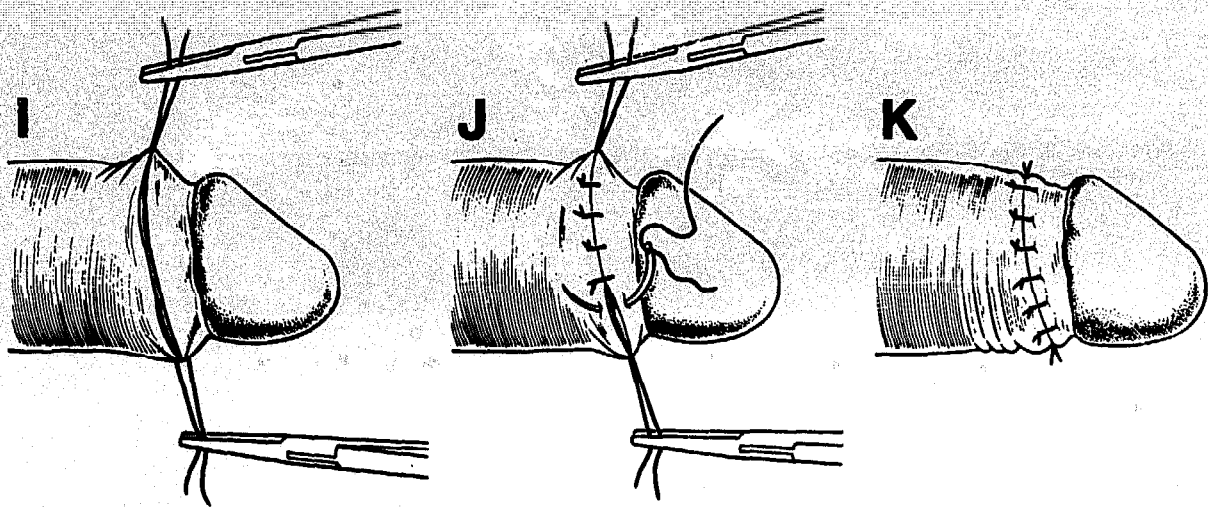


Fig. 20.2. Male circumcision (continued). Inserting traction (stay) sutures (I); closing the wound (J, K).

possibility of re-anastomosis). Emphasize that the operation is almost always successful, but that sterility cannot be guaranteed since there is a small chance of failure, for example resulting from spontaneous recanalization, even after meticulous surgery. Stress that sterility will not be immediate; indeed, it can take up to 8 weeks for the patient to become completely sterile. Observe any legal formalities.

Preoperative investigations are not essential.

Equipment See tray for *Minor operations*, Annex 1.

Technique Vasectomy is usually carried out with the patient under local anaesthesia, but general anaesthesia is preferable if the patient is nervous or has undergone inguinoscrotal surgery.

Place the patient in a supine position. Cleanse and shave the pubis and external genitalia. If you are using local anaesthesia, inject a wheal of 1% lidocaine and make an incision of 2–3 cm in the scrotal raphe (Fig. 20.3A–C). Infiltrate the deeper tissues, picking up each layer in turn to inject anaesthetic. At each stage, allow a few minutes for the local anaesthetic to take effect. Hold up the vas from one side with a pair of tissue forceps and infiltrate its connective tissue sheath with lidocaine (Fig. 20.3E). Open the sheath, isolate the vas with artery forceps, and excise about 1 cm (Fig. 20.3F–H). The cut ends will be characteristically conical, with the outer fibromuscular tissues retracting from the lumen. Ligate the testicular end and replace it within the connective tissue sheath. Turn the proximal end back on itself and ligate it so that it lies outside the sheath (Fig. 20.3I). Repeat the procedure on the other vas (Fig. 10.3J). Close the scrotal wound with a few 2/0 catgut stitches, making sure to include the dartos layer (Fig. 20.3K).

This technique is widely used and allows a rapid turnover of patients in outpatient clinics. The less experienced surgeon may find it easier to identify the vas by pinching it between the thumb and finger at the lateral side of the neck of the scrotum and then to incise the skin directly above it, catching the vas with a pair of tissue forceps before it slips away. This procedure is best done with the patient under general anaesthesia.

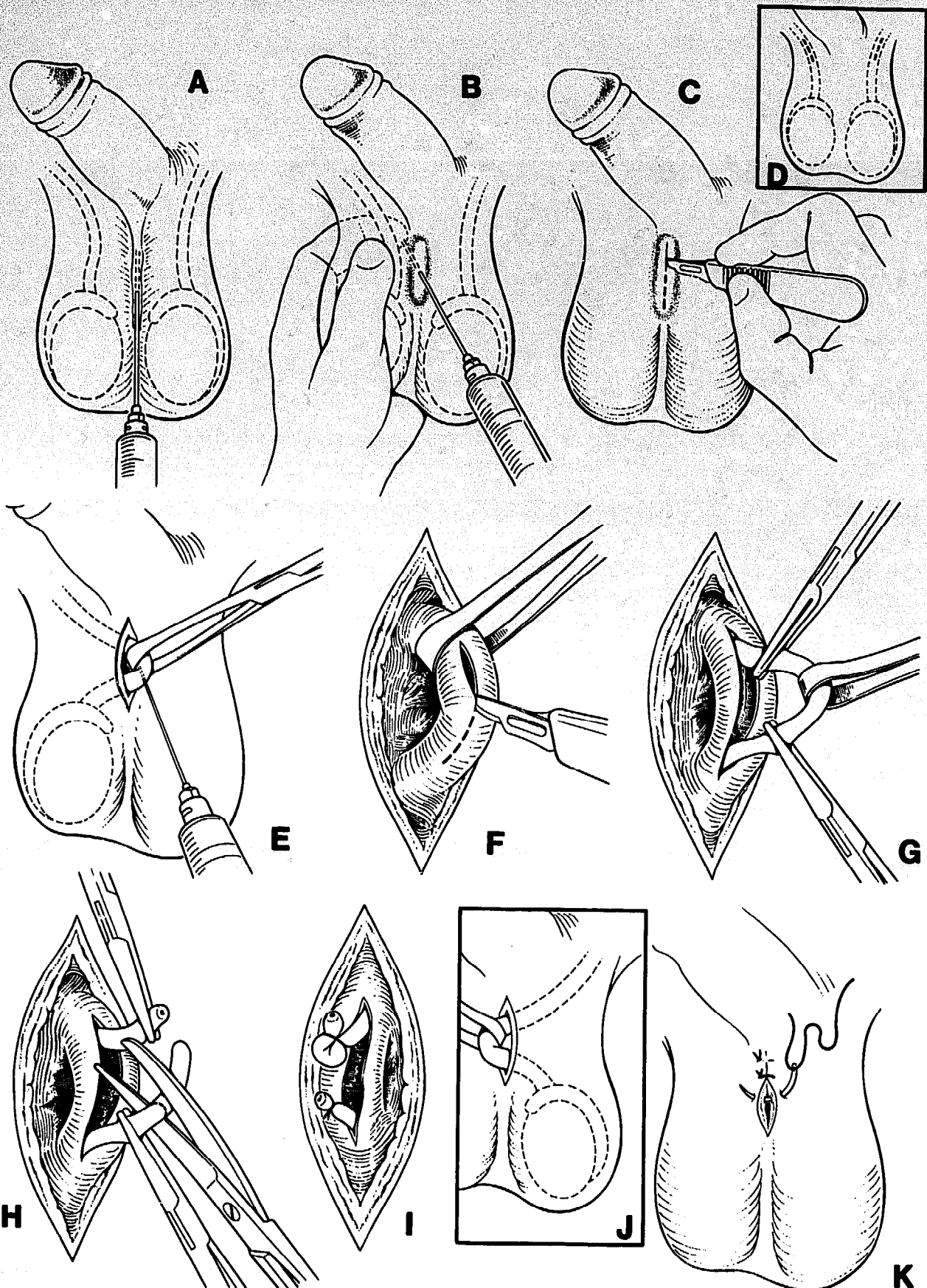


Fig. 20.3. Vasectomy. Injecting local anaesthetic (A, B); incision (C); alternative sites for infiltration and incision (D); infiltrating the tissue around the vas with local anaesthetic (E); opening the sheath and isolating the vas between clamps (F, G); excising a segment (H); ligating the cut ends of the vas (I); the other vas is dealt with similarly (J) and the wound is closed (K).

As an alternative, fix each vas under the skin by inserting a hypodermic needle, after effecting local anaesthesia with 1% lidocaine. Make a vertical incision 1 cm long over the vas on one side (Fig. 20.3D), and hook it out with forceps. Proceed to divide and ligate the vas as described above. Then make an incision over the other vas and repeat the procedure.

After-care The patient should wear a scrotal support for 48 hours after the operation. Carry out a semen analysis at 6–8 weeks to confirm sterility.

Exploration of scrotal contents

At the district hospital, exploration of scrotal contents should be confined to patients with acutely painful scrotal swelling, as described in the section on paediatric surgery, page 201. A scrotal incision is normally used; however, if a testicular tumour is suspected in the adolescent or adult, it is best to explore the testis through an inguinal incision, drawing the parts into the wound at the neck of the scrotum. Should a tumour be found, open the external oblique aponeurosis, clamp and doubly ligate the spermatic cord near the deep inguinal ring, and then remove the testis.

PAEDIATRIC SURGERY

General principles for paediatric surgery

Special considerations

In general, the basic principles of surgery and care for adults can be applied to children aged 10 years and over. Infants and younger children, however, have important physiological differences that influence the way in which they should be cared for before, during, and after surgery.

Nutrition	Infants and children are at special risk of becoming malnourished because of the volume of material and energy they need for rapid growth. Malnourishment also affects their response to injury, so ample nutrition forms part of their preoperative and postoperative care.
Temperature control	Infants and young children, especially those with diminished amounts of subcutaneous fat, are unable to maintain a normal body temperature when there are wide variations in the ambient temperature. Special care is needed during general anaesthesia, when they may be even less able to regulate body temperature adequately.
Fluid and electrolytes	Infants and small children have a much smaller pool of fluids and electrolytes than adults. As a result, minor departures from normal levels require early attention. Continued abnormal losses of both fluid and electrolytes must be corrected promptly.
Blood loss	Replacement is needed whenever blood loss exceeds 10% of blood volume. Chronic anaemia should be investigated and treated as part of the preparation for operation.
Anaesthesia	See Dobson, M.B., <i>Anaesthesia at the district hospital</i> (Geneva, World Health Organization, 1988) for discussion of the anatomical, physiological, and technical considerations relevant to paediatric anaesthesia.

Cut-down to umbilical vein

This procedure is indicated for the intravenous administration of fluids in neonates when a peripheral vein cannot be easily found, and for exchange transfusion.

Equipment	See tray for <i>Cut-down (paediatric)</i> , Annex 1.
-----------	--

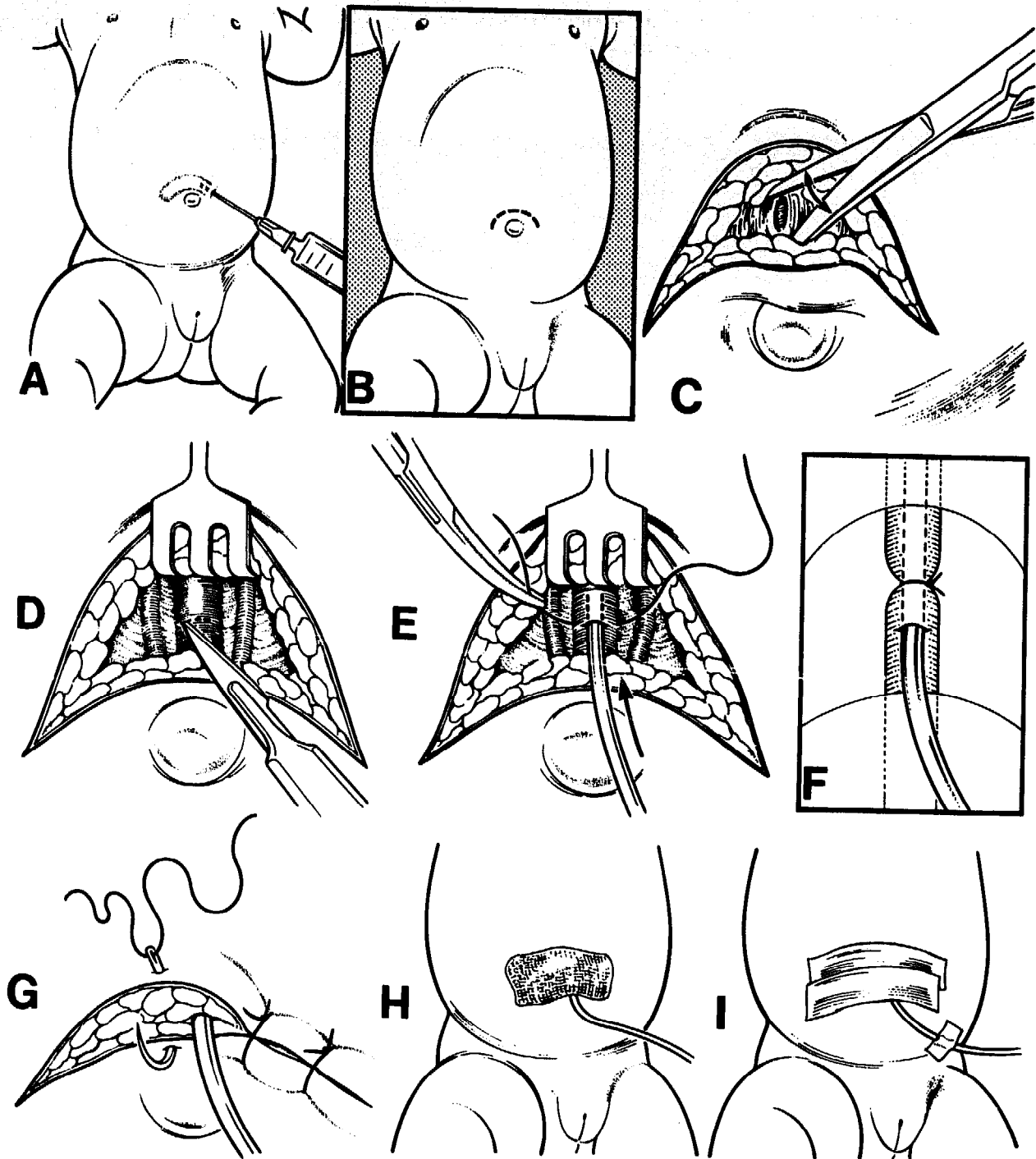


Fig. 21.1. Cut-down to umbilical vein. Infiltrating the skin and subcutaneous fat with local anaesthetic (A); site of curved incision just above the umbilicus (B); blunt dissection to isolate the umbilical vein (C); opening the umbilical vein, the largest of the three vessels (D); cannulating the vein (E, F); closing the wound in one layer (G); applying a dressing (H); fixing the cannula to the skin with adhesive tape (I).

Technique

Sedate the child, prepare the skin of the umbilical region with antiseptic, and infiltrate a small amount of local anaesthetic (Fig. 21.1A). Make a curved inci-

sion just above the umbilicus, keeping close to the umbilicus to avoid injury to the peritoneum (Fig. 21.1B).

Deepen the incision vertically by blunt dissection with scissors (Fig. 21.1C). Cannulate the vein, which can be identified as the largest of the three cord vessels, and secure the cannula in the vein with a ligature (Fig. 21.1D-F). Close the wound in one layer with 3/0 thread, apply a dressing, and fix the cannula to the skin with adhesive tape (Fig. 21.1G-I).

Should the peritoneal cavity be opened inadvertently, close the breach with catgut.

Abdominal wall and gastrointestinal tract

Operative reduction of intussusception

Intussusception is a form of intestinal obstruction in which one segment of the intestine telescopes into the next (Fig. 22.1A).

Assessment and preoperative management

The patient is usually less than 2 years of age, but intussusception in older children is not infrequent. The symptoms are intermittent crying and the passing of blood and mucus. A mass in the line of the large bowel will be detected on abdominal examination, and rectal examination will reveal blood and mucus.

Intussusception can be mimicked by dysentery or, less often, by a bolus of roundworms. It can be distinguished from rectal prolapse by rectal examination.

Before surgery, pass a nasogastric tube and begin suction. Give fluids intravenously.

Equipment

See tray for *Major paediatric operations*, Annex 1.

Technique

The patient should be given a general anaesthetic with a muscle relaxant. Place the child supine and prepare the skin with antiseptic. Open the abdomen through a midline incision centred at the umbilicus; the incision may be made either through or around the umbilicus (Fig. 22.1B).

After opening the peritoneum, locate and examine the intussusception. Make no attempt to reduce the telescoped bowel by pulling on its proximal end, but instead "milk" it in a retrograde manner with the fingers of one hand inside the abdomen pressing against the fingers of the other hand outside the abdomen (Fig. 22.1C,D). Once the bowel has been reduced into the ascending colon, deliver the colon through the wound and reduce the remaining intussusception slowly, inspecting the ensheathing layer for serosal and muscular tears (Fig. 22.1E).

If the intussusception is not fully reducible or if the bowel is gangrenous, resect the section of bowel involved and construct an anastomosis. Should anastomosis prove too difficult, exteriorize the two cut ends of bowel through the abdominal wall.

Close the wound in layers using catgut for the peritoneum and muscle, and thread for the skin. If the bowel ends have been exteriorized, arrange to refer the patient.

Complications

Possible complications include recurrence, and leakage from an anastomosis.

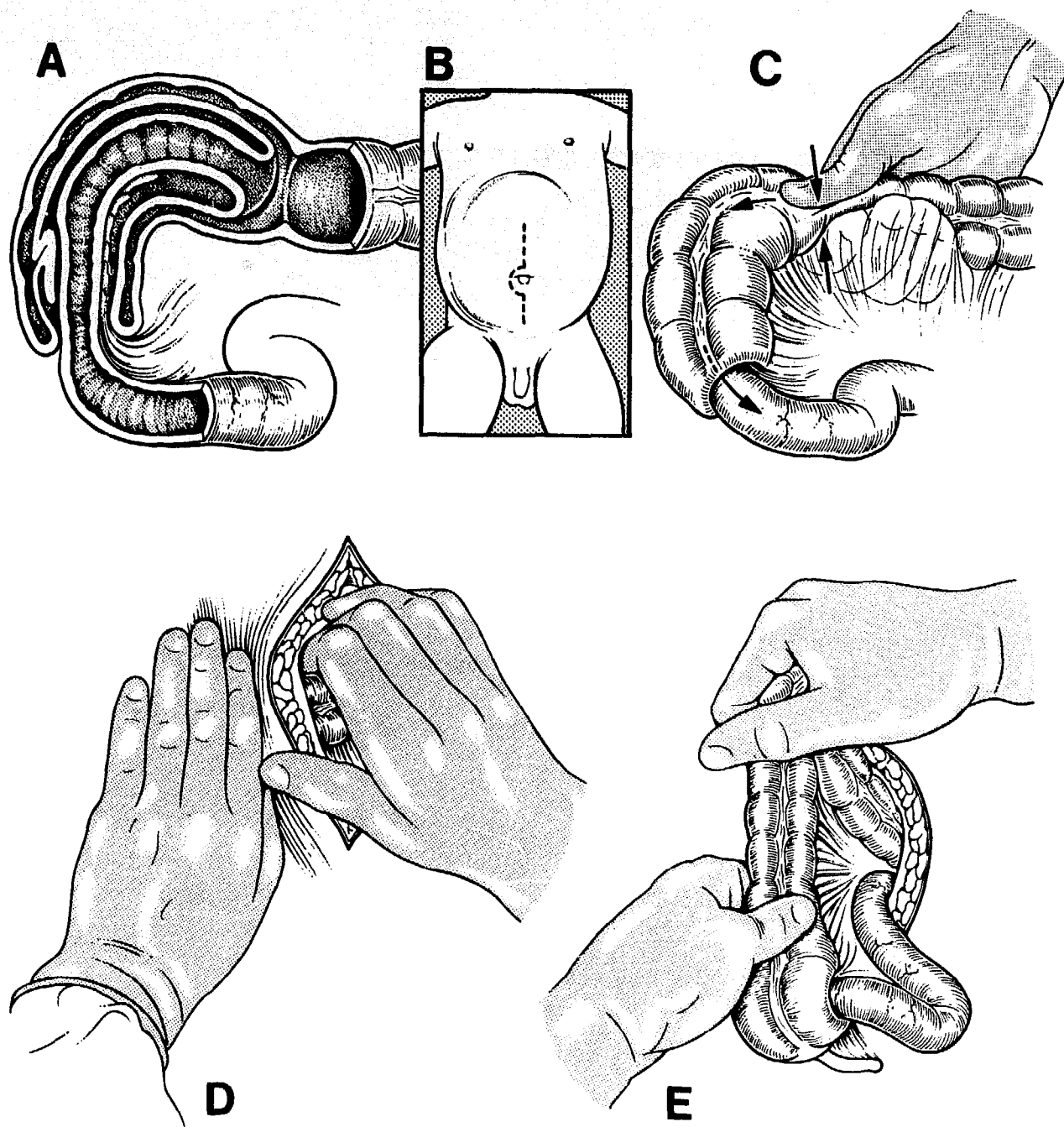


Fig. 22.1. Operative reduction of intussusception. Ileocolic intussusception (A); site of incision (B); "milking" the intussusception in a retrograde manner while supporting the abdominal wall with the other hand (C, D); delivering the colon through the wound and completing reduction (E).

Rectal prolapse

Rectal prolapse can occur in healthy children, but may also be associated with disturbed bowel action (caused by chronic malnutrition, diarrhoea, or constipation that necessitates straining on defecation), worms, or debility arising from some other illness. Rarely is it due to polyps.

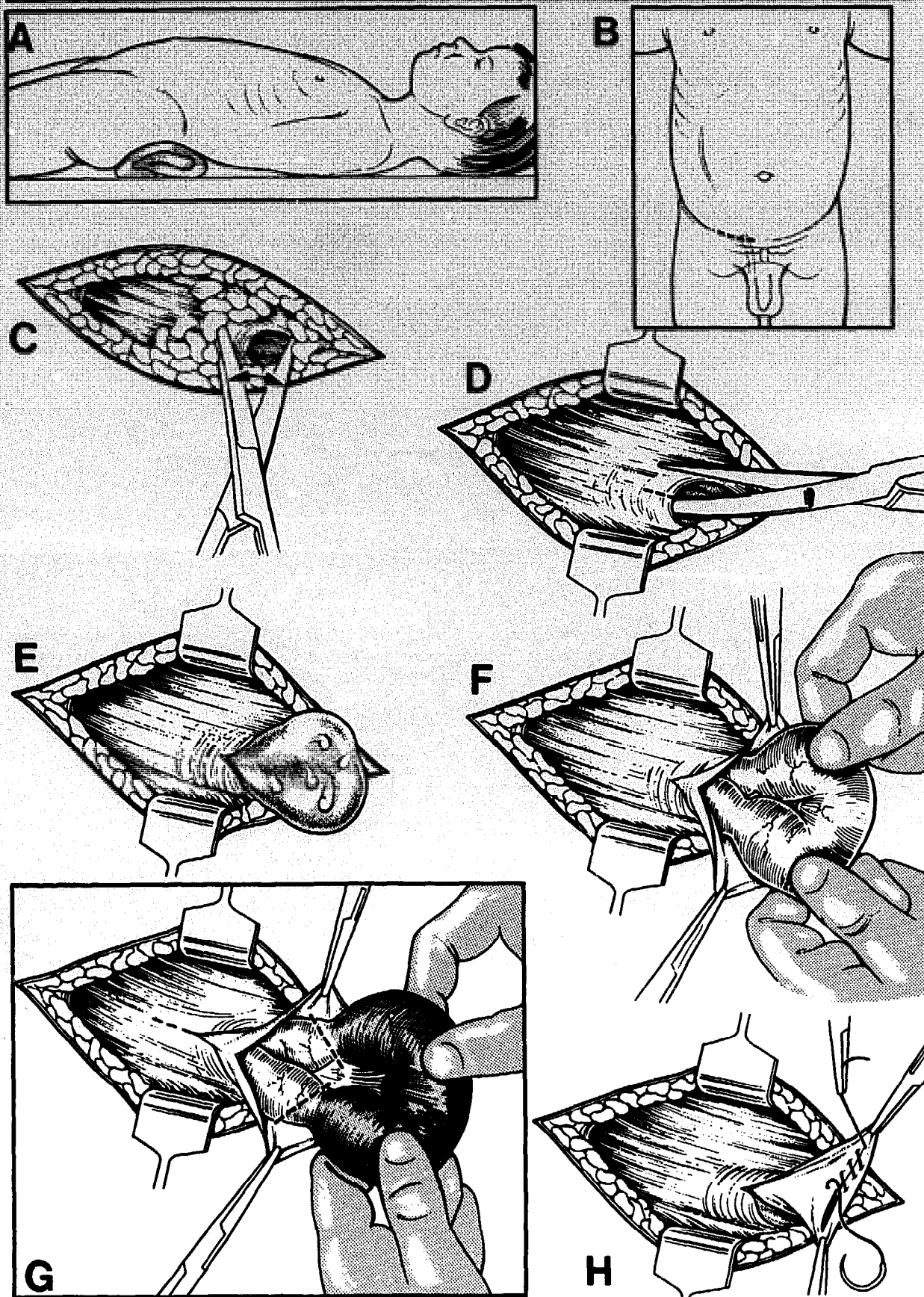


Fig. 22.2. Operative reduction of strangulated inguinal hernia. Position of the patient with the lumbar spine hyperextended (A); site of incision in the groin crease (B); blunt dissection to expose the external oblique aponeurosis and the external inguinal ring (C); dividing the anterior margin of the external inguinal sac to relieve the obstruction (D, E); opening the sac and inspecting the gut (F); site for resection of gangrenous gut and end-to-end anastomosis (G); closing the sac (H).

- Diagnosis** The prolapse occurs on defecation. Initially the prolapsed section of the rectum reduces spontaneously, but later it requires manual reduction; a prolapse may still occur immediately after such reduction. Rectal prolapse may be complicated by mucosal bleeding or even by strangulation with gangrene.
- Differential diagnosis should include large rectal polyps and submucosal venous congestion caused by excessive straining during defecation, although the latter condition is rare. A loose intussusception that appears at the anus may closely resemble a prolapsed section of rectum, but can be differentiated upon rectal and abdominal examination.
- Examine the stool for parasites. Other investigations should be carried out as indicated.
- Treatment** Correct any diarrhoea, constipation, or malnutrition. Provided that there are no complications, control the prolapse by prompt manual reduction and by strapping the child's bottom, if necessary. If the prolapse is complicated by strangulation with gangrene, perform a laparotomy, resect the gangrenous section of the rectum, construct a colostomy, and then refer the patient.

Relief of strangulated inguinal hernia

The relief of strangulated inguinal hernia is more difficult in young children than in adults because the tissues are smaller and more delicate, and the inguinal canal is extremely short. The obstructing ring is usually the external rather than the internal inguinal ring.

Non-operative reduction See page 160.

Operative reduction

Equipment See tray for *Minor paediatric operations*, Annex 1.

Technique The patient should be given a general anaesthetic. Place a roll of 7–12 cm diameter (depending on the size of the patient) under the pelvis to hyperextend the lumbar spine (Fig. 22.2A). Prepare the skin over the lower half of the abdomen, including the groin, with a bland antiseptic such as cetrimide.

In the male patient, palpate the spermatic cord as it passes over the pubic bone and make an incision in the groin crease just above this point (Fig. 22.2B); in the female patient, make a groin incision in a skin crease over the swelling. Extend the incision laterally, dividing only the skin.

Continue with blunt dissection using scissors held at right angles to the skin incision. Expose the external oblique aponeurosis and external inguinal ring and divide the anterior margin of the ring with scissors, taking care not to puncture the herniated mass (Fig. 22.2C–E). This will relieve the obstruction.

If the bowel in the hernial sac appears dark, open the sac and inspect the bowel (Fig. 22.2F). If normal colour returns, reposition the gut in the abdomen and close the sac with continuous catgut suture. A gangrenous section of bowel will be very dark in colour, with a dull surface and an absence of peristalsis or arterial pulsation. In such cases, extend the exposure of the inguinal canal and pull down some healthy bowel. Then resect the gangrenous bowel (Fig. 22.2G), make a one-layer anastomosis using 3/0 thread, and close the hernial sac with continuous catgut suture.

Whether or not the hernial sac has been opened, it should not be removed. Simply reduce the hernia and close the wound in two layers, suturing the deeper layer of subcutaneous fat with interrupted 2/0 or 3/0 chromic catgut. In the male patient ensure that the testis remains in the scrotum throughout wound closure. It may have become infarcted, but should not be removed. Apply a single layer of gauze dressing once the wound is closed.

After-care Continue nasogastric suction and the intravenous administration of fluids until normal peristalsis has returned. Make arrangements to refer the child for elective herniotomy.

Urethra and genital organs

Meatal dilatation

Meatal dilatation is used to treat meatal stricture in young boys. This condition is most common when the glans has been uncovered in infancy by circumcision or when the foreskin is of insufficient length to cover the meatus. Indeed, it is a common complication of infantile circumcision. Most affected children require no treatment, but dilatation is indicated if there is difficulty or pain on passing urine.

The child often complains of pain at the tip of the penis when urinating. The urinary stream is thin, under high pressure, and goes farther than normal. The child is unable to urinate into a container without holding his penis. Physical examination will reveal a narrow, circular, external urethral meatus, the opening of which may be a mere pin-hole (Fig. 23.1A). There is usually evidence of circumcision or a foreskin too short to cover the glans.

Before proceeding, examine the urine to rule out the possibility of infection.

Equipment See tray for *Meatal dilatation (paediatric)*, Annex 1.

Technique Dilatation should be done gently to avoid tearing the tissue of the stricture. Such tears heal with fibrous tissue, which can aggravate the stricture.

The patient should be given a general anaesthetic. Prepare the external genitalia and the perineum with a bland antiseptic and apply a perforated towel. Holding the penis erect, insert the tip of a pair of lubricated artery forceps (small mosquito type) as a dilator. Allow the tip of the forceps to enter the urethra largely under gravity; apply only very light pressure. The dilator should not pass beyond the middle of the shaft of the penis (Fig. 23.1B,C). When it stops, leave it for 3 min, and then remove it. Repeat the procedure twice.

After-care If the stricture is very tight, repeat dilatation at least once a week for 1 month and then once a month for 6 months, until the meatus is of normal size.

Exploration of scrotal contents

At the district hospital, exploration of the scrotal contents should be confined to patients with an acutely painful scrotal swelling, when it is necessary to explore the testis, the epididymis, or the distal part of the spermatic cord. Suspected torsion of the testis requires immediate exploration.

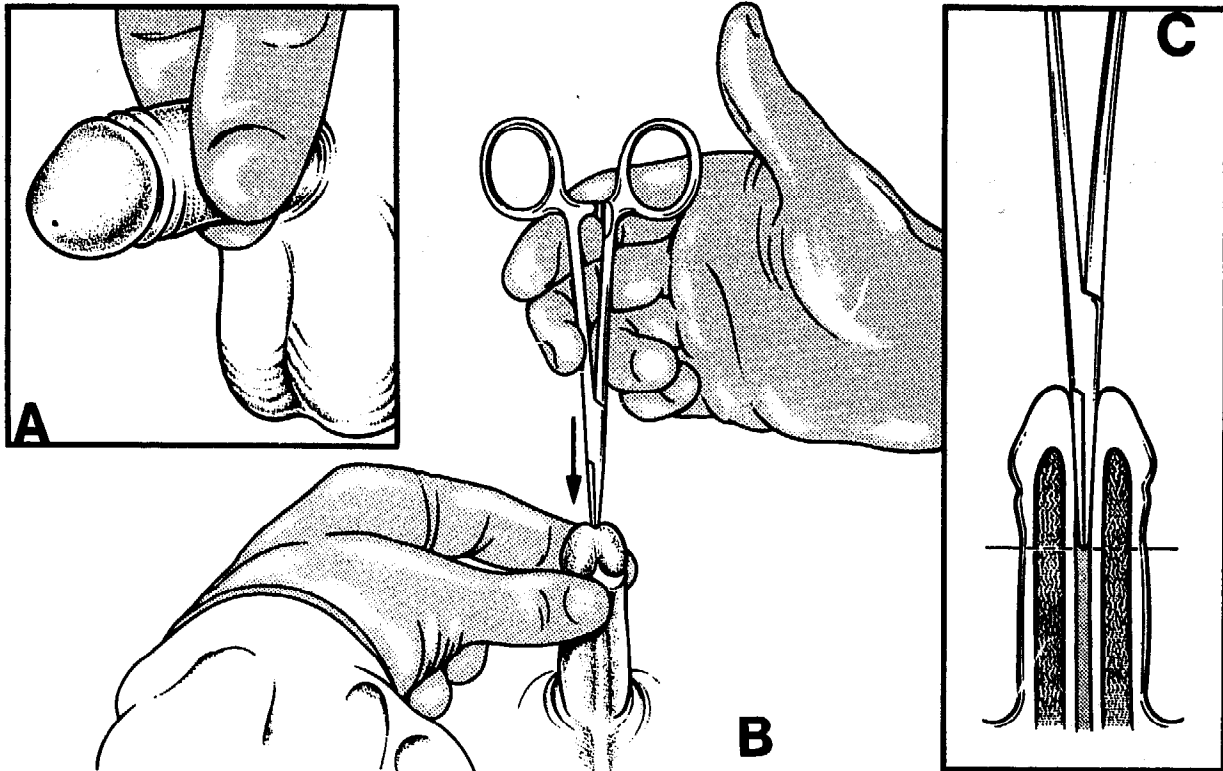


Fig. 23.1. Meatal dilatation. Pin-hole meatus (A); dilatation with the lubricated tip of a pair of artery forceps: the forceps enter the urethra largely under gravity (B) and should not pass beyond the middle of the shaft of the penis (C).

Differential diagnosis includes torsion of the testis and acute epididymo-orchitis, which can also occur in adults. The latter (which can be difficult to confirm clinically) does not require operation.

Equipment See tray for *Minor paediatric operations*, Annex 1.

Technique The patient should be given a general anaesthetic. Prepare the external genitalia and adjacent perineum with a bland antiseptic. Make a scrotal incision to expose the testis, and continue through the tunica vaginalis (Fig. 23.2A,B).

If torsion is confirmed, untwist the testis (Fig. 23.2C) and wait at least 5 min to see whether circulation will return. If the testis was black before being untwisted and remains black even after this time has elapsed, doubly ligate the spermatic cord and remove the testis (Fig. 23.2D). If the testis is plum-coloured, but not definitely gangrenous, or if it is clearly viable, fix the tunica albuginea to the scrotal septum with two stitches (Fig. 23.2E) and, through a separate incision, fix the other testis similarly. Repair the scrotum in two layers with fine catgut (Fig. 23.2F) and apply a firm dressing to hold it elevated.

Torsion of an appendix testis presents a milder clinical picture. At operation, the testis appears normal with a small, dark, berry-like lesion on the surface near its superior pole. This small lesion can be easily removed.

If epididymo-orchitis is found in the course of exploration, reposition the scrotal contents, repair the wound, and administer co-trimoxazole (sulfamethoxazole + trimethoprim).

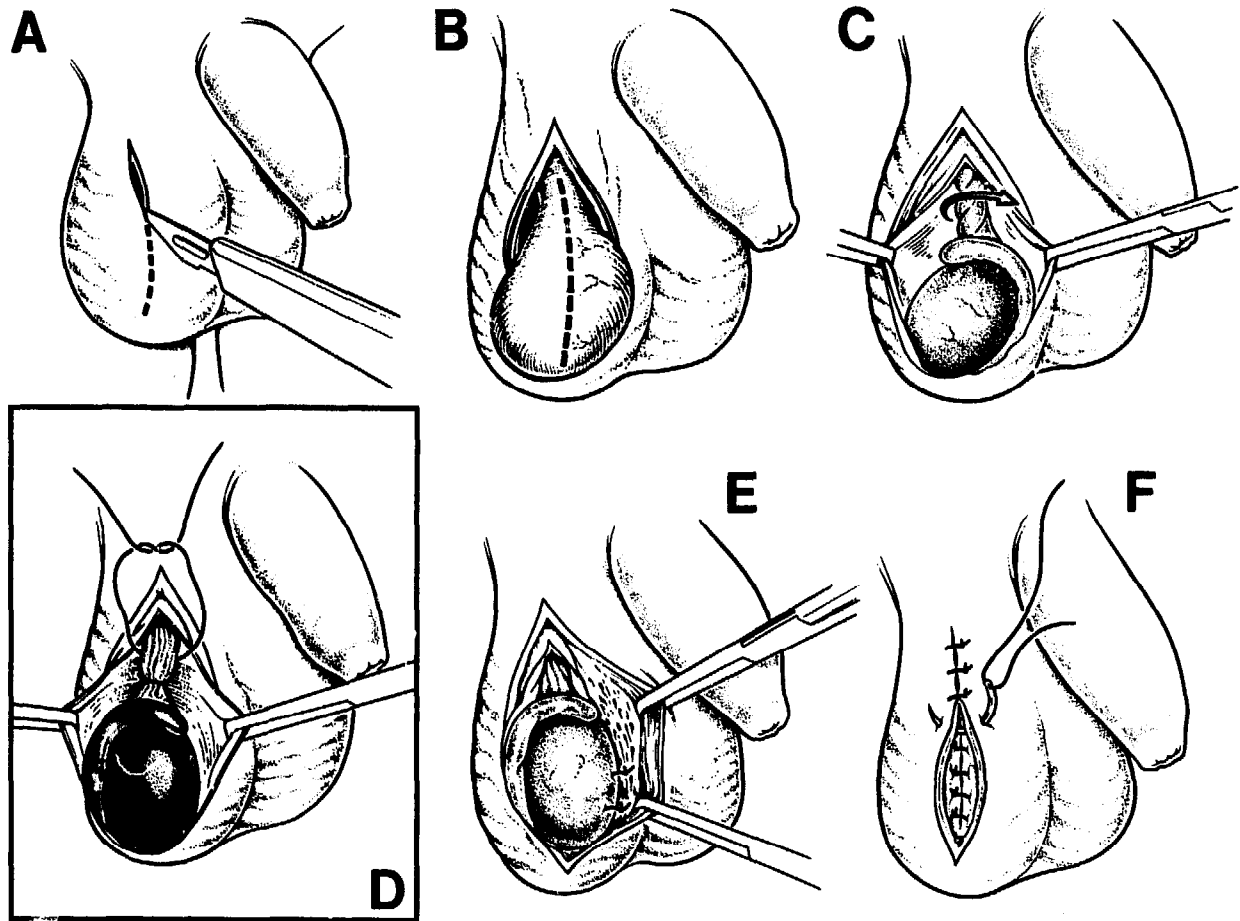


Fig. 23.2. Treatment of torsion of the testis. Making the first incision (A); site of incision in the tunica vaginalis (B); torsion of the testis, to be untwisted in the direction of the arrow (C); excising a gangrenous (black) testis and doubly ligating the cord (D); fixing the tunica albuginea of a non-gangrenous testis to the scrotal septum (E); and closing the wound in two layers (F).

Complications

Avoid haematoma by careful two-layer repair. Minimize the use of scrotal drains to reduce the risk of infection. To reduce scrotal swelling and pain, support the scrotum by bandaging it first against the lower abdomen.

Treatment of paraphimosis

In this condition the penile foreskin is retracted, swollen, and painful. The glans penis is visible, surrounded by an oedematous ring with a proximal constricting band (Fig. 23.3A).

Differential diagnosis should include inflammation of the foreskin (balanitis), for example due to infection, and swelling caused by an insect bite. In such cases, the glans penis is not visible.

Treat paraphimosis by reduction of the foreskin or, should this fail, by circumcision.

Equipment

See tray for *Minor paediatric operations*, Annex 1, and add 1% lidocaine.

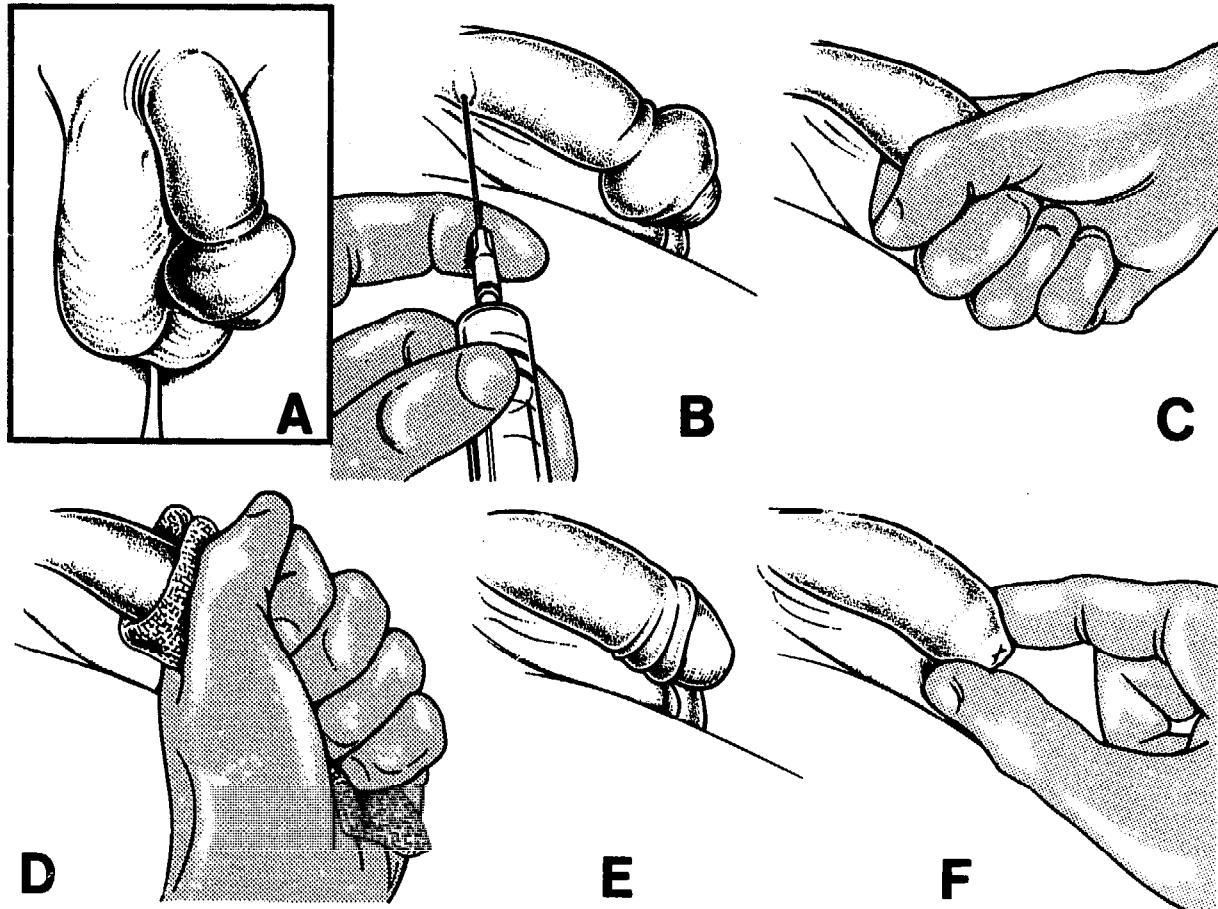


Fig. 23.3. Reduction of paraphimosis. The affected penis (A); injecting local anaesthetic in a ring around the base (B); squeezing the oedematous part of the penis (C, D); the foreskin (E) is pulled over the glans (F).

Technique

Sedate the child and prepare the skin of the genitalia with a bland antiseptic. Isolate the penis with a perforated towel and inject local anaesthetic in a ring around its base (Fig. 23.3B). Once local analgesia is achieved, take hold of the oedematous part of the penis in the fist of one hand and squeeze firmly; a gauze swab may be necessary for a firm grip (Fig. 23.3C,D). Exert continuous pressure, changing hands if necessary, until the oedema fluid passes proximally under the constricting band to the shaft of the penis. The foreskin can usually then be pulled over the glans (Fig. 23.3E,F). If this manoeuvre fails to reduce the foreskin, carry out circumcision with the patient under general anaesthesia.

Annex 1

Surgical trays

This annex lists the instruments, equipment, and materials that should be included, as a minimum, on the surgical trays used for the procedures described in this handbook. These items (with certain exceptions, such as head mirrors and torches) must be sterilized before use. For most procedures, dressings and drugs, apart from local anaesthetics, are not listed.

Appendicectomy

Sponge forceps, 4 pairs
Scalpel handle with blade, 1
Small, curved artery forceps, 3 pairs
Small, straight artery forceps, 3 pairs
Large, straight artery forceps, 2 pairs
Large, curved artery forceps, 2 pairs
Dissecting scissors, 1 pair
Stitch scissors, 1 pair
Needle holder, 1
Dissecting forceps, toothed, 1 pair
Dissecting forceps, non-toothed, 1 pair
Retractors (Langenbeck), narrow, 2
Tissue forceps (Allis), 2 pairs
Suction nozzle, 1
Diathermy electrode, 1
Sutures, 0 and 2/0 thread, ties and with needles
Sutures, 0 and 2/0 chromic catgut, ties and with needles
Sutures, No. 1 nylon, ties and with needles
Kidney dishes, 2
Gallipots, 2
Linen tape, 1 piece, 20–30 cm long
Gauze swabs
Antiseptic solution
Sterile drapes
Sterile gloves, 2 pairs

Bladder catheterization

Catheters (for example Foley or similar type), several different sizes
Catheter, coudé, 1
Urinary bag or bottle, 1, with connecting tube and tube-connection piece, containing antiseptic solution, sterile water, or sterile saline
Lubricant
Lidocaine gel
Gauze swabs
Large, curved artery forceps, 1 pair
Syringe, 10 ml, 1
Sterile water in a gallipot
Kidney dish, 1
Antiseptic solution

Adhesive tape
 Sutures, 2/0 thread, ties
 Sterile drapes (perforated towel)
 Sterile gloves, 1 pair
 Set of bougies

Cataract operation Scalpel handle with No. 11 blade (or a keratome, if available), 1
 Spring scissors (Westcott), 1 pair
 Straight ring scissors, 1 pair
 Corneal scissors, right and left, 1 pair of each
 Dissecting forceps, toothed with tying platform, 0.5 mm, 1 pair
 Dissecting forceps, toothed with tying platform, 0.9 mm, 1 pair
 Syringe, 2 ml, 1, with 23- and 19-gauge needles
 Syringe, 10 ml, 1, with 23- and 19-gauge needles
 Needle holder for fine suture, curved with lock (Castroviejo), 1
 Muscle hooks, 2
 Eyelid speculum, 1
 Sutures, 3/0, 4/0, and 8/0 thread, ties and with needles
 Irrigating cannula, 1
 Ophthalmic swabs
 Eye pad, 1
 Lidocaine 2%
 Tetracaine 0.5% eye drops
 Sterile saline
 Cetrimide 1%
 Adhesive tape
 Conjunctival scissors
 Iris forceps, 1 pair
 Iris scissors, 1 pair
 Capsule forceps, non-toothed, 1 pair
 Vectis, 1
 Cystotome, 1
 Iris spatula (repositor), 1
 Iris retractor, 1
 Needle, 28-gauge, 1
 Sterile drapes
 Sterile gloves, 2 pairs
 Hot-point cautery and spirit lamp, 1

Control of epistaxis Good light source and reflecting head mirror
 Nasal speculum, 1
 Gauze swabs
 Cotton wool
 Ice
 Angled dressing forceps, 1 pair
 Clothes-peg, 1
 Suction nozzle, 1
 Catheter, Foley, size 16 Ch., 1

Cut-down (paediatric) Intravenous cannula, paediatric size, 1
 Small artery forceps, 6 pairs
 Small dissecting scissors, 1 pair
 Stitch scissors, 1 pair
 Small dissecting forceps, toothed, 1 pair
 Small dissecting forceps, non-toothed, 1 pair
 Needle holder, 1

Sutures, 3/0 catgut, ties and with needles
Sutures, 3/0 thread, ties and with needles
Antiseptic solution
Gauze swabs
Small kidney dish, 1
Gallipot, 1
Adhesive tape
Lidocaine 1%
Syringe, 2 ml or 5 ml with needle, 1
Scalpel handle with blade, 1
Sterile drapes (perforated towel)
Sterile gloves, 1 pair

Enucleation of the eye

Small artery forceps, 6 pairs (3 straight, 3 curved)
Eyelid speculum, 1
Eyelid retractors, 2
Dissecting forceps, toothed, 0.5 mm, 1 pair
Dissecting forceps, toothed, 0.9 mm, 1 pair
Conjunctival scissors, 1 pair
Stitch scissors, 1 pair
Needle holder, 1
Scalpel handle, 1, with No. 11 and 15 blades
Muscle hooks, 2
Enucleation scissors, 1 pair
Lidocaine 2%
Tetracaine 0.5% eye drops
Syringe, 10 ml, 1, with 23- and 19-gauge needles
Tetracycline 1% eye ointment
Irrigating cannula, 1
Sterile saline
Ophthalmic swabs
Eye pad, 1
Sutures and ligatures, 4/0, 5/0, and 6/0 plain and chromic catgut,
ties and with needles
Sterile drapes
Sterile gloves, 2 pairs

Excision of pterygium

Eyelid speculum, 1
Conjunctival forceps, 1 pair
Conjunctival scissors, 1 pair
Scalpel handle with No. 15 blade, 1
Tetracaine 0.2% eye drops
Lidocaine 2%
Hot-point cautery and spirit lamp, 1
Pterygium knife, 1
Syringe, 5 ml with needle, 1
Ophthalmic swabs
Sterile drapes
Sterile gloves, 1 pair

Extraction of teeth

Dental probe/spoon, 1
Straight elevator, 1
Curved elevators, 2 (right and left)
Dental forceps, universal upper, 1 pair
Dental forceps, universal lower, 1 pair
Syringe, 5 ml with 25-gauge/25 mm needles

Lidocaine 2% with epinephrine 10 or 12.5 µg/ml (1:100 000 or 1:80 000)
 Dissecting forceps, non-toothed, 1 pair
 Needle holder, 1
 Suture, 0 chromic catgut on 30 mm needle
 Stitch scissors, 1 pair
 Gauze swabs
 Dental rolls
 Large kidney dish, 1
 Dental mirror, 1
 Warm saline or other mouthwash
 Sterile drapes
 Sterile gloves, 1 pair
 Ethanol, 70%

Hernia operation

Sponge forceps, 4 pairs
 Scalpel handle with blade, 1
 Needle holder, 1
 Small, straight artery forceps, 4 pairs
 Small, curved artery forceps, 4 pairs
 Large, straight artery forceps, 3 pairs
 Large, curved artery forceps, 3 pairs
 Tissue forceps (Allis), 2 pairs
 Curved dissecting scissors, 1 pair
 Stitch scissors, 1 pair
 Retractors (Langenbeck), narrow, 2
 Rake retractors, 2 (or self-retaining type, 1)
 Dissecting forceps, toothed, 1 pair
 Dissecting forceps, non-toothed, 1 pair
 Sutures, 0 and 2/0 chromic catgut, ties and with needles
 Sutures, No. 1, 0, and 2/0 thread, ties and with needles
 Gauze swabs
 Gallipots, 2
 Kidney dishes, 2
 Adhesive tape
 Linen tape
 Antiseptic solution
 Adhesive tape
 Diathermy electrode, 1
 Crushing clamps, 2
 Occlusion clamps, 2
 Sterile drapes
 Sterile gloves, 3 pairs

Incision and drainage of abscess

Sponge forceps, 4 pairs
 Scalpel handle with blade, 1
 Lidocaine 1%
 Syringe, 5 ml with needle, 1
 Dissecting scissors, 1 pair
 Stitch scissors, 1 pair
 Needle holder, 1
 Small, curved artery forceps, 3 pairs
 Large, curved artery forceps, 2 pairs
 Large, straight artery forceps, 2 pairs
 Sinus forceps, 1 pair
 Grooved director, 1
 Flexible probe, 1
 Corrugated drain

	<p>Safety pins, 2 Petrolatum gauze Syringe, 10 ml with wide-bore needle, 1 Dissecting forceps, toothed, 1 pair Dissecting forceps, non-toothed, 1 pair Gallipot, 1 Kidney dish, 1 Antiseptic solution Gauze swabs Cotton wool Specimen bottles, 2 (1 containing formaldehyde in saline) Sutures, 2/0 chromic catgut, ties and with needle Sutures, 2/0 thread, ties and with needle Sterile drapes Sterile gloves, 2 pairs</p>
Incision and drainage of peritonillar/retropharyngeal abscess	<p>Sponge forceps, 4 pairs Good light source Long, narrow (No. 5) scalpel handle with a narrow (No. 11) blade, 1 (most of the blade should be covered with adhesive tape, to leave only a small cutting portion at the tip) Syringe, 10 ml with wide-bore needle, 1 Local (surface) anaesthetic spray, e.g. lidocaine 2-4% Gauze swabs Cotton wool Artery forceps with fine-pointed jaws or sinus forceps, 1 pair Suction nozzle, 1 Tongue depressor, 1 Sterile drapes Sterile gloves, 1 pair</p>
Intercostal nerve block	<p>Lidocaine 1% with epinephrine or bupivacaine 0.25% with or without epinephrine Syringe, 10 ml, 1, with hypodermic and intramuscular (long) needles Gauze swabs Antiseptic solution Kidney dish, 1 Gallipot, 1 Sterile drapes Sterile gloves, 1 pair</p>
Interdental wiring	<p>Straight artery forceps, 1 pair Strong scissors (or wire cutters), 1 pair Large kidney dish, 1 Soft, stainless-steel wire, 0.35 mm thick Gauze swabs Warm saline Lidocaine 2% with epinephrine 10 or 12.5 µg/ml (1:100 000 or 1:80 000) Syringe, 5 ml with needle, 1</p>
Laparotomy	<p>Curved dissecting scissors, 1 pair Scalpel handle and blade, 1 Short dissecting scissors, 1 pair</p>

Long dissecting scissors, 1 pair
 Stitch scissors, 1 pair
 Small, curved artery forceps, 6 pairs
 Small, straight artery forceps, 6 pairs
 Large, curved artery forceps, 6 pairs
 Large, straight artery forceps, 6 pairs
 Needle holder, long, 1
 Needle holder, short, 1
 Retractors (Langenbeck), medium, 1; narrow, 1
 Retractors (Deaver), medium, 1; narrow, 1
 Self-retaining retractor, 1
 Dissecting forceps, toothed, 1 pair
 Long dissecting forceps, non-toothed, 1 pair
 Tissue forceps (Allis), 2 pairs
 Tissue forceps (Duval), 2 pairs
 Tissue forceps (Babcock), 2 pairs
 Sponge forceps, 4 pairs
 Malleable copper retractors (spatulae), 2
 Occlusion clamps, straight, 2; curved, 2
 Crushing clamps, large, 2; small, 2
 Syringe, 10 ml with needle, 1
 Syringe, 20 ml with needle, 1
 Sutures, No. 1, 0, and 2/0 chromic catgut and 2/0 plain catgut, ties and with needles
 Sutures, No. 1, 0, 2/0, and 3/0 thread, ties and with needles
 Sutures, No. 1, 0, and 2/0 nylon, ties and with needles
 Suction nozzle, 1
 Diathermy electrode, 1
 Flexible probe, with round point, 1
 Grooved director, 1
 Nasogastric tube, 1
 Towel clips, 6
 Stainless-steel bowls, 2
 Kidney dishes, 2
 Gallipots, 2
 Linen tape
 Gauze swabs
 Abdominal packs, 5
 Dissecting gauze rolls, 10
 Antiseptic solution
 Adhesive tape
 Tubing for tension sutures
 Drainage tubes
 Safety pin, 1
 Colostomy bags (optional)
 Sterile drapes
 Sterile gloves, at least 3 pairs

Major paediatric operations

Add the following to the tray for *Minor paediatric operations*:

Small, straight artery forceps, 2 pairs
 Small, curved artery forceps, 2 pairs
 Large, straight artery forceps, 4 pairs
 Large, curved artery forceps, 4 pairs
 Occlusion clamps, 2
 Crushing clamps, 2
 Retractor (Deaver), narrow, 1

	Sterile drapes Sterile gloves, 1 pair
Removal of foreign body from the ear	Good light source and reflecting head mirror Auriscopes, 1 Syringe, 1 Aural curette and hook, 1 set Water Glycerol Piece of soft rubber tubing
Removal of nasal foreign body	Good light source and reflecting head mirror Nasal speculum, 1 Small hook on long handle (aural hook), 1 Angled dressing forceps, 1 pair Gauze swabs Cotton wool Piece of soft rubber tubing
Sigmoidoscopy	Sigmoidoscope, with rubber pump, 1 Light source with cable to fit sigmoidoscope, 1 Proctoscope, 1 Biopsy forceps (of correct length for sigmoidoscope), 1 pair Lubricant Torch Gauze swabs Small cotton swabs (dental rolls) Stool specimen bottle, 1 Glass slides, 4 Biopsy specimen bottle, 1 Clean gloves, 1 pair
Skin grafting	Skin-grafting knife, Humby, with blade, 1 Scalpel handle with No. 10 blade, 1 Razor blade, 1 Sponge forceps, 2 pairs Towel clips, 4 Small, straight artery forceps, 6 pairs Small, curved artery forceps, 6 pairs Dissecting forceps, non-toothed, 2 pairs Dissecting forceps, toothed, 2 pairs Dissecting scissors, straight, 1 pair Dissecting scissors, curved, 1 pair Dissecting scissors (Metzenbaum), 1 pair Hook retractors, small, 2 pairs Stitch scissors, 1 pair Tissue forceps (Allis), 2 pairs Skin hooks, 4 Gallipots, 2 Ruler, 1 Petrolatum gauze Wooden boards with bevelled edges, 4 Antiseptic solution

Gauze swabs
 Gauze packs (abdominal packs)
 Cotton wool
 Sterile drapes
 Sterile gloves, 2 pairs

Suprapubic puncture Add the following to the tray for *Bladder catheterization*:

Syringe, 50 ml with wide-bore intramuscular needle, 1
 Syringe, 10 ml, 1, with hypodermic and intramuscular needles
 Lidocaine 1%
 Suprapubic trocar and cannula, 1
 Scalpel handle with blade, 1
 Needle holder, 1
 Stitch scissors, 1 pair
 Suture, 2/0 thread, with needle
 Catheter introducer, 1
 Catheter, de Pezzer, 1

Tarsorrhaphy Tetracaine 0.5% eye drops
 Lidocaine 2%
 Syringe, 5 ml with needle, 1
 Eyelid speculum, 1
 Dissecting forceps, toothed, 2 pairs
 Straight scissors, 1 pair
 Stitch scissors, 1 pair
 Needle holder, 1
 Scalpel handle with No. 15 blade, 1
 Suture, 4/0 thread, with needle
 Soft rubber tubing
 Sterile saline
 Ophthalmic swabs
 Eye pads
 Sterile drapes
 Sterile gloves, 1 pair

Tracheostomy Sponge forceps, 4 pairs
 Metal tracheostomy set (with inner and outer tubes and obturator), 1
 Lidocaine 1%
 Scalpel handle with blade (preferably No. 11), 1
 Syringe, 5 ml with needle, 1
 Suction nozzle, 1
 Sutures, 2/0 chromic catgut, ties and with needles
 Sutures, 2/0 thread, ties and with needles
 Linen tape
 Gauze swabs
 Small artery forceps, 4 pairs
 Large artery forceps, 2 pairs
 Small hook retractors, 2
 Small skin hooks, 2
 Needle holder, 1
 Dissecting forceps, toothed, 1 pair
 Antiseptic solution
 Sterile drapes
 Sterile gloves, 2 pairs
 Stethoscope with bell attachment

Treatment of entropion

Eyelid retractor, 1
Eyelid clamp or Trabut plate, 1
Scalpel handle with No. 15 blade, 1
Dissecting forceps, toothed, 1 pair
Fine ophthalmic scissors, 1 pair
Needle holder, 1
Suture, 4/0 thread, with needle
Stitch scissors, 1 pair
Ophthalmic swabs
Eye pad, 1
Adhesive tape
Syringe, 5 ml with needle, 1
Lidocaine 2%
Sterile saline
Tetracaine 0.5% eye drops
Sterile drapes
Sterile gloves, 1 pair

Underwater-seal chest drainage

Sponge forceps, 4 pairs
Chest-drainage tube, 1
Sterile tubing with connector
Calibrated chest-drainage bottle with appropriate fittings,
containing sterile water, saline, or antiseptic solution, 1
Large, curved artery forceps, 1 pair
Large, straight artery forceps, 1 pair
Small, curved artery forceps, 3 pairs
Scalpel handle with blade, 1
Needle holder, 1
Suture, 2/0 thread on a cutting needle
Syringe, 10 or 20 ml with needle, 1
Syringe, 5 ml with needle, 1
Stitch scissors, 1 pair
Dissecting forceps, toothed, 1 pair
Lidocaine 1%
Antiseptic solution
Gauze swabs
Gallipot, 1
Kidney dish, 1
Face mask, 1
Adhesive tape
Sterile drapes
Sterile gloves, 2 pairs

Urethral dilatation

Add the following to the tray for *Bladder catheterization*:

Curved bougies, 1 set
Straight bougies, 1 set
Filiform bougies, 1 set
Soft penile clamp, 1
Lidocaine gel

Annex 2

Essential surgical instruments, equipment, and materials for the district hospital

This annex lists the instruments, equipment, and materials needed, as a minimum, for the practice of general surgery in the district hospital. It contains all the items listed in Annex 1, with the exception of local anaesthetics, containers for laboratory specimens, and chemical products such as antiseptics and lubricants. It also includes operating-room and anaesthetic equipment, and instruments required for the surgical procedures described in *Surgery at the district hospital: obstetrics, gynaecology, orthopaedics, and traumatology* (Geneva, World Health Organization, in preparation).

Surgical instruments

	<i>Quantity</i>	<i>Size</i>
General instruments		
Sponge forceps (Rampley)	4	25 cm
Instrument pins (Mayo)	4	
Towel clips (Backhaus)	6	11 cm
Artery forceps (Crile): straight	6	16 cm
curved	6	16 cm
Artery forceps (mosquito): straight	6	13 cm
curved	6	13 cm
Curved artery forceps (Mayo or Kelly)	6	20 cm
Straight artery forceps (Spencer Wells)	6	20 cm
Tissue forceps (Allis)	4	15 cm
Standard dissecting forceps: toothed	2	14.5 cm
non-toothed	2	14.5 cm
Long dissecting forceps, toothed	1	25 cm
Long dissecting forceps, non-toothed	1	25 cm
Straight dissecting scissors (Mayo)	2	17 cm
Curved dissecting scissors (Mayo)	1	23 cm
Dissecting scissors (Metzenbaum)	1	18 cm
Stitch scissors, with blunt ends	2	15 cm
Rake retractors (Volkman), 4-toothed	2	22 cm
Rake self-retaining retractors	2	21 cm
Retractors (Langenbeck): narrow	2	6.0 mm wide
medium	2	9.5 mm wide
Retractors (Deaver): medium	1	25 mm blade
large	1	75 mm blade
Hook retractors	2	15 cm
Needle holders (Mayo): medium	2	15 cm
large	2	17.5 cm
Scalpel handles No. 3 (Bard-Parker)	12	
Scalpel handles No. 4 (Bard-Parker)	12	
Scalpel handles No. 5 (Bard-Parker)	4	
Suction nozzle (Yankauer)	1	28.5 cm
Nozzle (Poole-Wheeler)	1	

		<i>Quantity</i>	<i>Size</i>
	Diathermy electrodes, coagulating and fulgurating	2	
	Flexible probe, with round point	1	20 cm
	Grooved director (Kocher)	1	20 cm
	Stainless-steel sponge bowls: small	6	
	medium	6	
	large	6	
	Stainless-steel kidney dishes: small	4	
	medium	4	
	large	4	
	Stainless-steel gallipots	2	
	Sinus forceps	2	
Abdominal instruments	Self-retaining retractor with 3 blades (Balfour)	1	
	Proctoscope (anal speculum, Goligher):		
	child-size	1	6 cm
	adult-size	1	7.5 cm
	Sigmoidoscope, complete with pump: child-size	1	
	adult-size	1	
	Light source with cable, to fit sigmoidoscope	1	
	Biopsy forceps	2	
	Clamps (Moynihan), box-joint	6	23 cm
	Gallbladder trocar and cannula (Ochsner)	1	
	Gallstone forceps (Desjardin)	1	
	Malleable probe and scoop (Moynihan)	1	
	Lacrimal probes, set of 3	1	
	Tissue forceps (Duval): medium	2	15.5 cm
	large	2	19 cm
	Crushing clamps (Payr): small	2	21 cm
	large	2	36 cm
	Crushing clamps (Schoemaker): small	2	17 cm
	large	2	20 cm
	Malleable copper retractors (spatulae)	2	
	Occlusion clamps (Doyen): straight	2	22.5 cm
	curved	2	22.5 cm
	Twin occlusion clamps (Lane)	1	31.8 cm
	Intestinal tissue-holding forceps (Babcock)	4	24.0 cm
	Glass rods	2	
Chest instruments	Chest-drainage set, including tube and calibrated bottle	1	
Craniotomy instruments	Self-retaining rake retractors (West)	2	
	Periosteal elevator (Farabeuf)	1	
	Dissector (Macdonald)	1	
	Brace (Hudson), burrs and perforators with 3 sizes of bits	1 set	
	Bone forceps (De Vilbis)	1	
Dental, plastic surgery, and maxillo-facial instruments	Standard skin-grafting knife (Humby), with spare blades	1	
	Electric dermatome	1	
	Wooden skin-grafting boards	4	
	Pin-cutting forceps	1	
	Straight bone-awl (Kelsey Fry)	1	

		<i>Quantity</i>	<i>Size</i>
	Straight elevator (Warwick James or modified Kelsey Fry)	1	
	Curved elevators: right	1	
	left	1	
	Dental mirror	1	
	Dental forceps: universal upper	1	
	universal lower	1	
	Wire cutters	1	
	Skin hooks (Gillies)	4	
	Small hook retractors	2	
	Fine dissecting forceps: toothed	1	
	non-toothed	1	
	Curved artery forceps (Crile)	6	14 cm
	Handle holder (Mayo-Hegar) or needle holder (Gillies)	1	15 cm
	Dental probes/spoons	2	
Gynaecology instruments	Vaginal specula (Sims): small	1	1
	large	1	3
	Weighted vaginal speculum (Auvard)	1	38 × 75 mm
	Vulsellum forceps (Teale or Duplay)	2	28 cm
	Episiotomy scissors	2	
	Vacuum extraction apparatus	1	
	Amniohook	1	
	Uterine sound (Simpson)	1	30 cm
	Double-ended uterine dilators, set of 6	1	
	Uterine curettes (Sims)	1 set	26 × 7 mm to 26 × 14 mm (various sizes)
	Ovum forceps (de Lee)	1	24 cm
	Cranial perforator	1	
	Straight hysterectomy forceps (Pean)	6	22.5 cm
	Craniotomy forceps	2	
	Uterine haemostasis forceps (Green Armytage)	8	20 cm
	Obstetric forceps: low	1	
	midcavity	1	
	Retractor (Doyen)	1	
	Anterior vaginal-wall retractors	2	
	Punch biopsy forceps	1	
	Endometrial biopsy cannula	1	
	Suction cannulas, set of 4	1	
	Colposcope	1	
Ophthalmic instruments	Eyelid speculum (Clark)	1	
	Eyelid retractors (Desmarres)	2	
	Small rake retractors	2	
	Pterygium knife	1	
	Dissecting forceps, toothed	1	0.5 mm
		1	0.9 mm
	Dissecting forceps, non-toothed	1	0.5 mm
		1	0.9 mm
	Conjunctival scissors	1	
	Conjunctival forceps	2	
	Extracapsular forceps	1	
	Chalazion clamp	1	
	Chalazion curettes, set of 3 sizes	1	
	Enucleation scissors	1	

	<i>Quantity</i>	<i>Size</i>
Straight ring scissors	1	
Spring scissors (Westcott)	1	
Corneal scissors (Castroviejo): right	1	
left	1	
Iris scissors	1	
Iris forceps	2	
Needle holder, curved with lock (Castroviejo)	1	
Operating loupe (or similar magnifying device)	1	
Capsule forceps, non-toothed	1	
Simple ball-type cautery	1	
Muscle hooks	2	
Strabismus hooks	2	
Cystotome	1	
Vectis	1	
Periosteal elevator	1	
Iris retractor	1	
Iris spatula (repositor)	1	
Irrigating cannula	1	
Meibomian curette	1	
Eyelid clamp (and/or Trabut plate)	1	
Flat cataract curette	1	
Knife needle	1	
Spirit lamp with hot-point cautery	1	
Punctum dilator	1	
Tear-duct probes	1 set	4/0-4
Irrigating cannula	1	
Air cannula	1	
Eye spud (Walton)	1	
Orthopaedic instruments		
Plaster instruments:		
plaster saw (tenon)	1	
plaster saw (Engel)	1	
shears (Stille)	1	46 cm
scissors (Böhler)	1	25 cm
opening shears (Daw)	1	
bandage scissors (Lister)	1	
Pneumatic tourniquet	1	
Rubber bandages (Esmarch)	2	
Pins (Steinmann), with covers for ends		
Hand chuck for introducing pins (T-handle)	1	
Stirrups (Böhler)		
Wires (Kirschner)	6	
Wire stirrups (Kirschner)	6	
Hand drill and drill bits (Zimmer)	1 set	
Mallet (Heath)	1	38 mm head
Small mallet	1	
Straight osteotomes (Stille): broad	2	18 × 160 mm
narrow	2	6 × 160 mm
Straight chisels (Stille)	2	
Straight gouges	2	
Orthopaedic self-retaining retractor	1	
Tissue forceps (Lane)	2	
Spoons (Volkman): small	1	17 cm
medium	1	21 cm
Amputation knife	1	20 cm
Amputation saw (Satterlee)	1	
Finger saw	1	
Bone-holding forceps (Fergusson or Lane)	2	

		<i>Quantity</i>	<i>Size</i>
	Bone levers (Lane)	2	
	Rugine (Farabeuf)	1	
	Compound-action bone nibbler (rongeur)	1	
	Compound-action bone-cutting forceps	1	19 cm
	Bone file	1	
	Skull callipers (Crutchfield)	1	
	Skull callipers (Cone), with spanner	1	
Otolaryngology instruments	Auriscope and aural specula	1 set	
	Ear syringe	1	
	Head mirror	1	
	Nasal specula (Thudicum), set of 4 sizes	1	
	Angled dressing forceps (Tilley)	2	
	Self-retaining retractor (West)	1	
	Aural probe, hook, and curette	1 set	
	Myringotome	1	
	Mouth gag (Boyle-Davis): child-size	2	
	adult-size	2	
	Angled tongue depressors	2	
	Small suction tubes	2	
	Small catspaw retractors (Kilner)	2	
	Tracheal dilator (Bowby)	1	
	Assorted tracheostomy tubes or tracheostomy sets (Chevalier Jackson): child-size		
	adult-size		
Urogenital instruments	Curved urethral bougies (Clutton)	2 sets	10-24 Ch.
	Straight bougies (Powell)	2 sets	10-24 Ch.
	Filiform bougies	2 sets	33 cm long 2-6 Ch.
	Bougies (Guyon), for use as filiform guide	2	12 Ch.
	Bougies, 5/8 of a circle, olive-tipped (Hey Grove), set of 3	1	
	Soft penile clamps	2	
	Suprapubic trocars and cannulas	1	25 Ch.
		1	30 Ch.
	Catheter introducer (Malecot)	1	
	Catheter introducer (Foley)	1	
Vascular instruments	Bulldog clamps	4	22 mm
	Clamps (Satinsky), with 3 different blade shapes	1 set	
	Narrow-jaw needle holders (Hegar)	1	17.5 cm

Operating-room equipment

		<i>Quantity</i>
Fixed equipment	Fixed operating-room light	1
	Ultraviolet light source	1
	Scrub basins with hot and cold running water	
	Exhaust fans	
	Electric autoclave with horizontal drum	1
	Electric or kerosene sterilizer for boiling instruments	1

	<i>Quantity</i>
Other equipment	
Operating table, universal frame-type with headpiece	1
Plaster, orthopaedic fracture table (modified Watson-Jones)	1
Utensil sterilizer for bowls, boiling-type	1
Electric or kerosene hot-air sterilizer	1
Forceps sterilizers (Cheate), heavy-duty	2
Forceps sterilizers (Harrison)	2
Instrument trolleys	4
Anaesthetic trolleys	2
Instrument stands with trays (Mayo)	4
Instrument stands with bowls: single	2
double	2
Stands for swabs	2
Portable aspirating surgical suckers, electric	2
Portable aspirating surgical suckers, foot-operated	2
Cylindrical sterilizing drums: 24 cm diameter	4
29 cm diameter	4
34 cm diameter	4
Stainless-steel buckets with covers	4
"Kick-about" receptacles, on frames with roller casters	4
Revolving operating stools of adjustable height (enamel finish)	4
Footstools	2
Dressing trays: small	4
medium	4
large	4
Portable operating-room lights, with stands	2
Diathermy machine	1
Radiograph viewing boxes	2
Dispensers for hot and cold sterile distilled water (4 litres/hour)	2
Stretchers with combination wheel and adjustable sides	4
Labour and delivery beds, with two-piece mattresses	2
Folding stretchers	4
Covered instrument trays	4
Covered instrument/dressing trays	4
Instrument trays with handles	4
Instrument and catheter trays	4
Stainless-steel jugs: 3 litre	2
4 litre	2
Stainless-steel funnels, 200 ml	2
Stainless-steel graduated measures with handles, 1 litre	2
Utility basins, 3 litre	2
Self-retaining 4-wing catheters (de Pezzer), sizes 8, 14, 16, and 18 Ch.	
Self-retaining balloon catheters (Foley), sizes 8, 14, 16, 18, and 22 Ch.	
Urethral catheters (Nelaton), solid-tip, sizes 8, 10, 12, and 14 Ch.	
Urethral catheters, coudé, sizes 8, 10, 12, 14, and 16 Ch.	
Urinary bags	
Graduated drainage (collecting) bottles, glass, 1.5 litre	
Surgeon's latex gloves, sizes 6, 6.5, 7, 7.5, 8	

Rubber rectal tubes, funnel-end, 20 Ch., 50 cm long	
Rubber rectal tubes, funnel-end, 28 Ch., 50 cm long	
Colostomy bags	
Nasogastric tubes (Levin), 12 Ch.	
Polythene nasal feeding tubes:	
infant-size, 8 Ch., 38 cm long	
adult-size, 16 Ch., 80 cm long	
Metal irrigating syringe (Kramer), 90 ml	1
Glass irrigating syringes, 100 ml	2
Syringes: insulin, 1 ml	
tuberculin, 1 ml	
hypodermic, 2, 5, 10, 20, and 50 ml	
Hypodermic needles, gauges 18-25, 27, and 28	
Stomach tubes, 24 Ch., 150 cm long	
Face masks and caps	
Washable footwear, antistatic	
Drapes	
Gowns	
Surgeon's handbrushes with nylon bristles	
Sutures/ligatures:	
chromic catgut and	} 6/0, 4/0, 3/0, 2/0,
plain catgut,	
with and without needles	} 0, No. 1
nylon and silk,	} 8/0, 6/0, 5/0, 4/0,
with and without needles	
soft, stainless-steel wire, 0.35 mm thick (about size 0)	} 3/0, 2/0, 0, No. 1
Regular-eye needles, assortment of different types and sizes	
Scalpel blades, No. 10, 11, 12, 15, 21, 22, 23	100 of each size
Aneurysm needles: right	3
left	3
Stitch removal scissors	2
Heavy-duty "counter" scissors	2
Cannulas: stainless-steel	2
curved intravenous (Webster Luer)	2
transfusion (Luer), 1.25 × 41 mm (gauge 18)	2
transfusion (Luer), 0.90 × 41 mm (gauge 20)	2
transfusion (Luer), 0.70 × 41 mm (gauge 22)	2
Disposable scalp-vein infusion sets	
Polythene tubing, 0.86 mm inner diameter, 1.27 mm outer diameter	
Polythene tubing, 1.40 mm inner diameter, 1.90 mm outer diameter	
Polythene tubing, 1.67 mm inner diameter, 2.42 mm outer diameter	
Latex tubing: 3.2 mm inner diameter	
7.5 mm inner diameter	
10.0 mm inner diameter	
Soft rubber tubing, 2.0 mm inner diameter	
Connectors for tubing, assorted, including T-shape and Y-shape	
Utility apron, opaque plastic 90 cm × 100 cm	
Plastic sheeting, clear vinyl, 91 cm wide	
Rubber sheeting, double-coated, 91 cm wide	

Quantity

Foam rubber	
Corrugated latex drain	
Gauze bandage: 25 mm × 9 m	
50 mm × 9 m	
75 mm × 9 m	
Absorbent gauze (for dressings, swabs, abdominal packs, petrolatum gauze, etc.): 20 cm × 6 m	
1 m × 100 m	
Linen tape: 5 mm wide	
10 mm wide	
Surgical adhesive tape, 25 mm × 10 m	
Adhesive zinc oxide tape, 75 mm × 5 m	
Non-adhesive elastic bandage, 75 mm × 5 m	
Absorbent cotton wool	
Eye pads	
Eye shields	
Umbilical tape, 3 mm wide	
Indelible pencils	
Safety pins, medium size	
Rubber bands, assorted	
Garters, elasticated	
Manually operated hair clippers, narrow	2
Clipboards, 23 × 32 cm	2
All-metal safety razors, 3-piece	
Double-edged safety-razor blades	
Battery-operated wall clock, with hands showing time in seconds, minutes, and hours	1
Laboratory balance, 2 kg capacity	1
Sandbags	
Stainless-steel rulers	2
Aneroid sphygmomanometer, range 0–300 mmHg, with cuff	1
Stethoscopes, binaural (bell and diaphragm)	3
Oesophageal stethoscope	1
Fetal stethoscope	1
Tape measure, 1.5 m	1
Clinical thermometers: oral	1
rectal	1
Shiötz tonometer	1
Torch, battery-operated	1
Clothes-pegs	
Wooden spatulae	

Orthopaedic equipment

Gauze bandages, 10 cm and 15 cm wide	
Crêpe bandages	
Stockinet, assorted sizes	
Plaster of Paris powder (anhydrous calcium sulfate)	
Triangular cloth bandages (for arm slings)	
Thomas splints: child-size	8
medium-size	8
adult-size	8
Pearson attachments for Thomas splints: child-size	4
medium-size	
size	4
adult-size	4

	<i>Quantity</i>
Half-ring Thomas splints: right side	4
left side	4
Multi-purpose board splints, 3 sizes	1 set
Cramer wire splints: narrow, medium, and wide	
Frames with pulleys (Böhler-Braun)	3
Pulley systems: free	6
in frames	6
Wooden spreader bars, square: 7 × 7 cm	10
10 × 10 cm	10
Non-elastic traction cord	
Blocks (for elevating bed), 22 cm and 30 cm high	
Overhead traction suspension frames	4
Weights for traction	

Anaesthetic equipment

Anaesthetic face masks, infant-size to large adult-size	2 of each size, total 14
Oropharyngeal airways, sizes 00 to 5	2 of each size, total 12
Laryngoscopes	2 handles + 3 pairs of blades, or 4 plastic laryngoscopes (2 adult + 2 paediatric)
Spare bulbs for laryngoscopes	12
Batteries for laryngoscopes	30 (or 8 rechargeable batteries + charger)
Endotracheal tubes, sizes 2.5–10 mm (internal diameter) in 0.5 mm steps, Oxford or Magill or similar, with cuffs only on sizes > 6 mm	
Urethral bougies, for use as intubating stylets	
Magill's intubating forceps (in an emergency, ovum forceps can be used instead)	2 pairs
Endotracheal tube connectors, 15 mm plastic (can be connected directly to the breathing valve)	3 for each tube size
Catheter mounts (sometimes also called endotracheal tube connectors), antistatic rubber	4
Breathing hose and connectors:	
lengths of 1 metre antistatic tubing	2
lengths of 30 cm tubing for connection of vaporizers	4
T-piece for oxygen enrichment	1
Breathing valves (universal non-rebreathing type): child-size	2
adult-size	6
Breathing systems (for continuous-flow anaesthesia):	
Ayre's T-piece system	2
Magill breathing system	2
Self-inflating bellows or bags: child-size	1
adult-size	1
Anaesthetic vaporizers, for ether, halothane, and trichloroethylene (draw-over type)	
Needles and cannulas for intravenous use, including paediatric sizes and an umbilical vein catheter	
Intravenous infusion sets	
Spinal needles, range of sizes, 18-gauge to 25-gauge	

Index

- Abdomen 100–112
 “acute” 100, 119, 174
 binder for 107
 burst 106–107
 injuries to 108–112
 surgical instruments for 218
Abscess incision and drainage 31–32
 appendicular 134
 breast 98–99
 equipment for 208–209
 ischiorectal 148–150
 mastoid 73–75
 neck 85–86
 pelvic 141
 perianal 148–150
 peritonsillar 84, 85, 209
 retropharyngeal 84–85, 209
Acetazolamide 58, 64, 69
Acid–base balance 37–38
Acid–citrate–glucose solution 43
AIDS (acquired immunodeficiency syndrome) 22–23, 42
Anaemia 41, 42
Anaesthesia 23
 conduction (local) 54–55, 56, 59, 64, 71, 78–79, 93–94, 187, 188, 189
 dental surgery, for 78–79
 equipment for 225
 eye surgery, for 54–55, 56, 59, 64, 71
 paediatric 193
 rib fracture, for 93–94
 vasectomy, for 187, 188, 189
Anastomosis, intestinal, end-to-end 125–128
Anorectal atresia 135
Antimicrobial drugs 27–28, 45
Antiseptics 17, 22
Anus
 biopsy 143–144
 examination 141–144
 fissure 148
 manual dilatation 146, 147
Appendicectomy 130–134
 equipment for 205
Appendicitis 102, 130–134
Appendix
 abscess 134
 inflammation *see* Appendicitis
 mass 134
 removal *see* Appendicectomy
Asepsis (*see also* Sterilization) 15–17, 23
Atresia
 anorectal 135
 oesophageal 113
Atropine 57, 59, 64, 67
Autoclaving 19–21, 23
Autotransfusion 42–44

Balanitis 184, 203
Bandage, barrel (jaw) 80, 81
Bassini repair procedure 152–156
Binder, abdominal 107
Biopsy, anal and rectal 143–144
Bladder, urinary
 catheterization 167–174, 176, 205–206
 ruptured 174–176
Bleeding, control of 23–25, 76, 77
Blood (*see also* Plasma) 36–37
 filtration 43
 groups, matching of 42
 loss, in children 193

Blood (*continued*)
 storage 42
 transfusion 41–44, 193
Body fluids 36–41
 children, in 36, 37, 193
 compartments 36–37
 HIV transmission in 22–23
 loss 38–39, 193
 replacement 39–40, 44
 status, disturbances of 38–41
Bougies, urethral 177–178, 179
Bowel *see* Intestine
Breast abscess 98–99
Bronchopleural fistula 93
Buffer systems, body 37–38
Burns
 fluid replacement for 39
 oesophageal 113
 skin grafting for 33–35

Calculi
 gallbladder, in 119, 120
 urinary 167, 171, 174
Cataract extraction 64–68
 equipment for 206
Cargut 23, 24
Catheterization (*see also* Drainage)
 bladder 167–174, 176, 205–206
 gallbladder 119–121
 nose 76
 stomach 113, 114
 suprapubic 171–174, 176
 urethral 167–171, 176
Cellulitis, facial 49, 51–52
Chalazion removal 59, 60
 equipment for 212–213
Chest 89–99
 drainage, underwater-seal 91–93, 96, 215
 flail 94–95
 surgical instruments for 218
Children (*see also* Neonates)
 body fluids 36, 37, 193
 colostomy 135
 cut-down to umbilical vein 193–195
 electrolytes 193
 equipment for surgery in 206–207, 210, 211, 212
 hernia 160–161, 163, 198, 199–200
 hydrocele, scrotal 181
 intussusception, reduction of 196–197
 meatal dilatation 201, 202, 211
 nutrition 193
 paraphimosis 203–204
 rectal prolapse 197, 199
 scrotal contents, exploration of 201–203
 surgery in, general principles of 193–195
 temperature control 193
Cholecystitis 119–121
Cholecystostomy 119–121
Circumcision 184–185
 complications 185, 201
Colitis, amoebic 145
Colon 135–140
 injuries to 109
Colostomy 135–137
Corneal perforation 59
Corneoscleral laceration 59
Coudé catheter 169
Cut-down to umbilical vein 193–195
 equipment for 206–207
Cystostomy 167, 171–174

- Débridement, wound 29–31
 Dental surgery, equipment for 78, 79, 207–208, 218–219
 de Pezzer catheter 171, 173, 174
 Dextran 36, 40, 41
 Dilatation
 anus, manual 146, 147
 meatus, in children 201, 202
 urethra, male 177–178, 179, 215
 Direct hernia 151, 156
 Diverticulitis 102
 Double-barrelled colostomy 135, 136, 138
 Drainage (*see also* Catheterization) 27, 28, 31–32, 111, 118
 abscess *see* Abscess incision and drainage
 chest, underwater-seal 91–93, 96
 Drapes, sterile 17
 Dressings, bolster 33
 Dry-heat sterilization 21
 Duodenum
 perforation 102
 ulcer, perforated 113–118
- Ear 72–75
 foreign bodies in 72, 73, 213
 injuries to 51, 52
 surgical instruments for 221
 wax, removal 72
- Electrocardiogram 40, 41
 Electrolyte(s) 5, 36–41
 children, in 193
 exchanges 37, 38
 imbalance 36, 40–41
 therapy 36–41
- Emergencies
 blood transfusion in 42
 sterilization in 22
- Emphysema, surgical 97–98
 Empyema 91, 97
- End colostomy 135, 136
- Entropion treatment 60–62
 equipment for 215
- Enucleation, eye 69–71
 equipment for 207
- Epididymo-orchitis 202
- Epigastric hernia 164
- Epistaxis control 76, 77
 equipment for 206
- Equipment
 abscess incision and drainage, for 208–209
 anaesthetic 209, 225
 appendicectomy, for 205
 bladder catheterization, for 205–206
 craniotomy, for 218
 cut-down (paediatric), for 206–207
 dental 78, 79, 207–208, 218–219
 epistaxis control, for 206
 eye surgery, for 53–54, 206, 207, 212–213, 214, 215, 219–220
 facial wounds, for treatment of 49
 fixed 221
 foreign-body removal, for 213
 gynaecology, for 219
 hernia operation, for 208
 interdental wiring, for 209
 laparotomy, for 209–210
 maxillo-facial surgery, for 218–219
 minor operations, for 211–212
 myringotomy, for 212
 operating-room 221–224
 orthopaedic 220–221, 224–225
 otolaryngology, for 221
 paediatric operations, for 206–207, 210, 211–212
 plastic surgery, for 218–219
- Equipment (*continued*)
 proctoscopy, for 212
 rectal examination, for 212
 sigmoidoscopy, for 213
 skin grafting, for 34, 213–214
 sterilization of 19–22, 23, 54
 suprapubic puncture, for 214
 tracheostomy, for 214
 underwater-seal chest drainage, for 215
 urethral dilatation, for 215
 urogenital surgery, for 221
 vascular surgery, for 221
- Ethanol 17, 23
- Eversion, tunica vaginalis 181–184
- Extracellular fluid 36, 38
- Extraocular surgery 55, 59–64
- Extraperitoneal rupture, bladder 174–176
- Eye 53–71
 anaesthesia for 54–55, 56, 59, 64, 71
 enucleation 69–71, 207
 foreign bodies in 57–58, 59
 injuries to 57–59
 medication 53, 57, 59
 penetrating injuries to 58
 postoperative complications in 56, 67–68
 surgery, basic principles 57–55
 surgical instruments for 53–54, 206, 207, 219–220
- Eyelid lacerations, repair of 58
- Face
 nerve block 54, 55
 surgical instruments for 49
 wounds of 49–52
- Feeding gastrostomy 113, 114
- Femoral hernia 152, 158–160
- Flail chest 94–95
- Fluid(s)
 body *see* Body fluids
 therapy 36, 39–40, 44, 193–195
- Foley balloon catheter 76, 113, 119, 167–169
- Foreign bodies, removal of
 ear, from 72, 73, 213
 equipment for 213
 eye, from 57–58, 59
 nose, from 76–77, 213
- Formaldehyde 22
- Fractures
 jaw 80–83
 pelvis 174, 178
 rib 93–94
- Gallbladder 119–121
- Gallstones 119, 120
- Gangrene
 bowel 196
 colon 135, 136, 138
 small intestine 125, 126
 strangulated hernia with 160, 199
- Gastrostomy, feeding 113, 114
- Gentamicin 56, 57, 59, 67, 68
- Glaucoma, angle-closure 68, 69
- Globe, ocular, injuries to 59
- Gloves, surgical 19, 20, 22
- Glucose solutions 36, 40, 41, 43
- Glutaral (glutaraldehyde) 22
- Gowns, sterile 19
- Grafting, split-skin 33–35
- Groin hernia, strangulated 160–161
- Haematoma
 perianal 146–147
 perineal 180
 retroperitoneal 112

- Haematoma** (*continued*)
 scrotal 156, 184, 185
 skin graft, under 33
Haemopneumothorax 91, 95
Haemorrhoids 143, 145-147
Haemothorax 91, 96-97
Hartmann's solution 36, 39, 40, 44
Hernia
 epigastric 164
 femoral 158-160
 incisional 164
 inguinal 151-158, 198, 199-200
 strangulated 160-161, 198, 199-200
 treatment of, equipment for 208
 umbilical and paraumbilical 161-163
Hirschsprung's disease 40, 135, 142
HIV (human immunodeficiency virus) transmission, prevention of 22-23
Hot-air oven 21
Human immunodeficiency virus *see* HIV
Humby skin-grafting knife 34
Hydrocele, scrotal 152, 181-184
Hydrocortisone 67
Hyperkalaemia 40-41
Hypernatraemia 40
Hyphaema 58
Hypokalaemia 41
Hypovolaemia (*see also* Hypovolaemic shock) 38-40, 108
Hypovolaemic shock 39, 44-45, 96
- Ileum, typhoid perforation of** 128-129
Ileus, paralytic 102
Incision, surgical 23, 24
 abscess, of 31-32
 midline, for laparotomy 100-103, 105
 paramedian, for laparotomy 103-105
Incisional hernia 164
Indirect hernia 151, 152-156
Infection
 postoperative 15-17, 29, 56
 treatment of 27
 wound 15-17, 23, 25, 28, 29, 136
Informed consent 17
Inguinal hernia 151-158
 in children 198, 199-200
Inguinoscrotal hernia 156, 160, 181
Injuries (*see also* Wounds)
 abdominal 108-112
 eye 57-59
 facial 49-52
 intestinal 109, 110, 125
 kidney 112
 liver 102, 111
 mediastinal 97-98
 mesenteric 102, 125
 spleen 102, 109, 121-124
 stomach 109
Instruments *see* Equipment
Intercostal nerve block 93-94
 equipment for 209
Interdental wiring 82-83
 equipment for 209
Interstitial fluid 36-37
Intestine (*see also specific parts*)
 anastomosis of 125-128
 gangrenous 125, 126, 135, 136, 138, 196
 injuries to 109, 110, 125
 obstruction of 102, 125, 196-197
 perforation of 102, 125, 128-129
 resection of 125-128
 small 109, 110, 125-129
Intracellular fluid 36, 37
- Intraocular**
 pressure measurement 53-54
 surgery 53, 54, 55, 56, 64-69
Intraperitoneal rupture, bladder 174-176
Intravenous
 fluid administration 40-41, 193-195
 infusion 36, 39
Intussusception, operative reduction of 196-197
Ischiorectal abscess 148-150
- Jaw**
 fractures 80-83
 interdental wiring 82-83
- Kidney injuries** 112
Knife, skin-grafting 34
Knots for ligatures 23, 25
- Lacerations**
 corneal 59
 ear 52
 eyelid 58
Laparotomy 100-106, 108, 109
 equipment for 209-210
Lidocaine 54, 55, 59, 60, 61, 63, 64, 187, 189
Ligatures (*see also* Sutures) 23, 24, 25, 29
Lignocaine *see* Lidocaine
Linen, disposal of 22
Lip wounds 50
Liver injuries 102, 111
Loop colostomy 135-137
Lymphoedema, scrotal 181
- McBurney's point** 130, 131-132
Mandibular fractures 80-83
Mastoid abscess 73-75
Mastoiditis, acute 73-74
Mattress sutures 26, 60, 61, 111
Meatal dilatation, paediatric 201, 202
 equipment for 211
Mediastinal injuries 98
Mesenteric injuries 102, 125
Midline incision for laparotomy 100-103, 105
Minor operations, equipment for 211-212
Myringotomy 72-73, 74
 equipment for 74, 212
- Neck abscess, acute** 85-86
Neonates (*see also* Children)
 body-fluid compartments 36, 37
 cut-down to umbilical vein 193-195
Nerve block
 facial 54, 55
 intercostal 93-94
 retrobulbar 54-55, 56
Nose
 bleeding *see* Epistaxis control
 foreign bodies in 76-77, 213
 wounds of 51
Nutrition (*see also* Feeding gastrostomy)
 paediatric 193
Nylon sutures 23, 24, 25, 27
- Obstruction**
 intestinal 102, 125, 196-197
 oesophageal 113
Oesophageal atresia 113
Operating room 19
 equipment for 221-224
Operations, surgical
 equipment for *see* Equipment
 list of 15
 team for, preparation of 17-19
Ophthalmic instruments 219-220

- Oral rehydration salts 39
 Otitis media, acute 72, 73
 Otolaryngology, instruments for 221
- Paediatric surgery *see under* Children**
 Pancreas 111
 Paralytic ileus 102
 Paramedian incision for laparotomy 103–105
 Paraphimosis 184
 in children 203–204
 Paraumbilical hernia 161–163
 Patients
 duties towards 17
 HIV-infected 22–23
 preparation for surgery 16–17
 records on 29, 41
 Pelvic abscess 141
 Pelvis, fracture of 174, 178
 Peptic ulcer, perforated 113–118
 Perforation
 corneal 59
 duodenum, of 102
 peptic ulcer, of 113–118
 stomach, of 102
 typhoid, of ileum 128–129
 Perianal
 abscess 148–150
 haematoma 146–147
 Perineal haematoma 180
 Peritonitis 115, 130
 Peritonsillar abscess, incision and drainage 84, 85, 209
 Phimosis 184
 Pilocarpine 69
 Plasma (*see also* Blood) 36–37
 “expanders” 36, 40, 41
 potassium in 36, 40–41
 proteins in 36
 sodium in 40
 Pneumothorax 91, 94, 95–96, 97, 98
 Polygeline 40
 Polyposis 145
 Postoperative complications (*see also* Wounds, dehiscence of *and* Wounds, infection of)
 cataract extraction, of 67–68
 circumcision, of 185
 exploration of scrotal contents, of 203
 eye surgery, of 56, 57, 67–68
 hernia repair, of 158
 splenectomy, of 124
 tracheostomy, of 91
 Potassium
 chloride 41
 daily loss 38
 plasma, in 36, 40–41
 replacement fluids, in 39, 40
 Pregnancy, ectopic 102
 Preparation for surgery 16–22
 Proctoscopy 143–144
 equipment for 212
 Prolapse
 haemorrhoids, of 145–146
 iris, of 59
 lens, of 59
 rectal 150, 197, 199
 vitreous body, of 59
 Prophylaxis 27
 Prostatic disorders 167
 Proteins, plasma 36
 Pterygium excision 62–64
 equipment for 207
- Records, medical 29, 41
 Rectal tube, use in volvulus 138–140
 Rectum
 biopsy 143–144
 examination 141–145, 212
 injuries to 109
 prolapse 150, 197, 199
 Recurrent hernia 158, 160
 Rehydration salts, oral 39
 Resection of small intestine 125–128
 Retrobulbar block 54–55, 56
 Retroperitoneal haematoma 112
 Retropharyngeal abscess, incision and drainage 84–85
 equipment for 209
 Rib fracture 93–94
 Ringer's lactate solution 36, 39, 40, 44
- Saline, physiological (normal) 36, 39, 40, 44
 Schiötz tonometer 53–54
 Schistosomiasis 145
 Scrotum
 contents, exploration of 189, 201–203
 haematoma in 156, 184, 185
 hydrocele of 152, 181–184
 lymphoedema of 181
 Scrubbing up 18
 Shock
 hypovolaemic 39, 44–45, 96
 septic 44–45
 Sigmoid volvulus
 non-operative reduction 139–140, 145
 surgical reduction 137–139
 Sigmoidoscopy 144, 145
 equipment for 213
 Skin
 closure 25–27
 grafting 33–35, 213–214
 preparation for surgery 16–17
 Sliding hernia 156, 157
 Small intestine (*see also* Duodenum *and* Ileum) 109, 110, 125–129
 Sodium
 bicarbonate 40, 41
 daily loss 38
 fluorescein 57
 plasma, in 40
 replacement fluids, in 39, 40
 Spleen
 injuries to 102, 109, 121
 ruptured 121–124
 Splenectomy 122–124
 Split-skin grafting 33–35
 Sterilization (*see also* Asepsis) 19–22, 23, 54
 emergency 22
 Stomach 113–118
 injuries to 109
 perforation 102
 ulcer 113–118
 Strangulated hernia 151, 152, 158, 160–161
 children, in 198, 199–200
 gangrene with 160
 non-operative reduction of 160
 obstructing ring, division of 161
 Subconjunctival injection 56–57
 Suprapubic
 cystostomy 167, 171–174
 puncture 167, 171, 214
 Sutures (*see also* Ligatures)
 grading of 27
 materials for 24–27
 mattress 26, 60, 61, 111
 tension 106
- Quinsy 84, 85

- Tarsorrhaphy 59–60, 61
equipment for 214
Temperature control in children 193
Testis
appendix, torsion of 202
swelling 152, 189
torsion in children 201–203
tumour 189
Tetracaine 54, 56, 59, 63, 64
Tetracycline eye ointment 55, 57, 59, 60, 61, 64, 67,
69, 71
Thread sutures 23, 24, 25, 27
Throat 84–86
Tongue injuries 50–51
Tonometer, Schiötz 53–54
Tooth extraction 78–80
equipment for 207–208
Tracheostomy 89–91
equipment for 214
Trays, surgical 205–215
Trichiasis 60–61
Tuberculosis 84–85, 86
Tunica vaginalis, eversion of 181–184
Typhoid perforation of ileum 128–129
- Ulcer, peptic 113–118
Umbilical
hernia 161–163
vein, cut-down to *see* Cut-down to umbilical vein
Underwater-seal chest drainage 91–93, 96
equipment for 215
- Urethra
catheterization 167–171, 176
dilatation, in male 177–178, 179, 215
rupture 167, 178–179
stricture 167, 177–178
Urinary calculi 167, 171, 174
Urine
output 39, 44
retention 167
Urogenital surgery, instruments for 221
- Vasectomy 185–189
Vertical jaw-bandage 80, 81
Volume depletion, assessment of 38–39
Volvulus, sigmoid *see* Sigmoid volvulus
- Waste from HIV-infected patient, disposal of 23
Water
body *see* Body fluids
daily exchanges of 37, 38
Wounds (*see also* Injuries)
abdominal 24, 102, 106–112
care of 28
closure of 23–27, 109–112
contamination of 24, 25, 26, 28, 29, 136
débridement of 29–31
dehiscence of 106–108, 185
drainage of 105
infection of 15–17, 23, 25, 28, 29, 136
mediastinal 97–98