

nia

Incorporated Dental Society, Ltd.

Registered Office: 12, Tavistock Square, London, W.C.1.

Library Rules

- 1.— eligible t
- 2.— loss or d
of the bo
- 3.—
Library
order of
with stat
by the L
- 4.— with the
- 5.— time allo
- 6.— rotation :
- 7.— if not pro
for any c
- 8.— wise infr
Library
- 9.— the Libr
expired c
- 10.—

As t
addition
cost of p

New books likely to be of interest, will be added from time to time.

This Book may be retained for Four Weeks.

Return to—**THE LIBRARIAN,**
Incorporated Dental Society, Ltd.,
12, Tavistock Square, London, W.C.1



THE LIBRARY OF THE UNIVERSITY OF CALIFORNIA LOS ANGELES

are not

ood any
ceptance
fect.

ult their
s in the
together
returned
le.

ondence
e.

d if the

ve it in

aid, and
possible

r other-
use the

arned to
limit has

a time.

ting, an
over the

W. H. C.

Digitized by the Internet Archive
in 2007 with funding from
Microsoft Corporation

ESSENTIALS OF
OPERATIVE DENTISTRY



ESSENTIALS OF
OPERATIVE DENTISTRY

BY

W. CLYDE DAVIS, M.D., D.D.S.

DEAN AND PROFESSOR OF OPERATIVE DENTISTRY AND TECHNIC, LINCOLN DENTAL
COLLEGE, LINCOLN, NEBRASKA.

SECOND REVISED EDITION

LONDON
HENRY KIMPTON
263 HIGH HOLBORN, W. C.

1917

COPYRIGHT, 1916. BY C. V. MOSBY COMPANY

Press of
C. V. Mosby Company
St. Louis

Beomed
WLI
300
D299e
1916

PREFACE TO SECOND EDITION.

In presenting the second edition of this work, it is the aim of the author to follow the plan of the first edition, in that it be concise and yet cover a wide field in operative dentistry.

The book has been thoroughly rewritten and extensively illustrated. Four new chapters have been added, several have been materially enlarged, and others eliminated entirely in this edition.

There is a complete rearrangement of the chapters which it is believed will more nearly coincide with the progress of the student through his technical work and the operatory.

W. C. D.



PREFACE TO FIRST EDITION.

In the preparation of this text-book it has been the author's aim to meet a demand in dental college work for a treatise on operative dentistry which is sufficiently condensed to enable the student to master its contents in the comparatively short college terms at his disposal.

The subject matter selected is that which is generally taught by the instructors styled as "Professor of Operative Dentistry."

From a study of these teachers' courses of instruction it would seem that the definition of Operative Dentistry as commonly used today would be "That branch of dentistry which treats of the mechanical procedures performed within the oral cavity looking to the salvage of the teeth."

However, it has seemed wise in several instances to go beyond the exact limitations of this definition to get a better correlation of subjects.

The arrangement of the subject matter is different from that usually found, but is in accordance with the usual line of progress of dental students.

The author claims little originality in the essentials presented, having gleaned the facts from the writings, teachings and utterances of our greatest educators.

The "quiz-explanation" method of teaching is the one most in vogue in the leading universities as productive of the most work on the part of the classes taught, and at the same time giving the tutor more freedom for the expression of opinions to give individuality to his course of instruction.

An effort has been made to so publish the "Essentials of Operative Dentistry" that it would serve as a foundation for this quiz course as well as be suggestive to the teacher for a more full explanation, and, at the same time, encourage the student to extend his studies to more voluminous reference books, when time would permit, for an explanation in greater detail.

The author is much indebted to his co-laborer, partner and wife, Mattie M. Davis, D.M.D., for valuable assistance in connection with the publication of this volume.

W. C. D.

CONTENTS

PART I.

	Page
CHAPTER I.	
INSTRUMENT NOMENCLATURE	17
CHAPTER II.	
CAVITY NOMENCLATURE	21
CHAPTER III.	
CAVITY PREPARATION. (GENERAL CONSIDERATIONS.)	29
CHAPTER IV.	
GAINING ACCESS	31
CHAPTER V.	
OUTLINE FORM	34
CHAPTER VI.	
RESISTANCE FORM	38
CHAPTER VII.	
RETENTION FORM	40
CHAPTER VIII.	
CONVENIENCE FORM	42
CHAPTER IX.	
REMOVAL OF REMAINING CARIOUS DENTINE.—FINISHING ENAMEL WALLS.— TOILET OF THE CAVITY	44
CHAPTER X.	
MANAGEMENT OF PIT AND FISSURE CAVITIES. (CLASS ONE.)	48
CHAPTER XI.	
MANAGEMENT OF PIT AND FISSURE CAVITIES. (CLASS ONE, CONCLUDED.)	52
CHAPTER XII.	
MANAGEMENT OF PROXIMAL CAVITIES IN BICUSPIDS AND MOLARS. (CLASS TWO.)	58
CHAPTER XIII.	
LARGE PROXIMAL CAVITIES ENDANGERING THE PULP. (CLASS TWO, CON- TINUED.)	65

	Page
CHAPTER XIV.	
MANAGEMENT OF PROXIMAL CAVITIES IN INCISORS AND CUSPIDS NOT INVOLVING THE ANGLE. (CLASS THREE.)	72
CHAPTER XV.	
MANAGEMENT OF PROXIMAL CAVITIES IN INCISORS INVOLVING THE ANGLE. (CLASS FOUR.)	78
CHAPTER XVI.	
MANAGEMENT OF CAVITIES IN THE GINGIVAL THIRD. (CLASS FIVE.)	93
CHAPTER XVII.	
MANAGEMENT OF ABRADED SURFACES. OCCLUSAL AND INCISAL. (CLASS SIX.)	96
CHAPTER XVIII.	
CAVITY PREPARATION FOR GOLD INLAYS	98
PART II.	
CHAPTER XIX.	
THE MAKING AND SETTING OF A GOLD INLAY	112
CHAPTER XX.	
MANIPULATION OF COHESIVE GOLD IN THE MAKING OF A FILLING	123
CHAPTER XXI.	
MANIPULATION OF COHESIVE GOLD IN THE MAKING OF FILLINGS BY CLASSES	129
CHAPTER XXII.	
FINISHING GOLD FILLINGS	137
CHAPTER XXIII.	
MANIPULATION OF AMALGAM IN THE MAKING OF A FILLING	139
CHAPTER XXIV.	
THE USE OF CEMENTS IN FILLING TEETH	146
CHAPTER XXV.	
MANIPULATION OF SILICATE IN THE MAKING OF A FILLING	148
CHAPTER XXVI.	
THE USE OF GUTTA-PERCHA IN FILLING TEETH	164
CHAPTER XXVII.	
TIN AS A FILLING MATERIAL	166
CHAPTER XXVIII.	
COMBINATION FILLINGS	169

PART III.

	Page
CHAPTER XXIX.	
EXAMINATION OF THE MOUTH LOOKING TO DENTAL SERVICES	174
CHAPTER XXX.	
THE ALLEVIATION OF DENTAL PAINS	177
CHAPTER XXXI.	
PROPHYLACTIC TREATMENT OF THE MOUTH	180
CHAPTER XXXII.	
EXCLUSION OF MOISTURE	187
CHAPTER XXXIII.	
TREATMENT OF HYPERSENSITIVE DENTINE	195
CHAPTER XXXIV.	
PROTECTION OF THE VITAL PULP	204
CHAPTER XXXV.	
PULP DEVITALIZATION AND REMOVAL	211
CHAPTER XXXVI.	
MANAGEMENT OF PUTRESCENT PULP CANALS	219
CHAPTER XXXVII.	
THE FILLING OF PULP CANALS	225
CHAPTER XXXVIII.	
MANAGEMENT OF CHILDREN'S TEETH	229
CHAPTER XXXIX.	
EXTRACTION OF PERMANENT TEETH	233
CHAPTER XL.	
EXTRACTION OF TEMPORARY TEETH	269
CHAPTER XLI.	
LOCAL AND REGIONAL ANESTHESIA	275
CHAPTER XLII.	
THE USE OF FUSED PORCELAIN IN FILLING TEETH	293
CHAPTER XLIII.	
PREPARATION OF CAVITIES FOR PORCELAIN INLAYS	296
CHAPTER XLIV.	
THE CONSTRUCTION AND PLACING OF A PORCELAIN INLAY	306

ILLUSTRATIONS

FIG.	PAGE
1. Defects in enamel	21
2. Defects in enamel	22
3. Smooth surface decay	23
4. Smooth surface decay	23
5. Class One cavities filled	24
6. Class Two cavity filled	24
7. Class Three cavity filled	25
8. Class Four cavity filled	25
9. Class Five cavity filled	25
10. Bisected molar in which a mesial Class Two cavity has been cut and line angles indicated	26
11. Bisected molar in which a mesial Class Two cavity has been cut and point angles indicated	26
12. Diagram of tooth, giving angles and surfaces	27
13. Technic group illustrating outline form	35
14. Another view of cavities illustrated in Fig. 13	35
15. Fillings in place in cavities shown in Figs. 13 and 14	36
16. Another view of fillings shown in Fig. 15	36
17. Complex Class One cavity prepared	50
18. Class One filled. Cavity shown in Fig. 17	51
19. Large Class One cavities prepared	53
20. Class One filled. Cavities shown in Fig. 19	54
21. Lingual pit cavities	55
22. Class One filled. Cavities shown in Fig. 21	56
23. One of the few cases in which the step may be omitted in Class Two cavities	60
24. Class Two cavities in molar and bicuspid suitable for cohesive gold or amalgam	61
25. Class Two filled. Cavities shown in Fig. 24	62
26. Fillings shown in Fig. 25 contacted, illustrating the marble contact	63
27. Large Class Two cavities in non-vital teeth restoring part of the occlusal surface for the protection of weakened walls	67
28. Class Two filled. Cavities shown in Fig. 27	67
29. Mesio-occluso-distal cavities in molar and bicuspid, vital teeth	68
30. Mesio-occluso-distal fillings. Cavities shown in Fig. 29	68
31. (A) First superior molar, non-vital, restoring the lingual cusps. (B) Second superior bicuspid, non-vital, restoring the entire occlusal surface	69
32. Class Two filled. Cavities shown in Fig. 31	69
33. Class Three cavities filled	73
34. Drawing to illustrate the retention at the incisal angle of Class Three cavity	75
35. Class Three cavities prepared for cohesive gold	76
36. Class Three filled. Cavities shown in Fig. 35	76
37. Drawings to illustrate the principle of the lever in the dislodgement of fillings of the Fourth Class, plan one	79
38. Drawings to illustrate the principle of the lever in the dislodgement of fillings of the Fourth Class, plans one and two	80
39. Drawing to illustrate the difference in the directions the point angle fillings take in tipping to exit with various fillings	82

FIG.	PAGE
40. Drawings to illustrate the importance which should be given to the proper placing of the incisal point angle in fillings of Class Four, plan two	83
41. A study in the proper placing and depth of the gingival angles . . .	84
42. A study of the planes in which the gingival angles should be laid . .	84
43. Cavity of Class Four, plan one, for cohesive gold	85
44. Class Four, plan one, cavity filled	85
45. Shows incisal outline in Class Four, plan one, fillings with direct occlusion	86
46. Cavity of Class Four, plan two, for cohesive gold	88
47. Class Four, plan two, filled	88
48. Cavity of Class Four, plan three, for cohesive gold	89
49. Class Four, plan three, filled	89
50. Cavity of Class Four, plan four, for cohesive gold	91
51. Class Four, plan four, filled	91
52. Cavity of Class Four, modified plan three, for cohesive gold in the distal of the superior cuspid	92
53. Class Four, modified plan three, filled	92
54. Cavities Class Five for cohesive gold or amalgam	93
55. Class Five filled	94
56. Cavities of Class One for gold inlays	101
57. Class One inlay in position showing gold wire cast in the filling . . .	102
58. Cavities of Class Two for gold inlays	103
59. Cavity of Class Three for gold inlay, lingual approach	105
60. Inlay shown in Fig. 59 partly in place	105
61. Cavity of Class Four, plan one, for gold inlay	106
62. Class Four, plan one, inlay in position	106
63. Cavity of Class Four, plan two, for gold inlay	107
64. Class Four, plan two, gold inlay in position	107
65. Cavity of Class Four, plan three, for gold inlay	108
66. Class Four, plan three, inlay in position	108
67. Cavity of Class Four, plan four, for gold inlay	109
68. Class Four, plan four, showing cavity side of pattern with pins . . .	109
69. Class Four, plan four, inlay in position before removing wire loop . .	109
70. Class Five cavity and inlay	110
71. Shows the necessary amount of metal for adequate protection of abraded surfaces, when opening the bite	110
72. Large restoration in non-vital case	113
73. Some of the methods by which inlays may be given retentive form in large decays and non-vital cases	115
74. Starting cohesive gold, first plan	130
75. Starting cohesive gold, second plan	131
76. Starting cohesive gold, third plan	132
77. Burnishing back excess gold foil in covering the gingival margin . .	133
78. Covering the gingivo-lingual angle with cohesive gold	134
79. Suitable cavities for the use of silicate fillings	149
80. A Class One cavity on the labial of a central incisor properly prepared for a silicate filling	149
81. Extensive Class Three cavity properly prepared for a silicate filling . .	150
82. A Class Five and a Class Three cavity suitable for the use of silicate as a filling	150
83. A Class Five cavity properly prepared for a silicate filling	151
84. A Class Three cavity, lingual approach, properly prepared for a silicate filling	151
85. A small Class Three cavity, labial approach, properly prepared for a silicate filling	152

FIG.	PAGE
86. A small Class Three cavity, lingual approach, properly prepared for a silicate filling	152
87. A large Class Three cavity, labial approach, properly prepared for a silicate filling	152
88. A large Class Three cavity, lingual approach, properly prepared for a silicate filling	152
89. A large Class Three cavity properly prepared for a silicate filling	153
90. Two extensive Class Three cavities properly prepared for a silicate filling	153
91. A small set of instruments for manipulating silicate	154
92. A suitable slab and spatula for working silicate	155
93. Proper position of the spatula on the slab when manipulating silicate	156
94. Proper placing of the materials when manipulating silicate	156
95. Mixing the silicate filling	157
96. Mixing the silicate filling	157
97. Circular motion used in mixing the silicate filling	158
98. Scraping the material from the slab	159
99. The entire mix on the spatula	160
100. Method of removing the mix from the spatula to the slab	160
101. Proper consistency of silicate	161
102. Shows mix of silicate too thin	161
103. A homemade mallet and point	162
104. Three cavities suitable for silicate fillings	163
105. Shows the results obtained after filling with silicate the cavities shown in Fig. 104	163
106. Combination gold inlay and silicate	171
107. Amalgam in position ready to receive a partial facing of silicate	172
108. Amalgam filling shown in Fig. 107 with the silicate facing built in	172
109. An improper position with the operator doing his work at arm's length	235
110. Types of superior central incisors	236
111. Types of superior lateral incisors	237
112. Position for extracting superior incisors	238
113. Types of inferior central and lateral incisors	239
114. Position for extracting lower incisors	240
115. Types of superior cuspids	241
116. Position for extracting right superior cuspids	242
117. Position for extracting left superior cuspids	243
118. Mesial and distal application of forceps to a superior right cuspid when both adjacent teeth have been extracted	244
119. Types of inferior cuspids	246
120. Position for extracting inferior cuspids	247
121. Types of superior first and second bicuspids	248
122. Position for extracting right superior bicuspids	249
123. Position for extracting left superior bicuspids	250
124. Types of inferior first and second bicuspids	251
125. Position for extracting right inferior bicuspids	252
126. Position for extracting left inferior bicuspids	253
127. Types of superior first and second molars	254
128. Position for extracting first and second right superior molars	255
129. Position for extracting first and second left superior molars	256
130. Types of inferior first and second molars	257
131. Position for extracting first and second right inferior molars	258
132. Position for extracting first and second left inferior molars	259
133. Types of superior third molars	260

FIG.	PAGE
134. Types of abnormal superior third molars	261
135. One of the many abnormal conditions found when extracting upper second and third molars	262
136. Position for extracting right upper third molars	263
137. Position for extracting upper left third molars	264
138. Types of inferior third molars	265
139. Elevator beaked forceps for extracting third molars	266
140. Position for extracting right inferior third molars	266
141. Position for extracting left inferior third molar	267
142. Complete set of deciduous teeth with the first permanent molar added .	270
143. Irregularity resulting from premature extraction of first deciduous molar	271
144. Horizontal injection	275
145. Perpendicular injection	276
146. Drawing representing the positions of needles in local anesthesia . .	277
147. First position in the mandibular injection	278
148. Second position in the mandibular injection	279
149. Third position for the mandibular injection	280
150. Fourth and last position for the mandibular injection	281
151. A very clear and easy case with the needle in the best position for the mandibular injection	282
152. A difficult case where the lingula is almost entirely wanting	283
153. Same mandible as shown in Fig. 153 with the needle passed to position sufficiently high to be above the lingula	284
154. A mandible which belongs to a class on which it is very hard to give a mandibular injection	285
155. First and ideal position for giving the mental injection	286
156. Second position for giving the mental injection	287
157. Position of needle in giving the infra-orbital injection	289
158. Final position of the needle in giving the zygomatic injection . . .	291
159. Cavity preparation for a Class Two porcelain inlay	297
160. A Class Three cavity labial approach for porcelain inlay	298
161. A Class Three cavity labial approach for porcelain inlay	298
162. A Class Three cavity lingual approach for porcelain inlay	299
163. A Class Four cavity incisal approach for porcelain inlay	300
164. A Class Four, plan one, inciso-proximal approach for porcelain inlay	300
165. A Class Four, plan two, with double step for porcelain inlay	301
166. A Class Four, plan three, for porcelain inlay	302
167. Class Five cavities for porcelain inlay	303
168. Incisal cavity for porcelain inlay	304
169. A Class Six cavity using pin anchorage for porcelain inlay	305
170. Chisels for securing outline form	314
171. Spoons for removing softened dentine	315
172. Enamel hatchets for completing outline form and flattening dentine walls	316
173. Instruments for cutting point angles and sharpening base line angles .	317
174. Hatchets and hoes for cutting ascending line angles and completing retention form	318
175. Gingival marginal trimmers	319
176. Gold building pluggers	320
177. Dr. Rathbun's dentech with teeth in position ready for practice work	321
178. A student who has kept his appointment with his patient, "Mr. Den- tech"	322
179. Forceps made after the patterns of the author	323
180. Forceps made after the patterns of the author	324



OPERATIVE DENTISTRY

PART I

CHAPTER I.

INSTRUMENT NOMENCLATURE.

A dental instrument is an appliance, or tool, by means of which a dentist performs dental operations. It is quite essential that we learn the names and uses of the instruments most in use if we are to understand the teaching of operative procedures.

Instruments are named according to the purpose for which they are intended, where and how used, by describing their working points and the shape of their shank.

An order name describes that for which an instrument is used, as for example, excavator, clamps, mallet, pluggers, burnishers, etc.

A sub-order name describes where or how an instrument of a given order is used and is made by inserting a prefix before the order name. Examples are hand pluggers, push or pull sealers, etc.

A class name describes the working point of an instrument. Examples are serrated plugger, ball burnisher, chisel, hatchet, etc.

A sub-class name describes the shape of the shank, and is made by prefixing this description to the class or order name or to both combined. Examples are bayonet plugger, bin-angle chisel, mon-angle hatchet excavator, etc.

Rights and lefts are made as further divisions of many of the sub-classes of instruments and this division is especially advantageous in the spoons, bin-angle, contra-angle hatchets and marginal trimmers, as it enables the user to do the work by a movement of the instrument from right to left, or left to right, respectively.

An excavator is that order of hand instrument used in the removal of tooth substance preparatory to the making of a filling.

A chisel is that class of excavator which has the cutting edge placed at right angles to the shaft, is sharpened by grinding on

W. C.

12, TRAVISTOCK SQUARE.

one side only and is used by a pushing force applied in the direction of the long axis of the shaft.

The chisel edge is made with a bevel at an angle calculated to plane and cleave a substance possessed of a grain, and is so tempered as to retain an edge when working on hard substances.

The use of the chisel is, therefore, the cleaving and planing of enamel. The planing of dentine may be done with a chisel or with other instruments of a similar edge.

Chisels are divided into sub-classes according to the shapes of their shanks, as straight, bin-angle, contra-angle, etc.

A hoe is that class of excavator with the cutting edge at a right angle with the shaft, sharpened on the distal side only and is used by a pulling force applied parallel with the long axis of the shaft.

Hoes are divided into sub-classes according to the shape of their shanks, as, mon-angle, bin-angle, contra-angle and triple-angle contra-angle. The hoe is used mostly for cutting dentine.

A hatchet is that class of excavator with the line of the cutting edge laid in the plane parallel with the long axis of the shaft.

Hatchets are divided into sub-classes the same as the hoes, according to the shape of their shank, as, mon-angle, bin-angle and triple-angle contra-angle. The hatchet form is indispensable for the construction of flat walls and internal surfaces, the straightening of lines and the sharpening of angles.

A gingival marginal trimmer is a modified hatchet.

A spoon is that class of excavator which resembles in most respects the hatchet, other than the cutting edge. This is sharpened on one side only which is rounded like the convex side of the bowl of a spoon from which it derives its name. The cutting edge is rounded and sharpened to a thin edge. Spoons are always made rights and lefts.

The use of a spoon is to remove foreign matter and softened dentine from the tooth cavity.

The angles between the shank and the working part are designated as mon-angle, bin-angles, and triple-angles, according to the number of angles used being one, two or three, respectively.

The contra-angle is the placing of such angles in the shank of the instrument as to bring the cutting edge near the central line of the shaft which removes the tendency to tip or turn in the hand during use.

Bin-angles and **triple-angles** are properly made only when contra-angled, provided the cutting edge is more than three millimeters from the central line of the shaft.

Formula Names. Some instruments have the formula stamped on the handle in figures. There are generally three numbers given. The first is the width of the blade in tenths of a millimeter. The second is the length of the blade given in millimeters. The third is the angle of the blade with its handle given in the hundredths of a circle.

When a four-number formula is given, as with gingival marginal trimmers, the second number in the name designates the angle of the cutting edge of the blade with shaft or handle. This is also given in the hundredths of a circle.

A plugger is an order of instrument for the packing of material in the making of a filling. Those for gold are serrated on the working point in such shape as to result in a surface made up of prisms. These prisms should be of exactly the same size on all the points used in any individual filling when packing cohesive gold, as the interchange of points of different-sized serrations causes bridging. (See manipulation of cohesive gold, Chapter XX.)

The dental engine is almost indispensable and when properly used is a blessing to our patients and a time-saver to the dentist. However, it is all too frequently used, especially by students and young practitioners, to do things which can properly be done only with the hand instruments. The misuse of the dental engine has caused the public to regard it as the climax of all pain-producing instruments in the dental office, when in reality, if that which should be done with the engine is properly done, only a few seconds of pain is induced in the preparation of a very severe cavity.

The engine bur is the working point of the engine and is made in many shapes and sizes. However, those which are round and inverted cones, whose diameter is smaller than one millimeter, are most frequently indicated. The tendency of the beginner is to use too large burs. Burs are primarily intended to cut dentine in outlining cavity walls, and for undermining enamel to facilitate the use of hand instruments and they should rarely come in contact with the enamel.

The most indispensable use of the engine is for the polishing and grinding necessary to the successful termination of many varied operations, both in and out of the mouth.

The sharpening of instruments is of the utmost importance and is by no means accomplished without skill. No better can a dentist execute finished work than can a tradesman whose tools must be keen of edge if he is to produce that which is worthy of his craft. Again, dull instruments cause an undue amount of pain at each at-

tempt to cut, whereas when sharp, the pain is less and the effort in cutting is materially lessened, resulting in a saving of pain to the patient and time and energy to the dentist. A hard, smooth Arkansas stone is the only suitable abrasive and should be well oiled and wiped with a cloth after each use.

Care of Instruments. As the instruments are shipped to the dentist they are usually made and sharpened especially for the use intended and care should be exercised in sharpening that the degree of the angle of the beveled edge is not changed.

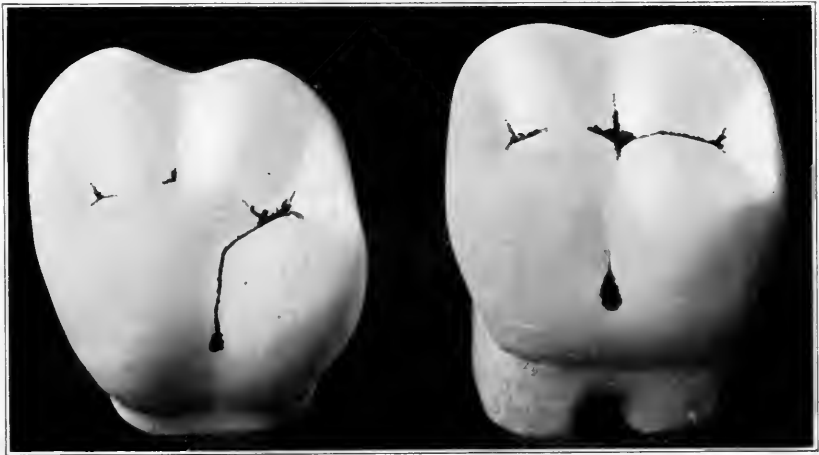Tests for Sharpness. An instrument is tested for sharpness best by placing the edge with light pressure against the finger nail and attempting to move it across the surface at right angles to the edge. If it catches or clings to the nail it is ready for use.

CHAPTER II.

CAVITY NOMENCLATURE.

A cavity nomenclature is necessary that we may understand one another in conversing about the formation of cavities, the description of their several parts and the methods of procedure in the preparation of cavities for fillings.

Cavities derive their names from the surfaces of the teeth in which they occur. Thus occlusal cavity, buccal cavity, labial cavity, etc., are cavities occurring in the surfaces named.



A

Fig. 1.—Defects in enamel.

B

Proximal cavities are those occurring in the proximal surfaces and are divided into two classes, namely, mesial and distal.

A simple cavity is one which involves but one surface.

A complex cavity is one which, either from decay or extension in preparation, involves more than one surface.

Complex cavities are named by combining the names of the surfaces of the tooth involved, as mesio-occlusal, disto-occlusal, mesio-disto-occlusal, etc.

An axial surface cavity is one which occurs in an axial surface.

Cavities are divided as to their origin into two groups.

First. Pit and fissure cavities, which are those originating in the minute faults in the enamel. (See Figs. 1 and 2.)

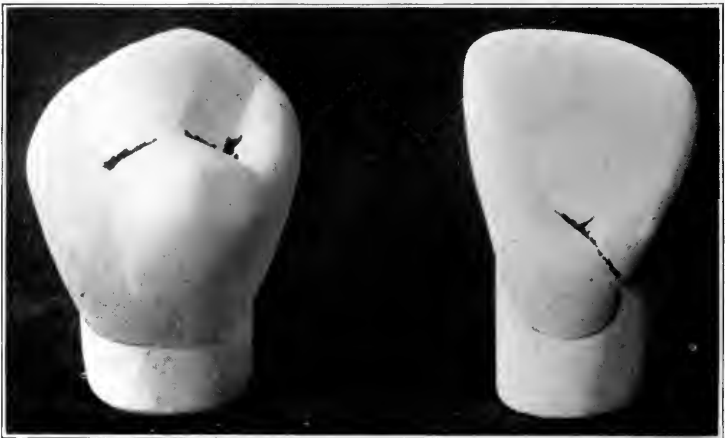
Second. Smooth surface cavities, which are those occurring on surfaces without defects in the enamel, but are habitually unclean. (See Figs. 3 and 4.)

Cavities are divided according to similarity in line of treatment into six divisions.

Class One. Those cavities beginning in structural defects. (Pits and fissures.)

Class Two. Those cavities in the proximal surfaces of bicuspids and molars.

Class Three. Those cavities in the proximal surfaces of incisors and cuspids not involving the incisal angle.



A

Fig. 2.—Defects in enamel.

B

Class Four. Those cavities in the proximal surfaces of incisors and cuspids which require the restoration of the incisal angle.

Class Five. Those cavities in the gingival third of the labial, buccal and lingual surfaces not originating in faults in enamel.

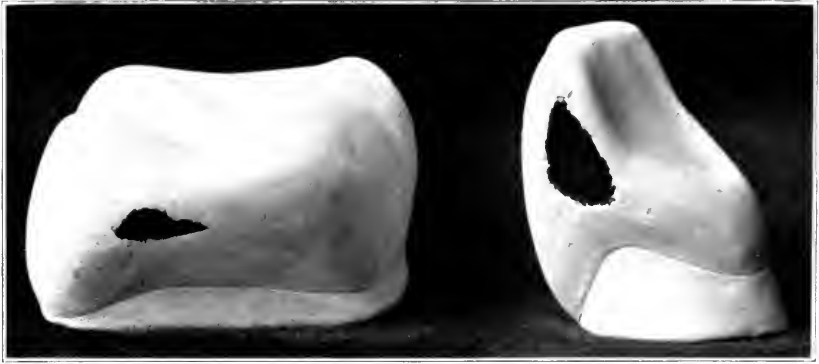Class Six. Abraded surfaces.

The outside walls of a cavity are those walls placed toward the outside surfaces of a tooth and take the names of the surfaces of the tooth toward which they are placed, as in an occlusal cavity the outside walls are buccal, distal, mesial and lingual, while the fifth or internal wall is the pulpal.

The pulpal wall is that inside wall of a cavity which covers the pulp and is in a plane at right angles to the long axis of the tooth.

In case the pulp is removed the pulpal wall becomes the sub-pulpal wall, in multi-rooted teeth.

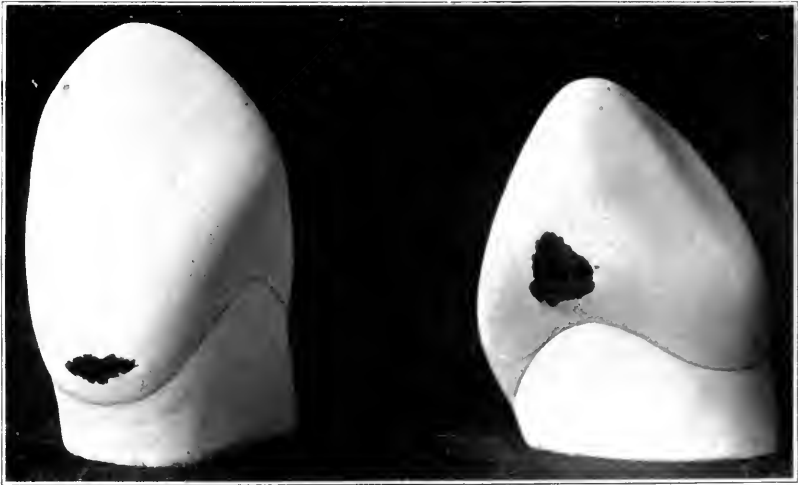
The axial wall is the inside wall of an axial surface cavity which covers the pulp and is in a plane parallel to the long axis of the tooth.



A

B

Fig. 3.—Smooth surface decay.



A

B

Fig. 4.—Smooth surface decay.

In case the pulp is removed in an axial surface cavity the axial wall becomes an outside wall and takes the name of the surface of the tooth toward which it is placed.

The gingival wall is the inside wall of an axial surface cavity

placed toward, and running in the same plane as, the gingivae.

Both gingival and sub-pulpal walls may be present in cases of pulp removal in mesio-occlusal, disto-occlusal, and mesio-disto-oc-

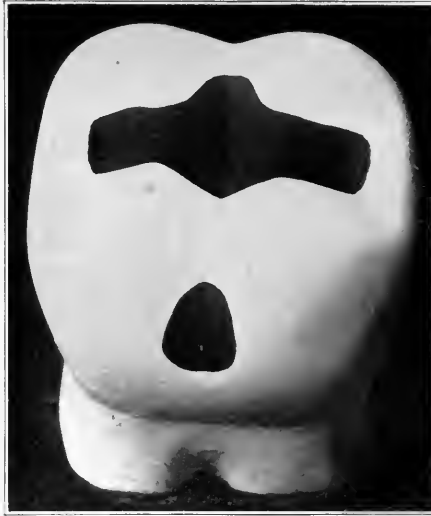

Fig. 5.—Class One cavities filled.

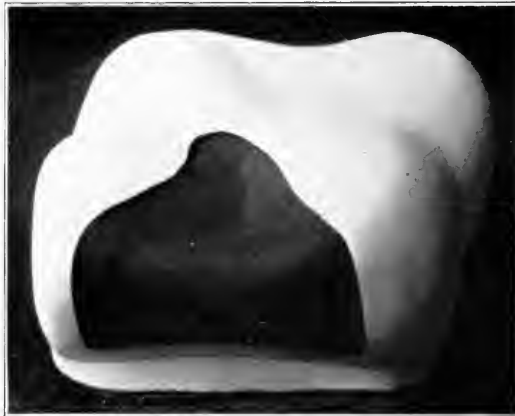

Fig. 6.—Class Two cavity filled.

clusal cavities when each is on a different level and the individuality of each wall is retained.

The inside walls of a cavity are those placed toward the pulp or root of a tooth.

The base of a cavity, or seat of a filling, is that portion of a cavity situated at right angles to the lines of force to which it is most likely to be subjected. Generally speaking, this is the gingival or pulpal wall, or both, where these walls are present, as in a step cavity.



Fig. 7.—Class Three cavity filled.



Fig. 8.—Class Four cavity filled.



Fig. 9.—Class Five cavity filled.

A line angle is formed where two walls of a cavity meet along a line and is named by joining the names of the walls so meeting.

There is but one exception to this rule. That is where the labial and lingual walls of a proximal cavity in the incisors and cuspids meet along a line. By applying the rule this would be called the

labio-lingual angle, but for convenience this is named the "incisal-line angle."

A point angle is formed where three walls of a cavity meet at




Fig. 10.—Bisected molar in which a mesial Class Two cavity has been cut and line angles indicated. The line angles are: *a*, Gingivo-buccal; *b*, Gingivo-lingual; *c*, Gingivo-axial; *d*, Axio-buccal; *e*, Axio-lingual; *f*, Axio-pulpal; *g*, Pulpo-buccal; *h*, Pulpo-lingual; *i*, Pulpo-distal; *j*, Disto-buccal; *k*, Disto-lingual.

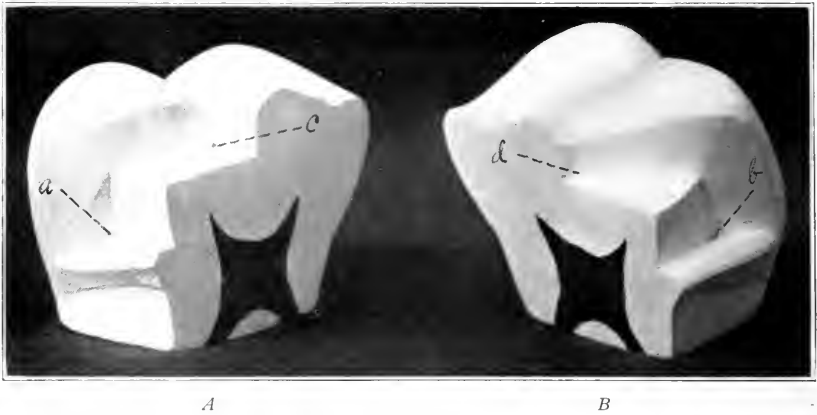


Fig. 11.—Bisected molar in which a mesial Class Two cavity has been cut and point angles indicated. The point angles are: *a*, Gingivo-axio-buccal; *b*, Gingivo-axio-lingual; *d*, Pulpo-distal-lingual; *c*, Pulpo-disto-buccal.

a point and is named by joining the names of the walls so meeting. There is but one exception to this rule. The point of junction of

the axial, labial and lingual walls in proximal cavities in the six anterior teeth is, for convenience, named the "incisal angle."

A simple cavity has two sets of line angles. First, the internal line angles surrounding the internal wall, which is the axial wall in axial surface cavities, and the pulpal wall in oclusal cavities.

The second set of external line angles is formed by the junction of the outside walls with each other.

The enamel margin is that point on the surface of the tooth where the cavity begins in enamel.

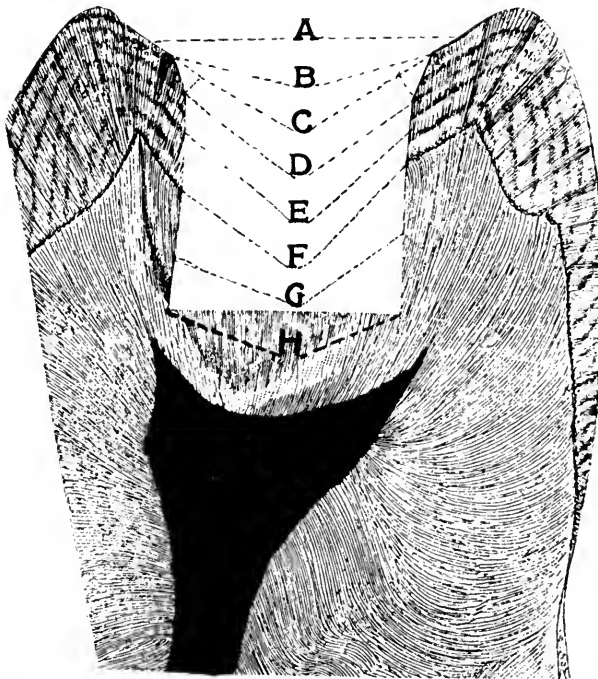


Fig. 12.—*A*, External enamel surface; *B*, Cavo-surface angle; *C*, Marginal bevel; *D*, Bevel angle; *E*, Enamel wall; *F*, Dento-enamel junction; *G*, Dental wall; *H*, Base line angles.

The external enamel line is the entire outline of the cavity at its enamel margin.

The cavo-surface angle is the angle formed by the junction of the wall of the cavity with the external surface of the tooth.

The base of the cavo-surface angle is the external enamel surface.

The marginal bevel of a cavity is the deflection of a cavity wall from its established plane, near the external enamel line.

It is necessary that beveling be resorted to, in order to manage

the enamel margins, direct the external enamel line and control the degree of the cavo-surface angle, without disturbing the general retentive form of the cavity.

The bevel angle is the angle formed by the junction of the marginal bevel with the remaining portion of the wall of which it is a part.

The base of the bevel angle is the remaining portion of the cavity wall.

The bevel angle is covered when the filling is in position. Its distance from the enamel margin depends upon the filling material used, and the location in the cavity outline. To illustrate: With porcelain inlays and amalgam the bevel angle must be deeply buried, resulting in a thicker edge of filling material. With cast gold inlays and platinum combination fillings the bevel angle should be near the surface, resulting in a short marginal bevel. The distance of the bevel angle from the cavo-surface angle must not affect the degree of the latter angle but determines only the length of the bevel and the thickness of the filling at its margin.

The planes of a tooth are three in number; horizontal plane, mesio-distal plane and bucco-lingual plane.

The horizontal plane is at right angles to the long axis of the tooth.

The mesio-distal plane passes through the tooth from mesial to distal parallel with the long axis.

The bucco-lingual plane passes through the tooth from buccal to lingual parallel with the long axis of the tooth. In the six anterior teeth this plane would be labio-lingual.

CHAPTER III.

CAVITY PREPARATION. (GENERAL CONSIDERATIONS.)

Definition of Cavity Preparation. Cavity preparation is that term applied to those mechanical procedures upon a tooth, looking to the making of a filling, as well as those changes and extensions necessary to resist stress and prevent a recurrence of decay.

Affected Dentine is dentine which has been acted upon by the lactic acid in advance of the micro-organisms of caries.

Infected Dentine is dentine which has been penetrated by micro-organisms.

Objects in Filling Teeth. There are four general objects in view in the filling of teeth :

First.—To arrest the loss of tooth substance.

Second.—To prevent recurrence of caries.

Third.—To restore full tooth contour.

Fourth.—To improve the primary conditions as to the performance of function and esthetic effects.

A Completed Cavity should be a combination of flat walls coming together at definite angles, surrounded by an external line made up of the largest curves permissible.

The Line Angles within a cavity, which are a necessary part of resistance and retention forms, should never be permitted to end in the external enamel line.

Order of Procedure. To simplify the preparation of all cavities and to insure the observance of certain fundamental principles it is well to follow a definite order of procedure. This will greatly facilitate the operations of the student and lead to the establishment of habits by the practitioner which will stand for thorough methods of execution.

The following would seem to be the natural order :

First.—Gain access.

Second.—Outline form.

Third.—Resistance form.

Fourth.—Retention form.

Fifth.—Convenience form.

Sixth.—Removal of remaining decay.

Seventh.—Finishing of enamel walls.

Eighth.—Toilet of the cavity.

Modification of Form is necessary in cavity preparation to meet the various properties of the different filling materials used. This is particularly true when considering the difference in edge strength and flow of metals and alloys.

The character of the oral fluids, the evident care bestowed upon the teeth, condition of patient's health, age of patient and the life expectancy of the patient and of the individual teeth, will frequently require a modification of cavity formation to best resist the recurrence of decay and the dislodgement of the filling through stress.

CHAPTER IV.

GAINING ACCESS.

Definition. Gaining access is the term applied to those procedures necessary to make sufficient room for the proper introduction of the filling.

Sufficient Access is Important, that we may have the advantage of space to properly handle the instruments and appliances used in the procedures of making a filling, that we may be able to introduce the filling into the cavity, that there may be complete contour restoration of tooth form and that the desired contact relation may be established to the adjacent tooth.

Access to the Tooth is the first consideration and will involve the opening of the mouth to a sufficient degree to permit of the free use of the usual appliances. The proximal spaces used for the adjustment of the dam should be examined to make sure that the rubber and ligatures will pass to the gingival line without injury. A sufficient number of teeth should be isolated, say four or five, to give a clear and unobstructive view of the cavity and surrounding teeth.

The operator must be able to bring the cavity into full view. Cases where there has been considerable decay sub-gingivally, and tumefaction of the gum septa has taken place, proper access will involve the packing of the cavity with a tampon of cotton which has been dipped in chlora-percha, or a packing of gutta-percha, for a period of twenty-four or forty-eight hours, to crowd the encroaching gum tissue from the cavity. A neglect of this consideration of access will often make proper management of the gingival wall and margin most difficult or impossible.

Surgical Access may be practiced on the cavity margins, when all tooth structure thus removed will subsequently be replaced with filling material. It may be practiced on the gum septa when there has been excessive tumefaction in the proximal space.

Formerly this method was practiced with Class Five cavities where the decay was to a marked extent subgingival, and it was desired to make a cohesive gold filling. However, much of this questionable practice may now be avoided by the use of the gold inlay, made from the wax model, as the presence of the overlying gum is no considerable hindrance.

Access as Related to Restoration of Proximal Space. As tooth

substance is lost through decay in proximal cavities, there is in most cases a movement of the teeth to the proximal, encroaching on the normal space, robbing the gum of sufficient room for full festoon. It is wholly impossible in such cases for the operator in making a filling to restore tooth contour, or leave a normal amount of room for the rehabilitation of the gum septa, without resorting to separation. The surfaces of a tooth which are covered with healthy gum tissue are practically immune from both primary and secondary caries, and it is greatly to the advantage of a filling, the outline of which in the proximal gingival third, to be so protected. Good access should be gained by preliminary separation, so that when the completed filling with its full tooth-form restoration is in place, there is restored the normal proximal space for the habitation of the gum septa. *A failure to regard this fact* will result in a strangulated, diseased and dwarfed septa, inviting an accumulation of the enemy of tooth structure and an early loss of the filling through secondary caries.

Restoration of Tooth Form is essential that the full function of the masticating organs may be established and maintained. It is also desirable for esthetic reasons, as the more nearly a dentist approaches complete tooth contour restoration, with all its details, the more pleasing is the appearance and the more artistic the result.

Proper Contact Point is often impossible unless sufficient access has been secured through separation. This contact should be a point of contact, the embrasures widening therefrom in every direction. It should be in no sense a line of contact or a surface, no matter how small. It is advisable many times, in this respect, to improve on nature by slightly varying the surface of the filling from the original shape of the tooth, as often the predisposing cause of the primary decay has been defective contact.

The Saving of Tooth Substance is materially effected by access through preliminary separation, particularly in the placing of inlays, as the more thoroughly this first step in procedure has been accomplished the less cutting will be required for convenience form, a point of no small importance.

Methods of Separation. There are two classifications of separation to gain access, preliminary, which is also slow separation, and immediate, which is rapid, both of which are a part of gaining access.

The preliminary is a part of the first consideration, while im-

mediate separation is brought to our attention during the introduction of the filling.

Preliminary Separation is best accomplished in proximal cavities in bicuspid and molars (Class Two) by packing into the partially excavated cavity an excess of gutta-percha base plate. A few days, or in some instances a few weeks, will suffice to accomplish the desired result, particularly if the patient uses that location in the mouth for daily mastication of solid food.

In the proximal space in the six anteriors preliminary separation is best accomplished by the use of cotton tampons tightly packed in the cavity and ligatured securely to position.

Immediate Separation is best accomplished with the mechanical separator, and should be used to gain additional access, not already secured by preliminary separation, or may be used primarily when only a small amount of additional space is desired. This instrument should be adjusted as soon as convenient after securing outline form, and removed only when the filling is finished.

Avoid Gum Injuries in the use of elastic rubber. In the use of the methods given care should be used not to crowd the gum tissue as permanent injury may result.

There are other materials used in slow separation, as linen tape, wooden wedges, etc., each with its merit and indicated use.

Soreness Resulting from Tooth Separation should be treated as any case of acute pericementitis, by giving the tooth physiological rest, and the use of stimulating applications on the gum over the tooth's root.

CHAPTER V.

OUTLINE FORM.

Definition. Outline form is that part of cavity preparation which determines the area of the tooth surface to be included within the external enamel line.

Rule 1. Extend to Sound Enamel. All cavity margins should be extended until all indications of surface decay have been included.

Rule 2. Obtain Full Length Rods. If necessary, further extend the outline until full-length enamel rods, supported by sound dentine, have been reached.

Rule 3. Self-Cleansing Margins. Extend the cavity outline until the surface of the filling can be so formed that the enamel margin not protected by the gum will be mechanically cleansed by the excursions of food in mastication.

Rule 4. In Relation to Developmental Grooves. A cavity outline should not follow a developmental groove, or parallel it so closely as to leave a small strip of intervening enamel. The outline should cross the grooves as squarely as possible.

Rule 5. Fissures and Sulcate Grooves. All fissures, sulcate grooves and angular developmental grooves encountered should be included within the cavity outline. This comes in for the greatest consideration when part of the outline is laid on an occlusal surface.

Rule 6. Enamel Eminences. The outline should avoid extreme eminences of enamel and centers of primary development. Such locations are subject to the extremes of stress during mastication. When the eminence in question is the seat of primary calcification it will be found to be less perfect in formation than the portion midway from that point to the grooves.

Rule 7. Avoid Angles in Outline. The outline should be made up of the greatest curves possible, avoiding all angles. Nearly flat axial surfaces should show nearly straight lines or the segments of very large circles, while on occlusal surfaces, which are made up of a succession of depressions and eminences, the outline should be a combination of smaller curves.

Rule 8. Outline in the Embrasures. The outlines in the labial, buccal and lingual embrasures should be parallel to each other and

at right angles to the seat of the cavity, and pass under the free margin of the gum at a point in full view of the operator.

Rule 9. Enamel Margins. The enamel margins should be planed smooth to a full cleavage of the enamel rods and then slightly beveled that the rods at the cavo-surface angle may be full-length

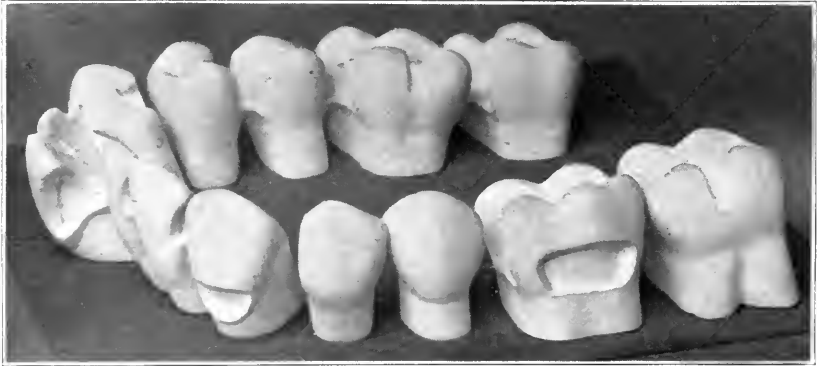

Fig. 13.—Technic group illustrating outline form.

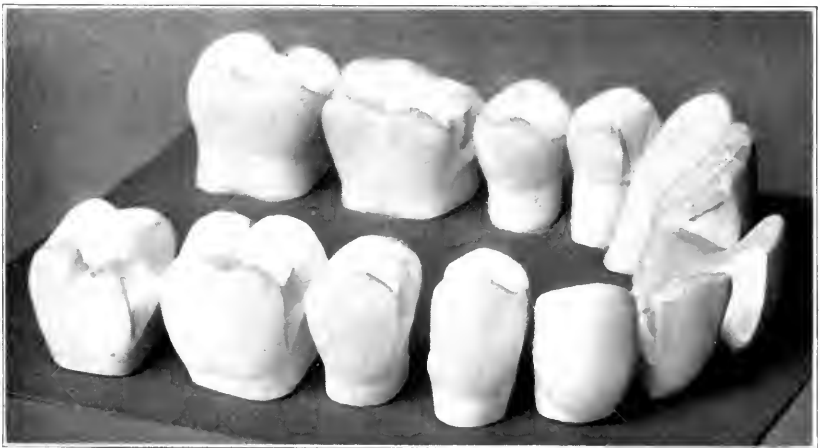

Fig. 14.—Another view of cavities illustrated in Fig. 13.

rods, supported by shortened enamel rods which are protected by the overlying filling material.

Rule 10. Extension for Prevention. When possible, carry the cavity outline upon smooth, unclean surfaces, from an area of great liability to caries to an area of lesser liability to caries.

This has reference to caries of enamel only and will come into

consideration in cavity outline when the rules previously given have not carried the outline to comparatively safe and immune localities.



Fig. 15.—Fillings in place in cavities shown in Figs. 13 and 14.

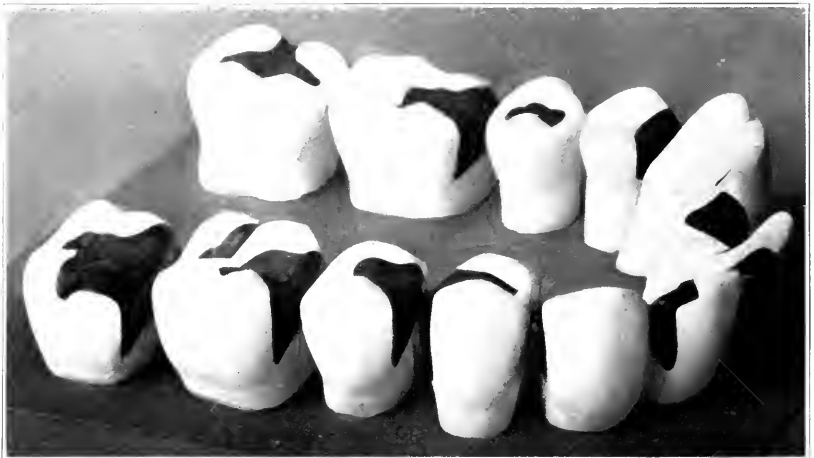

Fig. 16.—Another view of fillings shown in Fig. 15.

Extension for prevention does not mean the consideration of resistance to stress. It bears no reference to decay of the dentine. It has no relation to the management of frail walls.

Its maximum application is found in the management of small cavities where the ravages of decay have not yet carried the outline of the cavity to areas not subject to primary enamel dissolution.

The abuses of extension for prevention result in much unnecessary loss of tooth substance, while its sane and legitimate use is one of the most important factors in tooth salvage.

Dangers of Increased Cavity Outline. The danger of secondary caries increases in each mouth proportionately as the aggregate length of cavity outline is increased.

To Illustrate. If the total length of cavity outline of all fillings in a mouth is doubled by the increase in number of fillings the liability to secondary caries is doubled, all else being equal. For that reason each individual cavity should have its outline as short as permissible.

The laying of cavity outline in locations not susceptible to primary caries will materially decrease the liability to recurrent decay, even though the aggregate cavity outline in the mouth is thereby greatly lengthened. An aggregate cavity outline of two feet is preferable to a total of one foot, provided the additional length has been caused to extend to locations not liable to caries.

CHAPTER VI.

RESISTANCE FORM.

Definition.—*Extension for resistance* is a term applied to that procedure which has for its sole object the carrying of the cavity outline from localities subjected to great stress, to localities not frequently subjected to the crushing strain. This is often mistaken for extension for prevention, whereas it has reference only to resistance to stress.

A proper application of this procedure will involve a careful study of occlusion and articulation in each individual case.

Resistance form involves a consideration of the management of weakened enamel walls and a study of the flow and edge strength of the filling material used with a view of so shaping the cavity as to minimize the effects of the crushing strain.

Its importance is in direct proportion to the exposure of the filling in occlusion and articulation, and the strength of the closure of the jaws.

The force to provide for is from one to two hundred pounds and in some cases even more, particularly in mid-jaw locations.

Weakened enamel walls are those which through decay, or unnecessary cutting, have been robbed of much of their supporting dentine. All such unsupported enamel should be cut away with a chisel, particularly if by any chance the wall of enamel under consideration will receive much stress in the process of mastication, or the introduction of the filling.

Stress from within should be avoided by not allowing such weakened walls to remain and form any part of the retention of the filling.

Weakened walls are sometimes allowed to remain, or a portion of them, when they can be so protected by a layer of rigid filling material as to prevent all stress, but this is permissible only when their presence will screen unsightly metal fillings and when the kind of filling used can be introduced without injury to the walls.

Before applying the rubber dam each case should be inspected for the surface contact in occlusion and articulation and then the margin so laid as to occupy the least exposed position. Many times all stress cannot be avoided, but the amount of stress a margin is liable to receive should have due consideration and good judgment exercised in the placing of the margin.

Resistance Form as Applied to Filling Material. We are forced to consider the properties of the filling material to be used in each individual cavity. In preparing the cavity we consider the resisting power of the enamel margin we are able to obtain. We also take into account the resistance of the filling material used, to the crushing strain, as this property varies greatly. Amalgam, even under the most favorable manipulation, is subject to flow and more or less spheroiding, which often results in a slight exposure of the cavo-surface angle. Again, amalgam is not ductal, hence these edges of this filling are easily fractured at the margins under stress. This liability to fracture at the margin is also true of our cement and silicate fillings and great care should be exercised in placing the margins of these fillings. Cohesive gold, especially when alloyed with platinum, is our best filling material to resist the crushing strain at the margins, and when the edges are not too thin, the repeated blows from the opposing teeth only tend to drive this material in closer adaptation to the margins. When using the gold inlay, it is quite necessary to exercise great care at the margins to resist the crushing strain, not of the gold, but of the enamel margin and the intervening cement, for unless the gold inlay fits better than the average gold inlay, there is a line of cement which is subsequently dissolved. This leaves the last rods at the cavo-surface angle unprotected, and very liable to injury.

It therefore follows that the amount of marginal extension for resistance form is less for cohesive gold and gold inlays than other fillings. The greater the edge strength of the filling material, the more protection it gives the cavity margins. Yet resistance form should receive careful consideration with fillings of maximum edge strength.

CHAPTER VII.

RETENTION FORM.

Definition. Retention form is that part of the procedure in cavity preparation which deals with the provisions for preventing the filling from being displaced by the tipping strain. Force which results in tipping the filling bodily from the cavity, is one of the greatest enemies to permanency in tooth filling, second only to recurrent caries.

Partially Provided For in Resistance Form. Retention form is partially provided for in the previous step of resistance form, but it is further necessary that provision be made to resist the force of mastication in order to prevent the filling as a whole from being moved from its seat.

Maximum Retention Form is required in cavities in the proximal surfaces as the missing proximal wall renders these fillings particularly exposed to injury by the tipping force, during the movements of the mandible.

Flat seats for fillings are imperative in retention form. Seats should be cut in a plane at right angles to the stress of mastication, which is usually at right angles to the long axis of the tooth.

The Step as a Part of Retention Form. The addition of the step in cavities of Class Two and Class Four is for the purpose of giving added retention form. By this procedure in proximal cavities in bicusps and molars, the stress upon buccal and lingual walls of the cavity proper is transferred to those portions of the same walls which are a part of the step, a location much better situated to withstand the tipping strain. In cavities of Class Four, the addition of the step on the incisal or lingual, or both, will give added retention form, avoiding heavy cutting at the angle, which weakens the remaining tooth substance at the angle, to say nothing of the dangers of crossing the retractive tract of the pulp in this location.

Maximum Retention Form is not required when making simple cavities, as they are protected from the dangers of lateral strain by the presence of surrounding external walls. This will be found to be the case in cavities of Classes One, Three and Five when occlusion is normal. While in cavities of Classes Two, Four and Six, much additional cutting is sometimes necessary to give ample retention form.

Acute Angles Required. Much of the retention form required

is gained by laying the external surrounding walls at definite angles to the seat of the filling.

Little Retention in Enamel. It should be remembered in this step of cavity preparation that there is very little resistance to force in a filling wherein retention form is provided for in enamel walls. The enamel should be removed to a depth sufficient to get anchorage in angles laid in dentine. A good idea of the amount of retention form possessed by any completed cavity may be gained if one will for the time being imagine that all enamel has been removed from the tooth. The remaining cavity will still have nearly the original amount of retention form. We rely upon the presence of enamel in liable areas for resistance to recurrent caries and upon sound dentine for retention form.

CHAPTER VIII.

CONVENIENCE FORM.

Definition. Convenience form is that part of cavity preparation wherein is made those additional changes necessary for the proper placing of a filling.

Sparingly Used. As these additional cavity changes and their accompanying loss of tooth substance are made entirely for the convenience of the operator they should be resorted to only in cases of necessity.

Maximum Convenience Form. The cutting necessary for convenience form reaches the maximum; first, with inlay fillings, as the previously prepared filling is moved to position en masse; second, in the making of a cohesive gold filling, as it is of value to apply force as near as possible at a right angle to the anchorage of the first portion of gold, and at an angle of 45 degrees to the wall against which the gold is being condensed; third, in cavities in the posterior teeth, and in distal cavities as compared with mesial; fourth, more is required for proximal fillings not previously separated.

Minimum Convenience Form is required; first, in using plastic fillings; second, in anterior oral locations; third, where the teeth have had ample separation before the making of a proximal filling.

The Abuse of Convenience Form is of harm to the teeth and has reached its height in a desire to inlay every case possible. When excessive cutting for convenience form is necessary to the making of an inlay, it would often be better to avoid the unnecessary loss of tooth substance by changing the character of the filling.

Suitable Instruments for various locations in the mouth, particularly with the posterior distal cavities, will do much to minimize convenience form.

Previous Separation is the most potent factor of all in lessening the amount of cutting for convenience form, the same having been considered fully in access form, and should be resorted to in cavities of Classes Two and Three if for no other reason.

Starting Points for the making of a cohesive gold filling are a part of convenience form and are made by making one of the point angles more acute than is required for general retention. This is made in the point angle farthest from the hand when the

same is in position with the plugger point resting in the cavity. This will be found to be the point angle farthest from vision and most difficult to fill, and from the latter fact should be the first filled.

CHAPTER IX.

REMOVAL OF REMAINING CARIOUS DENTINE.—FINISHING ENAMEL WALLS.—TOILET OF THE CAVITY.

Removal of Remaining Carious Dentine.

Definition. This order is the secondary consideration of affected dentine. In the smaller cavities the previous steps in cavity preparation will have removed all affected dentine and this step has little consequence. However, it is well to have this step come to the mind even in these cases so that the minute corners and obscure localities are not allowed to pass imperfectly prepared.

In Large Decays the pulp is often in question. The dentine has been softened to a near approach to the pulp. If all of this be removed early in the procedure, the pulp will be exposed to the damaging effects of air drafts from the chip blower, or possibly low temperatures in the operating room. Pulp thus exposed not infrequently take on the initial stages of destructive diseases from which they never recover, resulting in much pain to the patient and chagrin to the operator. The foregoing is particularly true when one is making a filling for each of two large proximal cavities.

Two Large Proximal Cavities. It is often desirable to prepare both cavities at the same sitting, particularly when filling with amalgam.

With the cavity first prepared, there might be a long exposure of the pulp to a lower than body temperature, if the overlying decayed dentine is removed at the time the major portion is excavated.

Technic. The remaining decay in this step of procedure should be removed with broad spoon excavators, when working on axial or pulpal walls. In small cavities where there is no danger of pulp exposure the instruments should be small hatchets, with which the dento-enamel junction should be examined around the entire cavity. In case a softened area is found and removed the overlying enamel should be chiseled away, thus restoring the correct outline.

Where Exposed Pulp is expected or pulp treatment is intended, the decay is removed just following outline form.

Finishing Enamel Walls.

Definition. The last cutting done in the preparation of a cavity is the finishing of enamel walls. This should always be done with the rubber dam in place or at least sufficient means taken to prevent the margins from again becoming moist.

No Moisture should be Permitted to come in contact with any portion of the cavity surface, after final instrumentation, and if by accident any portion should become wet that portion should be thoroughly dried and freshened by cutting away the surface, and the filling immediately placed.

The Cavo-surface Angle of the cavity in every part of the cavity outline should receive special attention at this step in cavity preparation.

The Plane of the Enamel wall should be so laid with reference to the cleavage of the enamel that these will be cut more from the outer than the inner ends of the rods, resulting in the last rod at the cavo-surface angle being a full length rod, supported by shortened rods. The shortened enamel rods are covered with the filling material when the completed filling is in position.

This is accomplished by a slight planing motion parallel to the external enamel line, using a keen-edged chisel or enamel hatchet. The gingival margin trimmers are especially adapted for this purpose when finishing the margins in the gingival third.

The Marginal Bevel should be laid in a plane at an angle of from six to ten centigrade degrees from the plane of the enamel cleavage.

The Depth of the Marginal Bevel should generally not include more than one-fourth of the enamel wall, but when making a filling of inferior edge strength, as amalgam, porcelain, cement, etc., it becomes necessary to bury the bevel angle more deeply.

Locations subject to great stress also require the placing of the bevel angle more deeply, even carrying it beyond the enamel and laying it in the dentine.

Toilet of the Cavity.

Definition. The toilet of the cavity is the final step in the preparation of the cavity and consists of freeing the cavity of all loose particles of tooth substance which are not firmly attached to the cavity walls.

This is best accomplished by a blast of air from the chip blower, followed by a thorough sweeping and brushing of all surfaces with

cotton or spunk held in the pliers, and again using the chip blower to remove dust.

White Enamel Margins indicate the presence of loosened enamel rods. If the sweeping does not remove this, the margins should be again chiseled, using a keen-edged instrument and a light hand, then again be swept with cotton.

If the whitened margin still persists, it should be brushed over with an extra fine cuttle-fish disk or strip when the loosened rods will be carried away. The margin should be planed again with the chisel.

Care in the Use of Disk or Strip. It should be fully understood that when a disk or strip is used for this purpose, the grit must be so fine that there is no considerable cutting done, as there is danger of changing the relation of the bevel to the enamel cleavage.

All Fluids Should be Used Previous to Cavity Toilet. The habit of swabbing out cavities with alcohol or other substances after cavity toilet is useless, and may do harm by introducing substances with the liquid not easily removed.

Disinfection and Pulp Protection should have consideration following the removal of remaining decay and as a preliminary step in toilet of the cavity.

If a fixed oil, or an essential oil which may contain impurities has been used, free swabbing and scrubbing of the walls with alcohol, or sulphuric ether, is advised for cleansing purposes, to get rid of the oil and other residue. However, simply wiping the cavity out will not suffice. It must be thoroughly rubbed with an alcohol or ether-moistened cotton ball, followed by reasonable desiccation from the chip blower, and then every part of the walls and margins gone over and freshly cut. This is the only means of obtaining a clean surface.

Leaks in Rubber Dam, particularly near the gingival outline, must positively be detected. The portion which has become wet should be dried with an absorbent and the air blast. Then all parts which have been moistened must be gone over and freshly cut. Simply drying such portions is not adequate, as there is left salts and albuminoids from the saliva and blood serum which can only be removed by the cutting instruments. The placing of a filling over this gummy residue invites secondary caries. These deposits will subsequently dissolve out, resulting in a leak. It may be small

but the acid of tooth decay will easily exchange places with such films.

If the cleaning has been fairly well done, it may result only in what is termed "blue margin."

When time intervenes between cavity preparation and the making of the filling, as from one sitting to another, the walls and margins should be retrimmed to give fresh cut surfaces to fill against. This is not possible in the making of inlays as to retrim the margins destroys the fit. The fact that many times we cannot place the inlays against surfaces which have been freshly cut constitutes the greatest enemy to their permanency.

It is the one great argument that inlays should be made at one sitting and under dry conditions.

Conclusion. All fillings should be made against clean, freshly cut walls.

12
13
14
15
16
17
18
19
20
21
22
23
24
25
26
27
28
29
30
31
32
33
34
35
36
37
38
39
40
41
42
43
44
45
46
47
48
49
50
51
52
53
54
55
56
57
58
59
60
61
62
63
64
65
66
67
68
69
70
71
72
73
74
75
76
77
78
79
80
81
82
83
84
85
86
87
88
89
90
91
92
93
94
95
96
97
98
99
100

CHAPTER X.

MANAGEMENT OF PIT AND FISSURE CAVITIES. (CLASS ONE.)

Location. Class One cavities occur in the occlusal surfaces of molars and bicuspid; in the middle and occlusal thirds of the buccal and lingual surfaces of molars and in the lingual surfaces of incisors, more frequently in the laterals. (See Figs. 1 and 2.)

The Predisposing Cause of decay in these localities is a fault in the enamel due to imperfect closure of the enamel plates, affording a convenient point for the lodgment of food particles and the active principles of fermentation which is the exciting cause of all tooth decay.

Extension for Prevention is Seldom Necessary in this class of cavities from the fact that the surface of the enamel in the immediate neighborhood is exposed to the friction of mastication. It is only necessary to cut away the enamel walls sufficiently to uncover the area of affected dentine, and to include in the cavity outline all sharp grooves connected with seat of primary decay to a location that will permit a smooth finish to the surface of the filling and an outline void of angles.

Tendency to Extensive Dentinal Decay must be remembered in dealing with this class of cavities as the merest opening through the enamel will frequently, upon excavation, show an extensive loss of dentine.

Incipient Decays in Occlusal Defects.

Description. Upon examination it is found that the tine of a sharp explorer will pass between the non-united plates of enamel to the depth of the entire thickness of enamel in one or more points. A more careful examination may show the surface of the dentine to be softened to a greater or less extent immediately pulp-wise from the enamel fault. Such cases demand immediate attention.

Outline Form. To open such cavities there is placed in the engine a discarded No. $\frac{1}{2}$ or 1 round bur which has been made into a spade drill by flattening on two sides. This drill is made to travel between the plates of the enamel through a major portion of the defect, which results in widening the fissure. This preliminary step will result in much saving of burs, as a bur which has been once used on an enamel wall is unfitted to cut dentine. The

common practice of using dentate fissure burs for this work is considered as brutal to the patient and is a thief of the operator's time. A No. $\frac{1}{2}$ or 1 round bur is now used in the engine and applied to the dentine. By swaying the hand piece to and fro the dentine is cut away from beneath the enamel walls. The bur should be frequently removed to allow of cooling as heat readily develops and is a great and frequent source of pain to the patient.

The Use of the Chisel is next advised for the removal of the overhanging enamel wall; first, because this is the easiest and speediest means of its accomplishment, and second, because this is the only means of securing the cleavage of the enamel, giving the operator the opportunity to judge the amount of resistance to stress in the several localities, and to learn of the direction of the enamel rods. Many times a chisel-edged hatchet will be most advantageous, one which has a chisel edge upon the sides of the blade as well as the cutting edge. The size should be governed by the size of the opening secured, but in every case as large an instrument as the orifice will admit should be used. This process should be repeated with bur for cutting dentine and chisel or hatchet for cleaving enamel until the desired cavity outline is obtained.

Resistance Form. The operator should include all fissure and sulcate grooves. Cross all grooves and ridges at as near a right angle as possible. Avoid eminences of primary calcification. Lay the outline as much as possible along the sloping sides of the triangles and ridges, as these are the most favored localities for a cavity margin, for on these sloping surfaces we find the greatest amount of friction during the process of mastication, due to the excursions of food, and they are the least exposed to direct stress, as the blows are of glancing nature.

Retention Form. Here is a good rule to follow in cavities of Class One. When the depth of the cavity is equal to or greater than the width, parallel walls are sufficient. But when the width exceeds the depth the external walls should meet the internal wall at a slightly acute angle. These angles are best made acute by the use of a chisel-edged hatchet or hoe, having corners that are slightly acute. With a planing motion they should be made to travel parallel with the base line angles. This will, at the same time, flatten the seat or pulpal wall. The extreme ends of long arms in a filling, such as results from following a slender fissure, must be made retentive.

Convenience Form. No convenience form is usually necessary in small cavities Class One, except in rare instances it may be of advantage to sharpen one of the distant point angles to facilitate the starting of a cohesive gold filling. But usually the first portion of gold may be used of sufficient size to entirely cover the pulpal wall, in which case it can be securely locked to position between the surrounding walls.

Removal of Remaining Decay. By this time the carious dentine



Fig. 17.—Complex Class One cavity prepared.

will usually have been removed. Should any remain it should be excavated with suitable spoons.

At this point there should be a thorough inspection of the dento-enamel junction for small areas of softened dentine which may have escaped notice.

The Walls should all be flat, particularly the pulpal. In cases where decay has progressed so deeply into the dentine that to flatten the pulpal wall would cause the involvement of the recessional tracts of the horns of the pulp, the base-line angle should be made intermittent, omitting the squaring of the angles in the regions of the recessional tracts.

Disinfection. The cavity should be flooded with alcohol carrying a small per cent of formaldehyde, say one or one-half per cent, and evaporated to dryness.

Finish of Enamel Walls. The enamel wall should be planed for

the entire outline of the cavity with a sharp chisel using a light hand; the desired cavo-surface angle secured, and the bevel angle buried to the desired depth. The movement of the chisel should parallel the travel of the external enamel line.

Toilet of the Cavity. The cavity should be swept with a tightly rolled cotton ball or piece of spunk in the pliers and the dust finally removed with a blast of air from the chip-blower, and the filling immediately placed.

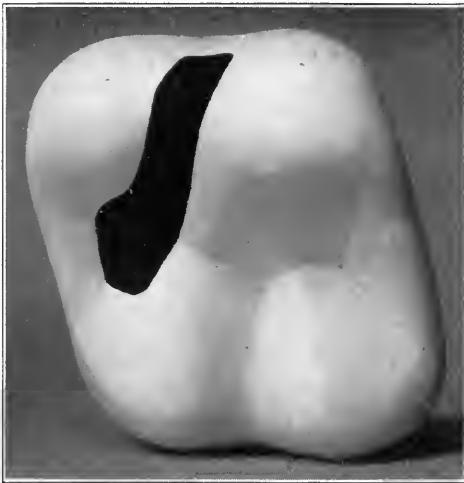

Fig. 18.—Class One filled. Cavity shown in Fig. 17.

Inlays. If the cavity is to be occupied by an inlay, retention form may have been omitted and applied to the cavity just before setting the filling, in which case the toilet of the cavity should be repeated. If the cavity has already been given retention form the same should be temporarily removed while making the model by wiping into the retaining angles wax, temporary stopping, or cement to be removed before final placing of the filling.

CHAPTER XI.

MANAGEMENT OF PIT AND FISSURE CAVITIES. (CLASS ONE CONCLUDED.)

Large Cavities in Central Fossa of Molars.

Description. Such cavities are usually the result of knowing neglect on the part of the patient. However, in cases where the enamel is strong and of a good resistant quality, or the teeth are so occluded as to have received little stress, the patient may be in ignorance of the great havoc which has been done, due to the major portion of the enamel remaining intact. There may exist in such cases only the slightest aperture through a defective fissure or fault in the enamel.

Outline Form. This division of Class One should be opened with a straight or bin-angle chisel of rather large size to prevent easy passage to the sensitive pulpal wall. A chisel of from two to three millimeters in width is advised. The securing of adequate finger rest on adjacent tissues is important. The chisel should be applied so as to throw the chips into the cavity, and the mallet substituted for heavy hand pressure. It is best to begin on margins most mesial and nearest the operator's eyes, as this increases the range of vision to the deeper portions of the cavity at an early stage in the procedure. This chipping away of the enamel should be continued until enamel supported by sound dentine is reached and until the margins have been carried to desired regions as set forth in general in the chapter on outline form.

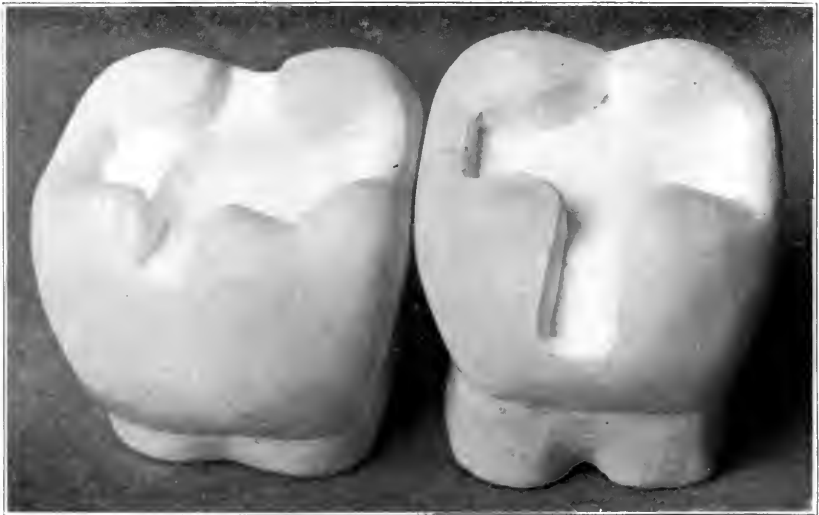When Pulp Exposure is Feared. In this case the sixth step in cavity preparation will come in third and we have for consideration the removal of remaining decay.

Up to this point only the most superficial examination of the internal surfaces has been made.

Placing the Rubber Dam at this point is expedient as dryness is imperative. The decay is now removed with large spoon excavators, whose blades are at least two millimeters wide. These spoons which should be keen of edge are carefully worked under the edges of the masses of softened dentine and by a prying, sweeping movement this lifted en masse from the walls. The blade of the excavator should be prevented from seraping, or sliding over the regions of suspected exposure.

When the Pulp is Exposed or nearly so the operator will proceed to pulp treatment, of either devitalization or conservation, as the case demands. This step completed outline form is again taken up and fissures and sulcate grooves included in the cavity outline.

Resistance and Retention Forms. As to resistance, we have only to consider the probable stress to be sustained by the filling as a whole and of the margins in their various localities. This will involve a study of each case in hand, as to occlusion and articulation, as well as to habits of the patient in mastication. The problem of concave pulpal wall is here met in its most exasperating



A

B

Fig. 19.—Large Class One cavities prepared.

form. Many times if the operator were to take the lower levels of the pulpal wall and attempt to flatten and carry this wall laterally until it could be made to meet surrounding walls at different angles, the recessional tracts of the pulp would be crossed and exposure of that organ result.

The Flattening of the Pulpal Walls Avoided. (See Fig. 19.) This lateral cutting to flatten pulpal walls may be avoided in two ways:

First. The operator may establish a level higher up on the lateral walls for the creation of the base line angles, resulting in steps. These steps should be established in places most remote

from recessional tracts, which will generally be found in the neighborhood of developmental grooves. There should be at least three of the steps or small supplemental seats. Four point suspension is better. As the seats are small and will probably be required to carry relatively heavy loads their angles should be most definite.

Second. To avoid the flattening of these pulpal walls in large cavities of this class the operator should build the metal portion of the filling immediately into cement which has been applied to the pulpal wall. This renders the base of the filling adhesive to its seat and nullifies the tendency of the filling to slip or revolve under load.

It might be said here that the principle of the inlay is marginal

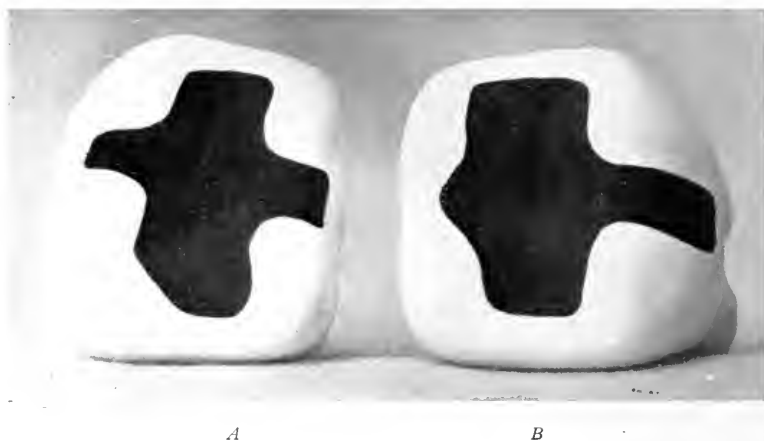

Fig. 20.—Class One filled. Cavities shown in Fig. 19.

ridge introduced into a built-in filling, a much valued feature by many operators.

Convenience Form. There is no convenience form required in this class of cavities when making a plastic filling. In the making of a cohesive gold filling in this division of cavities care must be taken that the mesial wall can be reached by direct force from the plugger point. In some cases it will be required to move the mesial margin well upon the mesial marginal ridge to accomplish the desired result.

Convenience Point for the beginning of the first pieces of gold should be obtained through the use of a small quantity of thin cement applied to the deepest portions of the cavity.

Finish of Enamel Walls and Toilet. The cavity should be phenol-

ized and the same evaporated to dryness. The entire cavity outline should be freshly planed, the margins slightly beveled and a positively determined cavo-surface angle established. The depth the bevel angle is to be buried should be determined.

The cavity should be thoroughly swept with cotton, the dust dissipated with a blast from the chip blower and the filling immediately placed.

Pit Cavities in Buccal and Lingual Surfaces of Molars.

Description. These cavities have their origin in defects in the enamel on the buccal surface of lower molars and the lingual surface of upper molars.

Instrumentation is the same for the same class and size of cav-

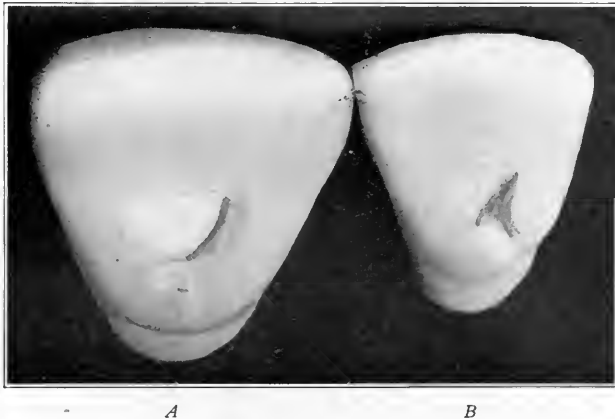

Fig. 21.—Lingual pit cavities.

ities just described on the occlusal surface, excepting perhaps it may be necessary to use the engine burs in the contra-angle hand piece, a necessity seldom met with on the occlusal surfaces.

Outline Form. The outline should be carried well out of the pit or groove and sufficiently extended to meet the general rules given in the chapter on this subject.

Resistance Form will come up for consideration only when the outline approaches the occlusal marginal ridge. In such cases if the occlusal wall is not made up of a sufficient bulk of dentine to withstand the stress of mastication, the outline should be carried over the marginal ridge to the occlusal surface, in which case rules for the outline of this portion of the cavity will be the same as previously given and applicable to all cavities invading occlusal surfaces.

Extension for Prevention will come in for consideration when the outline has for other causes been brought near to the free margin of the gum. A full application of the rule "Extension for prevention" would demand that the gingival outline be carried under the free margin of the gum when the gum has already been approached to within one millimeter. A failure to extend the outline is permissible in mouths kept scrupulously clean.

Retention Form. This step is very simple when the cavity does not involve the occlusal surface and is fully obtained when the internal line angles have been well squared. However, when the cavity reaches the occlusal surface, the filling is subjected to the greatest amount of tipping strain in mastication. These will then

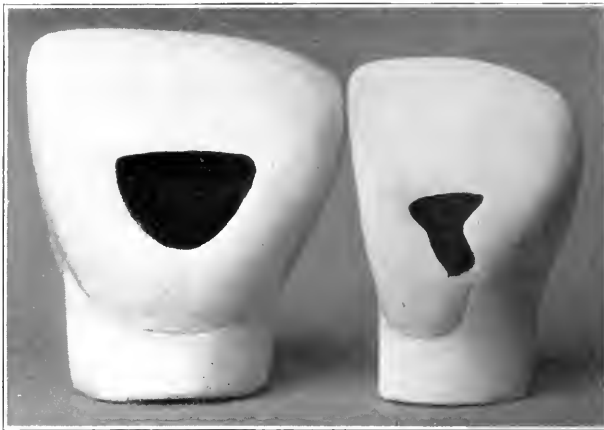

Fig. 22.—Class One filled. Cavities shown in Fig. 21.

demand a flat gingival wall, and in some cases of a vital tooth, a flat pulpal wall placed parallel to the gingival wall, and the line angles surrounding these walls well defined. The four point angles should be slightly acute.

Finish of Enamel Walls. In the management of these axial surface pit and fissure cavities the varying slant of the enamel rods should not be lost sight of. This should be noted when outlining the cavity with the chisel. The rods will generally be found to incline towards the pit, from every direction close to the defect, while a little way out they will be found at right angles to the surface.

Going farther toward both the occlusal surface and gingival line,

the outer ends of the rods will be found to incline more and more away from the seat of decay.

These facts should be borne in mind and a full cleavage obtained.

There now remains only the usual marginal bevel and cavity toilet.

Pit Cavities in Lingual Surfaces of Upper Incisors.

Should Receive Early Attention. These cavities should be detected in their early stages as their near location to the pulp renders pulp complications an early sequence.

It is the best of practice to permanently fill all cases presented where faults in enamel are diagnosed.

Instrumentation. Their location renders excavation hazardous. The engine bur should be used for superficial opening only, the most of the preparation being done with hand instruments.

Outline Form. The general rules in outline form should be observed. Particular note should be made of the extreme incisal inclination of the outer ends of the enamel rods along the margin of the incisal wall.

Inciso-Axial Line Angle. It is generally advisable to allow the incisal wall to meet the axial at quite an obtuse angle, in some cases almost to the obliteration of this line angle, as the squaring of this angle will greatly endanger the pulp.

CHAPTER XII.

MANAGEMENT OF PROXIMAL CAVITIES IN BICUSPIDS AND MOLARS. (CLASS TWO.)

Location. Class Two cavities are those which originate on the proximal surfaces of molars and bicuspids at a point slightly gingival from the point of contact.

Predisposing Cause. The predisposing cause is the fact of the presence of the adjoining tooth which establishes and maintains the sheltered position for the accumulation of substances which undergo fermentative decomposition.

Early Detection of These Cavities is Essential. It is of the utmost importance that Class Two cavities be discovered early. More pulps are lost to the teeth from the neglect of these cavities than from any other cause. Their early detection is by no means an easy matter to the inexperienced operator, as often their presence is shown only by a change in the color of the overlying enamel.

There are yet other cases where the teeth must be separated for an examination of the suspected surfaces.

It requires education in the use of the explorer to detect the difference in the "feel" of the explorer tine in the proximal space and the entry of the point into a cavity of slight depth. When the decay has extended along the dento-enamel junction the case becomes much easier and should never escape the detection of the operator.

Small Proximal Cavities (Class Two).

Description. By examination there is found to be established an area of decay upon the enamel surface between contact point and the free margin of the gum, or one or both teeth which go to form the space in question. The dentine may or may not be involved. The marginal ridge is yet intact and firm. The enamel shows no signs of injury in either the buccal or lingual embrasures. (Molar, Fig. 3.)

Gaining Access. Opening the cavity is often the most difficult step in the procedure.

There are three plans of procedure open to the operator.

The First Method. The one most common and often the best is to place the angle of a sharp, straight chisel, say one millimeter in width, on the proximal slope of the marginal ridge and tap it lightly with a mallet; turn the other angle so that the chisel

edge rests at forty-five degrees to the position of first impact and again apply the mallet. Repeat several times and this will generally break away the enamel rods in a small V-shaped space. This may be continued until the cavity is completely uncovered. In comparatively resistant cases the bi-bevel drill may be applied to break in the enamel.

The Second Method of procedure is to use the bi-bevel drill in the mesial or distal pit, giving the hand piece that slant which will cause the drill to enter the area of decay, when sufficient depth has been reached. The chisel is then applied and the occlusal surface enamel cleaved away either by hand pressure or the mallet. This method is more liable to cause pain than the first given and should be used with caution.

The Third Method is to adjust the mechanical separator and attack the enamel with a small chisel from the buccal direction, gradually shifting more and more to the occlusal surface until finally the enamel ridge gives way to the force of the chisel.

Preliminary Separation should in most cases be resorted to for proper access for the many reasons set forth in Chapter IV.

This is Best Accomplished by packing the cavity at this stage with gutta-percha for a few days or weeks. When case returns we should be ready to consider outline form.

Outline Form. Outline form in Class Two involves the outlining of the cavity proper, as well as the outlining of the occlusal step which is generally necessary because of the more secure seating and rigidity it gives a filling in all proximo-occlusal cavities in molars and bicuspids when the marginal ridge has been broken.

Step May be Omitted. *First:* In cases which are to remain permanently disarticulated, as when opposing tooth has been lost.

Second: When the proximating tooth is to be absent permanently thus obviating much cutting buccally and lingually in extension for prevention, as the remaining walls are sometimes strong enough to give sufficient resistance form without the added step.

Third: In proximal decays in the gingival third following excessive gum recession (so-called senile decay).

Fourth: When for any reason the patient should be shielded from long operations, or the life expectancy of either the patient or the individual tooth is short.

Fifth: In that form of lower bicuspids with a well defined and perfect transverse ridge. (Fig. 23.)

Outline of Cavity Proper. The outline should be carried into

both buccal and lingual embrasures until the excursions of food through these embrasures will sweep the margins of the completed filling for its entire length. This extension will result in carrying the outline out sufficiently that it can be seen to pass under the gum in full view.

A Good Rule to Follow is to cut sufficiently that a chisel one millimeter in width will pass easily from the embrasures to the open cavity when dragging the cutting edge lightly over the free margin of the gum. This is stated as a general rule only, there being circumstances which would permit falling short of this amount of space and yet there are cases which demand a greater amount of cutting to fully meet the requirements of extension for prevention, due to oral conditions and dental irregularities.

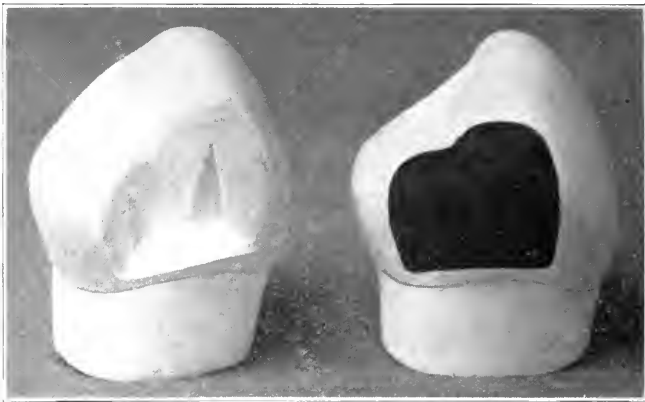


Fig. 23.—One of the few cases in which the step may be omitted in Class Two cavities.

Extensions Gingivally. The cavity outline should be carried subgingivally in extension for prevention when from other reasons that part of the outline approaches to within one millimeter of the gum line. The application of this rule will invariably cause the outline to go beneath the gum in case the gum is in or resumes its normal position.


If there is reason to believe that it will return to its normal position this fact should be considered. In cases of permanent recession it is better to stop the cavity outline midway from contact to gum line.

Care at Axio-Gingival Angles. The buccal and lingual portions of the outline should be carried directly gingivally and be made

to join the gingival portion of the outline by the use of a segment of a small circle. The use of a large circle here is a most common error. Investigation of fillings will show many failures wherein a large circle has been used allowing the external outline to disappear in the proximal space before it has disappeared beneath the gum.

The Gingival Outline should be a straight outline except in well defined and high gum festoons, when it may be made convex to the occlusal surface.

Forming the Step. Place a small round bur or spade drill against the axial wall at the dento-enamel junction, immediately below the central fissure and undermine the enamel the desired distance in the direction of the central axial line of the tooth. Here apply all of the rules and methods of procedure given in the formation



A

B

Fig. 24.—Class Two cavities in molar and bicuspid suitable for cohesive gold or amalgam.

of a simple occlusal cavity. Also remember to apply the rules as given in outline form, particularly as to resistance form.

Area Included. In addition to the above it is a safe rule to state that the step portion should involve the central third of the occlusal surface bucco-lingually.

Avoid all Angles in outline. Care should be taken when using the step that its union with the cavity proper does not show in the outline by an angle at their junction. Also when not using the step, as in the few cases cited, care should be given not to allow the axio-buccal and axio-lingual line angles to meet the external enamel line. These line angles should be stopped before they approach the enamel wall.


Resistance and Retention Forms. To reach the maximum of these forms it is necessary that the *gingival wall* be flat and laid in a plane at right angles to the stress of mastication. The gingival wall should meet the axial wall at an angle slightly acute.

The grooving of the gingival wall is condemned.

The Buccal and Lingual Walls should be flat, parallel, meet the gingival wall at least at right angles, and meet the axial wall at definite and acute angles.

The Axial Wall should be convex to the proximal and meet the pulpal wall in a rounded pulpo-axial line angle.

The Pulpal Wall should be laid parallel to the same plane as the gingival wall and slightly broader at the portion most distant from the cavity proper. This gives a pulpo-distal or pulpo-



A B
Fig. 25.—Class Two filled. Cavities shown in Fig. 24.

mesial line angle of a little greater length than that of the pulpo-axial line angle, resulting in a dovetailed effect that is most efficient.

Line Angles. The line angles should be squared out and made definite by the use of small hatchets and hoes of suitable shapes to reach the desired localities.

The gingivo-buccal and gingivo-lingual line angles should extend from their corresponding point angles to the dento-enamel junction. The axio-buccal and axio-lingual line angles which arise in the same point angles should travel occlusally one-third to one-half the height of the axial wall. In some rare cases where the pulpal wall is low from decay these line angles may meet the axio-

pulpal line angle. A failure to observe this rule endangers the pulp through a liability of crossing its recessional tracts.

Convenience Form. In the making of a cohesive gold filling a convenience point for the retention of the first piece of gold is desirable. This is best accomplished by employing a small inverted cone bur, say number thirty-three and one-half.

The flat face is placed on the gingival wall and first sunk to one-third its depth then drawn for a short distance occlusally along the axial line angle, taking dentine slightly at the expense of both axial and external walls.




Fig. 26.—Fillings shown in Fig. 25 contacted, illustrating the marble contact.

With the making of a plastic filling there is no need of cutting for convenience form in this cavity.

Inlays. When using an inlay proper convenience form is obtained by thorough separation and causing the external walls of both step and cavity proper to meet the gingival and pulpal wall at slightly obtuse angles. This will give draw to the occlusal.

Finish of Enamel Walls. The enamel walls are planed to full cleavage and the margins are slightly beveled. All but the gingival margins may be done with the chisel. Special instruments are required to bevel the gingival cavo-surface angle, known as gingival marginal trimmers. These are made rights and lefts for mesial cavities, and rights and lefts for distal cavities and should be on

hand in two sizes, which would result in eight instruments in a good working set.

In planing the gingival enamel wall the operator should have in mind the gingival inclination of the enamel rods in this locality.

Toilet of the Cavity should now be made and the filling immediately placed.

CHAPTER XIII.

LARGE PROXIMAL CAVITIES ENDANGERING THE PULP. (CLASS TWO, CONTINUED.)

Description. This class of cavities when presented show extensive loss of dentine in the proximal wall. The marginal ridge may be standing or it may have been broken through stress of mastication. In some cases there may be an occlusal decay in the central fossa.

Danger of Pulp Exposure. There is always great danger of pulp exposure in these cases and this fact must be continually borne in mind, during the procedure of preparation. The liability is increased when the patient is young or the cusps of the tooth are high, particularly when there exists a deep pit cavity in the occlusal surface necessitating a low pulpal wall. With young patients the pulps are large and the horns of the pulp generally extend well toward the cusps. Teeth with high, prominent cusps usually have long pulp horns, which should be considered in making resistance, retention and convenience forms.

Outline Form. The first cuts in this class of cavities should be with the chisel, using hand pressure, being sure that adequate hand and finger guard has been obtained. This precaution is essential as the chisel must be prevented from reaching the sensitive softened dentine within the cavity. Place the chisel so as to throw the chips into the cavity. The chisel should be made to engage only a small portion of enamel at each cut. Should the enamel prove resistant the aid of the mallet may be resorted to, still maintaining a firm finger rest.

Extension for Prevention is frequently not necessary as the extension necessary for proper resistance form will carry the cavity the required distance into both buccal and lingual embrasures. However, in many cases the decay will be found to have progressed more toward one embrasure than the other which necessitates additional cutting for prevention, in the direction of the embrasure least approached by decay. This should be done to the fulfillment of the rule for "extension for prevention."

Gingival Outline. The gingival outline in these cases will generally be under the free margin of the gum. At this stage it should be planed with the enamel hatchets until the overhanging enamel

is broken away to give access form for the free passage of the dam and ligature, which should now be placed and the cavity superficially sterilized.

Occlusal Outline. When the cavity has been rendered dry the occlusal outline should be proceeded with. This is carried out as previously given in the forming of the step portion, and the full satisfaction of the rules given in Outline Form, Chapter V.

Removal of Remaining Decay. This is an instance where the sixth step in cavity preparation comes in third and should now be cautiously proceeded with.

Technic. Large spoons should be used. The softened and discolored dentine should be lifted from its position with as little pressure pulp-wise as possible. If exposure exists upon its removal, pulp treatment for devitalization and removal is the immediate procedure. If exposure does not exist and the operator has reason to believe that that organ is healthy the pulpal and axial walls should be lightly scraped with large spoon excavators, the walls disinfected with the favorite drug, then dried, phenolized and dried again, the latter precaution to prevent thermal shock to the pulp during the remaining portion of cavity preparation, the imperative necessity for which is shown when pain is induced by a blast of air from the chip blower.

Resistance and Retention Forms. When the central portion of the decay is found to be deep and no exposure exists, the pulpal and axial walls should be left in their central portions much as decay has left them, no attempt being made to flatten these walls on a plane of their greatest depth as pulp exposure may result. The line angles surrounding these two walls should be established on higher levels.

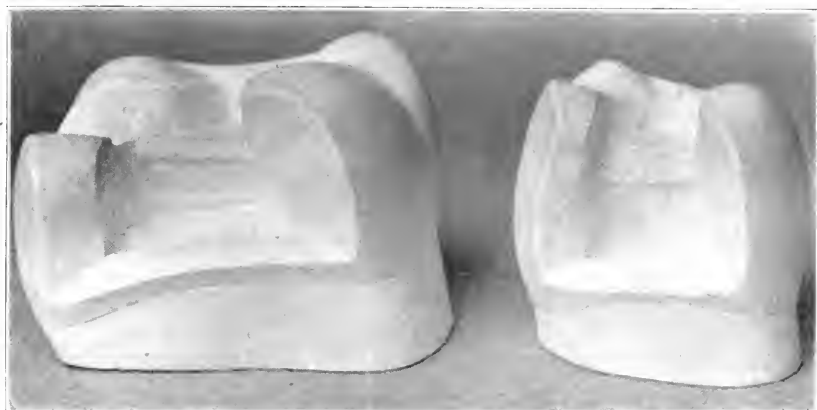
The Gingival Wall should be made flat in every direction. This is accomplished by lowering the point angles root-wise to the level of the central portion.

Convenience Form. Every part of the cavity should be examined to see that it is accessible to direct force in the packing of the filling and a convenience point cut in each of the gingivo-axio-lingual and gingivo-axio-buccal point angles.

Pulp Protection. The cavity should be flooded with an efficient non-irritating disinfectant, dried, phenolized and again dried. If the pulp is in danger it should be protected as described in Chapter XXXIV.

Finish of Enamel Walls.

The enamel walls should now be inspected, corrected for complete cleavage and the proper cavo-surface angle established, us-



A

B

Fig. 27.—Large Class Two cavities in non vital teeth restoring part of the occlusal surface for the protection of weakened walls.



A

B

Fig. 28.—Class Two filled. Cavities shown in Fig. 27.

ing for this a keen-edged chisel and a light hand with a planing motion parallel with the external enamel line.

For Toilet of the Cavity use a few blasts of air from the chip

blower, followed with a thorough brushing with a ball of cotton and more air blasts. The filling should be immediately placed.

Large Proximal Cavities in Non-Vital Teeth.

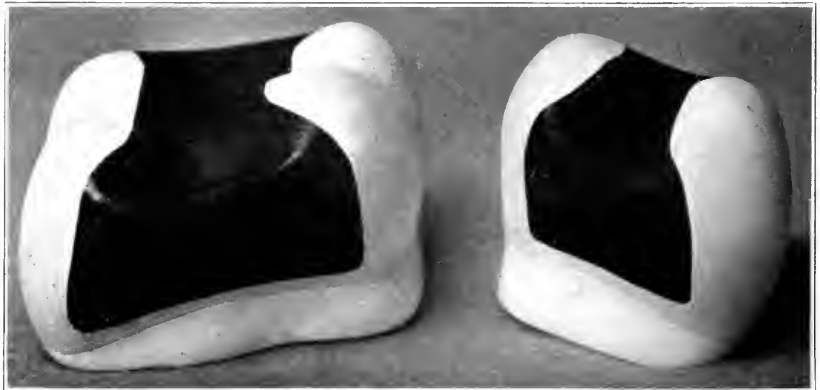
In the management of this class of cavities, cutting for resistance



A

B

Fig. 29.—Mesio-occluso-distal (M.O.D.) cavities in molar and bicuspid, vital teeth. Note that the occlusal portion of the cavities does not show any retentive form. It is not necessary to undercut these walls as there is ample retention in other parts of the cavity.



A

B

Fig. 30.—Mesio-occluso-distal fillings. Cavities shown in Fig. 29.

to stress reaches the maximum and outline is many times materially extended for this purpose alone.

Outline Form, With Molars. All decay and softened dentine is removed. Often this will leave standing an entire cusp of un-

supported enamel and possibly both proximal cusps are thus unsupported. In such cases a thin-edged carborundum wheel is placed on the occlusal and this surface ground away for one or two millimeters, extending as far toward the central axial line to just be-

*A**B*

Fig. 31.—(A) First superior molar, non-vital, restoring the lingual cusps. (B) Second superior bicuspid, non-vital, restoring the entire occlusal surface.


*A**B*

Fig. 32.—Class Two filled. Cavities shown in Fig. 31.

yond the buccal or lingual groove, or both when both cusps are to be removed. This grinding process is carried to a greater depth in the region of the groove, resulting in a step which gives the filling an occlusal surface seating.

With Bicuspids this buccal or lingual outline is carried past the crest of the cusp involved and partially down the opposite slope. This procedure results in disarticulating the frail enamel wall and so placing the metal that it will receive the force of mastication.

In Mesio-Disto-Occlusal Cavities in both bicuspids and molars, which are vital, and when using cohesive gold as a filling, the occlusal outline should include all of the middle third bucco-lingually. It should be made sufficiently deep to remove all of the enamel in the central fissure.

For cohesive gold the buccal and lingual walls should be parallel and without retention as the retentive form should all be placed low in the gingival angles of both mesial and distal cavities.

In the use of amalgam the outline should be farther extended bucco-lingually, to include about one-half of each of the buccal and lingual thirds. Thus two-thirds of the occlusal surface bucco-lingually will be filling. This occlusal portion should be without retentive form with the buccal and lingual walls meeting the pulpal wall at angles slightly obtuse. This is the minimum amount of extension for favorable vital cases.

In Cases of Extreme Frailty the entire occlusal surface of molars and bicuspids should be replaced with filling of at least one millimeter in thickness. With upper molars and bicuspids, when non-vital and very frail mesio-occluso-distal cavities, the lingual cusps should be removed for one or two millimeters and replaced with filling material.

Retention Form is Completed by squaring up the side walls and sub-pulpal wall, making a box shape of the pulp chamber, with fairly definite point angles.

Convenience Form. No convenience form is necessary in this class of cavities, except for inlay fillings, which will be considered later.

Neglected Access Form. In cases where large proximal cavities are of long standing and there has been much tipping to the proximal of one or both teeth, preliminary separation for good access is essential. Without this preliminary step complete contour restoration and proper contact is impossible. This is particularly true when the cavity is in the mesial of the first molar. Many times the second bicuspid will seem to have been engulfed within the molar cavity. In cases where preliminary separation for obvious reasons is impossible, the evil may be partly overcome by the free cutting away of both buccal and lingual walls until the filling may

be built in with a proximal surface slightly convex to the proximal. However, this is but a makeshift of a filling and the resulting proximal space will always be defective.

Toilet of the Cavity. In large decays, particularly if the pulp has been removed, there is more or less danger in leaving coatings of various materials clinging to the walls. Care should be taken that the walls are scrupulously clean. It is an advantage if the cavity be scrubbed with solvents for the suspected coatings. The cavity should then be dried, the enamel walls planed and the cavity freed of all debris.

Over-desiccation. Particular care should be had not to use excess desiccation in pulpless teeth as this will render them brittle and easy of fracture when put to use.

CHAPTER XIV.

MANAGEMENT OF PROXIMAL CAVITIES IN INCISORS AND CUSPIDS NOT INVOLVING THE ANGLE. (CLASS THREE.)

Definition. Class Three cavities are those in the proximal of incisors and cuspids where it is not necessary to restore the incisal angle. The angle may be allowed to remain when the enamel at the angle is supported by sound dentine to an extent which will give it sufficient resistance to prevent fracture under stress of mastication.

General Form of Class Three. Cavities in incisor proximal surfaces differ from all others in that they are in the surface of teeth of a triangular form and the cavities of necessity must be of this form, rather than the typical box shape in the other classes of cavities.

Location of Primary Decay. The location of primary decay, as with all contact decay, is just gingivally from contact point. This will result, as a rule, in the seat of initial decay being about midway from the incisal edge to the gingival outline. As the plates of enamel, both labial and lingual, are quite heavy and usually removed from direct stress, there will generally be considerable loss of dentine while the enamel walls are yet intact. The decay may be apparently small, yet reflected light by the use of mouth mirror will show a discoloration of a well defined area. The curved tine of an explorer may or may not enter from either the labial or lingual embrasure.

Opening the Cavity. Bathe the surfaces of all the anterior teeth in that jaw with water to free them of micro-organisms and gummy material, particularly the gingival border, and apply the mechanical separator.

Gaining Access. With a small straight chisel of about one millimeter in width cut away the enamel edge, throwing the chips into the cavity. Adequate finger rest must be secured before applying the chisel and only small portions of enamel engaged at each application, as a failure in either respect may result in checking the enamel to a greater extent than desired. When sufficient entrance has been made to the cavity to admit the instrument, the remaining enamel margins may be planed from this direction until a liga-

ture will pass from the incisal to the gingival line. Where time will permit the case should be packed for preliminary separation as described in Chapter IV. If immediate separation and filling is to be practiced the rubber dam should be adjusted and the mechanical separator placed and tightened to a snug pressure. The separator should be tightened from time to time until the required separation is obtained. The approximate space required is from one-half to one millimeter where only one cavity exists in the proximal, and a full millimeter in cases where two cavities exist.

Outline Form. As these cavities are located in the most exposed portion of the mouth esthetic reasons demand as little cutting as possible consistent with the demands for permanency. However,

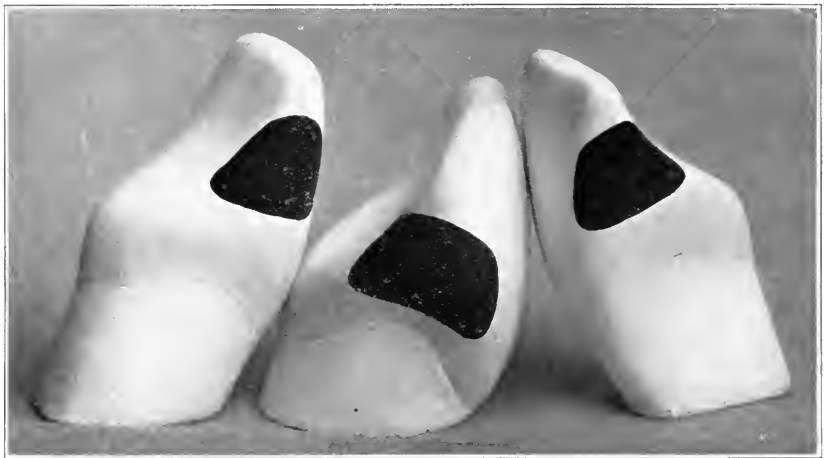

Fig. 33.—Class Three cavities filled so that the entire cavity outline, excepting that portion covered by gum tissue, is in full view of the operator. The gingival portion of (B) has been cut sufficiently low to be covered by gum tissue.

it is a good rule, in outlining cavities of Class Three, to extend in all directions until when the filling is completed, the entire cavity outline not covered with gum tissue, is in full view of the operator. (Fig. 33.) As stated before, excessive cutting to obtain this condition may be obviated by proper separation.

The Gingival Outline should be carried midway between contact and gum line, and farther extended to go under the gum when it approaches to within one millimeter of the gum. Great care should be exercised to square out both labial and lingual axio-gingival angles, carrying them sufficiently into these embrasures

that the cavity margins may be in full view as they pass under the gum.

The Incisal Outline should be carried incisally until the margin of the filling will be permanently in view, with a space sufficient to admit of the free use of the tooth brush on the margin. This would, in many instances, carry the margin beyond the incisal edge and make a Class Four cavity and is only avoided by separation and filling of the cavity to a slightly excess contour.

The Labial Outline should be carried into the labial embrasure until the margins are in full view. The enamel should be split away until full length rods are obtained. On account of the exposed location of these cavities the esthetic reasons demand as little cutting labially as possible. As this margin is practically removed from the stress of occlusion it is not essential that the enamel be supported by dentine in every instance. However, care should be taken that the rods are full length and that all rods are removed where there has been a backward decay as shown by a whitened powder-like condition at their dentinal ends.

Additional Extension for esthetic reasons is sometimes required in the labial embrasure. This is more often true in the mesial cavities wherein the teeth are angular in form and present surfaces that are quite flat, resulting in a very square or prominent mesio-labial angle. In such cases the outline should be carried over the angle and into the labial surface, that the metal may be brought into the light, otherwise the completed filling will have the appearance of a decay or dark spot on the tooth.

The Lingual Outline must be carried into the lingual embrasure sufficiently to be brought into full view in all cases.

In the case of teeth of rounded form this will not always include the proximal marginal ridge. In teeth of a squared form and prominent lingual ridges the marginal ridges should be included and the outline carried along the axial slope of the ridge. The fact that many cases show a lingual articulation and occlusion on the lingual marginal ridges of upper incisors, will bring demands for including within the cavity the major portion of these ridges, unless supported by a good bulk of sound dentine. The failure to recognize this fact on the part of many operators is responsible for the loss of a large per cent of this class of fillings.

Resistance Form. No special resistance form other than that just given is required in this class of cavities.

Retention Form. When this order in the preparation has been reached attention should be directed to the incisal angle, particu-

larly in the larger cavities, as cases will be met in which it will be found necessary to remove the incisal angle to secure proper "retention form." This looking to the incisal first will decide this point early in the procedure.

The Incisal Line Angle should meet the axial wall at least at a right angle. In cases where this line angle is short, as found in shallow cavities, the incisal line angle should meet the axial wall at a slightly acute angle. It is not necessary to make a convenience angle at the incisal point angle. (Fig. 34.)

The bevel angle on the gingival wall becomes the fulcrum. It is only necessary that the distance from this point to the incisal point angle be greater than that from the same point on the gin-

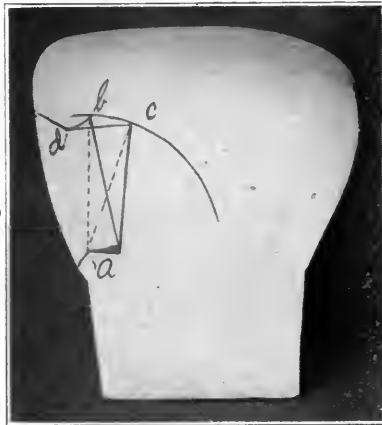


Fig. 34.—Drawing to illustrate the retention at the incisal angle of Class Three cavity. In shallow cavities with a short incisal line angle as $d-b$, the angle at b should be acute. In deeper cavities and longer incisal line angles as the one shown at $d-c$, the incisal point angle is efficient if it is a right angle and may even be obtuse. In the illustration shown the filling would pivot to exit at a . Dotted lines $a-b$ and $a-c$ are the same length hence the point angles of the two fillings would describe an arc of the same circle in tipping to exit.

gival wall to the most external portion of the incisal line angle. The more shallow the cavity in Class Three the more acute must be the incisal point angle.

Other Point Angles. The gingivo-axio-labial and the gingivo-axio-lingual point angles are now carried into the dentine at the expense of both axial and external walls, care being given not to groove the gingival wall.

Line Angles. Line angles are made with small hatchets and hoes of suitable sizes, say, one-third to one-half millimeter in width, with edges that are keen and whose corners are well defined, not having been rounded through careless sharpening or wear.

The **Axio-Labial Line Angle** is chased and sharpened for its entire length, making it particularly definite as it approaches each of the point angles.

The **Axio-Lingual Line Angle** is made definite for one millimeter in each direction from its two point angles, omitting the central por-

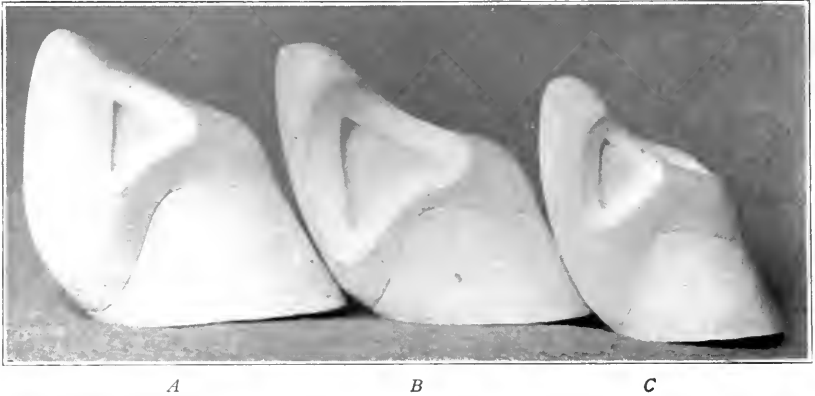


Fig. 35.—Class Three cavities prepared for cohesive gold. While the cavity in the cuspid (*A*) restores the mesial angle the shape of these cavities and the rules governing their management places them in Class Three.

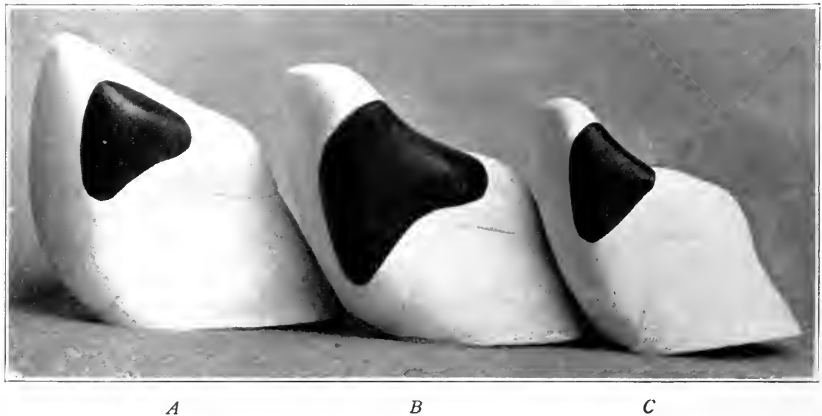

Fig. 36.—Class Three filled. Cavities shown in Fig. 35.

tion, as this precaution will give added resistance form to the lingual wall. The sharpening of these line angles is best accomplished by engaging the instrument in the dentine the desired distance from the point angle and cutting to the angle.

The **Gingivo-Axial Line Angle** should be well defined to make the

gingival wall meet the axial at a definite angle, but should in no way be a ditch or groove.

The Gingivo-Labial and Gingivo-Lingual Line Angles should be cut away from their point angles out to and end at the dento-enamel junction. As the general form of the cavity is that of a triangle these angles will always be acute.

Gingival Wall. The gingival wall should be flat in every direction.

Axial Wall. The axial wall should be left as decay has left it in the central portion and all additional cutting should tend to make it take on the form, in miniature, of the surface of the tooth in which the decay has originated. A disregard of this rule will endanger the pulp, whereas if the axial wall is left as convex as possible the pulp has all possible protection.

Labial and Lingual Walls. These walls should be, as far as possible, of the same thickness for their entire length, which will result in their inner surfaces being of the same contour as the external surface of the tooth.

Convenience Form. Two convenience points are advisable in this class of cavities, cut in each of the gingivo-axio-labial and the gingivo-axio-lingual angles. The filling should be begun in the latter angle.

Removal of Remaining Decay. At this point inspect the dento-enamel junction for softened dentine. Also the entire axial wall should be scraped with large spoons for the removal of the last of the softened dentine, the cavity disinfected, dried, phenolized and again dried. Pulp protector should be applied when indicated.

Finish of Enamel Walls. The enamel walls should be planed to full cleavage, with suitable instruments of chisel edges, not forgetting the incisal and gingival inclination of the rods of these locations. Bevel the cavo-surface angle, give the cavity its toilet and immediately place the filling.

In Non-Vital Cases. When the axial wall has been lost by reason of pulp removal the entire pulp chamber should be filled with cement of a very light yellow color or even a white cement may be used. In extremely frail teeth this may be only partially filled and the remaining portion used for retention.

CHAPTER XV.

MANAGEMENT OF PROXIMAL CAVITIES IN INCISORS INVOLVING THE ANGLE. (CLASS FOUR.)

Definition. Cavities of Class Four are those in which the incisal angle has either been lost or can not be safely retained. The decision as to its restoration is of most vital importance. To cut the angle from nearly every incisor which has a proximal decay is little short of malpractice, while at the same time to attempt to save those not wholly and adequately supported by dentine is to invite many disastrous failures.

Conditions Demanding Frequent Angle Restoration. *First.* When contact is in the incisal third. In such cases a very small decay will involve all of the dentine toward the incisal angle.

Second. Incisors which have long flat proximal surfaces. Such teeth will show a line of decay extending gingivo-incisally and may entirely weaken the incisal angle before the pulp is in danger.

Third. The pulp may be involved and its removal materially lessens the resistance of supporting dentine at the angle.

Fourth. The angle under consideration may be so located that it is frequently required to stand great stress in service. This is a point which must not be overlooked as an angle which stands well exposed must bear much greater and more often repeated force than an angle which does not occlude or can not be brought into articulation.

Difference Between Mesial and Distal Surfaces. The above four conditions will be more frequently met with in mesial surfaces, hence the mesial angles are in greater danger and more often require restoration.

Plans of Angle Restoration. There are four general plans of restoring the incisal angle which are worthy of consideration. Many plans have been advanced from time to time, but the four given below seem to have remained in favor.

Retention Form in Class Four Fillings. With each of the plans presented and generally practiced the effort is made to remove or nullify the principle of the lever.

With proximal fillings wherein the force of mastication is brought in direct contact with the filling the principles of the lever must be reckoned with. The force of mastication is the power, the filling the lever, the anchorage in the point angles the load and the point on

which the filling would most likely pivot to exit the fulcrum. By a study of the case we find we must deal with the force of levers of both the first and second class.

In Fig. 37 we have an illustration of a Class Four, plan one filling wherein the principles of a lever of the second class are fully operative. The heavy long lines *a-b* represent the full length of the lever. The short heavy lines *a-c* represent that part of the lever which is the working arm, as the load is at *c*. That we may study the amount of anchorage to be provided for at the incisal angle, (*c*), we will ignore the assistance of the two gingival point angles and for that reason they have not been shown in the drawing. We here

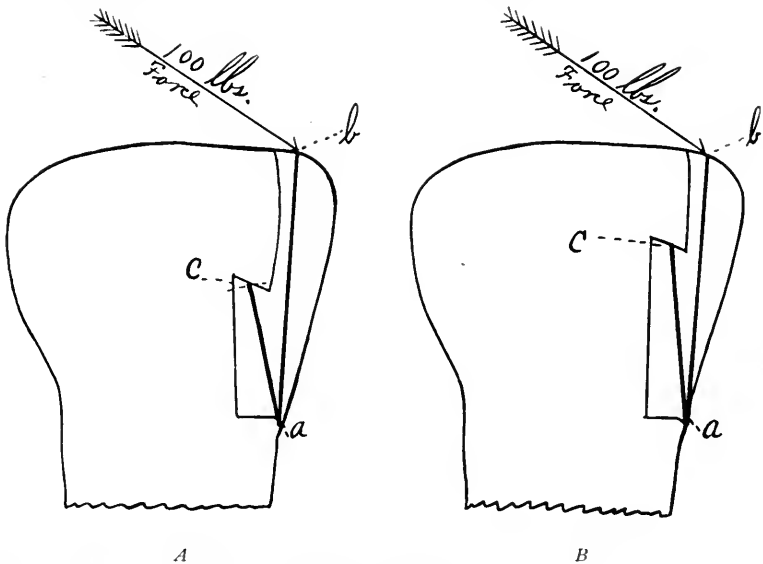


Fig. 37.—Drawings to illustrate the principle of the lever in the dislodgement of fillings of the fourth class, plan one.

have a lever of the second class with the fulcrum at *a*, the load at *c* and the force at *b*.

In order that we may not inject into the problem at this time the principle of the bent lever we will consider that by the lateral movement of the mandible the force is applied at right angles to the "lever-arm." In diagram A, Fig. 37, the working arm is one-half of the lever which is of the second class. We then have the following with *x* representing the load, or unknown quantity:

$$100 \text{ lbs.} : x :: 2 : 4 = \frac{400}{2x} = 200 \text{ lbs.} = x.$$

It would therefore follow that an incisal point angle placed mid-

way between the gingival wall and the incisal surface of the filling would be required to stand a strain just double the force at the incisal, or place of impact. In diagram B, Fig. 37, the incisal point angle is placed three-fourths of the way from the gingival to the incisal and we then have:

$$100 \text{ lbs.} : x :: 3 : 4 = \frac{400}{3x} = 133\frac{1}{3} \text{ lbs.} = x.$$

This shows a strain on the incisal point angle of one hundred and thirty-three pounds. It will therefore be seen that the incisal point

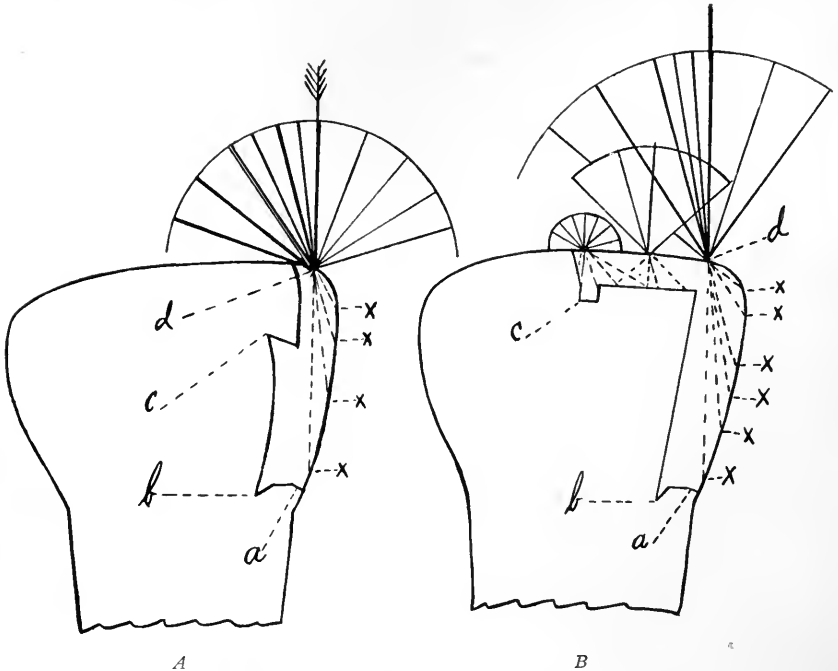


Fig. 38.—Drawings to illustrate the principle of the lever in the dislodgment of fillings of the fourth class, plans one and two.

angle should be laid as close to the incisal edge of the tooth as the strength of the dentine protecting that angle will permit as it follows that: *“The farther the incisal angle is from the force of mastication the greater will be the strain on both dentine and filling at this angle.”*

With Fig. 38 we will consider the principles in a little more complicated form. Let *a* represent the fulcrum, *b* and *c* the loads and *d* the point of the application of the force. The radii of the arcs of the circles represent a few of the directions from which force may be received by the filling. With the light lines the force would be

absorbed by the walls of the cavity. Force from the direction of the dark lines would put into operation the principles of the lever.

In diagram A, Fig 38, the filling would operate as a lever of the second class upon the load at *c*, as described in Fig. 37. With the gingival point angles at *b* the filling would operate as a lever of the first class over the same fulcrum (*a*), provided the gingival outline or fulcrum has been laid higher than the point angle and therefore nearer the point of the application of the force.

In case the gingival margin has been laid lower than the point angle or farther from the point of impact than the fulcrum we have a lever of the second class which when figured out will draw an immense load as shown in the explanation of Fig. 37.

In case the gingival point angles are cut more root-wise than the gingival margin and we have a lever of the first class we must consider the principles of the bent lever. When the direction of the force (or of the resistance) is not at right angles to the arm or the lever on which it acts, the "lever-arm" is the length of the perpendicular from the fulcrum to the line of the direction of the force (or the resistance).

We must therefore conclude: First, that gingival point angles should be placed so as to extend more root-wise than the height of the gingival line at the proximal (that part of the gingival wall which is nearest the incisal is regarded as the highest point). Second, the farther the gingival wall with all its parts is from the incisal the greater will be the length of the power arm with each individual blow. Third, the nearer the gingival wall is to the incisal the less the number of directions from which force may be received which will act upon the filling as a lever.

In order that we may eliminate the principles of the levers, the step cavity, in classes two and four, has been devised as shown in diagram B, Fig. 38. It will be seen by the radii of the three arcs drawn that the increase of the surface of the filling exposed to force does not increase the dangers of the lever as the area of the seat of the filling has also been increased which will absorb the force beneath the increased surface. Again, so long as the incisal angle in the step (at *c*) holds and the filling material remains rigid the lever principle has been eliminated as regards all other anchorage of the filling.

Direction of the Incisal Angle. Fig. 39 is a drawing to illustrate the difference in the directions the point angles take in tipping to exit with various filling. Let the perpendicular shaft represent the varying length of Class Four fillings and the horizontal bars the

varying lengths of the step in plan two of this class. The dotted lines are the radii of the various circles the arcs of which the point angles would describe in moving to exit, pivoting on the gingival margin. The length of the step portion relative to the height of the filling determines the direction the incisal point angle must take to exit. With a short proximal portion and a comparatively long step portion, the first movement of the point angle is almost perpendicular. See fillings in Fig. 39 (*a, x, h*; also *g, f, n*).

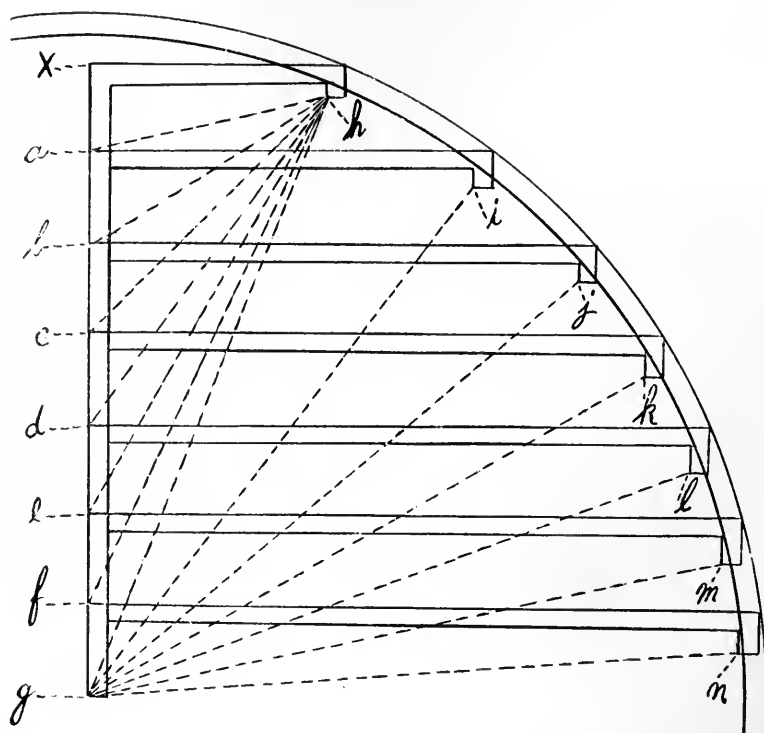


Fig. 39.—Drawing to illustrate the difference in the directions the point angle fillings take in tipping to exit with various fillings.

Note the difference in the direction the point angle would take to exit with an increased length of filling inciso-gingivally. Also see *h, x, a*, and then *h, x, b*, and on down until it is *h, x, g*. It will be seen that there is a gradation toward the horizontal movement of the incisal point angle to exit. Again note the change of direction to exit of the incisal point angles in *g, a, i*, and then *g, b, j*, then *g, c, k*, and on down to *g, f, n*. We see in this series that there is a gradation toward the perpendicular movement of the incisal point

angle to exit. In the first instance we lengthened the axial wall, using the same length of step. In the second instance we shortened the axial wall and at the same time lengthened the step and the change is more rapid. It would seem then that the direction to be given the incisal point angle is determined by the degree of the circle in which lays a line drawn from the deepest portion of the incisal point angle to the fulcrum. (See dotted lines Fig. 39.) The nearer this line in a given case approaches the perpendicular to the axial part of the filling the more essential is it that the point angle be cut in the same plane as the axial wall. Also the nearer this line approaches ninety degrees from the perpendicular the more essential is it that the incisal point angle be cut at forty-five degrees to the perpendicular of the axial wall.

By a study of Fig. 40 it will be seen that the incisal angle of

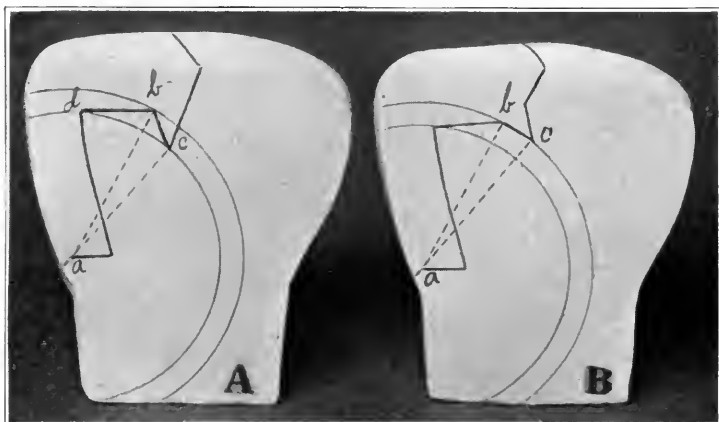


Fig. 40.—Drawings to illustrate the importance which should be given to the proper placing of the incisal point angle in fillings of Class Four, plan two, with particular reference to the plane in which wall *b-c* should be cut.

A would be effective while *B* would offer no resistance to exit with a filling pivoting at *a*. By materially shortening the axial walls of both, the point angle of *B* becomes effective and that of *A* ineffective.

As shown in the drawings in *A* the dentine included in *b*, *c*, *d* is the retention produced by having dotted line *a*, *b* longer than line *a*, *c*. In *B* these lines are the same length, hence no retention. The filling becomes a lever to lift the gingival point angles.

The Gingival Angles. In the study of the gingival angle retention, we will eliminate the incisal angle and consider that it has been improperly laid or has been weakened and the lever force has been transmitted to the gingival angles.

In Fig. 41, *a* is the fulerum and *b* the extreme point of the angle. Dotted lines *a-b* are the radii of the circles the arcs of which the point angle fillings would describe in going to exit. The two gingival point angles should be of different depths so that they will describe the arcs of different circles in being drawn to exit. It is most convenient to make the gingivo-axio-lingual the deeper.

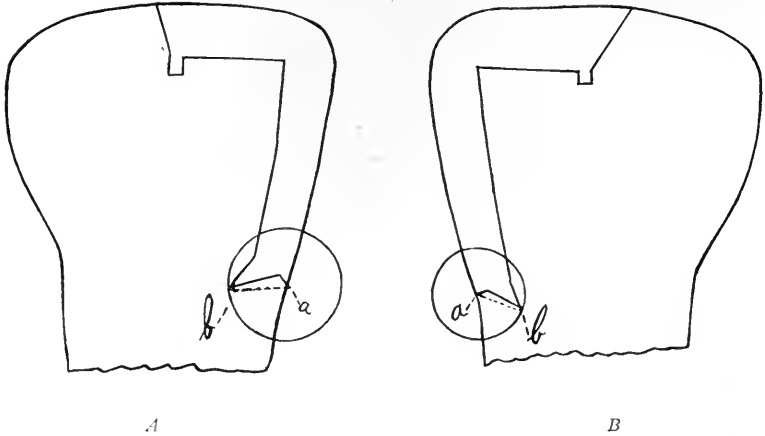


Fig. 41.—A study in the proper placing and depth of the gingival angles.

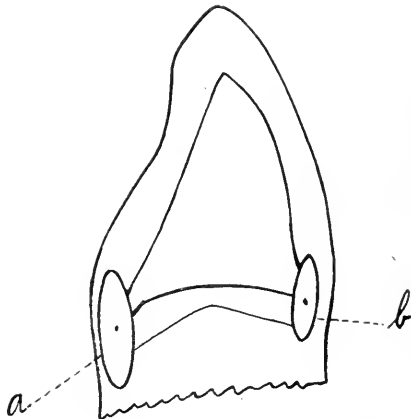


Fig. 42.—A study of the planes in which the gingival angles should be laid.

It is also essential that the two gingival point angles be so laid that the circles, the arcs of which the point angle fillings describe in passing to exit, stand in different planes as illustrated in Fig. 42. Failure to observe the last two principles given removes retention form as regards the gingival angles.

First Plan of Angle Restoration. (Class Four.)

The first plan of anchorage is made by undercutting the incisal edge. This plan is indicated in teeth of rather thick incisal edge that are rather short and stocky as they have a greater body of dentine near the angles upon which to depend.

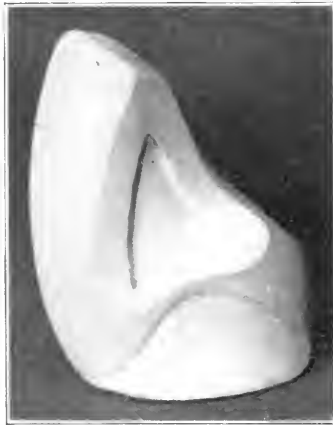
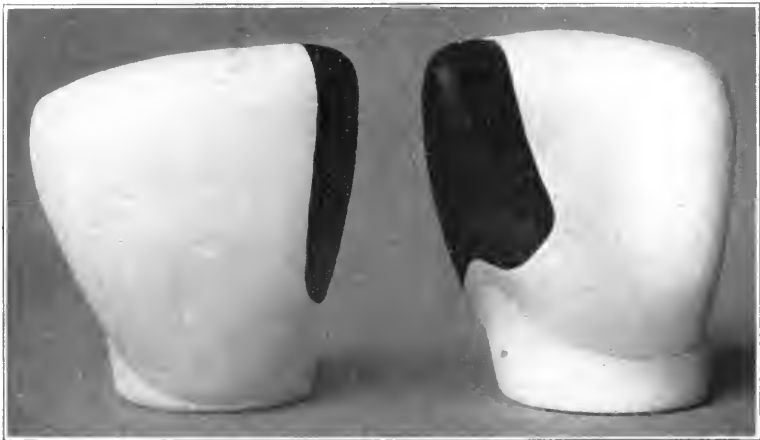
Fig. 43.—Cavity of Class Four, plan one, for cohesive gold.



A *B*
 Fig. 44.—Class Four, plan one, cavity filled. Labial and lingual views.
 Cavity shown in Fig. 43.

As a rule the horns of the pulp in such teeth are well retracted, at least in adult mouths, and there is less danger of pulp exposure as compared with the teeth of thin edges and angular outline. If this plan has been decided upon, the cavity should be cut well to the

gingival, particularly at the gingival angles, in some cases to the extent that the gingival wall is made convex to the incisal.

The Gingival Point Angles should be deep and well defined at the expense of both gingival and axial walls. This is particularly true of the gingivo-lingual angles, to protect against the torsion strain.

To Assist the Incisal Angle. To resist the tipping strain both the labial and lingual walls should be slightly grooved along the axio-labial and axio-lingual line angles much in the same way as with large Class Three cavities.

The Labial Outline should so proceed that the completed filling will be of about equal width for its entire length except that as it approaches the incisal edge it should be slightly curved to the axial.

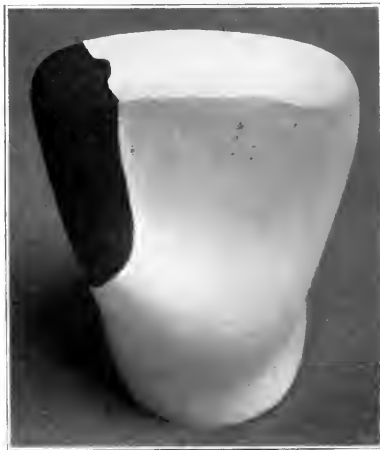

Fig. 45.—Shows incisal outline in Class Four, plan one, fillings with direct occlusion.

A Rule for Labial Outlines. All cavity outlines in incisal angle restorations should curve to the axial as they approach the incisal edge. The nearer this outline approaches the central axial line of the tooth the greater should be the curve. When the central axial line is reached by a cavity outline, the same should then be extended to involve the opposite angle. There are exceptions to the above rule but maximum resistance to stress is only thereby obtained.

The Necessity for Curving to the Axial. When approaching the incisal edge curve to the axial that the last rods at the cavo-surface angle may be adequately supported. A large per cent of fillings where this precaution has been neglected fail, showing a primary fault due to the breaking away of the enamel at this point.

The Incisal Outline as it crosses the incisal edge of thick teeth should have in its center a curve toward the axial caused by a slight groove in the center of the dentine. This groove which ends at this point in the cavity outline should originate at the external end of the incisal line angle. If there is sufficient dentine, and there generally will be in the class of cases calling for this plan of restoration, this groove is of best service if it be a flattened groove and made with a small hoe or hatchet. (Fig. 45.)

The Lingual Outline should be the same as for large Class Three except in the incisal third when it should curve to the axial even more rapidly than the labial outline and for a longer distance, resulting in cutting away more enamel from the lingual than is removed by the labial outline. This is made necessary from the fact that all stress is from the lingual.

With Lower Incisors the reverse is true and it is necessary to remove slightly more of the labial enamel in angle restoration, a fact which materially mars these teeth from an esthetic point of view. Fortunately we have comparatively few angles to restore on lower incisors, but when they are presented the fact must be borne in mind that they receive the major portion of stress from the incisio-labial direction.

Second Plan of Angle Restoration. (Class Four.)

The second plan of restoration is indicated in teeth that are of medium thickness, particularly if they are of angular build or have a direct contact on the incisal edge either in occlusion or articulation, and consists in the addition to plan one of what is termed the incisal step. The cavity proper is prepared the same as has been outlined in plan one up to the forming of the step.

The Incisal Edge is cut away with a narrow-edged carborundum stone, the cutting being extended toward the opposite angle a distance equal to the width of the cavity proper. The incisal outline should avoid both the centers of primary calcification and the point of coalescence, two weak places in enamel construction. The cutting should be more at the expense of the lingual side of the tooth by one-half to one millimeter.

The Depth of This Step, inciso-gingivally, will depend upon the thickness of the cutting edge, and the probable stress it will receive. The thinner the edge and the greater the probable stress, the deeper must be the step. The majority of cases will show not to exceed one millimeter of gold on the labial in the step portion.

Technic of Cutting. A small round bur is then used to cut a

groove in this newly formed pulpal wall, near the dento-enamel junction next to the lingual plate of enamel. The lingual enamel is then removed with a chisel thus carrying that portion of the pulpal wall to a lower level. This process is continued until it is at least

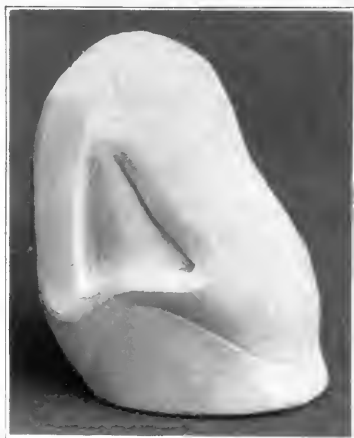

Fig. 46.—Cavity of Class Four, plan two, for cohesive gold.



A

B

Fig. 47.—Class Four, plan two, filled. Labial and lingual views. A very popular method. Cavity shown in Fig. 46.

one-half millimeter to one millimeter lower than the labial portion of the pulpal wall. This leaves the major portion of the dentine supporting the labial plate of enamel.

The Point Angle in the Step Portion should be deepened and made

acute largely at the expense of the pulpal wall. This will place it in just the right position to resist stress from the probable source and prevent tipping. (See Fig. 37.)

This Second Plan is Particularly Indicated in cases of much wear

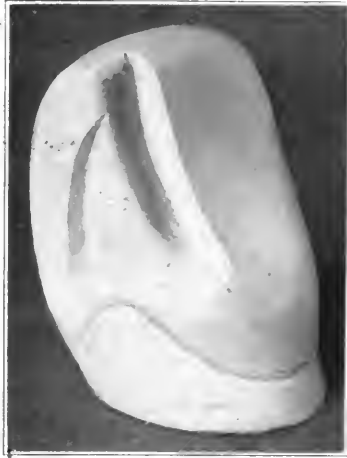

Fig. 48.—Cavity of Class Four, plan three, for cohesive gold.

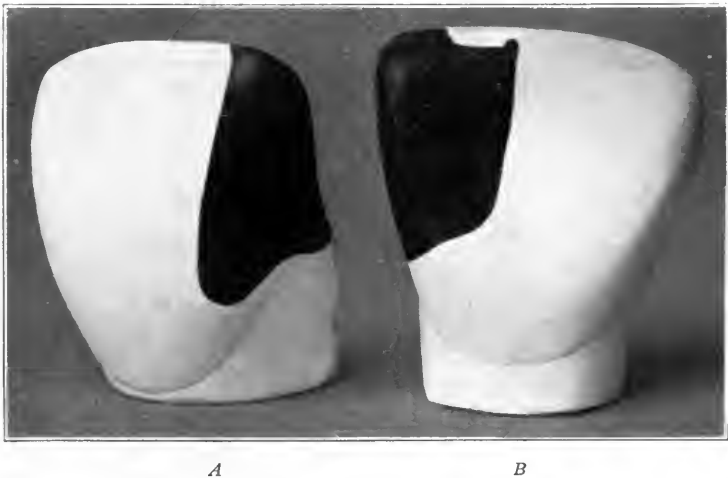


Fig. 49.—Class Four, plan three, filled. Labial and lingual views. Cavity shown in Fig. 48.

on the incisal, due to what is called "end-to-end" bite. However, in such cases all of the exposed dentine on the incisal edge should be included in the step and it is not necessary to remove much of either of the labial or lingual plates of enamel. In such cases the

step portion should be retentive throughout as it is liable to be worn away by subsequent wear, growing thinner from year to year, hence the necessity of retentive form from cavo-surface angle to the base line angles.

Third Plan of Angle Restoration. (Class Four.)

This plan is the addition to plan one of the lingual step. It is particularly indicated in cases of long incisors which are quite thin labio-lingually and subjected to a long sweep of the lower incisors in the movements of articulation, or what is spoken of as the "scissors bite."

Also Indicated in cases where the axial wall extends out to the enamel edge on the lingual thus removing the lingual wall.

The Labial Outline is the same as with the first plan of restoration. The step is formed on the lingual by cutting away the enamel from the lingual surface of the tooth toward the central axial line for a distance of from one to two millimeters at the incisal edge.

As the gingival is approached the cutting is narrowed to a point where the marginal ridge may be crossed at right angles to meet the gingival portion of the outline. This will form a V-shaped axial wall of dentine facing the lingual. There should be cut a flat-floored groove in this dentine parallel with the remaining enamel wall ending in the gingivo-axio-lingual angle which should be an acute convenience angle. The plan gives great resistance to stress from lingual pressure.

Fourth Plan of Angle Restoration. (Class Four.)

This plan consists of resorting to all of the features of resistance and retention embodied in plans two and three by combining both the lingual and incisal steps. Each of these has been fully described and the method of cutting both steps to the same should not prove hard to accomplish.

By this plan the maximum resistance and retention forms are secured with the minimum loss of dentine. It must be remembered that resistance to stress is good in proportion to the amount of securing dentine retained, hence it should be sparingly cut away. The removal of enamel to lay bare dentine wherein to lay anchorage is only harmful from the esthetic standpoint and is of little loss when taken away from a surface not in view, as is the case when we cut away a portion of the lingual plate.

Cavities in the Distal of Superior Cuspids. On account of the peculiar articulation of the lingual surface of superior cuspids this

cavity has been left for separate consideration. The plan given is a modification of plan three, using a lingual step not unlike the occlusal step in a class two cavity.

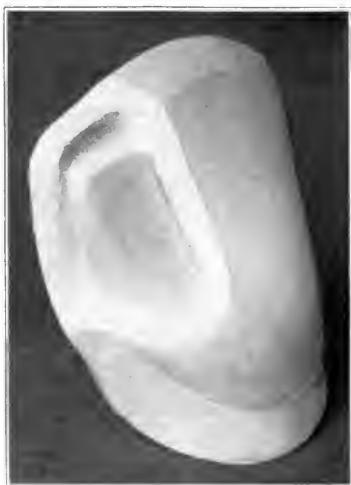

Fig. 50.—Cavity of Class Four, plan four, for cohesive gold showing maximum anchorage with a minimum loss of dentine. The use of this plan is advised when the lingual stress is great.

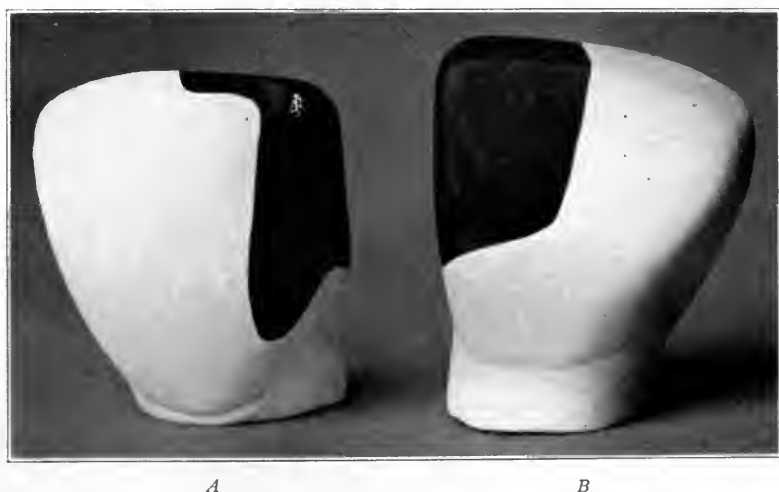

Fig. 51.—Class Four, plan four, filled. Labial and lingual views. Cavity shown in Fig. 50.

Access is an easy matter as the decay is in the most prominent part of the distal surface and a little work with the chisel gives access to the cavity.

Outline Form. In outlining the cavity proper most of that which has been said about plan one should be followed here.

As to the lingual outline and that of the step particular attention must be paid to so placing the margins as to remove them as much as possible from the stress of articulation.

The Step. The lingual step is added to this cavity as it materially assists in retention, resistance and convenience forms.

In the laying of the walls of the step portion the particulars are carried out much as though the lingual surface of the cuspid were an occlusal surface, as next to an occlusal surface it receives the greatest stress in articulation.

Axial Walls. It will be seen that this cavity has two axial walls.

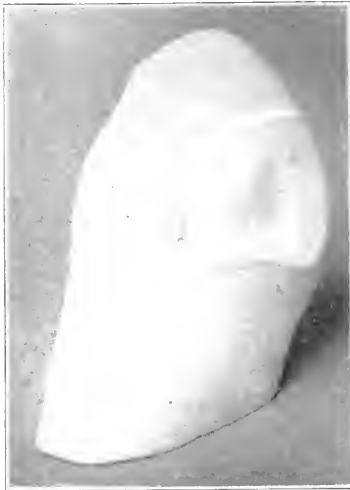

Fig. 52.

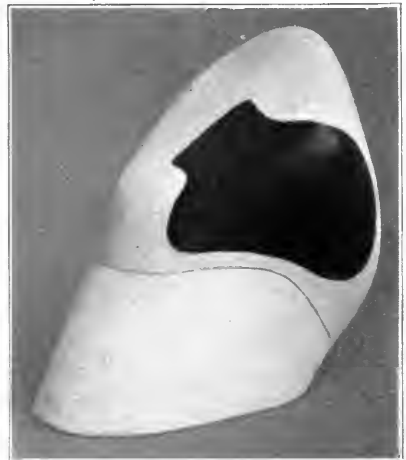

Fig. 53.

Fig. 52.—Cavity of Class Four, modified plan three, for cohesive gold in the distal of the superior cuspid. This plan is sometimes used to advantage in the incisors when the tooth is short and stocky. In such cases the lingual step is made to include the lingual pit.

Fig. 53.—Class Four, modified plan three, filled. Cavity shown in Fig. 52.

The one in cavity proper is the axial, while that in the step is termed the lingual axial wall.

The Lingual Axial Wall should be placed on a plane parallel with the lingual surface of the tooth. Its surrounding line angles should be laid just below the dento-enamel junction.

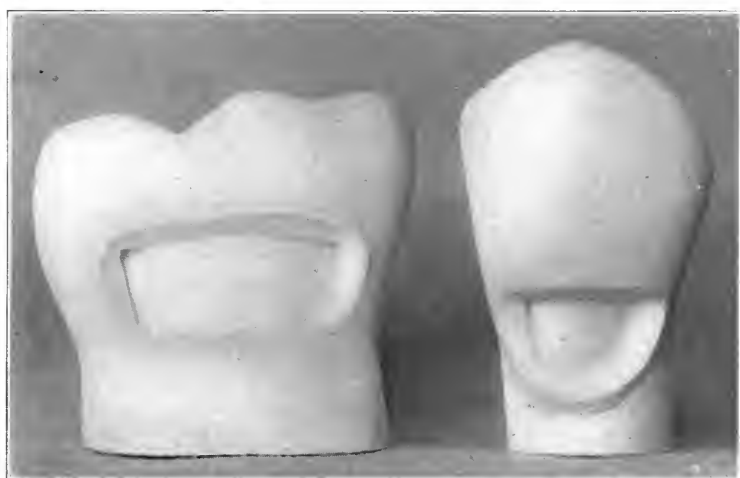Convenience Form in this cavity is pretty well secured by the addition of this lingual step, as the filling is then easily built in from the lingual direction. Both gingival point angles in the cavity proper should be made convenience angles as well as the axio-lingivo-mesial point angle in the step portion.

CHAPTER XVI.

MANAGEMENT OF CAVITIES IN THE GINGIVAL THIRD. (CLASS FIVE.)

Gingival Third Cavities Differ from all other cavities in the teeth in that they originate on perfectly smooth surfaces generally without flaw in enamel formation and without covering of any kind, or to state it more concisely, there seems to be no predisposing cause.

Their Prevention is an easy matter, as the accumulation of sordes which is the sole exciting cause, is unprotected and of easy access to the brush so that patients with this class of decay are paying the



A *B*
Fig. 54.—Cavities Class Five for cohesive gold or amalgam.

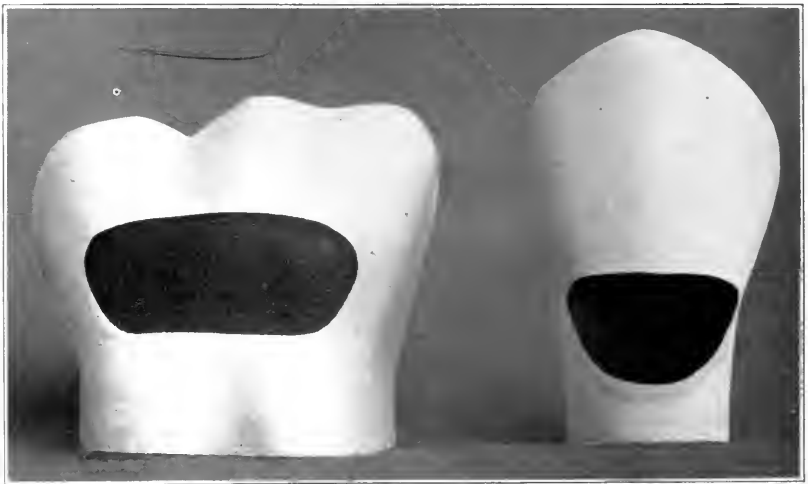
penalty for the careless neglect of the simplest forms of oral cleanliness. With these facts before us it becomes the duty of every practitioner to fully advise the patients of the neglect of their mouths in this particular locality, in an effort to check farther destruction.

The Tendency to Spread in the Enamel is a characteristic of this class of cavities. They usually originate near the center of the buccal surface near the free margin of the gum and seldom stop until they have extended both mesially and distally nearly to the angles. The fact that the encroachment seldom reaches the angle in the external enamel decay, is a point to be considered in the

study of extension for prevention in this class of cavities. It appears that when the outline is carried quite to the angle that secondary caries rarely occurs.

The Gingival Outline should be laid below the gum line for its entire length until the angles are reached when it should emerge from beneath the gum at a right angle to the free margin of the gum.

The Occlusal or Incisal Outline should be carried to a region of sound enamel. Where this extension does not carry this outline farther than one millimeter from the free margin of the gum farther extension should be made. With teeth surrounded by a heavy gum, particularly if there seems to be a condition of hypertrophy



A *B*
Fig. 55.—Class Five filled. Cavities shown in Fig. 54.

present, the occlusal outline should be laid at least two millimeters from the border of the gum.

Retention Form. Retention is secured by squaring out the four point angles. The axial wall should generally be left as decay has left it in the central portion. Any subsequent cutting should be of such a nature as would tend to make it convex to the external, or so to speak, the miniature of the tooth's surface in which it is being cut. An effort to cut a flat axial wall mesio-distally will often endanger the pulp and is unnecessary as these cavities need no resistance form.

In Large Buccal Decay often the gum has so grown into and

filled the cavity that the adjustment of the clamp and rubber dam is difficult or impossible. In such cases if the pulp is not involved much assistance is secured by packing the cavity full of gutta-percha base plate allowing it to crowd well down upon the gum. In a few days the gum will have receded or have been absorbed sufficiently to permit convenient access.

If the Pulp is Involved and requires extirpation make the application of the devitalizing agent, covering this with amalgam which should fill the cavity. Care should be taken that the gingival wall has been planed to a solid condition. During this operation dryness may be obtained by the assistance of cotton rolls.

When case returns the clamp will ride on the amalgam at the gingival and access to the pulp may be had through the upper portion of the amalgam. After the pulp canals have been filled the dam may be removed, the remainder of the amalgam excavated and cavity preparations proceeded with, as well as the placing of an amalgam filling, under dry conditions by the use of cotton rolls.

If Gold is to Be Used the gold inlay is clearly indicated as producing the best results with the least tax upon patient and operator.

With Labial Cavities in the gingival third the Hatch clamp will expose nearly every case presented and render access not difficult for the introduction of a cohesive gold filling. In cases of extensive gum recession on labial exposures the porcelain inlay is clearly indicated and is considered in the chapters on that subject.

CHAPTER XVII.

MANAGEMENT OF ABRADED SURFACES. OCCLUSAL AND INCISAL. (CLASS SIX.)

Definition. Class six includes the group of cavities necessary for the repair of injuries to the teeth through the loss of a portion of their articulating surfaces as the result of wear. The condition is abnormal and the extent of the destruction of tooth substance is by no means in proportion to the amount of use to which the teeth have been subjected. However it will be noticed in mouths with teeth of short cusps, and particularly if the incisors occlude directly upon the incisal edge, that there is an abnormal amount of lateral motion in the act of articulation, and in such mouths we find the maximum loss of tooth substance at any given age.

Cause Not Wholly Clear. Yet, that friction is the sole cause for this lesion, can not be demonstrated, as the surfaces thus affected do not show the exact impression of the opposing teeth, neither is this condition always delayed till advanced years. Cases will be occasionally met with in the mouths of people in middle life showing the advanced stages of this trouble.

At the same time locations will be found on the occlusal surfaces of teeth which at one time must have been in articulation but are so far lost and seemingly worn away that they could not be brought into occlusion.

It would seem from a study of a great number of cases that there must be some causes predisposing and exciting not yet understood. It is not improbable that the cause is a fault in tooth structure, not so much in the constituents of the tooth as in the lack of strength in their combination. This conclusion would seem plausible from the fact that teeth similarly situated and of the same chemical analysis are affected to a different degree by even slight friction. The bond of union does not seem to be so strong.

The Object in Filling or in making a cavity to fill is to permanently check the loss of tooth substance by entirely covering the affected surface with a substance that will resist the full force of mastication.

Occlusal Surfaces. In occlusal surfaces, particularly molars showing the first stages of general erosion, early interference is advised. As soon as a cusp is lost it should be restored and if pos-

sible built high with gold, preferably an alloy of gold, either platinized foil or a cast inlay of gold alloy.

This Early Restoration of cusps to their full height will tend to restrict the lateral motion of the mandible in mastication, which seems to be a factor in this dissolution.

Cavity Preparation. These cavities should be prepared as class one and should be retentive throughout.

If the Major Portion of the Occlusal Surface of a single molar is affected the whole occlusal surface should be lowered about one millimeter and the same restored with a cast inlay, sometimes termed an onlay. This is advised from the fact that the occlusal side of the filling may better fit the surface of the occluding teeth. This may and probably will necessitate the devitalization of this individual tooth when the pulp chamber should be utilized for anchorage.

If Contact Points have been reached by this cutting, a mesio-occlusio-distal cavity is imperative.

When Wear is General opening the bite to the extent of about one millimeter is preferable to cutting away any more tooth substance than is necessary for firm foundation and a correct outline.

With Incisal Abrasion, if the wear is not excessive, the building on of the "shoe," or covering the entire incisal end of the tooth with platinized gold is the best practice. The gold inlay, which is treated in the chapters on inlays, is also of service.

When there is excessive incisal wear opening the bite to practically normal is indicated, using gold for the posterior teeth and the porcelain crown for the anterior.

The Entire Enamel Edge on the occlusal and incisal surfaces must be covered with a protecting layer of metal as with these teeth the bond of union seems to be very weak, particularly at the dento-enamel junction, and they will chip away if not wholly protected from the force of mastication.

CHAPTER XVIII.

CAVITY PREPARATION FOR GOLD INLAYS.

Definition. An inlay is a body placed within a previously prepared excavation. As applied to the filling of teeth it refers to the process whereby the filling is inserted into the cavity of a tooth in one piece and retained there, by the assistance of cement.

The Materials in most common use are porcelain, pure gold, alloys of gold, as well as alloys of base metals.

The Indications for a Gold Inlay. *First.* In large contour restorations, as there is a material saving of both time and energy on the part of both patient and operator. Such cases, particularly with posterior teeth are frequently crowned with the shell gold crown with its almost universally irritating band, when the inlay could be of greater service.

Second. When it is difficult to maintain dry conditions for a long period of time about a cavity, as with large gingival cavities in molars and bicuspsids.

Third. When there are extensive occluding surfaces to be restored. It is much easier to cast a correct contour than to build up with the plugger point which is largely guesswork when the rubber dam is in position.

Fourth. When it is desired to put in a number of fillings in a given short time. In such cases the operator can make the wax models, and engage the help of the laboratory in completing the fillings while he is still busy with other fillings at the chair.

Fifth. When the necessary force to properly condense a cohesive gold filling is not permissible, as with loosened teeth, or invalid patients.

Gold Inlays Are Not Indicated in small cavities, or shallow cavities, unless the outline is extensive.

The Cavity Preparation for a gold inlay does not materially differ from that which has already been advised in the preceding chapters. It is possible to construct an inlay without change for nearly every cavity which has been correctly prepared to receive a cohesive gold filling. However if the order of procedure is slightly rearranged the operation is simplified.

This Change in the Order would be to put retention form last, attending to that part of the cavity preparation after the model has been made and just before setting the inlay.

In cases where this has not been done, or the cavity is naturally retentive, the retention should be temporarily covered, as will later be described, while making the model.

Change of Position of Retention Angles. It is quite ideal to cut just as heavy retention angles in the different classes of cavities for gold inlays, as for cohesive gold, only they should be laid in a different position and cut at the expense of the base walls rather than the surrounding walls, in order to give the cavity draw. This feature of the cavity preparation will be described as we consider the preparation of cavities by classes farther on in this chapter.

The Order of Procedure for Inlays would then be as follows:

1. Gain access.
2. Outline form.
3. Resistance form.
4. Convenience form.
5. Removal of remaining decay.
6. Finishing enamel walls.
7. Toilet of the cavity.
8. Retention form, which is given as the fourth order in other forms of fillings.

Gaining Access for inlay filling is the same as that with other fillings as far as surgical procedure is concerned. No more tooth substance should be cut away on this account.

When using preliminary separation for access, there should be in most of Classes Two or Three cavities, more room secured, as this will materially assist in getting a correct wax pattern as well as aid in the process of placing the inlay.

Resistance Form for Inlays should receive the same careful consideration as given for other fillings. Weakened enamel walls should be protected not only from the subsequent force received in stress but from the stress of setting the inlay. Flat seats for all inlays are imperative. The usual steps in Classes Two and Four are called for as an important factor in retention to resist the tipping strain.

Convenience Form for Inlays should not be practiced to excess. No convenience points are required. The major portion of convenience form should be gained through separation, preferably slow separation.

Removal of Remaining Decay. When it has been fully determined that the pulp is not to be removed, some decay may be left on the axial wall, or in the region of the bucco-axial or the linguo-

axial line angles, until the inlay has been cast and fitted. It should then be removed and the dentine over-lying the pulp, if hypersensitive to thermal changes, given a coat of cavity varnish. Allowing this softened dentine to remain during the interim between the making of the pattern and the setting of the inlay, will protect the pulp against irritation and save devitalization before setting the inlay.

The Finishing of the Enamel Walls will necessarily come in at this point as all cutting of the external outline of the cavity must be completed before proceeding to make the pattern. The only change advisable is that the cavo-surface angle should be more obtuse, and the bevel angle should not be as deeply buried, which results in a thinner metal edge.

This will assist in burnishing the margins to a closer adaptation in the final finish.

More Beveling at the Cavo-surface Angle should be resorted to for two reasons. First, the gold inlay should have a margin of rather an acute angle in order that the material may be burnished more closely to the margin. Second, during the process of setting the inlay and burnishing the margins, the cavo-surface angle stands in great danger of being fractured.

The Toilet of the Cavity for Gold Inlays. Herein lies the greatest weakness in inlay methods. No cavity margin is surgically clean after it has been moistened or been in contact with the inlay wax pattern.

After the pattern has been formed and removed our methods will not permit of again planing the cavity surfaces and particularly the margins, which is the only way to render them entirely clean.

Hence we are forced to wash the cavity walls just before setting the inlay with solvents of the substances which have contaminated them. Without going into detail, it is advised that the cavity be thoroughly scrubbed with chloroform, then absolute alcohol as a second cavity toilet, and immediately the cavity be flowed with the cement, introducing the inlay under dry conditions.

Line of Approach. In inlay work the cavities should be approached from the direction in which they are to receive stress during service.

In withdrawing the wax pattern and when the inlay is placed, each should travel parallel with a line drawn from the seat of the cavity to the source of the force of mastication. This line of approach is good practice with any filling, but is more essential with

the gold inlay than the cohesive gold filling, for we do not have the assistance of the elasticity of the dentine in retention made possible by the use of the wedging principle in the manipulation of cohesive gold.

Preparation of Cavities of Class One.

Of the cavities of this class calling for gold inlays only the large occlusal surface cavities in molars are of importance. Small pit and fissure cavities are more quickly and easily filled by other methods.

Outline Form. In large occlusal cavities the outline should be

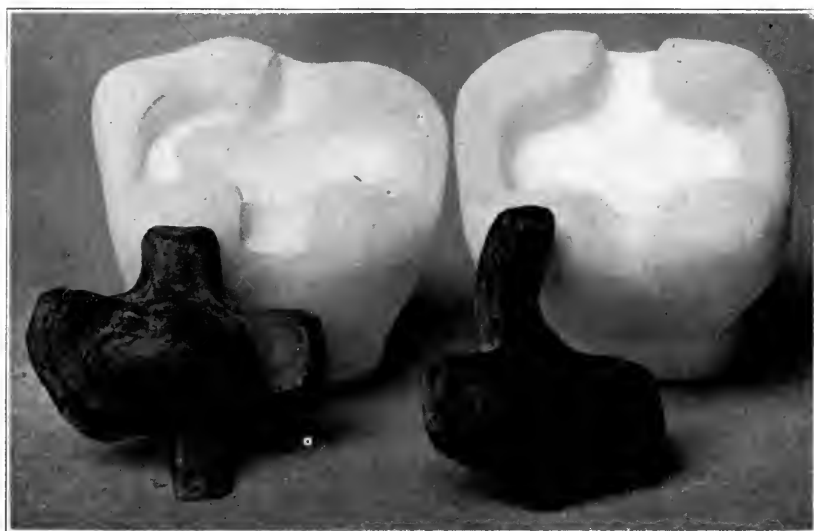

Fig. 56.—Cavities of Class One for gold inlays. Cavity side of inlays shown.

so carried as to avoid eminences at the crest of marginal ridge. When this is reached on the buccal or lingual the outline should include the marginal ridge and at least one millimeter of the axial wall be involved. All deep grooves should be included. The curves should be as generous as possible.

Resistance Form. The same rules apply as to other fillings. When much of the supporting dentine has been removed through decay or cavity preparation from either the buccal or lingual walls, that portion within the cavity should be covered with a thin layer of black wax, which prevents the wax pattern from coming in con-

tact with these walls. The cast inlay will then not touch these walls during the process of introduction, which will often save a fracture of these walls, due to stress from within when driving the inlay home to a seat.

The Major Portion of Retention Form comes in for consideration after the inlay has been cast and fitted and just before cementing to place. However, a flat seat and nearly parallel walls

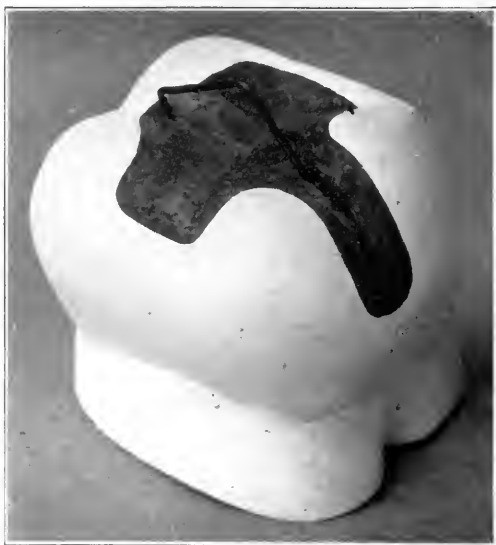

Fig. 57.—Class One inlay in position showing gold wire cast in the filling, which was put into the wax pattern to support the long buccal arm. Cavity shown at (B) Fig. 56.

to this seat with fairly definite angles, is necessary to guard against the tipping strain and produce proper retention form.

Preparation of Cavities of Class Two.

Large proximal cavities in molars and bicuspid are successfully handled with this method of filling.

Access. Preliminary separation is of the greatest service here and should be general practice as much cutting for convenience form is avoided, and better contact secured.

Complete Preliminary Separation very materially facilitates the removal of the wax pattern as the operator does not have to be as careful about having his wax pattern tight against the surface of the adjacent tooth. In addition to the preliminary separation before making the pattern, it is to the advantage of the operator

to pack the case for additional separation during the interim between making the pattern and setting the inlay.

Outline Form. The outline for inlay filling is much the same as for other methods. Care should be taken that the buccal and lingual walls are parallel, particularly the enamel portion of these walls, as the wax pattern must move directly to the occlusal surface in exit. It is equally essential in inlays that angles and sharp turns in outline be avoided, particularly as they will not take in the wax pattern and any defect in the casting exaggerates the misfit.

Resistance Form. Flat gingival and pulpal walls are demanded in class two. Weakened buccal and lingual cusps should be removed and replaced with the filling material.




Fig. 58.—Cavities of Class Two for gold inlays. Cavity side of inlays shown. Black wax has been used in the molar to temporarily remove the retention produced by decay.

Retention Form is best secured for vital cases by making four convenience angles in each case similar in size to those for cohesive gold. However, these convenience angles should be laid down in the gingival and pulpal walls and cut entirely at the expense of these walls rather than at the expense of the tooth substance in the region of the ascending line angles. To describe the process more accurately take a round bur, about number one-half or number two, sink it into the gingivo-axio-buccal and gingivo-axio-lingual point angles about the depth of the bur. To this point the procedure is the same as though we were going to make a convenience angle for cohesive gold. Instead of sinking the bur laterally into the ascending line angle and drawing it occlusally, as

with cohesive gold, we draw it toward the mesio-distal plane along the gingivo-axial line angle, allowing it to fade out, after going once or twice the width of the bur, taking the tooth substance from the gingival wall. Treat both lower point angles in this manner. In the step portion of the cavity follow the same procedure in the two point angles, cutting all tooth substances at the expense of the pulpal wall. This results in giving the cavity draw to the occlusal and giving your inlay four lugs, which key the filling to a seating, particularly in the region of the gingivo-buccal and gingivo-lingual point angles. It also results in placing your retention form high in vital cases and near the force of mastication, and in a part of a vital tooth which is well suited to stand the tipping strain. (Fig. 58.)

In Non-Vital Cases the retention form should be placed low in the tooth. In fact the major portion of it should be below the gingival wall, and this is more frequently secured by the use of the pin inlay. When the pin is not used, the pulp chamber is so shaped that the wax pattern will show a lug, which can be used for the major portion of the retention.

Finishing of Enamel Walls. This part of the cavity preparation should be attended to with all of the care and detail that is required when making a cohesive gold filling. In addition thereto, after the planing has been done with a chisel, particularly on the buccal and lingual outline, these margins should be polished with a very fine grit disk. This facilitates the travel of the wax on these two surfaces when going to exit. A chisel finish on these surfaces results in a pattern that under the microscope shows little fine projections, which have gone into the roughened surface. In drawing the pattern these little projections have been bent and point gingivally. This results in an imperfect casting along these surfaces and interferes with the fit. Whereas if the surfaces have been polished, a polished wax pattern results and the completed inlay more nearly fits the margins.

When the cavity on account of decay is naturally retentive or has undercut these are temporarily filled and overcome by covering the retentive portion of the cavity with some substance, as temporary stopping or wax of a different color than that used in making the pattern.

Preparation of Cavities of Class Three.

The gold inlay is seldom indicated, in cavities of Class Three.

An exception may be made in those which are large and have through decay lost their entire lingual wall.

Access. It is of a necessity from the lingual as Class Three cavities receive their stress from that direction.

The Outline is the same as though a cohesive filling were to be made. Care should be taken that the labial level is laid on the same plane as the travel of the wax pattern to exit, else this portion of the model will be distorted in removal.

The Gingival Wall Should Meet the axial wall at an acute an-



Fig. 59.—Cavity of Class Three for gold inlay, lingual approach. Cavity side of inlay shown.

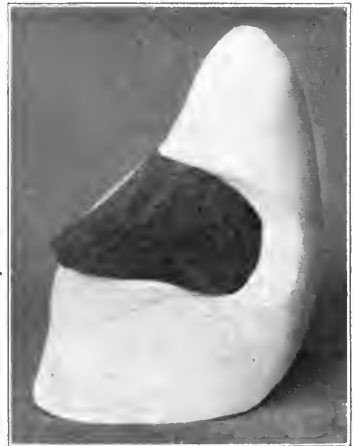

Fig. 60.—Inlay shown in Fig. 59 partly in place.

gle and the cavity should have a line angle which might be termed axio-incisal. The labio-axial line angle should be slightly shorter than the outline of the cavity where the axial wall meets the lingual surface. This will result in allowing the pattern exit to the lingual. As the labial wall, which is the seat of the cavity, is frail, care should be taken that it is well supported by sound dentine, else the seating of the inlay will cause fracture of this wall.

Preparation of Cavities of Class Four.

The use of the inlay should be largely restricted to non-vital cases and a pin in the pulp canal used for the major portion of retention.

If the Inlay is used in Class Four plans one and three, the ease

should always be devitalized. In vital cases the inlay may be used to advantage in plans two and four.

Resistance Form. In this part of cavity procedure the same care should be exercised as when using the cohesive gold filling.



Fig. 61.—Cavity of Class Four, plan one, for gold inlay. Cavity side of inlay shown.



Fig. 62.—Class Four, plan one, inlay in position. Cavity shown in Fig. 61.

This is particularly true at the incisal edge, where the beveling to the axial should be quite generous to protect against breaking down of this margin due to the fact that stress comes at right angles to the long axis of the enamel rods.

Retention Form. This step in cavity procedure will vary according to which plan of Class Four is used. In plan one, which as before stated should be used only in non-vital cases, a pin should be placed in the pulp canal and depended upon almost en-



Fig. 63.—Cavity of Class Four, plan two, for gold inlay. Cavity side of inlay shown. Black wax has been used to temporarily remove undercuts caused by decay.

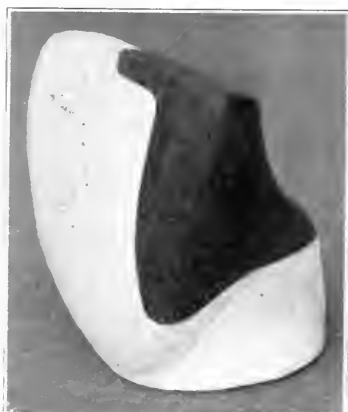

Fig. 64.—Class Four, plan two, gold inlay in position. Cavity shown in Fig. 63.

tirely for the retention. In plan two, largely used in vital cases, a short, 20-gauge pin of iridio-platinum or tungsten should be placed in the step portion of the cavity lying parallel to the long axis of the tooth. This small pin had best be from one to three

millimeters long, owing to the possibilities of the case. The gingival retention may be accomplished either by using a similar pin to that used in the incisal, placing the hole for same in about the center of the gingival wall, or the plan of retention used in the gingival wall Class Two may be used. This consists in cut-



Fig. 65.—Cavity of Class Four, plan three, for gold inlay. Cavity side of inlay shown.



Fig. 66.—Class Four, plan three, inlay in position. Cavity shown in Fig. 65.

ting the two convenience angles in the gingival wall. In plan three, non-vital, the pin in the root canal should be used. In plan four same retention used as in plan two as the case is nearly always vital.

The Enamel Walls should be well beveled, which will in no

way hinder the removal of the model. Model should make exit to the incisal with a slight lingual travel.

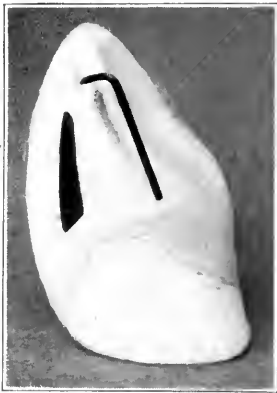

Fig. 67.



Fig. 68.

Fig. 67.—Cavity of Class Four, plan four, for gold inlay. Black wax has been spread on the labial wall before making the pattern to prevent the gold from touching this wall when setting the inlay for two reasons. First: It removes liability of fracture of this wall when setting the inlay. Second: This wax is replaced with cement and the color of the tooth is preserved. The wire loop secures the alignment of the two posts and facilitates handling the pattern. When the wire is not entirely buried, platitized gold should be used. When it is entirely buried tungsten may be used.

Fig. 68.—Class Four, plan four, showing cavity side of pattern with pins.

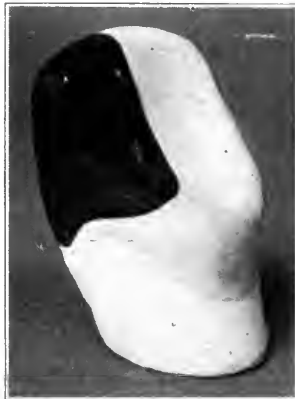

Fig. 69.—Class Four, plan four, inlay in position before removing wire loop. Cavity and pattern shown in Figs. 67 and 68.

Preparation of Cavities of Class Five.

Of this class the large buccal cavities call for gold inlays, in which they are the ideal filling, and should largely replace amalgam so commonly used.

The Occlusal Wall. The axio-occlusal angle should be slightly obtuse, while the axio-mesial and distal angles may be nearly a right angle. This will permit the model to tip to the buccal in exit, though the gingivo-axial angle be acute.

Preparation of Cavities of Class Six.

The restoration of abraded surfaces with the gold inlay is good practice, inasmuch as it is possible to effectually protect these

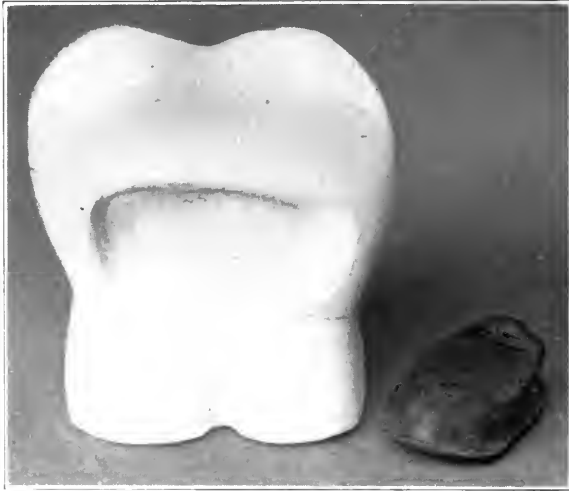


Fig. 70.—Class Five cavity and inlay.

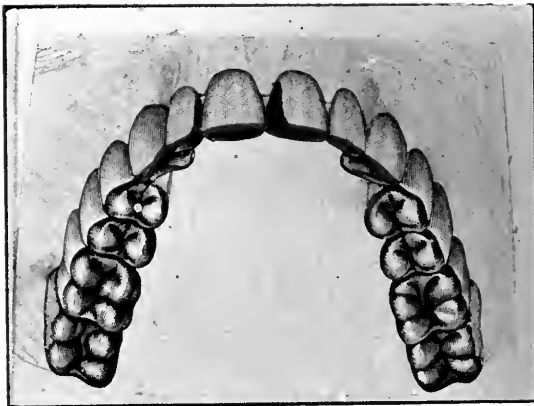


Fig. 71.—Showing the necessary amount of metal for adequate protection of abraded surfaces, when opening the bite.

surfaces from further destruction with the minimum amount of cutting. As is the case with the other forms of filling the surface

covered should be generous. If only one tooth is to be treated with this filling the amount of tooth substance cut away will be about the same as the quantity of gold in the inlay.

However if the bite is to be raised on most or all teeth the cutting should be very slight and only enough to properly cleave and bevel the enamel margins.

In vital cases either incisal, lingual or occlusal, the retention should be made by the introduction of short pins, iridio-platinum or tungsten preferred, through a matrix of pure gold, and then casting the contour.

In Non-Vital Cases a single large pin should be used, or the model may be so made as to occupy a part of the pulp chamber in lieu of the pin.

PART II

CHAPTER XIX.

THE MAKING AND SETTING OF A GOLD INLAY.

In discussing the methods of making any filling, particularly the gold inlay, one must bear in mind that the best practice today may be obsolete tomorrow. In this chapter an attempt is made to bring out only the most popular methods at this time, as we are fully aware that new methods are continually being devised, which may prove of better service. In fact, since placing the first edition of this book on the market, there have been material changes in methods, which have resulted in much improvement in this class of fillings. However, it is a question in the minds of most of our prominent teachers, as to the comparative value of this method when considering the cohesive gold filling. If the excellent results obtained in the use of cohesive gold are to be approached in the use of the inlay, great care and pains must be taken with every little detail.

The Object of the Inlay. The object of the inlay is to protect the cement which covers the cavity walls and restore lost contour.

If cement were permanent in the mouth when exposed to wear and dissolving agents, there would be no call for inlays, which are really only made to protect the cement. It is therefore of the utmost importance that the inlay completely cover the cement by a perfect adaptation at the cavity margins and that it be so constructed that it will maintain this close adaptation.

In choosing the method of construction in each case the marginal adaptation should be considered and the one selected which promises the greatest perfection.

History. The gold inlay is one of the oldest forms of filling. In fact, it is the oldest, as proved by excavations in the Orient. Teeth in the skulls of mummies have been found wherein cavities have been crowded full of lead, with the probable intent to check decay. Even in modern times the inlay has always been practiced more or less, and has become more popular as time goes on. As compared with the making of a cohesive gold filling, it is infinitely easier, and the history of our college clinics shows that the beginner attains a passing degree of success with the gold in-

lay long before he is able to understand and successfully bring to bear many of the qualities of cohesive gold.

Method Using Pattern Entirely of Wax. The cavity should be prepared as for any other metal filling except that the retention form should be omitted. In case decay has so left the cavity that it is naturally retentive by having excavated undercuts these should be filled with some substance which does not become a part of the pattern, and which is easily removed before setting the inlay. The substances used to temporarily remove the retentive form, are cement, temporary stopping, modeling compound and wax, the preference being with the wax.

This wax should be of a decidedly different color than that of which the pattern is made. (See Fig. 72.)



Fig. 72.—Large restoration in non-vital case. Part of the pulp chamber has been filled with black wax to remove undercut caused by pulp removal. The weak buccal wall has been covered with the same material to protect it from stress from within when setting the inlay. It goes without saying that this wax is all removed before setting the inlay and is therefore replaced with the cement with which the inlay is set.

The Filling of the Undercuts should be made to dry cavity walls, and with the wax quite warm to insure its adhering, that it may not leave the walls to distort the pattern. The difference in the color of wax used will cause the detection of any particles which may adhere to the pattern and make their removal easy.

By a little study and the judicious use of the above method much cutting for convenience form may be obviated and many seemingly difficult cases rendered quite simple.

The Making of the Pattern. After the retentive form has been removed, the cavity should be flooded with water of ordinary temperature. This will render the wax within the cavity suffi-

ciently hard not to yield under the force necessary to introduce the pattern wax. It will also prevent the portions of wax from adhering. The wax for the pattern should then be softened, preferably in warm water. The wax should be sufficiently plastic to permit of molding when manipulated in the fingers, care being taken that the wax is not folded upon itself as the portions will not adhere. Wax so folded is liable to part at the folds and come away from the cavity in sections. The wax should be gently shaped so that it can be introduced into the cavity in such manner as to come in contact with the base walls or floor of the cavity first, then by slow continued pressure for about fifteen seconds made to expand till it entirely fills the cavity, overflowing all margins.

If the inlay is to replace any portion of the occluding surface the operation should be done with the rubber dam off. The patient is requested to close the teeth to full occlusion, slowly. It must be remembered that the casting wax is only semi-plastic and moves very slowly, hence the best impression is obtained by moderate continued force, giving the sluggish wax time to flow. Wax is really quite elastic when confined and when the pressure from the bite is removed will spring back the least bit, so that the cast inlay will be too high when set.

To overcome this it is good practice to have the patient again close the teeth to occlusion with one layer of rubber dam over the occlusal surface of the model, requesting him to maintain the pressure for some seconds. The elasticity of the rubber dam will overcome the elasticity of the wax. This will do away with much grinding after fitting the inlay to position. The pattern should then be carved to full contour restoration and correct external surface form, and the wax thoroughly burnished around the entire cavity outline.

The carving and burnishing of the wax is materially assisted if the surface is warmed by the use of warm water. This is best accomplished by dipping large loosely-rolled cotton balls in water that is almost too warm for the fingers, carrying it to the mouth and folding about the wax, allowing it to remain for a few seconds. Upon removing the cotton the wax will be found to have softened to a sufficient depth to be easily manipulated. In case the wax does not quite reach the margin, the same should be crowded over to the margins, carrying quite a body of the wax over before attempting to burnish down to the margins. If this is not done the wax will be found to fit only at the cavo-surface angle, leaving a space just below this point to which the wax is not adapted.

Ideal Conditions Are Obtained when the wax slightly overlaps the cavo-surface angle at all points in the outline, about one-tenth of a millimeter.

This will give sufficient bulk for correct finishing. After the completion of the pattern it is well to insert the tine of an explorer to the depth of about one or two millimeters in a convenient position for removal.

The tine should be removed and the pattern chilled with cold water, the tine reinserted into the previously made hole, the pattern gently pushed to exit and then given a cold water bath.

The Placing of the Sprue Wire. While the pattern is still carried on the tine of the explorer, the sprue wire should be warmed and inserted.

The sprue wire should be very fine, preferably copper, and introduced deep into the pattern. This use of a fine sprue wire is of



Fig. 73.—Some of the methods by which inlays may be given retentive form in large decays and non-vital cases.

advantage from the fact that no considerable body of the wax melts and runs back up the wire to produce a concavity, close to where the wire is introduced, which happens when a large sprue wire is used.

In selecting the position for the wire, care should be taken that a location is chosen so that the contour of the surface of the pattern leaves the sprue wire in all directions at an obtuse angle. A neglect of this point will occasionally result in imperfect casts near the sprue former. The tine of the explorer should now be withdrawn and the resulting hole sealed by touching with the warm end of a small instrument.

A good instrument for such work is the flattened end of a large canal cleaner or broach, mounted on a wooden handle.

Giving the Wax Pattern Retention Form. Portions of the pat-

tern should now be removed, preferably by the use of the heated hollow needle, in such manner as to give the cement an ample grasp upon the inlay, and should be equal to or more than the amount of retention of which the cavity in the tooth is capable. The pattern is then ready for investment.

Method of Using Wax Pattern, Pin Attached. This method is of service when for any reason it is desired to have the maximum amount of retention. In such cases the tooth will generally be non-vital and a portion of the pulp cavity used for the reception of the pin.

Placing the Pin. The cavity should be first freed from retentive form as described above, using either cement, temporary stopping, modeling compound, or wax, then the opening made in the root canal to receive the pin which is placed in position, with a light coat of sticky wax on the outer end. The pin should be long enough to reach well into the body of the wax pattern and should be iridio-platinum, platinized gold or tungsten. These materials will stand the heat of casting the inlay without alloying or losing their rigidity.

Tungsten Pins. The use of tungsten in casting gold inlays is of great advantage, as this material is easily cast upon when the wire has been previously gold-plated. The wire is about six times as strong as iridio-platinum of the same gauge and three times as strong as steel. This material does not lose its temper upon being heated. It therefore gives us a very rigid pin in the completed work. As the gold will not cast to the end of the pin, which has been cut off and is not gold-plated, it is very essential that these exposed ends be well buried in the wax, which can be accomplished by seeing that the pin does not come near the surface of the casting, or else that the end is bent so as to throw the exposed surface more deeply into the wax pattern. With the pin in position in the cavity the wax for the pattern is manipulated the same as though no pin had been used. When the pattern is withdrawn the pin should come away with the wax. In case it does not, withdraw the pin from the tooth and seal it into the hole it has left in the wax pattern and return to position to insure alignment. Withdraw the pattern after chilling and all is ready for investment.

Method of Using Pure Gold Matrix With Pin Soldered on, Casting the Contour. This method is advised as most practical in cavities of Class Four (first plan), when teeth are non-vital, in incisal restorations vital or non-vital, in occlusal restorations, cavities of class six particularly in vital cases, and in lingual restorations.

With these lingual restorations, the amount of surface covered is generally quite large as compared to the thickness of the restoration which is best termed an "onlay."

This method simplifies angle restoration in Class Four plan one and provides ample resistance form, without the cutting of either the incisal or lingual step. In such cases the alignment of the pin must be perfect else the inlay will not go to proper place. The soldering of the pin to a gold matrix gives the desired security during the processes of removing and investment. The cavity preparation is the same as for cohesive gold except the convenience angles. The pin is fitted to a portion of the root canal as previously given. A sheet of pure gold, 32 to 34 gauge is selected of sufficient size to more than cover the cavity by about two millimeters. This is partially burnished to the cavity, enough to show the cavity outline in the gold. A hole is punched in the proper position to receive the pin, but smaller than the pin, which should be 15 or 16 gauge. In case the inlay is to be used as an abutment for a bridge, the pin had better be as large as 14 gauge, if platinized gold is used. When tungsten is used, 16 gauge is ample.

The operator should then place the matrix in position and crowd the pin through the hole to place; then scribe the pin just external to the gold matrix, remove and solder as nearly in correct position as possible, without stopping to invest, using 22K solder.

Only a very small amount of solder will be needed or should be used, care being taken that it is all flowed close to the pin to prevent stiffening the matrix. All should then be returned to the cavity and the gold reburnished to a perfect fit of the entire cavity outline.

It is necessary to burnish the gold only partially into the deep recesses of the cavity as the pin, if of iridio-platinum or tungsten, will be sufficient anchorage. This can be made to equal that frequently relied on for an entire crown. This pattern must move to the incisal for exit and if the matrix is burnished to contact with the axial wall it will become fixed. The matrix should be burnished to a complete fit of the gingival wall which should be flat and well squared into the labial and lingual angles.

Making the Wax Contour. The matrix and attached pin are removed, and the desired contour built up by flowing the wax to position with a spatula, trying the whole pattern to place in the cavity to guide in the restoration. When complete, the wax is chilled and removed and all is ready for investment.

To Restore Occlusal and Incisal Surfaces lost from abrasion with inlays where the tooth is vital, nothing answers the purpose better than the following method. The outline of the surface to be covered is established. Small holes are drilled to convenient depths in safe locations of sufficient size to receive a 20 gauge iridio-platinum or tungsten pin. Three or four pins are required for molars and two or three for bicuspids or incisors. A pure gold matrix, 32 or 34 gauge, is then burnished to an approximate fit. The positions of the holes in the tooth will be outlined in the gold. The matrix should be pricked at these points with a sharp pointed instrument smaller than the pins. One pin is inserted and should protrude occlusally through the matrix for a short distance, and be bent at right angles.

It is good practice when using tungsten to make a loop which goes to the full depth of two of the holes and lies along the gold surface in the body of the loop, thus establishing the alignment of two of the pins at once. This also places the exposed end of these tungsten pins, to which gold will not cast, entirely away from a position which might result in showing the exposed ends in the completed case.

This pin and matrix are then removed and attached with solder, applying the solder to the occlusal side of the matrix. The matrix should be returned to the tooth and another pin placed and attached in the same way, repeating until all pins are in position, when the matrix should receive a final burnishing. The wax contour is then added as before described, the pattern replaced and articulation secured in the mouth and finally trimmed to desired contour. The wax should then be chilled and the entire pattern removed and invested.

Method of Sweating the Contour.—Advantages. The advantages of this older method of making an inlay still exist where the inlay is to cover considerable surface and is very shallow. Such inlays are generally termed "onlays." This method is advised from the fact that models of such nature will seldom maintain exact form during the process of removing and investment unless a gold matrix is used.

If the gold matrix is used it is difficult to cast a thin layer of gold over the entire surface of this matrix and get good margins unless a large quantity of gold is melted to make the cast in which case the gold matrix is very liable to be entirely fused, which will not give the best results. Speed is also a factor in this instance.

Many times an onlay can be flowed to the desired thickness in much less time than that required to invest and cast.

Making the Matrix. This is done in the same way as though a greater bulk of gold were to be added. Such inlays must be retained by one or more pins soldered to the cavity side as previously described.

The matrix is burnished to perfect fit and the outline definitely established. The matrix should be trimmed to within about one-fourth millimeter of the cavity outline and reburnished and carefully removed.

The matrix is then given a coat of whiting on all that portion which is to come in contact with the tooth to prevent the solder from flowing on that surface.

Sweating the Contour. The gold matrix should be then laid upon the soldering block and with a brush flame from the blow pipe 22K plate or 22K solder fused to the thickness desired in the various locations on the matrix. When a sufficient amount has been fused in any portion, that part of the surface should receive a coat of whiting.

Gold can then be fused to still exposed surface without its spreading to portions where it is not wanted. By this means it is possible to build up a given portion of the inlay, even to the adding of cusps to occlusal surfaces.

Method of Using Sponge Gold as a Pattern. Take the sponge gold as bought on the market for making a cohesive gold filling and saturate it with any casting wax on the market. This is best accomplished by dipping a sufficient amount of the heated gold, while held in the pliers, into the molten wax, and immediately removing to a clean surface to cool. Remove any excess wax.

Making the Pattern. When this method is used any undercuts in the cavity should be filled with cement. A portion of the saturated gold large enough to a little more than fill the cavity is grasped between the pliers and slightly warmed and carried to the cavity and crowded to position and the contour determined in much the same way as amalgam is manipulated. A matrix should be used in class two cavities, but not sufficiently high to prevent occluding the teeth. When the pattern has the desired contour form, the whole is removed the same as described for removing a pattern composed of wax alone.

Investing. A sprue of wax is attached to the usual place as though the casting method were to be used. The pattern is then

submerged in much the same way as a tooth is invested to have a backing flowed but sufficiently deep upon the wax sprue former to leave upon its removal a receptacle for the gold solder to be fused.

Saturating the Model. Heat may be applied to the invested pattern as soon as the investment has set, and the wax gradually burned out leaving a framework of pure gold filling the mold. Then scraps of 22K gold plate are placed in the hole left by the sprue former and all is heated to the point of fusing the 22K gold which will disappear through the opening and completely saturate the pure gold within the mold. The inlay may be immediately chilled and finished. This method has to recommend it, speed of manipulation, and is indicated in large contour restorations, where it is desired to use a solid inlay.

Making the Cast. Generally considered we have three forces used in placing the gold in the mold; suction, pressure, and centrifugal. Centrifugal force is the only one wherein all atoms or molecules of the material are acted upon, and greater accuracy is obtained by this method.

Place of Heating the Gold. The temperature of the mold at the time the gold strikes it, in casting, is of great importance. Therefore, the place where the gold is melted should not be on the body of the investment over the mold, for by that method we are not able to vary the temperature of the mold at the time of casting. The gold should be melted on a separate tray and the mold should be heated to the desired temperature independently of the material being cast.

Temperature of the Mold. By a little experimenting we will be able to demonstrate that a body of molten gold contracts toward, first, that part which is chilled first, second toward the greatest body of gold; that is, when the gold consists of two parts connected by a small isthmus, or in other words, pedunculated, there is a tendency for the smaller body of gold to shrink toward the larger one. The first part of the gold which we desire to set through the process of chilling is that part of the inlay which is most essential to a perfect fit, namely the margin or that which covers the marginal bevel and second all of the cavity walls. Therefore, it is important when the gold is thrown into the mold that the investment which forms the mold be of a temperature to chill the gold at first impact, bearing in mind that it should be warm enough to permit of the gold to enter the sharpest recesses.

When Using Pin or Pure Gold Matrix. When casting an inlay to a mold which contains a pin or a pure gold matrix, the temperature of the mold should be considerably higher. Particularly is this true when the pin is large or the amount of gold to cover the matrix is thin as it may be close to the margins.

Quantity of Gold Used in the Cast. When using the suction or pressure machines it is quite necessary to have a large sprue left, as when the amount of gold is near the size of the inlay, failure is liable to result owing to the philosophy of the force used in casting. However, with the centrifugal machine, it is not absolutely essential that there be any considerable sprue left. Yet if we try to guess too closely, many failures will result from having too little material. Owing to the law of the shrinkage of the metal towards the larger body, the sprue which is left should never weigh as much as the inlay cast. A large sprue left is of advantage, as there is a tendency to hold the whole body of gold at a temperature sufficient to give it time to thread its way through the sprue hole into the mold. It is also of advantage where there is a large pin or matrix present, as the high temperature is maintained longer.

The large sprue is particularly at a disadvantage when casting the base to pin crowns. The low fusing pin is liable to be melted. There is also more danger of checking the porcelain.

Size of the Opening. The size of the hole leading to the mold is of importance for a number of reasons. As a general rule the larger the inlay, and the lower temperature of both the hole and the material at which you cast, the larger should be the hole; it necessarily follows that the hole should be smaller with the reverse conditions.

A small hole lengthens the time required for the stream of molten gold to pass to position. Hence, if the mold is cold and the material is not extra warm in casting a large body, the material is liable to become chilled and the mold not entirely filled. However, if we are casting a small inlay, in a rather warm mold with the gold extra hot, the small hole is preferable as there is less liability of a backward shrinkage of the gold to the sprue, when cooling.

Better results are obtained when the wax pattern is immediately invested, burned out and casting completed without allowing the mold, either with the pattern in position or burned out, to lay over night. If it must lay over night, it is best to burn out the wax and thoroughly heat the mold, as less change takes place thereafter in the investment. In this connection your attention is called to the

findings of Prothero in the expansion and contraction of plaster paris in the various periods following its mixture with water.

Finishing the Inlay. With any of the processes of making an inlay there are liable to be some imperfections which will be seen upon removing from the investment. If these are on the cavity side of the inlay and are of any considerable size it will probably be necessary to make a new pattern. If they are only slight and are in the form of little pedunculated masses they can generally be removed without injury to the filling. If the contour shows that the mold did not entirely fill the necessary amount to complete contour, and the margin is not involved it may be sweat on using a gold of lower fusing point than that of the inlay. Another method is to make a gold amalgam and build to the desired contour. Then the inlay should be subjected to heat gradually raised to nearly red heat when the mercury will be volatilized leaving the pure gold fused to the position desired. This gold amalgam is made by adding mercury to cohesive gold foil, pellets or fiber which have been annealed, mixing thoroughly in the palm of the hand and applying immediately to place. All exposed surfaces of gold inlays should receive a high polish before setting, omitting a line about one-fourth of a millimeter next to the entire margin.

Setting the Inlay. The inlay should be washed with water and dried; then dipped in chloroform to remove any oil that may have adhered from the hands. The cavity should be freed from all foreign substance, given complete retentive form, bathed with chloroform and alcohol in the order named and the surface of the cavity entirely covered with cement.

The inlay is given a coat of cement on its cavity side from the same mix and gently but firmly moved to position using hand pressure assisted by light blows from the mallet. The inlay should be subjected to pressure directed toward the seat of the cavity for some minutes which will in a measure overcome the tendency toward displacement caused by the expansion of the cement. An inlay may be finished at its margins within thirty minutes from setting, but it is better if this step is attended to at a subsequent time.

CHAPTER XX.

MANIPULATION OF COHESIVE GOLD IN THE MAKING OF A FILLING.

Physical Properties. The physical properties most desired in a filling are found in cohesive gold to a greater degree than in any other filling material, which places it at the head of the list as a means of restoring lost contour and preventing recurrence of decay. It is not affected by the fluids of the mouth; it may be very perfectly adapted to the walls of the cavity; the shrinkage and expansion range in varying temperature is very slight; the cavity can be filled immediately upon freshly cut surfaces before they have been contaminated, an advantage over the fused inlay; and when sufficiently condensed it possesses a greater specific gravity, hence density, than a fused inlay of pure gold. Hammered gold will flow under sufficient stress and always in proportion to the load, when it ceases to flow, unless the load is increased—a marked distinction between it and amalgam. This quality of gold makes it possible to build a filling which will at once sustain the force of mastication provided it has received sufficient aggregate weight during the process of introduction. This physical property of gold is also of service in that it does not farther compress when firmly wedged between the walls of living dentine which are elastic and retain a certain amount of residual elasticity which permanently grasps the unyielding gold. The expansion and contraction of gold under the varying oral temperatures is fully compensated for by this residual elasticity of the dentine so that the closely adapted cohesive gold filling is at all times in perfect adaptation.

The Objectionable Qualities of Gold. Gold is a good conductor of thermal changes, hence endangers the health of vital pulps. The color is an objection in anterior positions, and the process of building a filling is comparatively slow and taxing on patient and operator.

Welding of Gold. Gold welds cold when properly prepared, is absolutely pure, and the contacting surfaces are clean. Any alloy in its substance (excepting platinum) or foreign substance upon its surface totally destroys this quality, until such substances are removed, when the property of welding cold again returns.

If the Surface of Foil Becomes contaminated with a non-evaporable substance the injury is permanent.

To Protect the Surface of Gold. Place in the drawer where the gold is kept a small pledget of cotton or spunk saturated with ammonia.

Ammonium salts will form on the surface of the gold, which are easily volatilized by heat, leaving the gold clean. Before annealing such gold will be found thoroughly non-cohesive. This method of treating the gold to the fumes of ammonia will obviate the necessity of keeping more than one kind of gold on hand, as all will be non-cohesive till annealed and can be used in either form.

Annealing Gold is for the sole purpose of cleaning the surface of the gold by volatilizing any film that may have collected.

The Degree of Heat is about 1100°F., or just below red heat.

In the daylight this color is not apparent, but on a dark day the dull red color should show. The gold is not materially injured if carried to the full red of 1200 or 1300 degrees, but in no case should the melting point be reached, as it destroys the possibility of adaptation to the walls of the cavity, or the surface of the gold already in place.

Methods of Annealing. The electric annealer is by far the most satisfactory means, as it is possible to always obtain the same degree of heat for a continued period.

The Next Best Means is to place the gold on a tray above a flame, thus separating the flame from the gold, preventing contamination of the gold with carbon, and various gases which are frequently met with in combustion.

Gold Should Not Be Annealed by Passing It Through the Open Flame of either gas or alcohol, holding the gold either on a plugger point or the foil carriers. This is quite a common practice, which should be discontinued. In the first place, heating the gold with the open flame frequently contaminates its surface, to the injury of its welding properties.

Also that portion of the gold next to the carrier is not sufficiently heated and remains non-cohesive, a fact which is shown by the subsequent pitting of the surface of the filling during service by the flecking off of these non-cohesive particles.

Specific Gravity. The specific gravity of the cast gold inlay is about 19, varying the fraction of a point.

It is possible to condense a cohesive gold filling when confined between the walls of elastic dentine so as to obtain a slightly greater specific gravity than the cast inlay. However, this degree

of solidity is not possible of attainment unless the gold is confined and the wedging principle is taken advantage of.

Cohesion of Gold. The surfaces of pure gold when absolutely clean readily cohere. This cohesion is brought about by the friction of the surfaces of the gold when in absolute adaptation. The degree of cohesion is in proportion to the friction. The friction is in proportion to the load, the extent of the surfaces in opposition and the speed of the travel of the surfaces one upon the other. Hence, the greater the load, the smaller the surface, and the more rapid the movement of one surface upon the other the greater the cohesion. Polished surfaces of gold must be brought into coadaptation in order to get cohesion. The smaller the surfaces and the thinner the sheets, the less load and speed will be required.

The Serrated Plugger Points are used in condensing cohesive gold for the following reasons: That these polished surfaces may be kept small and uniform; that great pressure (load) may be easily exerted on the polished planes previously left in the surface of the gold by the wedge-shaped serrations. The mallet is applied to give the additional factor in friction (speed) as the fresh gold is moved over these small polished surfaces. The above conditions are obtained with the least exertion on the part of the operator and annoyance to the patient by the serrated plugger point, which is made of a collection of pyramids which act as so many wedges and exert great lateral force (load) upon the polished sides of their previous impression. That gold coheres to polished surfaces can be easily demonstrated by taking any cohesive gold filling and burnishing its surface to a glossy finish. Pellets of gold from the annealer will readily cohere and the filling may be continued to full contour by applying a steel burnisher with heavy pressure drawn over the surface of the fresh gold. This process proves that burnished gold coheres, but it is slow and laborious and objectionable to the patient, hence the serrated plugger point which accomplishes the same result, the friction of polished surfaces of gold under pressure, causing their welding.

Bridging is the term applied to that faulty manipulation which results in air spaces within the body of the filling, caused by the gold failing to reach the bottom of the indentations of the serrated plugger point.

The Cause may be insufficient pressure being given the plugger point, the gold thereby stopping short of the bottom of the serrations, or it may be caused by too much light malleting, going over the gold surface repeatedly thereby bending down the crests of

the pyramids thus choking them to the entrance of the gold. Again, it may be caused by changing to a plugger with a less number of serrations to the millimeter, or one wherein the serrations are not as deeply cut, resulting in a collection of pyramids that do not reach the bottom of the indentations made by the previous plugger.

Plugger Points Should Have the Same Sized Serrations. Each operator should have a set of gold plugger points same denomination as to the cuttings on the working point to use in the same filling. When forced to change to one of different sized serrations the surface of the filling should be gone entirely over with the new plugger to be used, before adding additional gold. This will create a new set of facets to accommodate the gold added with the new instrument. (See Figs. 176A and 176B.)

A little care in this respect will greatly increase the specific gravity of the cohesive gold filling.

Rotating the Plugger in the Fingers Should Be Avoided. The serrations are cut on the square and unless the point is rotated one-fourth of a circle each time the pyramids will ride the crests of the indentations, whereas if the shaft is held in one position as described, the leverage produced by the plane on the surface of the plugger point coming in contact with the plane on the surface of the filling, will twist the plugger point to position with each blow of the mallet. All this will prove plain to the vision if the field of operation is viewed under a high power lens while operating with a serrated plugger on the surface of gold in a technic block.

The Size of the Plugger Point. This depends entirely upon the force with which it can be used. It would seem from all the facts at hand that a point with the surface of one square millimeter should be regarded as the maximum. The force required to properly condense gold with a point of greater surface, is either not permissible in many cases or often not possible with the operator. A point of one square millimeter should receive a load of 15 pounds pressure at each contacting of the point.

At the same time points of much less than one-half millimeter will chop the surface by disturbing the gold close to the point with each impact; hence we are limited to a narrow range as to size of points.

Preparation of the Foil. The gold foil may be used from the book as it comes from the dealer, and shaped as desired by the operator, or it may be purchased as cylinders, squares, ropes and various other forms.

The shaping should be done without bringing the gold in direct contact with the fingers, and all manipulation and cutting should be done previous to annealing.

The Application of the Foil. In whichever form the foil has been shaped, it should be so placed upon the surface of condensed gold that the leaves lay flat. If the pellets are placed so that the leaves of gold are crumpled in packing to place the specific gravity will not be as great in the finished filling. Neither will the cohesion be as perfect.

Sheet gold has left in it a certain amount of spring even after annealing that has to be overcome if folded. The less handling of the sheets in folds when packing the better the result. The gold should be grasped by the carriers with as small a bite as possible to prevent precondensation and carried to the position desired and condensed, with no attempt to shift its position by pushing or poking it around over the surface.

If the pellet is placed near a wall, it should be placed so that it lies fully against that wall that it may be crowded for room when condensed. Short of this will hinder the wedging principle in packing. If the new pellet is to come out to contour it should reach slightly beyond contour and be burnished back to contour with a flat-faced steel burnisher.

The Forces Used in Condensing Cohesive Gold. There are two principal forces used in condensing cohesive gold, hand pressure and blows from the mallet. These may be either alone or one following the other or in combination; the last named is the most popular, the least taxing on patient and operator and produces as great specific gravity in less time. However, the best results are obtained by using each method at given times in the process of building most fillings.

To Illustrate. Hand pressure alone should be used in the filling of convenience angles. Also when on account of position the force must be applied at nearly a right angle to the wall against which the gold is being condensed, as in starting a filling and when covering the seat of the cavity with the first one-half millimeter of gold.

With the plugger point pointing directly at a dentinal wall, with a thin layer of gold between, the elasticity of the dentine causes the gold to rebound when struck a blow with the mallet. In such positions the closest adaptation is secured by hand pressure alone which should be applied with a rocking motion secured by swaying the outer end of the plugger from side to side for a distance of, say one inch, at each change of position.

Hand Pressure Alone is also of most service when packing gold

against thin walls. Again in cases where the condensing force should be applied at an angle to the long axis of the shaft of the plugger point as sometimes met with in distal cavities in posterior teeth with a distal inclination. Hand pressure alone is required when it becomes necessary to use force at an angle which would tend to unseat the filling.

A filling should never receive a blow through the plugging instrument when that instrument does not point quite directly toward one of the inner walls of the cavity, preferably the seat.

Mallet Force Alone is of service in adding the last portions of gold to an occlusal surface when adding thin layers of gold at each time, resulting in a very hard surface.

A Good Rule is to increase the hand pressure (load) both in frequency and weight as you increase the thickness of the pellets applied, and as the angle at which the gold is driven to a dentinal wall approaches a right angle.

The Different Plans of Mallet Force.

Hand Mallet. By far the best mallet force is the hand mallet driven by an experienced assistant. By this method the operator is able to vary the amount of hand pressure (load) and its relation to the mallet force (velocity) at will all through the filling, as well as at different points in the condensing of a single pellet of gold, a point of no small consequence.

The Automatic Mallet. It has been attempted to imitate this combination method in the automatic plugger, and is today the best substitute for the hand pressure and assistant mallet method, but it must be regarded as a substitute only and supplies a need in the absence of better facilities.

Power Mallet. Power mallets either electric or mechanically driven by the engine are of service in that part of each filling where mallet force alone is indicated as previously described. But this is such a small proportion of each filling that most operators do not care to bother with them and few have them at hand.

CHAPTER XXI.

MANIPULATION OF COHESIVE GOLD IN THE MAKING OF FILLINGS BY CLASSES.

Class One. Pit and Fissure.

This class of cavities is the easiest of all in that they are surrounded by solid walls of dentine with generally only one wall missing, which is the means of access to the cavity.

Starting the Filling. In the case of a small pit cavity it is generally well to start with a piece of gold that is sufficiently large to more than cover the internal wall and condense the greater portion with a rather large plugger point using hand pressure alone on this piece. With oclusal cavities the inner wall is the pulpal wall. When the cavity is in an axial surface it is the axial wall.

A second pellet of gold may be added and condensed in the same way. The mallet force should now be used on a smaller plugger point going entirely around the cavity close to the walls holding the shaft of the plugger at an angle of about 12 degrees centigrade to the wall against which the condensing is being done.

In Oclusal Cavities the condensing should be in the central portion first; then next to the distal wall; then along the buccal and lingual walls and lastly the mesial wall. This plan of procedure pertains to each separate layer of gold as it is applied when treating simple oclusal pits.

In Buccal Cavities the order of stepping is: first, center; second, gingival; third, distal; fourth, mesial; fifth, oclusal.

When the Cavity Has a Long Irregular Outline caused by the following out of one or more rather long fissures the plan is the same, except that the most distant arm of the cavity is filled first, allowing the gold to gradually build toward the operator's viewpoint, covering the base wall, portion by portion, with the plugger point always at the given angle to this base wall, which permits of the use of mallet force after the first pieces of gold have been securely anchored along the disto-pulpal line angle.

Class Two. Proximal Cavities in Bicuspids and Molars.

Beginning the Filling. There are three distinct methods of starting a filling of cohesive gold in this class of cavities. It is well if both gingival point angles are sharpened to a convenience angle. It

will not suffice to have these made into the form of a round hole or slot, but they should be shaped up to the distinct wedge shape. This shape will cause the condensed gold to crowd the elastic dentine on all sides as it is driven to place and insure the stability of the first piece of gold. If this small convenience angle is not sharp at its deepest point, but has a flat wall or seat, the mallet force is precluded as that flat wall will not permit its use, the elasticity of which will cause the gold to rebound when struck a blow, whereas when this point is sharp and the approaching sides leave a wedge-shaped opening the gold is firmly grasped when driven to position. Attention to this small detail will make easy starting of such fillings.

As to the Three Plans of Starting Class Two.—*The First Plan,*

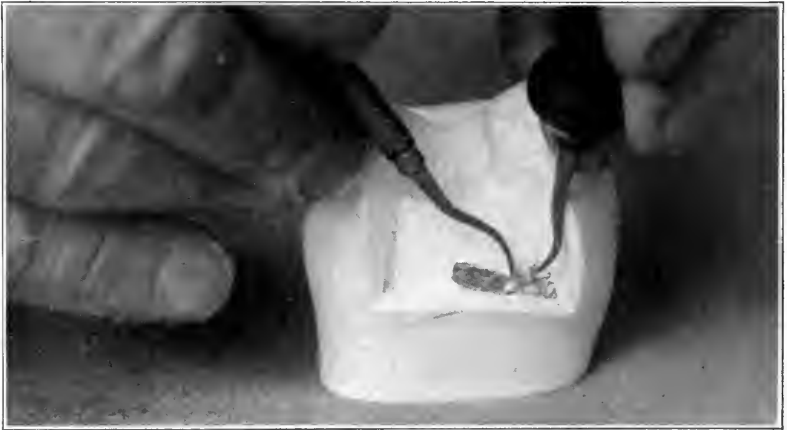

Fig. 74.—Starting cohesive gold, first plan.

and probably the most popular, is to fill one convenience angle, the one the farthest from the viewpoint of the operator, and while supporting this in position with a suitable instrument build along the gingivo-axial line angle to the other point angle.

A Second Plan is to fill each point angle separately and join the two with a third piece of gold laid along the gingivo-axial line angle.

A Third Plan is to start with a quantity of gold sufficient to fill both point angles and cover the connecting line angle as well as a considerable portion of the gingival wall next to the axial. This last plan is one used by some experienced operators and is well to be attempted when working for speed. The beginner will do well with the first plan.

The Order of Stepping the Plugger in Class Two. With each

pellet of gold added, the wedging principle is made most effective by the following order of stepping: Center of filling first; contour second; ascending line angles third; surrounding walls fourth and against ascending cavo-surface angles fifth, keeping the long axis of the plugger shaft at about a twelve degree centrifgrade angle to the axial, buccal and lingual walls.

When the Gold Extends Beyond Contour it should be burnished back to correct position and the plugger again stepped along the contour, holding the plugger close to a line of the long axis of the tooth, instead of striking the gold at nearly a right angle to this line, a practice so common with operators, and one that has a tendency to unseat the filling and separate the layers of the filling already condensed.

The Progress of the Filling should be kept on a plane parallel

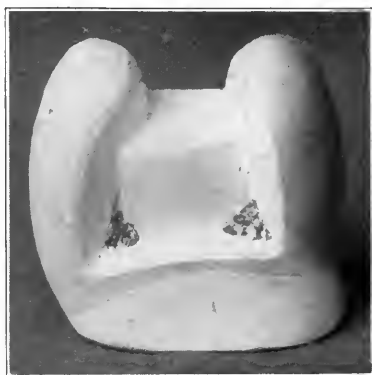


Fig. 75.—Starting cohesive gold, second plan.

to the plane of the gingival wall and kept in this plane to near the completion of the filling, having a strict care as to complete contour in the proximal, as the filling advances.

Covering the Pulpal Wall. There are two plans of covering the step portion in Class Two. *The First Plan.* The first and most common is to build the cavity portion to a level of the pulpal wall and gradually cover the pulpal wall by allowing each pellet of gold to extend a little farther than the previous one out over the pulpal wall till the pulpal point angles have been reached.

The Second Plan is to start an independent body of gold in the pulpal point angles, in one of the three ways outlined in starting the cavity portion on the gingival wall and finally uniting the two portions of the filling. Whichever plan is used nothing should be done

in the way of covering the pulpal wall till the gold in the cavity portion has reached a level with the axio-pulpal line angle.

The Contact Point. The building of contact point should receive special attention when the proper height of the filling has been reached. The gold should be thoroughly condensed against the proximating tooth much in the same manner as it is wedged against the walls, and should receive extra malleting to insure extreme hardness.

Position of Contact Point. When the proximating tooth is intact, the contact point should be in about the same position as it was previous to decay, and should be a contacting point and not surface or a line of contact. This should round away from this point

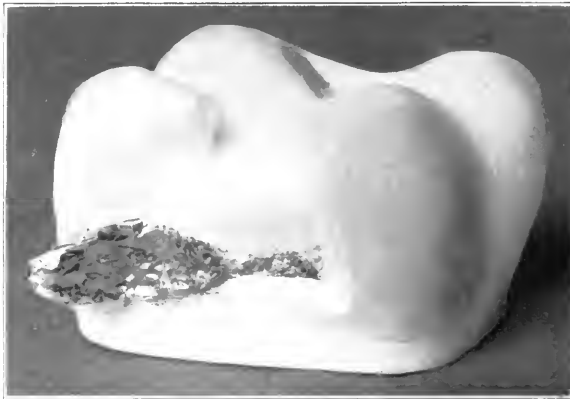

Fig. 76.—Starting cohesive gold, third plan.

in much the same manner as do the surfaces of two marbles when touching, and has come to be spoken of as the “marble contact.” (See Fig. 26.)

Moving Contact Point Flush to Oclusal. The contact point should be moved oclusally when both proximating surfaces are to be restored, one a mesial and the other a distal filling in the teeth making up the proximal space being considered, and when there has been considerable oclusal wear. This will result in a contact point from which the surfaces round away in all directions except toward the oclusal surface and is known as the “half marble contact” advised for the above condition only. In this connection attention is called to the immunity to decay of proximating surfaces where the “half marble contact” has been produced by oclusal wear. Many instances are seen where caries already started in such spaces have

ceased to progress because of the cleanliness of such surfaces, due to the lack of the egress of food substances.

The Last Portions of Gold. After leaving contact point the last portions of gold are added to restore normal contour or as near that condition as occlusion and articulation will permit giving special care to complete covering of the cavo-surface angle at all points.

Filling Class Two With Matrix in Position. This may be done, and is advised by some operators, who advance the theory of additional condensation due to the presence of the substitute for the missing wall.

When the matrix is used it should not be adjusted till the gingival cavo-surface angle is covered. It should be thoroughly wedged

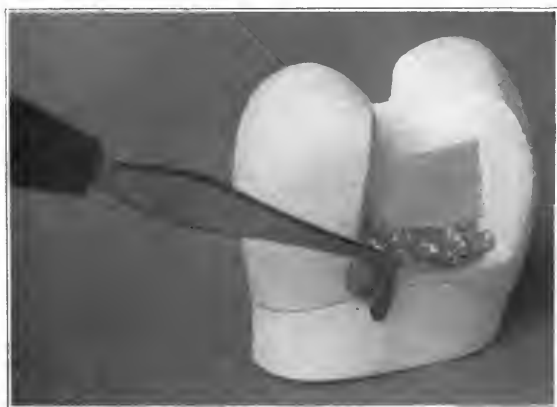


Fig. 77.—Burnishing back excess gold foil in covering the gingival margin.

at the gingival. The matrix should be removed just before the gold has been built to the height of contact point.

The Use of the Separator in Class Two. In cases where preliminary separation has not been made, a mechanical separation should be adjusted and tightened at short intervals to the full extent of safety. This will permit of better and more thorough finishing of contact point as the slight space resulting will be taken up, upon the removal of the separator.

Class Three. Proximal in the Six Anterior Not Involving the Angle.

Starting the Gold, in cavities class three, is the same in large or small cavities. The gold is first condensed into the wedge-shaped convenience angle farthest from the viewpoint of the operator which is the gingivo-axio-lingual angle. The gold is kept in this triangular

form by covering equally rapidly the three walls forming the angle; the gingival, axial and lingual walls, keeping the shaft of the plugger pointing all the time at the point angle primarily covered.

When the gold has been built out along the gingivo-lingual line

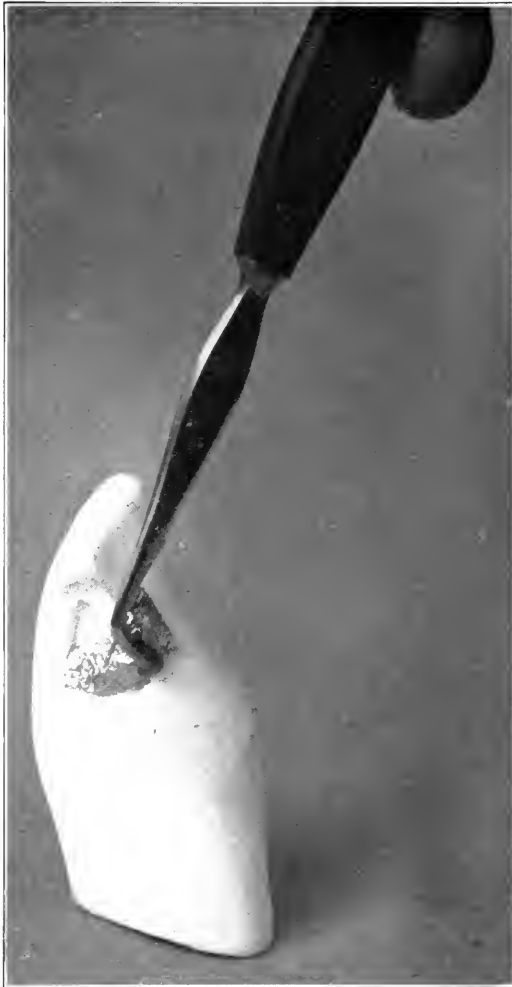

Fig. 78.—Covering the gingivo-lingual angle with cohesive gold.

angle to the cavo-surface angle great care must be taken at this stage of the filling that the linguo-gingival angle is covered and the gold built to full contour, as this is the only time it can be correctly done with the force directed in the right direction. As the gold reaches

the height of the gingivo-axio-labial angle this should be thoroughly filled and the filling continued, maintaining the same level of the gold, restoring full contour past contact point which should be well condensed and burnished.

Filling Incisal Angle. Shortly after passing contact point the gold should be advanced along the axio-lingual angle to the incisal angle which should then be filled using hand pressure alone as the direction of the force will not permit of the use of the mallet. The filling should then be completed with the plugger point still directed toward the angle where gold was first condensed, the last portions of gold being added to the labial portion of the filling at the incisal extremity.

With Lingual Approach in Class Three the whole plan is reversed. The gold is first built into the gingivo-axio-labial angle. The plugger point is maintained in a position pointing at this angle as the filling progresses, till the last additions of gold are to the lingual surface at the incisal extremity, all the while the operator is working to the image reflected in the mouth mirror.

The Lingual Approach Is Advised in cases where ample preliminary separation is secured or when the lingual wall is wanting and the axial wall meets the lingual cavo-surface angle. That said about the use of the mechanical mallet in Class Two applies to Class Three with equal force.

Class Four. Proximal Cavities in Incisors and Cuspids Involving the Angle.

The removal of the incisal angle permits of the plugger point being used in an ideal angle to the walls and allows the force being applied more nearly from the direction that the subsequent force of service is received.

Starting the Filling. These fillings are started as has just been described with Class Three; however, the gingival wall should be most rapidly covered and the plan of building similar to that described for Class Two, keeping the surface of the gold parallel to the plane of the gingival wall, restoring lost contour as the filling advances, and maintaining the plugger point at about 12 degrees centigrade to the surrounding walls.

The Final Portions of Gold should be condensed on the extreme incisal angle with the shaft of the plugger point still maintained at an angle of 12 degrees to the plane of the axial wall.

The Layers of Gold in Class Four should receive some attention and what is said in this connection is true of all contour restora-

tions subject to great stress. Not a little trouble has been experienced in the breaking of such fillings through given lines of fracture.

These should be noticed and the layers of gold leaf so placed as to cross these lines. The tensile strength of the sheets of gold is greater than the usual cohesion obtained giving a filling more strength across the laminations than parallel with them.

Class Five Cavities in the Gingival Third.

Class Five cavities in the gingival third need no special mention as they are built under the rules already outlined in Class One.

The gold is usually started in the disto-axio-gingival angle and carried along the gingivo-axial line angle to the other gingival point angle. The gingival wall will be the first wall to be completely covered. The mallet force should not be directed at a right angle until that wall has been covered with a considerable layer of gold.

Class Six. Abraded Surfaces.

These cavities are built the same as large flat cavities in the same surface, the principles of which have been given.

CHAPTER XXII.

FINISHING GOLD FILLINGS.

Secondary Consideration. When a gold filling has been built to its full size, the entire surface should be gone over with a plugger point of moderate size. The point should be stepped so as to cover every accessible part of the filling.

A light mallet with a hard surface should be used. A two ounce steel-faced mallet is preferred.

Burnishing. All accessible parts of the surface should then be thoroughly burnished with a steel burnisher. The egg-shaped burnisher is of most universal use as it will reach most positions.

If the filling is a proximal filling of Classes Two, Three or Four, a thin steel hand matrix should be forced between the filling and the proximating tooth to burnish the contact point and to better condense and harden the filling at this place. This is done by swinging the handle back and forth describing the part of a circle, till there is more or less freedom of movement of the burnisher.

Following This Secondary Condensation the process of smoothing the surface with abrasives begins. The first efforts should be to find cavity outline, second, to correct contour in localities where an excess has been built and third, to polish the contact point.

This is best accomplished by the use of small carborundum stones on occlusal surfaces, disks on buccal, lingual and labial contours, and narrow coarse strips in the proximal, gingivally from contact point assisted by the use of file cut burnishers.

Attention should first be given to all parts of the filling except contact point which, in all proximal fillings should be the last place to receive finish.

The Use of the Saw in the proximal space in the finishing of the filling cannot be too strongly condemned. In the first place no cutting instrument, or coarse abradent, as strips or disks, should be made to pass contact point except where there has been ample preliminary separation and the return of the teeth to position is relied upon to close the resultant space. Again there is no excuse for building an excess of contour sufficient to engage the bite of a saw blade.

The Excess at the Gingival should be slight, and it, with the excess fullness in the embrasures, should be filed away with the files, or whittled off with the burnishing knife, the edge of which should be keen. The files should be carried through the embrasures as far to-

ward the center of the filling as possible and drawn directly outward and over the edge of the filling out to the external enamel surface.

The Finishing Knife should be engaged into the substance of the gold and drawn from the gum and at the same time outward, taking off only a small portion of gold at each cut.

Coarse Abrasives, as carborundum stones and coarse disks and strips, should be abandoned as soon as a near approach to the cavo-surface angle is reached, and the files, plug-finishing burs, and knife edged instruments resorted to, to bring into view the exact cavity outline, after which the finer strips and disks should be employed to bring gold and tooth substance to an exact level at the cavo-surface angle for the entire cavity outline.

Finishing Strips in the Proximal. To reduce the quantity of gold from contact point to the gingival, a coarse finishing strip sufficiently narrow to reach from the gingival outline to near the contact point only, is of advantage. This strip is introduced by sharpening one end and passing through the embrasure below contact point and then drawn back and forth till the desired surface is secured.

Fine narrow linen strips are then used in the same way to give a final finish to this place of difficult access.

When the Entire Cavity Outline Has Been Exposed and the surface otherwise made ready for the final finish the separator should be tightened another degree, when it will be found that a broad fine linen strip will easily pass contact point. This should be given three or four sweeps with this broad strip not too tightly drawn, when the contact point should be considered finished.

The separator should be gradually loosened and removed, the rubber dam removed and the filling tested for occlusion and articulation and properly shaped. The filling should then receive a thorough finish, with wood points, leather wheels and tooth cleaning brushes, carrying first pumice, then whitening, till the surface of the filling is as smooth as the external enamel surface.

CHAPTER XXIII.

MANIPULATION OF AMALGAM IN THE MAKING OF A FILLING.

Definition. Amalgam is a composition of mercury with one or more other metals. It is most commonly combined with two or more other metals which have been previously alloyed and finely divided either as shavings or filings to facilitate union with the mercury.

History. Amalgam for the filling of teeth was introduced into France about the year 1826 by M. Teveau, who called it "silver paste." This was composed of silver and mercury alone, and must have given very unsatisfactory results as compared with those secured in the use of our modern alloys.

Reception. The use of amalgam was given a most unwelcome reception by the profession at large, while the converts of the "new process" were equally emphatic in their praise of the new filling which "would certainly cheapen dentistry, and harm the profession." But time has proved amalgam to be a blessing to the poorer classes in that it brings dentistry within the reach of all purses and has thereby proved of advantage to the dental profession by broadening its field of usefulness.

While amalgam has many faults and should generally be avoided when finance will permit, the fact still remains that more teeth have been saved through its use than with any other filling material.

However the percentage of salvage is greater with gold, which forces amalgam to second place.

The Properties of Amalgam which render it of value as a filling material are: First, its plasticity eliminating access form in cavity preparation, making possible the building up of lost contours in inaccessible places in the mouth, where convenience and access forms are hard to secure, sufficient for the manipulation of gold either cohesive or as an inlay; second, its property of being but slightly affected by the oral fluids, and the fact that it is fairly stable as to bulk and shape; and last, but not least in the minds of many patients, we are sorry to say, is its cheapness, as most dentists see fit to build fillings of amalgam for a much smaller fee than gold.

The Objections to Amalgam are: Its tendency to discolor both as to its exposed surface and the teeth with which it has been filled due to slight leakage with old fillings; its comparatively large expansion and contraction range; its continued flow under load; its

poor edge strength; its spheroiding during setting, when not properly mixed from a perfect alloy. It is also liable to injury between the time of introduction and complete setting through carelessness of either dentist or patient.

The Extent of Expansion and Contraction of amalgam is not under the control of manipulation by the operator, but is controlled by the composition of the alloy both as to materials used and their proportions; as well as the method of their preparation.

The Flow of Amalgam under pressure is the term applied to the tendency of amalgams to flatten or move from under stress.

Most metals will yield or flatten under a given stress in proportion to the load, up to a given point, and then cease unless the weight is increased. However amalgam continues to yield as long as the pressure is continued even though it is not increased.

This peculiarity in amalgam explains the phenomenon often observed in the mouth. Amalgams differ as to the amount of force necessary to produce flow, yet the peculiarity is exhibited by all amalgams.

Edge Strength in a Filling is the term applied to the resistance a filling shows to stress upon thin margins at that portion of a filling which covers the marginal bevel.

Edge Strength in Amalgam. This depends first, upon the metals entering into the alloy. The greater the proportion of silver entering into the amalgam up to seventy-five per cent, the greater the edge strength. Above seventy-five per cent it becomes more brittle. Second, the manner of packing. Third, the amount of actual union between mercury and alloy. Fourth, bulk at margin.

The Maximum Strength will be obtained when the alloy contains just enough mercury so that the mass will take the impression of the skin markings after prolonged kneading between the thumb and forefinger. Any more or less weakens the edge strength.

The Length of Time the Alloy Stands has an effect upon edge strength, as amalgams made from alloys lose their edge strength progressively with time, the more rapidly the higher the average temperature.

However Aged Alloys Show Less Variations in Expansion, Contraction and Range, and artificial aging is resorted to for this reason and is done by annealing. This annealing produces an amalgam that shows more uniform and consistent properties.

Annealing of Amalgam is accomplished by subjecting the alloy when freshly cut to either a dry or moist heat ranging from 110° F.

to 212° F. for some hours or days. The lower temperature for a longer period produces the best results.

Effect of Annealing. The artificial aging increases the contraction, the flow, and the ability to withstand the crushing strain; the amalgam requires less mercury, and sets slower.

The Alloy Showing the Least Expansion and Contraction when unannealed is composed of seventy-two parts silver and twenty-eight parts tin and may be modified very slightly by adding a small per cent of copper or other metals. When annealed the above formula of silver tin alloy should be changed to seventy-six parts silver and twenty-four parts tin, to get a stable amalgam.

Cavity Preparation for Amalgam. Many of the failures in the use of amalgam attributed to the property of the material used are in fact due to laxity in cavity preparation, since many practitioners believe that thoroughness is unnecessary in this particular. The preparation of a cavity for the reception of amalgam is even more exacting than for gold, as the operator is dealing with a filling material possessed of a greater number of faults, each of which must be given consideration, and the cavity should be prepared in such a manner as to minimize these to the least degree. In comparing amalgam with gold it might be said that amalgam requires less access in awkward localities in the mouth, requires much separation in proximal fillings, and that the outline form must receive more careful consideration as the margins must be farther removed from positions of great liability to caries, as well as stress.

Flat Seats for Fillings are even more imperative than with gold, and the *occlusal step* must be broader bucco-lingually. The enamel walls must be finished with as great care, with a cavo-surface angle more acute, and a more deeply buried bevel angle. Cavities must have more retentive form.

The Rubber Dam is very essential as it is imperative that amalgam be built against dry, freshly cut, walls and margins. It is as impossible to make a good amalgam filling as it is a good gold filling against moist walls. The residue from the saliva upon the walls will show leakage more quickly with the amalgam filling than with the gold. When operators come to the full realization of this fact and manipulate all amalgam fillings with as great care as gold, with-reference to dry conditions, the frequent failures of amalgam will be materially lessened.

The Matrix. All cavities filled with amalgam must have continuous surrounding walls. This will necessitate the adjustment of the

matrix in cases where a wall is missing and applies to all Class Two cavities which reach the occlusal surface.

The matrix should be thoroughly wedged at the gingival, to prevent excess contour at this point, and to secure additional space that contact point may be made close. It should be made of steel as thin as one one-thousandth of an inch. It should be made to encircle the tooth firmly either by ligating or by a retaining appliance, several of which are on the market. When two proximal fillings are to be built at the same time and in the same proximal space, two matrices are necessary, one for each tooth involved.

However, better results are obtained, particularly with reference to proper contact restoration, by building up and finishing one filling first, and then building the other filling at a subsequent sitting. By using a specially prepared matrix band of the proper size for the second filling, with a hole cut in the matrix to allow the metal to protrude at the point of contact with the first made filling, an ideal result may be obtained.

Separation. Preliminary or immediate separation is just as essential in the use of amalgam as gold.

Making the Proper Proportions of Alloy and Mercury. Each operator should test his favorite alloys and determine the exact amount of mercury for a given quantity of alloy, and by the use of a pair of balances be able to always mix in exactly the same proportions. By this means the operator is able to produce the best product by having the amalgam at its best. By the uniformity he becomes familiar with the habits of that particular alloy.

This method need not be a time-loser, if the portions of alloy and mercury are previously put up in separate capsules ready for immediate use. In early practice this can be done by the dentist himself at leisure times and in after years by the assistant.

Making the Mix. Upon the thorough incorporation of the mercury with the alloy prior to placing in the cavity depends much of the good qualities of an amalgam filling. Poorly mixed alloys have little strength. Amalgamation in an amalgam filling is never entirely complete, and while this process is going on, there is a certain amount of molecular action, which tends to change the form of the filling as a whole. A very great per cent of this union may be induced before placing the filling by a thorough preliminary mixing and kneading of the mass.

To this end the alloy and mercury should be put into a wedgewood mortar and thoroughly ground together till the contents seem to have become one mass. It should then be removed to the palm

of the hand and made into a pellet and then transferred to the thumb finger grasp and rolled between the fingers with sufficient force to produce a decided squeaking noise, sometimes spoken of as the "cry of tin." Either too little or too much mercury will destroy this sound which should be sought. This kneading should be continued till the maximum plasticity has been secured, and the tendency to stiffen has just appeared.

Wringing Out Excess Mercury. All surplus mercury should be expressed as soon as detected. With small masses this is thoroughly and quickly done by grasping the mass between the ball of the thumb and the tip of the first or second finger. The flesh of the fingers should entirely cover the mass from view. Then by a rocking motion in which the mass is kept entirely covered the mercury will appear from between the fingers and not carry with it any appreciable amount of the alloy.

If the mass is too large to keep entirely covered during the process, it may be placed in a chamois skin and wrung to dryness, or divided into pieces sufficiently small to be manipulated with the fingers. As soon as the excess mercury has been expressed the whole mass should be again kneaded, as it should not be allowed to stand in this compressed condition. The mass should be rolled between the thumb and finger into a loose rope, broken into pieces, and laid in a position convenient to carry to the mouth. The rope or ball of amalgam should never be cut with instruments, as that part close to the instrument is compressed and rapid setting facilitated.

Amalgam Pluggers. The packing instruments should be as large as can be well used in the cavity, that the whole mass may receive the force of compression at each effort. The face of the plugger should be serrated to prevent slipping. A ball burnisher should not be used in packing amalgam, but is intended for finishing after the amalgam has set.

Making the Filling. The cavity should be in complete readiness to receive the amalgam immediately after it has been prepared. The size of the portions will depend upon the orifice of the cavity, and should be as large as can be easily crowded into the opening. This should be immediately compressed upon the seat of the cavity with as large a plugger as possible, with a rocking motion and as much weight as the circumstances will permit. When using a point that is much smaller than the cavity, the same wedging principle used in packing gold should be employed; that is, compress the central portion of the mass first and against the walls last. A burnisher should not be used; neither should the burnishing nor wiping motion be used,

but all compressing force should be directed at a right angle to the base wall.

Quite a body of excess should then be added to the occlusal portion and a plunger point applied with mallet force which should be augmented with hard hand pressure. The hand pressure and mallet force combined will produce a more dense filling than by any other method and at the same time crowd the yet movable particles of amalgam and alloy into closer adaptation to every portion of the cavity walls.

Trimming Amalgam Fillings. After packing the amalgam it should be allowed to set undisturbed for one or two minutes, when the excess may be cut away with suitable knives. Gum lancet No. 2 and the discoid and cleoid from the "University set" are serviceable, as are also the large spoon excavators.

Removal of Matrix. The matrix should then be removed in proximal cavities by drawing to the buccal while pressing the ball of the finger gently on the occlusal surface. A loosely rolled, rather large, ball of cotton should be laid on the amalgam filling under the finger tip, in order to prevent the matrix from traveling occlusally in the process of removal.

The rubber dam should then be removed and the patient instructed to *slowly* close the teeth, stopping the instant he feels the presence of the filling between the teeth, which will occur if excess contour has been built. With the teeth still held in this same position, the patient is requested to give the jaws a gentle side movement. This will result in burnishing the spots of contact, after which the excess should be whittled away with knife-edged instruments.

Amalgam Should Be Cut From the Margins to the filling, which is just the reverse from the travel of the instrument in cutting gold fillings. If the cutting instrument moves from the filling to the cavo-surface angle with amalgam that is only partially set, it is liable to sink too deeply into the substance of the filling and expose the margin as it crosses over.

Passing Contact Point. In proximal fillings of amalgam nothing of any description should ever be allowed to pass the contact point until the amalgam has completed the process of setting, as one such attempt forever destroys proper contact and a filling so treated becomes at once a makeshift. All overhanging amalgam should be cut away, around the entire cavity outline, but the region of contact point should be entirely neglected at this time, and left for final shaping during the process of polishing. Finally the filling should be gently wiped with punk or cotton.

Polishing. All amalgam fillings should receive as thorough and careful polishing as gold. This must be done at a subsequent sitting. In proximal fillings the separator should be adjusted and the contact point properly formed and polished.

For this work abrasives of only the finest nature should be employed. Burs, carborundum stones, coarse strips and disks only do harm and prolong the operation. Fine strips, disks, wood points and leather wheels, using first pumice then whiting, and lastly the tooth polishing rubber cups should be used.

CHAPTER XXIV.

THE USE OF CEMENTS IN FILLING TEETH.

Varieties. There are five main varieties of cement available for use in the operation of filling teeth; silicate, cement, oxyphosphate of zinc, oxychloride of zinc, sulphate of zinc, and oxyphosphate of copper.

Cavity Preparation for cement when the entire filling is to be of cement is not unlike that for any other filling, except that the cavo-surface angle is left the same as that produced by the cleavage of the enamel, omitting the marginal bevel. The cavity should be given the usual retention form, and the matrix must be employed in cavities to supply the missing wall that the cement may be introduced with pressure to condense and create close adaptation to walls.

The rules given for dryness in the manipulation of gold and amalgam are also to be observed in cement filling.

The silicate cements have been evolved in an effort to produce a cement that would more nearly harmonize with the color of the teeth; to better withstand the action of the oral fluids and the abrading effects of mastication. Berylite is a prominent illustration of a silicate cement. Some of the silicates are now used as independent fillings and are not suitable for use as a cement. This material as a silicate filling is given full consideration in Chapter XXV.

Oxyphosphate of Zinc has many uses in the cavities of teeth as a partial filling and in some instances for the complete filling. Being a poor conductor, it makes an excellent agent as an intermediate between metal fillings and closely approached pulps.

Its adhesive quality gives it great value as a means of adding retention to all kinds of metal fillings. This quality together with its harmonious color with tooth substance makes it invaluable for lining weakened enamel walls which have lost much of their supporting dentine.

Its Chief Fault is its tendency to dissolve in the fluids of the mouth, which renders it comparatively temporary. However there is a considerable variation in its behavior in different mouths; in some instances it wears for years.

Oxychloride of Zinc is indicated in pulpless teeth to fill the pulp chamber, after the canals have been previously filled with gutta-percha, and for the lining of cavities for the preservation of color where adhesiveness is not of importance. It is not indicated in

teeth with closely approached vital pulp, or as a root filling, on account of its irritating properties.

Sulphate of Zinc, when pure, is the least irritating of all cements and is one of the best materials for pulp protection. A pulp capping of this material is of most universal application.

Oxyphosphate of Copper is especially indicated in remote cavities on the necks of teeth occasioned by gum recession. Cavities which are so ill-defined that the use of amalgam or gutta-percha is difficult, may be successfully filled with this preparation of copper.

It can be made to adhere very tenaciously to the walls of a cavity, thus obviating much cutting. Oxyphosphate of copper is also indicated in the small cavities in the deciduous teeth.

It is claimed that this material exerts a therapeutic influence upon the tooth substance, thus preventing further decay.

Manipulation of Oxyphosphate of Zinc Cement. The method of mixing this cement is not in the least difficult, yet certain details are essential. The slab, preferably of smooth glass, should be clean. The spatula should be flat with the side slightly convex.

Agate is the best material as it is not acted upon by the liquid. The liquid and powder should be placed upon the slab separately, the drop of liquid being carried there by the use of a small glass rod. The spatula should never be immersed in the bottle to obtain more fluid as this would destroy the efficiency of the liquid. Crystallized portions should be carefully wiped off the mouth of the bottle as soon as detected.

Plan of Spatulating. The powder should be added to the liquid a little at a time and each portion thoroughly rubbed by a swinging circular movement of the spatula upon the slab. This rubbing should not be rapid or vigorous. For lining cavities, where thin layers are desired which are very adhesive, the cement will prove correctly mixed when it shows slight stringiness and when the first stickiness appears, as shown by the slight resistance offered the spatula in its movement over the slab. Where the entire filling is to be of cement, more powder should be added and the spatulation continued till the cement materially resists spatulation and the mass is the consistency of freshly made putty. When cement is of the consistency desired no time should be lost in placing it in position, and it should be allowed to harden undisturbed. If the cement is to form the entire filling and permanency is desired, it should be crowded to place with some force and rapidly shaped up. As soon as crystallization begins it should not be disturbed by manipulation till it has fully hardened, when it should be polished with fine strips and disks.

CHAPTER XXV.

MANIPULATION OF SILICATE IN THE MAKING OF A FILLING.

Definition. *Materials for Silicate Fillings* are marketed under trade names which no doubt suit the purposes of the various manufacturers, and there can be no just criticism offered from the standpoint of the tradesman. However some confusion exists among the members of the dental profession as to the correct term to use which is broad enough to cover all of this class of fillings and not designate any special make. We will therefore consider some definitions from Webster's "Unabridged Dictionary."

Silicate (a noun) "is a salt composed of silicic acid and a base." Silicate from which we make fillings is made by silicization.

Silicization (a noun) "is the process of combining with silica, so as to change to a silicate," which is, chemically speaking, a synthetic process,—“the uniting of elements to form a compound.”

Porcelain (a noun). "A fine translucent kind of earthenware," named after the shell "Porecellana" "either on account of its smoothness and whiteness, or because it was believed to be made from it."

Cement (a noun) when used as a noun is, "Any substance used for making bodies adhere to each other, as mortar, glue, etc."

Cement (a transitive verb). "To unite by the application of a substance which causes bodies to adhere together."

Cement (an intransitive verb). "To unite or become solid; to unite and cohere."

Cementation (a noun). "The act of uniting by a suitable substance." Chemical definition: "A process which consists in surrounding a solid body with the powder of other substances, and heating the whole to a degree not sufficient to cause fusion, the physical properties of the body being changed by chemical combination with the powder; thus iron becomes steel by cementation with charcoal and green glass porcelain, by cementation with sand."

Enamel (a noun). "A substance of the nature of glass, but more fusible and nearly opaque,—with a variety of colors; also other materials used for giving a highly polished ornamental surface." Anatomical definition: "The smooth, hard substance which covers the crown or visible part of a tooth, overlying the dentine."

From the foregoing references to Webster it would seem that the term "silicate filling" is correct when used to name this kind of

filling material as a class and when used to restore lost tooth substance.

The use of the word "cement" as a part of the name, hence a noun, is incorrect unless the substance is used to "make bodies adhere together" and should be eliminated from the names of the silicates and other compounds intended for a filling *per se*, except when adhesive properties are taken advantage of.

The term "synthetic" is correctly used when applied to any of the plastics now in use in dentistry, with a possible exception in amalgam, as chemists are divided in their opinions as to exactly what takes place in amalgamation. The use of the word "Porcelain" as a part of the name, its being correct or incorrect, depends entirely

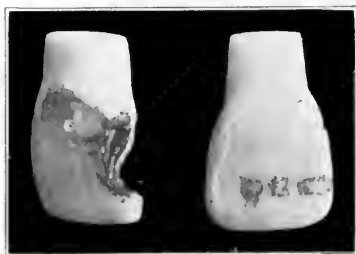


Fig. 79.

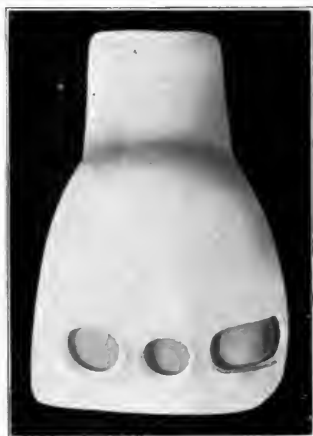

Fig. 80.

Fig. 79.—Suitable cavities for the use of silicate fillings.

Fig. 80.—A Class One cavity on the labial of a central incisor properly prepared for a silicate filling. The decays are shown in Fig. 79.

upon our understanding of the degree of heat necessary to bring about cementation. (See definition.) This is accomplished at comparatively low and ordinary temperatures with most of the makes. All are assisted in the process by temperatures slightly above that of the body, with one maker advising the melted paraffine bath during the period of setting. The use of the term "Enamel" is correct provided it is a "substance of the nature of glass, more fusible, nearly opaque, used for giving a polished ornamental surface," and the prefix of "Artificial" provided it is "a substitute" for the natural covering of a tooth's crown. It would seem that the silicates are all synthetic, that they all partake of the nature of porcelain,

that they are a trade enamel, that they are artificial when replacing the lost enamel of human teeth, that they are cement when used to hold a filling of other material in the tooth or when the material itself adheres to the tooth, and that they are not cement (a noun) when used as a filling *per se*.

The author therefore takes the position that the filling material under consideration is "silicate" as the correct manipulation of most makes eliminates adhesion to the cavity. Those which adhere to the cavity or will retain fillings of other materials in the cavity are for that reason a silicate cement. It therefore follows that with the use of silicate there must be retentive form in cavity preparation. At

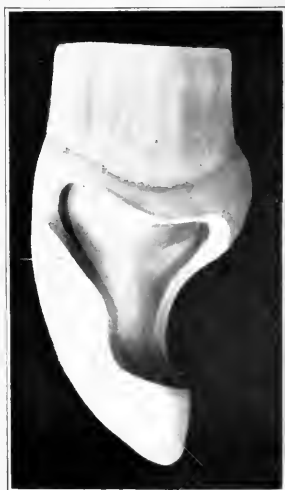

Fig. 81.

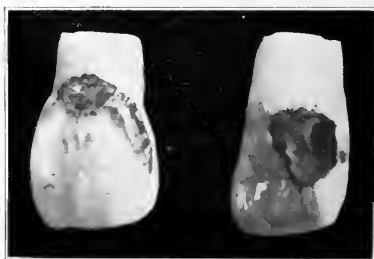


Fig. 82.

Fig. 81.—Extensive Class Three cavity properly prepared for a silicate filling. Decay shown in Fig. 79.

Fig. 82.—A Class Five and a Class Three cavity suitable for the use of silicate as a filling.

this time we find the best illustrations of this class of silicate in "De Trey's Synthetic Porcelain" and Aseher's "Artificial Enamel," neither of which should be used as a cement.

Cavity Preparation is quite similar to that for an amalgam filling and is here considered in the order of cavity procedure.

Gaining Access. The access required for the silicate filling is the same as that for any other plastic filling, as far as its introduction is considered and the conditions sought at the time the filling is completed. Contact point in Classes Two, Three and Four is just as essential, but is harder to maintain due to interproximal wear. It

would therefore follow that the primary contact should be greater and broader. In other words, if we are to use the marble contact it should be the contacting of larger marbles than in the more durable metal fillings. To put it in other words, the convexity of the filling's surface should be the segment of a larger circle than the metal filling. Proper separation is essential.

Outline Form. In the consideration of outline form, the same rules should apply as when using any other filling. We should extend cavity margins until all surface decay has been included. With other filling materials, we sometimes falter in this because of the unsightly results, but with silicate, when the color has been properly chosen, there should be no hesitancy, as large fillings are generally

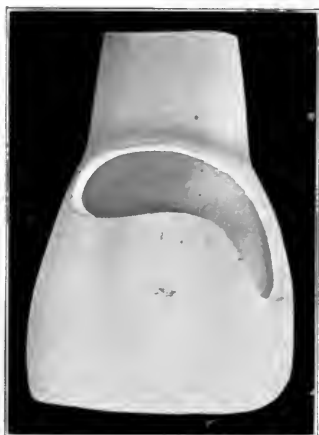

Fig. 83.

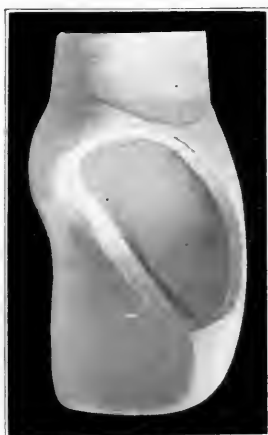

Fig. 84.

Fig. 83.—A Class Five cavity properly prepared for a silicate filling. The decay is shown in Fig. 82.

Fig. 84.—A Class Three cavity, lingual approach, properly prepared for a silicate filling. The decay is shown in Fig. 82.

as little observed as small ones, especially on flat labial and buccal surfaces. When fissures and sulcate grooves are encountered, they should always be included in the outline, as a leaky filling will result at the triangular space formed where the sulcate grooves meet the filling.

Resistance Form. In dealing with resistance to the crushing strain, we have a greater problem to solve than in the use of almost any other material. The edge of the filling is more easily broken, and after some months or years of wear there is great danger of exposure of the cavo-surface angle. It is therefore necessary to lay

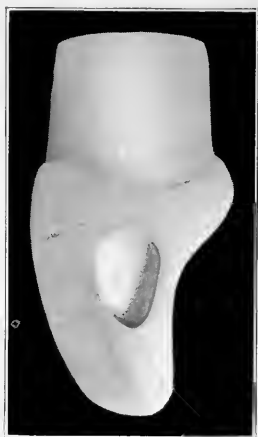

Fig. 85.

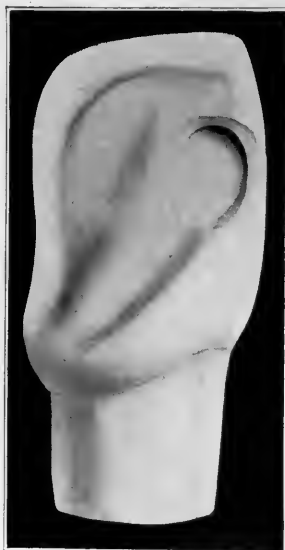

Fig. 86.

Fig. 85.—A small Class Three cavity, labial approach, properly prepared for a silicate filling.

Fig. 86.—A small Class Three cavity, lingual approach, properly prepared for a silicate filling.

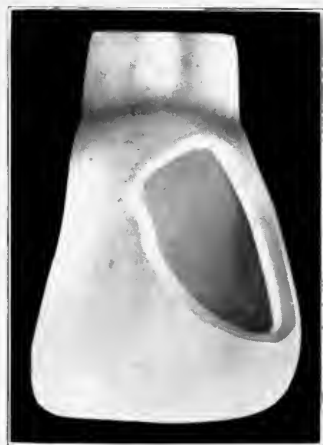

Fig. 87.

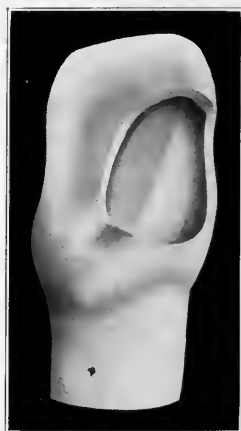

Fig. 88.

Fig. 87.—A large Class Three cavity, labial approach, properly prepared for a silicate filling. Note the irregular outline on the labial. This is not objectionable, for many times an irregular outline hides a slight deviation from the proper color.

Fig. 88.—A large Class Three cavity, lingual approach, properly prepared for a silicate filling. Note the fact that this cavity has two axial walls. This is a good form of preparation in vital cases.

the cavity outline in areas subject to as little stress as possible. In locations subject to great liability to stress, it is necessary to extend the outline until full-length enamel rods, supported by sound dentine, have been reached and then beyond that to a location not subject to the travel of the cusps of opposing teeth in the process of articulation. It is not necessary to pay much attention to developmental grooves, for when these grooves are normally formed they are fully as strong as the material in hand. It is most important that all enamel eminences be avoided, as the material is quite friable and offers very little support to the cavo-surface angle.

Retention Form. Provision against the tipping strain is the same as for other fillings and is more like that for amalgam. This

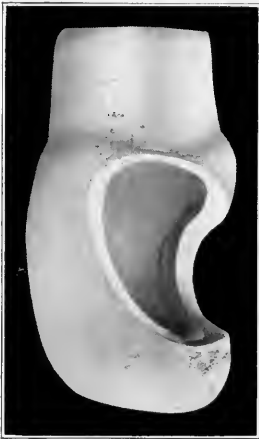


Fig. 89.

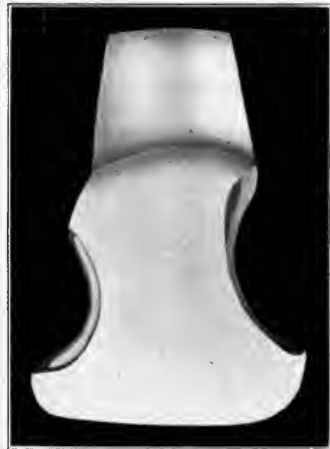

Fig. 90.

Fig. 89.—A large Class Three cavity properly prepared for a silicate filling. Note the small amount of dentine yet remaining near the incisal angle. While this angle can properly remain when using a silicate filling, it would be entirely out of the question when using cohesive gold.

Fig. 90.—Two extensive Class Three cavities properly prepared for silicate fillings. In both of these cavities the dentine has been practically all removed at the incisal angles. Cases like these may be filled with silicate but should be regarded as temporary in a large majority of the cases. The retention of these angles after filling will depend entirely upon the amount of force to which they were subjected. They would be comparatively permanent in cases of irregularity when that condition placed these angles in a position removed from stress in occlusion and articulation.

material only reaches its maximum strength to resist dissolution and the crushing strain when it has been so thickly mixed that it has lost practically all of its adhesive qualities. Therefore, the rules which apply to cavity preparation in reference to retention form would be the same as in the use of amalgam. We must have flat walls excepting the axial, flat seats of generous proportions and definite angles.

Convenience Form. This step in cavity preparation for the silicate filling, as with other plastics, comes in for only a minimum consideration, as it is seldom necessary in the use of this material to make any changes to facilitate the making of the filling, for when other rules have been followed we find ample convenience for its introduction.

Removal of Remaining Decay. There is one major reason why all softened dentine should be removed from the cavity walls. The decalcified portion of tooth substance is always saturated with the acid of tooth decay,—lactic acid. Experience has proved that the crystallizing silicate will absorb this acid, resulting in a filling of weak structure. It would therefore follow that no softened dentine be allowed to remain in the cavity.

Finishing of Enamel Walls. With other fillings it has been found




Fig. 91.—A small set of instruments for manipulating silicate.

advisable to bevel the enamel margins from 6 to 10 degrees centigrade. With all silicate fillings, this beveling seems to make an additional weakness and should be avoided as it will cause the filling to break at the margin, even though the procedure results in an imperfect cavity, from a scientific standpoint. We should determine that we have full-length rods and that we have found their direction by complete cleavage and then omit the beveling.

Toilet of the Cavity. To the ordinary toilet given for other fillings should be added the varnishing of the dentine walls, as a precaution against the material absorbing either acid or moisture from the walls or the absorption by drying dentinal walls of the fluid part of the filling, due to excessively desiccated dentine.

Rubber Dam. The application of the rubber dam, or other means equally as efficient, should have taken place following partial outline

form. Prior to adjusting the rubber dam, the color or combination of colors should have been selected, as the opinion formed after the rubber dam has been in place for a short time is worthless as a guide to the proper shade to be used. During the early experience with this material, with each operator, the shade guide should be frequently used as an educator, but in a few months, the operator should begin to be so familiar with the resulting colors that no shade guide is necessary.

Making the Filling. When cavity preparation is completed, the proper material and instruments for making the filling should be




Fig. 92.—A suitable slab and spatula for working silicate. The slab should be thick and heavy in order that when chilled it will remain at a low temperature during the mixing of the silicate.

placed in a handy position. Absolute cleanliness is imperative, particularly during the process of mixing, as otherwise the filling when completed will not be chemically pure. The mixing slab should always be kept scrupulously clean, should not have a scratched surface and should be without color. This last point is to avoid any effect color could have on the judgment as to the shade desired. A good slab is produced by taking a large-mouthed bottle and filling it with cold water, or even ice water, in order that during manipulation the material may be held at a low temperature. Before using a thick glass slab (Fig. 92) chill to a temperature of 60 degrees or a little below. The temperature feature in this manipulation is of importance. With nearly all of the processes in the filling of teeth wherein the dentist depends upon subsequent chemical action for

a final result, chemical action should be either retarded or held in check during the entire process of manipulation, which is easily accomplished by a low temperature mix. "The process of set-




Fig. 93.—Proper position of the spatula on the slab when manipulating silicate.




Fig. 94.—Proper placing of the materials when manipulating silicate.

ting" as it is called is held in check until the material is finally in place and further disturbance unnecessary. As soon as the filling has been placed in the tooth, the warmth of the body is sufficient

to hasten the chemical action and better results will be secured. With most of the silicate fillings, the body temperature is sufficient; with others the best result can only be obtained by keeping



Fig. 95.—Taking the first portion of the powder which should be about half of the entire amount needed.




Fig. 96.—Incorporating the first portion of the powder.

the filling for a short time bathed in melted paraffine. The mixing slab should be at as low a temperature as possible and should not produce discomfort to the patient. A temperature of 60 degrees

seems to be as low as can be borne by the patient when placing a filling in a vital tooth. It is therefore quite practical to use a bottle slab wherein the thermometer reaches 55 to 60 degrees, as no doubt the temperature of the filling is about 68 when placed in the tooth. It is quite possible to use a bottle that contains iced water when the filling is to be placed in a non-vital tooth. At such times when the atmosphere is close to the dew point, as is evidenced by the condensation on the fountain cuspitor, there will be trouble about the formation of moisture on the cold bottle. When this is only slight, it does not seem to damage the filling. However, when the condensation is sufficient to be noticed, or is excessive, the dentist has to either content himself with manipulation at a higher temperature or postpone the operation to a time when the atmosphere is above the dew point. The spatula must be of some material which will give off none of its substance during the process of mixing. For this reason the agate is the best and most popular.

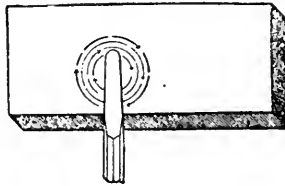


Fig. 97.—Illustrating the circular motion which should be given the spatula in mixing a silicate filling. Note that the spatula should be moved first in one direction and then in the other as indicated by the arrows. Also that the spatula describes segments of small circles and that the material is not spread over any considerable surface of the slab.

Begin the mixing only when the cavity is prepared and dried, and the filling instruments are laid out and ready for immediate use. While there is no great haste as long as the material lays on the cold slab, there are left but a few seconds to make the filling after the material has been removed from the slab, on account of the rising temperature hastening chemical action.

Preparing Materials. First pour out near the end of the slab to the right, the amount of powder the mix is liable to require, and then place stopper in the bottle. With the dropper place the proper quantity of liquid near and to the left of the powder. Immediately return the dropper to the bottle and secure the cap to prevent evaporation. The best results are obtained when no less than three drops of liquid are used for the mix. Do not shake the liquid bottle. Make the mix promptly, for if there is any considerable delay, the chemical formula of the liquid may be changed, due

to an evaporation in a dry atmosphere or the addition of water in taking up the condensation from the cold slab at low barometer.

Making the Mix. Begin with sufficient liquid on the slab and do not add any more at that stage. Mix by drawing into the liquid about one-half of the total amount of powder required to make the completed filling. Begin the mix by spatulating with a light rotating movement; hold the spatula flat on the slab, describing the arc of a small circle with a diameter of say one-fourth of an inch. As soon as the powder has been all incorporated and the mass rendered uniform, scrape all of the mass off the slab with about three strokes. Take one-third of the mix each time. This assists in securing uniformity of the mass. Then put it back on the slab this




Fig. 98.—The last stroke of scraping the material from the slab.

time getting all off the spatula. Do not scrape the spatula on the edge of the slab, but place it flat on the slab, holding it firmly and giving it a turn in the hand, which will practically clean it. Here more powder is added, a small portion at a time, and incorporated in the mass already mixed, by the method of crowding, which is done by rolling the spatula first against one side of the mass on the slab and then against the other. The addition of the powder by this crowding process is continued until the mass becomes of a consistency of putty, losing practically all of its adhesion and giving only slight evidence of a tendency to follow the spatula from the slab.

The Proper Consistency is reached when the mass has been mixed

so stiff that the material just loses its gloss when being crowded by a rotating spatula, yet can be made to show a glossy surface when patted three or four blows with the spatula. In case the material looks very wet and glossy the mix is not yet stiff enough. If the three or four blows do not produce gloss, the mix is too heavy and must be entirely discarded.

Time of the Mix. The lower the temperature at which the silicate is mixed the longer may be the time of manipulation; also the thinner the mix, the longer will it be before the chemical action of the setting will be noticed. By using the cold process of mixing, the time of manipulation is lengthened and the time of set-

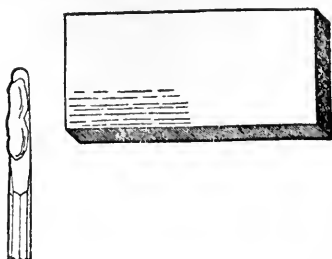


Fig. 99.—The entire mix on the spatula.



Fig. 100.—Illustrating in three successive steps the method of removing the mix from the spatula to the slab.

ting after leaving the slab is materially shortened, due to the thick mixture obtainable.

Making the Filling. It is important that all moisture be excluded, as we cannot manipulate silicate under moist conditions. Agate or ivory instruments are preferred for placing the material in the cavity. Those of bone or shell will do. If the instruments are absolutely clean and polished so that they will give off no substance in the material, it is possible to place the silicate in the cavity with steel instruments and get no subsequent discoloration. Fill the cavity slightly to excess with absolutely clean instruments by taking a quantity, one-half of that required to fill the cavity, and crowd or wipe the material against every portion of the cavity walls from cavo-surface angle to cavo-surface angle. The second time, take up a sufficient quantity to more than fill the cavity.

Crowd this into position and hastily get a partial contour. Immediately pat or paddle the material to complete contour, continuing until the material has been crowded slightly over the margins. This paddling force will jar the material so as to bring back the gloss, as produced by patting on the slab. In case the gloss is not produced by the paddling, a homogeneous mass is not secured and the fill-




Fig. 101.—Proper consistency of silicate, for immediate introduction into the cavity.




Fig. 102.—This mix of silicate is yet too thin and there should be more powder added. The material should show a tendency to follow the spatula when moved from the slab but it should not follow the spatula as here shown.

ing will lack proper color, will be of poor edge strength, and will make a very weak filling. If the gloss has been produced by the paddling or jarring of the material, it should be allowed to remain undisturbed until the process of setting has sufficiently taken place that the body of the filling will not be moved by any work upon its surface.

The Use of the Matrix either upon the posterior or anterior teeth should be the same as that for the introduction of the amalgam filling. With Class Three fillings, one end of the matrix is left loose until the cavity has been filled more than full with the material. The loose end is then brought over the tooth and tapped on the outside of the surface as it is being tightened upon the filling. This jarring process of bringing the matrix to position results in a homogeneous mass beneath the matrix. Immediately after paddling the filling and the detection of the glossy surface, the filling is to be entirely coated with cocoa butter to exclude the air during the process of setting.

Finishing the Filling. After the filling has been allowed to stand undisturbed for three or four minutes (no longer), there should be applied a very thin-edged knife or chisel and by a scraping motion

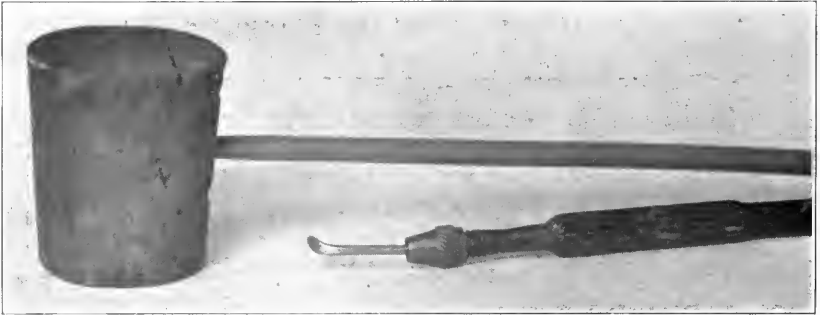


Fig. 103.—A homemade mallet and point used by the author in paddling and jarring silicate to position in the cavity. The mallet should be of light weight and have a soft surface. The plugger point here shown is made of platinized gold. Tandilum would be better for this provided it had a handle attached which was of very light material. It is quite necessary in this process that both hammer and plugger point are of the least possible weight.

parallel with the cavity outline the excess is cut away to within one-tenth of a millimeter of the cavo-surface angle, at the same time reducing the general contour to that desired, keeping the filling submerged in the cocoa butter. When the filling has been in position five or six minutes, very fine strips or disks coated with cocoa butter may be used to produce the desired gloss. The author prefers to leave the filling with file and knife finish and has abandoned the use of strips and discs as injurious. This completed filling should be scrubbed with cotton balls in order to remove all of the cocoa butter possible and the finished filling painted with a copal-ether varnish. No varnish of which alcohol is a part should be used. Evaporate to dryness with air, remove the rubber dam and test for occlusion and articulation, provided the filling in-

volves the occlusal or incisal surfaces. In case the filling is found to strike the apposing teeth, the excess should be ground off with fine carborundum wheels, and again varnished. It is entirely safe to use carbon paper to print these fillings, the same as with gold or amalgam and its use will not cause discoloration of the filling. The instruments used in reducing the size of silicate fillings should be the same as when reducing the bulk of a gold filling. The manufacturers of some of the silicates advise not to use any steel

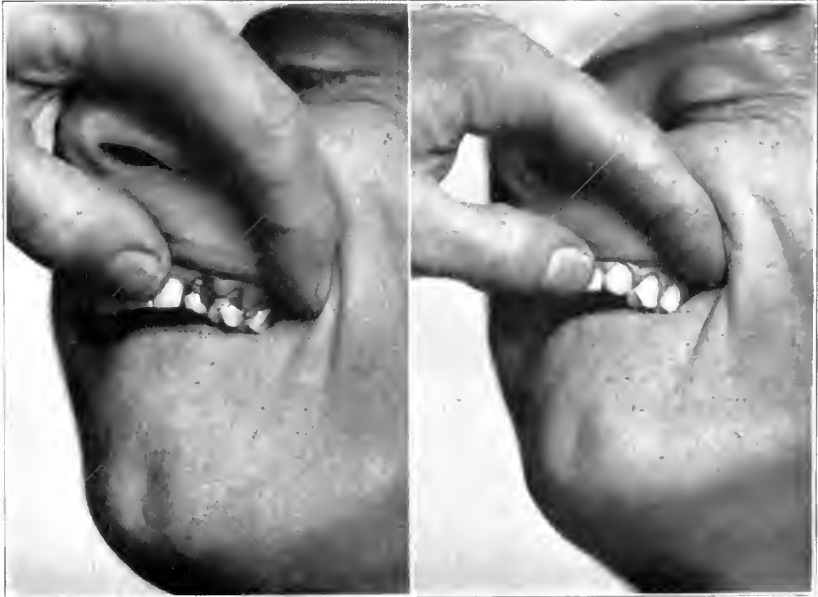

Fig. 104.

Fig. 105.

Fig. 104.—Three cavities suitable for silicate fillings.

Fig. 105.—This shows the results obtained after filling with silicate the cavities shown in previous figure.

instruments in the finishing of these fillings, but clinical experience has proved that any injury which can result is not due to the instruments, but to their unclean condition.

Facing Metal Fillings with silicate is many times of advantage and is at this time the only method wherein it is advisable to use silicate in connection with angle restoration in Class Four fillings. This will be more fully discussed in Chapter XXVIII dealing with Combination Fillings. (See Figs. 106, 107 and 108.)

CHAPTER XXVI.

THE USE OF GUTTA-PERCHA IN FILLING TEETH.

Gutta-Percha has its place in various operations upon the teeth. It is not acted upon by the fluids of the mouth and is quite permanent when placed in locations protected from the force of mastication.

It is a good tooth preserver as decay does not readily take place in cavities so filled.

Base Plate Gutta-Percha is the best form to be had. It comes in the white and pink colors, the last named being the most durable in positions exposed to wear as it gets the harder upon cooling.

Filling Cavities with Gutta-Percha. This material is indicated in subgingival cavities, both buccal and proximal, where a filling that is a very poor conductor of heat is desired, on account of close proximity to the pulp, the pulp being not yet exposed.

It is also indicated for those distressing cases where there is a decay started in the occlusal surface of a lower third molar which has erupted with its occlusal surface at an angle of about forty-five degrees to the distal of the second molar. Such cases cannot as a rule be properly extended to check decay in the use of amalgam or gold.

The gutta-percha filling will check decay and if renewed at stated periods will produce sufficient separation for correct filling or to render extraction easy.

Method of Preparation and Filling. The cavity should be freed of all decay and the cleavage of the enamel secured, omitting the marginal bevel. The cavity should be sterilized and dried, then slightly moistened with campho-phenique or eucalyptol. The gutta-percha should then be warmed and immediately crowded to position. Care should be taken that the material is not overheated as slight burning destroys the durability of rubber.

The gutta-percha should be introduced piece by piece sufficient to a little more than fill the cavity. The surplus must be wiped off flush with the cavity margins with warmed burnishers. Finally the surface should be wiped with a cotton ball carrying chloroform.

For Root Canal Fillings. The gutta-percha is dissolved in chloroform to the consistency of molasses, and carried to the canals by

dipping a smooth broach in the container. The canals should have been previously flooded with oil of eucalyptol, and the chloro-percha mixed with the eucalyptol in the root canal resulting in what may be termed eueo-percha. The eucalyptol may be added to the chloro-percha in the bottle, but the method given first is for various reasons the better.

For Canal Points. Gutta-percha is the standard material for canal points which should be at hand in various sizes to suit all cases.

These may be manufactured by the dentist, but with little economy, as they are well made by machinery. Those which are flattened on the larger end are the most handy to use. Such may be had from your dealer, or the assistant can flatten them as purchased by placing them on a glass mixing slab and pressing each large end with a smooth cold steel instrument.

Slow Separation. Gutta-percha for slow separation in proximo-occlusal cavities is unexcelled, the force of mastication doing the work slowly but surely. This fact prohibits the use of gutta-percha as a permanent filling in Class Two cavities.

Temporary Stopping, as purchased from the dealer, is gutta-percha to which wax has been added to render it more plastic when warmed. This is ideal for sealing in dressings, excepting when arsenic has been used, in which case poorly mixed amalgam is better.

CHAPTER XXVII.

TIN AS A FILLING MATERIAL

History. The first use of tin as a material for filling teeth would seem to date back to about 1780 and was much written about as a tooth preserver for the century following. After the introduction of amalgam in 1826 there seemed to have been much rivalry between the two substances, amalgam gaining the favored position.

At the World's Columbian Dental Congress, in Chicago, 1893, as will be seen by the report, many dentists of national repute went on record as classifying tin as one of our best tooth savers and deplored the fact that its value was being lost sight of.

The late Dr. W. C. Barrett expressed himself so emphatically as to say, "Tin is as cohesive as gold, and if everything were blotted out of existence with which teeth could be filled, except tin, more teeth would be saved." This may be putting it a little too strongly, but the fact remains that more teeth would be permanently saved if a more general use of tin was common with the profession today.

Therapeutic Value of a Tin Filling. Of all our filling materials there are only two for which any therapeutic value is claimed. All others prevent the farther loss of tooth substance by exclusion: mechanically shielding the defenseless tooth substance from the dissolving properties of the products of fermentation.

The Therapeutic Action of Tin is probably due to the formation of the sulfid of tin which is caused by the presence of sulfuretted hydrogen from the decomposition of food substance. The dentinal walls of a cavity which has been filled with tin for some time, turn brown or black and seem to have undergone a structural change rendering them quite impervious to decay, and very hard to excavate with hand instruments or the engine bur.

Discoloration. In some mouths tin turns black not only upon its external surface but this color is in a measure transmitted to the tooth substance, a fact which is one of the greatest objections to its use and debars it from exposed positions in the anterior portion of the mouth. In other mouths there seems to be little discoloration, the filling remaining polished and of a light color.

The Amount of Discoloration seems to bear no relation to its permanency as to bulk or as a tooth preserver.

Thermal Conductivity. Tin is only one-fourth as good a con-

ductor of heat as gold, hence, indicated under gold fillings in deep-seated caries with vital pulp.

Indicated in Rapid Caries. In caries of a light or white color indicating the most rapid form of decay, tin is of peculiar advantage, particularly in regions removed from view and protected from the wear of mastication.

Tin in the Teeth of Children. There is no better material for filling the teeth of children than tin. The principle of mechanical exclusion depended upon with other filling materials to prevent recurrent decay does not seem to be sufficient in the rapid form of decay met with in both temporary and permanent teeth in the mouths of children particularly during the age of rapid development as found before the age of fifteen or sixteen. The additional advantage of the therapeutic influences of tin seems to be sufficient to check this rapid progress of decay till a period is reached when the process of tooth destruction is less apparent, due to more hygienic conditions in the oral cavity.

Cavity Preparation for Tin. The cavity preparation for the use of tin is not unlike that given in the chapters on cavity preparation by classes for cohesive gold. It will be of advantage if the convenience angles are a little more distinct, and the general retentive form throughout should be emphasized. The bevel angle should be a little more deeply buried as the edge strength is not as good as hammered gold. However the edge strength is better than amalgam. Tin has no tendency to spheroid like amalgam. Its flow is similar to that of gold but greater with the same given load and like gold it is capable of being so condensed that it will stand repeated stress of a given load within a limited range and show no flow.

Forms of Tin. Formerly the only form of tin to be had for this purpose was the sheet tin. This was manipulated in much the same way as cohesive gold except that it required no annealing.

It was then, and is yet, sometimes combined with gold by rolling a sheet of pure tin with a sheet of annealed cohesive gold into rolls, the gold on the outside and condensed in the usual manner using a large proportion of hand pressure.

At present there is on the market a form of tin prepared in the shreds, which appears like a mass of coarse silver-colored hair. This is removed from the tube and shaped into pellets of suitable size and placed in the cavity in the manner one would place pellets of gold.

Methods of Introduction. The rubber dam or other efficient

means of dryness must be used. When one of the surrounding walls is missing as in proximo-occlusal cavities in bicuspid and molars (Class Two) the matrix must be in place. The first pellet of tin introduced should completely cover the base of cavity and be thoroughly condensed by good steady hand pressure, with points at least one square millimeter in size employing the rocking motion. The points should have deep serrations and be so stepped as to include the entire surface.

This hand pressure should be followed with the mallet force using a plugger point of medium serrations and the surface entirely gone over. A new pellet may now be applied and the plan just given repeated. If the filling is to be entirely of tin the cavity should be filled to excess and by a process of burnishing, condensed and rubbed to the size desired. This last method gives a surface of the greatest density possible.

Tin and Gold. When the filling is to be completed with cohesive gold little dependence should be put upon the gold adhering to the tin as the union is only slight. With a round-pointed instrument new convenience angles should be made in the substance of the tin near the line angles. The remainder of the cavity should be retentive independent of the space occupied by the tin.

Tin and Amalgam. No special care is needed when the filling is to be completed with amalgam. Amalgamation takes place in that portion of the tin next to the amalgam proper and the union is quite strong, even more than tin to tin. The amalgam should, if possible, be more thoroughly mixed and the process of kneading prolonged that all amalgamation possible be secured before contacting with the tin as the tin will take up some of the mercury from the amalgam for which it has a great affinity. This is liable to injure the amalgam as to strength unless the mixing has been thorough. The use of tin and amalgam is not advised where the surface of the tin is to be exposed by forming any portion of the contour as the presence of the mercury absorbed causes the tin to rapidly disintegrate. Gold should be used for topping in such cases.

Tin in Bifurcated and Punctured Roots. When through decay or by accident the cavity extends to the exposure of the peridental membrane the use of tin has no substitute. The opening should be rendered as clean as possible, sterilized and dried. The opening should be covered with a mat of pure tin made from folded sheets, being lightly burnished to place and covered with amalgam and the cavity finished with the desired material.

CHAPTER XXVIII.

COMBINATION FILLINGS

Definition. A combination filling is a filling composed of two or more distinct substances introduced into the cavity separately.

Objects of a Combination. The object of combining various materials in the filling of a tooth's cavity is to secure a perfect filling, one possessed of all virtues, and no faults. Many such combinations of material meet this demand in a large measure by bringing into service the strong features of each material, and at the same time nullifying the faults of all material entering into the construction.

Since dentistry has been raised to the dignity of a science there has been a diligent search to discover a filling material which possesses the virtues of all and the faults of none in present use. At the present time this is more nearly reached by the various combinations possible with the usual distinct materials. If perchance the ideal filling is ever produced, dentistry will at once become much simplified as to methods of procedure.

Single Materials Used as a Filling. There are only two filling materials now in use which are used in their pure state, pure gold and pure tin, and there are many instances where these combined with each other or with other materials, will produce better results than when used alone.

Gold and Tin Combination. This combination is of service in large cavities of Class Two which are subgingival and in large occlusal cavities in molars, where the pulpal wall is deep and rounded. In this combination the tin should be placed in the cavity first and thoroughly condensed, and the filling completed with cohesive gold.

In Class Two the tin should cover the gingival wall at least one millimeter deep and be condensed to place with the matrix in position.

Benefits derived. Dentine upon which has been built a thoroughly condensed tin filling does not readily decay. By completing the filling with gold the discoloration of tooth substance is avoided and the gold will better resist the force of mastication.

Gold and Cement. The object of this combination is to produce a filling that is adhesive, will protect weak walls, and resist the fluids of the mouth and the force of mastication.

Two Methods of Combining. There are two methods of producing this combination. One is to cast the filling and lay it into the cement-covered cavity, which is the inlay method. The other is to build cohesive gold into a thin mix of soft cement with which the walls of the cavity have been coated. The essential feature of both is that the cement be completely covered to protect it from dissolution by external agencies, as the fluids of the mouth and the effects of wear.

When Indicated. The inlay combination is indicated in large cavities of easy access. The built-in method of combination is indicated in small cavities of more difficult access, and where correct cavity formation is impossible or ill-advised. When using this method convenience angles may be omitted.

Gold and Platinum. This combination adds to the many virtues of cohesive gold fillings by increasing the resistance of the filling to the wear of mastication. The pure gold is first used as it is capable of more perfect adaptation to the walls, all of which should be covered before taking up the platinized gold. The contour portion should be made of the alloy. This alloy comes from the supply house in sheets which appear to be pure gold except that the color is a little lighter. This foil comes in three numbers, 1, 2 and 3, the No. 2 being preferable for most cases.

The rules for condensation are just the same as for pure gold, only the observance of each specific rule given on that subject is more emphatically demanded here, and when strictly followed the alloy will prove as easily handled.

Cohesive Gold and Non-Cohesive Gold Combined. By this combination much time is saved as the non-cohesive gold may be introduced in greater masses than the cohesive. Also the soft gold is more easily adapted to the walls than cohesive.

The cohesive gold is used to finish the contour as it will better resist the torsion strain and the effects of abrasion. Before the introduction of cohesive gold all gold fillings were non-cohesive, but since the introduction of the former the art of filling teeth well with soft gold has rapidly declined, so that the making of an entirely non-cohesive gold filling is now the exception.

Cement and Amalgam. Results similar to what might be termed an amalgam inlay are produced by coating the prepared cavity with cement, and immediately burnishing into this fresh cement, a portion of the amalgam. The enamel margins are rendered clean

again by freshly cutting them with a chisel for their entire outline and the amalgam filling immediately finished in the usual way.

The Benefits. This combination produces a filling with the virtues of an amalgam to which is added the adhesion of the cement and the protection of cavity wall from fracture and discoloration.

When Indicated. This is indicated in most large cavities to be filled with amalgam, where the walls are weak and thin and in cavities where insufficient retentive form is secured.

Cement and Porcelain. Cement is combined with porcelain in the filling of teeth for the purpose of making the filling adhere. The porcelain protects the cement from dissolution.

Silicate Cement and Fused Porcelain. Fused porcelain inlays




Fig. 106.—Combination gold inlay and silicate. *A* represents the gold inlay in position ready to receive the silicate. *B* represents the same after the silicate has been put in place.

may be set with some of the silicate cements to great advantage. The silicate filling materials which are at their best when mixed thin enough to be adhesive are those which can be used as a cement. In fact some operators are using these materials for setting the gold inlay with seemingly good results.

Silicate and Gold. Silicate may be used to face the gold filling for esthetic reasons. In filling Class Four cavities with the gold inlay, by either one of the four plans, the wax may be cut out of the pattern so as to present a labial surface almost entirely of silicate. After these two materials are combined in this class of cavity, care should be taken that the incisal edge is of gold and

particularly that the cavo-surface angle on the incisal outline is protected by one-half of a millimeter to a millimeter of the cast gold. The cast should be made and set with oxyphosphate of zinc cement. At a subsequent setting the silicate face may be built in. A similar effect is produced with the bicuspids and molars, in crown work. The gold crown is made in the usual way and set. A carborundum stone is applied to the buccal surface and ground away and a sufficient amount of cement cut out to make room for the building in of the silicate. Before building in the silicate it is best to coat the cement which is exposed within the crown with a thin application of copal-ether varnish.

Silicate and Amalgam. Many large contour amalgam fillings on the mesial surfaces of bicuspids and molars particularly in the

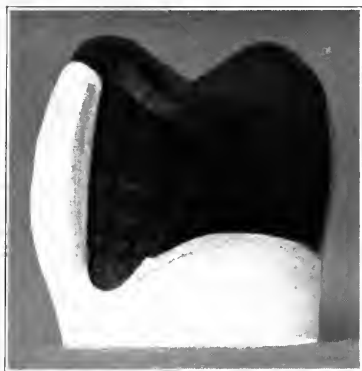


Fig. 107.



Fig. 108.

Fig. 107.—Amalgam in position ready to receive a partial facing of silicate.

Fig. 108.—This represents the amalgam filling shown in Fig. 107 with the silicate facing built in. The dotted line shows the outline of the silicate with that portion marked *x*, representing the silicate.

superior teeth are unsightly. A very pleasing effect is produced by cutting away the mesio-buccal contour of amalgam, either in new or old fillings, and in the resulting cavity, build silicate. The silicate will not discolor when thus applied to the amalgam. However, each individual case seems to require a different shade and to get it right a trial mix should be made before deciding on the combination of powder to produce the desired shade.

Silicate as Applied to Prosthetic Work. It is not within the scope of this book to deal with prosthetic procedures. However, it is well to call attention to the fact that this material is used to

advantage in the facing of crowns, the fitting of gingival ends of porcelain pin crowns to the root, and its application to many places in pieces of bridge work. It is also useful in the facing of partial and full removable dentures in a color to imitate the natural gum tissues.

There are many other combinations which are made and used to advantage in tooth salvage. It is improbable that the perfect filling material will ever be produced as the demands are so varied in different mouths, and in different localities in the same mouth.

We are more nearly able to meet all of those varying conditions by a wise selection of the materials to be used in each case and a judicious combination will go far to produce the perfect filling for each individual cavity as presented.

PART III

CHAPTER XXIX.

EXAMINATION OF THE MOUTH LOOKING TO DENTAL SERVICES

The First Duty of a dentist to one presenting himself for dental services is to comply with the patient's request, which is generally to examine a special tooth or a diseased condition of which the patient is aware. If the patient does not make such a special request it is well to ask some form of a leading question as to the reason of the call. This fact elicited, all else should be ignored until the object of the first visit has been accomplished.

A Light Hand and Slow Movements are very essential for the first few moments, especially at the first meeting of patient and dentist, as first impressions are often lasting and if the stranger is approached in a careless manner he may get ideas of undue roughness, many times unfounded, yet, nevertheless, lasting with the nervous patient.

The Washing of the Hands in the patient's presence or in running water within hearing of the patient should be universally practiced no matter if the operator knows his hands to be already scrupulously clean, as it assures the patient that the operator has a regard for at least the simpler forms of cleanliness.

The Linen Upon the Chair should be inviting and unsoiled. If convenient, it is well that the patient see that which is already on the chair changed for fresh.

Few Instruments should be in sight, as they serve to remind the patient of former experiences not always pleasant.

After the First Requests of the patient have been complied with it is well to take a rather general survey of the mouth before answering many questions regarding the advice to the patient as to future procedures. The operator should note in this "bird's-eye view," as it were, the probable care that is being bestowed upon the teeth and mouth in a prophylactic way. Also the health of the soft tissues, the number of extracted teeth, the presence of dentures and amount of dental work previously done, noting its quality and probable age, as well as the number of badly decayed teeth yet unfilled. He should note the health of the patient, probable

age and habits. All this can be done at a glance and in a few second's time, when the operator will be much better qualified to advise the patient as to what is best to do in a special case.

If the Patient Is in Pain its alleviation is of first importance and should receive immediate attention. It may require the application of medicinal remedies, or some mechanical procedure or even the extraction of a tooth, but, whatever it may be, it must be done at once as the patient is in no mood to receive sage advice about the future when he is at present in pain.

Early in the Examination Sitting the patient should be advised of the necessity of a prophylactic treatment provided the teeth and mouth are not scrupulously clean, which is seldom the case, unless the patient has recently visited the dentist for that purpose.

This Is Second Only to the relief of pain and it is manifestly the dentist's duty to attend to prophylaxis before proceeding to the making of fillings.

A Careful Examination should be suggested, following the hasty inspection, and, if advised to do so by the patient, the dentist may then proceed to search all surfaces for the various classes of decay, not forgetting the vulnerable points about work previously placed, as the margins of fillings and about the bands of crowns.

The Instruments Needed are, a clear, uninjured mouth mirror, a sharp pointed instrument called an explorer, cotton pliers and small balls of absorbent cotton, waxed floss silk, chip blower and mechanical separator. A small electric mouth lamp is also of value.

The Use of the Mouth Mirror is to see therein the image of surfaces and locations where direct vision is imperfect or impossible and to flood the point being examined with an abundance of light. Many cavities existing in the proximal spaces are not noticed until strong rays of light from a different angle than the line of vision of the examiner have been directed against them.

The Use of the Explorer is to note the extent of decalcification at suspected points and the inspection of pits and grooves for faults in enamel. This instrument should be in the shape of an elongated cork screw turn, that the more inaccessible points may be reached. A light hand in its use is imperative as the dentist is not excused for breaking down tooth substances or for causing much pain in any of the processes of examination.

Absorbent Cotton in the pliers is used to take up the moisture in cavities of considerable size and whose depth questions proximity

to the pulp; also sensitive surfaces suspected in shallow cavities, particularly those in the gingival third. The cotton balls should not be too large and rather tightly rolled.

Waxed Floss Silk is used to examine the proximal space where the reflection of light does not make diagnosis positive. It cleans the surfaces of debris and food particles, giving a deeper insight from the embrasure. When surfaces are roughened or cupped from incipient caries, it will show by the catching or cutting of the fibers of the thread; if the surfaces still retain their normal polish the thread will pass uninjured.

The Chip Blower is a small hand bellows for the expulsion of air and is used in examination of the teeth to blow away and evaporate the moisture from points where it is held by capillary attraction, giving, thereby, a better view and a more correct idea as to the color present, which is a strong factor in a diagnosis of conditions.

The Mechanical Separator will sometimes be of service to gain a little added space for the inspection of contacting surfaces.

The Use of the Electric Lamp on the lingual side of the teeth has many advantages and is a speedy and sure way of detecting any of the stages of caries in the proximal spaces, the vitality of a tooth's pulp as well as abnormal conditions about the alveolar wall and the presence of pus and inflammatory changes in the maxillary sinus.

When the Examination Is Completed the patient should be advised of the true condition of his mouth, including the indicated treatment of both hard and soft tissues. If the patient indicates a desire to have the services rendered as outlined by the dentist it is entirely good business, and by no means unprofessional, to apprise the patient of the probable cost of the work as planned when it can be approximately estimated, unless the patient is a frequent visitor and familiar with the charges expected from the dentist consulted.

CHAPTER XXX.

THE ALLEVIATION OF DENTAL PAINS.

The First Duty of the Dentist is to relieve suffering, and as in many instances this is the reason for the first call of the patient it is most essential that the relief sought is obtained. Many times the relieving of a paroxysm of pain by the dentist has made a lifelong friend and patient.

The Diagnosis is a most vital point and the battle is half won when this is correctly made.

Pay Strict Attention to What the Patient Has to Say as he is quite sure to give you his symptoms in the order of their prominence and it is generally the prominent symptoms that are pathognomonic.

After the Patient Has Given the Most Aggravated Symptoms, make an examination of the afflicted part of the mouth to verify the statements made. If all is not clear quiz him more specifically. Do not jump at conclusions. The patient is generally right as to symptoms but frequently wrong as to location and cause. These last are the points the dentist must decide, as well as upon the treatment for relief.

There Are Two Divisions of Dental Pains, those arising from lesions of the tooth pulp, and those arising from degenerative changes in the sub-dental tissues, which are generally the sequelæ of the same destructive processes in the pulp. They may follow the pulp troubles or occur simultaneously with them.

Pulp Lesions. Symptoms are sensitiveness to thermal changes. The tooth is not necessarily sore to percussive force. Pain is increased or induced when assuming a recumbent position. The presence of foreign substances in the tooth cavity cause pain especially when pressed against the walls of the cavity. Pain comes in paroxysms with a tendency to intermittence. Patient may complain of "jumping toothache." These symptoms may all be present in the same case or only one at a time in the series of changes that take place in a pulp from the initial affection to its death.

The Treatment for Speedy Relief is varied according to the most prominent symptoms, as these are the indications of the stage of dissolution.

If Cold Air or Water Causes Pain of a quick, sharp, shooting nature, comes on suddenly and passes off immediately upon the tooth regaining the body temperature, the pulp is in the stages of active

hyperemia, which is the initial stage of a destructive disease, and will respond immediately to the application of anodyne and effectual protection from air and fluids, which is accomplished by stopping the cavity with a non-conductor, generally cotton, or temporary stopping, or an application of phenol.

If Warm Fluids Cause or Intensify the Pain and the application of cold relieves the pain temporarily, the pulp will be found to be well advanced in the stages of dissolution, some portion of which has been resolved into the end products. Gaseous substances occupy portions of the pulp cavity, which is closed over the entire coronal portion by a layer of dentine, a filling or a plug of foreign substance. These gases are expanded by the elevation of the temperature, causing increased pressure upon the remaining vital portions of the pulp and intense pain results, which is further augmented, many times, by the pulsations of the heart. The pulsating symptom in this instance indicates that quite a portion of the pulp is yet vital.

The Treatment for Relief in This Case, which is called closed putrescence, is the removal of the obstruction for the escape of the gas. This involves opening into the pulp chamber through the route of the least obstruction or injury to the tooth. Necrotic portions of the pulp should be removed, disinfectants and anodynes applied and devitalization of the remaining vital portion effected.

If Moderately Warm Fluids Cause Pain as well as cold the pulp is in the first stages of passive hyperemia or congestion. This condition is generally soon followed by the symptom of being more painful upon the patient's lying down and the throbbing pains setting in, and many times patients will say, "I have the jumping tooth-ache;" or, "It began last evening about fifteen minutes after I went to bed."

Treatment of Passive Hyperemic Pulp for relief is sterilization of immediate surrounding tissue at the tooth's cavity and the application of sedatives and anodynes. If the pulp can be bled with causing but slight pain it is beneficial; then proceed to devitalization.

The Painting of the Gum with a revulsive is of service, especially if the pericementum is taking on the stages of inflammation indicated by slight soreness to percussion.

If the Presence of a Foreign Substance in a cavity causes pain it may be an exposed pulp which is not very highly organized, or hypersensitive dentine covered with a layer of leathery decay.

The Treatment Is the Removal of the offending object and the prevention of its recurrence by temporary or permanent stopping.

Pericemental Diseases Causing Pain have for their most pathognomonic symptom the soreness to percussion, as shown by gently tapping on the occlusal surface of the tooth with a steel instrument. Slight swelling of the pericementum causes the tooth to appear to the patient as much elongated and the patient will generally make such remarks as these, "I have a sore tooth;" "It hurts to close my teeth;" "My tooth is too long," etc.

If the pulp is entirely dead, and removed, or there is not a case of enclosed putrescence, thermal changes will have no effect, except in rare cases warmth applied to the parts will give a slight sense of relief.

Treatment for the Relief of Pericemental Pains is the thorough and complete removal of the cause, generally consisting of necrotic pulp tissue, and infectious matter in the pulp chamber. This should be thoroughly removed by mechanical means, assisted by the use of chemicals, and the entire chamber from crown to apex rendered aseptic as soon as possible.

If Pus Has Formed at the apical space and flows freely down the root canal temporary relief is most certain to follow if the case is allowed to remain open for twenty-four or forty-eight hours for free drainage, when further treatment may be proceeded with.

Acute Alveolar Abscesses should be opened externally, as soon as the presence of pus can be diagnosed, this to be done external to the alveolar wall and is least painfully done by freezing the tissues to be punctured.

Abscesses Are Assisted to the Surface by painting the mucous membrane over the diseased portion with aconite and iodine. In no case should such an abscess, no matter what its size, be lanced through the external surface of the face as all are easily reached from within the mouth.

CHAPTER XXXI.

PROPHYLACTIC TREATMENT OF THE MOUTH.

The Importance of Prophylactic Treatment early in a series of visits to a dentist and at stated periods thereafter, is second only to the relief of pain, the neglect of which jeopardizes the remaining tooth structures, the permanency of attempts to check the ravages of caries and disease, as well as the reputation of the operator's skill.

Unhygienic Conditions About the Teeth are the sole, immediate and exciting cause of primary or secondary decay of the teeth, and many an operator of exceptional skill as to the making of fillings has failed from a disregard of these conditions. As much of the success of dental operations depends upon the care of the mouth by both dentist and patient in the way of prophylaxis, as upon the skill of the dentist as an operator. The making of a filling is but the repair of an injury and is only a temporary check to the progress of destruction, if the primary cause of dissolution is to remain operative.

The Sub-Dental Tissues are also diseased by a lack of prophylaxis to the extent, many times, of their entire loss, so that the teeth, themselves, are loosened and lost, through a lack of structures to support them, while the teeth so lost are many times yet undecayed, and, in the present-day advancement of dentistry, experienced operators are forced to consign more teeth to the forceps from the result of diseased conditions in the tissues surrounding them than from decay of the teeth, themselves. If this be true the dentist cannot ignore the importance of combating the agencies which bring it about.

Preventive Dentistry has the same great field of usefulness as has "preventive medicine" in the practice of medicine and the dentist who masters this phase of the science of dentistry has gone a long way towards success, and many defects in manipulation, ability and ideals in conditions about tooth repair impossible of attainment, will stand the test of time if only hygienic conditions are attained and maintained.

The Kinds of Deposits Upon the Teeth are generally classified as salivary calculus, serumal calculus, green stain and sordes.

The first two named are enemies to tissue about the teeth, while

the last two are responsible for most of the destruction of the hard dental tissues by caries.

Composition of Salivary Calculus. Mixed saliva contains in man an average of about 0.5 per cent solids. The calculus is precipitated into the mouth in a form of a finely divided caleoglobulin, which collects in masses upon any stationary object, close to the mouth of the gland ducts. The fresh deposit is very soft and greasy to feel when first deposited, but within twenty-four hours it begins to harden and increases in hardness up to the time of thirty or sixty days, when it has generally attained its full hardness and will break away from the stationary object in masses showing distinct lines of fracture.

Lime Salts Held in Solution. Calcium phosphate and magnesium phosphate are held in solution in the saliva, made possible by the presence of a little carbon dioxide.

Reasons for Precipitation. When the saliva is discharged into the mouth it is released from the normal blood pressure and some of the carbon dioxide escapes which allows the calcium salts to be precipitated. The lactic acid which is continually formed in the mouth converts the mucus into a curd in which the calcium salts are entangled to harden into salivary calculus. This process is assisted by the presence of the oxygen taken into the mouth with the breath, which facilitates the liberation of the carbon dioxide, in the process of oxidization.

Time of Deposits. It would seem from the experiments of Dr. Black that the deposits of salivary calculus are paroxysmal and also that these periods of rapid deposit follow the ingestion of heavy meals. He thinks that these periods of excessive deposits come at a time when the blood is overcharged with food pabulum.

Kind of Food. It does not seem from his experiments that the kind of food has very much to do with these deposits. The more easily a food is digested, the more quickly following the meal will these deposits appear.

Habits of Patient. It would seem that the habits of the patient have little to do in influencing the amount of these deposits. However those who live a life of physical exertion, which favors the using of heavy meals have a greater tendency to deposits of tartar than those whose vocation would cause them to eat lightly.

Mouths Most Subject to the Deposit. From our present understanding of this subject it would seem that the mouths most subject to the deposit of salivary calculus are those individuals,

First, who from constitutional reasons have a tendency to an abundance of carbon dioxide in the excretions and secretions. This condition may be brought about by great physical or mental activity or where the skin, kidneys or lungs, or all, are not performing their full functions. These are the principal eliminators of carbon dioxide. Such individuals are very liable to be troubled with precipitation within the gland and ducts, through which their secretions are expelled, resulting in cystic, glandular, biliary or renal calculi.

Second, those individuals who either occasionally or habitually engorge heavy meals, wherein the quantity of such meals is greater than that needed for growth or maintenance.

Third, in mouths wherein the amount of lactic acid is more than normal.

Fourth, in the mouths of public speakers and mouth breathers, whether awake or during sleep. The great amount of oxygen coming in contact with the saliva assists in the rapid liberation of the carbon dioxide and consequent rapid precipitation of the calcium salts.

Prevention of Salivary Deposits. It would seem that salivary deposits can largely be prevented by stimulating the circulation; stimulating the elimination of carbon dioxide from the body; checking mouth breathing as much as possible, correcting over-acidity of the mouth, limiting the amount of food taken into the stomach at each meal by more nearly equalizing the three daily meals to the needs of the body. Also by so highly polishing the surfaces of the teeth upon which the deposit is precipitated, as to facilitate the mechanical removal of the fresh deposits. Last but not least, so instructing the patients in the mechanical features of the care of their teeth that insofar as possible all fresh deposits are removed before hardening takes place.

Serumal Calculus is a calcic precipitate from the blood. The salts in solution in the blood as well as the stability of suspension depends materially upon the presence of a normal amount of carbon dioxide.

Serumal Calculus Is Deposited beneath the gum tissue wherein there is a passive hyperemic condition or congestion. Here we have excessive tissue waste, lessened alkalinity of the blood, a liberation of the carbon dioxide and consequent precipitation of the inorganic salts. By the recession of the gum after the formation

of the serumal form of calculus, it may be exposed to view, or mixed with the mass of salivary calculus.

Serumal Calculus in Appearance is of a much darker color than salivary of a harder constituency, and generally adheres to the surface of the tooth more tenaciously.

Serumal Calculus Is Also Found on unexposed portions of roots of teeth which approximate inflammatory exudates, or, are bathed in escaping blood plasma associated with chronic conditions of the apical space. It also appears in other portions of the body as about the joints subjected to chronic inflammations as well as in the glands continually gorged with blood.

The Bulk of Serumal Calculus is comparatively small, owing to its formation in restricted spaces and is generally found in small nodules, narrow bands and thin scales, not always easy of detection or removal.

Stains Upon the Teeth are of varying degrees of shade in several colors and from cosmetic reasons stand for immediate removal when detected. However the green stain found upon teeth is so closely connected with the first stages of caries on surfaces so affected that it deserves special consideration.

Green Stain Is Generally Confined to the labial surfaces and particularly the gingival third of the anterior teeth. It is most frequently found upon the teeth of children and may be seen either upon the temporary or permanent teeth. When it persists for a considerable time upon these surfaces of the permanent teeth the enamel will be found to be etched by a dissolution of the cemental substance evidenced by the whitened surface.

The Color Is Due to the bacteria present.

The Injury to Tooth Substance is due to the acid which these bacteria produce.

The Reason for Their Presence is the favorable place for lodgment afforded by the persistence of the cuticula dentis.

Sordes Consists of a mixture of food, epithelial matter and micro-organisms collected upon the teeth.

Neglect in the Removal of Sordes results in tooth caries, particularly in localities habitually so unclean.

The Removal of Salivary Calculus is accomplished by two principal plans, the push-cut method and the draw-cut method, each with its advantages.

By the Push-Cut Method the blade of the sealer, which has a blunt chisel edge, is forced between the calculus and enamel trav-

eling in the direction of the root. In its use the principal danger is the slipping of the instrument to the gum tissue beyond and this accident should be well guarded against by first securing a positive and sufficient hand rest.

By the Pull-Cut Method the blade of the scaler, which has a hoe point of about twenty-eight degrees, is first passed under the free margin of the gum, its point engaged on the ledge of the calculus and its removal accomplished by a pulling force applied toward the crown of the tooth, or in a plane parallel with the long axis of the tooth. Care should be taken in passing the instrument under the free margin not to lacerate the gums. Pen grasp should be used and a secure hand rest obtained before making an effort to remove the deposit.

The First Teeth to Be Scaled is not important, yet if attention is first directed to the lingual surfaces of the lower incisors, we are able to create an impression upon our patients of the importance of the work in hand. It is here we generally find the heaviest deposits and by removing these first, and allowing them to fall in the mouth the patient is fully awakened to the need of the service being rendered. The same impressions never seem possible if the removal of the larger masses is left until the last.

The Proximal Surfaces Are Best Scaled with the pruning hook, draw-cut scaler or the straight push-cut having a very thin blade and about a twenty-three degree bevel.

These proximal surfaces will need such attention more from the deposit of serumal calculus than from the salivary variety, which is only present in the proximal surfaces after gum recession.

The Removal of Serumal Calculus is much more difficult than salivary, as all of the work is done under the cover of the gum, which requires delicacy of touch and the highest degree of digital skill.

Calculus Must Be Distinguished From Cementum, bone and soft tissues, simply by the sensation of touch conveyed through contact of the instrument with the structures in question.

The Surface of Roots, where the attachment of the pericementum has been lost, must be carefully examined and the removal of all calculus accomplished, and the root or roots thoroughly polished, as the gum will not regain health where particles of the deposit remain. Several sittings are often necessary to accomplish satisfactory results.

Pyorrhea Alveolaris. The desire to keep this book within cer-

tain limitations prevents the consideration of pyorrhea in its treatment. However the foregoing procedure will go far towards the prevention and cure of pyorrhea alveolaris. In fact thorough prophylaxis is the prime essential in the treatment of that disease.

The Removal of Green Stain is principally accomplished by the application of some abradent, as pumice stone, with a revolving brush in the dental engine. This also polishes the crowns of the teeth, removing the small particles of calculus still adhering to them after sealing.

Hydrogen dioxide (H_2O_2) added to the powdered pumice in place of water will assist in removing the stains and particularly green stain, of which it is a partial solvent. Following the use of pumice the gums should be thoroughly syringed with water to remove any trace of the pumice, which is insoluble in the mouth and should not be left around the free margins of the gums.

A Clean New Brush Wheel should be used and a fresh mix of the powder made for each patient as a means of preventing the transmission of disease as well as from a standpoint of cleanliness. As well might our patients be asked to all use the same toothbrush, a thing not thought of, even by members of the same family.

The Removal of Sordes is a matter which must be left to the efforts of the patients. Its accumulation about favorable portions of the teeth and mouth is but the matter of a night or a day and upon its speedy and frequent removal depends the salvage of the teeth from the ravages of caries.

The Toothbrush is the one great cleansing agent and nine-tenths of the removal of sordes is accomplished purely by mechanical abrasion through the movements of the bristles of the brush over the surface of the teeth. The movements of the bristles should be not only crosswise to the long axis of the teeth, but also from root to crown and vice versa, that the travel of the bristles may parallel the gingival, enter the embrasures and traverse the grooves and fissures.

Hydrogen Dioxide Is the Only Agent which can be used in the mouth in sufficient strength to dissolve sordes and not injure either the hard or soft oral tissues. This may be used either upon the brush or as a mouth wash. The dissolution of sordes is accomplished by oxidation.

The Massage of the Gums is advised to remove all unconsolidated calculus, food particles and other foreign substances from beneath the free margins of the gums as this appears to be the only satis-

factory method of cleansing these spaces. The massage is also most beneficial to the gums. It stimulates the circulation, retards tissue waste and lessens the deposit of serumal calculus, and in addition forces away that which has been precipitated before it has an opportunity to solidify.

Instructions to Patients as to the care of their teeth is an all-important duty of the dentist, not only from the standpoint of what is best for the patient, but much of the dentist's reputation as an operator depends upon the subsequent care given the teeth by the owner following the making of fillings, for upon their environment depends their permanency. Comparatively few individuals know how to properly care for the mouth and many will insist to their dentist that they are most careful of their oral habits when upon examination, the dentist finds surfaces which appear never to have been cared for in the least. They have failed to reach these surfaces with their brush.

The Technic of Proper Brushing should be thoroughly explained, with special reference to reaching the surface which they seem to be neglecting. Instruct them as to the massage of the gums with the finger tips, rubbing not only crosswise but also from root to crown, assuring them that if the gums bleed easily it is all the more essential that they repeat the operation and that finally they will regain their normal health and then they will not bleed under the treatment advised.

The Use of Floss Silk for passing through the proximal spaces to clean contacting surfaces by wiping off the embrasures and reaching points inaccessible to the brush, should be demonstrated to the patient.

Care should be taken not to snap the thread past contact points as it may lacerate the gums.

Toothpicks have no place in the care of the teeth and should be prohibited by law, especially those of soft wood so commonly found on the market and at public eating houses. Their square corners and splintered ends irritate the gums, causing their disease and recession thereby destroying the natural protection to the most vulnerable portions of the teeth.

CHAPTER XXXII.

EXCLUSION OF MOISTURE

The Exclusion of Moisture from most operations upon the teeth is essential to the successful manipulation of most filling materials, the sterilization of tooth structures and the prevention of infection, the cleanliness of cavity walls and margins, that a perfect view of the cavity may be obtained, that the extent of decalcification may be observed, to diminish the pain of operations on living dentine and to protect the soft tissues from injury in the use of caustic drugs, as well as to save time of both patient and operator.

The Methods of Securing Dryness during operations are here given.

The Rubber Dam, invented and given to the dental profession in 1864 by Dr. Sanford C. Barnum, of New York City, is widely used.

Absorbents, as napkins, cotton rolls and pads packed about the teeth and near the mouths of ducts, assisted by specially constructed clamps upon the teeth are also used. Dryness is also secured by the *use of the saliva ejector* whereby the mouth is continually drained of the secretions.

The Objections to the Use of the Rubber Dam are entirely on the part of the patient and can generally be traced to awkward and unskilled handling on the part of the operator. Every operator should become dextrous with each method, that he may employ the one most expedient in every case, using the one least objectionable to the patient.

The Neglect of Dryness in dental operations is to invite disaster in root canal treatment, as well as short life to all fillings so placed, and the operator who makes it a practice to neglect this essential, obtains only a partial success in that which he attempts.

So Important Is Dryness that a patient should be warned that a certain operation, where moisture has been allowed to flood the field, is short-lived at best and is liable to failure from this cause. Such conditions seldom arise but are occasionally met with, due to location and extent of decay and also from the fact that there are some patients who are nauseated by the presence of the dam or absorbents about all but the most anterior teeth.

All Filling Materials are better manipulated under dry conditions at some stage of the operation, porcelain being the only one demanding moist conditions at any stage of the process. This

moisture in porcelain filling is only required to preserve the shade of the tooth substance to be imitated in the fused filling.

Those to Which Dryness Is Most Essential are silicate, cohesive gold, cement amalgam and gutta-percha, named in the order of the importance of the demands. It is true that all of these excepting silicate may be successfully manipulated under moist conditions, but the effort is greater and the certainty of success is materially decreased.

The Exclusion of Moisture for Sterilization and the prevention of infection is imperative in the last stages of cavity preparation, as it is physically impossible to properly perform the toilet of the cavity and properly sterilize the same when flooded or even under moist conditions.

The Proper Treatment of Pulp Canals cannot be accomplished when flooded by the oral fluids to say nothing of the introduction of a permanent root filling. The saliva is at all times impregnated with various forms of bacteria. Its presence invites failure by preventing sterilization of canals already septic and permitting the re-infection of those already sterile.

Cavity Walls, and particularly the beveled margins, must be freshly cut and planed after being moistened before the introduction of a filling, as this is the only means of having an absolutely clean surface. We may resort to absorbing and evaporating the moisture from the walls and margins of a cavity, but there will invariably be left a residue or film upon the surface which is soluble in the oral fluids. No amount of pressure in introducing the filling, be it rubber, amalgam or cohesive gold, will displace the moisture absorbed by the cavity surfaces, hence we have this layer of moisture or sediment intervening the filling and cavity. This will be exchanged in course of time for that upon the outside carrying with it bacteria and the products of fermentation or lactic acid and secondary caries is the result. Bacteria, which are the active agents of caries, will go where moisture will not, and the lactic acid which they secrete will go where the space is too small for the bacteria. It will therefore be readily seen that a moist surface or one coated with a residue of an evaporated mixture, whether medicine or saliva, intervening between a filling and a cavity wall, becomes a large passage way for the greatest enemy to tooth substance—lactic acid.

A Better View of the Cavity Is Obtained When Dry, as its outlines become more distinct and its size and shape better defined.

No mechanic ever thinks of trying to accomplish his best work with the object submerged in moisture. The rays of light are broken, objects are distorted and distances misjudged. The dentist who does not effectually exclude the moisture from the immediate neighborhood of a cavity will catch only a glimpse now and then of portions of a cavity, this being particularly true of the gingival wall, except in cases of gum recession.

The Extent of Decalcification of both dentine and enamel is diagnosed only when dryness is obtained to bring out the colors and shades of each incident to these conditions. It is impossible to make proper cavity extension until the cavity has been made dry and so maintained for some time, as this is often the only means of detecting superficial caries. Semi-decalcified tooth substance, when moist, materially resembles the healthy structures and must be dried to detect its injured condition.

The Pain of Cavity Excavation is materially decreased by the extraction of the moisture from the dentine. The protoplasm within the dental tubules is the means of transmitting the sensation of pain to the vital pulp. Water is a large constituent of protoplasm and the extraction of this moisture through extreme and continued dryness removes the media of sensitiveness. It is therefore but humane that the cutting of dentine be done with the moisture excluded.

When Using Caustic and Concentrated Drugs the moisture should be excluded, that the drug may not be carried away to the injury of adjacent tissues and that the drugs may not be diluted to detract from their efficiency in accomplishing that for which they were used. Drugs placed in the cavities of teeth with moist margins even when placed under fillings of rubber, cement or amalgam, will follow the moisture of these margins to join that without and great damage to the surrounding tissues often results from no other cause than a lack of the exclusion of moisture during the operation.

As a Time Saver the exclusion of moisture should not be overlooked. With a dry cavity the continued uninterrupted view permits of more continuous work by the dentist. He does not have to wait for the patient to expectorate, make a few remarks and leisurely resume his position in the chair, not always in the position desired for operating. The operator will also be saved much time in drying the cavity after each flooding. All this takes valuable time, much more than is required to adjust a dam.

The Rubber Dam is the most dependable means of securing a dry

field for operating and its proper and speedy adjustment should be mastered. It is made in three thicknesses; heavy, light and medium, the medium being the weight best adapted for all purposes where only one weight is to be kept at hand.

The Size and Shape is of little importance so long as it completely covers the mouth after it has been made to isolate the teeth desired, as well as cover the chin and extend to either side of the mouth sufficient for the proper engagement of the holder. This will require a piece from five to six inches square, for all cases back of the six anterior teeth and is most frequently the size used on the anterior teeth. However, some economy of rubber dam may be practiced by cutting these squares in two triangular pieces, each of which will do for a separate case. These are applied with the diagonal of the quadrilateral (hypotenuse) uppermost.

The Holes to Receive the Teeth should be of the proper size and smoothly cut, otherwise there is an increased liability of being torn in adjustment. This is best done by the use of the rubber dam punch to be had at dental depots. However, in the absence of this, a very good result is obtained by drawing the rubber tightly over a tapering round handle of an instrument and touching the sharp edge of a knife to the rubber down the side of the handle when a perfectly round piece will be cut out.

The Distance Between the Holes will vary according to the space between the teeth, the height of the festoon of the gum, the weight of the dam and the size of the teeth to be engaged. Generally speaking, the holes are cut from two to four millimeters apart in medium dam. The lighter the dam the farther apart should be the holes. The holes are farther spaced with extremely large gum festoons, also when there is a considerable gum recession. If the holes are too close together in above condition the dam may not cover the entire proximal tissues and a leakage may occur, or the gum septa may be unduly compressed and permanent injury result from strangulation. If the holes are too far apart the rubber will wrinkle and bag at the proximal spaces and seriously hinder operations in these localities.

The Location of the Holes in the piece of rubber dam depends upon the location of the tooth to be operated upon and the teeth to be isolated. A beginner will do well to first place the dam over the mouth in the position desired for the outside edges, request the patient to open the mouth and with the finger cause the dam to come in contact with the occlusal surfaces of the teeth it is intended to include and then punch the holes as this trial indicates. By this

method the operator will soon become familiar with the location in each case.

The Number of Teeth Isolated depends upon the location and the operation to be performed. For the short treatment cases, sometimes the placing of one or two teeth under the dam will suffice, but in most cases where fillings are to be made and polished, from five to eight teeth should be included that a good view of the field of operation may be had and the loose folds of dam carried farther away to avoid them catching in the revolving points of the engine.

With Anterior Teeth the first bicuspid tooth of either side should be included, as the cuspid from its conical shape is many times unsafe for a final ligature.

With Bicuspids and Molars as the objective teeth in an operation, there should also be included the teeth anterior to the median line.

The Clamp should be placed on the tooth back of the one to be operated upon, excepting in mesial cavities in second molars when the clamp may be placed on the second molar, thereby avoiding the clamping of the third molar except when absolutely necessary, as with distal cavities in second molars.

The Placing of the Dam requires the freedom of both hands of the operator, and the aid of an assistant is of value. The necks of the teeth upon which the rubber dam is to be placed should be cleansed of all calculus and sordes and flooded with a jet of water from the syringe. If the gums show hypersensitiveness they should be bathed in a solution of novocain, restricting its use to the gingival borders. Waxed silk should be passed through the proximal spaces to clean them and prove access for the rubber. If sharp margins of cavities cut the silk these should be dulled by passing a thin ribbon saw through the proximal space or, with the chisel, carry the margin sufficiently into the embrasure to give access.

When teeth are in close contact so that the silk thread is passed with difficulty, the rubber can be made to pass more readily by the use of soap, which is done by placing the row of holes on the ball of the index finger, occlusal side up, and rubbing the soaped fingers of the other hand across the holes.

The Occlusal Side of the Rubber Dam is that side which is toward the occlusal surface when the dam is in position.

The Gingival Side is the opposite side and is next to the gingival margins when the dam has been applied to the teeth.

The Method of Applying the Dam is affected by the fact of

whether a clamp is used or not and kind of clamp when one is used.

With the Anterior Teeth we do not generally use a clamp and the rubber is placed by commencing at one side and then crowding the rubber through each proximal space in the order they should go, until the opposite side is reached. The rubber dam holder should be applied to one side before commencing the adjustment, and, as soon as the teeth have been forced through the holes, the other side of the holder should be attached.

With Posterior Teeth the holder should be attached to the short side of the rubber to prevent curling into the mouth, which would be the same side of the dam as the teeth are situated in the mouth, right or left. Adjust clamp to be used as this tooth receives first attention, while the remaining teeth are one by one pushed through, until the most anterior one is reached, when the remaining side of the rubber is secured with the holder.

To Prevent Leakage Around the Teeth the edges of the holes must turn toward the roots. This is accomplished by first pressing the dam well against the gums while grasping the rubber on either side of the tooth and drawing it tight, then releasing the rubber so that it slackens and then gently moving it occlusally. This will generally have the effect of inverting the edges. If inversion is not complete pass a small blunt instrument, as a spatula or dull explorer, around the gingival to turn the edge under.

The Use of the Ligature is to assist in inverting the edges of the holes in the rubber dam and to secure the edges about the teeth in this position against displacement by the movements on the part of the patient or the operator.

Caution in the Use of Ligatures is most important as much permanent injury is done the gingival attachments by the careless crowding of these on the dental ligaments. This is particularly the case where the proximal gum festoons are high as in these cases, especially with young people, the attachment to the tooth is also high. A tight ligature tends to encircle the tooth in a straight line and would thereby ride down the high proximal attachments, if the ligature is crowded to the full height both labially and lingually. Hence either the labial or the lingual should not be crowded to the full height of the crown.

Ligatures Are Made of well-waxed floss specially prepared for the purpose, cut into lengths of about five or six inches. Some economy may be practiced where three teeth are to receive ligatures by starting with a piece about twelve inches long. Tie the first tooth in the center of the strand and when the ends are cut off enough re-

mains for the other two, thus getting three out of the amount usually used for two.

The Cutting of the Loose Ends may be practiced for all the teeth except the lower anterior, cutting two or three millimeters from the knot. With the lower anterior teeth, ends of two or three inches should be left from each knot and the farther ends of all tied together, and weighted to overcome the efforts of the patient to elevate the lower lip, which endangers the security of the dam.

The Most Popular Knot for tying ligatures is the "surgeon's knot," either full or half. This knot is made by passing the ends around each other twice before each tie is made, for the "full surgeon's knot," while for the "half surgeon's knot" this is done with only the first half of the knot.

The "Wedelstaedt Tie" is even more secure than the above and is made by using the first half of a "surgeon's knot" on the lingual side of the tooth first and then passing contacts with the ends on either side of the tooth, complete the operation with a "half surgeon's knot" on the labial, thus circling the tooth with two strands.

The Removal of Ligatures from the tooth when the operation has been completed should be accomplished before the rubber dam has been disturbed, and is best done by the use of a small sharp-pointed knife as a No. 1 gum lancet. The thread should be severed to one side of the knot on the labial or buccal side, and by grasping the knot with a pair of pliers, the thread is pulled through from that side.

Where Amalgam Fillings Have Just Been Completed in a proximal space the ligature about a tooth so filled as well as that around the proximating tooth should be cut so that the part lying gingivally from the fresh amalgam will be loosened and will pass out to the lingual embrasure. The ligature about a tooth in which there has just been completed a filling in both the mesial and distal should be cut on the lingual portion. This action will result in both ends being loose ends. Attention to this point will prevent the ligature plowing a ditch in the amalgam and destroying the filling, in many cases, at the gingival-cavo-surface.

A Good Rule to Remember with mesial fillings is to cut to the mesial of the knot; with distal fillings cut to the distal of the knot and where a tooth has both mesial and distal fillings cut ligature on the lingual.

The Selection of the Clamp should be made and then tried on the tooth it is intended to be used upon. One should be secured that has jaws which fit the contour of the tooth at its gingival border, that will remain in position and yet does not hug the tooth so

tightly as to cause the patient pain or in any way injure the soft tissues.

The Method of Applying the Clamp with the dam is to stretch the rubber over the clamp, then apply the clamp forceps and carry all to position on the desired tooth, using the hole in the dam thus intended as a means of getting a view of the tooth to be clamped, which aids in the placing.

Some of the older makes of clamps require that they first be placed in position on the tooth and then with the first fingers of each hand the hole is distended in the rubber dam sufficiently to permit it to slip over the bow of the clamp.

In Using Cervical Clamps for cavities on the buccal and labial surfaces in the gingival third the dam is first passed to position and then the clamp applied.

The Removal of the Rubber Dam is accomplished by the following order of procedure:

First—The removal of the ligations as before described.

Second—Pull the rubber to the buccal or labial and with a sharp pair of scissors cut strips passing between the teeth.

Third—Disengage one side of the dam holder.

Fourth—With the right hand remove the clamp which should be holding the rubber dam, remove all clear of the mouth immediately, as the patient does not take kindly to any delays at this stage of the procedure.

Fifth—Inspect the rubber to see if it has all been removed.

Sixth—Inspect the teeth for any portions of rubber dam, ligatures or stray particles of filling material. Now proceed to knead the gums with the fingers, at the same time flooding them with a forceful stream of water from the syringe, to cleanse them and to re-establish circulation.

The Use of Absorbents may be resorted to in place of the rubber dam for short operations and more particularly with the upper teeth as these are the most easily managed. Absorbents are to be had in the market in the form of rolls and napkins at small cost and are to be discarded after once used, which is the only hygienic method. In their use particular attention must be paid to the mouths of the ducts responsible for the most abundant secretions and the absorbents so placed as to not only readily absorb the fluid which is ejected, but also that they compress the ducts thereby restricting the flow.

CHAPTER XXXIII.

TREATMENT OF HYPERSENSITIVE DENTINE.

Hypersensitive Dentine is dentine which is more than normally responsive to mechanical or chemical irritation.

Normal Healthy Dentine is only slightly sensitive, but when exposed to abnormal conditions and irritating agents it may become excruciatingly hypersensitive.

The Sensations Are Conveyed to the Pulp by means of the contents of the dental tubules which are prolongations of the odontoblasts. The odontoblasts are thickly surrounded by the terminal fibers of the nerves within the pulp.

The Contents of the Tubuli is largely protoplasm and although this has the power of transmitting sensation in response to irritation, it has not yet been demonstrated that the nerve fibers enter the tubuli or penetrate their contents. Hence it cannot be said that there is nerve tissue within the dentine.

The Direct Cause of Sensitive Dentine is the loss of the enamel which is the natural covering of the dentine.

The Most Common Agent in the removal of this normal covering is caries, which exposes the dentine to mechanical injury through contact with foreign substances and chemical irritants, particularly the acids of fermentation.

Rapidity of Caries has much to do with the degree of hypersensitiveness in dentine, as shown in the white and light stages or rapid forms of caries wherein the sensitiveness is most exalted, while with the dark, yellow and brown varieties it is not so marked and with the black or slow progressing form of caries the sensitiveness is scarcely above normal.

The Most Sensitive Part of a Carious Tooth is at the junction of the dentine with the enamel or cementum at the periphery of the tubuli. It is therefore evident that the second stage of caries will show a higher degree of hypersensitive dentine than the deep-seated stages and that the preliminary steps in cavity preparation in this division of caries will be more painful than the deeper cuts into the dentine, as then the more sensitive part has been passed.

Mechanical Abrasion is also an agent which produces hypersensitive dentine by first wearing away the enamel and then encroaching on the dentine. However, this process may be so slow and the irritation so slight as to act as a stimulus to the odontoblasts

and result in the obliteration of the dental tubuli by the deposit of calcific matter termed "tubular calcification." When this is the result all sensation may be absent.

Exposure of Cementum through gum recession is another exciting cause of hypersensitive dentine aggravated by allowing the accumulation of sordes about the exposed cementum.

Abnormal Oral Secretions often produce hypersensitive dentine and may be particularly looked for in the convalescent stages of fevers, as well as in dyspepsia, neuralgia, pregnancy, pulmonary tuberculosis and acute rheumatism.

Hypersensitive Dentine is found in poorly calcified dentine including the teeth of the growing child; teeth that have not been erupted for more than a few months; the teeth of those who follow indoor lives, particularly if they are under a heavy mental strain, as well as anything which may produce nervous irritation or debility.

The Varying Temperaments of Patients must be studied and understood to best cope with the problem of hypersensitive dentine. The suffering is actual upon the part of some, while there are those who magnify every pain and seem to be able to stand nothing and make as much fuss about a pin stick as it would be possible for them to make were they thrust through with a bayonet. The operator must separate these classes and vary the methods. He must understand the actual conditions and, by kind words of encouragement and a positive procedure, stimulate the nervous to withstand the necessary pain. This can only be done when the operator has full control of his own feelings, seeing to it that his temper is not ruffled, for, having lost control of himself, he has no control over the patient.

Highly-Wrought, Nervous Temperament is, by nature, sensitive to impressions, especially augmented by environment or occupation and calls for the most skillful management of both patient and teeth. People of this type are generally of a high order of intelligence and when handled by a master hand prove a most desirable clientage.

Patients of This Temperament will permit being hurt for a short time provided something definite has been accomplished. They should be advised at times as to the coming pain, and for what purpose it must be inflicted, as the forming of an angle or the flattening of a wall, explaining, when done, that that which had been intended has been accomplished. They will stand for no awkwardness or fumbling but admire exactness and precision and are the class which will reward the dentist most liberally for painstaking efforts and actual achievements. This class make the day long but they serve to stim-

ulate the dentist to his best efforts and work to the advancement of the really progressive operator.

The Irresponsible Individuals who have no mental or physical stamina require a strong hand to control them in any emergency in life. They go to the dentist only when forced there by pain or are children brought by their parents. While a dentist should never be harsh with any patient, yet this class will necessitate, many times, stern commands, and a "why, of course" method. In cases of this character where the operator has chosen to assume the role of a disciplinarian, the stern proceeding should universally be tempered with the kindest of tones before the patient leaves the chair, that he may depart with the impression that the dentist is kind of heart and has been severe only for the patient's good.

The Naturally Cowardly Patient who is strong, healthy and robust, yet lives in mortal dread of any physical discomfort, is the hardest class to manage. This class of patients have generally been raised in luxury and taught by example made possible by their environment, that they should not even be inconvenienced. They seldom work and mistake that tired feeling for sickness. To be hungry, cold or warm, is described by them as "simply terrible." With such, often the best an operator can do is simply to temporize to keep the teeth comfortable. To attempt thorough work merely drives them away to seek gas for painless extraction.

The Patient Who Simulates Pain should be early detected and severely dealt with. An operator should remember that a large amount of the gesticulation, grabbing the working hand, cringing and outcry, is simply voluntary on the part of many patients to inform the dentist that he is hurting them. Most of this can be done away with by the following procedure:

First tell the patient that "this will not hurt you," and then proceed to make the statement true by working on enamel margins, even to gently scratching on the external surface. Then state to the patient that "this may hurt a little" and the operator can proceed to test the dentine for its sensitive portions. He may then proceed to do the less painful parts of cavity preparation. Lastly when it comes to cutting the angles and cutting sensitive portions the patient should be warned that this particular place may be sensitive but that a certain amount of cutting is necessary. Advise the patient to hold still for just a second or two and then he will be allowed to rest. Caution him against moving during this brief period as it will undo what has been accomplished, necessitating his withstanding the pain again. Praise the patient for his bravery when he has

complied with the request and advise him as to the work accomplished. All this instills confidence into the patient as to the dentist knowing what he is about and as to his knowledge of the place and time that pain may be expected. Nothing unnerves a patient so much as to get the slightest idea that the dentist is not aware of the pain he is inflicting or that he has little care for one's sufferings and has no definite idea as to when it will end.

The True Simulator of Pain will try to make the operator believe he is causing pain when he is not suffering at all, with the idea that the dentist will be frightened into extreme care in his case. This class is easily detected by scraping an instrument on a surface where pain is impossible, as the external surface of a tooth. If the demonstrations continue it is the operator's duty to inform the patient of the detection of the attempted deception and that such will not be further considered, at the same time advising him to save his demonstrations until he is hurt when they will be considered, and every effort made to lessen the pain.

The Agents for Relief of Sensitive Dentine are:

First—Those which produce a physical change in the contents of the tubuli, as desiccation, heat and cold.

Second—Those agents which destroy or disorganize the contents of the tubuli, as caustics and escharotics.

Third—Those agents which, when applied, to the dentine, locally or hypodermically produce a condition of analgesia or absence of sensibility to pain, termed local anesthetics, and anodynes as phenol, menthol, morphine, oil of cloves, cocaine and novocain.

Fourth—Those agents administered with the view of reaching the nerves of the pulp through the general system as bromide of potassium, nitrous-oxide chloroform, etc.

Fifth—The mechanical condition under which the cutting of sensitive dentine is done.

Physical Agents.

Desiccation Is a Physical Agent of great virtue in alleviating hypersensitive dentine and accomplishes the result by extracting the moisture from the tubuli, which is a large constituent of the protoplasm.

This Is Best Accomplished by first flooding the cavity with absolute alcohol which has an affinity for water, and then directing into the cavity a continuous stream of warm air which is more effective if the temperature can be controlled so as to gradually raise it to the highest point tolerable to the patient. Painless cavity excava-

tion can be accomplished to the depth of desiccation which will vary with different cases.

A Continuous Stream of cold air will have a similar action through its desiccating effect and is practiced where compressed air is at hand. The force with which the air is contacted with the cavity walls is a factor in its efficiency.

Heat and Cold When Moist will produce physical changes in the protoplasm of the tubuli sufficient to destroy the sensation of pain.

In any locality of the body a moderate rise in the temperature, particularly moist heat, quickens vital action and heightens functional activity. This is true of sensitive dentine and the temperature must be materially raised before a stage of paralysis is reached.

The Best Means of Applying This Method is to direct into the protected cavity a forceful fine stream of water which can be gradually raised in temperature to the point of toleration, cutting the sensitive part of the cavity while the stream of water is still playing on the point being operated upon.

With the Application of Cold to any part, vital phenomena of every nature is retarded and entirely ceases with the lower temperatures.

The Best Method of Applying this principle is to spray the cavity with a highly volatile liquid as ethyl chloride, sulphuric ether, and its combinations with chloroform. The rapid evaporation lowers the temperatures, extracting the heat from that with which it comes in contact.

The Primary Pain in Applying these agents may be lessened by filling the cavity, temporarily with stopping, directing the spray first on this and the surrounding parts and later removing the stopping, directing the spray into the cavity without causing much pain, provided there is not a hyperemic pulp within the tooth, in which case all thermal changes must be avoided.

The Electric Current (Cataphoresis) as a physical agent to obtund sensitive dentine should be mentioned. It has been used to assist in carrying various drugs into the dentine, to facilitate their activity, but its use has proved so unsatisfactory, in many ways, that further description of this method is unwarranted.

Destroying Agents.

Caution in the Use of Caustics and Escharotics to relieve sensitive dentine in deep-seated cavities will save much pulp complications and great care must be exercised in their use not only for the safety of the pulp but also the soft tissues about the tooth must

be effectually protected. Many caustics are not limited in their action and when once applied on the dentine continue their destruction to the envelopment of the pulp. Arsenic trioxide is a notable example of this.

Zinc Chloride is one of the oldest and most efficient remedies for hypersensitive dentine. Its action is due to its affinity for water and its coagulating properties upon albumen.

The Danger in its Use in deep-seated cavities is through the liberation of hydrochloric acid, which causes pain in case of a nearly exposed pulp. This effect may be modified by using it in a solution of one part chloroform and four parts alcohol. Add the zinc crystals to the proportion of five grains to the ounce. Clarify by adding a drop of hydrochloric acid.

The Methods of Using Zinc Chloride are:

First—Saturate a pellet of cotton with the above solution, place in the cavity and evaporate with a draft of warm air from the warm air syringe or chip blower.

Second—Mix a thin paste of zinc oxychloride cement. Paint the sensitive dentine with this cement and cover with stopping or gutta-percha. After a few days or weeks, often, excavation may be accomplished with little pain.

Caustic Potassa and Carbolic Acid, equal parts (Robinson's remedy), often relieves sensitiveness of the dentine and is applied by placing a pledget of cotton in the cavity, always with the rubber dam in position to protect soft tissues.

Silver Nitrate may be employed to good effect upon exposed surfaces of dentine in the posterior parts of the mouth, such as those on the occlusal surface of molars due to abrasions, or exposed cementum. It reduces sensitiveness and by forming the albuminate of silver it retards decay even so far, in some cases, as to render the surfaces to which it has been applied immune to caries. On account of its discoloring effect its use is not permissible in parts exposed to view.

Formaldehyde. Formaldehyde is a protoplasmic poison and is a great desensitizer. The author called the attention of the profession to this method at the World's Columbian Dental Congress in 1893 in a paper before that convention. However, its irritating effects are sometimes injurious to the pulp and great care has to be exercised in its use, particularly that there is not a near pulp exposure. It is of advantage if the material can be so combined as to cause a slow liberation of the formaldehyde, which materially lessens danger to the pulp and pain from its application.

Local Anesthetics and Anodynes.

Novocain stands first as a local anesthetic to desensitize dentine. The methods of using novocain for sensitive dentine are slow absorption and injection by pressure, in the tooth and hypodermically. (See Chapter XLII.)

The Slow Absorption Method is best practiced by putting into the cavity a one-sixth grain tablet of novocain; over this place a pledget of cotton which has been moistened with the normal salt solution, and proceed to fill tooth with stopping, seeing the cavity again for excavation in twenty-four or forty-eight hours.

Pressure Anesthesia of the dentine may be accomplished in two general ways. The dentine should be thoroughly sterilized, the above application of novocain in the normal salt solution made, over this a piece of unvulcanized rubber placed, and all crowded into the cavity with as much force as the patient will permit.

High Pressure Syringes are sometimes of service to simply desensitize the dentine, but their use for this alone has never become general practice, due to the danger of pulp infection.

Phenol (known to the laity as carbolic acid) is a valuable remedy for hypersensitive dentine, as well as for materially lessening the pain caused by the blast of air from the chip blower, and should never be forgotten when the patient complains of the air causing pain. In addition to coagulating the albumen in the tubuli it possesses analgesic properties.

The Method of Using Phenol for sensitive dentine is to carefully desiccate the dentine with alcohol and warm air, applying a pledget of cotton saturated with the phenol, directing thereon a current of warm air until the cotton is nearly or quite dry. This should be repeated as often as the case demands.

Oil of Cloves is a valuable remedy in this respect and the method of its use is the same as that just described for phenol.

Oil of Cloves and Phenol Combined, as two parts phenol and one part oil of cloves, applied to the dry open cavity and evaporated therefrom, with the current of warm air, is more effective than either the phenol or oil of cloves alone. This method with these agents has to recommend it the fact of being a good means of sterilization, it is a pulp pacifier in deep cavities, and no injury can reach the pulp, provided the temperature of the current of warm air is not too high.

Through the General System.

Potassium Bromide in 5-grain doses three times a day for forty-eight hours previous to a sitting at the dentist's will do much to remove the nervousness caused by the fear of the intended visit and serve to minimize the pain to be endured.

Nitrous Oxide when properly administered is of great value and efficiency. It should be combined with oxygen or compressed air in proper proportions. So combined and administered, it may be given for a protracted period, long enough to prepare one or more sensitive cavities without pain to the patient and in most cases with no danger to health or life.

Somnoforme. Somnoforme when administered through a special apparatus is one of our most efficient means of rendering the patient semi-conscious and practically immune from any pain of dental operations. In the administering of this as well as other anesthetics for analgesia, all of the rules pertaining to the administration of the same anesthetic for major operations must be observed as the same danger to life exists.

Chloroform Slowly Administered and only to the first stage of anesthesia is a most valuable means of dealing with severe cases. This is particularly true of the A. C. E. mixture (alcohol, chloroform and ether, equal parts). The primary effect is to paralyze the sensory nerves, as the ends of the fingers, the skin and mucous membrane in general and this is true in the tooth's pulp with the fibers ending in the odontoblastic layer of cells wherein abundant sensitiveness has been developed.

The Method of Administration is quite the same as that for any other operation except that it is not carried past the first stage of anesthesia. All that part of the preparation of the cavity not producing pain is carried out, after which the dental chair is tipped back to as recumbent a position as will admit of operating. A napkin is then spread over the lower part of the face, leaving the eyes uncovered. The chloroform, or better the A. C. E. mixture, is added, first slowly a drop or two at a time and carried to the point where the patient feels a tingling sensation in the finger tips or expresses the fact that they begin to feel the effects of the drug. The anesthetic should never be crowded or confined while the patient can smell the chloroform, but can be pushed more rapidly when the olfactory nerves have been paralyzed, so that the sense of smell is lost, and it is not long thereafter until the dentine can be excavated painlessly. As soon as the operator begins to operate the assistant should

hold to the nostrils a large-mouthed bottle of the anesthetic to prolong the stage of anesthesia reached. At no time should the patient be sufficiently under the influence of the anesthetic to be unable to converse coherently or intelligently answer the questions put to him.

It must be remembered that any anesthetic has its dangers, particularly when its use is abused, but the above method can be recommended as comparatively safe. One writer reports its use in over 20,000 cases without ill effects. It is true that a large per cent of the cases wherein death has resulted from the administration of chloroform or ether have occurred in the first few breaths, as we believe due to a strong mixture used at first or before the nerve filaments of the air passages have been anesthetized.

If a few breaths administered as above, by the open method, proved fatal, literature would be replete with long accounts of druggists, physicians, dentists and others having met death by smelling of opened bottles of these drugs.

Rapid Breathing as a means of producing peripheral anesthesia should receive consideration, not only for hypersensitiveness of the dentine but for other minor dental operations as the use of hypodermic needle, lancing of abscesses and extraction of teeth. The anesthetic effect is brought about by superoxidization within the tissues caused by charging the blood with an abundance of oxygen.

This Method Is Employed by instructing the patient to take deep, long breaths as rapidly as possible and continue the same until a sense of dizziness is brought on, when from thirty to sixty seconds of the anesthetized condition will be found available for operating.

Mechanical Conditions.

The Mechanical Conditions under which the cutting of dentine is done is a great factor in the amount of pain produced.

Sharp instruments which cut without pressure upon the contents of the tubuli cause much less pain than dull ones even with hand instruments. With rapidly revolving engine burs this is also true to say nothing of the heat produced by the friction caused by rubbing surfaces which are worn away rather than cut, which is the chief source of pain in the use of burs.

The Cutting Should Be Done as much as possible at a right angle to the long axis of the tubules rather than to follow their course with pressure towards the pulp or in a line with their long axis.

CHAPTER XXXIV.

PROTECTION OF THE VITAL PULP.

The Normal Pulp has no tactile sense, neither is it responsive to thermal changes even though they vary considerably from the body temperature.

When Robbed of Its Normal Covering and Protection the reverse of the above conditions quickly develops. The sense of touch becomes very acute and any contact with foreign substances causes great pain. This is best illustrated when a tooth is broken through its crown by a blow, thus exposing the pulp. At first the pulp may be touched with the finger or an instrument without the knowledge of the patient but in a very few minutes the same will cause unbearable pain. Also at first the cold air does not affect the pulp, but, coincident with the development of the tactile sense, comes a repugnance to the cold.

The Chief Idiosyncrasy of the Pulp is its response to thermal changes and especially to cold, when these changes are rapid or the pulp is in any way hyperemic. A normal pulp will tolerate without response quite a range of temperature when the change is brought about slowly. This is generally the case when the pulp is covered with the full crown of the tooth. But when, through decay or other causes, this covering is all or partially lost, the changes are so rapid that the peculiar responsive features spoken of are developed.

The Recuperative Powers of the Pulp are very slight, the least of the soft tissues of the body, as it will regain a healthy condition from only the initial stages of disease. It will many times make a feeble effort to protect itself when the irritation is mild by filling up the dental tubuli with calcic matter or a secondary construction of dentine, through the activity of its odontoblastic layer of cells. Even this reparative process must not be vigorously inaugurated or the death of the pulp will result, proving that these reparative measures on the part of the pulp are pathological, rather than physiological in nature.

The Protection of the Pulp from its greatest enemy, sudden thermal changes, is most essential and as most of our desirable filling materials are good conductors of heat and cold it becomes necessary to place some substance which is a poor conductor between the filling and the dentine, this operation being termed "capping the pulp."

The Indications for Pulp Protection are not always clear, but will involve a consideration of the age of the patient, extent of loss of dentine, location of the cavity in the tooth, location in the mouth, length of time the pulp has been exposed, the stage of hyperemia, the general health of the patient and the possibilities of pulp infection.

The Age of the Patient has a bearing on the successful issue of a conservative treatment, as the teeth of the young are more easily saved from further irritation through capping than are the teeth of those past middle age, while at the same time they demand capping more frequently under the same conditions. Again, the pulp should be saved if possible until the teeth are fully formed, and many times the teeth of the younger patients are badly decayed and the pulp in great danger before the teeth are complete, hence if the pulp can be conserved and devitalization avoided, it is of great good to the patient.

In Advanced Age the apical openings become smaller and many become much contracted, barely accommodating the vessels with a normal flow of blood so that a very slight congestion may cause death from strangulation or gangrene.

When a Large Amount of Dentine Has Been Lost, even though the pulp as yet seems normal, it is safe practice to avoid the placing of the best conductors, as gold or amalgam, in close proximity to the pulp as repeated shocks to the pulp through the filling from thermal changes may bring on hyperemia of that organ. In the use of phosphate of zinc cement in such cases, there should be an intervening media to prevent the irritating effect of phosphoric acid.

The Location of the Cavity is a factor in the demands for pulp protection, as well as the probability of success in extreme cases. The first portions of the pulp to show hyperemic conditions are those nearest to the point of irritation. These congestions are more dangerous when they appear in the body of the pulp, as they do where decay approaches the pulp in the gingival third. Hence, when a pulp is nearly exposed in this location it demands greater protection and is at the same time harder to save than when the horns of the pulp are involved.

The Location of the Tooth should be considered. Anterior teeth are subject to greater extremes of heat and cold than are the molars, hence the demand for preventive protection with the anterior teeth should be remembered. At the same time their exposed position makes pulp-capping more hazardous and it should be practiced with great care in this location. Again, less risk should be taken in the

capping of pulps in the anterior portion of the mouth as it is better to remove a number of questionable pulps than to have one die in the tooth with its consequent discoloration.

The Length of the Time the pulp has been exposed to the irritating influences is to be taken into account as the shorter the time of exposure, the greater the probabilities of success in capping.

The Stage of Hyperemia should be a safe criterion where there are actual pulp complications, as there will be in almost every deep-seated cavity. In active hyperemia, from causes other than bacteria, it is safe to protect the pulp from future irritation and insure its conservation. However, when the symptoms of passive hyperemia have developed it is not safe practice to attempt to restore the pulp to normal and expect permanency.

The Symptoms of Active Hyperemia when the pulp demands protection and success may be expected are:

First—When the excavated cavity exposed to the air causes a continued pain not of a throbbing nature and the condition is relieved by packing the cavity with dry cotton.

Second—When a blast of air from the chip blower causes a quick, sharp, shooting pain which subsides as quickly as it came.

Third—When the pulp shows the power of accommodation as evidenced by tolerating a draft of cold air when the same is gradually applied.

Fourth—When it is improbable that the pulp has become infected.

Pulps Infected With Bacteria should be extirpated as too large a percentage of those exposed and capped die and thereby bring reproach upon dentistry in general and chagrin to the careful operator.

The time was when the profession attempted to conserve all portions of the pulp found to be vital, even to amputating the coronal portion and leaving intact the vital stumps. However, this was in the days of imperfect root canal treatment and filling and about as many abscesses followed one kind of treatment as the other. But at the present time the removal of a pulp is attended with such universal success that the capping of exposed pulps, in general, is unwarranted, as most pulps are infected at the time of exposure. Even in the case of an accidental exposure in the preparation of a cavity neither cavity nor instruments are surgically sterile.

The General Health of the Patient must be considered when choosing between the conservative or radical treatment of the pulp. With the same conditions presented, the pulps in the teeth of the anemic patient, those wherein the vital processes are at low ebb, or the

elimination of the vital ash is imperfect and cell metabolism is deficient, protective means of conservation are more imperative, while at the same time less risk should be taken in questionable cases.

With Robust and Particularly Plethoric Patients, all inflammatory processes run a rapid and riotous course, and when the pulp has taken on any stage of hyperemia changes towards dissolution are of rapid succession.

In Deep-Seated Cavities it is not unlikely that the thin layer of the dentine covering the pulp is infected and the pulp should be protected from the invasion by the thorough disinfection of the overlying dentine by medication, previous to filling as well as placing next to the dentine in question and under the filling a permanent dressing which will exert a mildly antiseptic influence for some time following the operation.

The Requirements of the Materials Used in Protective Procedures Are:

First—That they shall be poor conductors of heat and cold.

Second—That they shall be non-changing in character, both as to consistency and bulk.

Third—That they have no action upon the pulp.

Fourth—That they may be introduced into deep seated cavities without pressure.

The Materials Advocated for This Purpose Are Numerous and the market is flooded with preparations of a secret nature which are warranted to save the pulp in almost any stage of dissolution, but the operator who pins his faith to such slipshod methods will sooner or later find that he has been duped and his grief is measured by the extent to which he has employed these cure-all methods.

There Are Four Distinct Classifications wherein success may be expected in methods of pulp protection. The treatment of each class is here given.

First Class. In the Progressive Stage of Caries wherein but little dentine has been lost, yet a blast of air from the chip blower causes a quick, sharp pain, passing off as soon as the draft of air is checked, we find the simplest form demanding protective measures. This is the class most often neglected by the operator and many times irreparable injury is done a pulp by placing in such a cavity a filling of high conductivity, such as gold or amalgam. The patient often believes that "cold water leaks in about the filling" and may visit another dentist thinking that he has a poor piece of dentistry, and the patient may be lost to an otherwise good operator, all through the neglect of what may appear to the operator as a trivial matter.

The Treatment of the First Class is the thorough disinfection and then the application of phenol, full strength, for a few seconds, when the cavity should be dried and it will be found unaffected by the blast of air from the chip blower. The change is brought about by the superficial coagulation of the albumen in the exposed ends of the dental tubuli which renders them non-conductive.

Second Class. If, after one or two applications of the phenol as above, the distress from the blast of air is not relieved, or if the pain is continuous while the surface of the cavity is exposed to the air it is probably of the second class as met with in the nearer approaches to the pulp. This class of cases demands a media intervening the dentine and the filling.

The Treatment in the Second Class is as follows: Moisten the cavity with phenol and evaporate to comparative dryness. Then paint the entire dentinal walls with a cavity varnish composed of copal and gum dammar in alcohol and ether solution. Such a preparation can be had at the dental depots or it can be prepared by the druggist. This should be thin and spread evenly, applying one, two or three coats and drying with a draft of air from the chip blower after each coat. When the varnish is entirely hardened the filling may be placed.

Third Class. In the deep-seated stage of caries, where large quantities of dentine have been lost, even though the pulps may seem to be protected by secondary dentine that is much retracted, it is not safe to place a metal filling directly on the overlying dentine. The lost tooth structure should in a measure be replaced with a material which is not a better conductor of thermal changes than dentine. This should be neutral as far as irritating properties are concerned, non-changing and should resist the force necessary to properly introduce the intended filling.

The Treatment in the Third Class is as follows: Phenolize and dry. Varnish with the above cavity varnish and dry. Flow over the dentine, covering most if not all of the axial or pulpal wall, or both, according to the class of cavity being treated, a thin layer of oxyphosphate of zinc cement, being careful not to include thereunder any air bubbles; also apply without pressure. Then allow this to set to complete hardness, when the filling may be completed. In the three classes given above it will be noted that coagulation of the protoplasm in the exposed ends of the tubuli was the first step. This is good practice from the fact that this layer of coagulum is the least irritant to the remaining protoplasm of anything of which we have knowledge. Phenol is very limited in the extent of its action

and this layer of coagulation is very thin. Again, with this third class, it will be noted that in addition to the use of the phenol the cavity is given a coat of varnish before applying the oxyphosphate of zinc cement. This procedure is to prevent the irritating effects of the phosphoric acid, particularly while the cement is setting. Again, should the zinc contain any impurities their action on the pulp is prevented. One of the impurities of zinc is arsenic and some cements are thought to contain traces of this devitalizing agent. The cavity varnish given above is quite impervious to this element when it has been thoroughly hardened, a fact which should not be overlooked when it is desired to prevent the action of arsenic trioxide in a particular direction in a dental wall.

Fourth Class. In deep-seated cavities where there is a slight pulp complication from thermal shock and where the thin overlying layer of dentine is probably infected to some depth and more deeply affected in the process of caries, the dentine should be subjected to quite a continued disinfecting process and a portion of the lost dentine restored with a non-conducting material to shield the pulp from sudden thermal changes.

The Treatment in the Fourth Class of cases is as follows: The cavity should be flooded with a non-irritating antiseptic, as eampho-phenique, pure beechwood creosote or oil of cloves. If sealed in the cavity for twenty-four hours the result will be much better. The cavity should be then wiped dry with absorbent cotton and a thin paste of a cement containing sulphate of zinc spread over the dentine overlying the pulp. This paste should be thin enough to flow to position when coaxed with a small instrument, yet thick enough to prevent its spreading to surfaces not needed. Over this spread a layer of oxyphosphate of zinc cement and allow this to set hard before completing the filling.

In very questionable cases, the entire cavity may be completed with the cement and the patient dismissed for six months, at the end of which time, if the pulp is found to be normal, a portion of the cement may be removed and replaced with a more permanent material.

Pulp Preservers and So-Called Mummifiers should be avoided. Even their name is misleading and such preparations are used without permanent success in the majority of cases. Their use simply proclaims their users as unskilled laggards who will accept an uncertainty to avoid a little honest labor in pulp extirpation and root filling. The entire procedure is diabolical and cannot be condemned

in too severe terms as a retrogression in dentistry, unskilled in principle and unwarranted in practice.

Gutta-Percha as a Protecting Covering is not a success from the fact of its great range of contraction and expansion under varying thermal changes. When enclosed under a perfectly tight and unyielding filling, as all fillings should be, the change in bulk must have a piston-like effect upon the contents of the dental tubuli resulting in continued irritation.

CHAPTER XXXV.

PULP DEVITALIZATION AND REMOVAL.

The Reason for Devitalization and Removal of a pulp is its present unhealthy condition or when its future health is in danger, on account of environment in the way of dental operations.

There Are Two General Causes of diseased pulps.

First. That succession of tissue changes which has its origin in active hyperemia and its end in death due to the presence of bacteria or their products—inflammation.

Second. Reparative congestion, due to traumatic injury, abnormal thermal stimuli, lack of normal thermal stimuli and peripheral nerve irritation.

Bacteria and Their Products may enter the pulp tissue either through a loss of its normal covering, the dentine, as in the case of deep-seated caries, or through the general circulation by way of the apical foramen, as in pyorrhea alveolaris, or in other pus conditions in close proximity to the pulp vessels. We have no means of knowing that a pulp thus invaded has recovered, while we have complete proof of their subsequent death from this cause, hence devitalization is indicated as soon as diagnosis is clear.

The Removal of the Cause in reparative congestion of the pulp will generally suffice to save the pulp from further destruction provided the intervention is in the stage of active hyperemia.

The Traumatic Injuries most common in the production of pulp congestion are blows upon the teeth either through accident or excessive malleting in dental operations; rapid movement by the orthodontist; abnormal stress in occlusion or articulation; malocclusion and abnormal movement of the tooth in its alveolus made possible by the loss of supporting structures.

Abnormal Thermal Stimuli is a most potent factor in producing pulp congestion. The pulp is particularly and peculiarly susceptible to thermal changes and this idiosyncrasy is very rapidly magnified as the stages of congestion progress.

The Reason for Abnormal Thermal Changes reaching the pulp is the loss of its natural covering, the dentine and enamel, through caries, erosion, abrasion or dental operations as well as the denuding of the root by a recession or loss of the sub-gingival structures.

Lack of Normal Thermal Stimuli will induce a stagnated circulation with a sequela of degenerative changes within the pulp tissues,

resulting, many times, in the death of that organ. While the pulp is profoundly affected by abnormal exposure to heat and cold it is eminently essential to its normal physiological existence that it receive the stimulating effects of the ranges of temperature usually found in food and drink while covered with the entire tooth.

Peripheral Nerve Irritation may bring about reparative congestion within the pulp causing excessive tissue waste and a precipitation of lime salts within the pulp. There are two classes of these deposits, known as calcific degeneration and pulp nodules, the latter being the sequela of peripheral irritation, while calcific degeneration is the result of little local passive hyperemias with its cause related to abnormal thermal changes.

The Irritation May Be in the terminal fibers of the nerves within the pulp where the nodules are found, or in an approximating tooth, or in a tooth in the same lateral half of the jaw or face. Cases are reported where it is evident that the cause is even more remote than has been stated, it being a local expression of a general neurotic condition.

The Requirements of a Devitalizing Agent are:

First. That the present and future health of adjacent tissues be maintained.

Second. That it act painlessly.

Third. That the dentine is not discolored.

Fourth. That devitalization be accomplished promptly, resulting in a saving of time to both the patient and operator.

The Methods of Pulp Devitalization practiced at this time are two: Surgical amputation while anesthetized and poisoning by the application of arsenic trioxide.

To Determine the Method to employ in any given case requires an understanding of the pulp presented, its immediate surroundings, and results sought. Also the time at the disposal of patient and operator. While each of the two methods has its advantages, either can be so used as to meet the requirements of a satisfactory means of devitalization.

Anesthetization of the Pulp is accomplished by forcing into the pulp either a solution of cocaine hydrochloride or novocain popularly known as "pressure anesthesia."

Anesthetization Is Indicated:

First. When it is desired to remove a normal pulp.

Second. When slight exposure of the pulp exists which has not yet reached the stage of passive hyperemia.

Third. Pulps whose circulatory system is active, but whose nervous system is either deficient in development or is in the stages of neuromyolysis. Access to the tooth is a factor to be considered and will result in the more frequent use of this method with the anterior teeth. The possibility of securing a sterile field of operation must be considered as an advantage.

The Technic of the Operation where a cavity exists is as follows: Apply the rubber dam. Excavate the affected dentine. Sterilize the remaining cavity. Place in the cavity over the pulp a small pellet of cotton saturated with either cocaine or novocain. Apply over this a piece of unvulcanized rubber which will approximately fill the cavity and with blunt instruments, as amalgam packers, gently force the mass in the direction of the pulp. It is essential that the rubber first come into contact with the cavity margins at all points, or the fluid will not be confined and its escape renders the attempt a failure. If the first pressure of the confined solution upon the pulp causes pain the operator should stop increasing the pressure, but hold the advantage gained by not releasing the pressure already applied. When, after waiting a minute or two, the pressure may be increased and finally the rubber can be kneaded into the cavity with considerable force. Sometimes one application thus made will completely anesthetize a pulp. However, other cases will require two or more applications. Between such applications the dentine should be removed from over the pulp to complete exposure where this can be done without undue pain to the patient.

When, after two or three attempts of the above method there seems to be no effect obtained, it is generally best for both patient and operator to resort to the application of arsenic, unless the case is suited to favor the use of the high pressure syringe.

The High Pressure Syringe is of service where no exposure exists, and where the necessary puncture for the introduction of the syringe point can be included in the filling, or where the crown is to give place to an artificial one as an abutment for a bridge. The method has to recommend it speed, a certainty of preserving the color and is generally accomplished with little or no pain to the patient.

The Technic in Its Use. To the prescription given for the open cavity add fifteen drops of distilled water and load the syringe, seeing that all joints are screwed up tight. Select a point of direct access either on the dentinal walls or it may be on the external enamel surface, preferably in the gingival third of the tooth, and drill a hole directly towards the pulp one millimeter in depth and as much

farther as possible without causing the patient pain. The drill used should be smaller than the syringe point that a close fit to the hole may be secured. Syringes are generally constructed so that a drill made by flattening a No. 1-2 round bur will make a proper sized hole. The syringe is then applied to the opening with some pressure and its contents forced into the dentine.

It is essential that the solution be perfectly imprisoned as it requires high pressure to force the anesthetic through the tubuli. After holding the solution at high pressure in contact with the dentine for one or two minutes it should be removed and the drill applied to the hole to test its sensitiveness. If desensitized the hole should be carried close to the pulp but not so far as to enter the chamber. The syringe should be again applied and with great care, as sudden force may cause pain by too rapid pressure upon the pulp.

Great Care Should Be Exercised when the pulp has been thus nearly or quite exposed not to force into the pulp any considerable amount of the anesthetic as it is carried or forced beyond the apical foramen, from which no good can result and harm may, particularly if the contents of an infected pulp are forced through to the tissues of the pericementum.

Pulp Extirpation by Hypodermic Injection. Pulps may be removed very quickly and without pain by injecting the solution of novocain as given for use in extracting teeth in Chapter XLI.

If Correctly Done the Pulp May Be Removed or the tooth extracted painlessly. Extreme care as to asepsis must be given. This danger of infection makes this method unsuited for general use, but applicable to cases where haste is imperative or where trouble is experienced in the use of pressure anesthesia or arsenic devitalization.

The Removal of an Anesthetized Pulp is accomplished by gaining access to the pulp chamber from a position which will admit of direct or nearly direct approach to each of the pulp canals, and making the opening large enough to admit light enough to see either by direct vision or the image in the mirror, the entire floor of the chamber. First, a smooth sterile broach is passed down each canal to the apex of the root, to test the completeness of the anesthetization. If no sensation is found the barbed broach is then passed to the apex, preferably an extra fine size. This should be twisted to the right about one complete turn and then gently drawn from the cavity, which should result in the amputation and removal of the entire pulp. This accomplished, the sides of the canal should be rasped with a barbed broach of a larger size to remove any shreds which may adhere to the sides of the canals.

To Check Hemorrhage, should that ensue, wash the chamber and canals with cold water, dry as quickly as possible, flood cavity with a drop of adrenalin chloride and apply a plug of dental rubber, pressing this into the cavity and holding it for a few minutes. Remove the rubber and wash again with cold water. If hemorrhage continues repeat holding the adrenalin confined longer than before and applying a little more force. Care should be used in this procedure as a sore tooth will result when the method has been used too vigorously. Again thoroughly bathe the canals with cold water or alcohol and dry.

Discoloration Results from allowing any blood to remain in contact with the dentine, even though it be only from one treatment to another as the iron of the hemoglobin is absorbed or forced into the tubuli resulting in permanent discoloration. *The use of hydrogen dioxide* is not good practice until the blood has been washed from the dentinal walls as it oxidizes the iron of the hemoglobin and discoloration will result.

Post-Extirpation Pains may be prevented by pumping into the canals phenol with a smooth broach continuing this until the nerve stump at the foramen is bathed with this agent. This also has the effect of coagulating the mouths of the dental tubuli, resulting in sealing them to agents which may cause discoloration.

It Is the Best Practice to Dress the Canal or Canals for a few days with a stimulating anodyne which is at least mildly antiseptic, as the anesthetizing of the pulp has probably so much affected the tissues in the apical space that there is nothing to guide us in properly filling the pulp canals.

Immediate Canal Filling in these cases is sometimes practiced where lack of time demands a hurried completion of the case and is quite successfully accomplished where all is just right. But so many times ideal conditions for canal filling are not obtainable that its universal practice is condemned. However, if there is to be immediate canal filling the pulp canals should be bathed with water and dried with warm air, flooded with phenol and again dried, this time with the aid of absolute alcohol, when the canal filling may be introduced as outlined in the chapter on "The Filling of Pulp Canals."

Devitalization With Arsenic Trioxide is the method in most frequent use and although not always to be preferred to anesthetization, it may be used in almost any case with satisfactory results.

Arsenic Should Be Combined With Some Agent to allay the pain

LEWIS STOCK SQUARE

caused by its application as it is a most powerful escharotic and the clear arsenic applied to a pulp will often cause great pain. One of the most popular mixtures is here given :

Arsenic trioxide	gr. v.
Cocaine	gr. xv.
Creosote	Q. S. ft. stiff paste.

To this should be added enough lamp black to make the above a dark gray color so that it will have a contrasting color with that of the tooth to assist in placing it in the exact location desired.

The Technic of its application is as follows: The cavity should be thoroughly protected and dried, preferably under the rubber dam. Foreign matter should be removed from the cavity and the same thoroughly sterilized, the softened dentine removed and the pulp approached to as near exposure as possible without causing the patient pain. Complete exposure is not necessary. Again sterilize the cavity and dry. Bathe cavity with phenol and again dry. With the enamel hatchets secure a definite cavity margin, particularly if cavity is in the gingival third. In cavities that are sub-gingival build in amalgam as high as the gum line or at least one or two millimeters high, being sure not to let this approach the pulp exposure or the point where the application is to be made. Take, of the above paste on the point of a flat excavator, a quantity equal to about one-fourth the size of a common pin head and apply very close to, but not directly on the exposed pulp. By very close is meant within one-half millimeter. Place over this a piece of spunk the size of a pin head, or larger if cavity is large and roomy, which has been dipped in creosote and then pinched in a napkin to dryness, putting into place in such a manner as not to cause pressure on the pulp. The retaining filling may now be completed with amalgam, cement or temporary stopping.

Amalgam as a Retainer of arsenic has the advantages of making a tight filling at the margins. Nothing will pass through it and it is the most easily removed if it is applied where there are frail overhanging enamel walls which a chisel will easily cleave; or if the amalgam has been but partially mixed with not enough mercury, resulting in a mealy filling or where a great excess of mercury has been used, that is to say where a most poorly manipulated amalgam has been used resulting in its being cut with a bur much more easily than cement, an advantage in cases where a tooth becomes sore to percussion.

Cement as a Retainer of arsenic has the advantage of setting quickly, thus removing the danger, in occlusal cavities, of the patients causing themselves pain by biting on the fillings and producing pressure on the pulp. With anterior teeth it is more slightly than amalgam or stopping. Its only disadvantage is that it sometimes sets so well that it is hard to remove and its adhering properties may result in dragging or lifting the application from its placement, during the manipulation of introduction.

Temporary Stopping as a Retainer of arsenic has to recommend it the ease of its removal with warmed instruments and especially if its surface has been treated with a blast of warm air. The dangers in its use lie in the difficulty in preventing pressure upon the pulp either when applied or in mastication.

Cotton as a Retainer of arsenic should be entirely discontinued as it has nothing to recommend it and everything to condemn it.

Caution in the Use of Arsenic about the teeth is of great importance and when used it must be sealed in the dry cavity absolutely moisture proof and particularly when any of the cavity outline is sub-gingival as any leakage at this point will result in great destruction to the gums and alveolar process. Such accidents are all too frequent and the injury thus done is never fully repaired.

The Length of Time an Arsenical application should be left in the tooth is most uncertain and there seems to be no set rule. Neither the condition of the pulp nor the amount of dentine intervening can be taken as certain in judging the time. However it is most common practice to see the case in about one week's time, as in this time a majority of the cases will have become devitalized and the natural process of exfoliation has taken place between the dead pulp and the living tissues at the apex of the root enabling the operator to remove the pulp without pain or hemorrhage.

Primary Soreness of the Tooth to percussion generally indicates the death of the pulp. If an attempt is made to remove the pulp too soon great pain will result as the pulp is yet vital, hence it is best to wait until the pulp has been fully affected. Again during the primary soreness and particularly during the first twenty-four hours of this condition the patient cannot tolerate the instrumentation necessary. Such cases should be left from twenty-four to forty-eight hours from the time pericemental soreness develops, having applied to the gum over the afflicted tooth aconite and iodine when it will generally permit of treatment.

Secondary Pericementitis is dangerous to the sub-dental tissues

and no arsenical application should be allowed to remain until this second attack appears, as the loss of the tooth is not beyond the possibilities of such neglect.

The Treatment of Arsenical Poisoning due to its escape from the cavity is as follows: Remove everything from the tooth cavity. Flood the cavity and destroyed tissues with a forceful stream of tepid water to remove all traces of the arsenic not yet absorbed. With a sterile spoon excavator dissect and curet away all necrotic tissue continuing until hemorrhage is produced. Again flood the parts with warm water. Dry with a cotton ball and lightly paint the wound with aconite and iodine, repeating the treatment every other day until a healing is effected.

When Pulp Returns Partially Devitalized as is evidenced by sensation, particularly in the apical third of the canal, it is best to open the pulp chamber and amputate with a sharp spoon excavator only the coronal portion. Wash chamber with warm water and dry with warm air. Apply absolute alcohol working same towards the apex by the side of the pulp as far as possible without causing pain, following this with thorough desiccation with warm air. Then seal in a dressing of phenol and dismiss for one week or even longer and the case will usually return with devitalization complete. This treatment is particularly indicated in young teeth where the apical foramen is large.

The Removal of the Pulp following arsenical devitalization is practically the same as that following anesthetization, except that in the latter case there is danger of going beyond the apex, while with the arsenic devitalization method, the greater danger is in not extirpating the pulp entirely to the apex through mistaking a vital pulp stump within the canal for vital tissue beyond.

Immediate Canal Filling following arsenical devitalization is quite universally practiced and is generally satisfactory. However, too large a per cent is followed by mild or severe pericementitis, which might be averted by dressing the canals with a mildly anti-septic anodyne of a stimulating nature for a few days before filling the pulp canals.

All Treatments Above Referred To in this chapter should be carried out with the rubber dam in place at each sitting. (See chapter on "The Filling of Pulp Canals.")

CHAPTER XXXVI.

MANAGEMENT OF PUTRESCENT PULP CANALS.

By "**Putrescent Pulp Canals**" is meant that condition in these spaces resulting from putrefaction.

By "**Putrefaction**" is meant that serial, progressive decomposition through which albuminous substances are finally resolved into the end-products, hydrogen sulphid (H_2S), carbon dioxide (CO_2), ammonia (NH_3), water (H_2O), and hydrogen phosphid (PH_3). A distinguishing feature of the process is the evolution of malodorous gases.

The Presence of Bacteria is necessary to the process of putrefaction and all such cases must be approached with this fact in mind, and antiseptic measures and precautions are paramount from the beginning of the case to its termination, that the pericementum may not be involved in the destructive process.

There Are Four Classes of Putrescent Pulp Canals, according to the manner in which they are presented, symptoms present and the method of treatment.

First. Those cases where the canals are open and exposed to the fluids of the mouth known as "open putrescence" and which are generally the result of the encroachment of caries.

Second. Those cases wherein the pulps die under a filling or a layer of affected and infected dentine, the integrity of which will not permit of the passage of fluids or gases. This is known as "closed putrescence" and is the result of extrinsic infection.

Third. Those cases wherein the crown is integral and the bacteria necessary to putrefaction have entered the pulp tissue either before or after its death by way of the apical foramen, conveyed there by the circulation of the blood. This class of cases, from the apparent autopathy is termed "autogenous putrescence." Such cases are most likely to follow suppurative processes in close proximity to the arteries leading to the pulp, yet cases are seen where no such conditions can be diagnosed, primary to the pulp symptoms, and are generally traumatic.

Fourth. Those cases wherein the destructive processes have been communicated to the pericementum, and are known as "complicated putrescence." There may be pericemental inflammation in any of its stages with or without soreness to percussion. The apical space may harbor pus without other communication than the putrescent

pulp canal or there may be an abscess with a sinus passing through the alveolar process and opening through the gum.

Treatment in General may be stated as involving the removal by mechanical and chemical means of all products of putrefaction, thorough sterilization of all surfaces exposed, conservation of vital tissues beyond the apical foramen and the permanent closure of the foramen to the passage of fluids and gases.

The Symptoms of Open Putrescence (Class One) are not marked where the pulp is entirely putrescent, unless there are pericemental complications, when the case would come under the heading of complicated putrescence. When a portion of the pulp is yet vital it is probable that the pulp is undergoing a cellular disintegration through surface ulceration. This is usually a painless process and is responsive only to the encroachment of foreign substances which lacerate its tissues or produce pressure within its substance. Such cases call for sterilization and extirpation. However, with simple open putrescence the symptoms are largely objective, the operator discovering the conditions through instrumentation, and the noxious gases encountered.

Treatment of Open Putrescence. Excavate the cavity to complete exposure of the pulp chamber. Flood with a stream of water from the syringe. Apply the rubber dam and sterilize all teeth and surfaces exposed. For this purpose use a ten per cent solution of formaldehyde to which has been added a small amount of borax. Another efficient sterilizing agent is bichloride of mercury, in the proportion of one part to five-hundred of cinnamon water. Mechanically remove the contents of the pulp chamber and flood the open cavity with hydrogen dioxide, repeating the dioxogen two or three times or until active effervescence ceases. Apply absolute alcohol and evaporate to complete dryness. With an extra fine barbed broach mechanically clean each root canal with hydrogen dioxide. Care should be taken not to force any of the putrescent matter through the foramen. Remove the contents of the canal, portion by portion. The canals should then be dried with alcohol evaporation. Follow this with a fifty per cent solution of sulphuric acid which is allowed to remain three or four minutes when it should be thoroughly diluted with water and the canals dried. Apply campho-phenique and desiccate to dryness. For the final dressing flood with phenol, pumping it to the apex of said canal with a smooth broach. To this add a paste made by mixing iodoform with phenol sufficiently stiff to be handled to the cavity on a large spoon excavator. If crystallization takes place add a drop of water. Avoid glycerine or alcohol. By a

pumping motion of the broach the paste will be thinned and follow the phenol already in the canal to the apex.

By alternately adding the paste and absorbing the excess phenol the canal can be filled with a comparatively thick paste. Fill the pulp chamber with a pellet of dry cotton. Seal the cavity with temporary stopping or cement, preferably for a week or ten days, when the case will almost invariably return ready for permanent canal filling. If a shred of vital pulp is encountered in the apical third it will have been devitalized by the phenol and that without pain or noticeable soreness.

The Chief Objection to This Form of Treatment is the obnoxious odor of the iodoform. The deodorized preparations, however, will not accomplish the desired results. Care should be taken that the iodoform is kept moist at all times and finally deposited in the fountain spittoon. Each teacher has a different treatment for putrescence and the student is advised to familiarize himself with all. However the above is a one-sitting, successful treatment and its trial is advised particularly where other methods have resulted in pain to the patient and oft-repeated visits to the dental chair.

In Cases of Long Standing Putrescence, which are generally open cases, the dentine is thoroughly saturated with poisonous ptomaines, amido acids and end products. These must be gotten rid of and the most expedient method is to chemically change these irritating gases and poisonous liquids into non-irritating and non-poisoning liquids and solids. This is most successfully done through the use of formaldehyde. Formaldehyde, however, is very irritating to vital tissues and should not be brought into contact with them. Therefore its use is contraindicated in cases of large apical foramen. Also not indicated in cases where a portion of the vital pulp remains, as many times intense pain will be induced. To modify the irritating effects there may be added to a ten per cent solution of formaldehyde an equal bulk of either phenol, creosote, or creosol, the latter being preferable. This should be sealed in the cavity and crown ends of the canals for twenty-four or forty-eight hours before thorough broaching of the canals is attempted. Following the removal of the above treatment the canals should receive a bath first of water and then of alcohol to carry away in solution the compounds resulting from the chemical action of the formaldehyde.

Animal Fats, which consist of carbon, hydrogen and oxygen, are liable to be present in abundance in recent cases of putrescence and should be removed from the dentinal walls as they readily undergo fermentative decomposition.

Their Removal Is Best Accomplished by saponification through the action of sodium dioxide. This should be applied at the time of broaching the canals, using a platinum broach. Following its use the canals should receive a water bath.

Symptoms of Closed Putrescence (Class Two). Closed putrescence without complications is usually of short duration and when they are presented for treatment before complication there generally remains a portion of the pulp in the apical region yet vital.

The chief pathognomonic symptom is that heat produces paroxysms of pain while cold applications bring relief.

The Treatment for Closed Putrescence is to apply the rubber dam and with a small drill open directly to the pulp chamber when temporary relief will be immediate. The opening should then be enlarged and the necrotic pulp tissue removed. If no vital pulp tissue is found the case should be proceeded with as before outlined for cases of open putrescence. When a vital portion of the pulp remains nothing will be more palliative than the phenol and iodoform paste treatment already outlined. This paste will also devitalize the remaining portion of the pulp. Pressure anesthesia is certainly not indicated in such cases from the liability of infecting the pericementum. Neither is an arsenical application permissible within a pulp canal, hence the phenol treatment is the best practice.

Autogenous Putrescence of the Pulp (Class Three) are occasionally met with and may be of long standing without complications of the apical tissues and only discovered when the dentine of the crown is found to be non-vital. Such cases are generally of traumatic origin primarily, the putrescent condition developing long after the death of the pulp by the egress through the apical foramen of facultative anaërobic bacteria. Such cases are dealt with, when treated, as any case of closed putrescence, excepting that extra precaution as to access must be taken as the admittance of the air to such cases seems to render the putrescent matter most virulent and the dangers of complications are most extreme. Cases presented, of recent origin, which may be classed as autogenous are generally complicated when they come to the dentist as the complication is the cause of the patient's visit, when they would be classed as a case of closed putrescence. Their cause is the entrance of infection through the circulation, the bacteria having been picked up in pus areas not far distant from the apical foramen. Strictly speaking there are no autogenous diseases or conditions, such as auto-infection as all in this life is the result of ex-

trinsie causes more or less remote from the body but the classification of autogenous putrescence of the pulp is given, based upon the same theories and principles as those applied in general pathology, wherein the immediate cause is not at all apparent.

The Symptoms of Complicated Putrescence (Class Four) vary from slight soreness to percussion to the symptoms accompanying most violent and acute inflammatory processes even with general febrile disturbances. Other cases will present themselves with an entire absence of all the above symptoms, the only evidence of pericemental complications being detected by observation or instrumentation. It is generally true that the acute cases show the more marked symptoms, and the extremes of easy and difficult management are encountered, whereas with chronic complications the symptoms are not so marked and generally yield to stereotyped methods of treatment except where great destruction of tissue has taken place, where such cases should come under the head of surgery.

The Treatment in Complicated Putrescence is as varied as the symptoms presented and the conditions found. The first order of procedure is the removal of the cause which includes the elimination of the putrescent conditions within the pulp canal under aseptic precautions. If the pericementum is only inflamed and the presence of pus is not probable, the treatment is the same as that outlined for uncomplicated putrescence, adding external applications to the gum over the affected tooth to stimulate resolution. Painting with aconite and iodine is suggested.

In Acute Complication where pus has formed and upon broaching is freely evacuated down the pulp canal, it is the best of surgery to allow free drainage by this route for twenty-four or forty-eight hours before attempting further treatment. At the end of this time the most active symptoms will have generally subsided and the case can be proceeded with. However, there have been some cases so deeply affected beyond the apex of the tooth that external pointing on the alveolar wall is probable and only avoided by immediate extraction of the tooth. In such cases the salvage of the tooth depends upon the ability of the patient to withstand the pain to the termination. They may be assisted in this through the general administration of sedatives. Locally the application of re-ulsives to the gum will hasten the external pointing. Evacuation ushers in the stage of convalescence and the treatment of the pulp canals may be proceeded with.

In Chronic Complications of Putrescence where the drainage is through the pulp canal only, the case may answer to the treatment of the pulp canal. However other cases will demand special treatment for the sterilization of the enclosed pocket beyond the foramen. The greatest danger in the treatment of this class is in suddenly converting them into acute form. This can generally be avoided by attempting the treatment of the sub-dental conditions only following complete and absolute sterilization of the communicating canal. That there is a communicating canal in these cases of so-called "blind abscesses" is self-evident and this opening permits of treatment without the use of pulp canal drills, a method which is not advised and a practice wholly unwarranted, resulting, many times, in rendering the case beyond the possibilities of cure.

If the case must have additional drainage it is a case of surgical procedure and the point of attack should be through the external alveolar wall, a method sometimes resorted to with good results.

Chronic Alveolar Abscess With Sinus, generally with the opening on the external alveolar wall, is a complication resulting from a closed case of putrescence of long standing and when not associated with necrosis or denuded root is not, as a rule, hard to manage.

The Treatment of Chronic Alveolar Abscess is to thoroughly sterilize the pulp canal, then the fistulous tract. The tract should be established by forcing hamamelis or cassia water through the pulp canal and out through the sinus. Follow this with phenol or aconite and iodine only sufficient to cauterize the entire surface of the tract thus destroying the fibrous lining, improperly called the "*pyogenic membrane*." Then proceed as with any other case of putrescence, filling the pulp canal before closure of the sinus has been effected. Some advise the entire treatment and canal filling at the first sitting, but it is probable that better results will be obtained if case is allowed a week or ten days between the first treatment and the canal filling for complete sterilization of the dentine walls.

CHAPTER XXXVII.

THE FILLING OF PULP CANALS.

It Is Necessary to Fill Pulp Canals following the removal of the pulp, to prevent the exit of bacteria or their products to the tissues beyond the foramen, and to prevent the dissolution of the encompassing walls of dentine.

A Pulp Canal Is Ready for, and should receive the root filling when the canal is void of all else than air and it is not desired to again reach the pericemental tissues for treatment. To render a canal void of all else than air is by no means universally easy, yet it is the object sought and the conditions are not ideal until this result is obtained. This involves the removal of all pulp tissue, moisture, bacteria and their products as well as all medicines and chemicals used in the process of treatment.

The Perfect Pulp Canal Filling is one which permanently occupies the entire space of the pulp canal and closes the apical foramen to the exit or entrance of all substances, particularly gases and fluids.

The Requirements of a Material for Filling a Pulp Canal are that it be non-soluble in the fluids of the body, that it be non-irritating to soft tissues, permanent as to bulk and consistency, not subject to putrefaction or chemical changes, capable of easy introduction, and it is an additional virtue if it can be again removed from the canal after months or even years of occupancy.

The Objective Point in Pulp Canal Filling is in the region of the foramen. This point must be reached, made surgically and therapeutically clean, completely vacated and then permanently sealed with a suitable material.

Small Pulp Canals and particularly if they are tortuous, are a hindrance to always attaining ideal results and even, in rare cases, thwart effort to save teeth thus afflicted.

The Means of Cleansing and Vacating small and tortuous canals are both mechanical and chemical.

It Is Best Accomplished mechanically by the use of small, flexible, blunt-pointed twisted reamers, which enlarge the canal to the extent of entrance by cutting away the sides to increase their caliber until broaches of other forms will be admitted. This process is assisted chemically by flooding the canal with a fifty per cent

solution of sulphuric acid, as this will dissolve and soften the dental walls, thus facilitating the enlargement of the canals.

In Cases Where the Root Is Bent on Its Long Axis it is essential that the broach should be rounded and blunt of point that it may follow the canal and not cut its side wall at the bend of the canal, which will produce a shoulder and hinder further progress. This is essential with the finest of broaches and requires preparation on the part of the dentist of every broach used in this class of work, as all broaches that come from the factory have a very sharp point entirely unfitting them for opening crooked pulp canals. This blunting process is best accomplished by holding the end of the broach at an obtuse angle on the face of a fine cuttle fish disk while revolving in a dental engine, at the same time twisting the broach from right to left.

The Carrying of Cotton into a Pulp Canal is of assistance in the drying process and requires the special preparation of a broach to facilitate the application.

The Cotton-Carrying Broach is prepared by taking a perfectly smooth fine hook broach and by grasping with a pair of flat-nosed pliers, say the sixty-fourth part of an inch from the end, rocking the pliers back and forth until the end is broken off. This results in a blunt broken surface on the end which engages the fibers of the cotton twist and prevents same from slipping up the broach towards the handle, as it is introduced into the canal, allowing the cotton to be carried to the depth that the caliber of the canal will permit.

The Cotton Is Applied to the broach by taking a few fibers between the thumb and first finger, placing around the broach, twisting the handle of the broach to the right, and at the same time moving the thumb and finger to roll the broach in the same direction. The use of Red Cross absorbent points is better practice.

If It Is Intended to Leave the Cotton in the Canal as a dressing, roll upon the broach tightly at the point only, and when introduced to the entire depth of the canal twist the broach to the left part of a turn and use a tamping motion, and the cotton will be disengaged and packed in the canal.

If It Is Intended to Remove the Cotton With the Broach, roll tightly its entire length and when the cotton is being introduced, as well as during withdrawal, twist the broach to the right continuously, as this will cause the broach to maintain a tight hold on

the cotton. When all has been removed grasp the cotton between the fingers, twist broach to the left and cotton is easily disengaged.

The Most Popular Root Filling of today is gutta-percha, a portion of which is dissolved in chloroform to facilitate its introduction. However the less amount of chloroform or any other fluid there is in the finally completed filling, the better, as these constituents are not permanent.

Methods of Use. The canal must be entirely vacant except the air which it contains, for its entire length, not forgetting that this includes the removal of all moisture possible.

The First Step Is to Replace This Air with a fluid that is a solvent for the gutta-percha canal filling. A very popular substance for this purpose is the oil of eucalyptol as this, in addition to being a solvent for gutta-percha, is slightly antiseptic and, being an oil, does not mix with any blood serum or moisture that has, perchance, escaped the operator's notice in the apical end of the canal, or may have a tendency by capillary attraction to exude into the mouth of the foramen, floating the same from the walls.

The Introduction of Chloro-Percha is accomplished by dipping a small broach into the container and carrying the broach thus loaded, to each canal. Carry same to the foramen and by a pumping motion the chloro-percha is mixed with the eucalyptol, and no air or moisture will be imprisoned within the canal.

The Introduction of the Gutta-Percha Canal Point is here accomplished by grasping the large end, which may be flattened with the cotton pliers or attaching same to the warmed end of a canal plugger, then withdrawing the smooth broach which has been allowed to remain part way up the canal and immediately entering the small end of the canal point and shoving entirely to place by a steady gentle pressure.

The Size of the Canal Point should be great enough to entirely fill the canal. It should be about a millimeter longer to permit of slight tamping at the mouth of the canal. The size may have been previously ascertained by measurement and trial, which is good practice for a beginner. An experienced operator will, in most instances, be able to judge as to size without measurement.

Slight Flinching on the part of the patient or the sense of fullness is quite a trustworthy guide as to having reached the apical end of canal in recent cases of devitalization, but such symptoms should not be sought in devitalized teeth of long standing, particularly if there has been a loss of any of the tissue in the apical space. However, in these cases as with all others, care should be

taken that perfect and complete filling of the apical foramen has been accomplished, which is ideal. Yet to fill slightly beyond the canal by a fraction of a millimeter is a less error than to not entirely fill the canal. The opening of the canal should now be tamped solid, which process is aided by warming the protruding end of the canal point.

Cleanse Pulp Chamber of all traces of gutta-percha and case is ready for final operation.

The practice of filling pulp chambers with gutta-percha in any form is condemned as it is in no way suitable for the seat of a filling. Cement, amalgam or tin is preferable.

CHAPTER XXXVIII.

MANAGEMENT OF CHILDREN'S TEETH.

The management of children's teeth presents two difficulties additional to the management of the teeth of adults.

The First Difficulty and many times the most important is the management of the child. Children are very susceptible to external influence and even when quite young believe all they hear. The conversation of the older ones about the home pertaining to the "horrors" of the dental office, has many times so poisoned the mind of the child that it prejudices the dentist and his efforts to the extent of preferring any other punishment rather than meet the dentist, even for an examination.

The First Visit of a Child should be made one, wherein there is an entire absence of pain, or even inconvenience on the part of the child.

Such visits should be repeated till absolute confidence has been secured. After this has been thoroughly established, the children of a clientele will prove as easily managed as the adults, and in after years are the most tenacious patrons, seldom changing their dentist through life.

The Second Difficulty with the management of deciduous teeth is the comparatively short life of the most careful operations. The teeth are themselves but temporary. All about them is a panorama of change and we can hope at best for only temporary results. Parents should be given to understand this feature of the services and not be led to misjudge the skill of an operator by the results of operations on the teeth of children.

Early Attention is imperative and the keynote to success. All small enamel defects should be sought out and fillings made as soon as such are found to exist. It is hopeless to attempt the salvage of deciduous teeth after the pulps have become involved and subdental disorders have been established.

Oral Hygiene With Children should be established early. The parents should receive thorough instructions as to the use of the toothbrush, with or without a dentifrice, as the child prefers, and a daily attention established by the time the full temporary denture is erupted.

Frequent Visits to the Dentist are essential; even more than with adults, as the destructive process runs a rapid course when

once established, a few weeks' neglect often resulting in irreparable injury. These visits should be established at regular and frequent intervals, as the most unhygienic conditions may result from only a few days' neglect and upon early detection and eradication depends the success of interference.

Length of Time at Each Sitting should not exceed thirty minutes for a child under twelve years of age and should not exceed one hour until after eighteen years of age. Great care should be exercised in causing the child any considerable amount of pain. Better that the filling consist of temporary stopping to last but a few days than to cause lasting memories of dental pains inflicted by the dentist.

The Filling Materials to Be Used are limited to those of speedy manipulation, and those requiring a minimum of convenience form. This will place in the list, amalgam, tin, gutta-percha and cements.

Cavity Preparation should be limited to the removal of the major portion of decay, sterilization and securing the cleavage of the enamel in cavity outline by the use of the chisel. All else should be avoided.

Extension for Prevention, Extension for Resistance, Flat Seats for Fillings, Line Angles and Point Angles and all else in cavity preparation so carefully applied to filling the teeth of adults should be ignored when dealing with deciduous teeth. If decay has not left the cavity naturally retentive, cement should be resorted to instead of cutting.

Cavities of Class One. Pit and fissure should be filled with amalgam or tin under as dry conditions as can be secured without the rubber dam. The use of the rubber dam should be restricted to the six anterior superior teeth and when used should be very loosely ligatured.

Cavities of Class Two. Proximal cavities in molars should be filled with amalgam. When the retentive form is not good in the cavity without much cutting, the amalgam should be laid in soft cement.

When Two Cavities Exist in molar proximal space which are not retentive it is good practice to fill the two cavities as one, counting on refilling the cavity in the second molar if the first molar is lost early, or perchance when this has failed, which it will sooner or later, the cavities will return with independent retentive form.

Cavities of Class Three should be filled with cement with rubber dam in position. If decay has progressed till angle is lost or partially so, do not build to contour but fill as a Class Three.

Classes Four, Five and Six may be ignored.

Treatment of Exposed Pulp in Deciduous Teeth. Pulp devitalization with deciduous teeth should never be attempted. Pressure anesthesia will not prove successful. Arsenic should never be applied to deciduous teeth. The risk is too great and is condemned in every case. If the pulp is exposed and aching, clean out the debris, flood with warm water, dry and phenolize. Apply a pledget of cotton saturated with oil of cloves for twenty-four hours. When case returns, dry and again phenolize and apply a paste of phenolized iodoform over which place a filling.

If the pulp has begun to suppurate, the necrosed tissue should be cut away and the space filled with a paste made of oil of cloves and the oxide of zinc powder, over which is placed a filling of temporary stopping. The pulp will usually die under this without further pain.

When the case returns, which should be in about two or three weeks, the canals should be cleansed and filled with a paste made from campho-phenique and iodoform and cavity filled with a plastic filling.

Treatment of Abscessed Deciduous Teeth. Such teeth should be allowed or assisted to point externally, as they will generally have progressed almost to the stage of pointing before the dentist is visited.

As soon as the active stage has subsided, the case should be given the above treatment for putrescence and filled. If abscess persists, as will occasionally be the case in spite of all methods, a small hole should be bored in the buccal surface just sub-gingivally to the pulp chamber, leaving the filling in place.

Inter-Proximal Grinding is of service when filling is out of the question. This is practiced much after the same method it was used in primitive days with the permanent teeth.

The proximal surfaces are cut away so that they are non-retentive to food particles and the sides of the remaining surfaces thoroughly exposed to the excursions of food in mastication. With anterior teeth the contact point is thereby moved to near the gingival line. With posterior teeth the contact point is removed as far to the buccal as possible by widening the lingual embrasure at the expense of both approximating teeth. This method is unsightly in the anterior teeth and not altogether without its objec-

tions when used on posterior teeth, but it is nevertheless good practice in many cases as it materially retards the process of decay.

The Management of Permanent Teeth in Childhood constitutes one of the greatest trials of dental practice and is at the same time of the utmost importance. These teeth are erupted at a time of life when the oral conditions are the most favorable to decay. Again these teeth are expected to give their user the longest period of service of any of the entire set of permanent teeth.

It Requires Extra Vigilance on the part of the dentist to prevent irreparable injury to the first permanent molars, as the parents are not usually aware that permanent teeth are present at this age and do not assist the dentist in detecting incipient decays. More is expected and required of the first permanent molar than any other tooth. It must stand the onslaught of the most unhygienic conditions.

It must give its possessor longer years of service and that in a position in the mouth most often subjected to the stress of mastication. Slight faults in enamel should be sought out early and filled with amalgam to be changed for gold in more mature years. When badly broken down they should be restored to full contour with amalgam and crowned only when the second permanent molar is fully in position. If gold is used, it should be in the form of the inlay under about fourteen years of age as the tooth should not receive severe and prolonged condensing force till certain of full development, which is from ten to fourteen years with the first permanent molar.

Treating First Permanent Molars. In treating and filling the root canals of these teeth before fully developed, the apical foramen will many times be found quite large. In some cases the circulation is so great that devitalization is most difficult. In uncertain cases it is well to use a medicated root canal filling that is easy of removal and instruct patient to return in a few months or perhaps a year for final filling.

A Good Root Filling for Such Cases is phenolized iodoform for the canals, topped with gutta-percha base plate for the pulp chamber and covered with amalgam. When the case returns it will generally be possible to determine the length of the root and size of the foramen when a correct root filling of ehlora-percha will be possible. In applying arsenic for devitalization in teeth that have not fully developed as may be expected from their age, *great care should be exercised*, as there is great danger of apical arsenical poisoning which nearly always causes the speedy loss of the tooth.

CHAPTER XXXIX.

EXTRACTION OF PERMANENT TEETH

General Consideration. Under normal conditions tooth extraction is not a difficult operation. However, there is no oral surgeon even of experience who meets with universal success. There are abnormal conditions which render unsuccessful any attempts at removal by ordinary means; but if the patient is placed under an anesthetic there are instruments manufactured and competent and able surgeons to handle them, that can remove the tooth entirely, and if need be the entire maxillæ with it. Yet there is a limit to all operations.

There is a time to stop. All oral surgeons have had the same experience, finding cases where the unavoidable injury to the tissues in removing the tooth would do more harm than allowing a small part of the tooth to remain. To the laity, however, the skillful extraction of a tooth seems "quite a trick." For instance, the blacksmith or a man of great strength, who has not made a careful study of the teeth and their environment, may attempt to extract the tooth and fail. One who has made the subject a study, although possessed of far less strength, removes the same tooth skillfully and seemingly without the exertion of much muscular effort. Unless the force is properly and scientifically applied, it accomplishes nothing but injury. If the force is applied in a proper direction, with proper movements, the dislocation of a tooth is quite an easy matter. The old saying that there is no rule without an exception, and that the exception proves the rule, will apply to the rules for extraction; for there is probably as much difference in the formation of teeth and adjacent structure as in the facial expression of different persons. Therefore it is difficult to formulate any rules which we can follow literally in all cases. Still the extraction of teeth is best accomplished by the application of scientific principles.

These principles properly applied will give better results than extracting the teeth merely to get them out. For this reason we must study that which we wish to accomplish and how best to accomplish it, by considering the various shapes of that part of the teeth which cause their retention in the jaw; also the structures, strength and position of those tissues which hold the teeth in place.

Principal Retention. The constricted portion of a tooth at its

neck serves to retain the tooth firmly in the alveolar process, and constitutes its principal retention, by the process grasping the tooth at this point, assisted by natural adhesion of the tissues.

Opening Mouth of Alveolus. The alveolar process is just a little thicker or heavier at the neck of the tooth than just below. The gingival part of the alveolus, the tooth's socket, is called the mouth of the alveolus. This mouth once opened, which can be accomplished by slight fracture at this point, the removal of a normal tooth is made easy.

How Can This Best Be Accomplished? By application of force in the line of least resistance. This varies in different teeth, owing to the difference in anatomical structure, the number of roots and direction of eruption.

Three Forces Are Applied in the Extraction of a Tooth: Traction, Rotation and Pressure.

Traction is a pulling force; rotation is a motion, given the hand in using a screw driver, but moving the hand first in one direction then in another. Pressure is the force we would apply to a tooth in endeavoring to push it in or out of the mouth at an angle to its long axis.

Position and Movements. If the patient is of mature years and as is often the case possessed of as much or more strength than the dental surgeon, it is very essential that we consider position and movements and that we have so calculated these matters that the patient is at all times fully under the control of the operator. It is not well to give the patient to understand that we think this particular tooth is a very difficult one to extract, or that we are in the least timid about performing the operation.

Securing Patient's Confidence. After it has been decided to extract the tooth, the more precise and deliberate the operator's actions, the more confidence the patient will have, hence a firm but gentle hand instills into the patient's mind confidence in the operator's ability. In giving the positions of the patient and operator, it is assumed that the latter is right handed. If such is not the case, the positions would be reversed.

Position of Patient's Head. The patient's head should be inclined backward. It should be firmly fixed and absolutely under the control of the operator. This can be accomplished in different ways in the absence of a dental chair with its head rest and other conveniences, in which case the operator may be compelled to resort to very primitive means.

With All Superior Teeth the operator should stand back of the patient and a little to the right, placing the crown of the head against the chest of the operator, putting the left hand around to the left of patient's head with the index finger holding the lip away

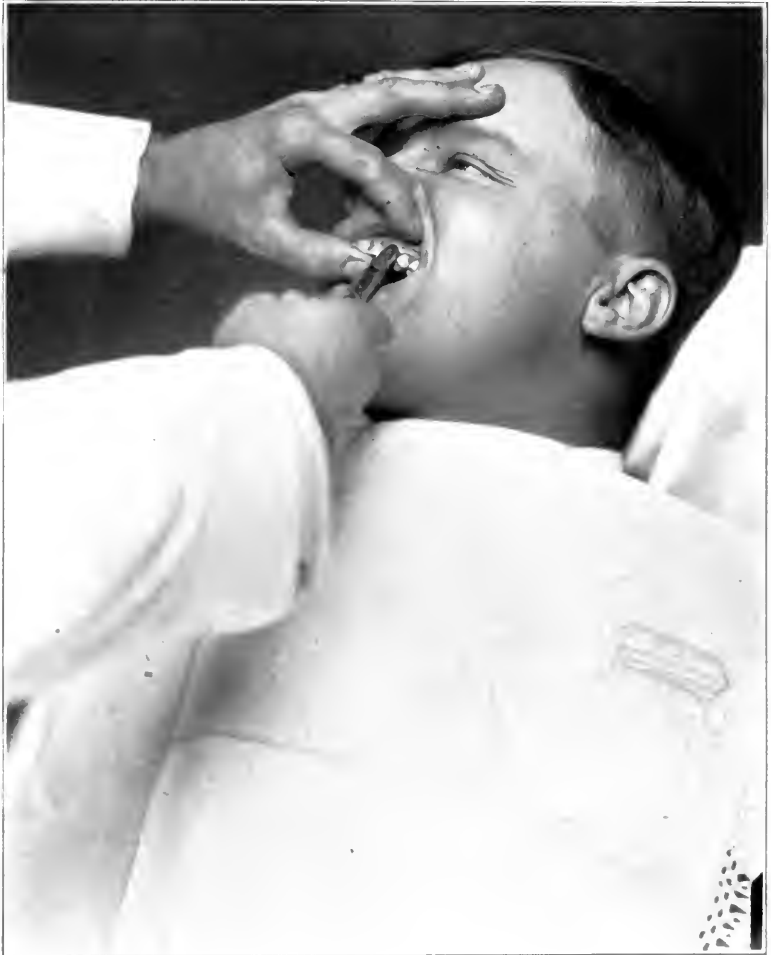

Fig. 109.—An improper position with the operator doing his work at arm's length.

from the alveolar process and at the same time lying against the process, to detect at once any extensive injury which might result from a fracture. The middle or second finger should be placed back of the forceps when the tooth is on the left side; or against the palatine process when the tooth is on the right side. Then by

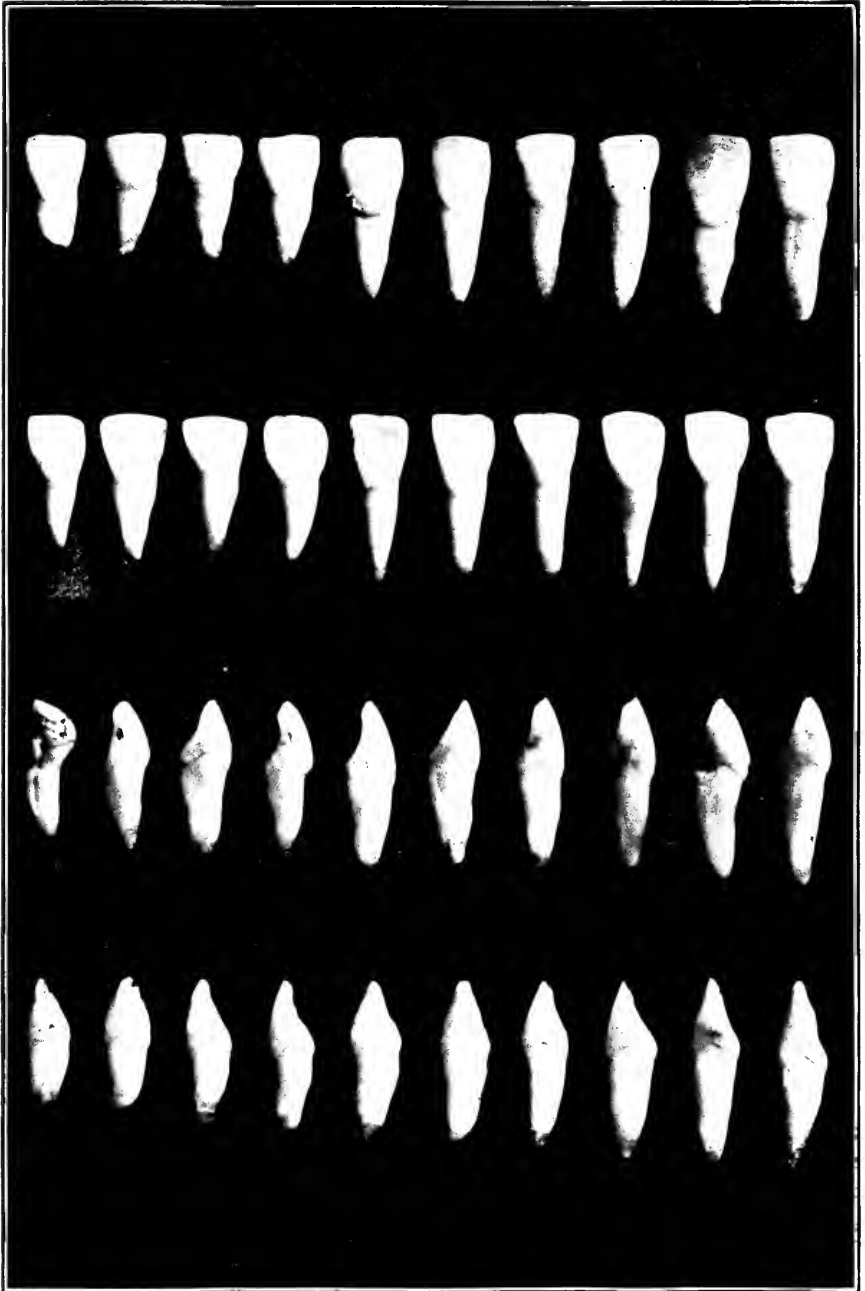


Fig. 110.—Types of superior central incisors. The first row shows the labial, the second row the lingual, the third row the mesial, and the fourth row the distal surface. (From Winter's *Exodontia*.)

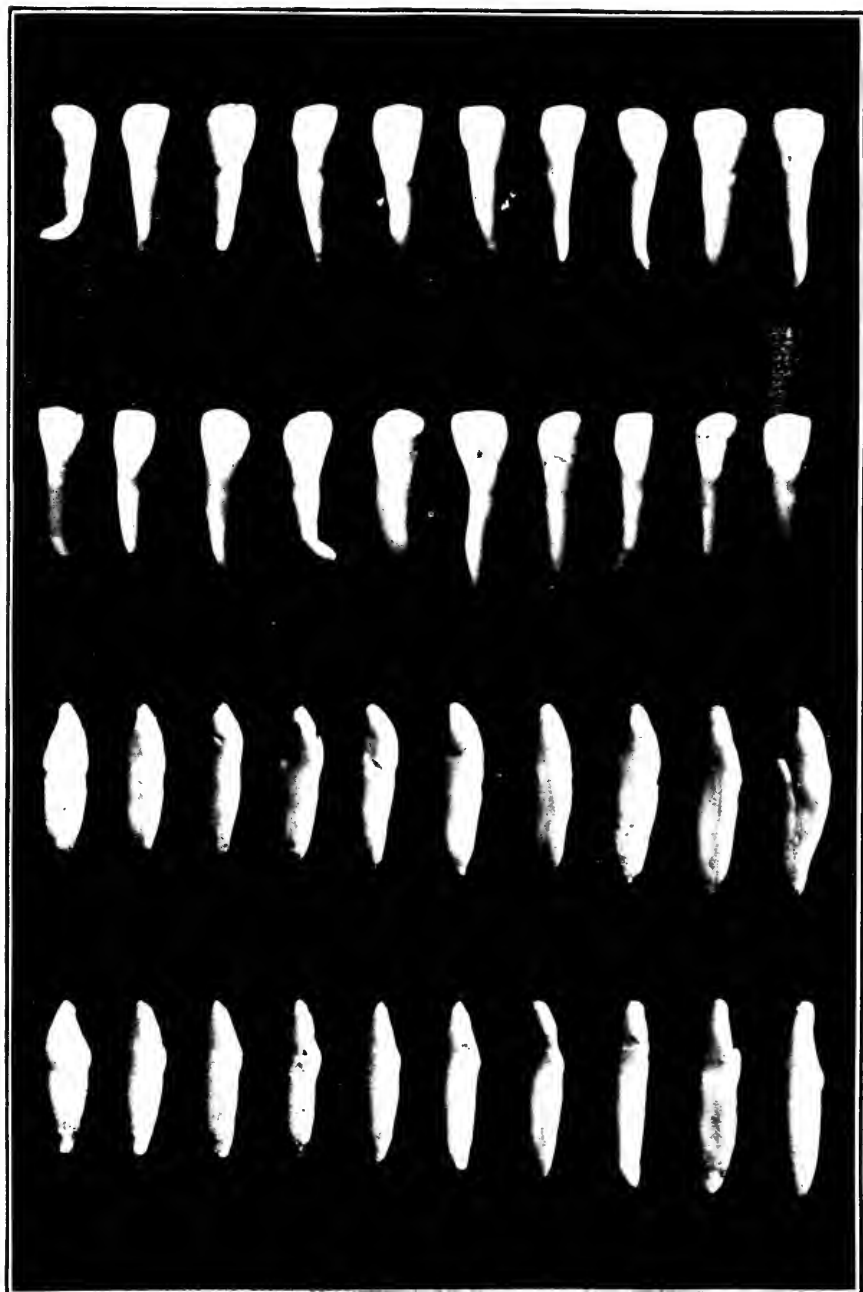

Fig. 111. Types of superior lateral incisors. The first row shows the labial, the second row the lingual, the third row the mesial, and the fourth row the distal surface. (From Winter's *Exodontia*.)

pressing the patient's head firmly against the head rest, or against the operator's chest, if using a low chair or stool, it is entirely from under the control of the patient, when inclined in a backward position.

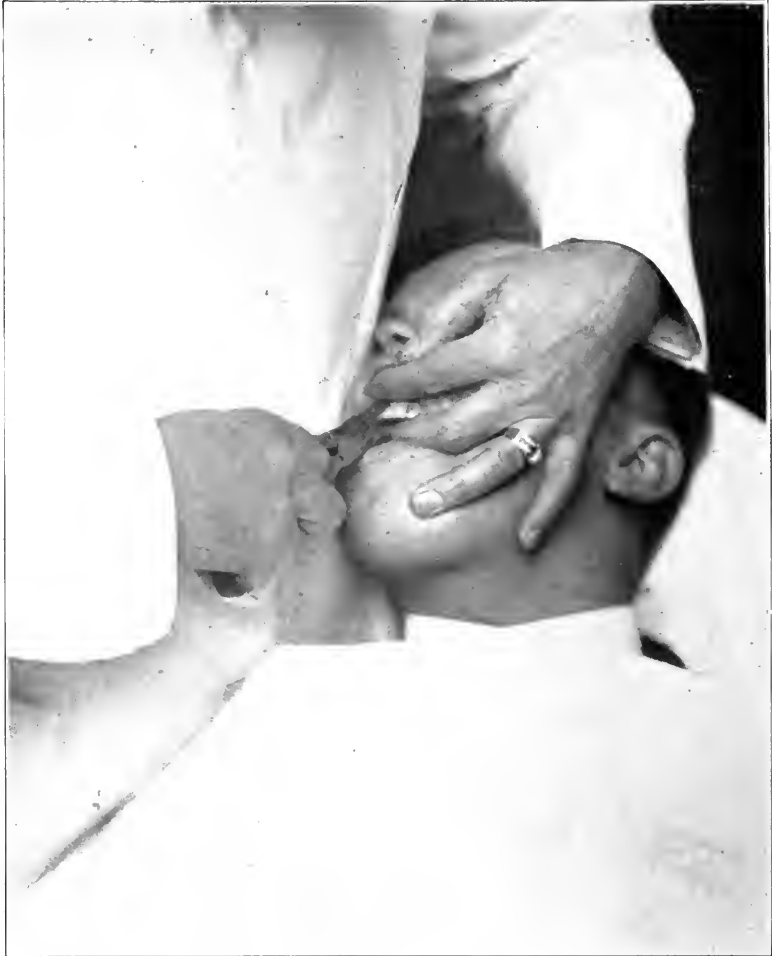

Fig. 112.—Position for extracting superior incisors.

The Position in Extracting the Lower Teeth is nearly the same, except that the relative position of patient should be lower. The general position for all inferior bicuspids and molars is the same as for the superior. In extracting inferior incisors and cuspids stand directly behind the patient, and use a straight or bayonet-




Fig. 10. Types of anterior teeth, (1) lateral incisor, (2) central incisor, (3) canine, (4) premolar, (5) premolar, (6) premolar, (7) premolar, (8) premolar, (9) premolar, (10) premolar. The second row the lingual, the third row the facial. (From Winter's, *Exodontia*.)

shaped forceps, such as are used in the extraction of superior incisors. The patient's head should be the height of the operator's waist line, he standing directly back of patient.

Position of Hands. The index finger should press down the

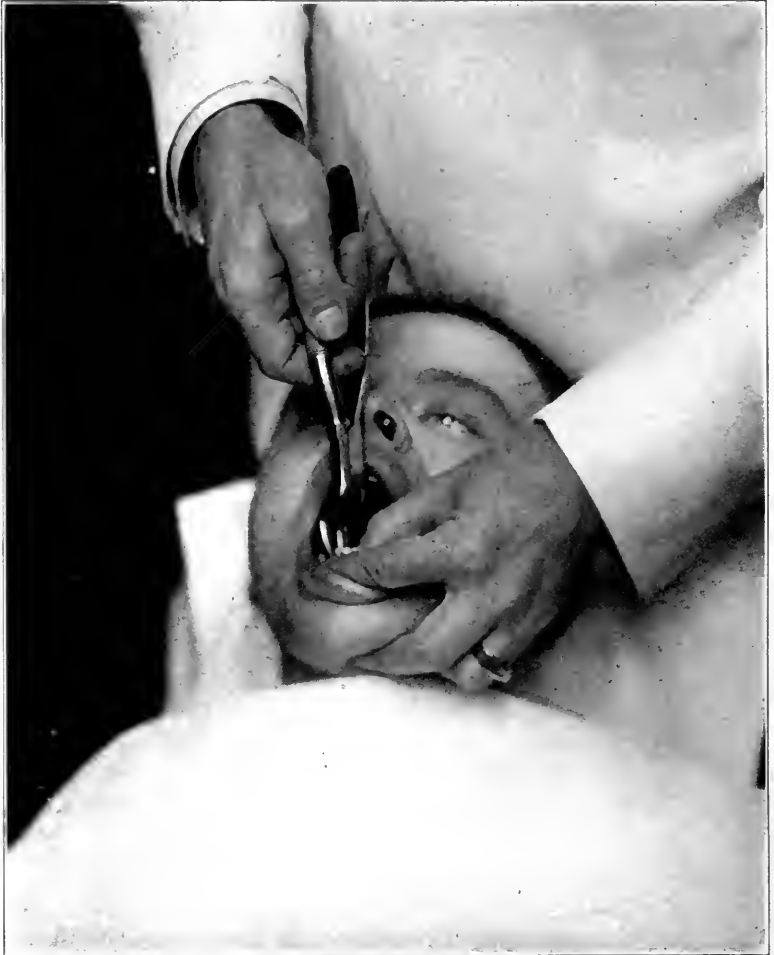

Fig. 114.—Position for extracting lower incisors.

lower lip and inspect the alveolar process. The thumb should be placed on the lingual surface of the process and the three remaining fingers should grasp the chin firmly, that the lower jaw may be fully under control.

Operating at Arm's Length. In no case leave your patient or

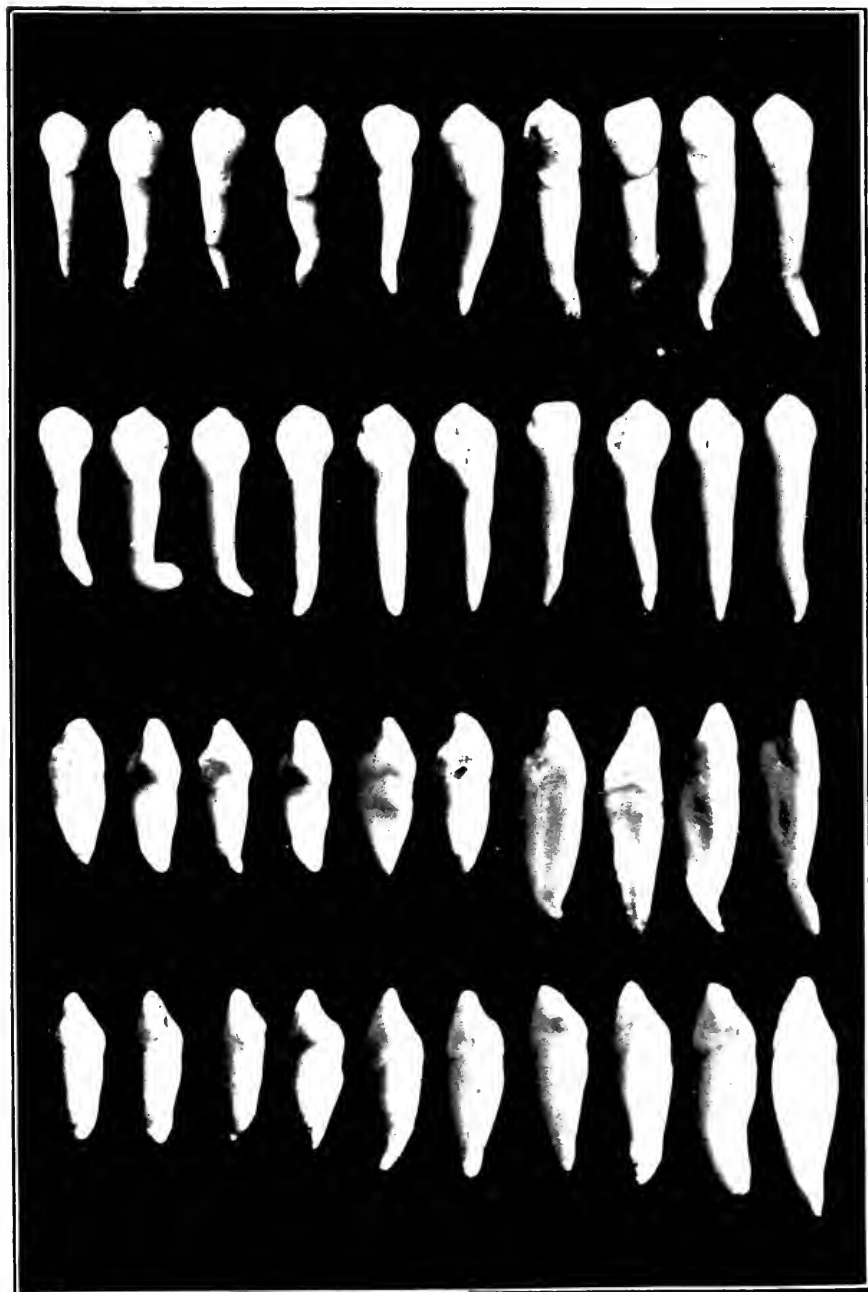

Fig. 115.—Types of superior cuspids. The first row shows the labial, the second row the lingual, the third row the mesial, and the fourth row the distal surface. (From Winter's *Exodontia*.)

step in front of him, using the hand and your forceps at arm's length, for with the head at liberty a sudden twitch or jerk on the part of patient would either destroy or misguide the force applied and either thwart the effort to remove the tooth or, perhaps, by

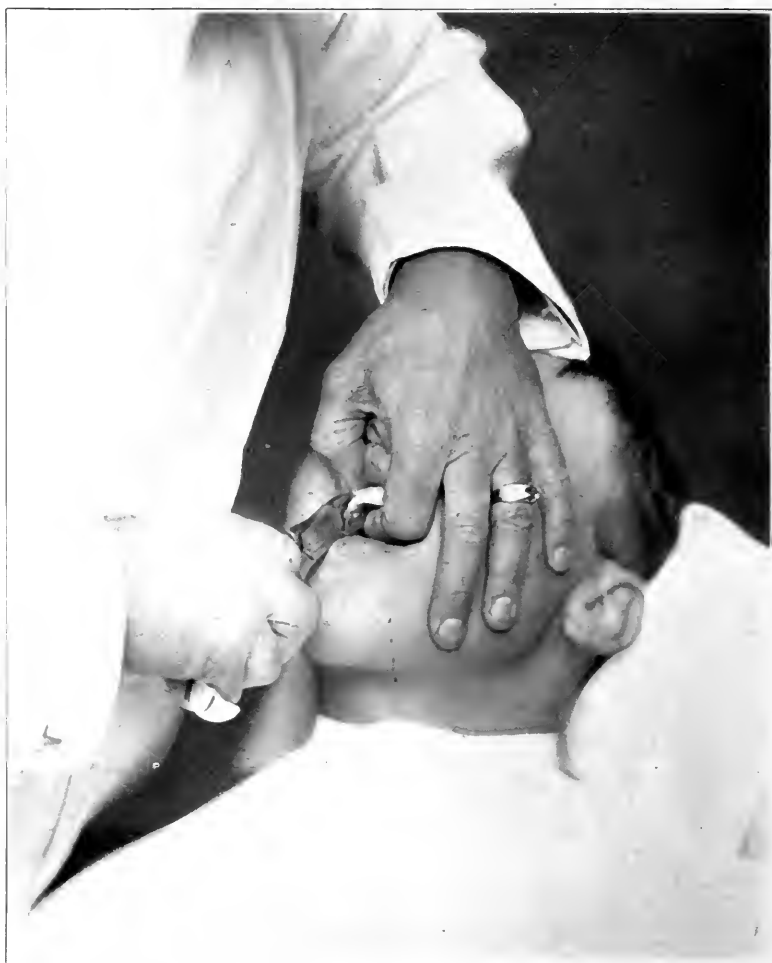

Fig. 116.—Position for extracting right superior cuspids.

increasing the pressure in the wrong direction cause permanent injury. (See Fig. 109.) Just as an operator is extracting the tooth, he is often troubled by the patient grasping the arm which is using the forceps. This is a serious matter, especially when ex-

tracting a lower tooth, as the line of force, which the operator wishes to exert is opposite to that in which the patient can exert great force thus resulting in diminishing the power of the former.

Overcoming Resistance of Patient. At this point the operator is

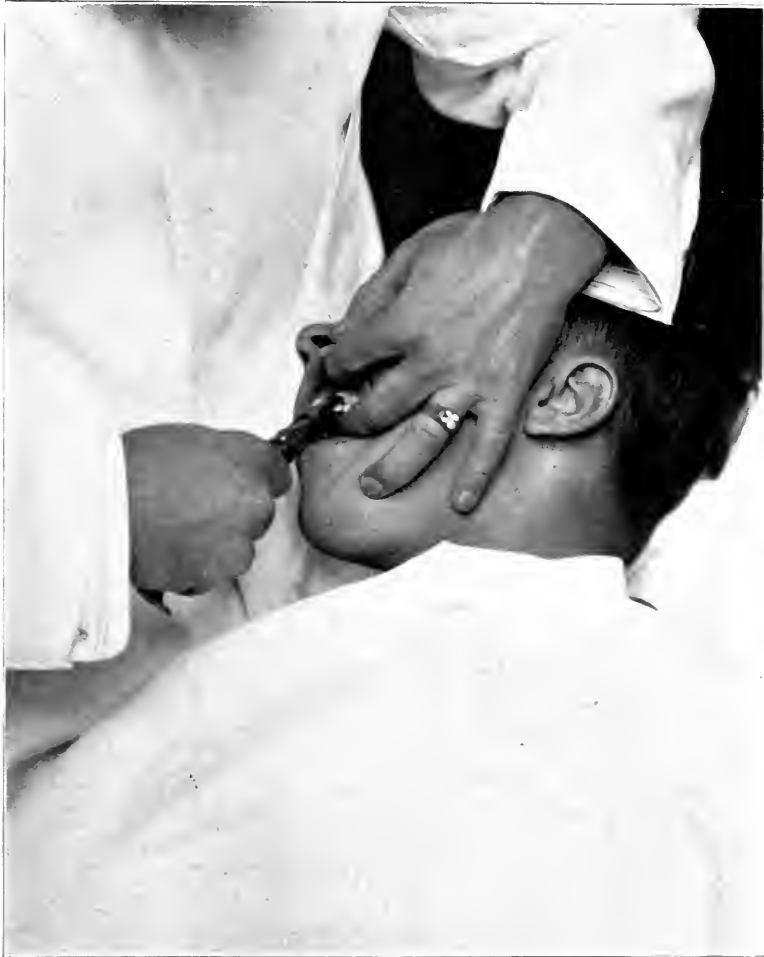

Fig. 117.—Position for extracting left superior cuspids.

justified in a sharp reprimand, even bordering upon crossness, perhaps getting the patient to desist for a moment, when the operation may be completed. The only precaution for guarding against such a turn of affairs is perhaps a suggestion that the patient hold

the hands of a friend or grasp the arm or seat of the chair, instructing him to give a vigorous pull just as you start to extract the tooth. This may assist him to endure the pain which is sometimes unavoidable when local or general anesthetics are contraindicated.

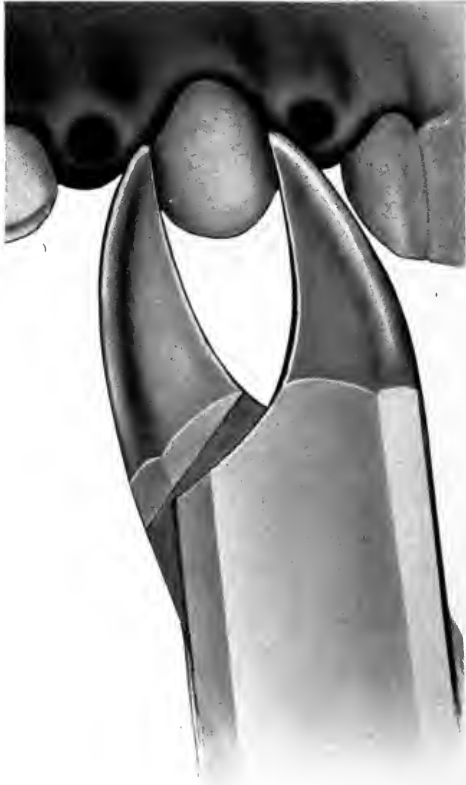


Fig. 118.—Mesial and distal application of forceps to a superior right cuspid when both adjacent teeth have been extracted in advance of the cuspid. The forceps illustrated is the author's No. 4.

In Superior, Central and Lateral Incisors traction or force is applied parallel to its long axis. Next rotation. Why? Because this is a single-rooted tooth and the root is slightly rounded. Also, should any of the adhering portions of the alveolar process be in danger of removal, the rotary motion will loosen that portion from the tooth.

For example, if upon the removal of a nail from a board, part of the board should adhere, the twisting of the nail would remove from it the adhering wood by bringing it in contact with the greater body of the board. Next comes pressure, outward, or labial, because this is in the line of least resistance as the process is much thinner on the labial than on the lingual aspect.

Do not alternate the motion between labial and lingual pressure, as any pressure lingually accomplishes nothing but increased pain, for before the tooth can be removed the mouth of the alveolus must be opened and this can only be effected by labial pressure.

All change of force should be of a rotary nature, with a slight labial pressure, and sufficient traction to remove the tooth upon the slightest fracture, or giving of the process at the mouth of the alveolus.

In Inferior, Central, and Lateral Incisors traction should be in a line parallel with the long axis of the tooth. No rotation is necessary because these teeth have flat roots with their greatest transverse diameter, labio-lingual. Any twisting or attempts at rotating these four teeth will only endanger their slender roots. Pressure is slightly labial, because this is in the line of least resistance, the process being thinner on the labial aspect.

Superior Cuspids. A considerable amount of force is required to remove this tooth, as it is the longest tooth in the human mouth. It is generally most firmly seated and as a rule requires more force for its removal than any other. Slight rotation is required, especially when the first bicuspid and lateral incisor are in position. The root of this tooth is not quite so nearly round as that of the central incisors, but rotation should be applied to prevent a fracture of the adhering process of the lateral surface. This rotation tends to peel or scale off any adhering process by bringing it in contact with the firmer portion not disturbed.

Pressure must be steadily labial, as this is in the line of the least resistance. By "steadily outward," we do not mean to grasp the tooth, and draw it out at right angles with the long axis of the tooth; but that in addition to the great amount of traction necessary and the slight rotation there should be a certain amount of labial pressure upon the process.

There is one case where this rule for the extraction of the superior cuspid may be ignored. That is when the first bicuspid and lateral incisor have just been extracted. In this case instead of grasping the cuspid labio-lingually, place the beaks of the forceps

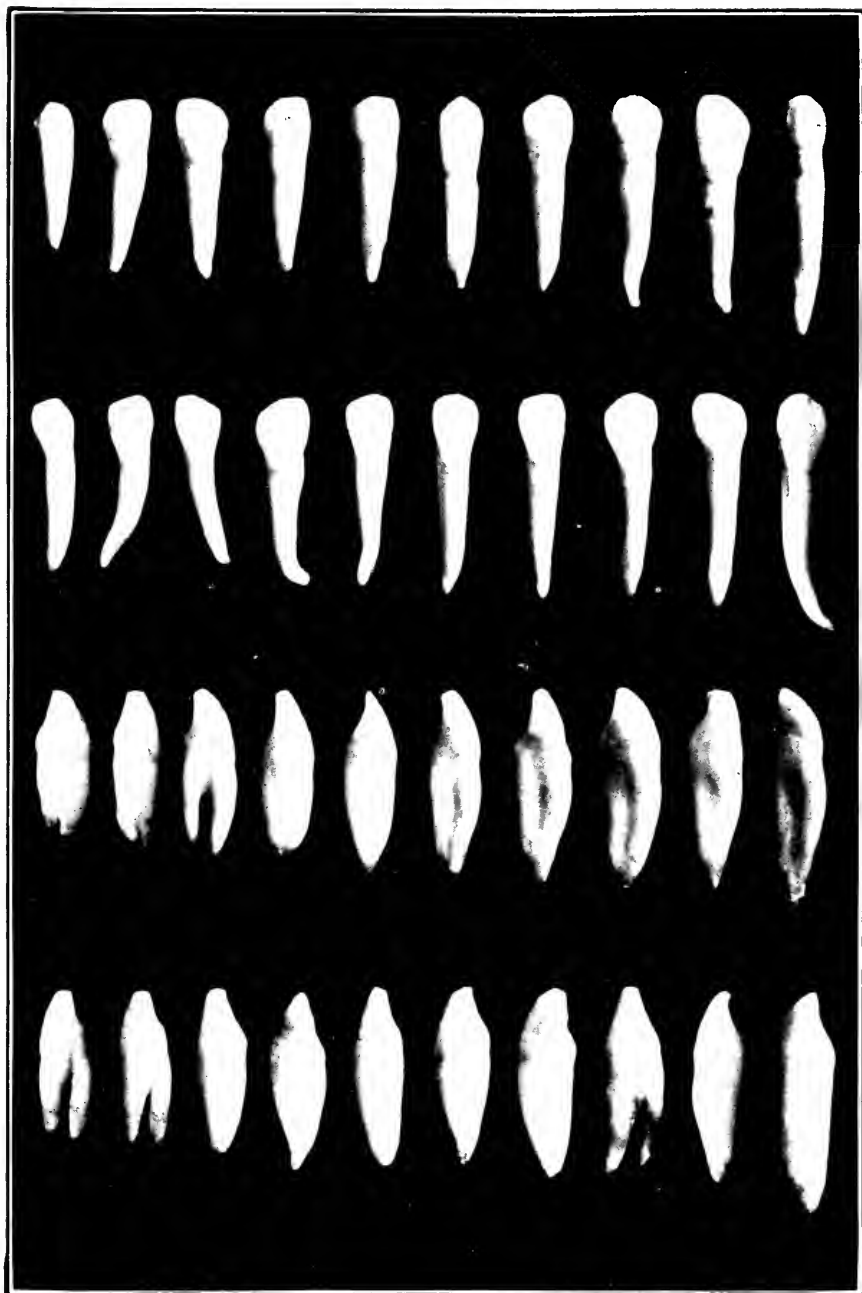


Fig. 119. Types of inferior cusps. The first row shows the labial, the second row the lingual, the third row the mesial, and the fourth row the distal surface. (From Winter's *Exodontia*.)

a short distance up into the cavities of the freshly extracted teeth, thus grasping the tooth mesio-distally. Then give the tooth great traction and also rotation in one direction. This rotation should be so applied that the labial portion of the cuspid would be moved

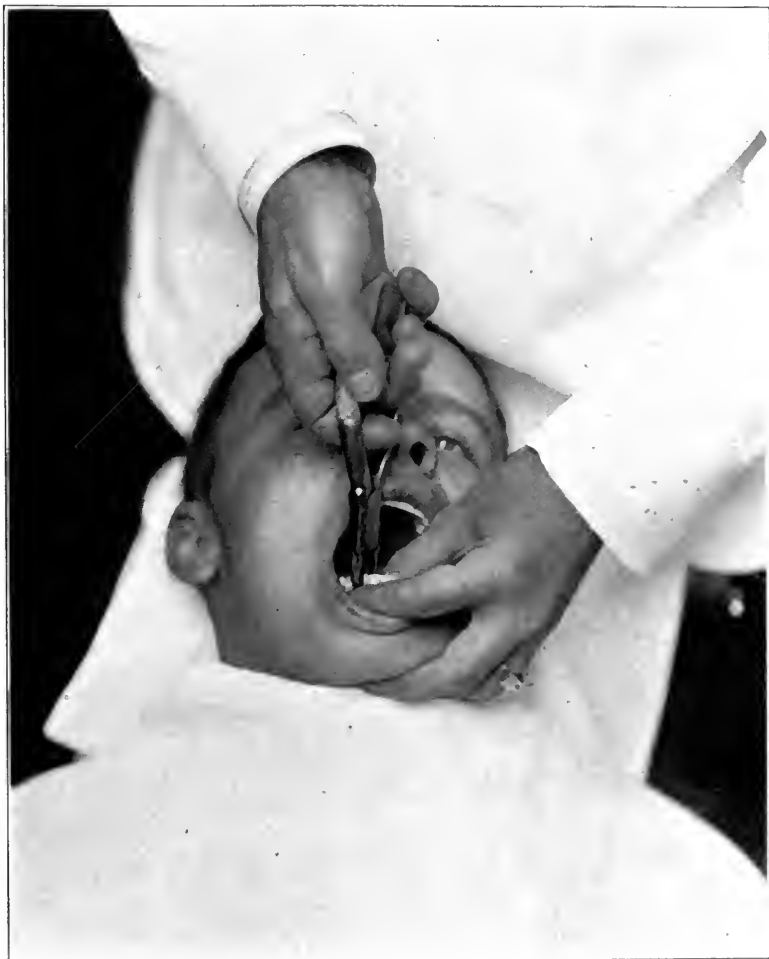

Fig. 120.—Position for extracting inferior cuspids.

towards the median line. The reason the motion should be applied only in this direction can be found in the fact that frequently the roots of cuspid teeth turn or bend backward, as they advance up in the process. Using traction and rotation in this one direction

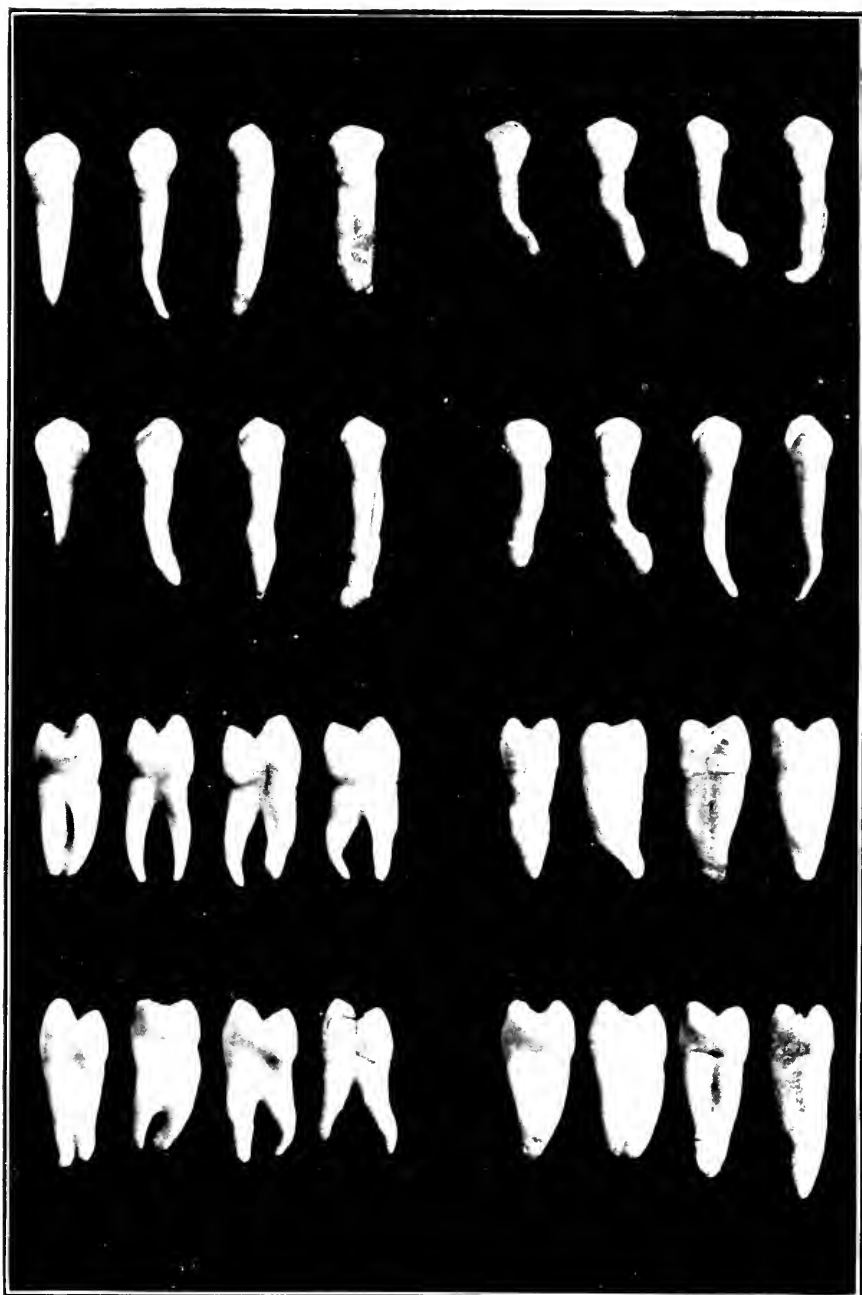


Fig. 121. Types of superior first and second bicuspids. First row—first four teeth, buccal surface of first bicuspids; second four teeth, buccal surface of second bicuspids. Second row—first four teeth, lingual surface of first bicuspids; second four teeth, lingual surface of second bicuspids. Third row—first four teeth, mesial surface of first bicuspids; second four teeth, mesial surface of second bicuspids. Fourth row—first four teeth, distal surface of first bicuspids; second four teeth, distal surface of second bicuspids. (From Winter's *Exodontia*.)

the principle is applied which removes a corkscrew from a cork, right or left thread.

Inferior Cuspids. Traction with slight rotation. Labial pressure. The rules for the extraction of inferior cuspids are quite

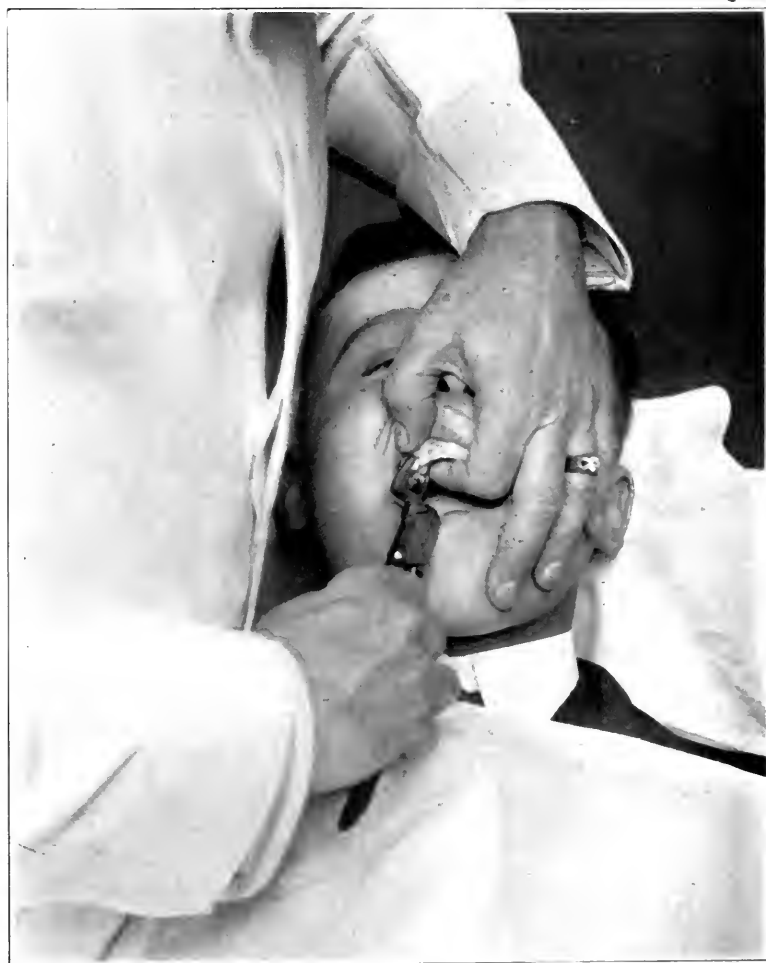

Fig. 122.—Position for extracting right superior bicuspids.

similar to those for the superior cuspids, adding only that owing to the curve sometimes found in its single root, it is well to direct the line of traction force a little backward.

Superior Bicuspids. Principally tractions, parallel with the

long axis of the tooth. Owing to the small size of the root in both cases and the first bicuspid frequently having a double root, other forces must be sparingly used in the removal of this tooth. Minute rotation, could only be used in second bicuspid, this being a single-

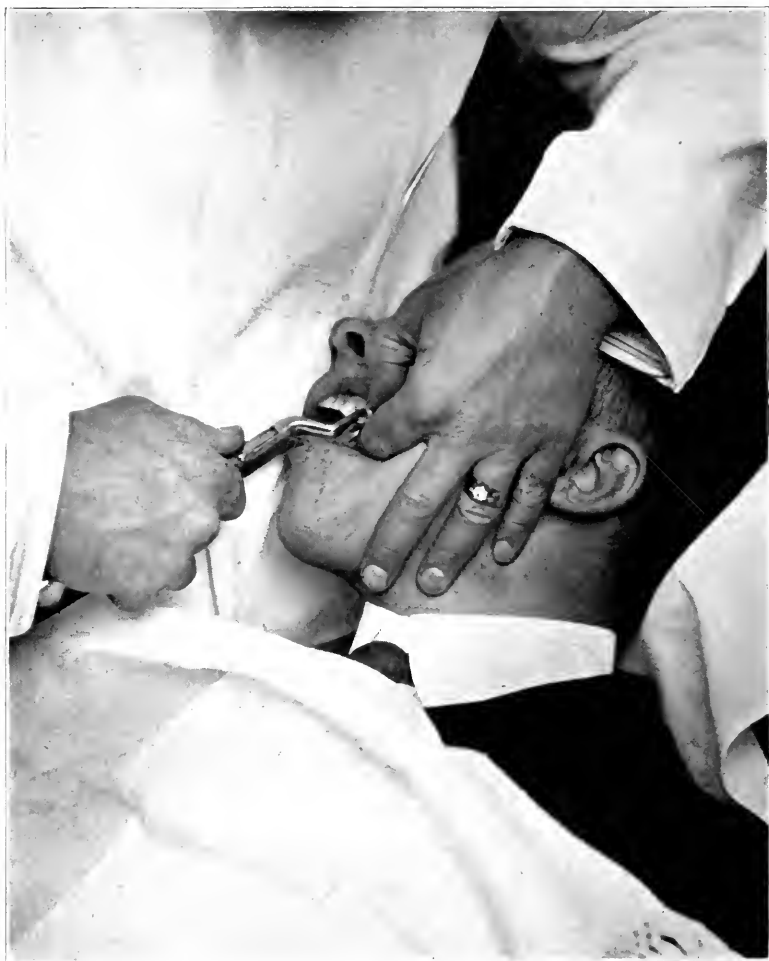

Fig. 123.—Position for extracting left superior bicuspid.

rooted tooth. The first bicuspid is generally possessed of two roots. When not sufficiently bifurcated to be classed as two distinct roots, they are so united as to form a very flat root with the greatest diameter bucco-lingually.

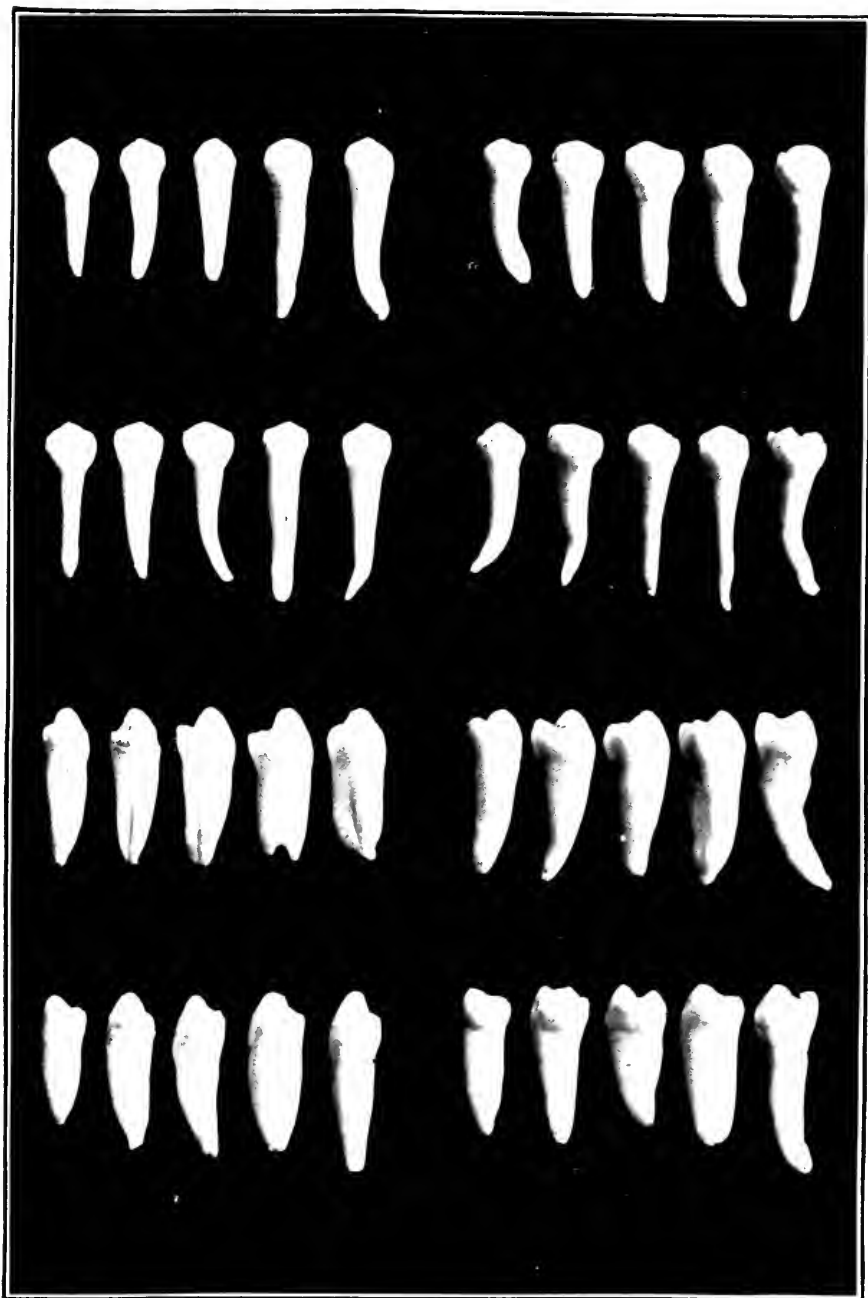


Fig. 1. c. Types of teeth: (1) first five teeth, lingual surface of first bicuspids; second five teeth, lingual surface of second bicuspids. Second row: first five teeth, lingual surface of first bicuspids; second five teeth, lingual surface of second bicuspids. Third row: first five teeth, mesial surface of first bicuspids; second five teeth, mesial surface of second bicuspids. Fourth row: first five teeth, distal surface of first bicuspids; second five teeth, distal surface of second bicuspids. (From Winter's *Prosthodontics*.)

Pressure, which is outward as this is in the line of least resistance owing to the thinness of process on buccal aspect, must be sparingly used; not so much because you would endanger the process by great force in this direction, for it is considerably thick-

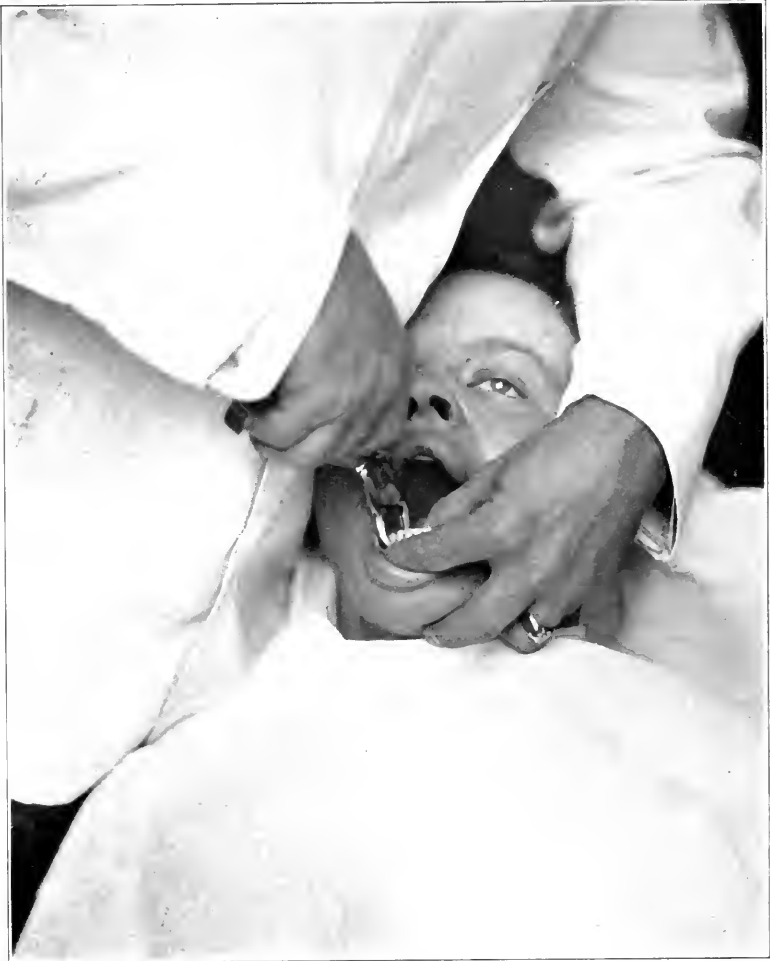

Fig. 125.—Position for extracting right inferior bicuspid.

er over the bicuspid than over the cuspid roots, but because there is danger of breaking the root just below the mouth of the alveolus, or close to where the roots begin their bifurcation. With the second superior bicuspid the pressure outward may be greater, bear-

ing in mind that the roots of these teeth are disproportionally long compared with their circumference at the neck.

Inferior Bicuspids. Principally traction. In applying this force bear in mind that the line of the greatest length of these teeth is

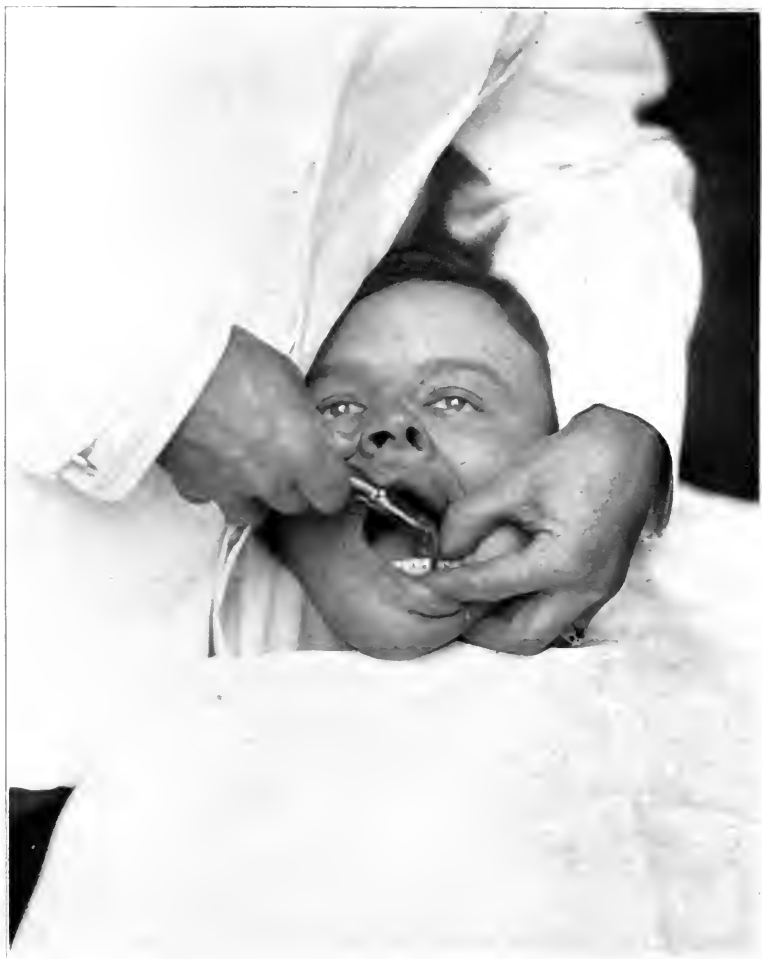

Fig. 126.—Position for extracting left inferior bicuspids.

normally inclined backward instead of being in all cases at a right angle to the plane of occlusion. Therefore, the traction must be applied in a direction which would move the tooth, if it suddenly came loose, towards the first molar or back of where it normally

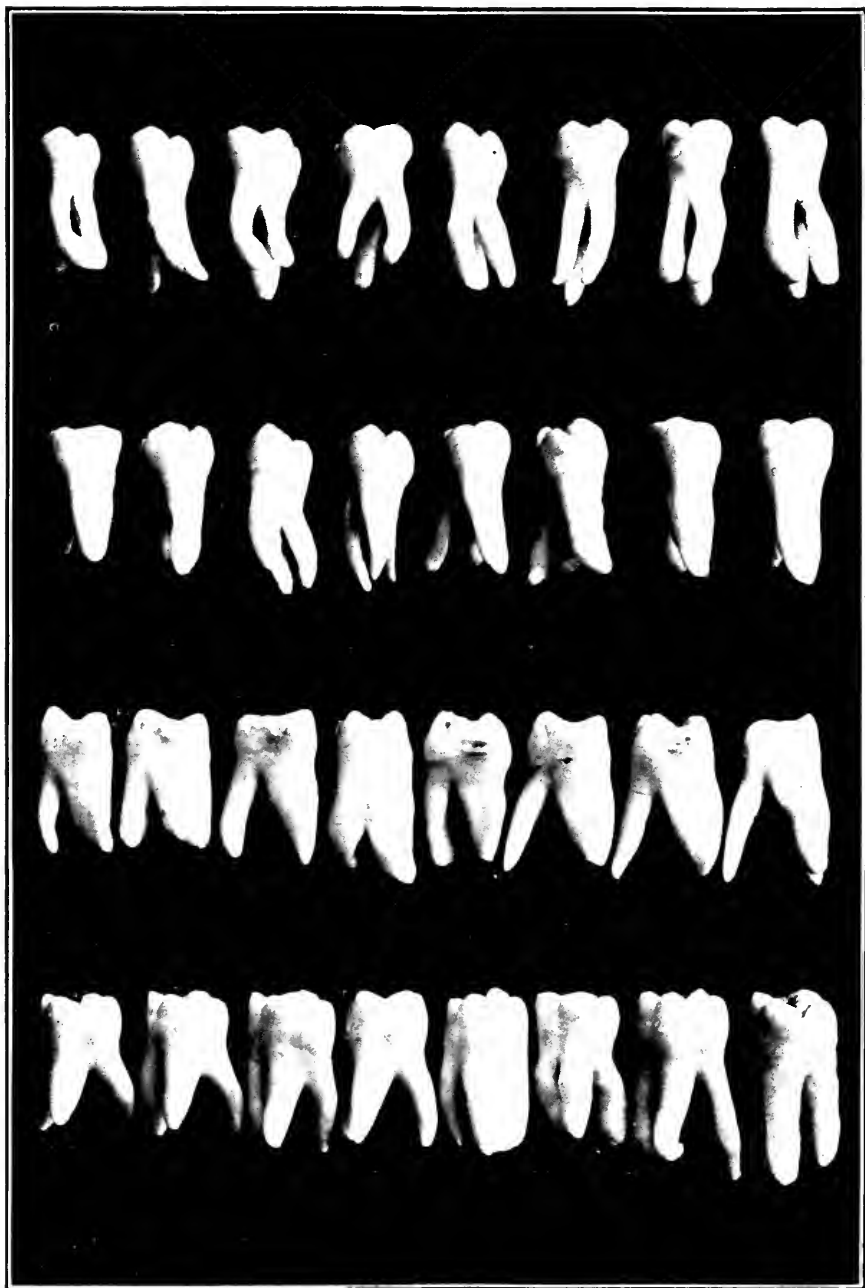


Fig. 127.—Types of superior first and second molars. . The first row shows the buccal, the second row the lingual, the third row the mesial, and the fourth row the distal surface. (From Winter's Exodontia.)

occludes. Minute rotation is necessary for the reason that these are also slender-rooted teeth and quite frequently somewhat curved. As a rule these teeth are possessed of but one root. The pressure should be minutely buccal, for this is in the line of least

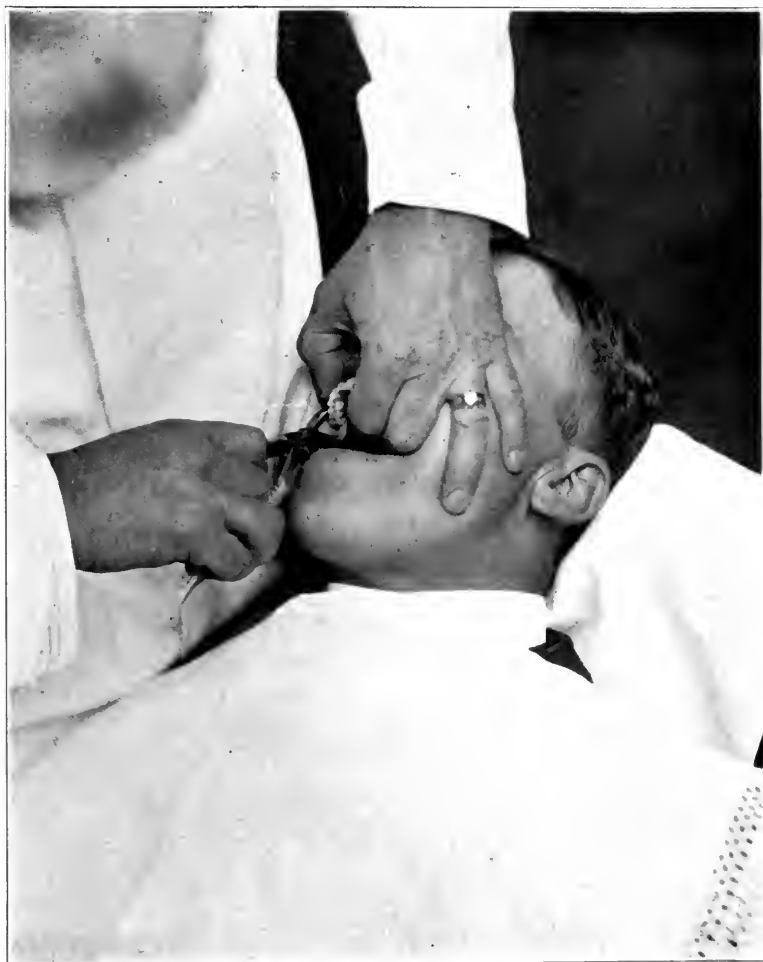

Fig. 128.—Position for extracting first and second right superior molars.

resistance. Care should be taken not to injure the upper teeth when inferior bicusps and first molars leave their sockets suddenly, as they sometimes do. Injury to the other teeth through striking them with the forceps is more likely to occur in extracting

bicusps, as the force of traction should be applied in a direction which would bring them in contact with the upper teeth.

Superior First and Second Molars. These teeth are grouped together, as in the case of the bicusps, on account of similarity in

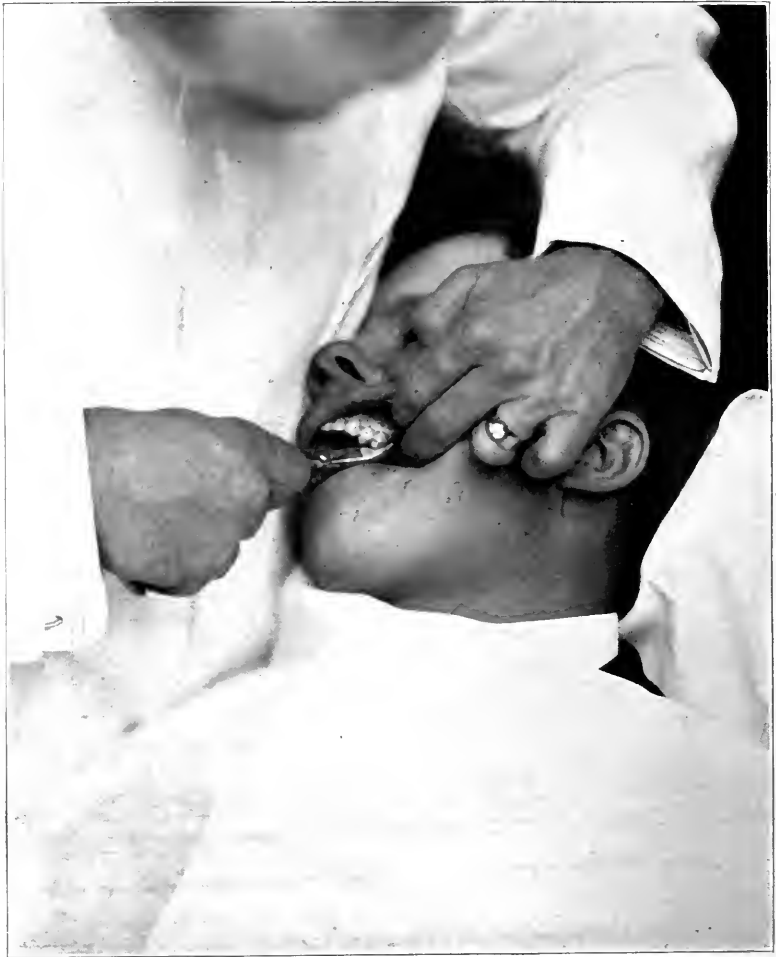

Fig. 129.—Position for extracting first and second left superior molars.

form, position and parts surrounding them. Traction should be applied in the direction of a line drawn from the central pit of this tooth to the apex of the lingual root. No rotation should be applied. Any motion in the way of rotation would not loosen the

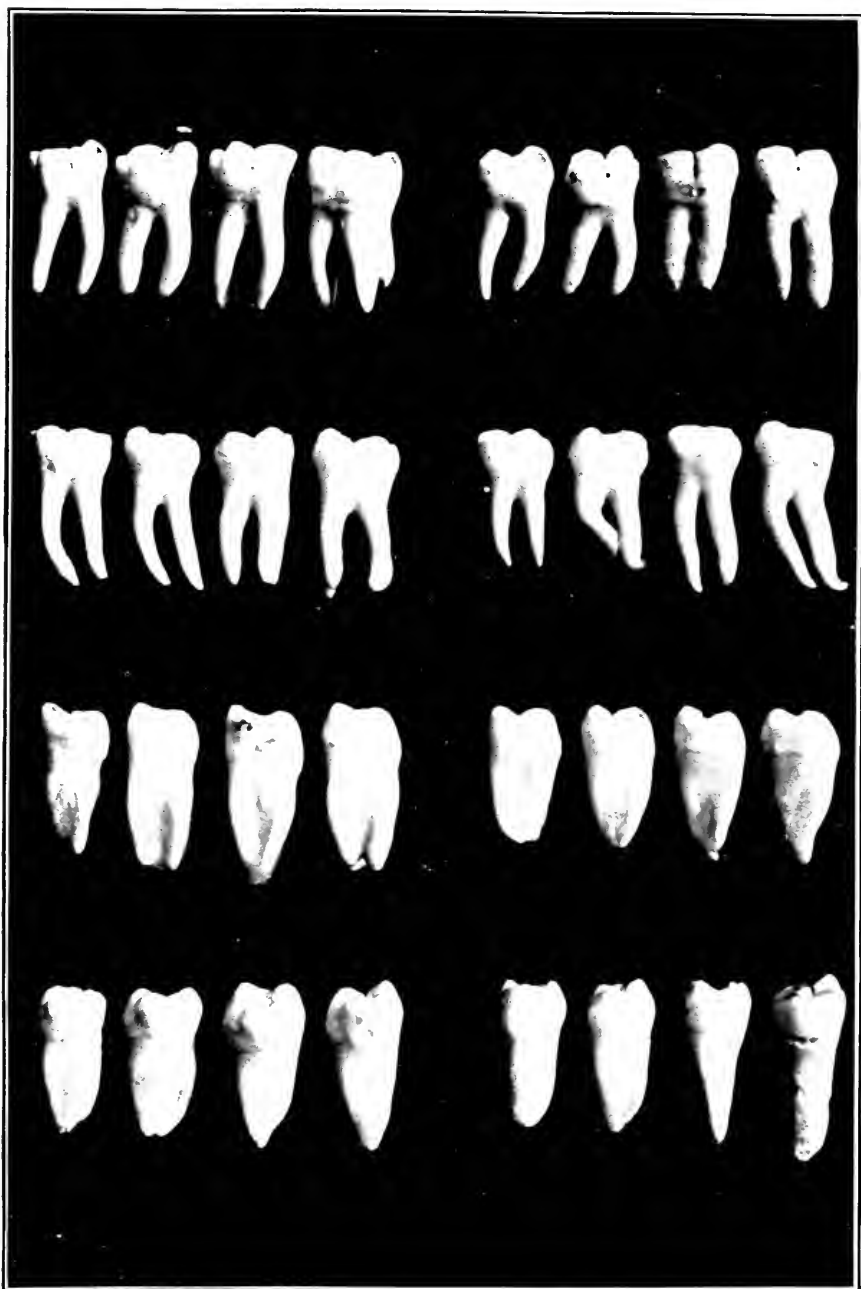


Fig. 130.—Types of inferior first and second molars. First row—first four teeth, mesial surface of first molars; second four teeth, buccal surface of second molars. Second row—first four teeth, lingual surface of first molars; second four teeth, lingual surface of second molars. Third row—first four teeth, mesial surface of first molars; second four teeth, mesial surface of second molars. Fourth row—first four teeth, distal surface of first molars; second four teeth, distal surface of second molars. (From Winter's *Exodontia*.)

tooth, as one root would brace the other. It is therefore advantageous to apply the force in the line of the greatest length of one of these roots, the lingual.

Pressure should be applied steadily buccally and not released until the mouth of the alveolus is opened. The process over the

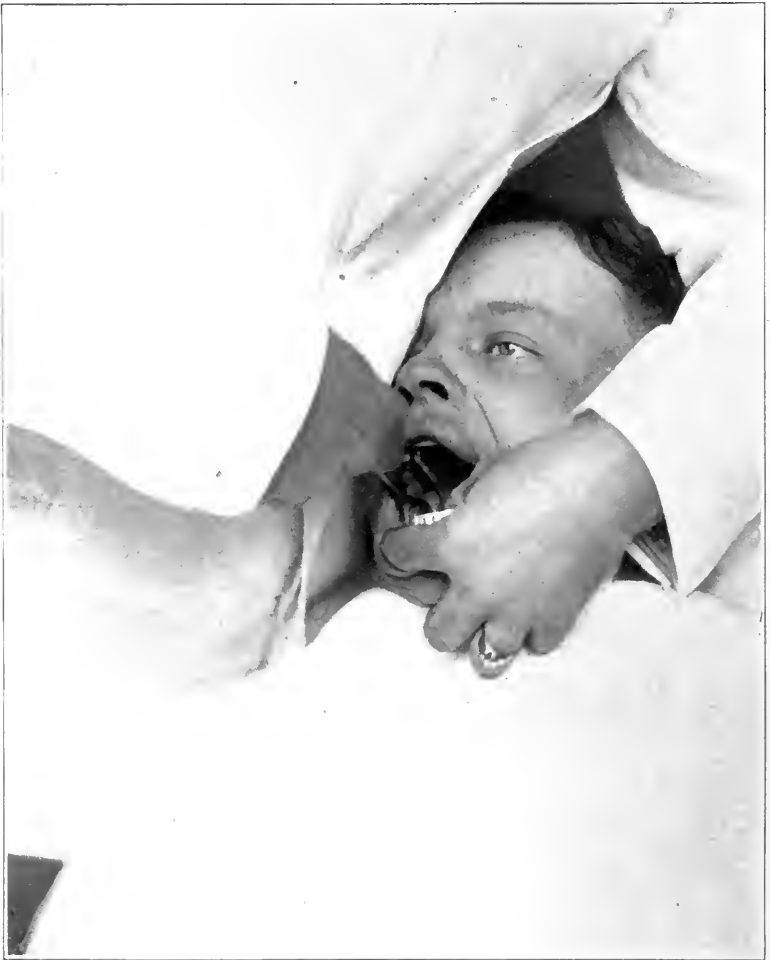

Fig. 131.—Position for extracting first and second right inferior molars.

lingual root, which is the palatine process of the superior maxillæ, is quite thick and heavy and seldom gives to any extent, but the two buccal roots are no great distance from the soft tissues and by

this steady buccal pressure this process gives and the tooth is allowed exit. Care should be taken not to make this pressure too strong or apply it too suddenly, as the two roots in such close proximity may act as a lever and loosen a considerable portion of the buccal plate.

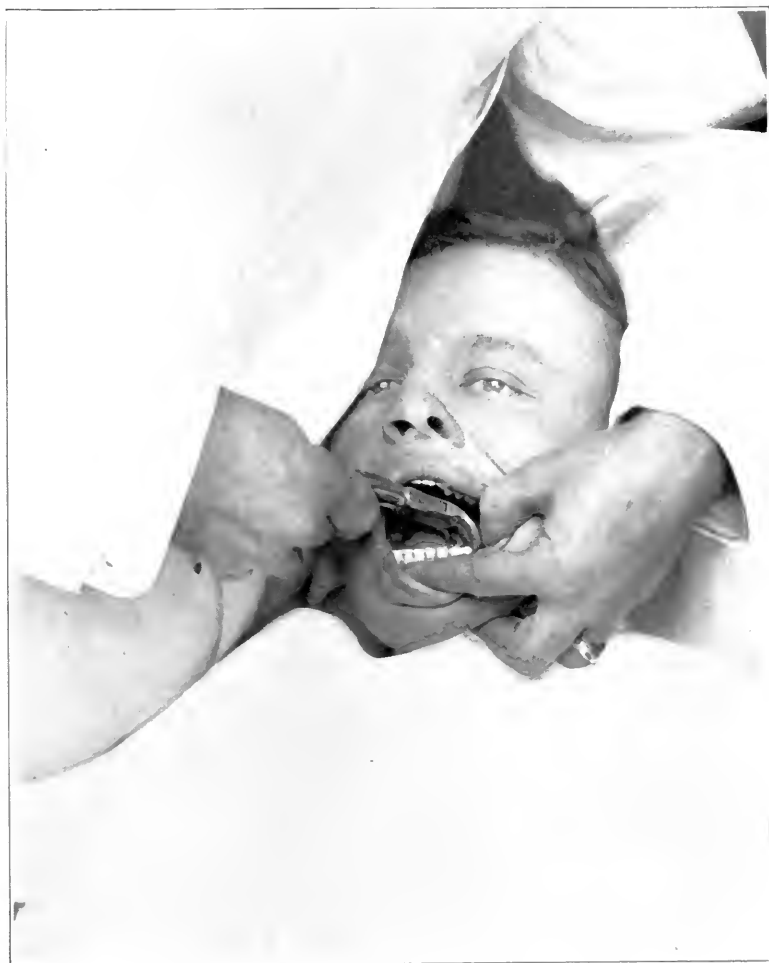

Fig. 132.—Position for extracting first and second left inferior molars.

Inferior First and Second Molars. Traction is necessary, the force of which should be applied not only upward but backward, remembering that the apices of the two roots are not directly un-

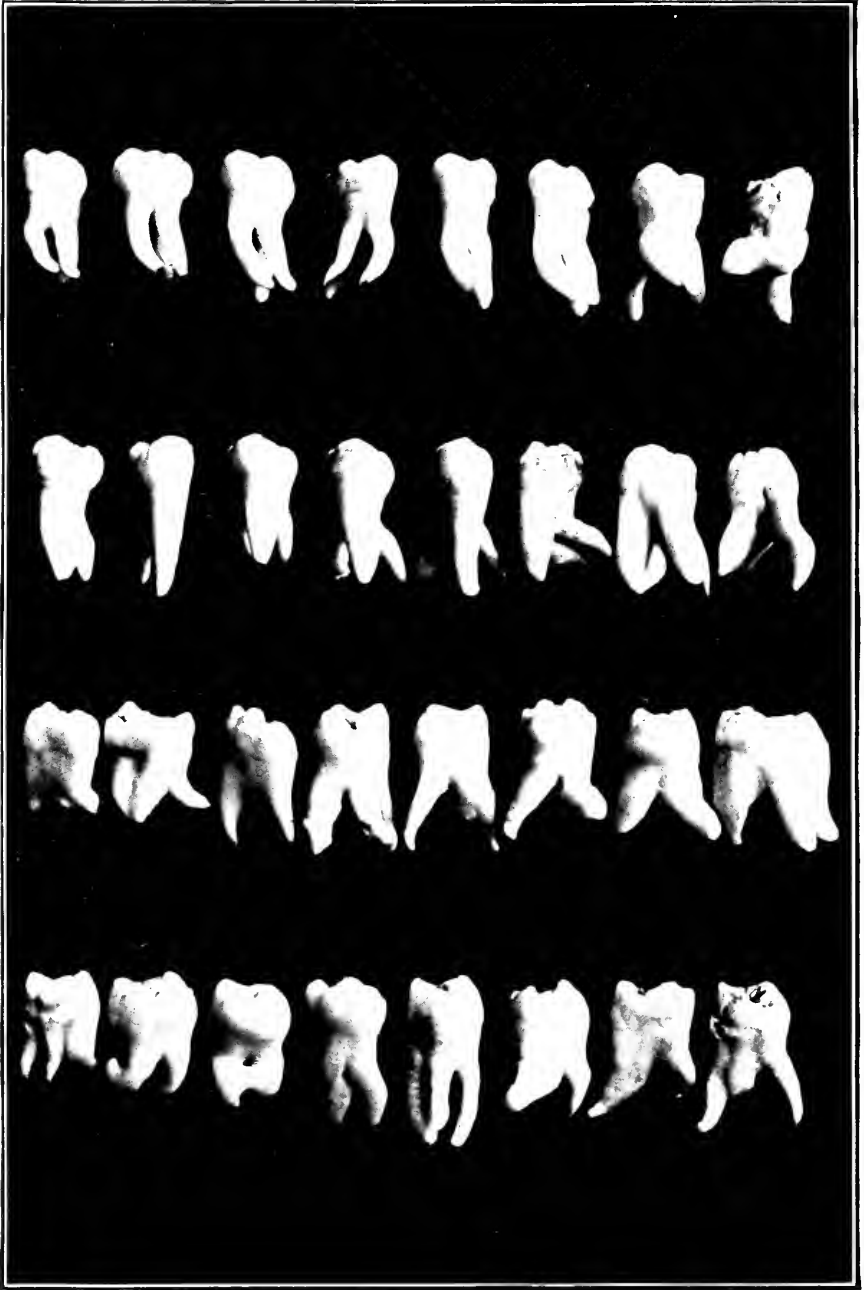


Fig. 133. Types of superior third molars. The first row shows the buccal, the second row the lingual, the third row the mesial, and the fourth row the distal surface. (From Winter's *Exodontia*.)

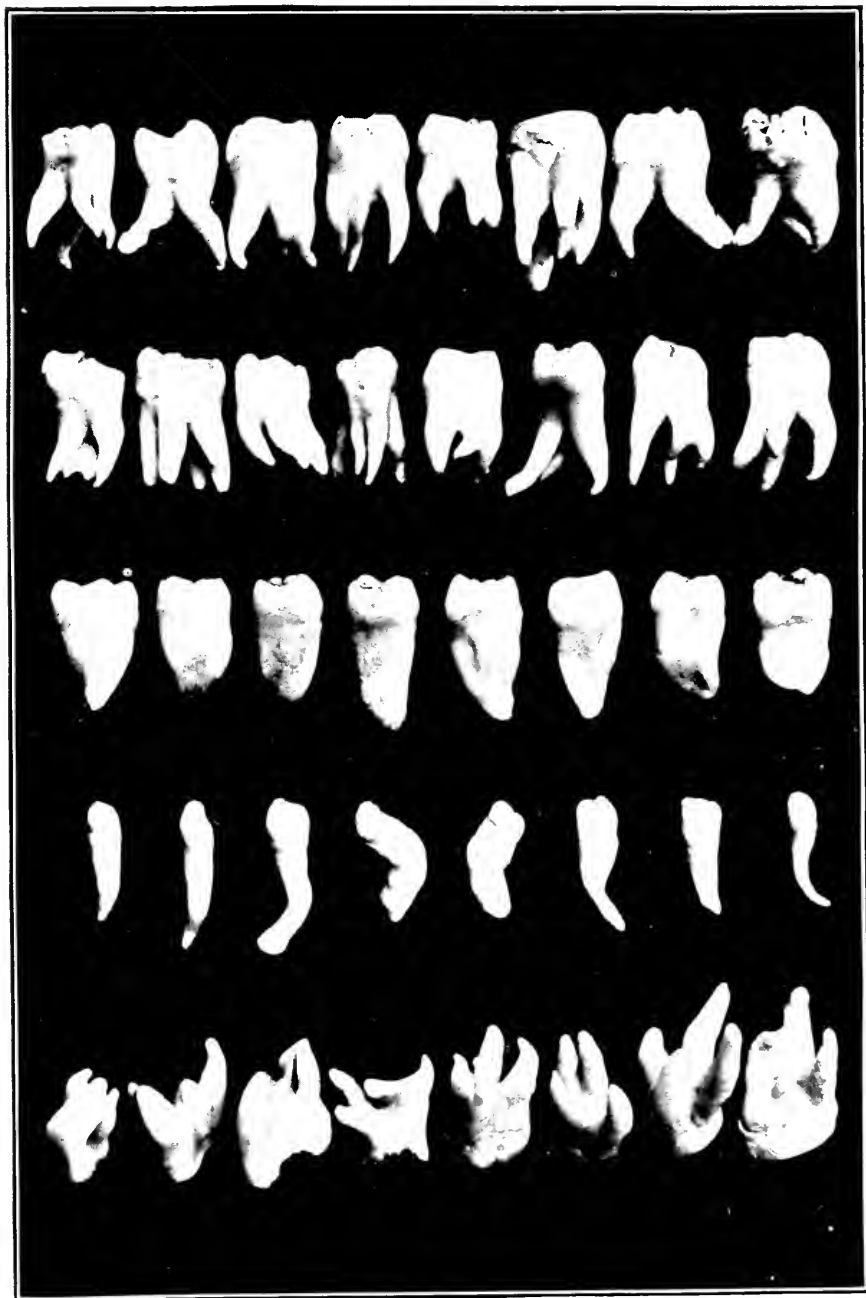

Fig. 134.—Types of abnormal superior third molars. The first and second rows show root-rooted teeth, the third row shows teeth with roots that are fused, the fourth row shows teeth having crowns with a single cone and only one root, and the fifth row shows teeth having roots in which there is great variation in form. (From Winter's *Exodontia*.)

der the crown but posterior to it, giving the root a curve backward. A common error is made when the force of traction is applied at a right angle to the plane of occlusion. There should be no rotation. For as these are double-rooted teeth rotation accomplishes nothing except to increase the pain by alternately increasing and releasing the pressure upon the highly vascular and sensitive periodontal membrane. Pressure should be directly buccal. Although it may seem to the operator that the process is thinner upon the lingual aspect of the inferior maxillæ, this is generally not the case. Yet, as with all lower teeth, a malocclusion or an irregularity may make the process thicker on the buccal surface.

Superior Third Molars. Rotation is applied in but one direction, one that would roll the top of the hand towards the median line. Pressure should be buccal and at the same time distal. Being the



Fig. 135.—One of the many abnormal conditions found when extracting upper second and third molars. In this case the first molar was the only one which had erupted. The patient was about forty years of age. A very severe abscess appeared beneath the tissues overlying the second and third molars. An incision revealed the condition. The photograph shows the result of extracting, all three coming out attached.

last tooth in the mouth and seated at the angle of the jaw, it is not very firmly supported by the process, which in some cases is almost entirely wanting on the posterior buccal corner.

Inferior Third Molars. Traction should not be only upward, but backward, which can be accomplished after grasping the tooth with the beaks of the forceps, and allowing the handle to lie across and near the anterior, inferior teeth. As the traction is applied the handles are raised and have an amount of spring which will tilt the crown backwards in proportion to the distance the anterior teeth are separated by the opening of the mouth. Here we have the only tooth in which there is an almost universal exception to the direction in which the pressure should be applied to be in the line of the least resistance. In the case of the third inferior molar, it is to the lingual. The coronoid process of the inferior maxillæ comes down

ending in the external oblique line which is an eminence and materially thickens the jawbone just buccal to the third molars.

It must also be remembered that there is little of the alveolar process formed around the third molar, seldom more than that por-

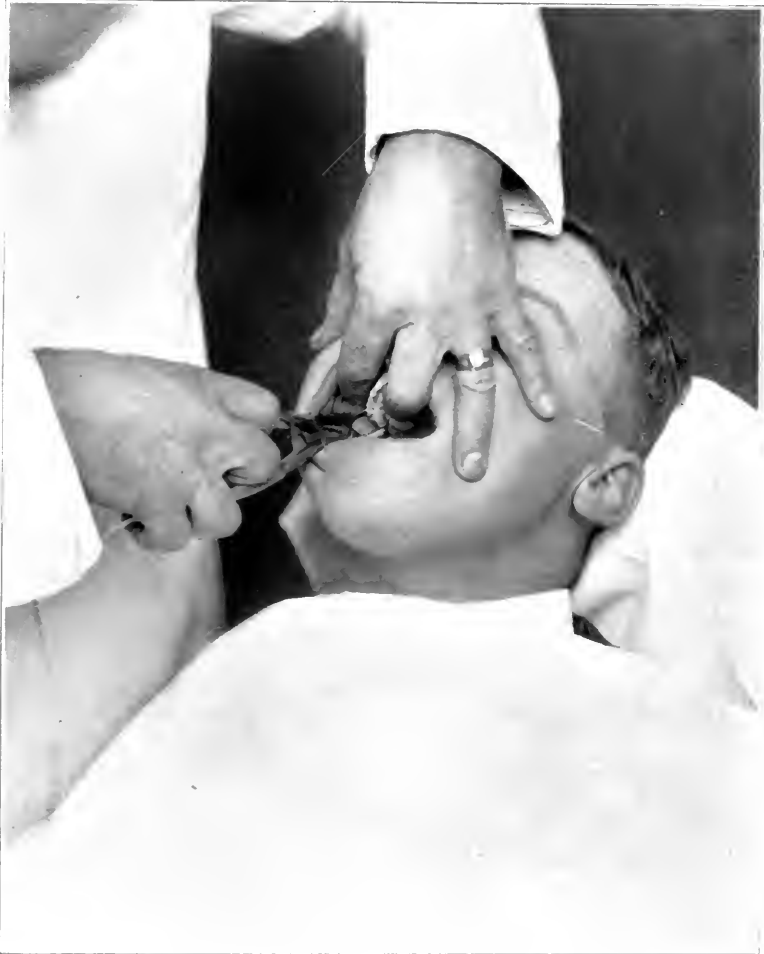

Fig. 136.—Position for extracting right upper third molars.

tion which builds in around the neck to insure its retention. Therefore when the tooth is broken off it at once becomes a very difficult task to remove the remaining portion, owing to the strength and width of the bone at this point.

Care Should Be Taken Not to Employ Great Pressure Lingually

as the anatomical structure at this point favors fracture which most frequently extends down and back to include the inferior dental foramen connected with the mylohyoid groove.

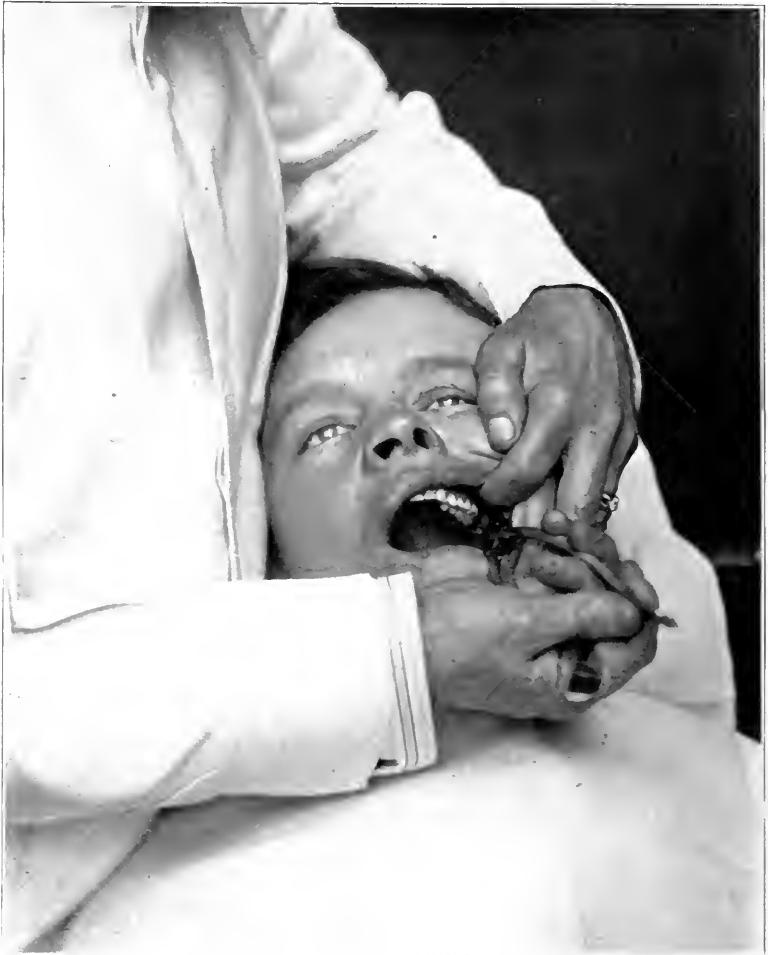

Fig. 137.—Position for extracting upper left third molars. Note the hand grasp on the forceps. This grasp can also be used, sometimes, on the first and second molars. The grasp is a powerful one as the bones and muscles of the arm and body are in a position to exert a great amount of force while giving the tooth buccal pressure and rotation with the top of the forceps moving toward the median line in the rotary motion and the handles of the forceps are pushed out and back. While this may look awkward in the photograph many of my students who have tried it have been very much pleased with the results.

Injury in this way at this particular point may be far-reaching in its effect, as fractures are most likely to follow weakened portions

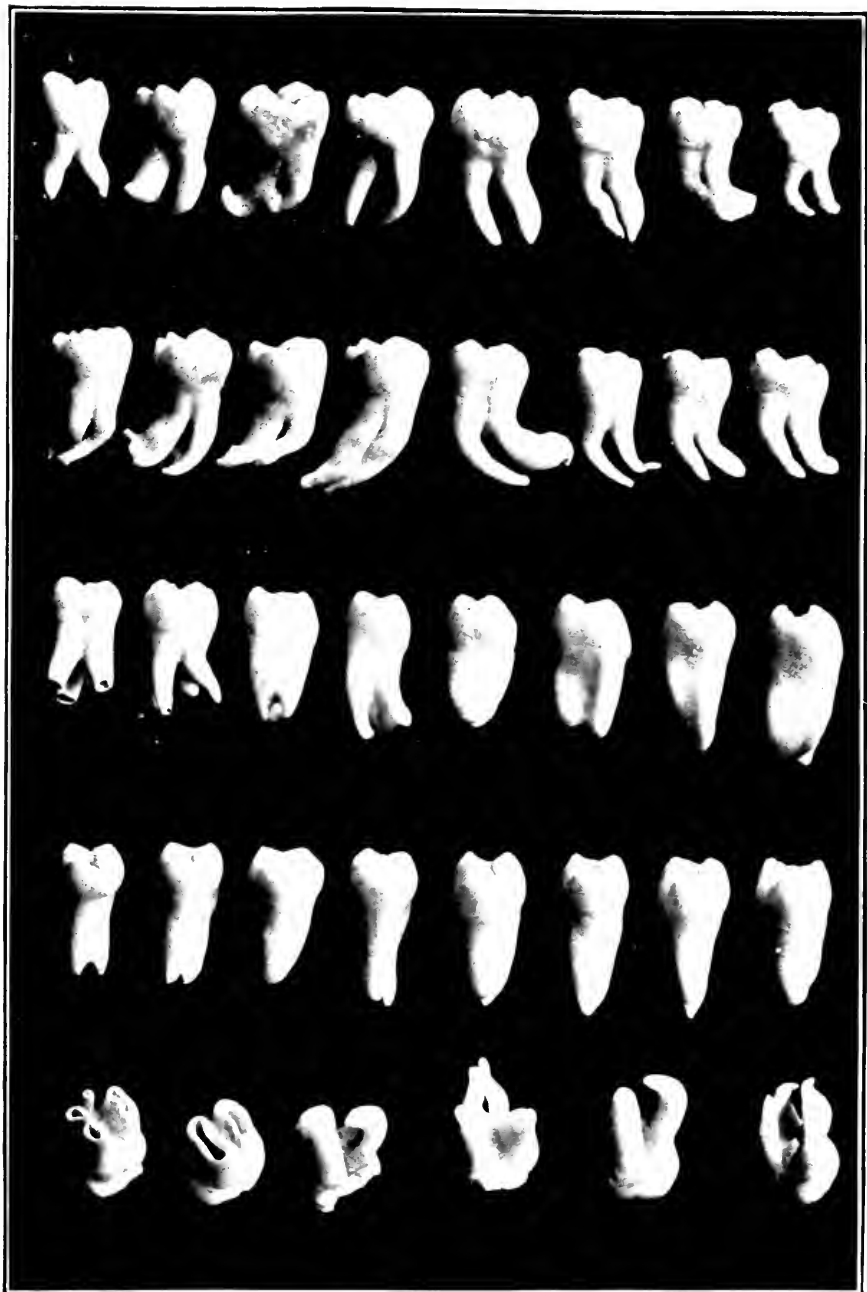


Fig. 138. Types of inferior third molars. The first row shows the buccal, the second row the lingual, the third row the mesial, and the fourth row the distal surface. The fifth row shows incomplete and malformed molar roots. (From Winter's *Exodontia*.)




Fig. 139.—Elevator beaked forceps for extracting third molars.

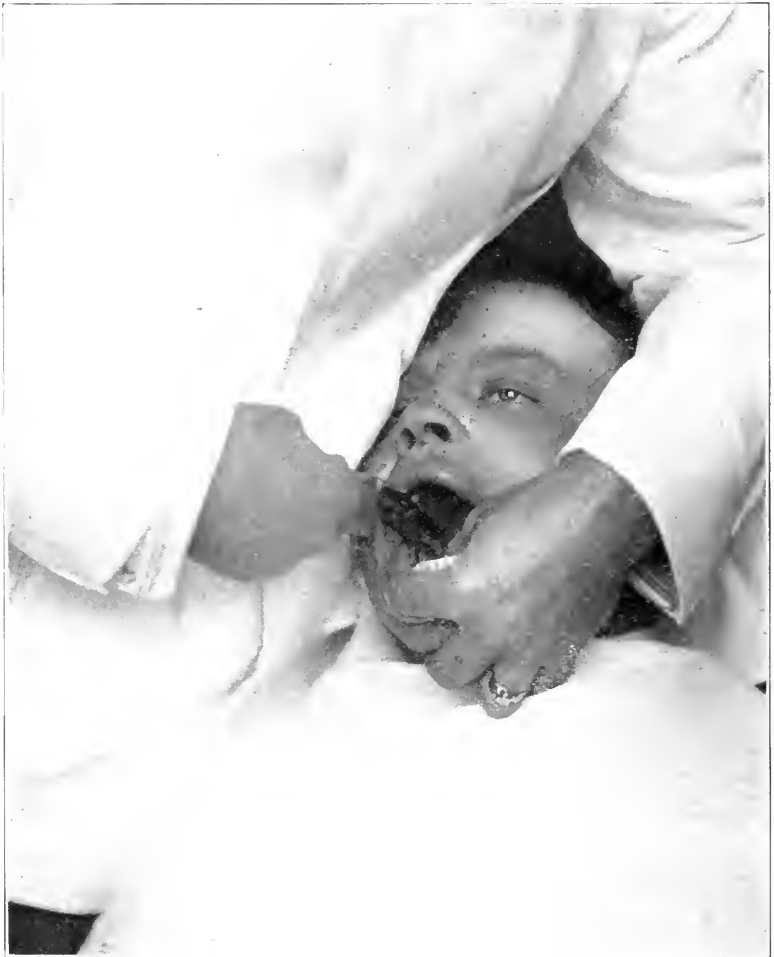

Fig. 140.—Position for extracting right inferior third molars.

of the bone, and in this case they overlie the inferior dental nerve and vessels.

Hemorrhage Following Extraction. Excessive hemorrhage frequently follows tooth extraction, and is more frequently met with in cases after extracting first or second lower molars.

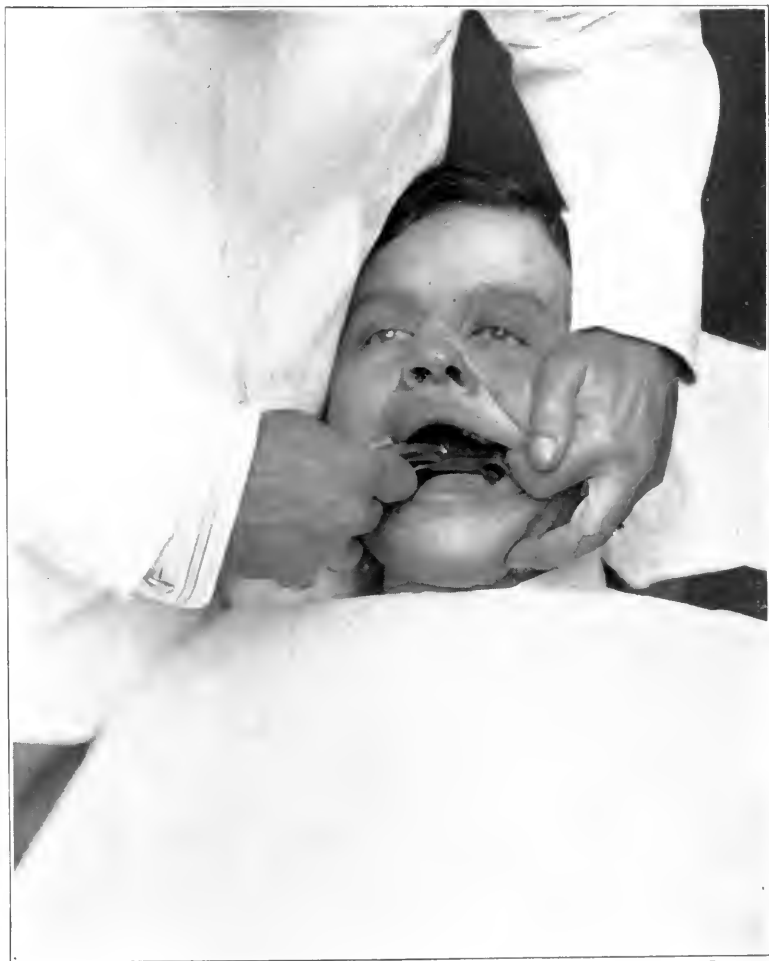

Fig. 141.—Position for extracting left inferior third molars.

In Mild Cases a tampon of cotton saturated with hydrogen dioxide or adrenalin chloride crowded well to the bottom of the alveolus from which the hemorrhage is coming will usually be sufficient.

In Severe Cases a tampon made of the serapings of oak-tanned

sole leather will prove effective. The scrapings are made by the dentist from a piece of sole leather by scraping shreds from the edge. These should be previously prepared and ready for an emergency. They should be placed in a large-mouthed bottle and sterilized by dry heat and securely corked.

Method of Applying. When case presents, there should be three pellets made, small, medium and large about the size of the alveolus. These should be introduced quickly one after the other and pressed to position and held there for some minutes with the ball of the finger.

The leather scrapings will swell and effectually plug the alveolus. Also the tannin in the leather liberates the fibrinogen and an impervious clot is formed. Within twenty-four hours the last applied pellet of scrapings will have been raised out of the socket and the next two will soon follow.

This is recommended as a method that has never failed in a long list of desperate cases but should not be resorted to except as an extreme measure as great soreness frequently follows the treatment due to the interference with the circulation for some considerable distance about the bleeding alveolus.

Hypodermic Injections of Adrenalin Chloride for hemorrhage following extraction is good practice. Load the syringe part full with Ringer's solution to which has been added five drops of adrenalin chloride. Introduce the needle, which should be long and large, into the apical space and inject a few drops. Repeat two or three times if necessary.

Capillary Hemorrhage. If the hemorrhage is capillary, inject into the tissues from which the blood is coming.

CHAPTER XL.

EXTRACTION OF TEMPORARY TEETH.

The extraction of temporary teeth at the proper time and under normal conditions is not a difficult operation, owing to the amount of physiological resorption of both alveolar process and roots of the teeth.

The Most Important Thing Connected With Their Extraction is an accurate knowledge of the order in which nature proposes to replace them with the permanent set.

Results From a Disregard of This Order. The premature or tardy extraction of temporary teeth has more to do with irregular and unsightly permanent teeth than any other one cause. Therefore it is well to make a careful study of the order in which the temporary set is replaced.

Time of Eruption of the First Permanent Molar. The first molar teeth make their appearance at between five and six years of age.

They are generally supposed by the laity to be deciduous and are frequently allowed to decay beyond remedy before the mistake is discovered. They are then extracted without much thought, either through necessity or from being mistaken for temporary teeth by the physician on account of the youth of the patient. The parents are wonderfully surprised to find such enormous roots on what they believe to be a temporary tooth.

Duty of Dentist in This Matter. The practitioner of dentistry has a very important duty to perform in insisting upon the retention of this tooth; for through its loss a decided derangement of the permanent set results and lack of proper development of the jaw is encouraged.

First Permanent Tooth to Erupt. Fig. 142 is a side view of child's jaw at about the sixth year. No. 1 in the top row is the first molar, and is a part of the permanent set, the second and third molars coming in after the temporary set has been entirely replaced by permanent teeth.

Reasons for a Permanent Tooth at This Time. Nature in giving us this permanent tooth at this particular time and located at this particular place, seems to desire to put in a permanent fixture as a dividing line in the jaw between the teeth which are to be replaced, and those which are not, as shown by line *A-A*.

Evil Effects of Early Extraction. *If by Proper Extraction and*

Coaching Into Place of the various teeth in their proper order the position of this line A-A, which bisects the jaw just at the mesial of the first permanent molar, is not allowed to move anteriorly, there is left just the proper space which the permanent teeth will occupy when they replace the temporary set, provided the jaw development is not interfered with, but if by the premature extraction of the second temporary molar, this *first permanent molar is allowed to tip forward*, thereby moving line A-A anteriorly, we have encroached just that much upon the space required by the permanent teeth.

The Irregularity Resulting From Such a Mistake will probably be shown in the cuspid as this is the last of the temporary set to be

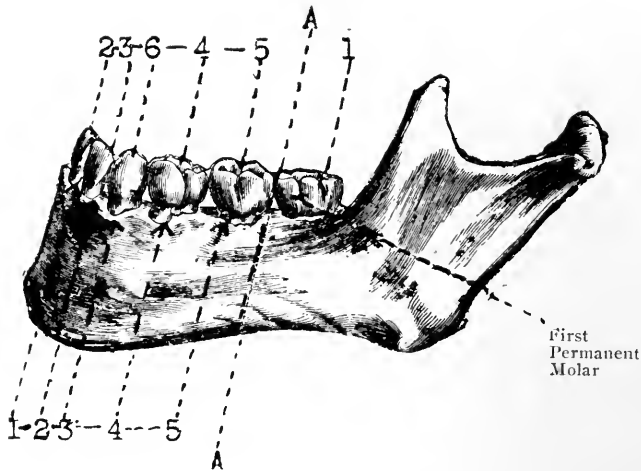


Fig. 142.—Represents the complete set of deciduous teeth with the first permanent molar added. Lower row of figures represents the order the deciduous teeth generally erupt. Upper row of figures represents the order of the replacement by the permanent set.

replaced. (See Fig. 143.) Again, if the first permanent molar is extracted before the temporary teeth have been replaced, nature seems to realize that further development of the jaw on this side is not necessary, and the jaw—be it lower or upper—will generally lack in length to correspond with its antagonist, the width of the tooth extracted. This may not be noticed in the exhibition of faulty occlusion or irregularities but a careful study of the features will show lack of *artistic contour*.

Let us here consider the *order in which the temporary teeth are replaced* by the permanent set. By reference to Fig. 142, you will see that the order differs somewhat.

The lower figures represent the order of eruption of the temporary set. The upper figures represent the order of the replacement by the permanent set including this first permanent molar. Nature has wise reasons for this change in the order.

The Inferior Teeth Generally Precede the Superior in the anterior part of the mouth by a few weeks and in the posterior part by a few months with the exception of the third molars. The inferior third molars sometimes precede the superiors by years. It must also be borne in mind that the variance in length of time and age of eruption is shorter in the case of females than of males.

Difference in Time as to Sex. Some females erupt their third molars as young as the sixteenth year, some males do not erupt them as late as the twenty-seventh year. They may be in part or entirely wanting in either male or female during life. They are sometimes

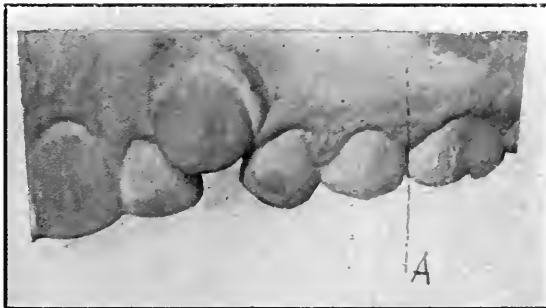


Fig. 143.—Irregularity resulting from premature extraction of the first deciduous molar.

so far retarded that they do not erupt until after the extraction of the first and second molars late in life. This sometimes gives rise to an idea in the patient's mind that he has at least part of a third set of teeth.

Compare Orders of Eruption. A careful consideration of the two tables will show that in the temporary set the cuspid teeth erupt before the temporary molars, while these are replaced by the permanent teeth in a different order. The first temporary molar is replaced by the first bicuspid. Then the second temporary molar is replaced by the second bicuspid and next we have the cuspid tooth coming into place, forming the keystone of the arch.

The Reason for Nature's Change of This Order. At five years we find the full complement of temporary teeth in place, only twenty in number. Then nature puts in this dividing line by putting into place one permanent tooth, the first permanent molar, before she

makes any attempt at interfering with the temporary arch already established.

When this tooth is fully in place nature begins her work of replacement. First come the centrals, then the laterals, and if we were to follow the order in which these same temporary teeth were erupted we would next have the cuspid, but not so, we have the first temporary molar lost and replaced by the first bicuspid, and as this temporary molar is lost, the first bicuspid has a space to occupy between two teeth, which should be in position to guide and assist it to proper place, leaving the second temporary molar in position to hold the first permanent molar in its correct position. Then nature replaces the second temporary molar with the second bicuspid. Note that these two temporary molars are wider than the permanent bicuspids taking their place, but the cuspid of the permanent set is wider than the temporary cuspid.

Loss of Temporary Cuspid. As soon as the temporary molars have been replaced by the bicuspids, the temporary cuspids should be lost and replaced by the permanent cuspids, which as stated before, forms the keystone of the arch, and being a little wider wedges the two bicuspids quickly back into position against the first permanent molar. Coming into position just in this order and at this time it is easily seen how the first permanent molar is kept in its proper place. At this time the question may arise as to how the permanent centrals and laterals find sufficient room, being so much larger than their predecessors. This is compensated for by the development of the maxillæ at this age. Some authors advance the idea that the difference in the space occupied by these four teeth was compensated for by the permanent bicuspids being smaller than the temporary molars. We cannot agree with this. For when the four incisor teeth are erupted in position in almost every instance the temporary cuspid retains its former and original place.

Having completed the changing of the temporary teeth nature will add teeth to the posterior part of the jaw without any danger of subsequent irregularities.

Evils Resulting From Disregarding the Order in Which the Temporary Teeth Are Replaced by the Permanent in Their Extraction. For instance, if, as we are frequently requested by our patrons, we extract lateral incisors before the central incisors have attained nearly their proper height in the process of eruption, either one of the two evils may result.

The central incisors in the inferior maxilla stand on either side of the symphysis, or where the two segments of the jawbone unite. In the superior maxilla the central incisors stand on either side of the median line in the intermaxillary bones. If the temporary laterals are extracted before the centrals are fully erupted, should the jaw continue proper development, the central incisors will stand apart as they do not have the lateral incisors to hold them toward the median line. Thus when the laterals attempt to come into place, their space has been encroached upon and they may fail to crowd the centrals over to place.

However in most cases the bones do not continue proper development and the space between the two temporary cuspids occupied by the four temporary incisors, is not sufficiently increased to accommodate the permanent incisors; hence the crowded condition frequently met with.

Therefore no lateral incisors should be extracted until the central incisors are quite in position. If the central incisors do not seem to have sufficient room, instruct the patient to put pressure with the tongue or fingers in the labial direction which will put them into proper position; but for no reason whatever should the laterals be extracted before the centrals have attained their proper height in the line of occlusion.

Next we lose the lateral incisors. As this tooth erupts after the temporary lateral has been extracted, it very frequently loosens the temporary cuspid, which by this time has had its root quite freely resorbed. Patients then request that the cuspid be extracted as the lateral has not sufficient room. Very frequently it will look as though this was necessary. However if we extract the cuspid at this point rest assured that there will not be room enough for the permanent cuspid, when it wishes admittance to the arch. We should insist upon the retention of the cuspids and as the lateral crowds for room, development all through the jaw and especially at the median line will take place.

In the superior jaw the intermaxillary bones materially develop at this age, and as the temporary cuspid is not lost until between the eleventh and thirteenth year the development is ample. So the incisor teeth (the two centrals and two laterals), have allotted to them the space between the temporary cuspids, as well as that which is made by the growth of the jaw between the time of their eruption and the loss of the cuspid teeth.

Therefore the lateral, which did not seem to have space enough when it erupted will have ample space in five years as it is that

long before any teeth in its immediate vicinity are disturbed. Nature then skips this cuspid tooth which is to hold the incisors in place, and the first temporary molar is replaced by the bicuspid which has ample room and needs little attention beyond the removal of its predecessor at the proper time. Just at this point the second temporary molar may become decayed or lost and patients will insist upon its extraction; but if by any means the patient can be made comparatively comfortable it should not be extracted as its removal allows the first permanent molar to move forward caused by the growing and developing second permanent molar at this age. When the first bicuspid is fully erupted to the line of mastication, we are justified in removing the second temporary molar to give place to its successor. During the eruption of the first bicuspid, the cuspid will very frequently become loose and possibly hard to retain, and the patient will again insist upon its removal; but it should not be extracted at this time.

Leave the temporary cuspid in position until all of the other teeth have been replaced. If the order which nature has mapped out has been preserved, an even set of teeth will result in almost every instance. If the order has been interfered with in the least, the patient's mouth is placed in a condition where gross irregularities, faulty occlusion, and great disfigurement is almost sure to result. Therefore the great necessity for the preservation of nature's order in the extraction of the temporary teeth. It is the one thing to be looked after and adhered to and should be disregarded only in extreme cases, which does not mean merely the satisfaction of the ideas of parents. The operation of extracting temporary teeth is simple. If we have carefully looked the mouth over and decided that it is necessary to extract any tooth, it can be accomplished with almost any pair of forceps. Great care should be taken not to take too deep a grasp upon the tooth, that the developing permanent tooth, which is supposed to be close to its temporary predecessor, may not be injured in the removal of the temporary tooth. It is also advantageous to use a lance separating the gum from the tooth as the gum at or near the neck of the tooth frequently adheres quite strongly to the cementum. By using the lance, laceration of the parts is avoided.

When there is nothing left but the separated or decayed points or unabsorbed portions of roots, it is best to remove them with a root elevator or chisel.

CHAPTER XII.

LOCAL AND REGIONAL ANESTHESIA

Definition. Local anesthesia is that term applied to the results obtained when only a circumscribed part of the body is rendered without sensation.

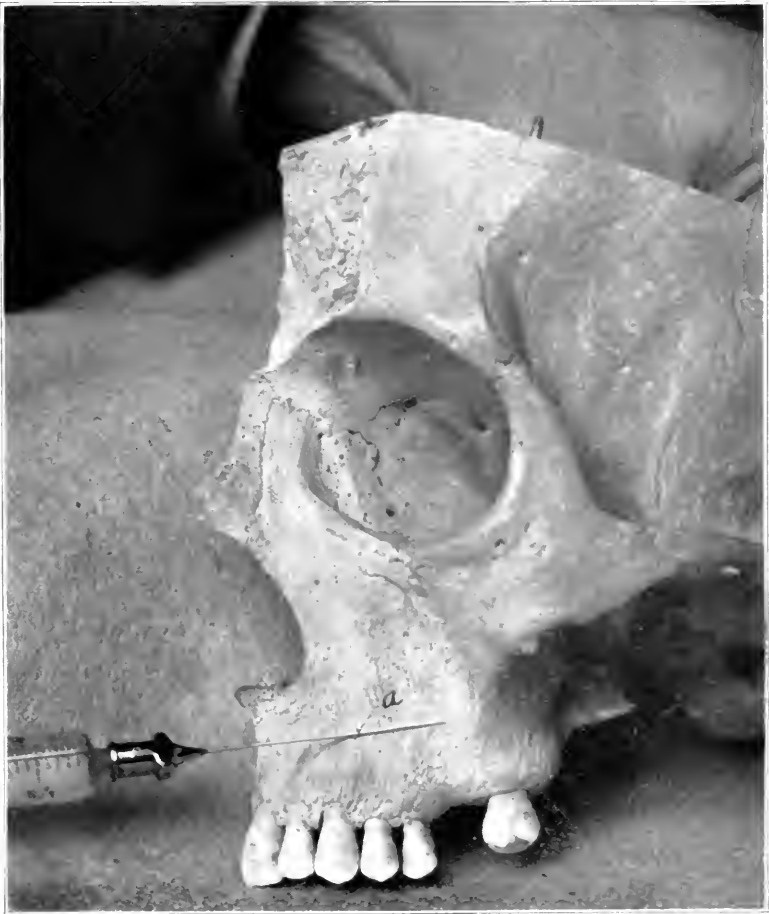

Fig. 144.—Horizontal injection. a represents place of puncturing the soft tissues.

Divisions of Local Anesthesia are surface anesthesia, infiltration anesthesia, intra-alveolar anesthesia, and regional anesthesia (frequently called conductive).

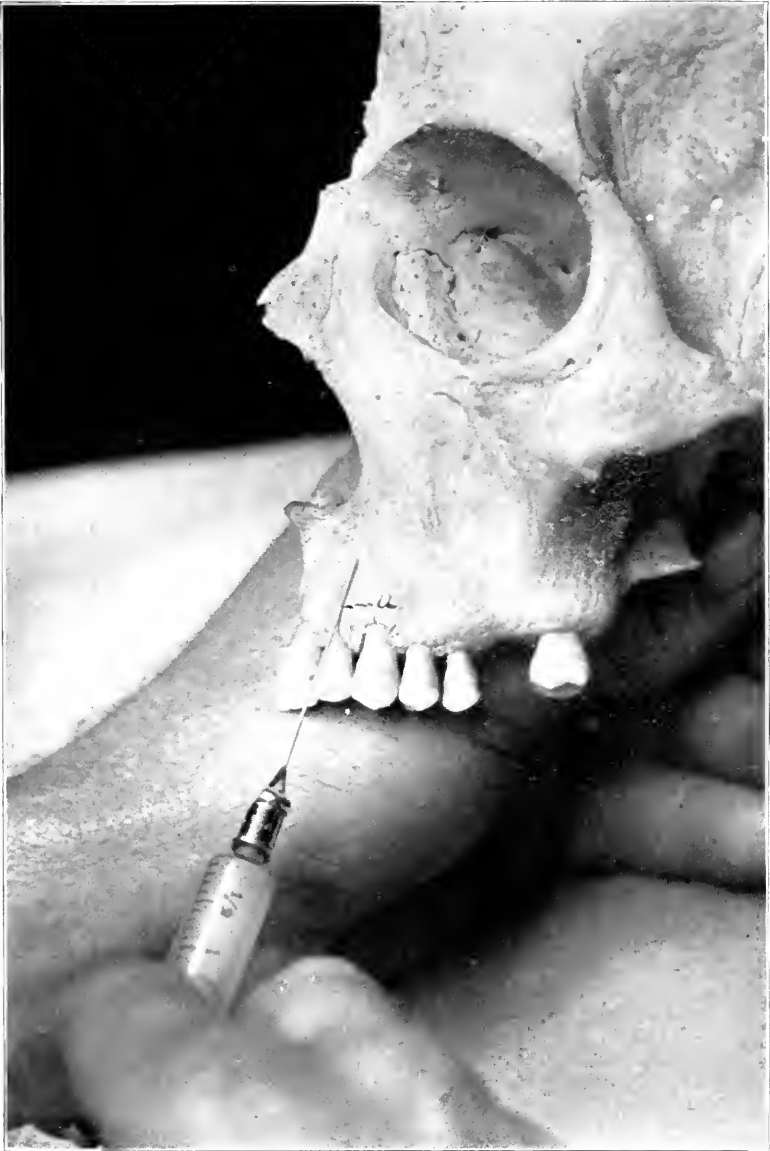

Fig. 145.—Perpendicular injection. *a* represents place of puncturing the soft tissues.

Uses in Dentistry. Local anesthesia when rightly practiced and successfully used is the most practical anesthesia for exodontia, minor surgical operations about the mouth, as well as most of the delicate dental operations connected with pulps of teeth. The suc-

cess of local anesthesia is based on a working knowledge of the oral anatomy, scrupulous asepsis, fresh drugs and a correct technic in their use.

Anatomy. The knowledge of anatomy should embrace a clear understanding of the muscular attachments, the position of the foramen and a knowledge of the position of the trigeminal nerve with its complete ramifications.

Cocaine. For many years cocaine has been almost universally used by the dental profession as the principal local anesthetic. Its

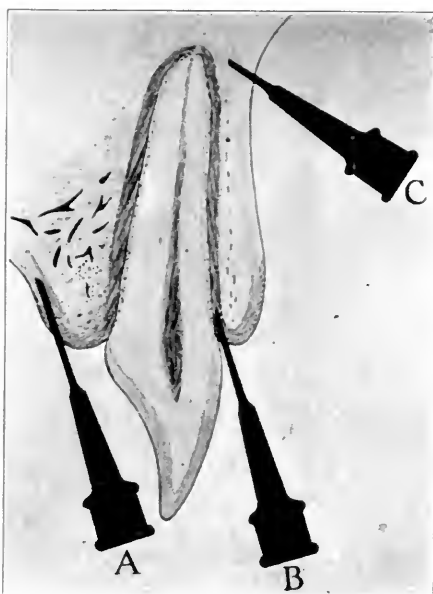

Fig. 146.—Drawing representing the positions of needles in local anesthesia. *A*, position for sub-periosteal injection for surgical anesthesia; *B*, intra-alveolus injection. This will result in surgical and sometimes dental anesthesia. This injection is subject to very severe criticism due to the liability of the introduction of infection. *C*, intra-alveolar injection. This will result in dental anesthesia and quite frequently surgical anesthesia on the side toward which the injection is made.

toxicity was not clearly understood at the beginning and thus occurred overdosing particularly with stale solutions. It has been fully demonstrated that some individuals could stand heavy doses without showing systemic ill effects, while death would result in other cases where only a small dose had been used. For these reasons the profession has been hunting a substitute. That substitute seems to have been found in novocain.

Novocain is equal to cocaine in anesthesia producing power. It

is relatively non-toxic. It is particularly non-irritating even on the most delicate tissues. It is easily combined with suprarenin, and, so combined, does not lose its anesthesia producing power. Neither does it affect the action of the suprarenin. It can be

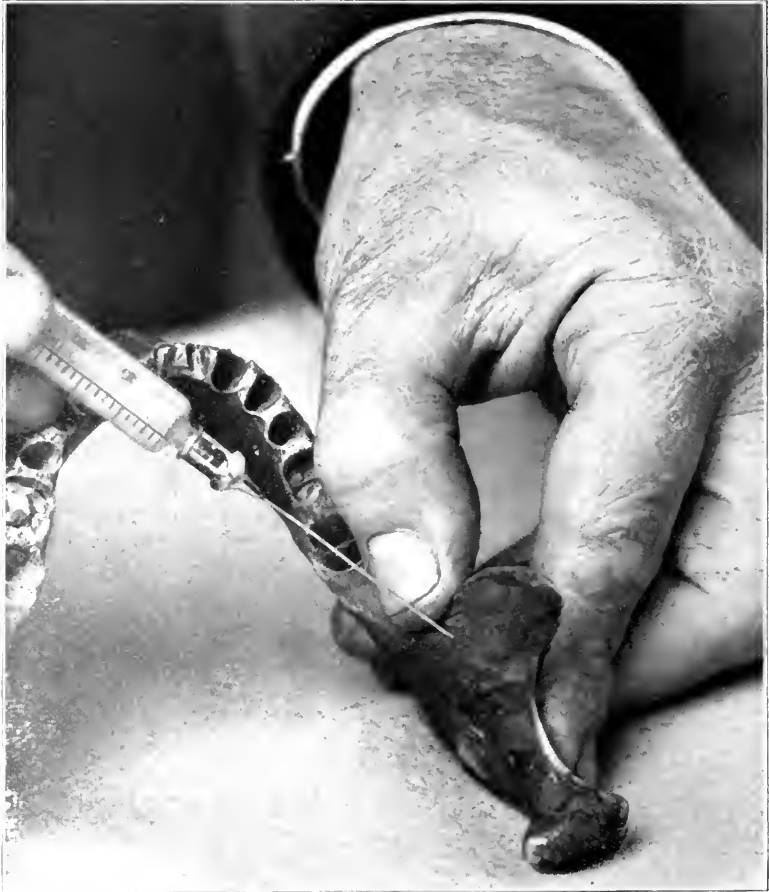

Fig. 147.—First position in the mandibular injection.

boiled for the purpose of completing sterilization. Novocain is a non-habit producing drug, and, as claimed by the manufacturers, is derived from an entirely different source than cocaine, to which it is in no way related. The general effects upon the system after it has been absorbed are scarcely perceptible. Neither the circulation nor the respiration suffers and the blood pressure is not

increased. From experiments it has been found to be only one-seventh as toxic as cocaine.

Doses. The best solution for dental uses is probably the two

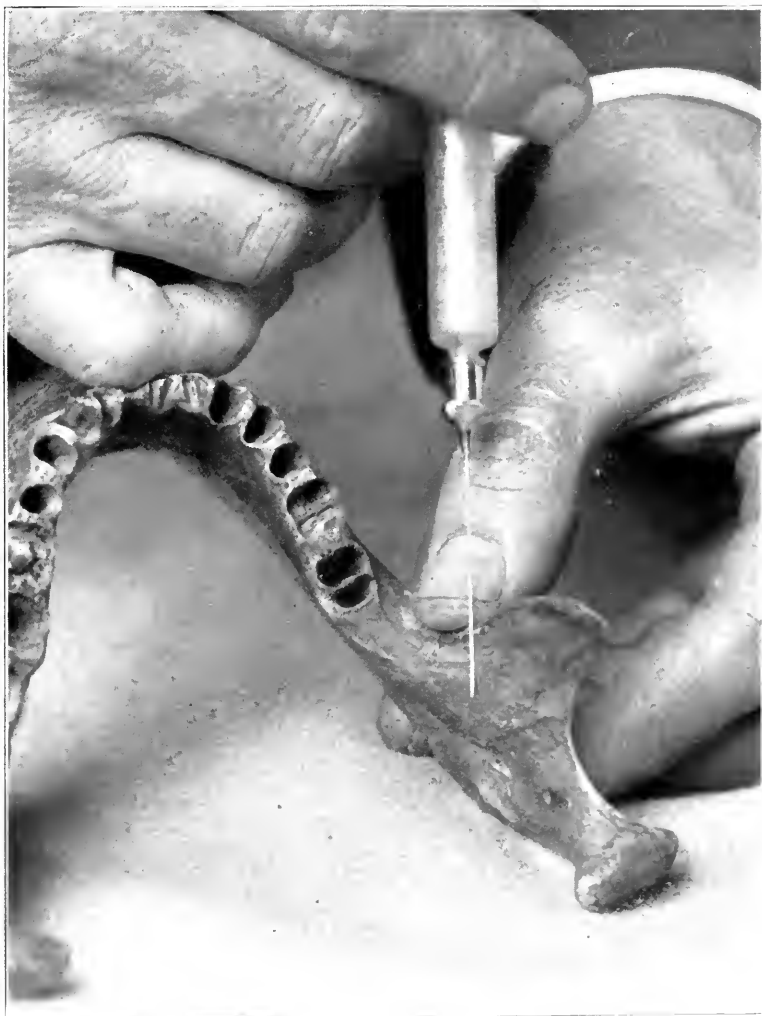

Fig. 148.—Second position in the mandibular injection. This position is taken for the deposit of the anesthesia for the lingual nerve.

per cent solution for both the infiltration and the regional methods. The maximum dose of a two per cent solution is twenty-four cubic centimeters. Such a quantity would never be called for in any dental operation.

Suprarenin is added to contract the capillaries and prevent absorption and infiltration into the tissues beyond the field of operation, thereby increasing the duration and strength of the anesthesia. It is also added in certain cases to decrease the flow of blood.

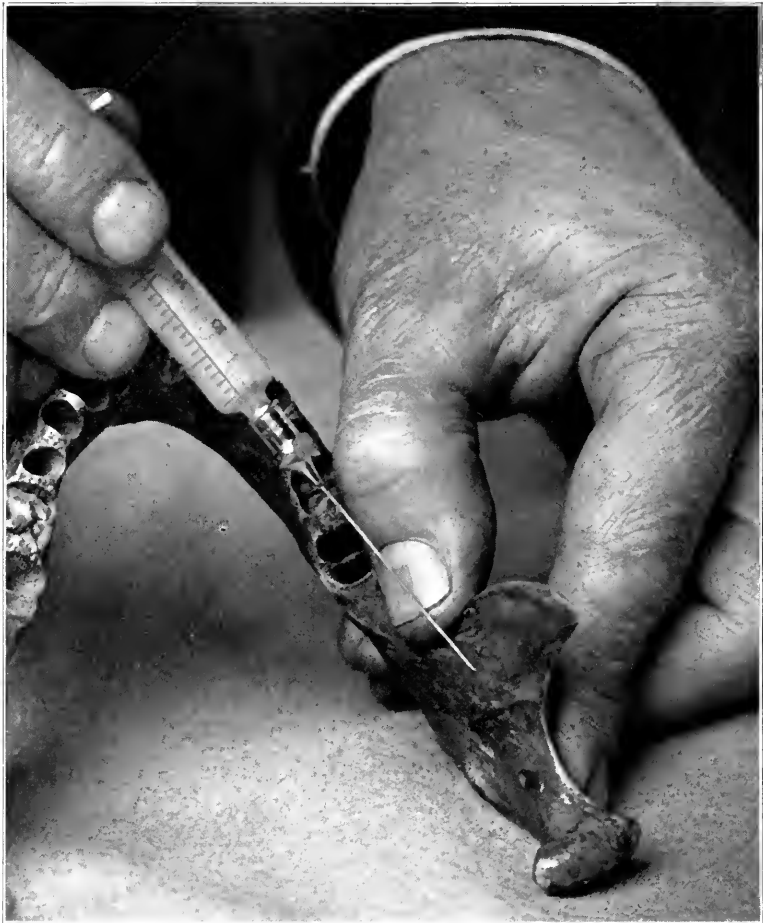


Fig. 149.—Third position for the mandibular injection.

Dosage of Suprarenin. Differing from the amount of novocain used the suprarenin should be varied for individual cases. In fact it has probably been the practice of surgeons to use too strong a solution of suprarenin in their local injections.

Preparing the Solution. In a dissolving cup, place a tablet of

novocain and suprarenin to which add Ringer's solution Q. S. to make a two per cent solution of the novocain. Boil over the open flame for one-half minute to sterilize.



Fig. 156.—Fourth and last position for the mandibular injection.

Ringer's Solution is made as follows: Ringer's tablets; sodium chloride, 0.050 gram; calcium chloride, 0.004 gram; potassium chloride, 0.002 gram. Dissolve ten tablets in 100 cubic centimeters

of aqua dest. Sterilize by boiling and put in bottle double corked to be ready for use when needed.

Stale solutions of novocain and suprarenin should not be used. It should be mixed fresh for each operation. It should not come in contact with anything but the boiling cup and the syringe and should not be left longer than necessary in either of these.

Care of Novocain Tablets. The tablets should not be touched with the hands and should be kept in a bottle, rubber-stoppered. The solution should be as clear as water and discarded as soon as it shows a light pink color.

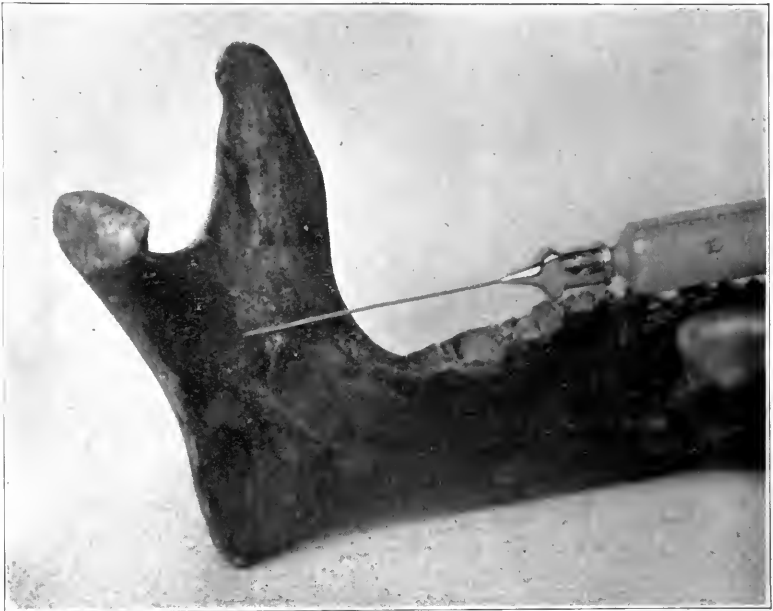


Fig. 151.—A very clear and easy case with the needle in the best position for the mandibular injection.

Surface anesthesia is anesthesia produced by topical application. The method is of advantage upon mucous membranes, as they absorb the solution rapidly. The effect is generally not deep. However, applied to the gum it is usually sufficient for fitting bands and crowns or the finishing of fillings at the gingival margin. A pellet of cotton saturated with a twenty per cent solution of novocain and packed on the floor of the nasal cavity over the incisor teeth will many times anesthetize the incisors of the respective side

sufficient for operations upon the dentine and even for pulp extirpation.

Infiltration Anesthesia is the method whereby anesthesia is produced by injection of the tissues about the nerve endings. The suc-

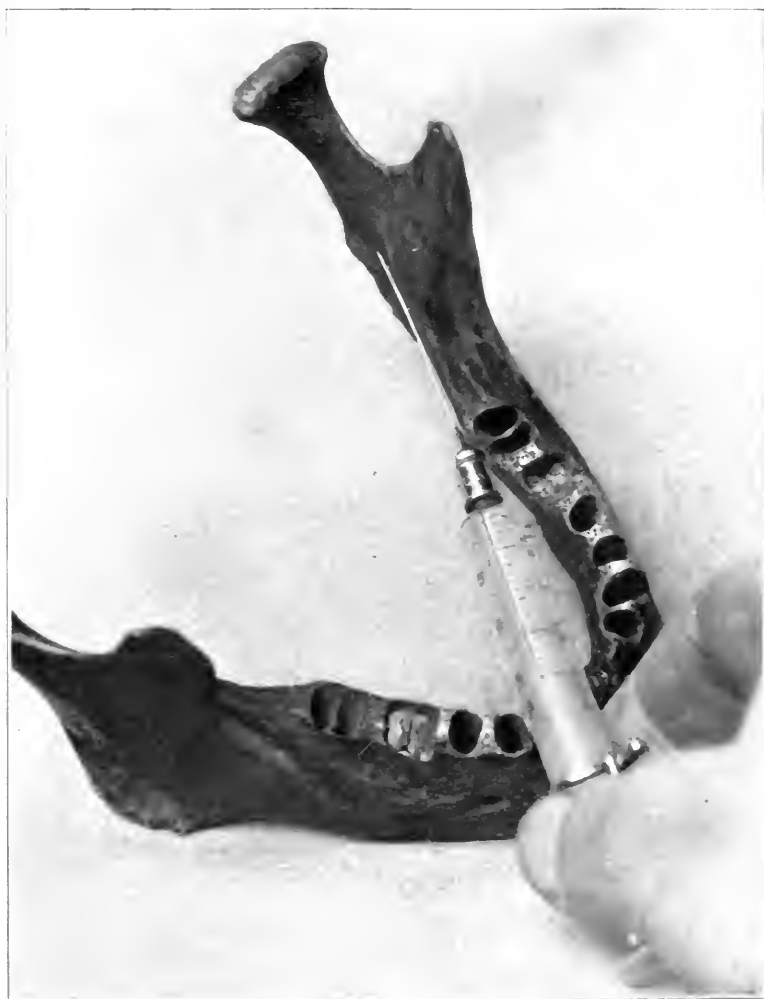

Fig. 152.—This represents a difficult case where the lingula is almost entirely wanting and the needle has entered the sulcus too low and may yet be engaged in the tissues of the external pterygoid muscle which it must have penetrated to reach this position.

cess of the method depends upon the thoroughness with which the tissues to be operated upon are infiltrated. If any nerve endings are missed only partial success is obtained. The infiltration

method is of advantage in the extraction of non-vital teeth, roots and parts of roots. It is the best method for the extraction of all deciduous teeth and roots. This method is used for any of the teeth in the maxilla, but the greatest success is with the single-



Fig. 153.—The same mandible shown in Fig. 152 with the needle passed to position sufficiently high to be above the lingula represented by *a*.

rooted teeth. With the mandible the infiltration method is of little service posterior to the cuspids when vital teeth are involved. There are but two injections to consider with the infiltration method in dental operations, namely, the horizontal and perpendicular.

The Horizontal Injection for the bicusps and molars excepting the third molar. By this method several teeth may be injected with only the one puncture of the tissues, thereby materially lessening the liability of infection. This injection is contraindicated in diseased tissue.

The Perpendicular Injection is applicable for all single-rooted teeth. The needle should generally be inserted just below the gum margin and the point carried lingually or buccally of the apex of

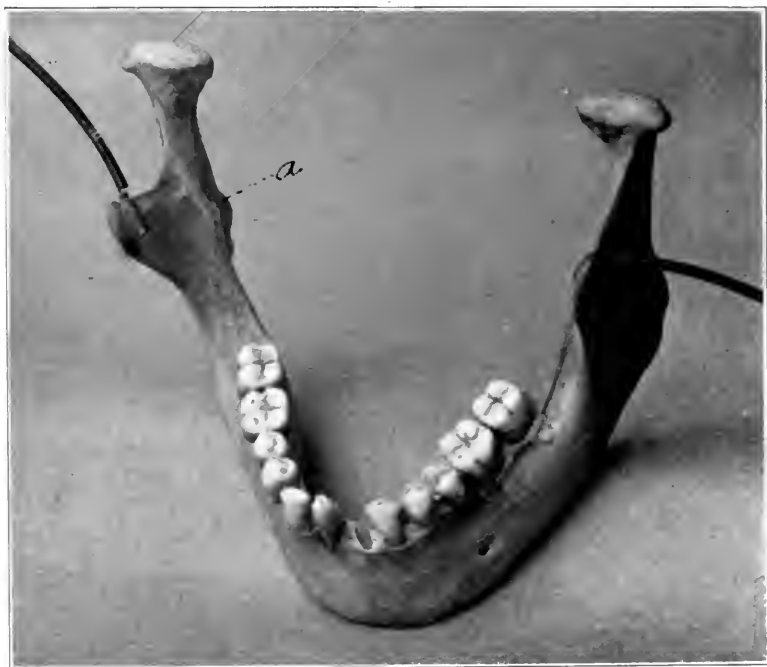

Fig. 154.—This is a mandible which belongs to a class on which it is very hard to give a mandibular injection. Note that the internal oblique line is continuous up to the sigmoid notch. The lingula (*a*) is one cm. higher than normal and is only about four mm. back of the internal oblique line. Conditions like this possibly explain why even the most expert sometimes do not get results upon first attempt.

the tooth the anesthesia of which is desired. The solution is injected without pressure and the needle does not go sub-periosteal as in distinction from the intra-alveolar. The quantity of solution to inject is about one and a half cubic centimeters for the horizontal injection and about one cubic centimeter for the perpendicular. A one-inch needle of small size is best suited for all infiltration work.

Intra-alveolar Anesthesia has for its object the blocking of the

nerve before it enters the pulp of an individual tooth by injecting deeply into the alveolus. There are two injections in this method. They are the pericemental and the subperiosteal, or intraosseous.

The Pericemental Injection has been the most widely used of all the methods of local anesthesia up to this time, for the reason that it requires the minimum amount of the drugs used. This is a point

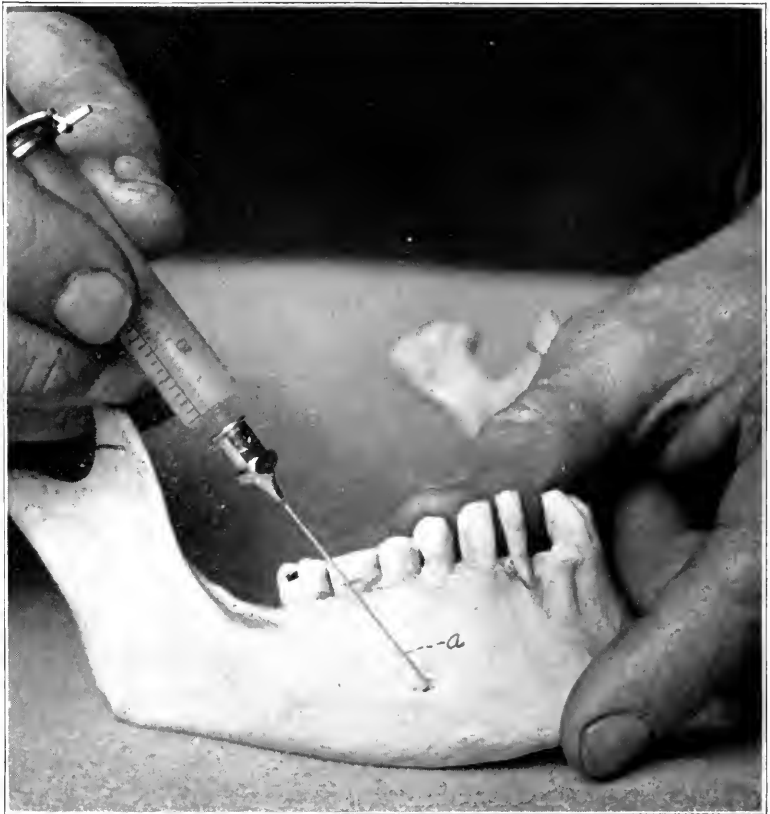

Fig. 155.—First and ideal position for giving the mental injection. *a* represents the position of puncturing the soft tissues. With fleshy patients the syringe barrel will of necessity have to be more anterior.

of great importance in the use of cocaine. However, with the advent of novocain the method will be used less frequently, owing to the liability of infection. The method has been useful in surgery, in extracting teeth, due to the accompanying infiltration of surrounding tissues. The needle should be short, say one-fourth of an inch, and of twenty-eight or twenty-nine gauge.

The Sub-periosteal Injection in intra-alveolar anesthesia is of the greatest use in operating upon vital dentine and pulp extirpation. The needle should be short and stocky, twenty or twenty-two gauge. It is inserted beneath the periosteum and even into the alveolar process itself, as near as possible to the apical foramen of the tooth to be operated upon. Considerable force is used in both of

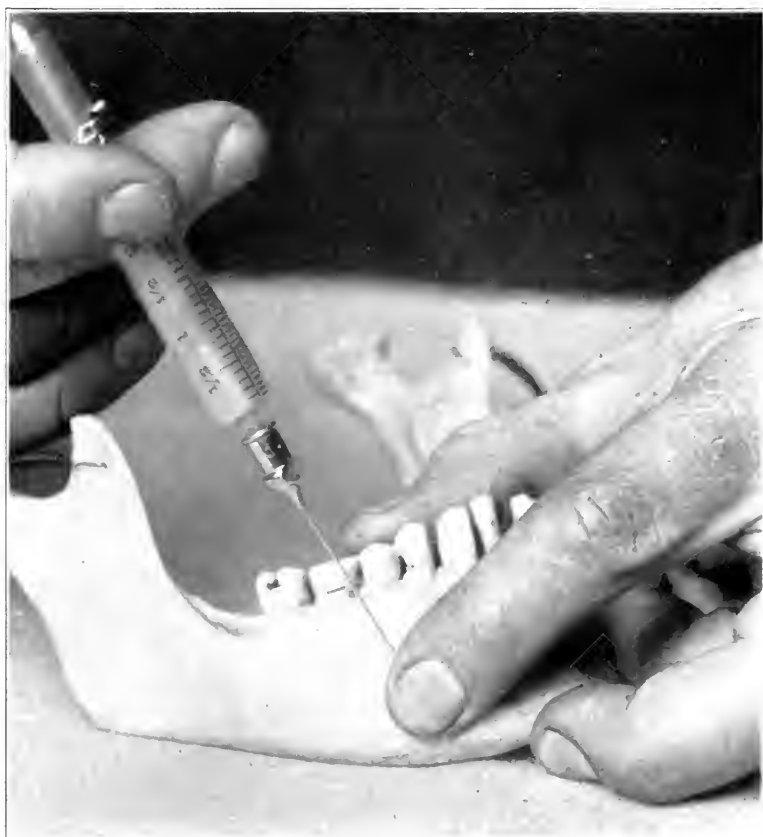

Fig. 156.—Second position for giving the mental injection, showing the finger compressing the tissues over the needle inside of the mouth to facilitate injecting the canal.

the intra-alveolar injections in counter distinction of all of the other methods of local anesthesia.

Regional Anesthesia Conductive Anesthesia is strictly a nerve blocking process whereby a region of the desired extent is anesthetized. The method is not new, having been practiced more or less since the latter eighties, but has received a great impetus, due

to the production of an agent like novocain which is comparatively safe for general practice. Regional anesthesia is by no means limited to the field of dentistry, but its use is as broad as the field of surgery on mankind, as well as that on the lower animals. The surgeon has but to know his anatomy to be able to render a region as void of sensation as though the part had been amputated from the body. For instance, the arm is now operated on without pain, even to amputation, by surrounding the axillary nerve with a puddle of a two per cent solution of novocain with suprarenin, reached with a needle in the top of the shoulder posterior to the clavical and internal and anterior to the scapula. Aside from the completeness of the anesthesia obtained, regional anesthesia has to recommend it the fact that the injection is made far from the field of operation, which is many times undergoing pathological changes often due to bacterial invasion. About the face, we have seven separate and distinct nerve blocking operations for regional anesthesia. The injections are; Gasserian ganglion, Spheno-maxillary, Pterygo-mandibular, Mental, Infra-orbital, Zygomatic, and Posterior and Anterior palatine.

The Gasserian and Spheno-maxillary Injections are employed for major surgical operations about the face and will be passed over by simply mentioning them, as the strictly operative dentist will have no need to employ them. However, the remaining five injections are of vital interest to the general practitioner of dentistry and will be taken up in the order given.

Pterygo-Mandibular Injection has for its object the blocking of the nerve supply to the lateral half of the mandible and the immediate overlying tissues.

Technic of Injection. Palpate the posterior molar triangle having first sterilized the immediate field of puncture with camphor-phenique. Then find the internal oblique line. Puncture the tissues over its inner edge, using a forty-five millimeter iridio-platinum needle, one centimeter above the plane of the inferior teeth with the barrel of the syringe resting on the occlusal surfaces of the bicuspids of the opposite side, as shown in Fig. 147. Push the needle point four or five millimeters into the tissues. Now swing the syringe to the position shown in Fig. 148 for the lingual nerve. Again swing the syringe into the position shown in Fig. 149. Push the needle into the tissues, closely following the inner surface of ramus for a distance of about two centimeters in all (see Fig. 150), varying with the size and age of the patient. To follow the inner

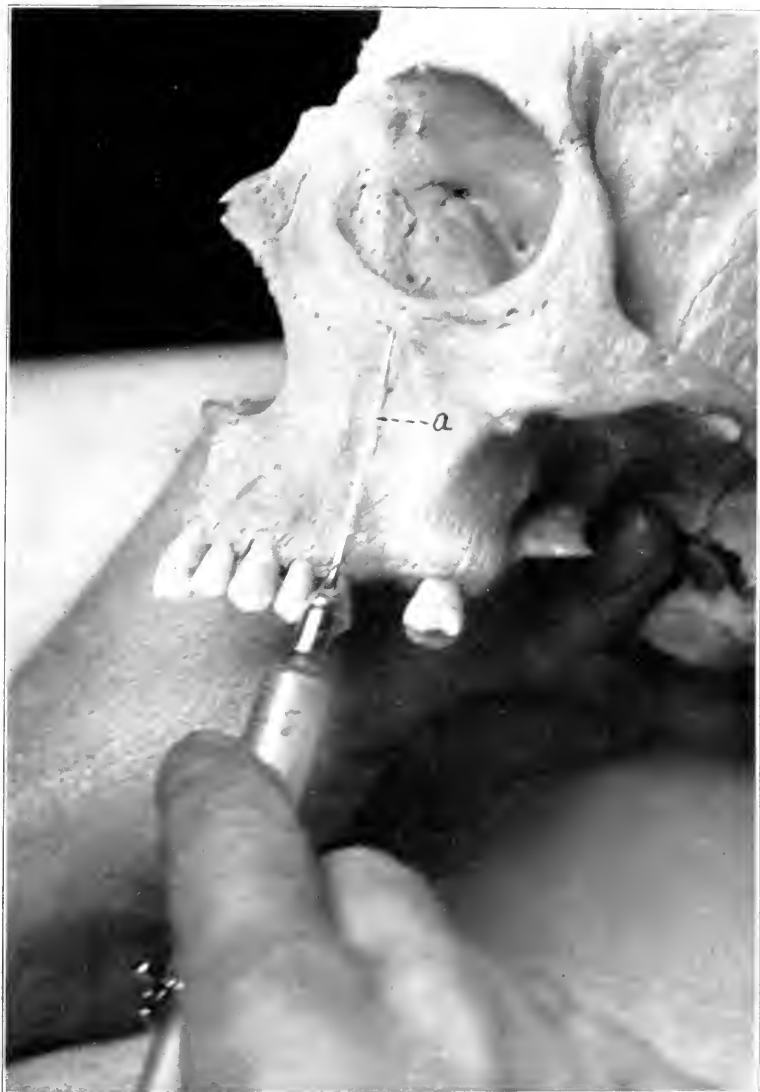

Fig. 157.—Position of needle in giving the infra-orbital injection. *a* represents the place of puncturing the soft tissues. If it is desired to accompany this injection with the perpendicular infiltration injection, the soft tissues should be punctured midway between the point marked *a* and the gingival margin of the gum.

surface of the ramus will necessitate the swinging of the syringe to the median line as the needle progresses. It is very essential that the needle passes into the *suleus mandibularis*, above the lingual, or else it will pass over this into the pterygoid muscle, of-

ten resulting in false unilateral ankylosis, generally temporary, but sometimes more or less permanent and always to be avoided. If anesthesia of only the pulps of the teeth is desired, the special part of the injection for the lingual nerve should be omitted, as there is less liability of injecting bundles of muscle fibers. In case injection is made for surgical purposes, as the extraction of the first molar and bicuspid, an infiltration injection had best be made buccal to the tooth or teeth to be extracted to include the descending branch of the buccal branch of the third division of the fifth, which is given off just above the pterygoideus internus and innervates the soft tissues of the bicuspid and molars buccally. Anesthesia occurs in fifteen to twenty minutes and lasts about one hour, sometimes longer. If longer anesthesia is desired, the amount of the injection is to be increased up to four cubic centimeters.

The first sign of anesthesia is the numbness of the side of the tongue if the injection for the lingual nerve has been included and of the lip above the mental foramen on that side. These are the signs of a successful injection and occur in a very short time, yet the deepest state of the anesthesia may not work back to the posterior molars for twenty to thirty minutes, as frequently happens with operations for the extraction of lower third molars.

Mental Injection. The mental injection is made with a one or two centimeter needle passed as shown in Fig. 155. The operator should compress the mucous membrane and tissues over the foramen. When the needle is felt under the finger (see Fig. 156) one cubic centimeter should be injected while pressing which will direct the solution through the foramen into the mandibular canal, anesthetizing the first bicuspid, cuspid and incisors of the respective side.

Infra-Orbital Injection. This injection is made in the same way as that described for the mental foramen, using the same length of needle and one cubic centimeter of the solution. Dental and surgical anesthesia is obtained in the bicuspid, cuspid and incisors of the respective side.

Zygomatic Injection. The long needle is inserted over the roots of the second superior molar progressing upward, backward and inward, depositing some of the solution as the needle progresses, until the position of the needle is as shown in Fig. 158 where the last of the solution is deposited, in all two cubic centimeters. This injection will reach the posterior superior alveolar nerve and the middle superior alveolar in case it is given off before the maxillary

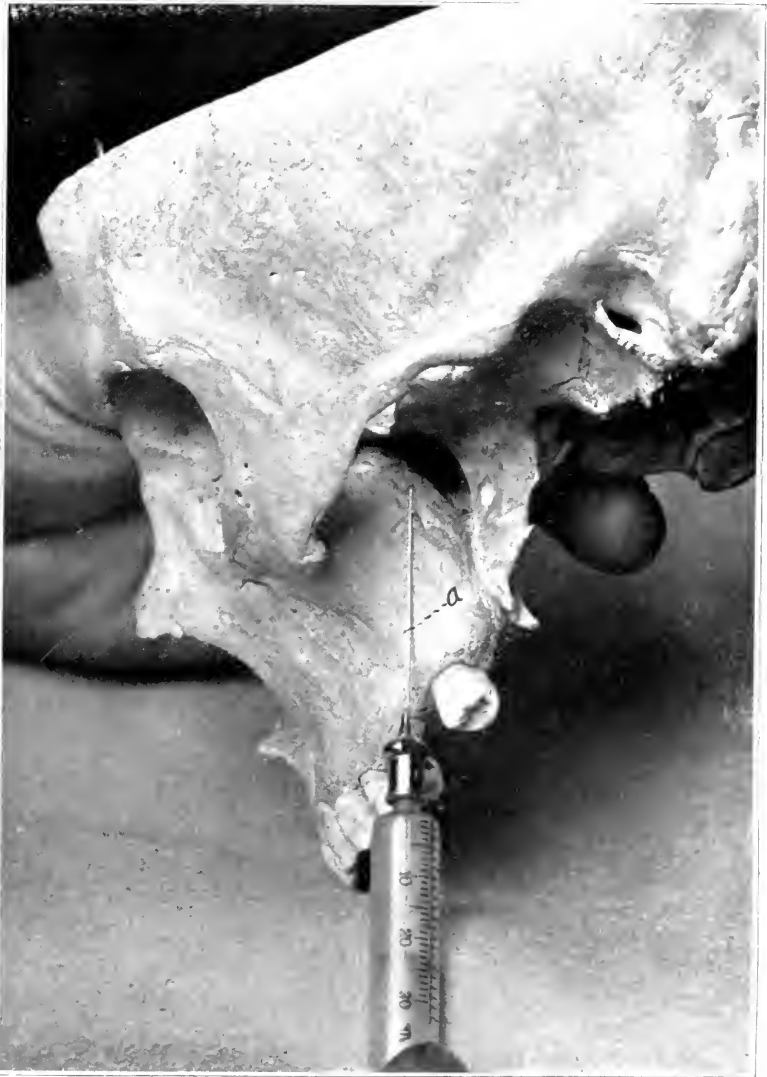

Fig. 158.—Final position of the needle in giving the zygomatic injection. *a* represents the place of puncturing the soft tissues.

nerve enters the infra-orbital canal. It is many times advisable to add to this the horizontal infiltration injection as shown in Fig. 144 to reach the anterior superior alveolar, the branches of which anastomose with the branches of the middle alveolar. This zygomatic injection especially when assisted by the horizontal in-

jection will give dental and surgical anesthesia of the bicuspid and molars of the respective side.

Palatine Injections. The needle is inserted above the gingival margin of the mesial part of the third molar for the posterior palatine and passed upward and backward to the palatine process, injecting one-third of a cubic centimeter. For the anterior palatine the needle is inserted lingually and above the gingival margins of the superior central incisors and passed upward and backward to the anterior palatine canals, depositing one-third of a cubic centimeter. These injections will anesthetize the palatal part of the gums for surgical work, as extractions.

In Conclusion. Always use the simplest method that will be successful. Do not inject pathological tissue. Avoid infection. Use only fresh solutions. Do not inject muscle tissue. Use a solution that is isotonic. Attempt regional anesthesia only after careful study and preparation.

CHAPTER XLII.

THE USE OF FUSED PORCELAIN IN FILLING TEETH.

Definition. A porcelain inlay is a filling made of dental porcelain and retained in position by cement.

A Dental Porcelain is a solidified mass of silicious substances suspended in a flux of fused silicate.

Composition. Dental porcelain is composed: First, of the basal ingredients which are refractory, as silex, kaolin, and feldspar. Second, fluxes used to increase the fusibility. Those in common use are sodium borate, or borax, ($\text{Na}_2\text{B}_4\text{O}_7$), sodium carbonate (Na_2CO_3), and potassium carbonate (K_2CO_3). Third, metals and oxides used as pigments.

Silex (SiO_2) is the oxide of silicon. It is an infusible substance, insoluble except in hydrofluoric acid and is used to give strength to the porcelain. It gives it more translucent appearance.

Kaolin [$\text{Al}_4(\text{SiO}_4)_3 \cdot 4\text{H}_2\text{O}$] is the silicate of aluminum. It is added to the porcelain to give stability, and permits unfused porcelain to be molded and carved in the shaping of the contour.

Feldspar [$\text{K}_2\text{OAl}_2\text{O}_3(\text{SiO}_2)_6$] is the double silicate of aluminum and potassium. It forms over eighty per cent of the basal mass of porcelain and adds translucency.

Pigments. The various shades and colors in porcelain are produced by the addition of precipitated gold, platinum, purple of cassius, oxides of cobalt, titanium, iron, uranium and silver, producing the colors of red, yellow, blue, green, brown and gray.

High-Fusing Porcelain. By high-fusing porcelain is meant a porcelain that requires five minutes or more to fuse at a temperature exceeding the fusing point of pure gold.

Low-Fusing Porcelain. This is a porcelain that requires less than five minutes to fuse at a temperature not exceeding the fusing point of pure gold. This division is one of creation by the manufacturers and commonly accepted by the profession. However the distinction is only relative as porcelain has no definite fusing point, as any enamel or tooth foundation body may be fused on a matrix of pure gold if enough time is given to the fusing process.

Effects of Fusing at Lower Temperatures and a Longer Time.

A more homogeneous mass is produced.

A more characteristic color is maintained.

A less friable filling is produced.

A High-Fusing Porcelain May Be Made Low-Fusing by repeated fusing and grinding.

In Building a Filling by Layers the first layer should be fused to a state of high biscuit otherwise the process of fusing the subsequent layers will over-fuse the first.

High Biscuit Fuse. Heating the porcelain sufficient to obtain shrinkage, but not enough to glaze.

Fine Grinding. The more finely porcelain is ground the lower the fusing point from the same formula and the greater the shrinkage.

Size of Mass. The larger the mass the greater the length of time required to fuse.

Amount of Flux. The more flux a porcelain contains the greater the liability to bubble, which liability increases as the temperature is raised.

Shrinkage in Fusing. High fusing porcelains shrink from fifteen to twenty-five per cent. Low fusing porcelain shrinks from twenty to thirty-five per cent.

Spheroiding. All porcelains have a great tendency to spheroid when over-fused.

A Basal Body is porcelain composed of basal ingredients and the pigments.

A Foundation Body is one composed of basal ingredients to which has been added a flux to increase fusibility, and has been ground less fine than enamel body to raise fusing point and give stability as to form.

An Enamel Body is a basal body which has been more finely ground and to which there has been added more flux to increase fusibility.

The Advantages of the Porcelain Inlay. When skillfully made they more nearly harmonize with tooth structure in appearance. Thermal changes do not readily affect the pulp in vital cases as porcelain is not as good a conductor as metal.

Margins of cavities well filled with porcelain are not readily attacked by caries, as cement dissolves out of the margin to a depth only equal to the breadth of the line exposed. Patients are relieved of sitting with the rubber dam in position for protracted periods.

The Disadvantages of the Porcelain Inlay. The friability of porcelain restricts its use to locations removed from great stress. It is necessary to omit the marginal bevel in all cavities, as the

edge strength of porcelain is no greater than full length enamel rods.

The Cavo-surface Angle should be that which the cleavage of the enamel gives, or about a right angle. Its greatest disadvantage is the fact that the inlay must be set upon unclean walls as the whole process must be done under moist conditions; moisture being necessary to maintain the color of the teeth while trying to imitate their shade. This prevents the placing of the filling upon freshly cut surfaces which have not been moistened, the greatest enemy to all inlay fillings.

Another disadvantage is that the retention of the porcelain depends upon the integrity of the cement, which is not wholly protected at the margins. While porcelain inlays fit the cavity from a practical standpoint, the fact exists that they never exactly fill the cavity, the cement taking up the space resulting from the misfit, and is exposed in proportion to the amount of existing space at the margins.

Indication for Porcelain Filling: Porcelain is indicated in the following:

In cavities in the anterior location in the mouths of patients who have an appreciation for esthetic qualities of dental operations.

In cavities of Class One when they occur in defects on labial surfaces.

In cavities of Class Three when much of the labial wall is gone and rather strong lingual wall remains.

In cavities of Class Four, plan three, vital teeth with rather thick incisal edge, not subjected to great stress in articulation.

In cavities of Class Four, plan one, when proximating tooth is not in position as when the missing tooth is worn upon a plate or is to be subsequently replaced with a crown or bridge.

In cavities of Class Four, plan four, in upper teeth when the lingual surface does not articulate.

In gingival third (Class Five) in anterior teeth exposed to view when patient smiles.

In cavities of Class Six on the six anterior teeth, when the porcelain is built to a thickness of at least two millimeters, and in pulpless lower molars, restoring the entire occlusal surface.

Contraindications. Porcelain is not indicated in the cavities not above mentioned, and in all locations subject to great stress and where good access form is difficult to obtain.

CHAPTER XLIII.

PREPARATION OF CAVITIES FOR PORCELAIN INLAYS

The filling of teeth with porcelain demands some change in the usual and accepted form of cavity preparation for other materials.

Access Form. Access form reaches its maximum in porcelain filling. Even greater access is required than for the gold inlay. Hence preliminary separation should be practiced with all proximal fillings, before forming the matrix, and generally mechanical separation is of advantage when setting the filling.

Outline Form for Porcelain Inlays. Outlines must be extended to regions of sound enamel. The obtaining of full length enamel rods supported by sound dentine is imperative. Extending to self-cleansing margins is of additional advantage, yet not so imperative as with gold filling, as secondary decay is not as liable to take place about a porcelain filling.

The outline should not follow a developmental groove nor cross a ridge at its extreme eminence. Sharp angles in outline should be avoided. Extension for prevention as applied to the embrasures is not as great as with metal fillings.

Extension for Resistance to Stress at margins is more essential than with gold, due to the friability of porcelain margins.

Resistance Form for Porcelain Inlays. The rules for flat seats for all fillings apply equally to porcelain fillings. The use of the step in Class Four is essential to give added resistance to the tipping strain. Margins should be extended to locations less frequented by the crushing strain.

Retention Form for Porcelain Inlays. Maximum retention form is required in all directions except one, until the matrix has been formed and the filling made ready for setting, when retention should be added in the remaining direction.

Acute line and point angles should be avoided; all angles being rounded angles until the matrix is formed.

Convenience Form for Porcelain Inlays. The filling of teeth with porcelain requires more cutting for convenience form than for any other method. This fact makes such fillings contraindicated many times, due to the great loss of tooth substance necessary to properly form the matrix and introduce the filling. Previous separation will overcome this cutting to a large extent with this as well as other fillings.

Finish of Enamel Walls. All finishing of enamel walls must be completed before forming the matrix. The cavo-surface angle should be a right angle as the strength of fused porcelain is about equal to supported enamel margins. If a bevel angle exists it should be deeply buried.

Toilet of the Cavity. This is attended to the same as with other inlay fillings before forming the matrix.

Another Cavity Toilet is necessary just before setting the inlay. This consists in washing the cavity with chloroform to dissolve any oily substances adhering to the cavity walls. This is

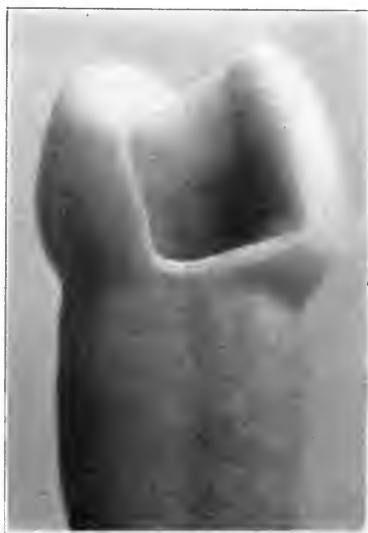

Fig. 159.—Cavity preparation for a Class Two porcelain inlay, non-vital case with the porcelain occupying a portion of the pulp chamber.

followed with absolute alcohol and moderately dried. Excessive desiccation is not required and in fact should not be practiced as the integrity of the cemental substance in the enamel is injured and liability to marginal checking increased.

Preparation of Cavities of Class One. Defects in enamel. Porcelain is indicated in cavities on the labial surfaces of the six anterior, due to faulty enamel. These are shown as small orifices in the enamel surface, generally rounded in form, and is the result of imperfect development. The cavity should be not less than two millimeters in width at its narrowest point, as a smaller cavity than this hinders proper working.

Avoid the Exact Circle in outline, as this will bewilder the operator as to the position when setting. In case the outline is so near a circle as to make position questionable, the axial wall should have a small rounded pit at one side to guide the operator in setting.

The Axial Wall should, in large cavities, be the miniature of the tooth surface in which it occurs. The axial wall of small cavities should have a rounded groove cut around the entire circumference.

The Surrounding Walls should meet the axial at an obtuse angle to relieve any undercuts before the matrix is formed. When the

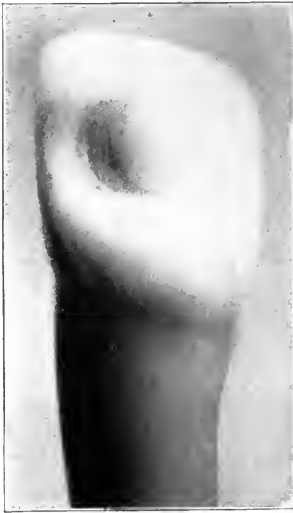

Fig. 160.—A Class Three cavity labial approach for porcelain inlay.

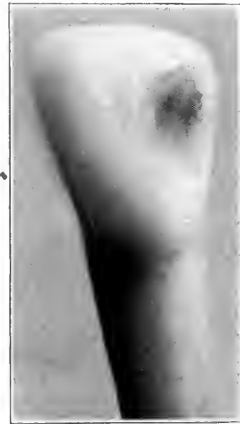

Fig. 161.—A Class Three cavity labial approach for porcelain inlay.

inlay is ready to set give the cavity retentive form by making the base line angles acute.

Cavities in Proximal of Bicuspids and Molars. Class Two. Experience has taught us that porcelain is not indicated in this class of cavities. Their location subjects the filling to extreme crushing strain which porcelain will not stand. The occlusal surfaces are of an irregular shape and made up of a great variety of forms with surfaces in any number of planes. This makes the right angle cavo-surface angle demanded in porcelain filling improbable and results in exposing porcelain margins of an acute angle. (Fig. 159 may be used.)

Cavities in Proximal of Incisors and Cuspids Not Involving the Angle. Class Three. This class of cavity is ideal for porcelain inlays and is by far the most sightly filling when properly done.

These Cavities Should be Divided Into Two Classes in accordance with the three different lines of approach.

First division, labial approach; second division, lingual approach.

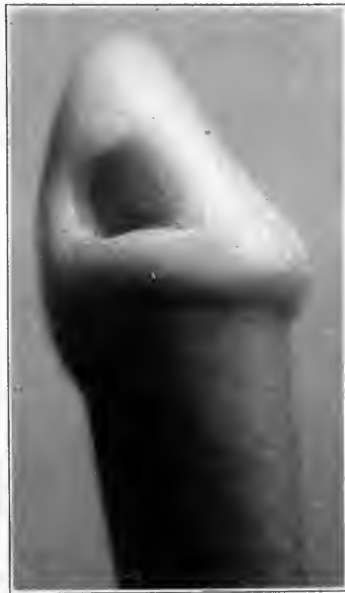

Fig. 162.—A Class Three cavity lingual approach for porcelain inlay.

Labial Approach. This approach should be decided upon when any considerable amount of the labial enamel is to be replaced and a lingual wall is possible. (Figs. 160 and 161.)

The Gingival Wall should be extended gingivally to include all affected enamel. It should be flat axio-proximally and meet the axial wall at an angle slightly acute. It should meet the lingual wall at an angle slightly obtuse.

The Axial Wall should be flat labio-lingually and be continuous from the axio-lingual line angle to the labial cavo-surface angle which results in the entire removal of the labial wall. This wall should meet the lingual and incisal walls at an acute angle. The incisal lingual line angle should be slightly obtuse. This results

in a cavity retentive in all directions except to the labial which gives it "draw" in this direction.

Lingual Approach. The whole general plan is reversed resulting in the retention of all or a good portion of the labial wall and an entire absence of the lingual wall resulting in the draw being to the lingual.

To Resist the Tipping Strain the lingual step may be added. This is done by cutting away a sufficient amount of the lingual enamel resulting in two axial walls. One will face the proximal and



Fig. 163.—A Class Four cavity incisal approach for porcelain inlay.

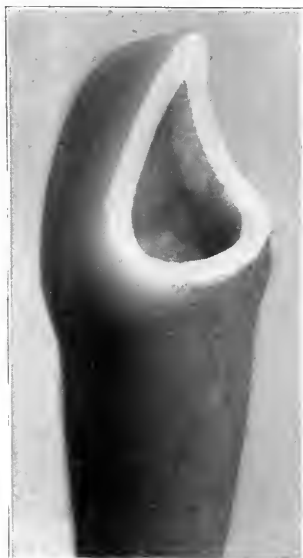

Fig. 164.—A Class Four, plan one, incisoproximal approach for porcelain inlay.

the other the lingual. This creates a line angle where the two walls unite, the axio-axial line angle which should be a rounded angle. Just before setting the inlay the axial wall should be slightly grooved next to the surrounding walls, except in the region of the incisal point angle.

Cavities in Proximal of Incisors and Cuspids Involving the Angle. Class Four, Plan One. This plan of angle restoration may be successfully accomplished with porcelain when the conditions of stress would permit of this plan being used with any other ma-

terial. The cavity form is the same as that just described for a gold inlay.

Proximal Approach May be Used in this instance under some conditions. The incisal approach may be used when excess separation has been produced a little greater than the length of the incisal line angle, as well as more than the thickness of the inlay measuring from contact point to the greatest depth of the axial wall, which permits the filling entrance from the incisal.

To Break the Cement Line on the Incisal Edge a rounded groove

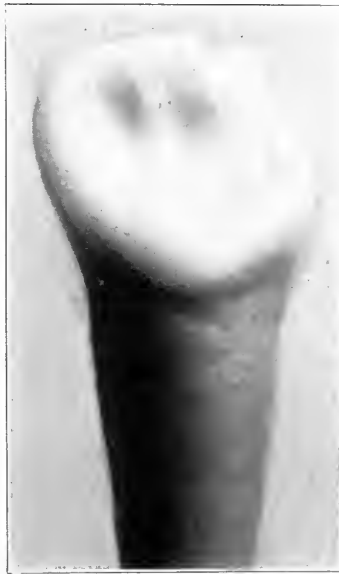

Fig. 165.—A Class Four, plan two, with double step for porcelain inlay.

should be made from the external end of the incisal line angle to the incisal cavo-surface angle.

Plan Two, Class Four, is suitable for porcelain filling provided the material will stand the strain at union of step and cavity proper. The double step is advised. (Fig. 164.)

Plan Three, Class Four. The addition of the lingual step makes many angle restorations with porcelain practical, as the tipping strain can be well provided for by grooving in the lingual axial wall next to the distal or mesial wall according to whether the cavity is distal or mesial. The cavity should be so shaped that the draw is directly to the incisal. The gingival wall should be

flat and meet both axial walls at an acute angle. The axio-labial line angle should be acute. The lingual axial wall should be concave. The axio-axial line angle should be a rounded angle and continue out to the incisal cavo-surface angle.

Plan Four, Class Four. In angle restoration the creation of both incisal and lingual steps is most popular. The incisal step is formed in much the same way as when gold is to be used. However the pulpal wall should be placed farther from the incisal edge and be laid in a plan less acute to the axial wall than for gold.

The angle formed by the junction of these walls, the axio-pulpal angle, should be rounded. In forming the lingual step the enamel may be removed entirely to a level of the gingival wall, or it may be only as much of the incisal portion as may seem necessary to strengthen the body of porcelain in the incisal region and resist the tipping strain.



Fig. 166.—A Class Four, plan three, for porcelain inlay.

The Double Step is of service in cases where there has been extensive loss of tooth structure, particularly in non-vital cases. This plan results in a gingival wall and two pulpal walls; also in two short axial walls placed on an equal number of levels. The gingival and pulpal walls should be made to meet the axial walls at acute angles. Each of the two pulpal walls should be grooved from the connecting axial walls, and each axial wall in the central portion resulting in a continuous groove from the gingivo-axial line angle to the incisal edge. This cavity has draw directly to the incisal.

Cavities Occurring in the Gingival Third of Class Five. Labial cavities in the gingival third are favorite places for porcelain and should to a large measure displace gold. If the cavity extends beneath the gum line, the gum should be forced from position by

previous packing of gutta-percha or cotton saturated with chloro-percha.

Outline Form should be the same as for other filling. The axial wall should be the miniature of the tooth surface wherein the cavity occurs. The gingival wall should be flat and meet the axial at an acute angle. All other surrounding walls should meet the axial at slightly obtuse angles. This gives a cavity with draw to the labial allowing the incisal portion to swing out in advance, the inlay going to place gingival first.

This hinge movement is slight but constitutes a valuable point

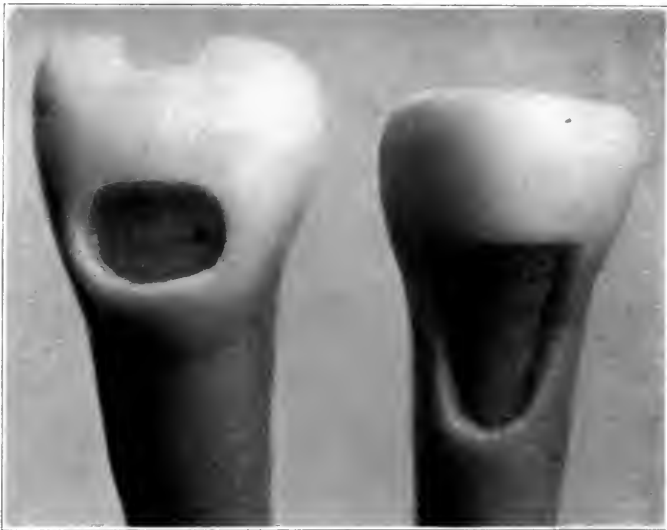

Fig. 167.—Class Five cavities for porcelain inlay.

in subsequent retention. Just before setting the inlay the axio-incisal line angle should be sharpened to add retention form. In cases where the decay resulting in a cavity is materially *horseshoe* in form the cavity may be filled by two distinct operations.

This is accomplished by filling the cavity with cement and cutting out one-half and filling with porcelain. This completed, the other half is cut out and the operator then proceeds to fill that portion. This results in two porcelain fillings with cement between.

One Point Must Be Observed. The first portion of porcelain will necessarily slightly overlap a cement wall. Before setting, this portion of the inlay must be ground at the expense of the external surface of the filling to reverse the draw, or this portion of

the remaining cavity will be found with an objectionable undercut hard to manage.

Restoration of a Portion of the Incisal Edge. The general outline in this class of cavities when they are simply a notch in the body of the tooth, is that of the half moon when viewed either from the labial or the lingual. However the lingual enamel should be removed for a greater distance root-wise resulting in a lingual step to provide against the tipping strain. The pulpal wall should have a groove mesio-distally in its central portion and extend well

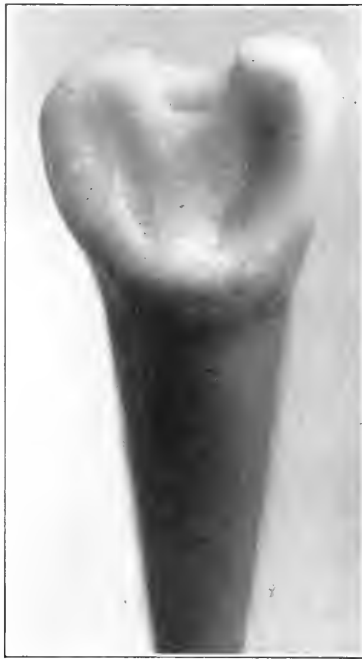

Fig. 168.—Incisal cavity for porcelain inlay.

up along both mesial and distal walls, and with the larger cavities coming out to the cavo-surface angle.

Restoration of the Entire Incisal Edge—Outline Form. The enamel is chiseled root-wise till it is firm and will result in a thickness of porcelain at all points equal to at least two millimeters.

Retention is accomplished by the addition of pins, or a generous lingual step, or both.

In vital cases where pin retention is to be used there should be cut a V-shaped groove mesio-distally, the spreading angles of

which should come just short of the dento-enamel junction labially and lingually. Mesially and distally it should continue to the cavo-surface angle. A pin hole should then be bored in the extreme ends of this groove not a great distance from the dento-enamel junction in the dentine to receive the pins. When the lingual step is to be added the enamel on the lingual is removed additionally to a distance root-wise at least equal to the labial exposure; also an amount of dentine sufficient to make the newly created axial wall meet the two pulpal walls at right angles. If pins are to be added the holes should be bored in the floor of the pulpal wall nearer the labial surface.

In Pulpless Six Anterior Teeth the pulp chamber may be rounded out and porcelain so baked as to form a post of porcelain for retention.

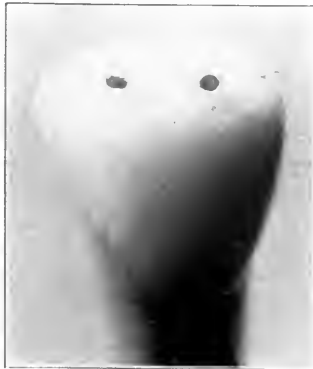

Fig. 169.—A Class Six cavity using pin anchorage for porcelain inlay. This plan is also used with the gold inlay.

Pulpless Molars are treated in the same way.

Treatment of Teeth With Malformed Enamel. The major portion or all of the enamel can be successfully replaced with porcelain.

The enamel is removed to the desired point resulting in a gingival wall entirely encircling the tooth. Sufficient dentine is removed in the incisal region to render the largest girth at the gingivo-axial line angle which is continuous around the tooth. This leaves a peg-shaped body of dentine over which the porcelain is telescoped. The method is termed the jacket crown and the method of construction and setting is fully described in the writings of others on crown work.

CHAPTER XLIV.

THE CONSTRUCTION AND PLACING OF A PORCELAIN INLAY

Following the completion of cavity preparation the next step in porcelain inlay filling is the formation of a matrix.

A Matrix is a thin piece of metal shaped to the cavity form in which the porcelain is fused.

Matrix Material. The matrix materials in common use are pure gold, pure platinum and platinized gold. Pure gold and platinized gold can be used only with what is termed low fusing bodies, while pure platinum can be used with either high or low fusing bodies. Gold is more easily shaped to cavity form, but tears more easily and does not hold its shape as well after burnishing.

Thickness of Foil. The most popular thickness of platinum foil to be used in the construction of a matrix is 1-1,000 of an inch. Thicker than this is difficult to manipulate, while the thinner foils tear too easily, and are more liable to distortion during the processes of building and fusing.

Annealing of Matrix Material. This is best accomplished by placing the entire sheet of material as it comes from the supply house in the electric oven and bringing it to the desired temperature before cutting off the piece desired for the case in hand. Pure gold and platinized gold should be brought to the full red heat or about 1,200° or 1,300° F. Platinum should be carried up as high as it is expected to carry the temperature during the process of fusing and held there for two or three minutes. It is not necessary to anneal several times during the process of shaping the matrix.

Methods of Forming the Matrix. There are three general methods in use for the construction of a matrix. First, burnishing directly into the cavity. Second, swaging over an impression of the cavity. Third, swaging into a model of the cavity.

Each has its advantage in different cases and are recommended by all porcelain workers. However, the combination of the first and second methods will bring good results and is the method requiring the least time.

Technic of the Combination Method. First take an impression of the cavity. If the cavity is large it is best to use modeling compound, trimming off that part which flares out over the external

surface of the tooth. The matrix is then shaped over this impression with the fingers, using the soft part of the ball of the thumb as a counter die.

The most prominent parts of the impression will represent the deepest portion of the cavity and will assist in causing the matrix to reach this without tearing which is accomplished by using the impression to crowd the matrix to position. The impression should be removed leaving the matrix, which has been by this means partially swaged, in the cavity.

The Removal of the Impression Without Carrying Away the Matrix is accomplished by bending the portions of matrix exposed above the cavo-surface angle away from the impression. The matrix should not be burnished down onto the external surface of the tooth until the other portion has been made to thoroughly conform to the cavity walls.

When the impression has been removed the matrix should be thoroughly burnished to all cavity walls beginning at the seat of the cavity first. This burnishing is done with suitable smooth-faced instruments, keeping moistened chamois skin discs between the instrument and the matrix.

The cavity should now be packed with *damp cotton balls* crowding the matrix ahead of them to every part of the cavity. While this cotton is in position, the matrix should receive thorough burnishing at the cavity margins and finally be turned out on to the external surface of the tooth a distance of one-fourth of a millimeter to one full millimeter in all locations except one, which may be two or three millimeters.

This one place will *facilitate handling* during the process of filling in the porcelain. The cotton may now be removed and gum camphor or gold inlay casting wax crowded into the cavity over the matrix, filling the cavity nearly full with one piece of material packed to place with a flat-faced amalgam burnisher as large as the cavity will admit.

Removal of Matrix. The matrix is then removed from the cavity by sticking the tine of an explorer into the body of the *camphor or wax* near its central portion. The matrix and wax or camphor still on the tine of the explorer should be immersed in alcohol if camphor has been used or chloroform if wax has been used, which will immediately loosen the tine and dissolve the material from the matrix, after which the matrix should be picked up

in the lock tweezers at that portion where the metal has been left to extend the farthest from the cavo-surface angle.

The matrix should now be passed through the alcohol flame when the camphor or wax remaining will be burned off leaving no ash.

Wood as an Impression. In simple small cavities it is well to shape a piece of soft pine (as cork pine) to proximately fit the cavity. This should be then introduced against the deepest portion of the cavity and given a few blows from the mallet which will cause the wood to conform to the floor of the cavity. This should then be used as an impression and the matrix forming proceeded with, as described when modeling compound has been used. The use of the stick with modeling compound on the end is of advantage in large deep cavities where the pulp chamber is to be filled with porcelain in place of metal pin. By this means it is possible to place a matrix well to the bottom of any cavity without tearing, provided the walls are regular and have the proper draw devoid of under cuts.

Taking the Spring Out of a Matrix. If a matrix seems to retain "spring" and does not seem to lay well on all surfaces, as frequently met with in complex cavity outlines, this may be removed by the following method: When cavity is thoroughly packed with wet cotton, stretch a piece of rubber dam over the matrix, cotton and all, and thoroughly burnish the entire outline. If "spring" still persists, remove the matrix and anneal, and then repeat the method when it will be found that the fault has been removed.

Selection of Porcelain. The selection of that portion of the inlay which replaces dentine and that which replaces enamel should be attended to before the process of building begins. The part replacing dentine should be of foundation body coarsely ground and of a yellow color in all vital cases. In devital cases this shade may be darkened by the addition of the brown shade, and in vital teeth for young patients, particularly if the cavity is shallow, or on a distal surface, the addition of white powder is of advantage to lighten the shade of yellow.

The enamel shades may be decided upon after a careful study of the shades and hues found in each case. Delicate shading is secured by building one layer upon another, thus getting the benefits of reflected light. The deep and pronounced shades and colors are best obtained by building in sections. Teeth that are much of one color and not pronounced in lines of shades will be best represented by the layer method, while teeth that are decidedly yellow at the

cervix and pronouncedly blue at the incisal edge are best represented by building in sections provided; the cavity involves both regions spoken of as in Class Four (proximo-incisal).

After the different sections have been applied and brought to a hard biscuit fuse, a uniform layer of neutral color is applied over the whole and all fully fused.

Applying the Porcelain to the Matrix. The foundation body is put upon the porcelain or glass slab and sufficient distilled water, or alcohol or a mixture of both, added to make a stiff paste, stiff enough to retain its shape when taken up on the point of a spatula.

A small quantity of this is laid in the bottom of the matrix and by a little jolting made to flow over the surface. This jolting is best produced by drawing the edge of a fine gold file over the tweezers holding the matrix. The additions should be continued until sufficient body has been added. Excess moisture is removed by repeated jolting and absorbing with blotting paper. Dark colored blotting paper is used so as to detect any paper fibers which by accident adhere, which should be removed. The addition of dry porcelain of the same color will take up the excess moisture, the surplus adhering powder being brushed off with a small brush.

In Case the Matrix is Torn, the opening has to be comparatively large to cause the porcelain to run through, unless the matrix is damp on the cavity side or too moist a mix is being applied. Should any of the porcelain flow through, it can be removed with a dry brush provided the porcelain has been rendered quite dry.

Do not apply a wet brush to the cavity side of the matrix. The inlay should now be placed in the oven and fused sufficiently to produce the greater part of the shrinkage, but not to a full gloss. When removed from the oven if more foundation is needed it should be added and fired to a high biscuit.

The Enamel in Proper Shades is now added, either in layers or sections, and again fired to a high biscuit. The inlay should then be tried into the cavity for bulk and contour. If not correct more enamel is added. When the contour suits, the inlay is replaced in the oven and fired to a full glaze. The skill necessary to reproduce the colors of the teeth comes with practice and the longer one engages in this work the more often will the results please the operator.

Technic of Fusing Porcelain. The furnace should be first heated up to a bright red and held there for a minute or two, to thor-

oughly warm the fire clay entirely through, and then the lever returned to the first button to maintain a warm oven.

When ready to fuse, the furnace is completely shut off provided the oven shows any redness. Never put an inlay mix into a hot oven, as it causes too rapid evaporation of the moisture, producing checks and an extremely friable porcelain.

When the inlay is in position in the oven the lever is put on the second or third button and advanced only when the needle of the milliamperemeter ceases to advance. The heat should be increased gradually and when it has reached the desired degree immediately shut off. Each furnace has a way peculiar to itself and each operator should learn the time for perfect results.

Grinding to Contour. After the final fusing the inlay should be tried in and ground to contour and articulation on the incisal or occlusal surface before removing the matrix.

To Remove the Matrix. Drop the inlay and the matrix in alcohol or water, then remove and peel the matrix from the inlay, drawing from the margins all around first, then from the body of the filling. This procedure prevents chipping at the margins.

Etching the Cavity Side of Inlay. When the matrix has been removed the inlay should be embedded, contour surface down, into a sheet of pink base plate wax. With a warm spatula it is sealed entirely around, being sure to cover the edges of the inlay on the cavity side for a short distance, say one-half millimeter. This leaves the cavity side exposed, upon which is applied hydrofluoric acid. This is applied by dipping a stick in the wax bottle in which the acid is delivered, and painting the inlay with a small quantity of the acid. Two minutes will generally be sufficient to thoroughly etch the surface.

Toilet of Inlay. The inlay should be flooded with water, removed from the wax and placed in boiling water for a few minutes and then given a chloroform bath, and dried with warm air while laying on spunk or blotting paper, and should not be again contacted with the hands on the cavity side.

Toilet of Cavity. The cavity should be rendered dry. All inlays, and particularly the large ones, are best set with white cement with the faintest tinge of cream. The attempt to match the color of tooth substance with the cement is an error as the pigment in the cement increases the shadow line which is objectionable. Use a white cement mixed to the consistency of greatest adhesiveness yet thin enough to flow from between inlay and cavity walls

with light pressure. This will be about the consistency of thin cream. The cement should be thoroughly and rapidly spatulated and when the "stick" is felt under the spatula it should be applied to the cavity and the surface of the inlay which is immediately placed. Use a non-corrosive spatula, preferably bone or agate. Apply to the cavity with a flattened orangewood stick. Press inlay to position with a stick of orangewood using gentle pressure, gently tapping the end of stick with the knuckle of the forefinger, or blows of equally cushioned nature.

In labial and buccal fillings (Class Five) the inlay should receive gentle pressure for five or ten minutes. In proximal (Classes Three and Four) the filling should be gently wedged against the proximating tooth or tightly ligatured to position and so left for some hours.

The Finishing should be left till another sitting. If the building has been well done there will be little to do. All overhanging margins should be dressed down with fine stones and disks and the surface polished with small Arkansas stones, using a light hand and keeping the stones well watered.

APPENDIX

As a suggestion to those who use this book as a text in college teaching, the author submits the following courses based on the subject matter of the foregoing chapters and illustrations. Herein are also shown the author's selection of instruments for doing the work and Dr. Rathbun's "dentech" to take the place of the patients.

While carrying out this course the freshman completes the first seventeen chapters. During the second year the student hurriedly reviews the first seventeen chapters and completes the remainder of the book. The courses in both the first and second years are quiz courses. The third year students review the book entirely with the teacher giving lectures elaborating on each subject by adding personal ideas to give individuality to the course. The fourth year is devoted to a study of the subject as presented by other writers, each member of the class writing papers for the consideration of his fellow-classmen, who should be allowed to discuss the papers presented.

Operative and Dental Anatomy Technic Courses

FRESHMAN YEAR.

First Semester.

(1) Fourteen plaster tooth carvings, three times Black's measurements.

Second Semester.

(2) Fourteen bone tooth carvings, average measurements.

(3) Six bone tooth carvings from models of extracted teeth.

(4) Nine cavities as assigned in technic block, finished March 1st.

(5) Twenty-four cavities as assigned in fourteen plaster teeth, finished May 1st. (See Figs. 13 and 14.)

JUNIOR YEAR.

First Semester.

(6) Fill nine cavities in technic block.

(7) Mount bone carvings and natural teeth on "dentech." (See Fig. 177.)

(8) Fill natural teeth as per following list.

A. Second lower molar. Oclusal. Class One cavity. Expose




Fig. 170.—Excavators, group one. Chisels for securing outline form.



Fig. 171.—Excavators, group two. Spoons for removing softened dentine.




Fig. 172.—Excavators, group three. Enamel hatchets for completing outline form and flattening dentine walls.




Fig. 173.—Excavators, group four. Instruments for cutting point angles and sharpening base line angles.



Fig. 174.—Excavators, group five. Hatchets and hoes for cutting ascending line angles and completing retention form.



Fig. 175.—Excavators, group six. Gingival marginal trimmers. Instruments for shaping and finishing gingival walls.

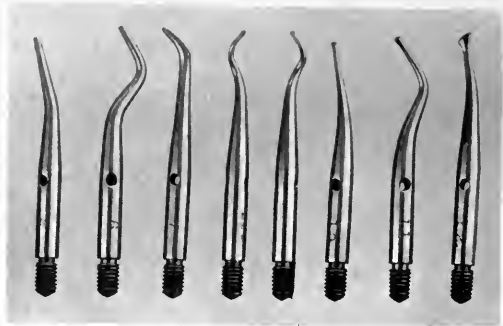



Fig. 176.B.

Figs. 176. *A* and *B*.—Gold building pluggers. Numbers one to seven inclusive are for building foil gold. These instruments have the same sized serrations and are made in conformity with the principles taught in Chapters XIX and XX. Instruments numbers eight to twelve inclusive are for building fiber gold. These five instruments have serrations specially adapted for use on this form of gold. In changing from foil builders to fiber gold builders or vice versa the surface of the gold should be gone entirely over, before adding the differently prepared gold, with the instrument with which the operator expects to condense the new gold.

Fig.
176-A.




Fig. 177.—Dr. Rathbun's dentech with teeth in position ready for practice work. This appliance may be used either on the bench or head rest of any operating chair. The author advises the advanced work with this on the dental chair to familiarize the student with positions.

pulp. Devitalize. Remove pulp. Fill pulp canals. Fill cavity with silver cast inlay.

B. Upper lateral. Lingual pit. Class One. Open and treat for putrescence. Fill pulp canal. Fill cavity with amalgam.

C. Second lower bicuspid. Occlusal pit. Class One cavity. Open



Fig. 178.—This shows a student who has kept his appointment with his patient, "Mr. Deutch." The student is required to keep an appointment book with this dummy patient the same as though the mouth to be worked on was animate.

and treat for putrescence. Fill pulp canal. Fill cavity with tin.

D. Upper central. Distal. Class Three cavity. Expose pulp. Devitalize. Fill pulp canal. Fill cavity with cement.

E. First lower molar. Mesial. Class Two cavity. Devitalize. Remove pulp. Fill pulp canal. Fill cavity with tin, restoring contact.

F. First superior molar. Mesial. Class Two cavity. Devitalize. Fill pulp canals. Fill with amalgam restoring the contour and contact.

G. Second superior molar. Class One cavity. Central pit rather large. Prepare so as not to injure the pulp in vital case. Fill with amalgam.

II. First and second superior bicuspids. Mesial cavities. Class

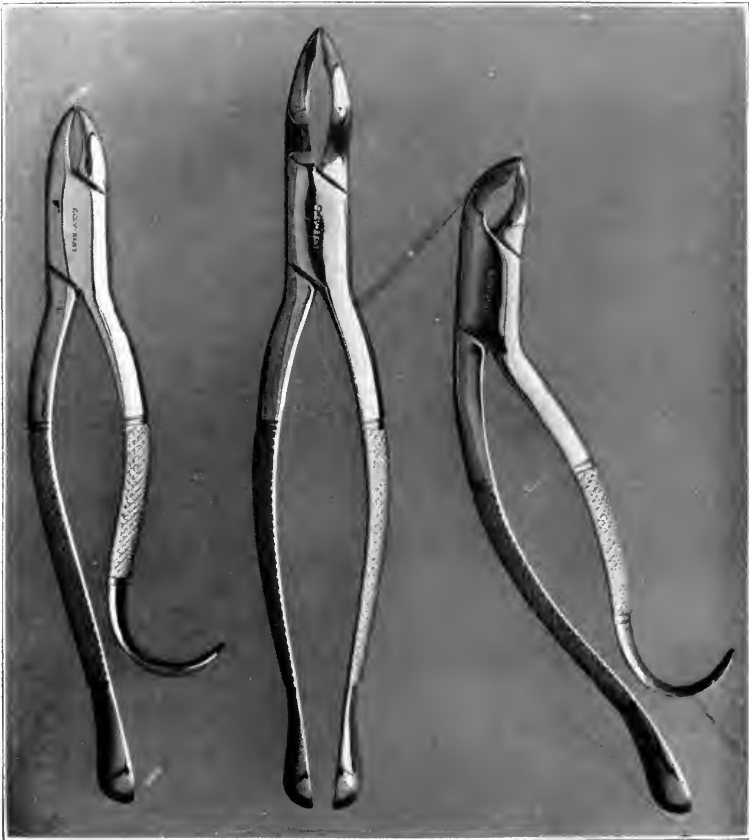


Fig. 179.—Forceps made after the patterns of the author. The middle and right hand pairs are spoon beak forceps, hollow ground and should be kept reasonably sharp by grinding.

Two. Expose pulps. Use pressure anesthesia. Remove pulps. Fill pulp canals of both. Fill both cavities with tin.

I. First inferior molar. Class Five. Prepare cavity and fill with amalgam without injury to the pulp.

J. Admitted to infirmary practice.

Second Semester.

(9) Twenty-four cavities in carved bone teeth mounted on "dentech," duplicating those in plaster teeth of the freshman year. Cut and fill in the order listed, completing each filling before cutting the next cavity.

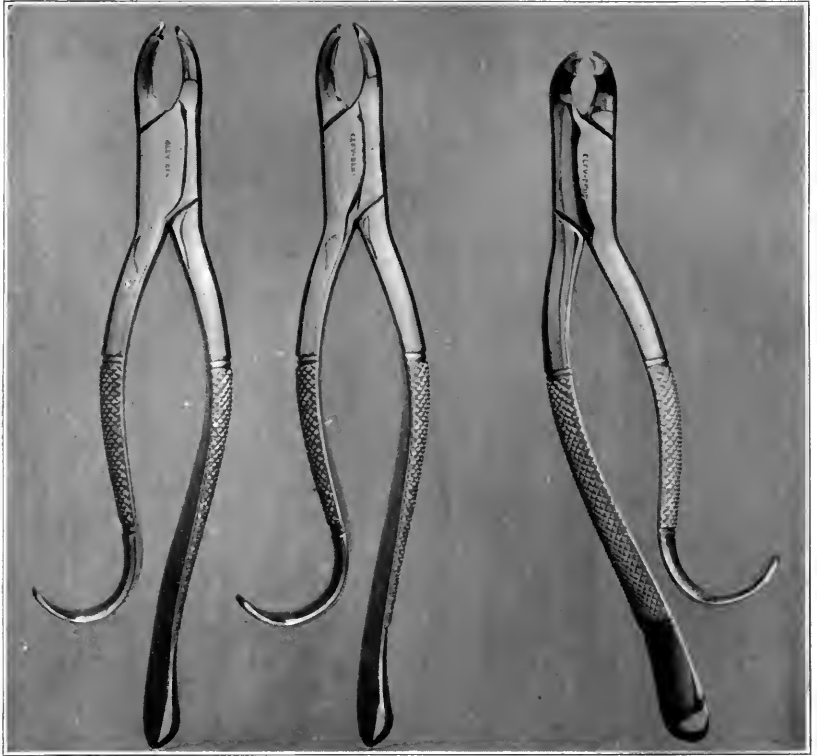


Fig. 180.—Forceps made after the patterns of the author. The right hand pair is a combination of cow horn and hawk bill beak.

INDEX

A

- Abrasion:
causes not clear, 96
incisal, 97
mechanical, 195
- Abscess:
alveolar, acute, 179
alveolar, chronic, 224
- Absorbents, 187, 194
- Absorbent cotton, use of, 175
- Access form, defined, 31
importance of, 31
surgical for, 31
- Access form for:
class two,
first method, 58
second method, 59
third method, 59
class three, 72
inlays, 99
class two, 102
class three, 105
silicate, 150
- Affected dentine, 29
- Alloy,
ageing of, 140
annealing of, 141
- Alveolus, opening mouth of, 234
- Amalgam:
cavity preparation for, 141
contraction of, 140
cutting from the margins for, 144
defined, 139
edge strength of, 140
expansion of, 140
expressing mercury from, 143
flat seats for, 141
flow of, 140
history, 139
making the filling, 144
making the mix, 142
matrix, removal of, 114
matrix, use of, 141
maximum strength of, 140
- Amalgam—Cont'd
objections to, 139
polishing of, 145
properties of, 139
proportion of alloy and mercury,
142
reception of, 129
trimming the filling of, 144
- Anesthesia:
conductive, 285
infiltration, 282
intra-alveolar, 201
local and regional, 275, 292
pressure, for pulp, 213, 214
pulp, 212
sensitive dentine, 202
sensitive dentine, general for,
202
surface, 282
- Angles, avoided in outline, 34
avoided in outline, class two, 61
line, class two, 62
- Angle restoration:
conditions demanding, class four,
78
plans of, class four, 78
plan one, class four, 85
plan two, class four, 87
indications for, 88
plan three, class four, 89
indications for, 88
plan four, class four, 90
- Appendix, 313, 324
- Arsenic trioxide:
caution in use of, 217
combination, 215
poisoning from, 217
retainer, 216, 217,
technic in, use of, 216
amalgam as a, 216
cement as a, 217
cotton as a, 217
stopping as a, 217
soreness from, 217
time of application of, 217

B

- Bevel angle, base of, 28
 - defined, 27
- Broach, cotton carrying, 226
- Burnishing cohesive gold, 137

C

- Calculus:
 - salivary:
 - composition of, 181
 - removal of, 183
 - serumal:
 - appearance of, 183
 - deposited, 182
 - distinguished from, 184
 - removal of, 184
- Canal point, size of, 227
- Canal, filling, pulp:
 - chlora-percha as, 227
 - general, 225-228
 - gutta-percha as, 227
 - immediate, 215, 218
 - material for, 225
 - most popular, 227
 - necessity of, 225
 - objective point in, 225
 - perfect, 225
 - ready for, 225
- Caries:
 - progressive stage of, 207
 - rapid, indications of, 167, 195
- Carious dentine:
 - in large decays, 44
 - in large proximal cavities, 44
 - predisposing causes, class one, 48
 - class two, 58
 - removal of remaining, defined, 44
- Cavities:
 - axial surface, 21
 - base of, 24
 - buccal and lingual surfaces, 55
 - cavo-surface angle, defined, 27
 - for fused porcelain, 295
 - class one, defined, 22
 - class two, defined, 22
 - early detection essential, 58
 - non-vital, 67

Cavities—Cont'd

- class three, defined, 22
 - form of, 72
 - management of, 72
 - class four, 78-92
 - defined, 22
 - inlay, 63
 - class five, 93-95
 - defined, 22
 - prevention of, 93
 - tendency to spread, 93
 - class six, 96, 97
 - cause of, 96
 - defined, 96
 - early restoration in, 97
 - line angles in, 25
 - occlusal surfaces, 97
 - complex, 21
 - distal superior cuspids, 91
 - divisions as to manipulation, 22
 - groups of, 21
 - how named, 21
 - increased outline in, dangers of, 37
 - laying of outline, 37
 - mesio-disto-occlusal, non-vital, 68
 - mesio-disto-occlusal, vital, 68
 - point angles in, 25
 - proximal, 21
 - simple, 21
 - stress from within, 38
 - toilet of, 45-47
- Cavity nomenclature, 21-28
 - necessity of, 21
 - names, how derived, 21
 - Cavity preparation:
 - completed, defined, 29
 - general consideration of, 30
 - gold inlay, 98-111
 - modification of form, 29
 - order of procedure in, 29
 - porcelain inlay, 296-305
 - Cements:
 - amalgam, and, 170
 - cavity preparation for, 146
 - cement, int. v. defined, 148
 - cement, n. defined, 148
 - cement, t. v. defined, 148

- Cements—Cont'd
 cementation, n. defined, 148
 gold, and, 169
 porcelain, and, 171
 retainer of arsenic, 217
 varieties of, 146
- Cementum, exposure of, 196
- Children's teeth, management of, 229-233
 cavities, class one, in, 230
 cavities, class two, in, 230
 cavities, class three, in, 231
 cavity preparation in, 230
 early attention imperative, 229
 exposed pulp, in, 231
 extension for prevention in, 230
 extension for resistance in, 230
 filling materials in, 230
 first difficulty in, 229
 first visit of child, 229
 inter-proximal grinding in, 231
 root filling in, 232
- Chip blower, use of, 176
- Chloroform, 202
- Clamp:
 cervical, use of, 194
 methods of applying, 191, 194
- Cocaine:
 for sensitive dentine, 277
 local anesthesia, with, 277
- Combination fillings,
 cement and amalgam, 170
 cement and porcelain, 171
 defined, 169
 gold and cement, 170
 gold, cohesive and non-cohesive, 170
 gold and platinum, 170
 gold and tin, 169
 object of, 169
 silicate and amalgam, 172
 silicate cement and fused porcelain, 171
 silicate and gold, 171
- Contact point, proper, 32
 build of, amalgam, 144
 class six, 97
 condensing of, 132
 position of, 132
- Convenience form, 42-43
 abuse of, 42
 class one, 50
 class two, 63, 66
 class three, 77
 defined, 42
 distal superior cuspid, 92
 inlays, 99
 maximum required, 42
 minimum required, 42
 porcelain inlays, 296
 previous separation lessening, 42
 silicate, 154
 sparingly used, 42
 suitable instruments for, 42
- D
- Dentech, 321
- Deposits, 180
 food as related to, 181
 habits as to, 181
 kinds, upon the teeth, 180
 mouths most subject to, 181
 salivary, prevention of, 182
 time of, 181
- Disinfection and pulp protection, 46
- Disks and strips, are in use of, 46
- Dryness, 187
 importance of, 187
 neglect of, 187
- E
- Electric lamps, use of, 176
- Enamel:
 defined, 97
 edge, 97
 malformed, 305
 margin, 27
 plane of, 45
- Enamel walls, 45
 axial, surface pit, 56
 class one, 50
 class two, 63, 67
 class three, 77
 inlay, class two, 104
 inlay, class four, 109

- Enamel walls—Cont'd
 inlay, porcelain, 297
 silicate, 154
- Examination of mouths:
 care in, 175
 instruments needed in, 175
 light hand in, 174
 when completed, 176
- Exclusion of moisture, 186
 as a time saver, 189
 better view of the cavity, 188
 decalcification detected, 189
 for proper canal treatment, 188
 for sterilization, 188
 methods of, 186
 pain decreased by, 189
- Explorer, use of, 175
- External enamel line, defined, 27
- Extensions gingivally:
 buccal, class one, 56
 buccal, class two, 60
- Extension for prevention:
 approaching the gum, 56
 buccal pits, 56
 defined, 35
 esthetic reasons, 74
- Extraction of teeth, permanent,
 233-268
 care in, 263
 forces used in, 234
 general consideration of, 233
 hemorrhage following, 267, 268
 movements in, 234
 positions in, 234
 position of arms in, 240
 position of hands in 240
 position of operator for inferior,
 238
 position of operator for superior,
 235
 resistance of patient in, 243
 rules for,
 inferior bicuspid, 253
 superior bicuspid, 249
 inferior cuspids, 249
 superior cuspids, 245
 inferior incisors, 245
 superior incisors, 244
 inferior molars, 259
 superior molars, 256
- Extraction of teeth:
 rules for—Cont'd.
 third, inferior molar, 262
 third, superior molar, 262
 temporary teeth, 269-274
 early extraction, evil results of,
 269
 first molar, related to, 269
 first molar, time of eruption,
 reasons for, 269
- F
- Feldspar, formula of, 293
- Finishing cohesive gold filling, 137
 abrasives in, 138
 burnishing in, 137
 gingival excess in, 137
 knife, in, 138
 strips, in, 138
- Floss silk, waxed, use of, 176, 186
- G
- Gingival Angles, class four, 83
- Gingival outline,
 class two, 61, 65
 class three, 73
 class five, 94
- Gold:
 annealing of, 124
 application of, 127
 bridging of, 125
 building of class five, 136
 building of class six, 136
 cement and, 169
 cohesion of, 125
 cohesive physical properties, 123
 condensation, secondary, 137
 condensing of, 127
 covering of pulpal wall, with, 131
 hand pressure in use of, 127
 last portions of, class two, 133
 layers of, 135
 objectionable qualities, of, 123
 order of stepping, 129
 buccal cavities, 129
 class two, 130
 irregular outline, 129
 occlusal cavities, 129

Gold—Cont'd

- platinum and, 170
- preparation of, 126
- specific gravity of, 125
- starting a filling,
 - class one, 129
 - class two, 129
 - class three, 133
 - class four, 135
- tin and, 169
- use of, in class five, 95
- welding of, 123
- Gum massage, 185
- Gutta-percha, 164
 - base plate, 164
 - canal points of, 165
 - filling root canals with, 164
 - filling with, 164
 - preparation of filling, 164
 - separation with, 165
 - temporary stopping of, 165

H

- Hand pressure, cohesive gold, 128
- Health of patient, 207
- Hydrogen dioxide, 185
- Hyperemia:
 - active, 177, 206
 - passive, 178
 - stages of, 206
- Hypersensitive dentine, defined, 195
 - caustic potassa in, 200
 - chloroform in, 202
 - cold air in, 199
 - desiccation of, 198
 - destroying agents in, 199
 - electric current in, 199
 - formaldehyde in, 200
 - moisture, heat and cold in, 199
 - nitrous oxide in, 202
 - novocain, 201
 - oil of cloves in, 201
 - phenol in, 200
 - potassium bromide in, 202
 - rapid breathing in, 203
 - sharp instruments in, 203
 - silver nitrate in, 200
 - somnoforme in, 202

- Hypersensitive dentine—Cont'd
 - treatment of, 195-203
 - zinc chloride in, 200

I

- Incisal abrasion, class six, 97
- Incisal angle:
 - class three, filling of, 87
 - class four, 78
 - class four, direction of, 81
 - class four, to assist the, 86
- Incisal edge, porcelain inlay, 304
- Incisal line angle, class three, 75
- Incisal outline:
 - class three, 74
 - class four, plan one, 87
 - class five, 94
- Infected dentine, 29
- Inlays:
 - beveling of cavo-surface angles, 100
 - carving the wax, 114
 - defined, 98
 - finishing the, 122
 - gold used, in, 121
 - heating the gold, for, 120
 - history of, 112
 - hole leading to model, 121
 - indications for, 98
 - investing, pattern of, 119
 - line of approach, for, 100
 - making pattern, for, 113, 119
 - making the cast, of, 120
 - materials for, 98
 - matrix for, 119
 - not indicated, 98
 - object of, 112
 - occlusal restoration, with, 118
 - pin for, 116
 - placing spruce wire for, 115
 - porcelain, construction of, 306-311
 - applying of, 309
 - etching of, 310
 - finishing of, 310
 - grinding of, 310
 - matrix for, 306
 - pushing technic of, 310
 - selection of, 308
 - toilet of, 310

Inlays—Cont'd

- retention form for, 51
 - retention temporarily removed, 51
 - retention form of pattern, 115
 - saturating the model, 120
 - setting, 122
 - sponge gold as pattern, 119
 - sweating the contour, 118, 119
 - temperature of the model, 120
 - toilet for, 100
 - undercuts, filling of, 113
 - wax pattern, for, 113
- Instruments, 17-20
- angles in, 18
 - bin-angles in, 18
 - bur, 19
 - care of, 20
 - chisel,
 - defined, 18
 - edge, 18
 - use of, 18
 - class name, 17
 - contra angles in, 18
 - cuts of, 314, 324
 - dental engine, use of, 19
 - excavators, 17
 - few in sight, 174
 - formula names, for, 18
 - gingival marginal trimmer, 18
 - hatchets, defined, 18
 - hoes, defined, 18
 - how named, 17
 - nomenclature, for, 17-20
 - plugger, point serrated, 19, 125, 126
 - amalgam, 143
 - rotating the, 126
 - size of, 126
 - rights and lefts, 17
 - sharpening of, 19
 - spoon, use of, 18
 - sub-class name, 17
 - sub-order name, 17
 - test for sharpness, 20
 - triple-angles in, 18
- Instrumentation, lingual pit, 57

K

Kaolin, formula of, 293

L

- Labial outline:
 - class three, 74
 - class four, plan one, rule for, 86
 - class four, plan three, 90
- Length of sitting (children), 230
- Ligature, 192
 - caution in use of, 192
 - cutting ends of, 193
 - how made, 192
 - knot in, 193
 - removal of, 193
 - Wedelstaedt tie, 193
- Lime salts in solution, precipitation of, 181
- Line angles, (*see* Cavity),
 - axio-labial, class three, 76
 - axio-lingual, class three, 76
 - gingivo-axial, 77
- Linen, 174
- Lingual approach:
 - advised, 135
 - class three, cohesive gold, 135
 - inlay illustrated, 105
- Lingual outline:
 - class three, 75
 - class four, plan one, 87
 - lower incisors, 87
- Local anesthesia:
 - anatomy, related to, 277
 - cocaine in, 277
 - defined, 275
 - horizontal injection in, 285
 - infiltration in, 283
 - intra-alveolar in, 285
 - novocain, doses of, 279
 - novocain in, 277
 - pericemental injection in, 286
 - perpendicular injection in, 285
 - preparing solution for, 280
 - Ringer's solution for, 281
 - suprarenin, doses of, 280
 - suprarenin in, 280
 - uses in dentistry, 276

M

- Mallet force:
 - alone, 128
 - automatic, 128

- Mallet force—Cont'd
 hand, 128
 power, 128
 rule of, 128
- Marginal bevel:
 angle of, 45
 defined, 27
 depth of, 45
 necessity of, 27
- Matrix:
 annealing of, 306
 applying porcelain to, 309
 material, for, 306
 methods of forming, 306
 porcelain inlay, 306
 removal of, amalgam, 144
 removal from porcelain, 310
 taking the spring out of, 308
 thickness of, 306
 torn, 309
 use of, class two, gold, 133
 use of, in silicate filling, 162
 use of, with amalgam, 141
- Mouth mirror, use of, 175
- N
- Novocain:
 sensitive dentine, 201
 tablets, care of, 281
- Nitrous oxide, 202
- O
- Objects in filling teeth, 29, 96
- Occlusal defects, 48
- Occlusal outline:
 class two, 66
 class five, 94
- Operative technic courses, 313, 322,
 323, 324
- Order of procedure:
 cavity, 29
 for inlays, 99
- Outline form:
 buccal pits, 55
 class one, 48
 class two, 59, 65
 class three, 73
 class five, 303

- Outline form—Cont'd
 curving to the axial, class four,
 86
 defined, 34
 distal superior cuspids, 91
 for silicate, 151
 inlays,
 class one, 101
 class two, 103
 class three, 105
 large class one, 52
 lingual pits, 55
 porcelain inlays, 296
 rule one of, 34
 rule two of, 34
 rule three of, 34
 rule four of, 34
 rule five of, 34
 rule six of, 34
 rule seven of, 34
 rule eight of, 34
 rule nine of, 35
 rule ten of, 35
 step omitted in class two, 59
- Over dessication, 71
- Oxychloride of zinc, 146
- Oxyphosphate of copper, 147
- Oxyphosphate of zinc, 146
 manipulation of, 147
 spatulation of, 147
- P
- Pain, dental:
 alleviations of, 177
 cold, causes, 177
 divisions of, 177
 foreign substances, causes, 178
 patents in, 175
 pericemental diseases, causing,
 179
 symptoms, aggravated, 177
 treatment for, 177, 178, 179
- Passive hyperemia of pulp, 178
- Pins:
 placing for inlay, 116
 soldered to matrix, 116
 Tungston, 116
- Planes of a tooth:
 bucco-lingual, 28

- Planes of a tooth—Cont'd
 horizontal, 28
 mesio-distal, 28
- Porcelain:
 advantages of, 294
 basal body, 294
 biscuit fuse, 294
 build of layers, 294
 cavo-surface angle for, 295
 cement line in, 301
 composition of, 293
 contra-indications for, 295
 dental, fused, 293-295
 disadvantages of, 294
 double step in, 302
 enamel body, 294
 fine grinding of, 294
 flux, amount of, 294
 foundation body, 294
 high fusing, 293, 294
 indications for, 295
 lingual approach, class three for, 300
 low fusing, 293
 methods of fusing, 293
 pigments in, 293
 proximal approach for, 301
 shrinkage in, 294
 size of mass, 24
 spheroiding of, 294
- Potassium bromide, 202
- Preventive dentistry, 180
- Primary decay, location of, class three, 72
- Prophylactic treatment, oral, 180
 brushing, technic of, 186
 importance of, 180
 instructions to patients in, 186
 oral hygiene, children, 229
- Proximal Space, restoration of, 31
- Pulp:
 canals,
 air in, 227
 bent, 226
 putrescent, 219
 small, management of, 225
 chamber, cleaning of, 228
 chief idiosyncrasy of, 204
 devitalization,
 causes for, 211
 agents for, 212
- Pulp:
 devitalization—Cont'd
 anesthetization for, 212
 arsenic trioxide, for, 215
 bacteria as related to, 211
 care exercised in, 214
 determining the method of, 212
 high pressure for, 213
 methods of, 212
 technic of, 213
 exposed, class one, 53
 exposure, dangers in, class two, 65
 exposure feared, class one, 52
 infected with bacteria, 206
 involved, class five, 95
 lesions of, 177
 normal, 204
 partially devitalized, 218
 peripheral nerve irritation, 212
 preservers, 209
 protection, 204-210
 gutta percha in, 210
 in class two, 66
 in deep seated cavities, 207
 indications for, 205
 materials used in, 207
 putrescence, 219-224
 animal fats in, 221
 autogenous, symptoms of, 222
 autogenous, treatment of, 222
 classes of, 219
 closed, symptoms of, 222
 closed, treatment of, 222
 complicated, symptoms of, 223
 complicated, treatment of, 223
 defined, 219
 open, symptoms of, 220
 open, treatment of, 220
 treatment of, general, 220
 recuperative powers of, 204
 removal of, 214-218
 canal dressing following, 215
 canal filling following, 215
 discolorations following, 215
 hemorrhage following, 215
 pains following, 215
 sensations are conveyed to, 195
 stimuli, abnormal, 211
 stimuli, normal, 211
 traumatic injuries to, 211

Pus in apical space, 179
 Putrefaction defined, 219
 Pyorrhoea alveolaris, 184

R

Regional anesthesia:
 defined, 287
 gasserian injection in, 288
 infra-orbital injection in, 290
 mental injection in, 290
 palatine injection in, 292
 pterygo-mandibular injection in,
 288
 speno-maxillary injection in, 288
 zygomatic injection in, 290

Removal of remaining decay:
 class one, 50
 class two, 66
 class three, 77
 for silicate, 154
 inlays, 99

Resistance form:
 applied to filling material, 39
 buccal pits, 55
 class one, 49
 class two, 62, 66
 class three, 75
 extension for, defined, 38
 force to provide for in, 38
 for porcelain inlays, 296
 for silicate inlays, 151
 importance of, 38
 inlays, 99
 class one, 101
 class two, 103
 class four, plan one, 106
 involves a consideration of, 38

Retention angles for inlays, 99

Retention form:
 acute angles required in, 40
 buccal pits, 56
 class one, 49
 class two, 62, 66
 class three, 75
 class four, 78-81
 class five, 94
 flat seats in, 40
 inlays,
 class one, 102

Retention form:

flat seats in—Cont'd
 class two, 103
 class four, plan two, 107
 for porcelain inlays, 296
 for silicate, 153
 little, in enamel, 41
 maximum not required, 40
 maximum required, 40
 step as a portion of, 40
 Ringer's solution, 281
 Rubber dam:
 before applying, 38
 class one, 52
 essential in filling with amalgam,
 141
 for silicate, 154
 gingival side of, 191
 holes, distance between, 190
 holes, location of, 190
 holes, size of, 190
 invented by, 187
 leaks in, 46
 method of applying the, 191
 number of teeth isolated with,
 191,
 objections to use of, 187
 occlusal side of, 191
 placing of, 191
 prevent leakage in, 192
 removal of, 194
 size and shape of, 190
 thickness of, 189

S

Secretions, abnormal, oral, 196

Separation:

class two cavities, 59
 for amalgam, 142
 gutta-percha for, 165
 immediate, 33
 inlays, class two, 102
 methods of, 32
 preliminary, 33
 soreness resulting from, 33
 mechanical not essential, 176
 use of, class two, gold, 133
 Silix, formula of, 293
 Silicate:
 amalgam, and, 171

Silicate—Cont'd

- applied to prosthetic work, 172
- cavity preparation for, 150
- defined, 148
- facing metal fillings with, 163
- finishing the filling, 162
- gold, and, 171
- making the filling, 155
- making the mix, 159
- preparing the materials, 158
- proper consistency, 159
- time in mixing, 160
- use of matrix, 162

Silicatisation, defined, 148

Somnoform, 202

Sordes, consistency of, 183

Sordes, removal of, 183, 185

Stains on the teeth, 183

- green stains, color due to, 183
- injury to teeth, 183
- removal of, 185
- where found, 183

Step:

- area included, class two, 61
- depth of class four, plan two, 87
- distal superior cuspids, 91
- forming of, 61
- omitted in class two, 51
- technic of cutting, class four, plan two, 88

T

Teeth:

- compared, 270
- order,
 - changes in, 271
 - disregarding of, 272
 - of eruption, 270

Tin:

- amalgam and, 168
- as a filling material, 166
- cavity preparation for, 167
- discoloration, amount of, 166
- discoloration, by, 166
- forms of, 167
- gold and, 168, 169
- history of, 166
- in teeth of children, 167
- methods of introduction, 167,
- therapeutic action of, 166
- thermal conductivity of, 166

Toilet of cavity:

- best accomplished by, 45
- class one, 51
- class two, 67
- defined, 45
- for porcelain inlays, 297, 310
- for silicate, 154

Tooth:

- brush, use of, 185
- form, restoring of, 32
- pieks, 186
- substance, saving of, 32

Tubuli, contents of, 195

W

Wall:

- axial,
 - class two, 62
 - class three, 77
 - defined, 23
 - for porcelain, class one, 298
 - for porcelain, class three, 299
- buccal, class two, 62
- distal superior cuspid, 91, 92
- freshly cut, 88
- gingival, defined, 23
- gingival, class two, 66
- gingival, class three, 77
- gingival, class three, inlay, 105
- inside, defined, 24
- labial, 77
- lingual, 77
- lingual, axial, 62
- lingual, class two, 92
- occlusal, class five, inlay, 110
- outside, defined, 22
- pulpal, class two, 62
- pulpal, defined, 22
- sub-pulpal, defined, 23
- weakened enamel, 38

Wide enamel margin, indicated, 46

Z

Zinc:

- chloride of, 200
- oxychlorate of, 146
- oxyphosphate of, 146
- sulphate of, 147



University of California
SOUTHERN REGIONAL LIBRARY FACILITY
405 Hilgard Avenue, Los Angeles, CA 90024-1388
Return this material to the library
from which it was borrowed.

Interl
Due two
Non-rer
For A
JAN 1

JAN

BIO

Stomer

M

BIOME

A 000 373 570 1



3 1158 00551 6306

Un