



3 1761 05478245 3

THIS BOOK IS FOR  
REFERENCE ONLY AND MUST  
NOT BE TAKEN FROM THE



*Amura*

Digitized by the Internet Archive  
in 2007 with funding from  
Microsoft Corporation















**SURGERY AND DISEASES  
OF THE MOUTH AND JAWS**



M/S  
B

SURGERY  
AND  
DISEASES  
OF THE  
MOUTH AND JAWS

A PRACTICAL TREATISE ON THE SURGERY  
AND DISEASES OF THE MOUTH AND  
ALLIED STRUCTURES

BY

VILRAY PAPIN BLAIR, A. M., M. D.

PROFESSOR OF ORAL SURGERY IN THE WASHINGTON UNIVERSITY DENTAL  
SCHOOL, AND ASSOCIATE IN SURGERY IN THE WASHINGTON  
UNIVERSITY MEDICAL SCHOOL

SECOND EDITION

263888  
27.1.32

WITH 384 ILLUSTRATIONS

ST. LOUIS  
C. V. MOSBY COMPANY  
1913

COPYRIGHT, 1912, 1913. BY C. V. MOSBY COMPANY

*Press of*  
*C. V. Mosby Company*  
*St. Louis*

TO  
THE FRIENDS

WHOM I HAVE NEGLECTED WHILE  
PURSUING THESE STUDIES

THIS VOLUME IS IN ALL SINCERITY  
DEDICATED





## PREFACE TO FIRST EDITION

---

In spite of all of the special work that has been done in the study of the teeth and allied structures, the ordinary standard of surgical treatment given to diseases and deformities of the mouth does not equal that attained in other regions. This is due largely to a rather general lack of reciprocity of ideas and observations between constructive workers in the medical, with those of the dental professions.

It was with the hope of presenting their more pertinent observations and deductions in a coördinated scheme that the present work was undertaken. This attempt has been made possible by the untiring efforts that the author's many associates in the dental profession have always made to help him solve cases that contained dental problems.

For the benefit of his dental students certain chapters on surgical pathology and surgical principles have been included. As hemorrhage is often a serious matter in mouth operations, this has been considered at some length.

Throughout, the attempt has been made to give proper credit to the originators of ideas presented, but this is not always possible. Most procedures are common property, their origin having been lost. Further, similar problems often evoke similar answers, and the same procedure is often reinvented many times. Even when a unique condition demands a somewhat radically new procedure, the deductions that seem to warrant it are often largely adapted from the observations and procedures of others, though these may have been made and executed under different circumstances and in other regions.

The author is deeply indebted to Dr. William Krenning for a thorough sifting of the English, German, and French literature of the subject. Among others, he is also indebted to Drs. Thomas Gilmer, Hermann Prinz, Willard Bartlett, John Kennerly, B. E. Lischer, Greenfield Sluder, William Coughlin, William Mook, James Clemens, M. A. Bliss, and Charles Klenk for reading certain chap-

ters, or for other help extended, and to many other physicians and dentists for the opportunity of studying interesting cases.

The illustrations have, with the exception of bone lesions, been almost entirely confined to special anatomy, deformities, and technic. These have been made directly from bones, dissections, or from patients. For permission to reproduce certain anatomical plates from Spalteholz, Hand Atlas of Anatomy, the author is indebted to J. B. Lippincott and Company.

Most of the skiagrams presented were made by Dr. R. D. Carman or by Dr. F. B. Hall.

VILRAY PAPIN BLAIR.

St. Louis, October, 1912.

## PREFACE TO SECOND EDITION

---

Advantage has been taken of the opportunity afforded by the issuing of the second edition, to eliminate certain typographical errors and in a few places to reconstruct the text. The author wishes also to avail himself of this opportunity to thank the profession for their kind reception of this book.

VILRAY PAPIN BLAIR.

August 1st, 1913.

# CONTENTS.

## CHAPTER I.

	PAGE
PHYSICAL EXAMINATION—ANATOMICAL CONSIDERATION . . . . .	1-27
Examination—Mouth Cavity—Floor of the Mouth—Tongue—Palate— Fauces and Pharynx—Teeth—Gums—Vestibule of the Mouth—Lips— Temporomandibular Joint—Jaws—Muscles of Mastication—Salivary Glands—Lymph Nodes.	

## CHAPTER II.

INFLAMMATIONS, INFECTIONS, TUMORS, CYSTS . . . . .	28-41
Inflammation—Infections—Suppuration—Treatment of Infections and Inflammations—Method of Preparing and Administering Auto- genous Vaccines—Tumors and Cysts.	

## CHAPTER III.

PREPARATION OF THE HANDS, OPERATIVE FIELD, INSTRUMENTS, AND DRESS- INGS . . . . .	42-45
Preparation of the Surgeon's Hands—Preparation of the Operative Field—Sterilization of Instruments—Sterilization of Rubber Gloves —Sterilization of Cloths, Dressings, Etc.—Sterilization of Sutures.	

## CHAPTER IV.

HEMORRHAGE, SHOCK, AND ALLIED COMPLICATIONS . . . . .	46-66
Hemorrhage—Saline Transfusion—Blood Transfusion—Shock—Air Embolism—Postoperative Pneumonia—Edema of the Lungs—Sup- pression of Urine—Acetonuria.	

## CHAPTER V.

WOUNDS AND INJURIES OF THE SOFT PARTS . . . . .	67-79
Wounds—Burns—Sutures—Dressings.	

## CHAPTER VI.

INJURIES OF THE TEETH AND ALVEOLAR PROCESS . . . . .	80-82
Mechanical Abrasion of the Teeth—Loosening or Avulsion of the Teeth—Fracture of the Teeth—Fracture of the Alveolar Process.	

CHAPTER VII.

	PAGE
FRACTURES OF THE UPPER JAW . . . . .	83-88
Character of the Injury—Treatment.	

CHAPTER VIII.

FRACTURES OF THE LOWER JAW . . . . .	89-114
Character of the Injury—Treatment—Time Required for Union— Delayed Union—Malunion—Feeding During the Treatment of a Frac- ture of the Jaw.	

CHAPTER IX.

DISLOCATION OF THE LOWER JAW . . . . .	115-121
Kinds of Dislocations—Treatment—Unreduced Dislocations—Chronic Dislocations—Subluxation.	

CHAPTER X.

CONGENITAL FACIAL CLEFTS . . . . .	122-138
Morphology—Relation of the Alveolar Cleft to the Teeth—Clinical Types of Congenital Clefts—Theories of Failure of Cleft Closure— Congenital Lip Pits.	

CHAPTER XI.

CONGENITAL PALATE CLEFTS—PRINCIPLES OF REPAIR BY PLASTIC FLAPS .	139-147
Anatomical Considerations—Flaps made from Palate Tissues—Flaps made from other than Palate Tissues.	

CHAPTER XII.

CONGENITAL CLEFTS OF THE PALATE AND LIP—PREFERABLE AGE AT WHICH TO OPERATE . . . . .	148-150
Consideration of Various Ages—Advantages of Very Early Operation.	

CHAPTER XIII.

CONGENITAL PALATE AND LIP CLEFTS—OPERATIONS IN EARLY INFANCY .	151-156
Preparation for Operation—Brophy Operation—Lane Operation— Choice of Operation—After-treatment—Mortality.	

## CHAPTER XIV.

	PAGE
CONGENITAL PALATE CLEFTS—PLASTIC OPERATIONS IN ORDINARY CASES AFTER EARLY INFANCY . . . . .	167-185
Preparation for Operation—Position and Light—Instruments and Materials—Flap Sliding Operation—Retention Devices—After-treatment—Postoperative Hemorrhage—Non-union—Reoperation—Mortality—Results.	

## CHAPTER XV.

CONGENITAL PALATE CLEFTS—OPERATIONS FOR EXTRAORDINARY CASES . . . . .	186-195
Küster's Operation—Two-step Operations—Approximation of the Maxillæ—Repair by Flaps from Other than Palate Process.	

## CHAPTER XVI.

CONGENITAL CLEFTS OF THE LIP AND ALVEOLAR PROCESS—OPERATIVE CORRECTION . . . . .	196-210
Correction of Alveolar Clefts in Infants—Correction of Single Alveolar Clefts at Later Periods—Correction of Double Alveolar Clefts at Later Periods—Correction of Harelip—Rose Operation—Owen Operation—Operation for Double Harelip—Correction of Deformity of the Nostril and Nose—Difficult Respiration After a Lip Operation—After-treatment—Results.	

## CHAPTER XVII.

OBTURATORS, ARTIFICIAL VELA, AND SPEECH TRAINING . . . . .	211-216
Physiological Action of the Muscle Concerned—Obturators and Artificial Vela—"Cleft Palate" Speech—Speech Training—Postpharyngeal Injection of Paraffin—Obturators Versus Operation.	

## CHAPTER XVIII.

REPAIR OF ACQUIRED DEFECTS IN THE LIPS, CHEEKS, AND PALATE . . . . .	217-229
Transplantation of Skin- or Mucus-covered Flaps—After-treatment—Closure of Defects at the Angle of the Mouth and Cheek—Restoration of the Lower Lip—Restoration of the Upper Lip—Perforations of the Palate.	

## CHAPTER XIX.

IDEAL OCCLUSION AND MALOCCLUSION OF THE TEETH—IRREGULARITIES IN THE GROWTH AND RELATIONS OF THE JAWS . . . . .	230-237
Ideal Occlusion—Malocclusion—Causes of Irregular Setting of Teeth—Malrelation of the Dental Arches and of the Jaws—Orthodonture in the Treatment of Malrelations of the Jaws—Indications for Surgical Operation.	

CHAPTER XX.

	PAGE
TREATMENT OF DEFORMITIES AND MALRELATIONS OF THE JAWS . . .	238-262
Deformities of the Maxillæ: Osseous Obstruction of the Nares—Retraction of the Lower Jaw—Operation for Retraction of the Lower Jaw—Obliquity of the Chin—Protrusion of the Lower Jaw—Transmucoperiosteal Operation for Protrusion of the Lower Jaw—Submucoperiosteal Operation for Protrusion of the Lower Jaw—Babcock's Operation for Protrusion of the Lower Jaw—Open Bite—Operation for Open Bite—Atypical Deformities—Preoperative Considerations—After-treatment.	

CHAPTER XXI.

DISEASES OF THE TEMPOROMANDIBULAR JOINT—LIMITED MOVEMENT OF THE JAW . . . . .	263-275
Diseases of the Temporomandibular Joint—Hysterical Closure of the Jaws—Limitation Due to Reflex Irritation—Limitations Due to Scar Bands or Ankylosis—Operative Treatment of Oral Scar Bands—Operation by Flap Transplantation—Operations for Ankylosis of the Jaw.	

CHAPTER XXII.

EXTRACTION OF TEETH . . . . .	276-283
Removal of the Individual Teeth—Impacted Teeth.	

CHAPTER XXIII.

INFECTIONS AND INFLAMMATIONS OF THE MOUTH . . . . .	284-305
Stomatitis—Gangrene—Noma—Specific Infections—Parasites of the Mouth.	

CHAPTER XXIV.

INFECTIONS OF THE TEETH, PERIDONTAL TISSUES, AND JAW-BONES . . .	306-318
Dental Caries—Alveolar Abscess—Alveolar Fistula—Retraction of the Gums—Inflammation of the Pericementum—Pyorrhea Alveolaris—Osteitis or Inflammation of the Bone—Necrosis—Specific Infections of Bone—Atrophy—Hypertrophy—Tumors of Bone—Leontiasis Ossea.	

CHAPTER XXV.

TREATMENT OF INFECTIONS OF THE TEETH, PERIDONTAL TISSUES, AND JAW-BONES . . . . .	319-332
Alveolar Abscess—Retractions of the Gums—Pericementitis—Pyorrhea Alveolaris—Alveolar Fistula—Necrosis—Chronic Bone Abscess—Specific Infections.	

## CHAPTER XXVI.

	PAGE
SEPTIC INFECTIONS OF THE FLOOR OF THE MOUTH AND NECK . . . . .	333-341
Acute Adenitis—Acute Cellulitis—Chronic Adenitis—Chronic Cellulitis—Treatment of Acute Adenitis—Treatment of Acute Cellulitis—Treatment of Chronic Adenitis—Treatment of Chronic Cellulitis—Phlegmonous Stomatitis—Abscess of the Tongue.	

## CHAPTER XXVII.

DISEASES OF THE MAXILLARY SINUS . . . . .	342-350
Antral Infection—Cysts of the Antrum—Tumors of the Antrum.	

## CHAPTER XXVIII.

TUMORS OF THE MOUTH AND JAW-BONES . . . . .	351-369
Hypertrophy of the Gums—Mucous Cysts—Epulis—Lipoma—Fibroma—Chondroma—Osteoma—Myxoma—Odontoma—Supernumerary Teeth—Dental Cysts—Sarcoma—Myeloma—Endothelioma—Multilocular Cystic Tumors—Carcinoma—Retromaxillary Tumors.	

## CHAPTER XXIX.

EXCISIONS AND TEMPORARY RESECTIONS OF THE JAW-BONES . . . . .	370-383
Resections and Excisions of the Maxilla—Osteoplastic Resections—Resection and Excision of the Mandible—Prevention of Deformity.	

## CHAPTER XXX.

DISEASES AND TUMORS OF THE LIP . . . . .	384-389
Injuries—Scars—Lip Cracks or Chaps—Simple Hypertrophy—Macrocheilia—Furuncle—Phlegmon—Gangrene—Herpes—Perlèche—Tuberculosis of the Lips—Syphilis—Cysts—Hemangioma—Endothelioma—Warts and Papillomata.	

## CHAPTER XXXI.

CANCER OF THE LIP . . . . .	390-399
Diagnosis—Treatment—Prognosis.	

## CHAPTER XXXII.

TUMORS AND CYSTS OF THE FLOOR OF THE MOUTH . . . . .	400-407
Obstruction Cysts of the Mucous Glands—Ranula—Dermoid Cysts—Benign Tumors—Malignant Tumors.	

CHAPTER XXXIII.

	PAGE
AFFECTIONS OF THE SALIVARY GLANDS AND THEIR DUCTS . . . . .	408-436
Inflammation of the Larger Ducts—Epidemic Parotitis—Acute Suppurative Inflammation of the Submaxillary and Sublingual Glands in Young Infants—Secondary Infections—Chronic Inflammation—Mikulicz's Disease—Specific Infection of the Salivary Glands—Obstruction of the Ducts of the Salivary Glands—Cysts—Foreign Bodies and Stones in the Ducts and Glands—Wounds of the Salivary Glands and Ducts—Salivary Fistula—Tumors of the Salivary Glands.	

CHAPTER XXXIV.

CONGENITAL AFFECTIONS, INJURIES, AND DISEASES OF THE TONGUE . . . . .	437-449
Congenital Deformities—Nodules—Indentations—Fissures—Ulcers—Inflammations—Raw Tongue—Erythema Migrans Linguae—Chronic Superficial Glossitis—Glossodynia Exfoliativa—Tuberculosis of the Tongue—Syphilis of the Tongue.	

CHAPTER XXXV.

TUMORS OF THE TONGUE . . . . .	450-463
Lymphangiomatous Macroglossia—Simple Muscular Macroglossia—Tumors of the Blood Vessels—Cartilaginous Tumors—Lipoma—Fibroma—Keloid—Tumors and Cysts of the Thyroglossal Tract—Papillomata, Warts—Sarcoma.	

CHAPTER XXXVI.

CANCER OF THE TONGUE . . . . .	464-505
Position—Etiology and Predisposition—Early Diagnosis—Responsibility of Medical Practitioners and Dentists in Regard to the Recognition of the Early Manifestations of Cancer—Early Types of Cancer—Early Clinical Characteristics—Clinical Stages of Carcinoma of the Tongue—Mid-period of Carcinoma of the Tongue—Final Stage of Carcinoma of the Tongue—Diagnosis—Differentiation between Operable and Non-operable Carcinomata—Prognosis of Carcinoma of the Tongue—Treatment of Carcinoma of the Tongue—Operation for the Removal of the Tongue—Intraoral Operation—V-shaped Operation—Excision of One Half of the Body—Bilateral Excision—Resection of the Tongue at the Root—Kocher's Operation—After-treatment.	

CHAPTER XXXVII.

TUBERCULAR AND MALIGNANT DISEASES OF THE CERVICAL LYMPHATICS . . . . .	506-518
Tubercular Adenitis—Secondary Carcinoma of the Cervical Lymphatics.	



## CHAPTER XXXVIII.

PAGE

CONGENITAL MALFORMATIONS, INJURIES, AND DISEASES OF THE PHARYNX	519-531
Anatomical Considerations—Congenital Malformations of the Pharynx—Injuries of the Pharynx—Acute Infections—Adhesions of the Velum and Fauces and Pharyngeal Wall—Stricture of the Pharynx.	

## CHAPTER XXXIX.

TUMORS OF THE VELUM, TONSILS, AND PHARYNX . . . . .	532-541
Teratomata—Benign Tumors—Palate Adenoma—Nasopharyngeal Polypus or Nasopharyngeal Fibroma—Retropharyngeal Goitre—Malignant Tumors of the Pharynx—Pharyngotomy.	

## CHAPTER XL.

LIGATION AND TEMPORARY CONSTRICTION OF THE ARTERIES . . . . .	542-546
Coronary Arteries—Temporal Artery—Facial Artery—Lingual Artery—External Carotid Artery—Common Carotid Artery.	

## CHAPTER XLI.

MOTOR DERANGEMENT . . . . .	547-556
Paralytic Affections—Spasmodic Affections.	

## CHAPTER XLII.

TIC DOULOUREUX AND SPHENOPALATINE NEURALGIA . . . . .	557-587
Fifth Cranial Nerve—Tic Douloureux: Major Neuralgia of the Fifth Cranial Nerve—Sphenopalatine Neuralgia—Treatment.	

## CHAPTER XLIII.

LOCAL ANESTHESIA . . . . .	588-600
Means of Producing Local Anesthesia—Hypodermic Armamentarium—Technic of Injection—Local Anesthesia for Operations About the Mouth.	

## CHAPTER XLIV.

GENERAL ANESTHESIA . . . . .	601-603
Chloroform—Ether—Nitrous Oxid.	



## ILLUSTRATIONS.

FIGURE	PAGE
1. Coronal section through the face . . . . .	3
2. Muscular floor of the mouth . . . . .	4
3. Sublingual mucous surface . . . . .	5
4. Sublingual structures . . . . .	6
5. Sagittal section through the face . . . . .	8
6. Dorsum of the tongue . . . . .	9
7. Submucous palate structures . . . . .	13
8. Position of the teeth . . . . .	15
9. Sweet's cannula . . . . .	56
10. Vein-to-vein transfusion—Application of cannula . . . . .	57
11. Vein-to-vein transfusion—Cannula applied . . . . .	57
12. Vein-to-vein transfusion—Veins connected . . . . .	58
13. Myocardiogram in air embolism . . . . .	61
14. Blood pressure tracings in air embolism . . . . .	62
15. Blood pressure tracings in air embolism . . . . .	63
16. Blood pressure tracings in air embolism . . . . .	64
17. Interrupted suture, defective . . . . .	77
18. Interrupted suture, defective . . . . .	77
19. Interrupted suture, effective . . . . .	77
20. Relation of suture to wound . . . . .	77
21. Deep suture . . . . .	77
22. Modified Lane suture . . . . .	77
23. Figure-of-eight suture . . . . .	77
24. Fracture of the maxilla . . . . .	86
25. Fracture of the maxillæ . . . . .	87
26. Direction of pull of the floor muscles . . . . .	90
27. Diagram of horizontal displacement in fracture at first molar . . . . .	90
28. Diagram of horizontal displacement in double fracture at the cuspids . . . . .	90
29. Diagram of horizontal displacement in fracture near the angle . . . . .	90
30. Diagram of the pull of the floor muscles . . . . .	91
31. Diagram of vertical displacement in fracture in front of the cuspids . . . . .	91
32. Diagram of vertical displacement in double fracture at the cuspids . . . . .	91
33. Diagram of lack of vertical displacement in double fracture at the bicuspid . . . . .	91
34. Diagram of the pull of the muscles of mastication . . . . .	92
35. Diagram of vertical displacement in fracture behind the molars . . . . .	93
36. X-ray of fracture of the ramus . . . . .	94
37. Angle fracture bands . . . . .	96
38. Gilmer's method of wiring the teeth . . . . .	96
39. Gilmer's wires in position . . . . .	97
40. X-ray of silver wire passed around symphysis . . . . .	98
41. Gilmer's wires protected by gum . . . . .	99

FIGURE	PAGE
42. Diagram of method of wiring the body of the jaw . . . . .	100
43. X-ray of a wired fracture . . . . .	101
44. Hammond splint . . . . .	104
45. Plaster cast in fracture of the jaw . . . . .	104
46. Sawed plaster cast of the fractured jaw . . . . .	104
47. Plaster cast reconstructed, in fracture of the jaw . . . . .	104
48. Gunning splint . . . . .	104
49. Angle bar splint . . . . .	104
50. HULLIHAN splint . . . . .	104
51. Gilmer posterior band splint . . . . .	104
52. Diagram of mouth blocked open . . . . .	107
53. Modified Gunning splint . . . . .	107
54. Induration surrounding fracture . . . . .	108
55. Improperly set fracture . . . . .	110
56. Improperly set fracture . . . . .	110
57. X-ray of displacement of the ramus . . . . .	111
58. X-ray of displacement of the ramus . . . . .	112
59. Ligaments of the temporomandibular joint . . . . .	116
60. Section through the temporomandibular joint . . . . .	117
61. Head of a fetus in the fifth week . . . . .	122
62. Head of a fetus in the seventh week . . . . .	122
63. Schematic diagram of facial clefts . . . . .	123
64. Diagram of oblique facial cleft . . . . .	124
65. Oblique facial cleft . . . . .	124
66. Diagram of ordinary harelip . . . . .	125
67. Single harelip . . . . .	125
68. Median harelip . . . . .	125
69. Absence of the intermaxillary process . . . . .	126
70. Absence of the intermaxillary process . . . . .	126
71. Diagram of macrostomia . . . . .	127
72. Partial macrostomia . . . . .	127
73. Macrostomia . . . . .	127
74. Diagram of cleft of lower lip . . . . .	128
75. Diagram of the palate in the sixth fetal week . . . . .	128
76. Diagram of complete cleft palate . . . . .	129
77. Pendulous tooth in alveolar cleft . . . . .	130
78. Protruding tooth buds in alveolar cleft . . . . .	130
79. Incomplete double harelip . . . . .	132
80. Complete double harelip . . . . .	132
81. Skull with complete single palate cleft . . . . .	133
82. Skull with incomplete double palate cleft . . . . .	134
83. Incomplete harelip . . . . .	137
84. Lip pits . . . . .	138
85. Essential palate muscles . . . . .	140
86. Diagram of double cleft of the palate . . . . .	141
87. Diagram of single cleft of the palate . . . . .	141
88. Diagram showing the velum detached from the palate . . . . .	142
89. Intranasal palate flaps . . . . .	143
90. Diagram of the efficiency of palate flaps . . . . .	144
91. Diagram of cleft closed with the flap from the neck . . . . .	146

FIGURE	PAGE
92. Single complete cleft in an infant . . . . .	149
93. Single complete cleft in an infant, repaired . . . . .	149
94. Closure of the bony cleft in early infancy, first step . . . . .	152
95. Closure of the bony cleft in early infancy, second step . . . . .	153
96. Closure of the bony cleft in early infancy, third step . . . . .	154
97. Closure of the bony cleft in early infancy, wires traversing the maxillæ . . . . .	155
98. Closure of the bony cleft in early infancy, completed operation . . . . .	155
99. $\frac{5}{8}$ -circle needle . . . . .	155
100. Coronal section of an infant's face . . . . .	156
101. Relation of an infant's jaws in cleft of the palate . . . . .	157
102. Growth of the palate . . . . .	157
103. Diagram of needle traversing the maxilla . . . . .	158
104. Brophy palate needle . . . . .	158
105. Diagram of crushing forceps applied to maxillæ . . . . .	159
106. Knife for cutting the maxilla . . . . .	159
107. Cast of single cleft of the palate in an infant . . . . .	160
108. Cast of single cleft of the palate in an infant, repaired . . . . .	160
109. Diagram of mucoperiosteal flaps . . . . .	161
110. Incision for Lane operation for a single palate cleft . . . . .	161
111. Lane operation for a single palate cleft, completed . . . . .	161
112. Lane operation for a velum cleft . . . . .	161
113. Incisions for Lane operation for a cleft in the posterior part of the hard palate . . . . .	162
114. Lane operation for a cleft in the posterior part of a hard palate, completed . . . . .	162
115. Incision for Lane operation for a complete double palate cleft . . . . .	163
116. Lane operation for a complete double palate cleft, completed . . . . .	163
117. Robert's modification of Hammond palate clamp . . . . .	166
118. Diagram of the amount of tissue available for a palate flap . . . . .	167
119. Lane gag . . . . .	169
120. Owen's modification of Smith gag . . . . .	170
121. Palate tenaculum constructed from artery forceps . . . . .	171
122. Tonsil scissors . . . . .	172
123. Brophy elevators . . . . .	173
124. Bartlett elevator . . . . .	173
125. Application of Bartlett elevator . . . . .	174
126. Shepherd's crook needle . . . . .	175
127. Insertion of the shepherd's crook needle . . . . .	175
128. McCurdy's method of using the shepherd's crook needle, first step . . . . .	175
129. McCurdy's method of using the shepherd's crook needle, third step . . . . .	176
130. Vertical mattress suture . . . . .	176
131. Freeing the velum from hard palate . . . . .	176
132. Paring the left border of a palate cleft . . . . .	178
133. Paring the right border of a palate cleft . . . . .	178
134. First insertion of the needle . . . . .	180
135. Last insertion of the needle of the first suture of the palate cleft . . . . .	180
136. Vertical mattress suture in the mucoperiosteal flap . . . . .	181
137. Vertical mattress suture in the velum. . . . .	181
138. Suturing the velum . . . . .	181

FIGURE	PAGE
139. Suturing the mucoperiosteal flaps . . . . .	181
140. Stay sutures in position . . . . .	182
141. Lead plates in position . . . . .	183
142. Incisions for modified Küster operation . . . . .	187
143. Modified Küster operation, completed . . . . .	187
144. Palate cleft of extraordinary width . . . . .	188
145. Cleft narrowed by packing under flaps . . . . .	188
146. Cast showing the lateral incisions in a wide cleft . . . . .	189
147. Cast showing the lateral incisions in a wide cleft . . . . .	189
148. Cast showing the result of operation on a wide cleft . . . . .	189
149. Cast showing the defect resulting from sloughing at previous operations . . . . .	190
150. Cast showing the operative results . . . . .	190
151. Cast showing wide cleft with protruding intermaxillary process . . . . .	191
152. Cast showing cleft narrowed, and intermaxillary process brought back by orthodontic apparatus . . . . .	191
153. Cast showing final operative results . . . . .	191
154. Incisions for repairing cleft with buccal flaps . . . . .	192
155. Cleft repaired with buccal flaps . . . . .	192
156. Cast showing wide defect resulting from sloughing at previous operations . . . . .	194
157. Cast showing wide defect repaired with neck flap . . . . .	194
158. Permanent gag protecting the neck flap from the teeth . . . . .	195
159. Scar resulting from turning a neck flap into the mouth . . . . .	195
160. Displacement of alveolar process in a case of alveolar cleft . . . . .	196
161. Method of closing a wide alveolar cleft . . . . .	197
162. Alveolar cleft closed by operation . . . . .	197
163. Line of incision for replacing intermaxillary process . . . . .	198
164. Protruding intermaxillary process in a double harelip, with single alveolar cleft . . . . .	199
165. Protruding intermaxillary process in a double harelip, with complete double cleft of the palate . . . . .	199
166. Retraction of the tip of the nose after the repair of the double harelip . . . . .	199
167. Constriction of nostril after a harelip . . . . .	200
168. Temporary compression of blood vessels, while repairing a harelip . . . . .	201
169. Incisions for a Rose operation for an incomplete lip cleft . . . . .	202
170. Incisions for a Rose operation for a complete single cleft . . . . .	202
171. Method of approximating the cleft borders for a suture, after a Rose operation . . . . .	202
172. Incision for a Rose operation for incomplete double harelip . . . . .	202
173. Completed Rose operation for double harelip . . . . .	202
174. Cast showing result of an unsuccessful harelip operation . . . . .	203
175. Cast showing the result of operation after an unsuccessful harelip operation . . . . .	203
176. Incisions for the Owen operation for single harelip . . . . .	204
177. Suturing of the vertical cut in an Owen operation . . . . .	204
178. Suturing of the transverse cut in an Owen operation . . . . .	204
179. Incisions for an operation for a complete double harelip . . . . .	205
180. Completed operation for double harelip . . . . .	205

FIGURE	PAGE
181. Stay suture and lead plates, after a harelip operation . . . . .	206
182. The cutting of a displaced nasal septum . . . . .	207
183. Replaced nasal septum anchored to a bicuspid tooth . . . . .	208
184. Replaced nasal bones anchored to a molar tooth . . . . .	209
185. Breathing tube . . . . .	209
186. Diagram showing closure of nasopharynx by the velum and superior pharyngeal constrictor . . . . .	212
187. Nasopharynx open . . . . .	212
188. Constrictor action of the superior pharyngeal constrictor . . . . .	213
189. Obturator for cleft of the velum . . . . .	213
190. Obturator for cleft of the velum . . . . .	214
191. Nasal pharyngeal obturator to supplement a short velum . . . . .	214
192. Diagram of the seventh nerve . . . . .	219
193. Neck flap sloughing . . . . .	220
194. Incision for repairing a cheek defect by sliding flaps . . . . .	221
195. Repair of a cheek defect with a neck flap . . . . .	222
196. Repair of a cheek defect with a neck flap, second step . . . . .	222
197. Repair of a cheek defect with a neck flap . . . . .	223
198. Serre operation for replacing the angle of the mouth . . . . .	223
199. Result of a Burow-Stewart operation . . . . .	224
200. Ability to elevate the upper lip after a Burow-Stewart operation . . . . .	225
201. Burow-Stewart operation for restoring the lower lip . . . . .	226
202. The V-shaped excision of a small lip tumor . . . . .	226
203. Result of a V-shaped excision from the lip . . . . .	226
204. Excision of half the lower lip in the corner of the mouth . . . . .	226
205. Result of excision shown in the preceding figure . . . . .	226
206. Excision of the corner of the mouth . . . . .	227
207. Result after the excision shown in the preceding figure . . . . .	227
208. Excision of the lower lip and chin to be repaired with neck flaps . . . . .	227
209. Result of the excision shown in the preceding figure . . . . .	227
210. Restoration of the upper lip . . . . .	228
211. An acquired defect of the palate . . . . .	229
212. Repair of an acquired palate defect . . . . .	229
213. X-ray of undeveloped lower jaw . . . . .	230
214. Occlusion of the teeth, viewed from behind . . . . .	231
215. Jaw deformity resulting from premature loss of the first molar tooth . . . . .	232
216. Greek profile . . . . .	233
217. Negro profile . . . . .	233
218. Cast showing protrusion of the lower jaw . . . . .	234
219. Skull showing retraction of the lower jaw . . . . .	234
220. Diagram after Hunter, illustrating growth of the lower jaw . . . . .	235
221. Casts of a case of an open bite . . . . .	236
222. Photograph of a case of an open bite . . . . .	236
223. Correction of retraction of the mandible by orthodontic appliance, Lischer . . . . .	239
224. Correction of retraction of the mandible by orthodontic appliance, Lischer . . . . .	240
225. Transverse section of the face, diagrammatic . . . . .	241
226. Subcutaneous section of the ramus of the mandible . . . . .	242
227. Needle for passing a wire saw around the ramus . . . . .	242

FIGURE	PAGE
228. Dilator for forceful opening of the mouth . . . . .	242
229. X-ray showing the ramus cut and the body of the jaw moved forward	243
230. Lateral deviation of the chin . . . . .	244
231. Lateral deviation of the chin, corrected . . . . .	244
232. Jaw wired in position after section of the ramus . . . . .	245
233. Obliquity of the chin . . . . .	246
234. Retracted mandible brought forward by operation . . . . .	246
235. Retraction of the mandible, full face . . . . .	247
236. Operative correction of retraction of the mandible, full face . . . .	248
237. Retraction of the mandible, profile . . . . .	249
238. Operative correction of retraction of the mandible, profile . . . .	250
239. Cast showing protrusion of the lower jaw . . . . .	251
240. Cast showing protrusion of the lower jaw . . . . .	251
241. Cast showing protrusion of the lower jaw, corrected by operation .	251
242. Protrusion of the lower jaw, correction by orthodontic appliance, Lischer . . . . .	252
243. Protrusion of the lower jaw, correction by orthodontic appliance, Lischer . . . . .	253
244. Bone cuts for resection of the lower jaw for the correction of pro- trusion . . . . .	254
245. Reconstruction of the lower jaw after resection . . . . .	254
246. Double-bladed saw . . . . .	255
247. Submucous resection of the lower jaw . . . . .	257
248. Modified Angle splint for resected lower jaw . . . . .	258
249. Modified Angle splint, adjusted after resection of the jaw . . . .	258
250. Fixation of the jaw by wires, after resection . . . . .	259
251. Correction of open bite by simple section of the body of the jaw . .	259
252. Open bite corrected by V-shaped excision of the body of the jaw . .	261
253. Open bite corrected by an S-shaped section in the body of the jaw .	261
254. Ankylosis with retraction of the chin . . . . .	265
255. Pneumatic dilator for fibrous ankylosis . . . . .	266
256. X-ray showing normal mandibular joints . . . . .	268
257. X-ray showing ankylosis of the temporomandibular joints . . . .	269
258. Skin incision for resection of the joint . . . . .	270
259. X-ray showing resection of the joint . . . . .	271
260. Natural limit of opening in a case of ankylosis . . . . .	272
261. Limit of opening immediately after reconstruction of the joint . .	272
262. Mouth blocked open after reconstruction of the joint . . . . .	272
263. Final opening obtained after reconstruction of the joint . . . . .	272
264. Opening temporarily obtained after section of the ramus . . . . .	272
265a. Ankylosis with retraction of the chin . . . . .	273
265b. Operative result in a case of ankylosis . . . . .	274
266. Reconstruction of the temporomandibular joint . . . . .	275
267. Upper incisor and bicuspid forceps . . . . .	277
268. Right and left upper molar forceps . . . . .	277
269. Bayonet root forceps . . . . .	277
270. Hawk-bill forceps for lower anterior teeth . . . . .	277
271. Hawk-bill lower molar forceps . . . . .	277
272. Slender root forceps . . . . .	277
273. Root elevators . . . . .	278



FIGURE	PAGE
274. Root elevator . . . . .	278
275. Lecluse elevator . . . . .	278
276. Impacted upper third molar . . . . .	282
277. Impacted lower third molar released . . . . .	283
278. Noma . . . . .	292
279. Diagram of peridental infection . . . . .	307
280. Diagram of peridental infection . . . . .	307
281. X-ray of chronic bone abscess . . . . .	309
282. Bone absorption, resulting from pyorrhea alveolaris . . . . .	310
283. Infection around unerupted teeth . . . . .	312
284. Inflammatory destruction of bone . . . . .	313
285. Necrosis of the jaw-bone . . . . .	314
286. Acquired perforation of the palate . . . . .	316
287. Leontiasis ossea . . . . .	317
288. Rubber drain . . . . .	320
289. Unerupted third molar . . . . .	323
290. Diagram of bone abscess . . . . .	327
291. Diagram of the treatment of bone abscess . . . . .	327
292. Submaxillary incision for indurations of the floor of the mouth . . . . .	337
293. Submaxillary incision completed . . . . .	338
294. Submaxillary incision completed . . . . .	339
295. Result of operation . . . . .	340
296. Drilling the antrum . . . . .	345
297. Self-retaining temporary drain in antrum . . . . .	345
298. Denker operation . . . . .	348
299. Denker operation . . . . .	349
300. Calcified antral cyst . . . . .	350
301. Hypertrophy of the gums . . . . .	351
302. Epulis . . . . .	352
303. Osteoma . . . . .	354
304. Ossicles from jaw tumor . . . . .	355
305. Follicular odontoma . . . . .	356
306. Cementoma . . . . .	356
307. Cementoma . . . . .	356
308. Composite odontoma . . . . .	356
309. Inflammatory cyst of the jaw . . . . .	357
310. Bone cyst . . . . .	357
311. Supernumerary teeth . . . . .	358
312. Cystic adamantinoma . . . . .	364
313. Cystic adamantinoma . . . . .	364
314. Excision of the upper alveolar process . . . . .	371
315. Kocher incision for excision of the maxilla . . . . .	374
316. Total excision of the maxilla . . . . .	374
317. Ostoplasty resection of the maxilla . . . . .	374
318. Excision of the lower alveolar process . . . . .	378
319. Occlusion, after excision of one half of the mandible . . . . .	380
320. Scar band limiting the opening of the mouth . . . . .	380
321. Result obtained by releasing the scar band . . . . .	380
322. Martin splint . . . . .	380
323. Buried silver splint . . . . .	381

FIGURE	PAGE
324. Scar resulting from noma . . . . .	385
325. Lymphangioma of the face . . . . .	389
326. Lymphangioma of the face, result of the treatment . . . . .	389
327. Inoperable cancer of the mouth . . . . .	393
328. Submental incision for cancer of the lip . . . . .	395
329. Lymphatic excision in the upper part of the neck . . . . .	396
330. Diagram of location of sublingual dermoids . . . . .	404
331. Operation for sublingual cyst . . . . .	405
332. Exposure of the parotid gland . . . . .	410
333. Relations of the parotid duct . . . . .	425
334. Excision of the parotid gland, first step . . . . .	432
335. Excision of the parotid gland, second step . . . . .	433
336. Excision of the parotid gland, completed . . . . .	434
337. Scar from suppurating thyroglossal fistula . . . . .	459
338. Thyroglossal fistula . . . . .	460
339. Operation for invading the retrohyoid region . . . . .	461
340. Lymphatics of the tongue . . . . .	474
341. V-shaped excision from the tongue . . . . .	495
342. Excision of one half of the tongue from within the mouth, third step . . . . .	496
343. Excision of one half of the tongue from within the mouth, fourth step . . . . .	497
344. Diagrammatic coronal section of the tongue . . . . .	498
345. Excision of one half of the tongue within the mouth, completed . . . . .	499
346. Excision of the deep cervical lymphatics . . . . .	512
347. Paralysis of the lower lip following the submaxillary operation . . . . .	515
348. Branchial fistula of first cleft . . . . .	521
349. Branchial fistula of the second cleft . . . . .	521
350. Incision into the anterior faucial pillar . . . . .	530
351. Anastomosis of the facial nerves . . . . .	553
352. Injection of the facial nerve . . . . .	555
353. Anomalous distribution of the first division of the fifth nerve . . . . .	559
354. Anomalous distribution of the first division of the fifth nerve . . . . .	559
355. Pain spots in tic douloureux . . . . .	559
356. Pain spots in tic douloureux . . . . .	559
357. Pain spots in tic douloureux . . . . .	560
358. Radiation of pain in tic douloureux . . . . .	560
359. Needle for deep injections . . . . .	566
360. Injection of the mandibular nerve . . . . .	568
361. Position of the patient during injection . . . . .	569
362. Course of the needle during injection of the second and third division . . . . .	570
363. Osteoporosis of the skull . . . . .	571
364. Osteoporosis of the orbit . . . . .	574
365. Injection of the first division of the fifth nerve . . . . .	575
366. Anesthesia after injecting the second division of the fifth nerve . . . . .	576
367. Anesthesia after injecting the second division of the fifth nerve . . . . .	576
368. Anesthesia after injecting the first and second divisions of the fifth nerve . . . . .	577
369. Anesthesia after injecting the first and second divisions of the fifth nerve . . . . .	577
370. Anesthesia after injecting the second and third divisions of the fifth nerve . . . . .	578

FIGURE	PAGE
371. Incision for approaching the posterior root of the Gasserian ganglion	582
372. Rubber head apron on standard . . . . .	580
373. Rubber head apron in position . . . . .	581
374. Incision for approaching the posterior root of the Gasserian ganglion	582
375. Avulsion of the posterior root of the Gasserian ganglion—Exposure of the dura . . . . .	583
376. Avulsion of the posterior root of the Gasserian ganglion—Path trav- ersed along the floor of the middle cerebral fossa . . . . .	584
377. Avulsion of the posterior root of the Gasserian ganglion—Display of the middle meningeal artery . . . . .	585
378. Avulsion of the posterior root of the Gasserian ganglion—Ligation of the middle meningeal artery . . . . .	586
379. Avulsion of the posterior root of the Gasserian ganglion—Display of the root and the ganglion . . . . .	587
380. Subperiosteal injection of a cuspid tooth—Prinz . . . . .	594
381. Subperiosteal injection of a molar tooth—Prinz . . . . .	594
382. Subperiosteal, peridental, and intraosseous injection of a cuspid tooth—Prinz . . . . .	594
383. Peridental injection of a bicuspid tooth—Prinz . . . . .	594
384. Perineurial injection of the upper teeth—Prinz . . . . .	596



## CHAPTER I.

### PHYSICAL EXAMINATION—ANATOMICAL CONSIDERATIONS.

During the physical examination, at least mental note must be made of the condition of all the essential and correlated structures of the mouth.

#### EXAMINATION.

The adult to be examined should, if possible, be placed in a sitting posture. The light, which may be direct or reflected from a head mirror, should be good. To inspect the posterior part of the tongue or the nasopharynx, a head mirror and laryngoscopic or rhinoscopic mirror are necessary. One of the latter may also be used in place of a dental mirror. A comfortably fitting, broad tongue depressor is preferable to the handle of a spoon. Cocain<sup>1</sup> may be necessary to satisfactorily conduct certain details. If there is an overhanging mustache, it should be brushed or held well out of the way. The hands of the surgeon should be well washed, either in the presence of the patient or in an adjoining room, and the odor of tobacco, especially in examining women, should be entirely eliminated.

It is sometimes almost impossible to make a satisfactory examination of a struggling child, but patience and kindness will be successful in nearly every case. As a rule, children resist because they are frightened, and it is better to spend a little time in making friends than to risk prolonging strained relations by a forced examination. If the examination or treatment must be done forcibly, it is best accomplished by seating the child upon the nurse's lap, with its body well against her. With one hand pressed on the forehead, she holds the child's head against her shoulder or forehead; with the other arm she controls its arms and body.

Infants are best examined lying on the back on the nurse's lap, with the feet toward her body and the head hanging between her knees, with the face toward the surgeon and the light. The arms may be swathed to the body by a large towel or sheet, but if this is done, it should be done effectually.

A history should be obtained, not only of the affection for which relief is sought, but also the hereditary and personal history of any and

<sup>1</sup>The word cocain is used here as the generic term for local anesthetics of this class.

all conditions that may bear upon it. It should always be borne in mind that the mouth is an integral part of the body, that it may show local expressions of general diseases, and that local diseases are apt to have more or less effect on the whole organism.

If a rash is present, its character and distribution should be studied, and its possible relationship to a local irritation or a general disease considered. A sinus should be recognized and its cause determined.

In examining an ulcer, the surgeon should determine the character of its base, its edge and its discharge, the presence or absence of pain, the condition of the surrounding tissue, local and distant; their number and position should be noted, and their cause sought. An ulcer is a process of disintegration which is more intelligible to us than are formative changes. Sometimes the cause of the ulceration is as evident as the ulcer itself. With ulcers of uncertain character, a diagnosis is often facilitated by a microscopic examination of the discharge or scrapings made from the ulcer, or preferably from a piece removed from the edge and base.

The character of a tumor or a swelling can usually be more or less accurately diagnosed by following the scheme planned by Pierce Gould, which includes attention to the following points: its position, the determination of the structure in which located, its manner of onset, its physical characteristics, its life history, its mode of growth, presence or absence of pain, its evidence of infectivity—local and distant, the effect of the growth on the general condition of the patient, and when necessary, a laboratory examination of its tissues or its aspirated contents.

Microscopic and macroscopic examination should be made of pathologic discharges, while bacteriologic cultures will often shed further light.

Pain may result from local or distant causes. A carious tooth may cause pain at its site, or a neuralgia in the ear or in some distant point. Tenderness on pressure is always due to a local lesion. Referred pain, induced by pressure, may be due to impulses transmitted through nerves. Touching the cheek may start a paroxysm of tic douloureux at some other point. The pressure itself may be transmitted to a distant site. Pressing on the angles of the jaw will cause pain at the site of a fractured symphysis.

### MOUTH CAVITY.

The mouth is a part of the face. The latter consists of a series of bony partitions, covered with soft structures, attached to the fore part of the under surface of the brain case. These partitions inclose spaces that contain either air or special organs. The mouth is most inferiorly



## FLOOR OF THE MOUTH.

The floor of the mouth consists really of a muscular plane, which separates the mouth and its contained structures from the neck below. For convenience, however, the structures lying along its upper surface are spoken of as being in the floor of the mouth, and all of these, with their intraoral mucous covering, are referred to as the floor of the mouth.

The muscular floor is formed by geniohyoid muscles and the unpaired mylohyoid muscle, which stretches between two concentric bony arches from the concavity of the body of the mandible to the convexity of the body of the hyoid bone. Behind this, within the concavity of the hyoid bone, the air and food passages proceed downward from the oral

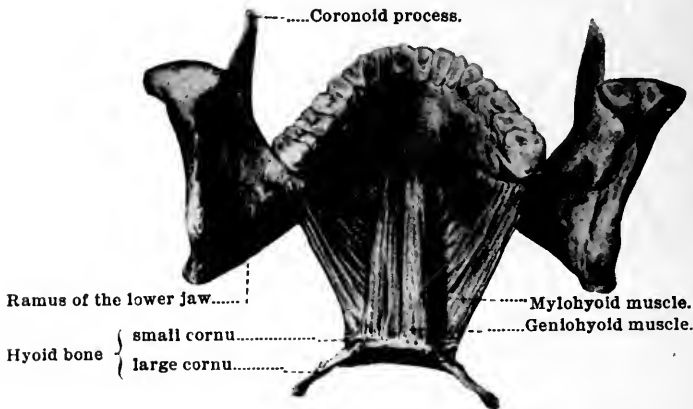


Fig. 2. Muscles that form the floor of the mouth stretching between the concavity of the body of the mandible and the convexity of the hyoid bone.—From Spalteholz.

pharynx into the neck. The lateral walls and most of the roof of the mouth are of unyielding tissue, and when closed, it is through the muscular floor that adjustment of capacity is accomplished (Fig. 2).

Except through a central vertical septum composed of the geniohyoglossi muscles, nowhere is the tongue in contact with the muscular floor. This is best illustrated by referring to coronal and sagittal sections of the mouth (Fig. 1). The space between the body of the tongue and the muscular floor is divided into two lateral compartments by this muscular septum. Each of these subspaces is bounded below by the muscular floor, externally by the body of the mandible, medially by the geniohyoglossi and geniohyoid muscles, and above by the reflection of the mucous membrane upon which the body of the tongue rests. In these compartments are the structures that are spoken of as being in the floor. Anteriorly these spaces are limited by the mental portion of



the mandible, while posteriorly, between the root of the tongue and the angle of the jaw, they open freely into the intermuscular connective tissue spaces of the neck. It is these posterior intermuscular spaces that afford entrance and exit to the vessels, nerves, and ducts that are found in the floor. Within the floor of the mouth are contained the lingual vein, lingual nerve, and submaxillary duct. The lingual artery lies buried in the under surface of the tongue. Within the floor of the mouth and in the under surface of the tongue are several excretory glands, mucous and salivary.

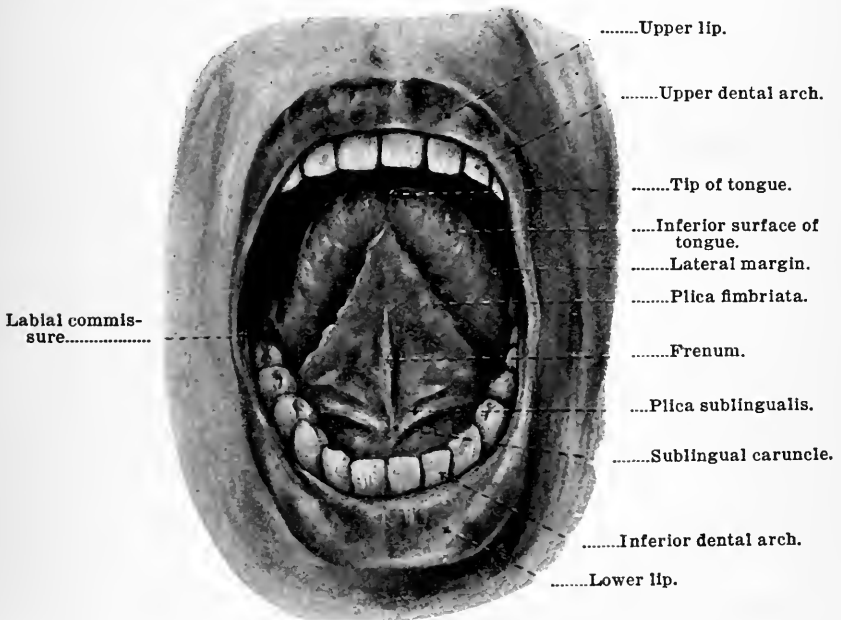


Fig. 3. Mucous reflections under the anterior of the tongue.—From Spalteholz.

**Glands of Nuhn and Blandin.**—Blandin first described a gland lying on the under surface of the tongue, near the tip, on either side of the midline, about the size of an ordinary almond. Each gland has one or two excretory ducts opening on the under surface of the tongue. Cysts, stones, and tumors occur in connection with these glands.

**Incisive Glands.**—Besides the glands of Nuhn and Blandin, Suzanne and Merkel have described a group of glands on either side, lying in front of the salivary caruncle and just behind the periosteum of the jaw.

Tillau and Fleischmann describe an inconstant sublingual bursa on either side between the geniohyoglossi muscles and the mucous membrane lying between the frenum and the sublingual gland. This has

been credited as the cause of acute ranula. Merkel and others have denied the existence of this bursa.

**Bochdalek's Glands.**—Bochdalek's glands are certain remnants containing ciliated epithelium supposed to be derived from the thyroglossal tract, which is often called the thyroglossal duct. Chronic obstruction of the excretory duct of an incisive, a Bochdalek, or a sublingual salivary gland causes a cyst known as ranula.

The sublingual salivary glands consist of lobules lying on the floor of the mouth beneath the submaxillary duct. The submaxillary salivary gland lies mostly outside of the mouth, beneath the mylohyoid muscle. Part of the gland, however, containing the common excretory duct, bends around the posterior border of this muscle, and comes

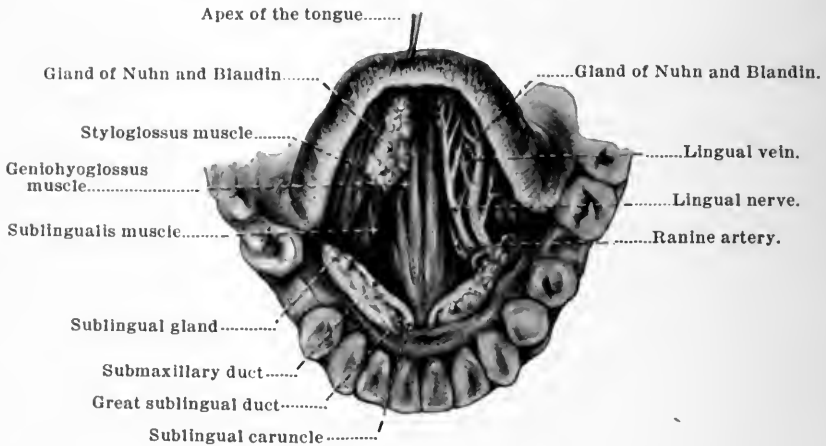


Fig. 4. Structures lying beneath and within the anterior part of the tongue.—After Spalteholz.

to lie above the muscle within the floor. The duct is continued along the upper surface of the mylohyoid muscle and sublingual gland.

On either side of the junction of the frenum of the tongue with the floor is a small papilla, on which may be seen the openings of the submaxillary ducts. Running backward from this, at the bottom of the sulcus, are two elevated ridges of mucous membrane, under which lie the sublingual glands, and through the crest of which the sublingual ducts open (Figs. 3 and 4). These ridges, the plicæ sublingualis, also mark the course of the ducts of the submaxillary glands, the lingual nerve, and the lingual vein, which lie along the floor of the mouth to the median side of the sublingual gland. The lingual nerve enters the floor of the mouth from above, just to the inner side of the body of the mandible, and can be felt by pressing the tip of the finger against the bone below the last molar tooth.

With one finger in the sulcus and two fingers of the other hand thrust under the jaw from without, the sublingual gland in front, and the submaxillary gland, posteriorly, can be distinctly outlined, unless there is too much fat. In the normal condition the submaxillary duct cannot be felt, but a stone in the duct, or the thickening around it, can always be detected. In carrying on this examination of the floor, the mouth should be moderately open, with the head bent slightly forward, to relax the muscles of the floor and the platysma. The fingers of one hand should steady the structures while they are being palpated by the other. In examining for stone in the duct, it is possible to pass a probe into the duct from the opening in the papilla. The connective tissue in the floor of the mouth is very lax. In certain inflammatory conditions it may become rapidly infiltrated with serum until the mucous membrane is raised up in a roll above the level of the gums, and the tongue is pushed before it.

### TONGUE.

The tongue in the normal state of rest is entirely within the mouth. The body occupies the upper portion of the cavity, and the dorsal surface presents an antero-posterior convexity that approximates a half circle. When the mouth is opened, the body follows the movements of the lower jaw (Fig. 5). It is anchored, by relatively small muscular attachments, posteriorly to the body of the hyoid bone and anteriorly to the symphysis of the mandible. Its mucous reflections and some extrinsic muscles further limit its excursion and determine its shape. Nowhere is it attached or supported by ligaments. The mobility of the tongue is further augmented by the fact that the hyoid bone is, in turn, dependent for its position entirely on the muscles to which it furnishes attachment.

Far back on the tongue, and best seen with a mouth mirror, is the sulcus terminalis, a scarcely visible V-shaped furrow on the dorsal surface. It runs from the attachment of the anterior faucial pillar, on either side, backward and toward the median line to the foramen cecum, which latter marks the upper termination of the thyroglossal duct or tract. Slightly in front of and parallel with the sulcus terminalis is a V-shaped row of large taste papillæ, known as the circumvallate. These, by their supply through the glossopharyngeal nerve, are related to the pharyngeal portion of the organ.

That portion of the tongue behind the sulcus is called the root, and is morphologically related to the pharynx; while that in front is the body, and is derived from the primitive buccal cavity. The root of the tongue forms most of the anterior wall of the oral pharynx.

The mucous covering of the pharyngeal surface continues on to the

fauces and the lateral pharyngeal walls. Below it is reflected on to the front of the epiglottis and forms the middle glossoepiglottic fold. This part of the mucous membrane is much more sensitive to pain than that over the dorsum, and in examination, unless cocainized, should not be touched by the tongue depressor. The submucous tissue of this

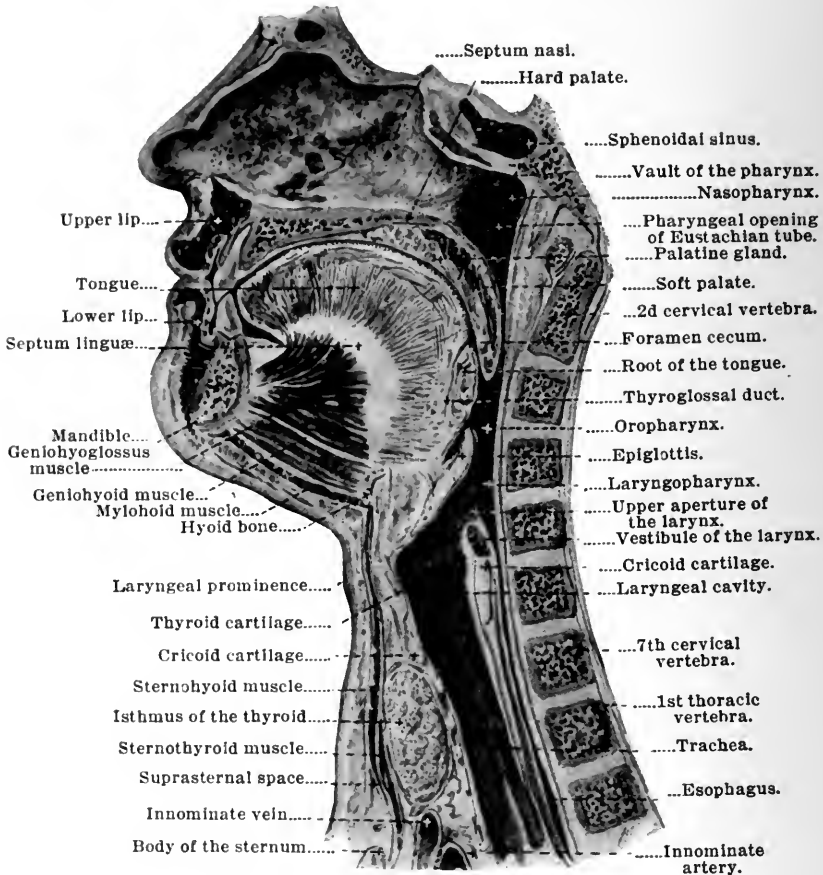


Fig. 5. Sagittal section through the midplane of the face.—After Spalteholz.

part contains mucous glands and heaped-up lymph follicles, the latter constituting the lingual tonsil (Fig. 6). This, with the faucial and pharyngeal tonsils, makes a complete ring of adenoid tissue surrounding the entrance of the pharynx. There are also mucous glands on the dorsal surface, and lateral borders in the neighborhood of the sulcus terminalis and circumvallate papillæ, and any of them may give rise to a mucous cyst. Over the dorsum the mucous membrane is beset

with taste papillæ. These give the tongue a rough appearance, which varies greatly under certain conditions.

The mucous covering is reflected from the dorsum around the borders to the inferior surface of the body, which latter it invests over the greater part of its extent. Thence the mucus passes to and across the floor to the gum and fauces, and while it forms part of the anchorage of the organ, this distribution permits of great freedom of movement and also of digital examination of the body and of the floor separately.

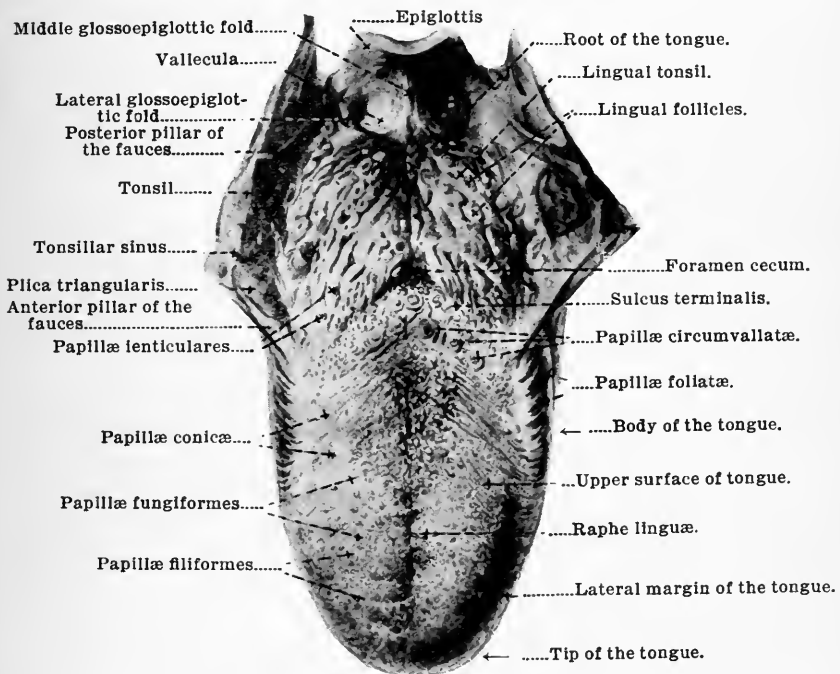


Fig. 6. Dorsum of the tongue.—After Spalteholz.

On raising the tongue, it will be seen that the mucous membrane on the under surface is smooth in character, and that it is reflected to the bottom of the glosso-alveolar sulcus in a double fold, with a free border anteriorly (Fig. 3). At the posterior limit of this fold the membrane forms the posterior limit of the glosso-alveolar sulcus by becoming continuous with the lower gum and anterior faucial pillar behind the last molar tooth. In the anterior portion of this fold the two layers of mucous membrane inclose but little connective tissue, while posteriorly they are separated by the interposition of the geniohyoglossi muscles. Grasping this septum with the thumb and finger,

the anterior border of the muscles can be felt. The anterior non-muscular portion of the septum is called the frenum. It may be abnormally short from above downward, and its upper attachment may extend sufficiently forward to bind the tongue down in the sulcus. This condition is known as tongue-tie, and is rather rare. The opposite condition of too great laxity of the frenum has been reported to have caused death by suffocation by the tongue turning back into the pharynx.

Two elevated fringes may be seen on the under surface of the tongue, converging at its tip. These indicate the positions of ranine arteries. About 12 millimeters on either side of the frenum may usually be seen the terminations of the ranine veins. These, with other veins in the sulcus, may become varicose, in which case a mass of large dark veins are seen under the mucous membrane, almost obliterating the fore part of the sulcus. They are soft and yielding to touch, but fill as soon as the pressure is removed.

A dermoid cyst may be met with on the under surface of the tongue, usually in the midline between the two geniohyglossi muscles, and is probably due to an infolding of integument during development. Accessory thyroids may occur above the mylohyoid muscle, and may become the seat of a goiter.

The surface in front of the circumvallate papillæ is the least movable part of the body of the tongue, and is therefore more apt to be coated. Unilateral furring has been noted in connection with irritations of the fifth cranial nerve of the same side, but as Mr. Hutchinson states, unilateral furring in the presence of toothache may be due partly to the instinctive immobilization of the tongue on that side. We have repeatedly observed unilateral furring in tic douloureux.

The mucous membrane of the tongue, like that of the mouth, is liable to a variety of superficial lesions. Aphthæ may form upon the tip and edges, thrush may occur in infants and adults whose health is broken down, herpes is occasionally seen, and the ulcerative stomatitis may extend to it from the cheek or palate. In addition to these, however, and to various kinds of specific diseases—such as syphilis and tubercle—the tongue is especially subject to certain forms of chronic inflammation. Some are superficial, and spread over the greater portion; others are local, and end in deep ulceration. On the mucous surface of this part—or, in fact, over any part of the mouth—may develop one or more white sodden patches of leucoplakia, or a papiloma or nevus may be present.

The body of the tongue is composed almost entirely of intrinsic muscles. Between the two halves of the body is an incomplete fibrous septum corresponding to the median raphe. Butlin is inclined to re-

gard this as analogous to certain fibrous or bony processes found in connection with the midplane of the tongue or body of the hyoid bone in certain lower animals. Occasionally fatty and cartilaginous masses have been found in connection with the median septum of the human tongue. It is a matter of clinical observation that cancer of one side of the body of the tongue is very slow to cross the median septum.

Foreign bodies may become imbedded in the body of the tongue. It may be the seat of gummata and many other infections. Dermoid cysts, lipomata, and fibromata occur in its substance, but these benign growths are rare. It is a favorite seat of cancer, which often develops from a papilloma, leucoplakia, or any chronic irritation, but sarcoma of the tongue is very rare. Abscess of the tongue is not common, but it contains sufficient connective tissue to allow great swelling; and it is sometimes subject to a congenital enlargement known as macroglossia. Congenital deformities of the tongue are very rare, the commonest being tongue-tie, or a median cleft of the body. The latter resembles that of some lower animal.

The tongue is plentifully supplied with blood, chiefly from the lingual arteries, which run near its inferior surface and which have but scanty intercommunication.

The lymphatics are especially large and numerous, and rapidly disseminate cancer cells. They drain from different areas into the submental, submaxillary, and superior and inferior deep cervical nodes. Special importance is attached to one superior deep cervical node situated a little above the bifurcation of the common carotid artery, which, on account of the numerous streams that reach it, has been called the principal node of the tongue.

The motor nerve supply of the tongue is mostly from the hypoglossal. Injury to this nerve or its center, or pressure on the nerve at its foramen of exit or any other point, will cause paralysis and atrophy on the affected side. When protruded, the tongue deviates toward the paralyzed side.

The tongue is well supplied with sensory nerves for both taste and common sensation. Tactile sensation is more acute on the tip than on any other part of the body. The sensory supply of the pharyngeal surface and the circumvallate papillæ is through the glossopharyngeal nerve from fibers originally derived from the trifacial. This latter nerve supplies also the oral part of the organ directly through the lingual. The taste papillæ on the tip, sides, and dorsum probably send their afferent fibers through the lingual and chorda tympani nerves.

Painful affections of the tongue in the area supplied by the lingual nerve may be accompanied by severe neuralgia deep in the meatus of the ear through the connection of the fifth nerve with the seventh, or

it may be over the terminal branches of the fifth. Spasmodic contractions of the muscles of mastication may result from the same reflex irritation of the fifth. According to Dr. Head, irritation on the pharyngeal surface may be associated with tender areas in the skin of the larynx.

### PALATE.

The palate presents a median raphe, which ends anteriorly in the incisive papilla, which marks the opening of the anterior palatine fossa. In infants this papilla is connected with the frenulum of the lip. The raphe may be raised by a ridge of bone in the midline, the *torus palatinus*. Sometimes a small pit that will admit the point of a pin is seen on each side immediately behind the incisive papilla about 2 millimeters from the midline. These correspond to the lower openings of Stenson's canals.

In the region of the junction of the hard and soft palates is usually seen on each side of the raphe a small pit, the *foveola palatina*, which contains the excretory ducts of several palate glands. The palate ridges are confined to the anterior part of the hard palate.

The mucous membrane and periosteum of the hard palate are fused into a single layer, which is thickest at the edges and is rather insensitive. The vessels of the palate lie in its deeper portion, and the descending palatine arteries may be felt pulsating in the posterior part, close to the junction of the palate with the alveolus (Fig. 7). In the submucous tissue is a layer of mucous glands, which is thickest at the lateral border and at the junction of the hard and soft palates. Large mucous glands are found on both surfaces of the uvula.

The soft palate, or *velum*, is composed of muscle and the palate aponeurosis. It is attached to the posterior border of the hard palate, and covered with mucous membrane on both surfaces. From the middle of its posterior border hangs a fleshy mass, the uvula, which helps to close the space between the posterior faucial pillars during the act of swallowing, etc. It may be absent, bifurcated, or abnormally large.

The anterior faucial pillars, arching from the under surface of the *velum* 1 centimeter in front of its free edge, near the base of the uvula, pass downward and slightly forward to join the tongue a little in front of the middle of its lateral border. These are made up of the *palatoglossi* muscles, covered by mucous membrane.

The posterior pillars spring from the posterior border of the palate, and pass downward and slightly backward, to be lost in the lateral wall of the oral pharynx. They contain the *palatopharyngei* muscles. Between the anterior and posterior pillars lie the faucial, or oral, tonsils. Just behind the last upper molar tooth is the prominence of the max-



illary tubercle, and behind that may be felt the hamular process which surmounts the internal plate of the pterygoid process of the sphenoid bone. Over this hamular process plays the tendon of the tensor palati muscle.

The upper surface of the hard palate can be partially examined through the nose with a sound or by inspection. As suggested by Kocher, after division of the columella and the nasal septum, this examination may be made with the finger. The upper surface of the soft palate can be palpated from behind through the oral pharynx.

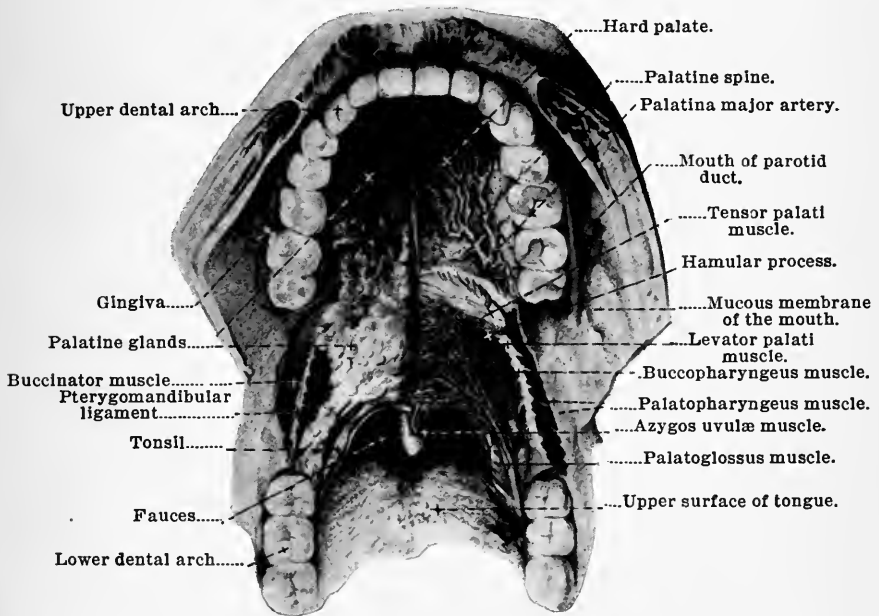


Fig. 7. Submucous structures of the palate and faucial pillars.—After Spalteholz.

The arch of the palate varies in height, width, and shape. Marked variations are usually credited to, or associated with, early mouth breathing. The palate may show a congenital longitudinal cleft in a part or the whole of its length. It may show the scars resulting from the surgical repair of such a deformity, or defects due to injuries or distinctive ulceration.

The velum or the fauces may be deformed by cicatricial contraction and adhesions resulting from destructive inflammations. The palate is a favorite site for gummata and resulting syphilitic perforations, and in some countries lupus and tuberculosis are not uncommon. Cysts and benign and malignant tumors are also found in the palate, and teratomata may be connected with it.

### FAUCES AND PHARYNX.

When the patient breathes deeply through the mouth with the head thrown back, the soft palate is raised, the pillars are separated, and the uvula, tonsils, fauces, and walls of the oral pharynx are exposed. The arch of the atlas corresponds to the hard palate, and the body of the axis to the soft palate (Fig. 5). The upper four, in children the upper six, vertebral bodies can be examined with the finger. The posterior pharyngeal wall should rest firmly against the bodies of the vertebræ, but may be separated from them by a postpharyngeal collection of pus.

The examining finger can feel the circumvallate papillæ, lingual tonsil, epiglottis, arytenoepiglottic folds, and smaller laryngeal cartilages. Passing the finger upward behind the velum, the vault of the nasopharynx, posterior part of the nasal septum and Eustachian cushions, and if enlarged, the pharyngeal tonsil may be felt. In examining a hypertrophied pharyngeal tonsil, the amount of enlargement may be gauged by observing the height to which it rises on the posterior border of the septum. This may be done with the finger or with the posterior nasal mirror. Cocain may be necessary to make such an examination in the adult, but here the laryngoscope and posterior rhinoscopic mirror will reveal what is more readily felt in children.

The palate, fauces, and oral pharynx in children are especially liable to injury from falling on sharp sticks. This may be followed by a condition of trismus, not necessarily tetanus, and requires an anesthetic to make a satisfactory examination. The lymphatics from the palate and upper part of the pharynx pass to the lateral pharyngeal and retropharyngeal and to the superior cervical nodes.

Besides the acute and chronic catarrhs, the pharynx is subject to secondary tuberculous ulcers, mucous patches, snail-tracked ulcers of secondary syphilis, diffuse gummatous infiltration, and localized submucous gummata. Benign tumors and both primary and secondary malignant tumors are also found in the pharynx.

The oral tonsils are situated between the anterior and posterior faucial pillars, and rest on the superior constrictor muscle of the pharynx. When enlarged, the tonsil may stand out freely from the pillars, or it may push the anterior pillar inward, in which case it is known as a buried tonsil. Often as much or more can be gained by palpating the tonsil as by inspection (Fig. 7).

Besides the enlargement of the tonsil itself from acute or chronic inflammation, there may be infection and suppuration of the peritonsillar tissue, with diffuse swelling and induration of the surrounding parts. If such a collection of pus bursts through the pharyngeal

wall, postpharyngeal suppuration will result. Chancre, secondary snail-tracked ulcers, and diffuse gummata are the syphilitic lesions most commonly found. Fibroma, epithelioma, lymphosarcoma, and round-celled sarcoma are the tumors common to the tonsils.

The lymphatics from the tonsils drain into the superior deep cervical nodes. An enlargement of one of these, situated just behind the angle of the jaw, is so constant in tonsillar infections that it has been called the tonsillar node.

### TEETH.

The crowns of the teeth rise free in the mouth above the gum margin. The anterior teeth have incisive edges, and are for biting off the food; while the posterior, the molars, are broad and have grinding surfaces. The teeth between these, the cuspids and bicuspid, are in-

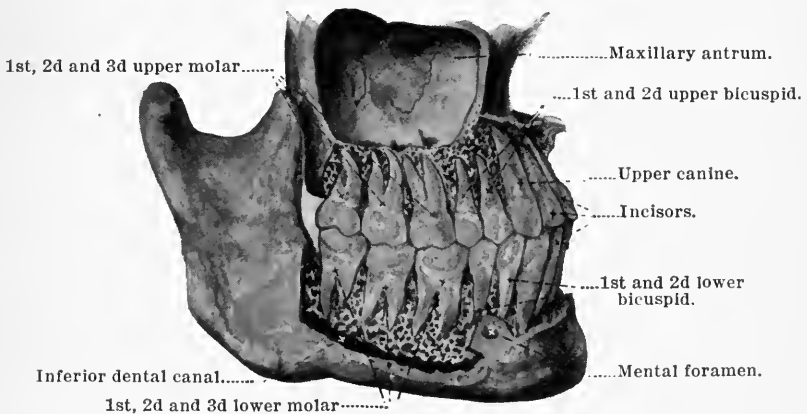


Fig. 8. The occlusion of the teeth and their position in the jaw-bones.—After Spalteholz.

termediate in character and function. Later in life, when the teeth are worn down, fairly good grinding surfaces are formed on the anterior teeth, which are very useful when the bicuspid and molars are lost. In most individuals the edges of the lower incisors are slightly overlapped by those of the upper, which gives them a scissors action. The crowns of the upper central incisors are wider than the lower, with the result that every tooth in the lower jaw, with the exception of the central incisors, is in relation with two teeth in the upper, and every tooth in the upper jaw, except the last molar, is in relation with two in the lower. This relation is in such a way that any cusp of any tooth in the lower jaw is slightly in advance of the corresponding cusp of the same tooth above (Fig. 8). In the molar region the buccal cusps of

the lower teeth rest in the grooves formed between the buccal and lingual cusps of the upper. Any variation from this arrangement in the child, especially if the variation is in the occlusion of the first molars, should be referred to the orthodontist for examination.

The crowns of the teeth may be perfectly formed, or show the malformations resulting from early nutritional disturbances. Common among these is the Hutchinson tooth, which is best marked in the upper central incisors, and consists in a notching of the incisal edge and a globular shape to the crown. This has been supposed to be almost always caused by congenital syphilis. The crowns of the teeth may be of various sizes and shades of color, and the teeth may vary in form and number. They may be abnormally soft, and as a result of this in young people, or from continued use in older ones, the crowns may be worn away almost to their necks. The teeth may present all stages of caries from slight pits in the enamel to total destruction of the crowns and parts of the roots. In most instances the caries is evident on ordinary inspection. A cavity may, however, be hidden on the interdental surface, or a very slight crack in the enamel may lead down to an extensive destruction of the dentin or to an open pulp cavity.

Unless the patient is scrupulous in the care of his teeth, and even then in certain individuals, the teeth will show deposits of tartar. This consists mostly of the precipitated calcium salts of the saliva, and therefore the deposits will be greatest on the lingual surfaces of the lower incisors and canines and on the buccal surfaces of the upper molars, these being exposed to the salivary streams from the submaxillary, sublingual, and parotid glands.

The nerves supplying the teeth are derived from the second and third divisions of the fifth nerve, the dental branches from which pass through bony canals in the substance of the maxilla and the mandible. They also receive fibers from the palatal, lingual, and buccal nerves. Caries or other irritations of the teeth, or direct irritation of the nerves in the bony canals, may cause reflex neuralgia along other distributions of the fifth nerve. It may also cause spasm of the muscles of mastication. Spasm seems to be more commonly associated with irritation of the third division than of the second.

In this regard, the condition of the tooth pulp—whether healthy, inflamed, or dead—and the condition of the peridental membrane is often a matter of importance.

The diagnosis of the conditions of a tooth depends on changes of color, sensitiveness or lack of sensitiveness to certain stimuli, including the electric current, heat and cold, variations in translucency, and percussion note produced when struck with a metal instrument. To interpret these accurately requires the experience and training that be-

long essentially to the dentist. The most accurate method of diagnosing the condition of the pulp is by the use of the electric current as developed by Prinz.<sup>2</sup>

### GUMS.

The gums may be inspected and palpated throughout their entire extent. They are composed of a mucoperiosteum, which surmounts the alveolar processes of the jaws. This covering resembles the soft tissue of the hard palate, and contains large mucous glands. These are especially numerous near the necks of the teeth, and any of them may give origin to mucous cysts. It is continuous with the mucous covering of the lips and cheeks on the outer surface, and with that of the palate and floor of the mouth on the inner. Around each tooth the mucofibrous tissue rises on the base of the crown, forming a collar which constitutes the gingival margin. For some distance from its occlusal edges, each tooth is in contact with the tooth on either side of it. Toward the neck the crown decreases in size, leaving the interdental spaces into which the gingiva extends, forming the interdental papilla. The periosteum descends into the alveolus as the periodontal membrane, which performs its double role of covering the root and lining the socket.

The periodontal membrane is of such consistency that, while it holds the teeth sufficiently firm for function, they are not perfectly rigid in their sockets, and an inflammation of this membrane will cause the teeth to rise and become abnormally loose.

Salivary calculus, which collects around the necks of the teeth, is one of the causes of chronic irritation of the gingiva, and brings about the recession of the gums so commonly seen. This irritation may open an avenue of infection to the periodontal membrane, in which case pus may be seen exuding from between the socket and root, and the teeth may become permanently loosened and lost. When advanced, this condition is called pyorrhea alveolaris, and is to be distinguished from an abscess in connection with the root, which discharges between the tooth and the soft tissue. Certain mineral poisons also predispose the gingiva to ulcerative inflammation, among which are mercury, phosphorus, and bismuth, while lead produces the characteristic blue line running along the gingival edge.

After an unchecked caries has attacked the dentin of the crown, it is apt to open into the pulp chamber, which is continuous with the root canal. This later opens through the apical foramen into the apical connective tissue space of the alveolus, creating an open avenue of infection from the pulp chamber to the periodontal tissue, which may result in any degree of inflammation or suppuration (Figs. 279, 280).

<sup>2</sup> Prinz, Dental Materia Medica, page 513.

If properly treated by the dentist, such an abscess may sometimes be made to discharge through the root canal, but if neglected, it seeks the surface by one or two routes. In the incisor region it may occasionally discharge at the side of the root, so that the pus will be seen welling up around the neck. In all cases it will most likely perforate the alveolar process, and give rise to a subperiosteal abscess, which occasionally points toward the mouth, but generally toward the buccal cavity. In the upper jaw such an abscess, having perforated the bone, may burrow under the mucous membrane of or perforate into the maxillary sinus. Such abscesses are generally accompanied by considerable swelling of the face and marked constitutional disturbance. The acute pain is, for a time at least, relieved when the pus finds egress from the alveolus (Fig. 280).

If the perforation is from the abscess surrounding the root of a tooth that has but a single root, as an incisor, it will almost always be on the labial surface of the alveolar process. In the case of a lower molar—which has two roots, one in front of the other—the perforation may be on either surface, usually the buccal. The first and second upper molars, however, have each three roots, one large one on the palate side and two smaller ones situated buccally. Infection from the tooth may travel through any of these roots, and therefore the perforation of such an abscess may be into the antrum or on the palate, or the buccal surface. In any event, the resulting abscess may be present at the time of the examination, or a sinus may lead down to a piece of dead bone or root, or to a chronic bone abscess (Fig. 281).

In the lower jaw the dissecting up of the periosteum by pus is apt to be followed by extensive necrosis of the bone, but in the upper jaw caries or absorption abscess is more common. The presence of areas of necrotic bone may be verified by feeling with an ordinary probe, but caries is best detected by thrusting a sharp steel Gilmer probe through the gum tissue into the soft insensitive bone, or by use of the x-ray. Though the mucous covering of the gum is relatively rather insensitive, it is better to cocaine it before making the punctures. A local tenderness, a submucous thickening, or an abnormally soft spot will generally be the guide for making such a puncture. In any of these conditions a radiogram is very helpful.

The gums may be the seat of leucoplakia, acute or chronic abscess, or mucous cysts. Very rarely in young people there is a chronic hypertrophy of the gums that may hide the teeth and greatly encroach upon the vestibule and mouth cavity (Fig. 301).

Epulis may be present on the gums in the form of a small pedunculated or sessile tumor arising from the periodontal membrane or periosteum; or a sarcoma, osteoma, or fibroma may involve a large section of

the gum and jaw-bone. Carcinoma, often secondary to carcinoma of the lip, cheek, or tongue, is common in old people, especially men.

### VESTIBULE OF THE MOUTH.

The vestibule of the mouth is the space bounded by the lips and cheeks externally, and the teeth and gums internally. The muscular layer of the cheeks and lips is more or less closely attached to the outer surface of the jaws. The mucous lining is reflected on the alveolar processes, and is continuous with the gums. In the midline above, this reflection is drawn down in a fold which connects the upper lip with the gum. This fold, which is called the frenum or frenulum of the lip, may contain a nodule or may preserve the infantile arrangement of reaching to the incisive papilla. In the latter case it will cause a separation of the two central incisors. The frenum of the lower lip is not so marked as the upper.

Posteriorly, when the mouth is closed, there is a space behind the third molars and the maxillary tubercle, that will admit a 5-millimeter tube, through which the vestibule communicates with the cavity. When the mouth is widely open, the pterygomaxillary ligament can be felt stretching from the hamular process of the sphenoid bone to the inner side of the ramus of the mandible. Posteriorly the superior constrictor of the pharynx is attached to the full length of the ligament, while anteriorly it gives attachment to the buccinator muscle, and through it these muscles are continuous with each other. The orbicularis oris muscle in front, the buccinators laterally, and the superior pharyngeal constrictor behind form a continuous muscular band which surrounds the vestibule and the oral pharynx. To the outer side of this ligament may be felt, in the order named, the anterior border of the internal pterygoid muscle, the whole of the anterior of the border of the ramus of the mandible and its coronoid process, and the anterior border of the masseter muscle (Fig. 225).

Temporal abscess may point into the upper fornix of the vestibule, between the coronoid process and the maxillary tubercle. In the upper fornix above the first molar may be felt the prominence of the malar process of the maxilla. In front of this prominence is the canine fossa, through which the antrum may be opened. Opposite the second molar tooth will be seen the papilla through which the duct of the parotid gland discharges. It admits a probe with difficulty. The cheeks and lips are everywhere closely applied to the gums and teeth by the tone of the buccinator muscle, which, in chewing, prevents the food from falling into the lower fornix. In palsy of the seventh nerve this power is lost.

The mucous membrane is everywhere closely adherent to the mus-

cles of the cheeks, with but little submucous tissue. This accounts for the fact that in health it is seldom caught between the teeth.

There are a number of mucous glands lining the cheek, especially in the neighborhood of the last molar teeth, which are called the buccal glands. These may become cystic. Over the lips the submucous tissue contains a number of large mucous glands, which may be felt with the tongue, and which may be congenitally cystic or may become distended later. The cheek may present an acute or chronic traumatic ulcer, a papilloma, a patch of leucoplakia, or a carcinoma. Sarcoma of the cheek may be secondary to sarcoma of the jaw. The gums, lips, and cheeks may show recent noma or its resulting scars. Dense scars from this or other causes, situated in the oral surface of the cheek, may materially limit the separation of the jaws.

### LIPS.

The lips surround the entrance to the vestibule, which is the rima oris. Here they are covered with a modified mucous membrane, which begins where the integument changes color at the outer margin. This membrane ends posteriorly just behind the line along which they meet when closed, where it merges into the ordinary mucous membrane of the vestibule. It contains numerous simple vascular papillæ, in which its nerves terminate, and which renders this part of the lip exquisitely sensitive to pain. It contains no hair follicles, but especially near the skin line are numerous sebaceous follicles, which may become the seat of minute retention cysts, or the starting point of rodent ulcer. The lips themselves are made up of skin, fatty superficial fascia, the orbicularis oris muscle, submucous tissue, and mucous membrane. The two lips converge at the angles of the mouth, which are situated opposite the first bicuspid teeth. The line of closure of the lips is slightly curved, and is just below the middle of the upper incisor crowns. The size of the rima oris varies in individuals, and seems to be related to the size and prominence of the teeth.

The orbicularis oris, which surrounds the aperture, is a circular muscle, which has very slight bony connections, but is closely attached to both the mucous membrane and the skin. It receives fibers from and constitutes the insertion of every muscle of the face that converges to the mouth, including the buccinators, and accounts for the infinite variety of expressions and contortions of which the lips are capable. The laxity of the lips favors plastic operations, but is also partly responsible for the distortion caused by scars that follow destructive inflammations. The lips contain a large amount of connective tissue, and are capable of immense swelling that may be dependent on injury, infection, or angioneurotic edema.



The blood supply of the lips is mostly from the coronary arteries, which form an elliptical anastomosis around the mouth near the deep surface, and which can usually be felt pulsating under the mucous membrane. In falls on the lips, they are easily cut by the teeth, and the blood may be swallowed, thus giving rise to the surmise of some internal injury. The facial vein continues above with the ophthalmic, and neither contain valves, which accounts for the comparative frequency with which facial infections cause septic thrombosis of the cavernous sinuses. The cutaneous surface of the lips in both sexes is closely beset with hair follicles, that may become the starting point of carbuncle. The lymphatics of the lip drain into the submental and submaxillary nodes. The sensory supply is of the fifth nerve—the upper lip through the infraorbital, the lower through the long buccal and inferior dental. The motor supply of all the muscles of the face is from the seventh cranial nerve. Complete unilateral paralysis causes a characteristic drawing of the mouth to the opposite side and inability to close the eye.

The lips and oral slit are subject to a variety of malformations. The lower lip especially may be subject to congenital enlargement due to lymphatic hypertrophy. There may be enlargement of the upper lip in children, associated with labial fissures. In both children and adults enlargement of the lower lip may be due to syphilis. The skin of the lips immediately surrounding the mouth may be covered with fine radiating scars of syphilitic origin. The lips are the common seat of nevi of various sizes, and the mucocutaneous edge of the lip is the most common site of herpes, fissure, extragenital chancre, and epithelioma. Papillomata of the lip have been known to become cornified, and even to develop true protruding horn. Either lip may be congenitally cleft.

### TEMPOROMANDIBULAR JOINT.

Passing the finger backward along the lower border of the zygoma, the condyle of the mandible is distinctly palpable just in front of the ear. Pressing gently on this point with two fingers while the mouth is being opened, the condyle is felt to travel first downward and forward, and then straight forward as it travels on and then across the articular eminence. As the limit of excursion is approached, there may be a slight click, a loud cracking, or even a locking of the condyle on the eminence. The latter is a subluxation. The condyle may be dislocated into the pterygoid fossa, in which event the mouth is held rigidly open. When the mouth is wide open, a deep hollow can be felt in the position that is occupied by the condyle when the mouth is closed. By violent force transmitted through the jaw, such as a fall on the chin, the condyle may be driven through the tympanic plate of

the temporal bone into the middle ear or upward into the middle fossa of the skull, constituting the backward or upward dislocations.

This joint, on one or both sides, may be replaced by a true ankylosis, or the movement may be limited by fibrous tissue. If ankylosis has existed during the period of growth, it will interfere with the development of the mandible and cause retraction of the chin. The joint may be the seat of any of the affections to which true joints are subject. Suppuration in the joint is more apt to spread anteriorly or posteriorly than externally or medially on account of the relative thickness of the capsule in these various surfaces. On account of its proximity to the middle ear, the pus may invade that cavity, or vice versa.

There may be mechanical interference with normal action of the jaw, or there may be paralysis or spasticity of one muscle or a group of muscles, or certain members of several groups. The former condition may be due to one or more of several causes. A tumor may mechanically interfere, or the joint may be the seat of true or fibrous ankylosis, or of exostosis. The condyle or interarticular cartilage may be dislocated, or scars may bind the bone in any part. In certain fractures the jaws cannot close voluntarily. The limitation may be voluntary, to avoid the pain it would induce as the result of inflammation or an injury. Muscle spasm may be caused by central irritation or peripheral irritation along the distribution of its own or associated nerves; almost never by disease within the muscle. Paralysis is always caused either by a central lesion or some interference in the course of the motor-conducting paths to that muscle.

## JAWS.

The jaws should be examined on all exposed surfaces. With the exception of the sigmoid notch, all of the borders and most of the surfaces of the mandible may be palpated. The maxillæ, with the malar bones, are almost equally accessible to the examining fingers. In seeking for obscure fractures, care should be taken not to increase the original damage in the effort to obtain crepitation. Gentle manipulation is all that is ever permissible, and is usually sufficient. Pressure applied at the angles will cause pain at a fracture, and such a hint should be sufficient.

The portion of the alveolar process may be broken from either jaw. Fractures of the maxillæ are usually impacted, and crepitus is rarely present. One maxilla may be broken loose, or there may be a complete transverse fracture through both bones, so that the upper jaw hangs from the cranial base only by the soft tissues. Fractures of the maxillæ may extend into the oral, orbital, or nasal cavities, or into the maxillary antrum, or may injure the superior maxillary nerve, the nasal duct, or

branches of the internal maxillary artery. Through its intimate associations with the nasal passage and accessory cavities, fractures of the maxilla may be followed by emphysema of the cellular tissues of the face.

With advancing age, as the teeth are lost, the alveolar processes are absorbed; when entirely gone, plates for artificial teeth are worn with difficulty. As their function is lost, the muscles of mastication atrophy, and with them the bone that serves for their attachment, so that the angle of the jaw appears to gradually open out and the body to lengthen. Loss of teeth and alveolar processes gives the peculiar shortening of the lower part of the face and the prominence of the chin often seen in old people.

The jaws may present deformity resulting from maldevelopment, necrosis, or malunion of fracture, and are subject to a variety of cysts and tumors.

Among the tumors of the upper jaw are fibroma, enchondroma, osteoma, myeloid sarcoma, round- or spindle-celled sarcoma, and cancer. The last is secondary, usually to cancer of the mucous membrane of the mouth or antrum. In the upper jaw, mucous cysts of the antrum and dental cysts are the varieties usually found. The lower jaw is subject to the same tumors as the upper, but myeloid sarcoma is much more common. The common cyst of the lower jaw is a dentigerous cyst, while fibrocystic tumors also hold this as their site of election. Actinomycosis is commonest in the neighborhood of the lower jaw, and both jaws may be involved in leontiasis ossea.

Fractures of the mandible are not impacted, and those of the body are usually compound, owing to the inelastic character of the muco-periosteum covering the gums. We have seen one impacted fracture of the mandible, but regard it as a surgical curiosity.

**Maxillary Antrum.**—The maxillary antrum is situated in the body of the maxilla. The upper wall of the antrum is the floor of the orbit, the inner wall is part of the outer wall of the nasal fossa, the outer wall is the facial surface of the maxillary bone, and the inferior wall is the base of the alveolar process. It communicates through a small opening in the hiatus semilunaris with the middle meatus of the nose. This opening is at the upper part of the antral cavity, and free fluid, usually pus, can drain through this opening only when the head is held downward or to the opposite side. The infraorbital nerve runs in the upper wall of the antrum, and its anterior and middle dental branches course downward in canals in the outer wall. The nasal duct, which conducts the tears from the lacrymal sack to the inferior meatus of the nose, runs through its inner wall. The apices of the roots of the molar teeth, of one or both of the bicuspid teeth, and sometimes of

the cuspid tooth, are in close relation with its floor and may extend up into the cavity. Malignant growths tend to infiltrate through the wall, while cysts and benign tumors may thin the wall and push it outward. Cysts may arise from the mucous glands of the interior, or may be the extension upward of dental cysts—rarely dentigerous cysts. The outer wall may become so thinned that digital pressure will cause a crackling, or fluctuation may be felt. Aspiration or puncture of the antrum is done through the inferior meatus of the nose, the canine fossa, or, when a suitable tooth has been recently extracted, through the alveolus. The antrum may be examined by palpation, transmitted light, x-ray, aspiration, and exploration. Infection from the roots of the teeth in relation to it may cause suppuration between the mucoperiosteal lining and the bony wall, may infect the mucous cavity directly, or may even cause infection of the orbit (Figs. 290, 300).

Tumors that arise in the antrum may grow in any direction. When inward, they obstruct the nose and the nasal duct; inward and backward, they obstruct the nasopharynx; upward, they infringe on the orbit, causing exophthalmus and neuralgia; outward, they cause swelling of the face, with neuralgia; and downward, cause downward arching of the palate, loosening of the teeth, and toothache.

### MUSCLES OF MASTICATION.

When tense, the masseter muscle can be distinctly felt, and often seen, on the outer surface of the ramus. The temporal muscle can be felt while chewing, and by pressing with the finger just above and in front of the ear. As mentioned, the anterior border of the internal pterygoid can be felt in the mouth, but the external pterygoid muscle cannot be palpated.

In tetanus the masticatory muscles are usually the first and most constantly involved, but spasm of these muscles may result from intra-oral irritations, especially those located over the distribution of the third division of the fifth nerve. The spasm may be clonic or tonic.

Paralysis of the muscles of mastication will follow any injury of the motor root of the fifth nerve, and commonly an operation on Gasserian ganglion or its root for facial neuralgia.

### SALIVARY GLANDS.

**Sublingual Gland.**—The sublingual gland, lying between the mylohyoid and the geniohyoglossus muscles, and covered by the mucous floor of the mouth, has already been noted. It has a number of ducts, and contains no lymph nodes.

**Parotid Gland.**—The parotid, the largest of the salivary glands, lies just in front of the ear, behind and overlapping the ramus of the

jaw and masseter muscle. When inflamed, it causes the swelling that is characteristic of mumps. The space in which the gland lies is increased when the head is held erect, with the mouth closed and the jaw thrust forward, and advantage should be taken of this while making an examination. It is impossible to feel the substance of the gland in the normal condition. It seems to be peculiarly liable to infection in some epidemic of typhoid fever, and may also become infected by local injury, or through its duct. The gland is incased in a dense fascia externally and below; but internally, at the upper part, the sheath is lacking, and the parotid space communicates with the deep connective tissue spaces of the pharynx. Retropharyngeal abscess may infect the gland, or pus from the gland may burrow into the space, into the temporal fossa, down into the neck, or into the external auditory canal; but it rarely points superficially. Virchow has reported cases of intracranial infection from parotid abscess along the branches of the fifth nerve.

The duct of the parotid gland, Stenson's duct, runs through the cheek a finger breadth below the zygoma to turn toward the mouth at the anterior border of the masseter muscle, where it can be distinctly felt when the muscle is made tense.

Besides the external carotid artery and external jugular vein, it contains the seventh nerve, the auriculotemporal branch of the fifth nerve, and filaments from the great auricular nerve of the cervical plexus. Facial paralysis or neuralgia of the temple or upper part of the anterior surface of the pinna may result from infection or tumors of the parotid gland. It also contains a number of lymphatic nodules, which receive their efferent vessels from the eyelids, eyebrows, root of the nose, upper part of the cheek, the frontal and temporal part of the scalp, the outer surface of the ear, the tympanum, and possibly from the mucous membrane of the nose, the posterior alveolar region of the superior maxilla, and the soft palate. Its afferent vessels pass into deep cervical nodes. Tumors of the parotid are usually of a peculiar variety known as salivary gland tumors. They arise from the body of the gland or detached nodules, most commonly in young adults, grow slowly or remain stationary for years, and then may take on rapid infiltrating growth. Some sarcomata of the parotid grow rapidly from the first.

**Submaxillary Gland.**—The submaxillary gland lies under the side of the jaw, in front of the angle, and is inclosed in a complete capsule. Part of the posterior end of the gland turns around the posterior border of the mylohyoid muscle and lies in the floor of the mouth, and it is from this part that the duct is given off. Unless there is too much subcutaneous fat, the normal gland can usually be palpated

by feeling in the floor of the mouth with one finger while the gland is pressed up from below with the other hand. The facial artery grooves its deep surface. While the vein crosses superficially, its sheath contains lymph nodes—usually only the superficial layer. These receive lymphatics from the lips, middle of the dorsum of the tongue, and the floor of the mouth, and are sometimes the secondary starting point of a fulminating infection in the neck—Ludwig's angina. Primary growths of the submaxillary are rarer than in the parotid, but stone in its duct, with secondary inflammation of the gland, is very much more common.

### LYMPH NODES.

The lymph nodes are always of interest. It is comparatively seldom that they are the seat of primary disease. Secondary enlargement, however, almost constantly follows infections of the areas which they guard, and they form the first barrier to infectious material that has escaped into their lymph streams.

The lymph nodes that concern the mouth and upper part of the pharynx are grouped as follows:

The lingual nodes lie between the geniohyoglossi muscles above the mylohyoid. They are small and rarely palpable.

The suprahyoid or submental lymph nodes are situated in the anterior part of the digastric triangle, below the chin and above the hyoid bone. They are apt to become enlarged in disease of the tip of the tongue, the midpart of the gums or floor of the mouth, the midpart of the lower lip or chin. They send their lymph partly into the submaxillary nodes and partly into a node situated on the anterior surface of the internal jugular vein, at the level of the cricoid cartilage. The infrahyoid nodes lie in front of the internal jugular vein, between it and the omohyoid muscle, just above the point where this muscle crosses the carotid sheath. They are supposed to drain the neighborhood of the frenum of the tongue.

The submaxillary group lies under the deep cervical fascia, just below the border of the mandible on each side. They are usually superficial to the submaxillary gland, but rarely one may lie beneath it. A large node is usually situated near the fascial artery. They receive streams from the side of the nose, the upper lip, the outer border of the lower lip, the anterior third of the lateral border of the tongue, the gums, the submaxillary and sublingual glands, and the adjacent parts of the floor of the mouth. They discharge into the upper deep cervical nodes, mostly into those in the neighborhood of the bifurcation of the common carotid artery.

The retropharyngeal glands lie behind the nasopharynx, and receive lymph from the nasal cavities and the accessory air sinuses, the

nasopharynx, Eustachian tube, and adjacent structures. Their efferent vessels run to the upper deep cervical glands. From their position they are rarely palpable.

There are a variable number of nodes situated along the course of the internal maxillary artery. These rarely, if ever, are palpable, and receive streams from the orbit, the zygomatic and temporal fossæ, the cerebral meninges, the nose and palate, and discharge into the upper deep cervical nodes.

There are a few nodes in the superficial fascia of the cheek, and also superficial to the parotid gland. They drain the superficial structures of the upper part of the face and ear, and empty into the superficial and deep cervical nodes. According to Cunningham, there may be present a lateral nasal node situated between the ala of the nose and the cheek. The deep parotid nodes were described with the parotid gland.

The superficial cervical nodes are upon or imbedded in the deep cervical fascia along the course of the external jugular vein. They drain from the superficial tissues of the neck and the superficial parotid and submaxillary nodes. The lymph streams from all of these are emptied into the deep cervical nodes, which are arranged in two groups. Those along the common carotid artery and internal jugular vein, which constitute the deep cervical group, lie under the sternomastoid muscle. The others, which are disposed in the posterior triangle of the neck behind the sternomastoid muscle, are called the supraclavicular group. They all finally empty their lymph streams into the general blood stream at the junction of the internal jugular and subclavicular veins.

While the above indicates the normal course of the lymph streams, all the vessels are connected, and when any group of glands and vessels becomes blocked with pathological material, the lymph will seek other and more roundabout courses, so that finally all the neighboring groups of nodes may become involved from a single primary lesion.

## CHAPTER II.

### INFLAMMATIONS, INFECTIONS, TUMORS, CYSTS.

We are more resistant to some infections than to others—as a rule to those that we are constantly carrying around with us. Our preservation from infection depends: first, on the fact that we are entirely enveloped in a resisting capsule composed of skin and mucous membrane; secondly, on a more or less perfectly acquired or inherited immunity, which, when efficient, will prevent the development of bacteria after they have gained access to our tissues. Sometimes infectious agents penetrate the skin or the mucous membrane by some inherent power they possess, and at other times they enter through open wounds.

One kind of infection having gained a foothold often serves to pave the way for the entrance of an infection of another variety. The opportunities for invasion are so numerous that, were it not for our natural or acquired immunities, and for the power that the tissues have for overcoming infections after they have gained a foothold, none of us would long survive. Both the immunity acquired or inherited, which prevents infection, and the resistance that overcomes infection after it has occurred are developed by a process that may be broadly termed inflammation.

#### INFLAMMATION.

Inflammation is the reaction exhibited by live tissues to irritation. The irritation may be mechanical, thermal, toxic, chemical, electric, etc., but to produce inflammation, the irritant must be directly or indirectly continuous in its action. After an irritation ceases to act, the process is simply one of repair. The inflammatory process and repair are very similar in many respects. We will consider that phase of inflammation that accompanies an infection. The changes that accompany and constitute inflammation are briefly as follows:

There is, first, a local dilatation of the blood vessels, with an increased supply of blood. Next follows a slowing of the blood current, with agglutination of the white cells to the walls of the vessels. There may be for a time an absolute stoppage of the blood current in some of the smaller vessels; accompanying this, there is a pouring out of plasma and white cells into the surrounding tissues. In very severe inflammations even the red cells may leave the vessels without an apparent rupture of the wall. At some time during this process there is a pro-



liferation of certain of the fixed tissue cells. If the process advances sufficiently far, there is an increase in the number of blood vessels. By this process, it will be understood, the tissues involved in the inflammation have increased blood supply and become crowded with plasma and wandering fixed cells, which form a resisting wall that mechanically helps to keep the invading infection localized.

Certain of the white cells that are poured out into the tissues in an inflammation have the power of devouring invading bacteria. This is another factor in overcoming infection, but the multiplying connective tissue cells are much more resistant to irritants than are the leucocytes derived from the blood. Blood plasma poured out in the presence of an inflammation has a much higher bactericidal power than has the normal blood. Even beyond all this, the effort to overcome an invading infection is seldom limited to a local inflammatory reaction. In the first place, in the presence of a septic infection, there is an increase in the absolute number and relative proportion of the polymorphonuclear white cells of the blood. Secondly, when bacteria or bacterial poisons are absorbed into the general circulation, there is a reaction on the part of certain widely distributed cells, by which is produced a specific antibody, which directly or indirectly, when effective, destroys infection and neutralizes the toxins. From this it will be seen that an inflammation, both in its local and general manifestation, is a process that has for its object the overcoming of infection.

The resistance to a specific infection is not immediately lost with the subsidence of the disease, but in many cases is permanently retained. Thus it is that such diseases as measles, whooping-cough, scarlet fever, and many others are seldom acquired more than once by the same individual. This acquired immunity may even be handed down as an inherited immunity. It is in this way that certain individuals are immune to certain diseases which they have never had. In other instances, and especially with certain diseases, the immunity is but short-lived. We see individuals who are subject to recurrent attacks of pneumonia, pus infections, erysipelas, etc.

**Symptoms of Inflammation.**—The classic symptoms of inflammation, handed down from the time of Hippocrates, are redness, heat, swelling, and pain. The redness and heat are due to the increased blood supply; the swelling, to the dilatation of the vessels and infiltration of the tissues with plasma and blood cells, and in some instances to the increase in the number of fixed tissue cells. Pain is not an essential symptom of all inflammations, but is rather constant in the acute stages. There are many subacute and chronic inflammations in which no pain occurs. Pain seems to be due, at least partially, to pressure; but it is well recognized that the passive congestion and edema that accompany

an inflammation, to a certain extent, allay pain. It is safe to state that the pain is in part caused by the irritant, and not wholly by the inflammation.

**Kinds of Inflammations.**—An inflammation may be acute, chronic, or subacute, but in all of its stages a rigid distinction should be made between the inflammation and the irritant that causes it. Until this is done, only confusion can result. Inflammation is essentially a protective process, closely allied to repair and body growth. A subacute or chronic inflammation means a continuously acting irritant, for, when the irritant is withdrawn and the resulting damage repaired, the inflammation subsides. Inflammation is essentially not an evil, but an evidence of vital resistance. It does not occur in dead tissue, and we occasionally see instances where inflammation fails to occur in tissues of very low vitality. Pus formation is but a way of ridding the body of the poisons it cannot neutralize.

An inflammation of any particular organ or structure is designated by the suffix "itis" or "ia," as gingivitis, peritonitis, glossitis, ophthalmia, and pneumonia.

Cellulitis is a term used to express a more or less diffused inflammation, dependent on bacterial infection, which travels along the cellular tissue planes, particularly those under the skin, though it may occur between muscles or in any part of the body. It may stop short of or extend to suppuration. Local cellulitis is a common phenomenon around any suppurating focus, and is often seen around a suppurating focus in the mouth.

Lymphangitis and adenitis refer to infections spreading in the lymph channels, and are evidenced by an inflammation along the course of the lymphatics and a swelling of the lymph nodes. An adenitis may attain any stage of inflammation from acute or chronic hyperplasia to suppuration. With certain infections, as the tubercle, the chronic hyperplasia may be followed by a kind of tissue necrosis known as caseation.

**Results of Inflammation.**—Besides the overcoming of the infection, certain more or less permanent results may accompany or follow an inflammation. As an inflammation subsides, the blood vessels contract, the normal circulation is restored, and the plasma and cells that have left the blood vessels are carried off in the lymph streams. If the inflammation goes to suppuration, quantities of serum, of white cells, and of fixed tissue cells are thrown off in the pus.

Any excess of connective tissue that has formed usually turns into scar. As scar tissue ages, it contracts, and it is this contraction of the interstitial scar tissue that impairs the function of the vital organs after they have been the site of a chronic inflammation.

In an interstitial nephritis, a cirrhosis of the liver, and a tabes dorsalis the parenchymatous cells of the kidney, or of the liver, or the axis cylinders of certain nerve tracts in the spinal column are squeezed until they can no longer perform their function. Scar formation may be long delayed, due possibly to the persistence of the inflammation in a subacute state. The surface epithelium may remain thickened or changed. In some instances masses of new connective cells will remain unchanged for indefinite periods. As an instance of this, we have the simple hyperplasia. The new tissue may become necrotic, and either liquefy or caseate, and it sometimes becomes impregnated with lime salts. We have examples of this in ulcerating gummata, or breaking-down or calcification of the tubercle. This fixed tissue cell proliferation is somewhat analogous to tumor formation, which consists chiefly in the localized growth of the cells of a certain tissue. Some of these localized growths we know to be caused by an infection, as, for example, granuloma resulting from infection with actinomycosis. These granulomata, tubercles, gummata, etc., which are known to be caused by an infection, are no longer classed as tumors. Just how many of the new growths that we now consider to be true tumors will be ultimately classed under inflammatory processes, it is impossible to foretell.

It might be argued that the interstitial scar deposits that follow some inflammations are positive evils, and that therefore the inflammation that caused this scar deposit is also an evil. It is, however, safer to conclude that the inflammation was a conservative process, and that the interstitial scar formation is a lesser evil than the condition that would have resulted if there had been no inflammatory reaction. An inflammatory granuloma is to be regarded as an effort to hold in check an infection which the tissues are unable to destroy. Whether the true tumors as we now regard them will eventually be placed in the same category, we do not know. It may be possible that even the malignant tumors, such as cancer, are but a vain inflammatory effort to overcome an infection. Even the fever that accompanies most infections is not to be regarded as an evil *per se*, but as a necessary part of the effort to overcome infection.

Without negating this view of inflammation, it is, however, probable in many instances that the inflammatory process is carried beyond the point where it accomplishes unmixed good. Just as a fireman may distribute more water than is needed to extinguish a fire, and thereby sometimes does more harm than the blaze, so there is no question that stagnation of blood and lymph in an inflamed area can be so great as to cause gangrene by pressure, and that the inflammation, and not the toxins, is often the immediate cause of the localized tissue death. If we grant that inflammation can cause tissue necrosis by pressure, we

will have also to grant that by a less degree of pressure the vitality of the tissues can be damaged to a less extent. It would seem, therefore, that an excessively active inflammation can produce evil results, and this idea is borne out by the extreme contradictions that are met with in clinical observations.

Gangrene is the death of tissue, with putrefaction. Necrosis is the simple death of tissue. It is for the reason that, bone being little changed by the organisms of putrefaction, the death of bone, even when due to sepsis, is spoken of as necrosis.

Ulcer is the defect that remains after a local surface destruction of tissue from bacterial invasion, from the breaking down of a tumor, or following a number of different inflammatory processes the cause of which we may not understand. Any open sore, whether it be the result of the bursting of a herpetic bleb; the breaking down of a carcinoma, of a gumma, or a tubercle; whether it be the granulating surface left after the separation of a superficial slough; an open sore due to the melting away of any of the surface tissues; or an open sore of almost any kind, excepting the acute stages following an injury—any of these may be spoken of as an ulcer. Naturally the varieties of ulcer are very numerous.

### INFECTIONS.

An infection is the invasion and growth of some kind of a minute organism, that feeds upon and poisons the living tissues. Agencies of infection, as we recognize them, are various, and include certain very low forms of life called bacteria, to which class belong: the pus-producing organisms, pneumococci, typhoid bacilli, etc.; certain plant cells, as yeast fungi and mycoses; and also some of the lower forms of animal life. These agencies of infection are widely distributed. With some of them we are in constant touch—for instance, those that are normally found in the mouth and in the intestines. With some other infections we rarely come in contact. As examples of the latter, we might mention the cholera bacillus, *Bacillus mallei* (which causes glanders), the leprosy bacillus, and *Bacillus pestis* (the cause of plague).

**Spread of Infections.**—If an infection fails to remain localized, it may spread in a number of ways. If there is not sufficient local resistance, infection may be disseminated along the neighboring cellular planes, or it may spread through the lymphatics, giving rise to lymphangitis. If septic inflammation spreads along the blood stream, the condition is known as pyemia or septicemia, according to its mode of transfer. If it is carried to distant parts of the body by means of small infected blood clots—septic emboli floating in the blood streams—the condition is known as pyemia. When such a clot lodges in a capillary, a new focus of infection may occur. At first this is most likely to hap-

pen in the capillaries of the lungs or liver, and it is for this reason that pneumonia may follow an infection of any part of the body, or liver abscess may follow an infection of the area of the portal circulation. Ultimately a pyemia may cause numerous localized infections in many parts of the body. If bacteria, or any other agencies of infection, float free in the blood stream in any quantity, not bound up in blood clots, the condition is known as a septicemia. The chief difference between this condition and that of a pyemia is that in the latter the clots containing the bacteria are bound to lodge in some small vessel, where a secondary focus is very likely to arise. Bacteria floating free in the blood have no protection from the germicidal action of the blood, and are more apt to be destroyed.

### SUPPURATION.

When the tissues are invaded by certain organisms, under certain conditions, suppuration results. Suppuration is characterized by the formation of fluid containing waste material, that has been sacrificed in the struggle against the invading organisms, together with dead and living microbes and their products.

It is preceded by changes in the circulation and fixed tissues, already described as being essential parts of inflammatory process, and is one of the ultimate manifestations of the struggle between the germs and the resisting power of the body. In dead tissue there is no inflammatory action, and in tissue of low resistance there may be no suppuration.

It was because, in the formation of certain kinds of pus, the older surgeons recognized a strong resistance on the part of the body which foretold ultimate recovery, that this pus was referred to as laudable pus. Practically, from a surgical standpoint, there can be no pus formation without the presence of bacteria of certain species. Still, pus can be produced experimentally by injecting certain irritating chemical substances. Certain organisms that do not really produce pus can cause a tissue necrosis that may liquefy or become semiliquid, but this is not true pus. The most common example of this is the caseation that may take place in the granulations that result from the presence of tubercle bacillus.

**Microorganisms of Suppuration.**—Some pus-forming organisms, such as the staphylococcus and *Streptococcus pyogenes*, will always tend to form pus. Often, however, owing to the lack of virulence or lack of sufficient numbers in proportion to the tissue resistance, the inflammatory process may be cut short before it reaches the stage of suppuration. Thus there may be a swelling of the gum and face around an infected tooth, but this may subside without the formation of pus.

Certain infectious organisms, such as the typhoid bacillus, will cause suppuration only under extraordinary circumstances.

The principal microorganisms of suppuration are *Staphylococcus pyogenes aureus* and *albus*, *Streptococcus pyogenes*, *Micrococcus gonorrhæa*, *Bacillus pyocyaneus*, and the pneumococcus. Among the organisms that less commonly cause suppuration are the typhoid bacillus, influenza bacillus, diphtheria bacillus, actinomyces, and various forms of the yeast fungi. Of the two more commonly present pyogenic bacteria, *Staphylococcus pyogenes* and *Streptococcus pyogenes*, the former is usually less virulent, and is more easily limited by the inflammatory reaction to the neighborhood in which the infection occurs. Therefore *Staphylococcus aureus* or *albus* is more commonly found in localized abscesses. The streptococcus seems to be less easily resisted by the inflammatory reaction, and has a greater faculty of becoming diffused. It is therefore more often the cause of rapidly spreading extensive infection, and as a rule, is much more destructive.

**Tissue Changes in Suppuration.**—The changes in the tissues that occur in suppuration are briefly as follows:

The changes already described as constituting the active stage of an inflammation always occur. The bacteria of suppuration seem to have the power of attracting from the blood vessels the polymorphonuclear white cells in great numbers, the greater demand for them being met by a greater production of them in the bone marrow. The fixed tissue cells are excited to greater proliferation, and there is a wall of cells thrown around and throughout the inflamed area, derived from the fixed tissue cells and from the leucocytes, that tends to localize the infection. It would appear that around the staphylococcus this wall is produced with comparative ease; but around the streptococcus it is not easily accomplished, and it is for this reason that one remains localized and the other so commonly becomes diffused.

Owing to the peptonizing power of certain bacteria, the tissues in the central part of the inflamed area become liquefied. As a result, there is a mixture of blood plasma, dissolved fixed tissues, leucocytes, newly formed cells, bacteria, and poisons, that is termed pus. An abscess is a circumscribed cavity of pathological origin containing pus.

A collection of pus in a closed anatomical cavity, such as the pleural cavity, is often spoken of as an empyema. If the infection becomes localized, the abscess which contains the pus is surrounded by a limiting wall of granulations. This wall confines the pus until it is either liberated spontaneously by some tract of exit formed by the action of the phagocytes, or it is liberated artificially by an incision. Less commonly the abscess remains permanently buried, or may even be absorbed after the death of the bacteria it contained.

## TREATMENT OF INFECTIONS AND INFLAMMATIONS.

After an infection has once gained a foothold in the living tissues, we must in our treatment regard not only the infection but the inflammatory processes that it has excited. We are not certain that the inflammatory process itself ever needs treatment, and we do know that there are very few, if any, infections that could ever be overcome without inflammation. Inflammation is nature's way of fighting infections, and we must work with it, not against it; for otherwise our efforts will be in vain.

There are a few infections that we can overcome by saturating the body with a poison that will not destroy the tissues. Among these may be mentioned malaria, which may be killed by quinin, and syphilis, which may be killed by mercury or salvarsan. When an infection is superficial, it may be influenced by locally applied antiseptics, such as alcohol, essential oils, iodoform, silver salts, etc. With a few isolated exceptions, however, treatment consists, at least in part, in promoting or regulating the inflammatory process.

One of the first requisites is the regulation of the body functions, especially the excretory organs. In the presence of an infection, the parenchymatous cells of various organs may become sluggish in their action and may require stimulation. The most common instance of this treatment is the administration of a purge and a stimulation of the skin by bathing. Next comes the establishment, as far as possible, of physiological rest of the affected part. Nature gives a strong hint in this regard in the pain that results from exercising an inflamed part. This rest should include the proper quota of sleep, and it may be necessary to administer an analgesic or a soporific. If the disease is at all prolonged, careful attention must be given to the nourishment of the patient. During this time the tissue waste is often greater than ordinary, and the ability to assimilate food is lessened; therefore food should be given in an easily digested form.

Prolonged high fever is very detrimental, but it is not proper to continuously give antipyretics to reduce it. Bathing reduces the fever, stimulates the secretions, and tends to quiet nervous irritation. It has been a routine custom to give alcoholic stimulants in septic infections, but except when the vital functions need stimulating, this practice is falling into disuse.

Another well-established therapeutic procedure is, where anatomically possible, to remove the infection by a surgical operation. If the infected part is no longer functional, this can be done by an excision—as the surgeon removes an inflamed appendix, and a dentist removes a tooth whose utility cannot be reestablished. In the presence of certain virulent infections, even more important organs may be sacrificed. The

tongue or the cervical lymph nodes may be removed on account of a tubercular infection, and an arm may be removed on account of a pus, gas bacillus, or other virulent infection that threatens life. A carbuncle may be totally excised, and any but the absolutely vital organs are sacrificed when carcinomatous. However, in many of our surgical operations for infection we are content with a less radical measure, which consists in draining the affected tissues by making one or several incisions. The tissue fluids are allowed to flow out of the wound, and with them great quantities of the infecting organisms and their toxins. This free drainage often gives the fighting tissues just the help they need, and enables them to overcome the infection that remains.

There are three therapeutic agencies, all of established value, and each contradictory to one of the others, which have to be mentioned, but the rationale of which we do not fully understand. These are heat, cold, and passive hyperemia. One of the oldest treatments for localized infection is heat. In general, it seems to promote comfort, allay pain, and promote the circulation. With septic infections it probably predisposes to suppuration, but in the presence of a septic infection of a certain virulency, local suppuration cannot be regarded as an evil. Local irritants—counterirritants, as they are sometimes called—act like heat, as they cause a deep as well as superficial dilatation of the blood vessels, with increased circulation. According to our ideas, an increased blood supply means increased resistance.

According to our present ideas, it is rather difficult to explain the good that undoubtedly results in many instances from the application of cold to an inflamed part. It cannot be from the direct action of the cold on the infecting organisms, for they are generally much too deep in the tissues to be influenced by a direct cooling effect. Cold, undoubtedly, causes a contraction of the blood vessels, a lessening of the inflammatory reaction, and tends to prevent suppuration and allay pain. There are certain animal experiments that demonstrate the fact that reducing the temperature of the tissues reduces their resistance. We might conclude that in all instances the inflammatory reaction is excessive, and that cold is beneficial by regulating it. Blood-letting was once popular, and in certain cases it undoubtedly accomplishes good. Whether this is by reducing the inflammation or by stimulating it, or by draining off poisons, or by a combined effort, is difficult to say. In apparent contradiction to this is the fact that induced hyperemia, commonly known as Bier's treatment, increases the inflammatory reaction, and is a strong agency in overcoming infections. Bier's hyperemia consists in the establishment of a temporary venous stasis, either by suction or by constricting the veins above the inflamed part. This is an augmentation of an essential part of the inflammatory process.



There are two other plans of treatment which have lately demanded considerable attention, and which in certain cases are giving great results. The first of these is the use of artificially produced antitoxins. When an animal overcomes a disease, it has circulating in its blood antibodies which give it an immunity to that disease. With some diseases this immunity is permanent. By the injection of gradually increased doses of toxins into a susceptible animal, it is immunized. When the blood of such an immunized animal is withdrawn and injected into a similarly infected individual, his resistance is immediately increased. The most brilliant example of this is the use of the diphtheria antitoxin. Unfortunately there are at present very few infections that can be treated in this way.

Another form of treatment, and one that promises to have a wider range of application, is the artificial stimulation of the production of antibodies within the infected individual. A localized infection may persist, or a person is overcome by an infection, not because the body cannot produce antitoxin, but because it does not do so, or because it does not do so until the infection has gained too great a headway before the antitoxin-producing reaction has taken place. As stated earlier in this chapter, the production of antitoxin is stimulated by the presence of toxins in the general circulation. As long as the infection remains localized, there may not be sufficient toxin in the general circulation to call up this reserve power, and when the infection becomes generalized, this may happen so rapidly that the cells have not time to form the antibodies before they are overcome and destroyed by the invading host. It has been found that, by injecting measured doses of killed bacteria of the same strain as the infection, all the antitoxin-producing cells of the body can be safely stimulated, so that they will evolve sufficient antitoxin to overcome an infection while it still remains localized.

## **METHOD OF PREPARING AND ADMINISTERING AUTOGENOUS VACCINES.**

BY DR. CHARLES L. KLENK.

In order to produce an immunity against certain conditions produced by certain bacteria, one method is the use of a substance commonly called a vaccine. These so-called vaccines are supplied in stock form by various biological laboratories. Preparations are made from a given organism of a certain strain or species, and used against all conditions, irrespective of the strain to which the organism belongs. These "stock" vaccines are in most instances of no value, because it has been definitely determined that, with perhaps the exception of certain strains of staphylococcus, in order to immunize an individual against a certain organism it is necessary to use one of the same strain.

This form of vaccine is called an autogenous vaccine. The autogenous vaccines commonly used are composed of dead bacteria obtained from cultures, taken from the individual to be immunized.

Immunity has also been produced by the injection of very small doses of living bacteria of full virulence, or those attenuated by prolonged cultivation *in vitro*, or those modified by heat.

The method of using dead bacteria has many advantages that the others do not possess. The dose is under accurate control—there is no danger of the spread of the infection, as might be the case if living bacteria were used—and the vaccine is easily kept for use without the danger of multiplication.

The method of preparing a vaccine is usually a simple matter. The chief difficulty is to insure the purity of the organism used and the absence of all other bacteria, especially the pathogenic varieties. If possible, a lesion should be selected that is recent and uncontaminated. For example, in case of an abscess the following is the procedure:

The skin should be carefully cleansed, and possibly seared with a hot instrument, to insure the destruction of all surface bacteria. With an absolutely sterile knife or needle an opening is made, and the exuding pus or fluid is immediately transferred to a suitable culture medium and incubated for at least twenty-four hours. The resulting growth is examined, and the organism identified. If a good culture is secured, the growth can be washed off the medium with sterile salt solution and put into a sterile tube. The number of bacteria to the cubic centimeter are determined preferably by Wright's method. A certain amount of the bacterial emulsion in salt solution is mixed with human blood in definite proportions, and smears are prepared over a strainer. The red cells and bacteria are counted, and the proportion of the two will permit of the calculation of the number of bacteria.

In conditions in which the organism is known, but other bacteria are present, it is necessary to get rid of this contamination. Cultures are usually made on Petri dishes, or other containers giving a large culture surface. The writer has used a form of container which has been very useful—an ordinary 4- or 6-ounce bottle, the so-called flat Philadelphia oval form. A small amount, about 10 cubic centimeters, of medium is put into the bottle, which is placed flat on its broad side. The medium is allowed to solidify, and a large, smooth, transparent surface is obtained. After these cultures are made, the entire growth is worked off with sterile salt solution. In some instances the exact organism is not known, several species being present which produce similar conditions. If such is the case, a vaccine may be prepared containing all these forms. This vaccine is known as "combined vaccine." After the growths have been examined and found to be pure, the dose

for injection is determined. The usual dose for adults is from 25,000,000 to 50,000,000 bacteria as an initial dose. The kind of organism, if a bacillus or a coccus, should be taken into consideration. The writer usually begins with 25,000,000 when bacilli are used, and 50,000,000 when cocci are used. Wright's method of counting may be used for this purpose.

The injection of these dead bacteria usually produces a reaction, both local and general—in most instances very mild in character. The local reaction is recognized by redness, slight swelling, and some pain; the general reaction, by some nausea, pains in the joint, a slight elevation of temperature, and perhaps a slight headache, all of which usually disappear in three to five days. This reaction usually occurs twelve to twenty-four hours after the injection. After this reaction subsides, about four or five days after the injection, a second dose is given. This dose is usually twice as large as the first, and is continued until the desired amount is obtained.

A much simpler method, and one which the writer recommends, is the determination of the dose by the injection of a very small amount of the vaccine, perhaps two or three drops, and if no reaction occurs, the dose is doubled for the next injection, and so on until a proper reaction is obtained. This is then used as a basis for determining the subsequent injections.

The form of vaccine in which the number of bacteria are known is called "standardized," while that in which the dosage is determined by the reaction is called "unstandardized." The writer secures a rich growth on a large surface in a 4-ounce flat medicine bottle, previously described, and washes off the bacteria, if cocci, in 10 cubic centimeters of sterile salt solution; if bacilli, in 20 cubic centimeters. The emulsion is transferred to a sterile bottle, and heated to a certain temperature in the water bath to insure the death of the bacteria. The temperature must not be too high, so as to injure their antibactericidal properties. The usual temperature is 60 to 80° C.

The streptococcus, pneumococcus, gonococcus, and colon bacillus can be killed at 60 to 65° C. in one hour. Some strains of staphylococcus will also be killed at this temperature. The writer has found certain strains of staphylococcus that require 80° C. for several hours to kill them. The best results have been with the staphylococcus, streptococcus, and pneumococcus. The colon has not given quite as good results for the reason that, as the writer believes, the colon bacillus does not commonly produce infections, being a normal inhabitant of the body, and accordingly the body establishes a natural immunity against it.

It has been found in many instances that, in conditions in which colon

bacilli were found, the symptoms were not due to them, but to other organisms also present, and vaccine made from these bacteria produce the desired immunity.

### TUMORS AND CYSTS.

The original meaning of the word tumor was swelling, but as it became known that many swellings were due to an inflammatory reaction or to some infection or injury, the word tumor was restricted to growths that were not known to be due purely to injury or to a recognized parasitic infection. As knowledge of pathology increased, certain enlargements that were formerly called tumors have, as their specific cause was discovered, from time to time been withdrawn from this classification and placed among the infectious diseases. It is probable that this process of elimination will continue indefinitely. The unmistakably inflammatory processes, such as pus infections, were early differentiated from tumors, but certain of the more chronic infections—among which are tubercle, actinomycosis, and syphilis—cause swellings that were often confounded with tumors. Even now it is sometimes difficult, clinically, to distinguish between them.

Tumors that contain fluid are called cysts. A cyst always possesses a definite wall of special tissue that has grown to accommodate its contents—not simply stretched. This eliminates from the class of cysts such accidental accumulations as pus or blood, and also the simple distention of the normal duct with fluid. For example, an abscess, hematoma, or a recent obstruction of Wharton's duct does not constitute a cyst; but a permanent obstruction of a sublingual duct, which is one form of ranula, is a true cyst. Fluid areas in a solid tumor may sometimes be spoken of as a cystic degeneration.

Tumors are often classified according to the tissue that predominates. Thus we have lipomata, that are composed mostly of fat; fibromata, composed of fibrous tissue; osteomata, composed of bone. An important clinical distinction is that between the malignant and non-malignant tumors.

**Benign Tumors.**—A non-malignant tumor is one that grows within a definite limiting capsule and does not invade the neighboring structures, though it may grow between them, pushing them before it, or cause them to atrophy by pressure. A benign tumor never spreads to some distant part of the body by something transmitted through the blood or lymph streams, as do malignant tumors.

**Malignant Tumors.**—Malignant tumors have no definite limiting capsule. As they grow, they tend to infiltrate neighboring tissues, the essential cells of the tumor growing directly into the neighboring tissues. Furthermore, malignant tumors disseminate to distant parts

of the body through the blood or the lymph streams. When wandering cells lodge at some distant site, they begin to grow, and there is a secondary tumor of the same character at this site. This process of distant infection is called metastasis, and by it the whole body may become permeated with the tumor. Tumors that tend to infiltrate neighboring tissues, but do not cause metastasis, are spoken of as being locally malignant. Myeloma is an example of this. At present malignant tumors are divided into three primary classes—sarcomata, endotheliomata, and carcinomata, or cancer.

**SARCOMA.**—Sarcoma is a term applied to all malignant tumors that arise from connective tissues—such as bone, muscle, or fascia—in contradistinction to those that arise from endothelial or epithelial cells. The metastasis of a sarcoma is usually through the blood stream and rarely through the lymphatics. Sarcomata are often classified according to the structures they represent. Thus we have osteo-, fibro-, and chondro-sarcomata, etc., when bone, fibrous tissue, and cartilage can be respectively recognized in the growth. When the cells fail to develop sufficiently to recognize the tissue from which they form, they are classified according to size and shape of the component cells, as round cell, spindle cell, and giant cell sarcomata.

**ENDOTHELIOMA.**—Endotheliomata arise from the endothelial cells of the blood vessels or serous cavities. The blood vessels and lymphatic tissues arise originally from the same germinal layer as does the connective tissue: the mesoblast. Endotheliomata somewhat closely resemble sarcomata, from which they have more recently been differentiated.

**CARCINOMA.**—Carcinoma, or cancer, is a growth of epithelium that breaks through the normal, limiting, basement membranes and invades the subepithelial tissues. This is the chief distinguishing feature between cancer and a benign papilloma or wart. The cells of the latter grow toward the surface, and never break through the limiting basement membrane. The metastasis of cancer takes place through the lymphatics, and it is for this reason that the regional lymph nodes always become infected with the growth. Carcinomata are classified mainly by the kind of epithelium from which they grow, those arising from the surface being squamous carcinomata, and those from glandular epithelium being adenocarcinomata. In the nose and accessory sinuses the normal ciliated epithelium may be replaced by squamous epithelium at the site of a developing carcinoma. Carcinomata are also classified as medullary and scirrhus, according to the softness or hardness of the growth.

The exact classification of some tumors is still a matter of question.

## CHAPTER III.

### PREPARATION OF THE HANDS, OPERATIVE FIELD, INSTRUMENTS, AND DRESSINGS.

The object of these preparations is to reduce to a minimum the amount of septic material that may be introduced into a wound. Surgery cannot be done under the circumstances that test tube experiments in the bacteriologic laboratory might lead one to deem essential, but fortunately for the practicability of our art and for the preservation of the race, there is a natural resistance on the part of the tissues that will usually overcome any moderate bacterial invasion.

We are often somewhat prone to forget what we owe to tissue resistance, crediting good results to some particular agent, when, as a matter of fact, we frequently do more harm than good by our activities. In observing the technic in vogue in any large clinic, where the operators have the best opportunities for clinical observations and laboratory diagnosis, one must be impressed with the simple methods and the tendency to discard antiseptics. Complicated methods are apt to miscarry, and to do more harm than good.

#### PREPARATION OF THE SURGEON'S HANDS.

All that is demanded for dental work and mouth examination is ordinary personal cleanliness, but the hands should be cleansed in the presence of the patient before each examination or operation. When bone or soft tissues are to be invaded, then what is regarded as surgical cleanliness is to be adopted. This differs from the former in degree—not kind. It is absolutely impossible to free the skin from all bacteria, but their number can be greatly reduced.

To clean the hands for an operation, the nails should be trimmed and cleaned, and dead cuticle and "hang nails" should be removed from the edges of the nails. A surgeon's nails should be kept cleaned with a brush, and not require the use of a scraper or "nail cleaner." The hands and forearms to above the elbows are scrubbed with a brush or wash cloth in hot water and soap for five minutes. It is customary to subsequently immerse them for a few minutes in some antiseptic solution. In the way this is ordinarily done, it makes little difference what is used if it causes no irritation of the skin. Ninety-five per cent alcohol used for five minutes will destroy most of the surface bacteria, and has several advantages over the aqueous antiseptic solutions. It is usually

non-irritating, and is a much more powerful germicide than are any of the solutions that can be habitually borne by the hands. It is very deliquescent, and quickly penetrates into wet crevices and pores. Various strengths have been advocated as being most efficient, but we use 95 per cent.

To remove all danger of transferring bacteria by the hands, the latter must be covered by rubber gloves, and the arms with sterile sleeves. If gloves are worn, they should be free from minute holes, and should be changed if punctured. The perspiration that collects within a glove is usually germ-laden. One of the most important points in the care of a surgeon's hands is to avoid irritation of the skin and exposing them to infectious material, such as pus.

### PREPARATION OF THE OPERATIVE FIELD.

Within the mouth little more can be done than the removal of gross sources of sepsis and repeated washing with a non-irritating fluid. Weak solutions of essential oils, iodine, permanganate of potassium, or certain other chemicals help to reduce the number of bacteria present, but their strength should not be sufficient to cause irritation. One of the most efficient antiseptic washes is a 50 per cent solution of alcohol. In the preparation of the skin of an operative field, it was formerly the custom to wash the skin several times with soap and water and alcohol or ether. This might be followed with various other antiseptics. Of late the simple method of painting the skin with a solution of iodine in alcohol has become rather popular. The rationale of the latter method is not supported by laboratory experiments, but in practice it has been found eminently satisfactory, and is less annoying to the patient than repeated prolonged scrubbing. Our custom is as follows: If hair is present, it is removed several hours before with soap and water and a sharp razor, or immediately before the operation with benzine and a razor. Dirt and scales of skin are removed with benzine. When the iodine preparation is used, the skin should be dry before being painted. Just before the operation, a 2½ per cent solution of iodine in alcohol is applied to the skin three times at ten-minute intervals. If the skin is dirty or scaly, it is first cleansed. If it is not convenient to make the three separate applications of the weaker solution, then U. S. P. tincture of 7 per cent iodine in alcohol is applied once freely, and as soon as dry, is removed with alcohol. If the full strength tincture is left on the skin, it is apt to blister. We are still uncertain whether the value of this mode of preparation is by virtue of the iodine, alcohol, or both. During "clean" operations, all skin is covered with sterile towels as soon as the incision is made.

### STERILIZATION OF INSTRUMENTS.

It is an almost universal custom to sterilize instruments by boiling them from ten to twenty minutes in plain water. At sea level, water boils at 100°C. or 212° F. This will kill nearly all pathogenic bacteria, but will not always kill spores. Certain staphylococci and the spores of anthrax and tetanus will resist boiling water for long periods, but it is probably very seldom that these are present. It is possible that some of the bacteria that we now consider harmless are not so, and that certain of the little understood chronic diseases are due to infections with organisms that we now consider non-pathogenic. It may therefore occur that the practice of partial sterilization will be discarded, and that some time in the future all instruments, dressings, etc., will be sterilized by steam or water at a higher temperature than 212° F. Boiling for twenty minutes is injurious to the edges of fine-cutting instruments, and these should always be sharp. It is therefore usually customary to resort to some form of chemical sterilization. One plan is to dip them in 95 per cent carbolic acid and then boil them for a minute. Another good plan is, after thoroughly cleansing them, to place the knives for fifteen minutes in 95 per cent alcohol. For chemical sterilization to be successful, the knives must be absolutely clean and free from finger marks. It is a good plan for dentists to sterilize their burs, forceps, etc., in the presence of the patients. This can be conveniently done immediately after using them, and it removes a doubt that is often present in the patient's mind.

Brushes, wooden-handled instruments, etc., may be sterilized in formaldehyde vapor, and cabinets for this purpose may be improvised or bought from supply houses. This sort of sterilization requires a number of hours, and is more often a matter of show than result.

### STERILIZATION OF RUBBER GLOVES.

These are boiled with the instruments, and should be thoroughly wet inside. Dry sterilization of gloves is not practical, as dry heat drives off the sulphur, and a glove will stand only three sterilizations in a steam chamber.

### STERILIZATION OF CLOTHS, DRESSINGS, ETC.

These may be boiled, but this is not convenient. They may be partially sterilized in steam under normal atmospheric pressure at sea level in twenty minutes. It is usually customary in hospitals to subject them to steam under fifteen pounds pressure for ten to fifteen minutes. This will give absolute sterilization. In sterilizing dressings, cloths, etc., it is essential that the steam penetrates, and for this reason they must not



be packed tightly. Steam, even under fifteen pounds pressure, will not easily sterilize tightly packed cloths.

Dry heat, such as a hot oven, will kill bacteria in from fifteen minutes to one hour, depending on the temperature, but dry heat does not penetrate as well as steam. Outside of hospitals it is usually more practical to buy dressings already prepared by reliable manufacturers.

### **STERILIZATION OF SUTURES.**

Silk, horsehair, silkworm gut, wire, etc., may be boiled or put in a pressure sterilizer. Catgut may be boiled in oil, ether, or alcohol, after all of the water has been removed in a dry oven. It is customary to buy catgut already prepared, but it can be done by anyone who will give it proper care.

## CHAPTER IV.

### HEMORRHAGE, SHOCK, AND ALLIED COMPLICATIONS.

While most of the complications that may follow surgical operations are preventable, they will nevertheless occasionally arise. When conditions are present that predispose to any of these complications, such conditions may usually be recognized in a careful preoperative examination, and be corrected by proper treatment.

#### HEMORRHAGE.

**Prevention of Hemorrhage.**—In surgical operations the unnecessary loss of blood is to be rigidly avoided, and the control of hemorrhage should always be considered in planning the technic. Wherever possible, vessels should be isolated and temporarily or permanently ligated before being cut, and every cut vessel that continues to give a flow sufficiently large to be recognized as an individual source of hemorrhage should be controlled.

The proper planning of incisions, and the controlling of the larger vessels before cutting them, constitute our most potent prophylactic measures. For operations on the face the control of one external carotid is not always sufficient, on account of the number and size of the anastomoses, especially if there is any arterial sclerosis. We have found that the plan of temporarily clamping both external carotids, or one external and the other common carotid, serves the purpose well. We believe that the common carotid should never be tied without absolute necessity, and both common carotids should not be clamped at the same time.

The position of the patient especially influences venous bleeding, which is greatest when the head is low, by sheer weight of the column of blood in the veins. If, to avoid aspiration of blood, the head is allowed to hang downward during an operation, this objectionable feature may be somewhat ameliorated by having the table in such a position that the trunk and limbs slope slightly downward—the reverse Trendelenburg position.

The sequestration of blood, after the manner proposed by Dawbarn, holds a certain amount in reserve, and we have resorted to it when free hemorrhage is anticipated. It is accomplished by fastening elastic bands around the extremities, close to the trunk, at such tension that the venous, but not the arterial, flow is retarded. This causes the

veins and capillaries to become engorged. Later, when the bleeding is controlled, this reserve is liberated.

If, for any reason, it is suspected that the clotting power of the blood is below normal, the clotting time should be ascertained, and if sluggish, an attempt should be made to remedy the defect. It is our practice to obtain some idea of the clotting time in all cases of elective operations. One very simple, yet practical, way of doing this is to obtain a drop of blood, about 8 or 10 millimeters in diameter, on a clean glass slide. In obtaining the blood, the end of a finger or the lobe of an ear is stuck with a cutting needle. The blood must flow without squeezing the part, as squeezing lessens the clotting time. The point of a clean needle is passed through a new place on the edge of the drop every minute until a distinct string of fibrin can be made to adhere to the needle, which occurs just a little before the true clot is formed. This method is sufficiently accurate for practical purposes. A more exact way is to draw the blood up into a freshly made capillary tube 1 or  $\frac{1}{2}$  millimeters on its inside diameter. A short section of the tube is broken off each minute, or a part of the blood is blown out of the tube at minute intervals. As soon as the clot forms, the fibrin is seen stretching between the separate tube ends, or it can no longer be expelled by blowing. Still more exact methods are employed in physiological laboratories. A deficiency in clotting power may be natural or acquired. The formation of the clot depends on the presence of three elements—thrombogen, thrombokinase (both supplied by the blood or the tissues with which the blood comes in contact), and calcium ions (also normally present in sufficient quantity).

Were calcium the element lacking, it could be easily supplied. It has been our experience and that of Dr. Sluder, who uses calcium lactate as a routine practice before tonsil and adenoid operations in children, that calcium lactate will lessen the clotting time in almost all cases. Between 1 and 4 grams are given daily for several days before the operation when the natural clotting time is over four minutes. It is not unusual for the clotting time to be reduced by this from as high as seven down to three minutes or less. We have seen even more striking reductions. Judging from the general tone of the literature, our experience with calcium lactate has been more fortunate than has been that of some others. Lack of calcium is not always where the fault lies, and for this reason various other therapeutic agents have been proposed. The repeated intravenous injection of a 2 per cent solution of gelatin, in normal saline, has been supposed to be helpful, but our personal experience with this method does not support this.

In the review of all the literature, Wirth states that gelatin, calcium, and ovarian and other organotherapy have been disappointing, but that

Weil's method of subcutaneous or intravenous injection of fresh animal serum is far better. Thirty cubic centimeters of a freshly made serum from an animal should be injected subcutaneously. Where conveniences for preparing fresh serum are not at hand, an antitoxic serum has been used, but it is not as good as the fresh serum. Good results have sometimes been obtained from the local application of a foreign serum or blood to the wound.

Morawitz has proposed defibrinated blood transfusion as a styptic and reports good results. But in these cases improvement did not show until after forty-eight hours. Holt recommends this highly. We have had excellent results from direct blood transfusion. General hygiene, tonic medication, and feeding should not be overlooked.

The lack of clotting may be due to an increased percentage of salts in solution, as the presence of bile salts, or to certain diseases or poisons, as sepsis, scurvy, hemophilia, or purpura. When possible, the causes of these conditions should be treated; or, by serum injections or by direct transfusion, a blood that will clot should be obtained before an operation is undertaken. The clotting time in the individual may vary from time to time. When reduced by the administration of calcium, we have noticed that it begins to rise again within a few days after the drug is withdrawn. As hemorrhage continues, the clotting time decreases. We have learned from clinical observations that in the same patients the clotting time may change from time to time without apparent cause.

**Control of Hemorrhage.**—Hemorrhage is designated as arterial, venous, or capillary, according to its source, but as a matter of fact in almost every instance it is a combination of all three, with one predominating. To intelligently treat bleeding, one must understand and work in harmony with the natural hemostatics, without the existence of which all the surgeon's efforts would be futile. These are the retraction and contraction of the cut vessel, the lowering of the blood pressure by diminution of the strength of the heart's action and of the arterial tone, and most important of all, the clotting of the blood. The clotting is facilitated by the retraction and contraction of the vessels and by the lowered blood pressure.

Arterial bleeding is usually controlled by digital pressure, forceps pressure, torsion or ligation of the bleeding ends, or by ligation of the vessel and tissues *en masse* by means of deep sutures. Bleeding from the vessels situated in bony canals, such as the inferior dental or posterior palatine, may be controlled by inserting a peg, or pieces of muscle, or connective tissue, into the canal, or by occluding it by pressing in a soft piece of wax. The formula of Horsley, carbolic acid, 1 part; olive oil, 2 parts; white wax, 7 parts, is very serviceable. The wax is

sterilized by heat, and while still liquid is floated out on cold sterile water. Pieces of the congealed wax may be forced into the bone spaces and canals. When the bleeding point cannot be attacked directly, the outflow can be lessened and clotting favored by tying the artery any place proximal to the bleeding point. Where an artery has few and small anastomoses, such as the lingual, this plan is very effectual.

Ligatures, whether of silk or catgut, should be drawn just tight enough to close the lumen of the vessel and to prevent slipping. They should not cut any of the coats, which would predispose to secondary hemorrhage. If there is not a sufficient amount of the vessel exposed to insure the ligature against slipping, the strand should be engaged in the tissues by means of a needle. The vessels should be tied with a square knot, and the forceps should be released just as the first tie of the knot is drawn tight. Except on large vessels, as a cut lingual, only catgut ties should be used in closed wounds of doubtful asepsis. Silk may be used in open wounds and in aseptic closed wounds.

In wounds of any depth, especially if the vessels cut are not too large, the bleeding may be controlled by a temporary packing with gauze. If this is done aseptically, the wound may on the second, third, or fourth day be closed by secondary sutures, which might have been put in at the time the packing was placed. If the wound is not sufficiently deep to maintain the packing, it may be fixed in place with sutures, the pressure of a bandage, or, in some parts of the mouth, by fastening the lower to the upper jaw by ligating the teeth, or less effectually by a Barton bandage.

One of the most effectual and convenient ways of controlling the bleeding in most wounds in the face, mouth, and scalp is by the use of deep approximation sutures, which should be drawn just sufficiently tight to accurately approximate the cut surfaces. Unless there is a grave fault in the clotting power, this will be sufficient. Greater tension will cause necrosis and risk of sepsis along the suture tracts.

Bleeding veins had best be tied, but a light pressure will control the flow. When there is any question of the collateral circulation, a longitudinal wound in a large vein, such as the internal jugular, may be stitched with a fine catgut or silk, or even patched by slitting a tributary or neighboring vein and sewing it in to the defect.

Torsion, tying, packing, and plugging replace or supplement the natural contraction of the vessels and clotting of the blood, while the ligation of an artery at a distance lessens the local blood pressure.

In average individuals the bleeding from capillaries and small vessels needs no treatment. Continued capillary oozing is almost always due to slow clot formation, and may be treated by lowering the blood

pressure and increasing the clotting time, and also by the local application of styptics, pressure, and means that stimulate the contraction of the local vessels. The direct application of the extract or powder of suprarenal bodies, preferably in the form of the alkaloid—as the 1:1000 solution of adrenalin chlorid, for example—causes a contraction that will often control the bleeding from small vessels until the clot has had time to form. The application of cold, usually in the form of ice or cold water—either directly to the bleeding area or, where this is not practical, to some related area—also lessens the caliber of the vessels, and is therefore helpful. Hot water will cause a contraction and also hastens clotting.

On account of the association of vasomotor reflexes, the application of cold to certain regions will cause a contraction in other anatomically remote areas. The immersion of one hand in cold water will in this way lessen the temperature of the other hand. The application of an ice bag over an inflamed appendix will lessen the hyperemia of the organ, and, what is more applicable to our subject, the application of ice to the back of the neck will cause a contraction of all of the vessels of the head, including those of the nose and mouth. Cold is very efficient in moderating and controlling the bleeding from subcutaneous injuries, thus limiting the size and extent of ecchymosis and hematoma.

For persistent bleeding following the extraction of one or more teeth, the sockets should be packed with antiseptic gauze or cotton. The selvage of the gauze is convenient for this purpose. If this does not control the bleeding, two to four thicknesses of the gauze are laid smoothly over the surface of the packing and the adjacent gums, and the whole is covered with soft modeling compound or quick-setting plaster of Paris. The modeling compound (a hard wax that softens in hot water and is used by dentists for taking impressions in the mouth), or impression plaster, should embrace the gauze-covered gum, and be of sufficient bulk to be in contact with the opposing gums or the teeth when the jaws are in contact. Before the wax or plaster is quite hard, the jaws are closed firmly and held in this position. The enveloping wax or plaster now holds the gauze in a position under slight pressure. If there are any occluding teeth in the upper and lower jaws, the fixation is best done by wiring the lower to the upper jaw, with or without bands (page 96). If there are no teeth to which to wire, then a chin bandage must be depended upon, or resort may be had to a modified Kingsley splint (page 87) to hold the gauze in place. Measures should also be instituted to increase the clotting of the blood.

Delayed clotting may be locally treated by applying foreign serum or blood (Prevention of Hemorrhage, page 46), or certain coagulents,

such as alcohol, boiling water, chemical styptics, or the actual cautery. But any application that produces a slough or favors sepsis may be only temporarily effective; for, as the slough separates, or the extravascular clots are liquefied, unless there is an intravascular clot in the intact part of the vessels, the bleeding will recommence. Boiling water, instantaneously applied, alcohol, or a saturated solution of anti-pyrin, or an antiseptic gauze pack, are probably the best local styptics. The actual cautery is useful to touch a bleeding point, but it is hardly applicable to the surface. Gauze packing may be impregnated with a 5 per cent solution of collargolum, or colloidal silver in water. We have found that this is non-irritating and antiseptic.

The presence of a large extravascular clot may favor the persistence of bleeding. One is sometimes surprised, on cleaning the clots out of a bleeding wound, to find that the flow rapidly diminishes and ceases.

After hemorrhage has persisted for a certain time, the blood pressure continuously falls. The general, and with it the local, blood pressure is lowered by laying the patient in the recumbent position, insuring quiet with sedatives, and not resorting to stimulants. This is an imitation of the faint that often accompanies severe hemorrhage. To raise up or stimulate a patient who has fainted from the loss of blood is but to invite an increase of the bleeding. Certain drugs, such as the nitrates, will lower the blood pressure, but their employment has seldom been advocated. Morphin, though a stimulant, is most valuable in quieting both the mind and body. The use of vasoconstrictor drugs as styptic, that cause a general contraction of the blood vessels, is on physiological grounds to be unqualifiedly condemned. Vasoconstrictors cause an elevation of blood pressure, which will outweigh the benefit derived from the relatively slight contraction of the blood vessels that occur at one point. The value of ergot in uterine hemorrhage is not due to its general action, but to its selective action on the uterine muscle.

In bleeding of moderate severity, resort may be had to an expedient proposed in a German clinic. This consists in keeping the patient in the erect or sitting posture until he faints and then laying him flat. By this means syncope must come earlier, and with less loss of blood than in the prone position. As bleeding continues, the clotting time continually decreases until one half the total quantity of the blood is lost. This is possibly the reason why, in many instances, apparently hopeless bleeding finally ceases before causing death.

**POSTOPERATIVE HEMORRHAGE.**—Primary hemorrhage should be controlled at the time of the operation or injury. If this has been properly done, postoperative bleeding, which is due to the slipping of ligatures or the expulsion of intravascular clots on restoration of normal blood pressure, will seldom occur. If it is due to the slipping

of a ligature or the expulsion of a clot from a larger vessel, it is usually best to catch, and either re-tie it, or simply leave the forceps in place. Often the bleeding can be controlled by removing clots, readjusting the packing, maintaining the recumbent position, quieting the patient with a little morphin, and the avoidance of any pernicious surgical activity. As stated before, the patient may be made to sit up until he faints and then laid flat.

**SECONDARY HEMORRHAGE.**—This usually occurs some days after the operation or injury. It may follow suppuration or the separation of the sloughs, and presents a special difficulty, inasmuch as the vessels involved may be very friable or held in a dense inflammatory mass. It is best treated by cleaning out the wound with antiseptics, cutting instruments, or a cautery at a dull red heat, and the use of any other previously mentioned means that circumstances dictate. If a pack is applied, it must retard, not favor, sepsis. The actual cautery is dangerous in the neighborhood of large vessels. An artery can be ligated at a distance to control bleeding from its trunk or any of its branches.

The efficiency of this latter procedure varies inversely with the size and number of the anastomoses distal to the ligature, because the collateral circulation will be proportionally active. Ligation of the lingual artery will effectually control bleeding from one half of the tongue. ligation of one external carotid has little effect, and ligation of the individual branches will vary in efficiency according to the size and number of their communications. The ligation of the internal maxillary artery is too difficult to be practicable, but after tying the external carotid above the occipital artery, the temporal can be tied above the origin of the internal maxillary, which will leave only the transverse facial, the posterior auricular, and some parotid branches uncontrolled.

A patient suffering from loss of blood first feels faint, and possibly nauseated; if the erect position is maintained, he may fall. With moderately slow progressive hemorrhage there is thirst and restlessness; there is an increasingly rapid and weak pulse, with a continuous fall of blood pressure; the skin is often moist and clammy, and both the skin and mucous membrane become pale. Eventually there is air hunger. The condition closely resembles the restless form of shock, from which it is often difficult to distinguish when the bleeding does not show on the surface.

**Treatment of the Effects of Hemorrhage.**—With rare exceptions, according to our experience and opinion, neither stimulants nor transfusion, nor any other method of raising blood pressure, should be employed before the bleeding is at least temporarily controlled. If the condition of the patient seems critical, quiet should be insured, if nec-



essary, with a little morphin given hypodermatically. The head should be on or below the level of the body; the limbs may be elevated, or even bandaged, to keep as much of the blood as possible circulating between the heart, the lungs, and the vital centers; the body should be kept warm by blankets and artificial heat. Hot-water bottles placed around an unconscious or semiconscious person should be at a temperature of 115° F., and no higher, for otherwise the patient may be seriously burned.

Once the loss of blood is controlled after a severe hemorrhage, the vessels should be filled with normal saline solution at a temperature of 104° F. to 110° F. Fatal hemorrhages can occur through loss of fluid when there are still enough blood cells and plasma in the vessels and tissues to comfortably carry on function, if they could but circulate. A level teaspoonful of salt to a pint of water, boiled and cooled to 110° F., by setting the vessel in a pan of cool water, is a practical way of preparing the saline solution. It should be introduced either directly into a vein, under the skin, or into the rectum at a temperature of 100° F. For want of a special reservoir, a sterilized fountain douche bag is usually accessible and is very effective. It is difficult to accurately gauge the amount of fluid that is slowly running from a rubber douche bag, but if the bag is hung on the ordinary spring balance scale that is usually found in every house, the flow can be gauged with some accuracy.

### SALINE TRANSFUSION.

**Intravenous Transfusion.**—To introduce saline directly into a vein, the cephalic, median cephalic, or median basilic are the veins usually selected, but any vein of sufficient size in either extremity will answer. Sometimes the long saphenous vein in front of the internal malleus is more accessible than are those of the upper extremity. The vein may be tied after being exposed under a local anesthetic, the ends of the ligature remaining long. A V-shaped or longitudinal slit is made in the vein, just proximal to the ligature, and the point of a glass eye-dropper attached to the douche tube is slipped into the vein. A simpler method is to attach a fair-sized hypodermic needle to the douche tube and insert the point directly in the vein without incising the skin. This is sometimes very difficult to do.

It is needless to state that these operations should be done aseptically. If necessary, a vein can be made prominent by throwing a bandage around the upper part of the limb. The compression bandage must be removed before allowing the saline to flow. Fluid should not be put directly into the vein at a greater rapidity than 500 cubic centimeters in ten minutes, and the flow should be withheld on any signs

of cardiac embarrassment. In either method, the second sound is a good index to the heart's condition. The air and cold water should be expressed from the tube and needle just before inserting by holding the needle with a little less than one half of the tubing pointing toward the ceiling, and allowing the water to flow until it comes warm from the needle unmixed with air. Air that remains in the tube after this will not be carried into the vein.

**Hypodermoclysis.**—Saline may be put into the subcutaneous tissue of the chest, abdomen, or thighs by means of a hollow needle and gravity. This method is more painful than intravenous transfusion, but it is safer and usually sufficiently rapid. Absorption from the subcutaneous tissues is hastened by massage and kneading of the induration.

**Proctoclysis.**—If the rectum is loaded with feces, this may have to be removed with an enema. If a large quantity of water is thrown into the rectum, it may start peristalsis and be expelled. If the saline solution is allowed to trickle in, its absorption is more certain. Ordinarily it should not be allowed to flow much more rapidly than it can be absorbed—one or two drops a second. This latter method was first proposed by J. B. Murphy. Of the various methods of introducing saline into the circulation, proctoclysis is the freest from danger, and the one most commonly employed.

Water flowing slowly into the rectum, or into the subcutaneous connective tissue, cools rapidly in the tube. There are special devices for maintaining the proper temperature, a very efficient one having been devised by O. Elbrecht, but these are not always at hand. For intravenous and subcutaneous transfusions, if it is found necessary, several coils of the douche tube may rest in a basin of water, or be wound around a hot-water bottle maintained at the proper temperature, and held very close to the patient. For slow rectal injections, the douche bag is held very little above the level of the bed, and all of the tube can be under the bed clothes and thus kept warm.

If, after transfusion, or any other method of introducing fluid into the circulation, there is profuse sweating, it should be controlled with moderate doses of atropin. Even where this is due to shock, the atropin often seems helpful. It is a serious question to our mind as to whether other internal stimulants than filling the vessels and the use of a little morphin are ever indicated in the treatment of hemorrhage.

When a transfusion is done with saline, the blood is diluted, which may increase the clotting time. If it has not already been controlled, it will be more difficult to accomplish this after than before the saline transfusion, on account of both increased blood pressure and decreased clotting power. If repeated hemorrhage and saline transfusions alter-

nate several times, a blood of very poor clotting power will result. When not satisfied that the source of the bleeding is permanently controlled, the transfusion should be with blood.

### BLOOD TRANSFUSION.

Direct blood transfusion is done by connecting a blood vessel of a donor, who is free from transmissible taint, to a vein of the patient in such a way that the blood passes from the donor to the patient. One method of doing this is to unite the radial artery of the donor to the cephalic vein of the recipient in such a way that the blood in its passage comes in contact only with the endothelial lining of the vessels. The radial artery and cephalic vein are selected simply for convenience. This is usually done by means of a cannula, first devised by Payr, and of which various modifications have been made. The operation is done under a local anesthetic. The clinical symptoms evinced by the donor and donee should determine the length of the operation. A strong, full-blooded donor in the recumbent position will probably lose 500 to 800 cubic centimeters of blood before showing marked symptoms. A dog may bleed to the last drop and be perfectly restored by this method. This operation, while apparently simple, is not apt to be conducted smoothly by one who has never performed it. Even in the hands of one more or less expert, it is not always successful. The two people to be operated upon should be placed in the proper juxtaposition, and sufficient of each vessel should be freed. The arteriovenous operation has two serious difficulties inherent to it—one, the lesser, is that an artery has to be freed, and the other is that the cannulæ are very minute, somewhat difficult to handle, and give very little room for the blood stream. It is for these reasons that we look on the method devised by Dorrance and Ginsburg as superior, which consists in uniting the distal end of a vein of the donor to the proximal end of the recipient's vein.

**Vein-to-Vein Transfusion of Dorrance and Ginsburg.**—Sufficient blood pressure can always be obtained by encircling the limb of the donor, above the site of the operation, with an elastic band, that constricts the veins, but not the arteries. The Sweet cannula used for this purpose is much larger, and it is much easier to turn a vein back over the flange than an artery (Fig. 9).

**Selection and Preparation of the Donor.**—The donor should, if possible, be one of the same family, moderately young, and free from any organic disease of the heart, etc. The arm of the donor should be constricted just below the axilla by a tourniquet sufficiently tight to distend the superficial veins, but not to obstruct the arterial flow. The

preparation of the recipient will consist in the dilatation of the veins and the sterilization of the arm.

**Technic of Vein-to-Vein Transfusion.**—An incision about three inches in length, following the course of the vein, will usually be sufficient. Until it is made certain that there is a vein of sufficient size present, only a short exploratory incision should be made. The cephalic vein is not infrequently absent. In one case, when the cephalic vein was absent in both donor and recipient, sister and brother, we united the two basilics. This presented some difficulty. After exposure of the vein in the donor, a bulldog clamp is applied to this vessel at the lower angle of the wound, and the vein is grasped at the upper angle by a hemostat. The vessel is next divided immediately below the hemostatic forceps. A small, round, pointed needle, threaded with fine silk, is passed through the end of the vein, to assist in thread-

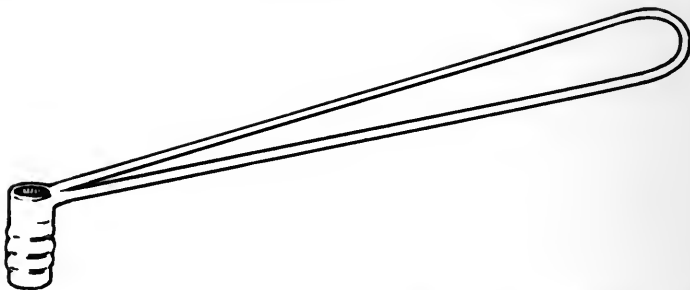


Fig. 9. Sweet's cannula for vein-to-vein transfusion. (Natural size.) The cannula can be obtained in different sizes, the one shown being of an intermediate size.

ing the cannula upon the vein. The upper proximal end of the vein in the grasp of the hemostat is ligated, and the hemostat is removed. The open distal end of the vein which has been passed through the cannula is grasped by three mosquito hemostats, applied equal distances apart. When traction is made upon the hemostats, the lumen of the vein assumes a triangular shape. A hemostat should now be introduced into the vein, and the cannula is pushed up against the hemostat to prevent the vein from retracting (Fig. 10). The protruding end of the vein should be drawn down or everted over the cannula, forming a cuff, by gentle traction on the hemostats (Fig. 11). A ligature is tied around the everted portion of the vein covering the cannula, and the hemostats are removed. The distal end of the vein of the donor has now been prepared for insertion into the proximal end of the vein of the recipient. Exposure of both veins should be made simultaneously, and as soon as the cannula is fixed in the vein of the donor, the next step in the operation should be the juncture of the two veins. Since the blood current is to be directed toward the heart of

the recipient, the vein in this subject is divided below, and its distal end ligated. The proximal portion of the vein is compressed by a clamp at the upper end of the wound, and the free end is drawn over and ligated to the cannula previously applied to the vein of the donor. All forceps are released (Fig. 12.)

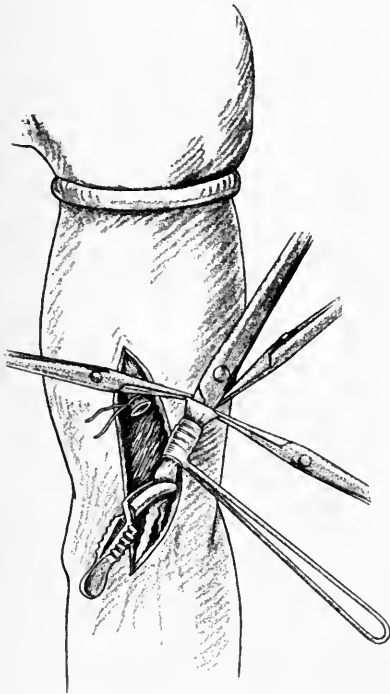


Fig. 10.

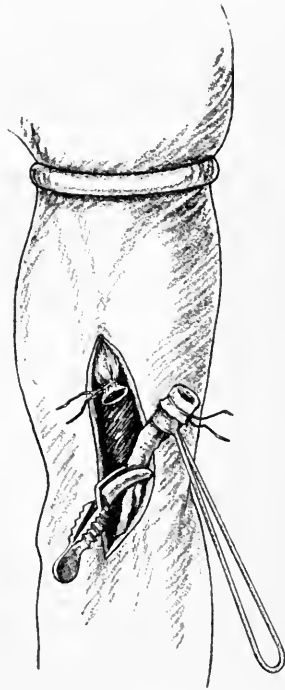


Fig. 11.

Fig. 10. Vein-to-vein transfusion, after Dorrance and Ginsburg. Arm of donor constricted with rubber band. Cephalic vein exposed. Distal part temporarily clamped with bulldog forceps. Vein drawn through cannula and held by pushing the jaws of a pointed forceps into the vein until its walls are compressed between the forceps and the cannula.

Fig. 11. Vein-to-vein transfusion, after Dorrance and Ginsburg. Cuff of the vein of the donor turned back and tied over cannula.

The clamps on the vein of the recipient and donor should be removed, and the blood allowed to flow. The tourniquet should be removed from the arm of the recipient, and that on the arm of the donor should be slightly loosened. If the veins in the arm of the recipient are very small, it may be necessary to employ the internal saphenous vein of the thigh.

Hartwell has devised a means of transfusing without a cannula. The vein is held open by retention sutures, and after the cut end of the artery is greased with petrolatum, it is passed into the vein, the two vessels being held by a loose ligature. In this operation the blood

stream comes in contact with cut tissues that are protected only by the petrolatum. He has done this numerous times on animals without observing any intravascular clot. The vessels can also be united by direct suture.

Direct blood transfusion is not absolutely free from danger. Pepper reports a fatal hemolysis following the second direct transfusion on the same patient with two different donors. Rehling and Weil conclude

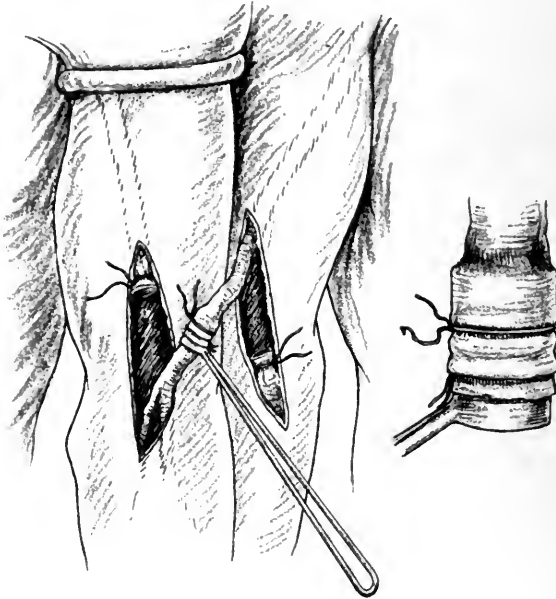


Fig. 12. Vein-to-vein transfusion, after Dorrance and Ginsburg. Proximal end of the cephalic vein of the recipient slipped over and ligated upon the everted cuff of the cephalic vein of the donor.

that test reactions appear to afford reliable data as to the possibility of hemolysis.<sup>1</sup>

### SHOCK.

It is easier to prevent than to effectually treat shock. Fear, loss of blood, rough handling of richly innervated tissues and nerve trunks, chilling of the surface, and prolonged operations are all conducive to shock. It is difficult to estimate the resistance of the individual, and therefore the energies should always be conserved. Old people, with high blood pressure, stand the loss of blood poorly, and the supervening shock comes suddenly. Shock is accompanied by a fall of blood pressure; in fact, the latter may be taken as an indication of the degree of the shock. Except in cases of advanced arteriosclerosis, in cases of

<sup>1</sup> See taking experiment in any manual of physiology.

increased intracranial pressure, and in cases where the shock is produced by a sudden injury—as cutting large nerve trunks or chiseling on the skull—the stage of severe shock is usually preceded by a somewhat gradual loss of pressure. Therefore, in all operations in which shock might develop, it is a wise precaution to keep track of the blood pressure by palpation of an artery, or, more accurately, by frequent readings from a sphygmomanometer.

One of the most concise descriptions of shock has been given by Moullin:

Two varieties of shock are described—the one characterized by extreme depression, the other, which is much more rare, by great excitement. Upon what the difference depends, why one form should occur and not the other, is not known.

In the ordinary form the patient lies perfectly quiet, with the eyelids half closed and the limbs in the position that chance may have placed them; conscious, but paying no attention to anything around; able to speak feebly and slowly, but entirely incapable of any mental effort. The face has lost all expression; the skin is cold, pale, and clammy, that on the forehead often being covered with perspiration; the pulse is frequent, generally more or less irregular, the artery seeming to collapse and empty itself with each beat; the respiration is shallow, and the temperature far below normal—sometimes as much as three or four degrees. The sphincter ani is usually relaxed; urine, if the bladder is full at the time of the accident, is retained, but afterward for many hours the secretion stops almost altogether.

In the worst cases, such as are almost certain to prove fatal, there is complete absence of the sense of pain. The writer has many times seen patients dreamily looking on, without a sign of intelligence, while broken fragments of bone were being removed and search made for bleeding arteries in limbs that had been crushed in a railway accident.

Vomiting is of frequent occurrence; in head injuries it not uncommonly marks the onset of reaction. In a few moments the face becomes flushed, and the pulse regains its vigor and fullness. In other cases it may either occur at the commencement, when it is comparatively of little significance, or later, after a few hours, and then it not uncommonly marks the beginning of the end.

Shock may be almost instantaneously fatal. The author has known death to occur within five minutes from puncturing a small hydatid cyst in the liver, or it may begin more gradually and slowly become worse and worse until death ends the scene.

The other variety, that which is characterized by furious excitement, is more uncommon. Its onset is nearly always gradual; at the first there is some ground for hope, and the general condition appears not

altogether unsatisfactory, although the pulse is very rapid and devoid of power; very soon, however, the patient becomes restless and begins to talk volubly and incoherently; delirium sets in; the limbs are thrown wildly, utterly regardless of pain, and in a short time this is followed by a condition resembling furious mania. The result is invariably fatal from collapse.

**Diagnosis.**—Syncope due to failure of the blood supply to the brain rarely causes any difficulty; with hemorrhage, especially when it is internal, it is different. In many cases of injury to the abdominal viscera it is practically impossible to make a diagnosis—the two are so often associated. Given a case of severe contusion followed by collapse, it may be due to shock alone or to shock complicated by hemorrhage from rupture of the viscera or tearing of a mesenteric artery or vein, and there is no certain method of separating one condition from the other. Failure of sight due to anemia of the retina, constant yawning or deep sighing inspirations, and throwing the arms over the head are very suggestive of hemorrhage, but nothing more; and a great deal of blood may collect in the abdominal cavity without causing any marked degree of dulness.

**Treatment.**—The expeditious operator, who uses ordinary judgment, will seldom have to deal with severe shock of his own production. Operations should be carefully planned and nicely executed. They should never be begun without a definite plan of technic and of coöperation on the part of the assistants and anesthetist. Many operations can advantageously be done in two stages. The patient should have his fears allayed before the operation. During the operation the patient should be kept dry and enveloped in woolen blankets or rubber dam. Excessive loss of blood should be immediately followed by rectal, subcutaneous, or intravenous infusions of salt solution. Where practical, large nerve trunks should be blocked by the injection of a 1 per cent solution of cocain or novocain directly into the sheath before they are cut. The same holds true for the superior laryngeal nerve.

Until we learn the true pathology of shock, all treatment must remain empirical. Varied as are the views as to the precise nature of this condition, there is a unanimity of opinion that the prime essentials in the treatment are bodily warmth and mental and physical rest. Warm blankets and hot-water bags, or bottles, will insure the former; while for the latter we are much dependent on the behavior of those around the patient. Morphin in small doses hypodermatically is often very useful. The value of stimulants in shock is a mooted question, but it is probable they are given, as a rule, rather from the desire to be doing something than from any warranted conviction as to their utility. If a stimulant is to be administered, it is possible that an ordi-



nary hypodermic syringe of neutral camphorated oil injected every half hour will be found to be as useful as any and open to fewer objections. If intravenous or subcutaneous infusion of saline is resorted to, it should be supported and sustained by adrenalin and atropin.

Because of the supposed loss of vasomotor control and consequent sequestration of blood in the abdominal veins, bandaging of the limbs in severe shock has been a common practice, and Crile elaborated a pneumatic suit for maintaining the blood pressure. Even if effective, the latter is at the disposal of but few, but it can be imitated by bandaging the inner tube of a bicycle tire to the extremities and trunk, and then inflating the tubes. After all, however, aside from rest, the restoration of the normal bulk of fluid in the vessels, the maintenance of bodily warmth and of mental and physical rest, and the elimination of pain, shock is best treated in a negative way.

### AIR EMBOLISM.

If air enters a vein in sufficient quantity to reach the right auricle, grave depression or death may follow. If any conclusion can be

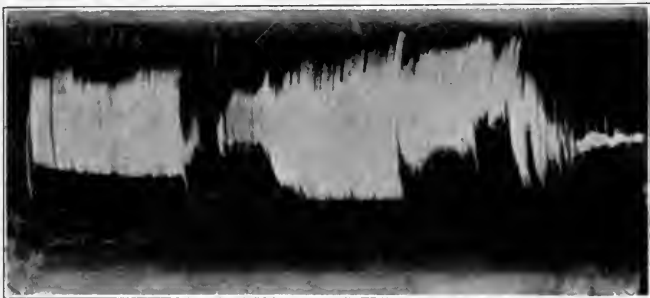


Fig. 13. Experiment 11B. Tracing made from ventricle of a cat while repeated injections of air were made into the jugular vein. The interruptions in the contractions are plainly shown.

drawn from animal experimentation, it must be that the danger resulting from air in the right heart is considerably exaggerated in most textbooks, although there are a number of apparently authentic cases of death from this cause. In 1885, Senn collected about twenty such instances.

In a carefully conducted series of experiments on cats and dogs, which were made for the purpose of obtaining accurate data for this subject, during which blood pressure tracings were taken while and after measured quantities of air were let or forced into the jugular vein, it was observed that there was both a mechanical and a vital disturbance on the entrance of the air into the right heart. The air destroyed the action of the valves, and at the same time the heart's effort

was decreased (Fig. 13). As a result the blood pressure would fall dangerously low—sometimes almost to zero.

The amount of air required to kill different animals of the same species varied enormously, which possibly explains the lack of uniformity in the published clinical reports on the subject (Figs. 14 and 15). Based on the observations made during these experiments, the treat-



Fig. 14. Experiments 5 and 7.

Death from injection of air into the jugular veins of two cats.

Experiment 5, March 16, 1910.  
Cat, weight 3500 Grams (male).

Time.		Blood pressure Hg.
10:03:	Normal pressure .....	164 mm.
10:05:	4.5 c.c. air in jugular.....	80 mm.
10:07:	.....	150 mm.
10:09:	4.5 c.c. air in jugular.....	30 mm.
10:12:	40 c.c. salt solution.....	20 mm.

Containing 1 c.c. adrenalin, this was repeated in 1 minute—no sign of recovery.

11:20: Animal dead.

Postmortem: A clot in right heart. Air in right heart, lungs, and inferior vena cava back to liver; no air in left heart.

Experiment 7, March 16, 1910.

Cat, weight 2500 Grams.

Blood pressure 134 mm. Was injected with 9 c.c. of air. Pressure fell at once to zero, and treatment with adrenalin and salt was ineffective.

Autopsy: Showed air in all abdominal veins, air in right heart, no air in left heart, not dilated.

ment we propose for air embolism accompanied by serious symptoms is the introduction of adrenalin chlorid in a fairly concentrated solution, 1:10,000 to 1:1000, directly into the right ventricle, and this should be accompanied by a small amount of normal saline solution. In our experiments on dogs we used 40 cubic centimeters or more of saline solution; but in most cases a large quantity of air had been put in under

pressure, and it required a pressure of 60 centimeters of water to force the fluid into the vein (Fig. 16).

For clinical application, a fine hypodermic needle might be pushed through the chest wall directly into the right heart. This could be done by inserting the needle through the chest wall and lung at the anterior extremity of the third or fourth right intercostal spaces. We



Fig. 15. From Experiments 4, 1, 3, and 14. Experiment 4: Dog revived of itself. Experiment 1: Cat revived with .9 saline. Experiment 3: Cat, which failed to revive with .9 saline, was revived with .9 saline and adrenalin. Experiment 14, drum 3: Dog revived with adrenalin in a concentrated solution.

observed no evil effects in dogs from perforating the heart wall with a fine needle, but to attempt to do it through the chest wall would be a very uncertain procedure.

Air embolism usually results from operations in the neck in which large veins are exposed. We believe a practical application of this treatment would be to insert a douche point or transfusion needle, attached to some sort of transfusion apparatus, or douche can containing

normal saline. The adrenalin chlorid can be introduced into the tube of the douche apparatus close to the vein by piercing it with a hypodermic needle. The water can be put in with safety at a pressure of 25 to 30 centimeters of water pressure.

In regard to the quantity of a 1:1000 adrenalin solution to be used, we suggest that 2 cubic centimeters be tried in a severe depression and repeated.

In dogs  $\frac{1}{4}$  cubic centimeter was sometimes effective, and the extreme activity resulting from a large dose was of but short duration. Any dangerous symptom short of apoplexy arising from an overdose can be modified by bleeding from an artery (See experiment No. 14, drum 3, Fig. 16).

Artificial respiration according to the Schafer method should be employed when respiration ceases. As a last resort, the chest might

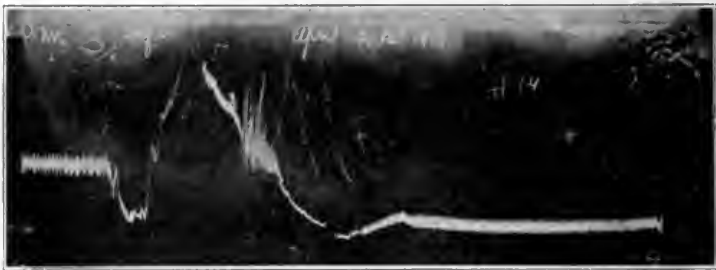


Fig. 16. Experiment 14, drum 3. Shows fall in pressure after injecting 40 c.c. of air in the jugular vein of a dog and the excessive rise in blood pressure on injecting 1 c.c. of a 1:1000 solution of adrenalin chlorid. This excessive pressure was controlled by taking 75 c.c. of blood from the femoral artery. The resulting fall in blood pressure is shown on the tracing.

be opened, and direct cardiac massage applied. We reestablished the circulation in two dogs in this manner after giving the adrenalin. The experiments of Senn show that horses are more severely affected by air embolism in the erect than in the horizontal position, and therefore a patient should be kept in the latter position during the effort at resuscitation.

In animals in which the air was forced in under pressure it was necessary in most cases to apply the remedy within two minutes, but it is probable in many clinical cases in which small quantities of air are aspirated that sufficient time will elapse between the accident and impending death to allow of some attempt to save them. The violent contraction of the heart muscle that results from the introduction of a concentrated adrenalin chlorid solution into its cavities is the most efficient agent that we found for restoring a circulation embarrassed by air embolism.

There are other possible postoperative complications, but to go beyond these more important ones would draw us too far away from the main purpose of this book. We will sum up by repeating that the expeditious operator who makes careful inquiry into the functional condition of the vital organs, who conserves the vital forces, and early establishes elimination will have a relatively limited personal acquaintance with postoperative complications.

### POSTOPERATIVE PNEUMONIA.

Postoperative pneumonia is more apt to occur in elderly people. The determining cause is irritation from ether; aspiration of mucus, blood, or stomach contents; exposure and chilling during or after the operation; or sloughing in the wound. A predisposing cause is impaired circulation. The quantity of ether given should be the minimum necessary.

Except in intestinal obstruction, there is little danger of aspiration of stomach contents if the patient's head is turned to the side when he vomits, because in ordinary vomiting the pharyngeal and palate reflexes are present.

The function of the lungs is augmented, and pulmonary complications are rendered less likely, by placing all patients in a sitting posture in bed as soon as they come from under the anesthetic. This is especially important with weak or elderly people. It is not practical or necessary with infants or young children. All should be well protected during and after operation.

### EDEMA OF THE LUNGS.

This is a rather rare postoperative complication, the determining cause of which may be ether; but it is probable that a weakened heart's action or renal disease may be a contributing cause. It is to be guarded against in the same manner as are other chest complications. It is the practice of some to give all patients with enfeebled heart several moderately full doses of digitalis during the twenty-four hours preceding operation. Twenty minims (1.25 cubic centimeters) of the tincture is what we ordinarily use. If the stomach is intolerant, several doses of the alkaloid or the tincture may be given hypodermatically. A milligram of strophanthin (Böhringer) may be given once intravenously twenty-four hours before operation. Atropin, if given early, will sometimes control the edema after it has set in.

### SUPPRESSION OF URINE.

This is best avoided by assuring kidney function before operation and limiting the quantity of ether. Contrary to a somewhat popular

practice, patients should not be dehydrated before or after operation, but may receive fluids up to two hours before the operation, and by the stomach as soon after as water can be swallowed. We also avoid drastic purges. When the excretion of urine is deficient, broken doses of calomel, and rectal, subcutaneous, or intravenous saline infusions, and possibly digitalis and sweating, are indicated.

### ACETONURIA.

Owing to a derangement in metabolism, there is sometimes found a condition in which acetone, oxybutyric acid, or diacetic acid is formed in excess and liberated into the circulation. When this occurs as a postoperative complication, it is supposed to be due to the anesthetic, especially chloroform. It causes dryness of the tongue, excessive thirst, and asthenia, and may be recognized by a sweet odor on the breath and the presence of acetone or diacetic acid in the urine.<sup>2</sup>

This complication is comparatively common in children, and is combated by withholding protein foods, the establishment of free elimination, and neutralizing the poison by giving bicarbonate of soda in medium-sized doses—2 grams, or 30 grains, each six hours.

<sup>2</sup>Legal's test for acetone: One fourth of a test tube of urine is treated with a few drops of freshly prepared, somewhat concentrated, solution of sodium nitroprussid. A few drops of acetic acid are added to prevent the reaction with creatinin, and the mixture is then rendered alkaline with ammonic or sodic hydrate. The mixture gradually develops a red color, which increases to a deep purple-red color. In the absence of acetone the red or purple color does not form. V. Jaksch's test for diacetic acid: To the urine a fairly concentrated solution of perchlorid of iron is cautiously added. If a phosphatic precipitate forms, this may be removed by filtration, and more perchlorid solution is added. If the Bordeaux red appears, one portion of the urine is boiled, while another is treated with sulphuric acid and extracted with ether. If now the urine that has been boiled gives no reaction with the perchlorid of iron solution, while the ethereal extract shows the claret color with the iron solution, diacetic acid is probably present, particularly if the urine is found to be rich in acetone.

## CHAPTER V.

### WOUNDS AND INJURIES OF THE SOFT PARTS.

In this chapter will be considered not only wounds and injuries of the soft parts, but general surgical principles underlying the care of all wounds and injuries. Injuries may vary from slight scratches and contusions to total destruction of the face, from scalds of the mucous membrane to burns involving immense loss of tissue, and therefore in a single chapter on these injuries one can do little more than deal with only the more important details.

There are four points to consider in dealing with any wound or injury—namely, (1) the extent of the injury, including the determination of the structures involved, (2) the possible presence of a foreign body in the wound, (3) the probability of sepsis, (4) the repair of the injury.

#### WOUNDS.

**Extent and Character of the Injury.**—Injuries resulting from violence or force may be classified as open and closed wounds. As an example of the former, we may take a knife cut or a bullet wound; of the latter, contusions and closed fractures. Open and closed wounds differ from each other in that the latter are but little liable to infection.

From their clinical significance, open wounds have been divided into four classes:

1. **INCISED WOUNDS.**—These are wounds in which the tissues are clean cut without bruising, and in which the depth is not out of proportion to the surface extent. In such wounds it is usually easy to determine the exact tissues involved. There is little likelihood of a foreign body remaining undiscovered in their depth, and, owing to the fact that vitality of the tissues is but little impaired, repair without sepsis is probable.

2. **CONTUSED WOUNDS.**—These wounds differ from incised wounds in that the vitality of the tissue involved is greatly impaired, and that sepsis or sloughing will be a probable complication.

3. **PUNCTURE OR STAB WOUNDS.**—These are wounds of great depth compared with their surface extent. The examination of such an injury may leave one in considerable doubt as to the extent of the damage. If clean cut, as with the blade of a knife, there is less probability of sepsis than in an incised wound; but if any individual structures are to be repaired, or if there is a foreign body to be removed, enlargement

of the original wound or the making of another incision will probably be necessary. If a punctured wound is made with a dull instrument, such as a stick driven into the tissues, the element of contusion is added. In this case sepsis and necrosis, if they occur, will be at a depth, and may necessitate enlargement of the wound or special incisions for drainage.

4. GUNSHOT WOUNDS.—These wounds vary in character according to the size, consistence, and velocity of the projectile. The small, jacketed, high-velocity rifle bullets make clean-cut tracks, carrying no shreds of clothing into the wound. If they strike a bone, they may pierce it cleanly or may smash it to fragments, according to the amount of vibration they transmit. Slow-moving, large revolver bullets, or the wads of blank cartridges, are apt to carry bits of clothing into the wound and to remain buried in the tissue. They cause more contusion of the soft tissues, and if one of these break a bone, will probably splinter it. They are easily deflected from the direct course; and the bullet may be torn in several fragments after entering the wound, and each fragment pursue a different course.

Closed injuries may be confined to the soft parts, including the periosteum, in which case they are called contusions; or they may involve a bone, constituting a fracture. Burns which are destructive of tissue, due to the action of heat, light, electricity, or caustics, will be considered separately.

The method of determining the structures injured should be both anatomical and physiological, and will vary with the character of the injury. If the eye or the finger can penetrate a certain depth into an incised wound, a fairly accurate estimate of the damage can be made on purely anatomical grounds. Again, if a probe can be passed into a punctured wound a certain depth and direction, we may be able to say that certain structures are injured, but to determine if other neighboring structures have escaped, we may have to resort to the examination of function.

A completely severed muscle will lose its function. An injury of a motor nerve will cause a paralysis of its muscle or muscles, an injury of a sensory nerve will cause anesthesia or loss of taste, an injury to a blood vessel will cause hemorrhage, and an injury of a salivary duct will be evidenced by leakage of saliva. In this manner, by a careful examination, it is usually possible to form an accurate estimate of the anatomical damage.

**Possible Presence of a Foreign Body.**—The possible presence of a foreign body in a wound may be determined by the sum of several investigations: First, the history of the injury and, if possible, an examination of the instrument with which it was inflicted. If with



a stick or knife, the determination that the point is missing will lead to the surmise that it may be in the tissues. If a bullet wound shows no hole of exit, the same conclusions may be reached; but the presence of a wound of exit does not exclude the possibility of a part of a lead bullet remaining. Feeling with the finger or probe may show the presence of a foreign body, but it is difficult to exclude it with the latter. Lastly, the presence or absence of bodies that are impenetrable to the x-ray may be determined by its use.

Before inserting a probe or anything else into a fresh wound, one should stop for a moment to consider whether the act will be productive of more good than harm. It is often difficult to follow the course of a deeply punctured wound in soft tissue with a probe, and one who attempts to do so will seldom be certain that he is following the track of a wound and not dissecting the tissues. Further, unless the probe and the mouth of the wound are clean, he may carry into the depths an agency of infection that failed to penetrate with the original injury. The same holds true, but to much less degree, with sinuses and abscess cavities. We do not mean this as a condemnation of probes and probing, both of which have a distinct place in surgical operations, but as a condemnation of the indiscriminating, thoughtless use of probes.

A foreign body deep in the tissues may sometimes be located by palpation, both by the objective resistance transmitted to the finger of the examiner and by the subjective pain or discomfort caused by a certain manipulation or manipulations. Foreign bodies can be approximately located by the x-ray by radiographing from two different surfaces and determining the point of intersection at which the foreign body is situated. Unless they are very difficult of access, they should be removed. If rather inaccessible, their location and character will determine our course. Hard structures—such as bullets, bits of knives or slate pencils—often remain in the tissues without causing further disturbance, and it may be better to wait for positive indications for their removal than to do greater damage by the immediate attempt. When it is seen that a foreign body is the focus of suppuration or the cause of nerve irritation, it should be sought, and removed if found. It is not well to attempt to find a deeply seated or a very small object by cutting down to its supposed situation through a straight incision. Success is more apt to crown the effort, and less damage will probably be done, if a semilunar incision is made through the skin and fascia and a flap turned. This will give room for examining and for dissecting between the more important structures as they are encountered.

**Probability of Sepsis.**—Infection of a wound depends on the

lodgment of pathogenic bacteria in the wound in sufficient numbers to overcome the resistance of the tissues. The probability of infection will depend on the location of the injury, character of the injury, manner of its infliction, and time which has elapsed before treatment.

Clean-cut wounds are less liable to infection than open contused wounds, and punctured wounds, unless contused, are more apt to heal kindly than even incised wounds. Wounds that contain a foreign body—especially such as bits of stick, dirt, or clothing—are more apt to be infected than those that do not, and wounds that have been exposed for hours are less liable to remain clean than those that are immediately treated.

All accidental wounds, and probably all operative wounds, contain the bacteria of sepsis, most commonly *Staphylococcus albus*. As stated before, they must, however, be present in sufficient numbers to be able to overcome the tissue resistance before they can cause suppuration. There are three ways in which they can be present in great numbers: (1) by being introduced in quantity with the infliction of the wound, (2) by being continuously introduced into an open wound, (3) by having considerable media in the wound—blood clot, serum, devitalized tissue, catgut, etc.—in which they can multiply unmolested until their numbers have sufficiently increased and they have elaborated enough toxin to enable them to attack the living tissues.

It is probable that the first contingency is comparatively rare, and that the majority of clean-cut wounds would, if immediately approximated, heal by what is clinically known as first intention. In the face and mouth the blood supply is so abundant that the tissue resistance to infection is very high, and immediate suture of wounds is usually followed by success.

The third method of wound infection—the development of the bacteria in culture media present in the wound—is to be avoided by attention to the following points: removal of devitalized tissue, avoidance of porous sutures and ligatures, closing of the wound without dead spaces, and providing drainage. To this end, when possible, hemorrhage is to be controlled by simply suturing the wound and applying moderate pressure, or by crushing and twisting the bleeding ends of the vessels. Shreds of tissue may be removed with knife or scissors, or the wound may be dressed antiseptically and sutured later, when all damaged tissue has either recovered or sloughed. In suturing, the cut surface should be approximated to the full depth of the wound. If this is not done, a dead space may become distended with fluid that will serve as culture medium for germs. In wounds that are liable to become infected, it is customary to provide drainage to carry off the wound secretions. This may be done in two ways. If it is a deeper portion

of the wound that is to be drained, some substance—as a hollow tube, strands of horsehair, silk or silkworm gut, a folded slip of rubber dam, a strip of gauze, or some other device—is carried from the point to be drained to the surface, either out through the wound or through an extra stab wound. Drainage from the superficial part of a wound is best accomplished by only loosely approximating the cut surfaces, so that the secretions may exude from between them. Tight suturing not only interferes with drainage of the wound, but, by limiting the blood supply, lessens the tissue resistance. Even where infection of a wound of the face or mouth is well established, unless it is of a virulent, spreading character, union will usually follow suture if drainage is not obstructed.

It is somewhat customary to advise the attempt to clean fresh wounds before suturing them. Without going into the rationale of the procedure in wounds in general, it may be well to state that, with the exception of the removal of gross particles and torn shreds of tissue, which really constitute foreign bodies, we never make any systematic attempt to clean wounds of the face and mouth by washing them. Where practicable, the skin edges should be cleaned with normal saline solution, ether, alcohol, or tincture of iodine. We usually use the latter in one half or one third of its normal strength for all skin preparations. We are convinced that any attempt to wash bacteria from a fresh cut, besides impairing the vitality of the tissues, is more apt to have the reverse effect.

In dealing with infected wounds of the face and mouth, it may be expedient to wait a few days before suturing. By this time a wall of active granulations has grown in the cut surface, and necrotic parts, possibly with minute foreign bodies, have been thrown off. The factor that is disadvantageous in delayed suture is the contraction that occurs in the developing granulations, which, though it lessens the wound surface, distorts the relations of the cut structures, drawing the skin toward the depth of the wound and causing the retraction of loose flaps.

If it is seen that suppuration is developing in the depth of a sutured wound, drainage must be established; but on the face and in the mouth it is seldom advisable to recklessly remove all sutures. Preferably, drainage from between the sutures should be encouraged by inserting a pair of pointed forceps into the wound, gently opening them, and removing a suture here and there as necessary. It is only when an infection is of a fulminating character, or when there is a great systemic reaction, that it is necessary to lay the wound open to its full extent. Even then the infection can often be controlled by the use of the ice bag.

Men who confine their practice to the mouth cavity become so accustomed to see infected wounds and abscesses that result from tooth infections heal with relatively slight general disturbance, that they may sometimes lose sight of the fact that infections do not always remain local, and that serious illness or death may result from apparently most trivial cases. (See Infections, page 32.)

In the consideration of wound infection, we have confined ourselves to the mention of sepsis, which usually means an infection with bacteria that causes suppuration. There are bacteria of other diseases that may gain access through wounds, but their development is dependent on the same conditions. One of these diseases requires particular mention, and that is tetanus. The bacillus of tetanus is rather broad in its distribution, and is found particularly in manure, street dirt, and the surface earth. Its entrance into wounds that have been inflicted by an object that has been in contact with the ground must be relatively common. The rusty nail that causes tetanus does so, not because it is rusty, but because it carries tetanus bacilli and because it inflicts a deep, lacerated wound. For the development of lockjaw it is necessary that the bacilli of tetanus develop in the wound, and they will not develop in the wound unless favorable conditions are found. It is not even necessary that the wound be deep, as scabs and slough may furnish the protection needed for the development of bacilli that lie under them. If the clinical symptoms of tetanus become manifest within six days from the date of injury, as a rule there is little that can be done to avoid a fatal issue. But its development can always be prevented by the early injection of a prophylactic dose of tetanus antitoxin, and therefore, in every case of a wound that has been received in the street or on the ground, or inflicted with an instrument that has been in contact with the ground, 1,500 units of tetanus antitoxin should be injected as soon afterward as possible. Dr. Tupper and the author have been following this procedure for the past fourteen years, and neither of us has since had a case of tetanus develop from a wound of which we had the original care.<sup>1</sup>

**Healing of Wounds.**—Wounds heal by means of a hyperactivity of the contiguous tissue. The first change in the tissues around the wound is a contraction of the cut blood vessels, which tends to stop the bleeding. Next there is a dilatation of the vessels with increased blood supply, and an exudation of plasma and white cells. Later there is an increase of the fixed tissue cells and a growth of new blood vessels. This growth or increase in the fixed tissue cells is largely confined to the connective tissues. Besides these, there are very few of

<sup>1</sup>Anaphylaxis has somewhat recently been put forward as a rather uncomfortable possibility when repeated doses of an animal serum are given to the same individual. This is to be borne in mind.

the body tissues that have the power of reproducing themselves. Among the exceptions are the surface epithelial cells of the skin or mucous membrane. The endothelial lining cells of blood vessels and lymphatics and the axis cylinders of nerves that still retain their connection with nerve ganglia are capable of reproduction.

The growth of the connective tissue cells forms an embryonal tissue called granulations—the red velvety surface that is seen in every open healing wound. This granulation tissue ultimately undergoes changes by which it is transformed into scar. It is almost entirely by means of scars that bind together the contiguous tissues that wounds are healed. Bone granulations become impregnated with lime salts and go through a series of changes, which may ultimately result in true bone tissue.

It has been found convenient to speak of the healing process as divided into two kinds—that which takes place in a clean, closed wound, and that which occurs in an open or infected wound. The first is called healing by first intention, or primary healing, and the second is spoken of as healing by second intention, or healing by granulation. Though the healing in these cases differs clinically, still essentially it is identical.

When the surfaces of a clean wound are held in apposition, they are first agglutinated by the wound secretions and later are permanently united by granulation, which turns to scar. In open and suppurating wounds the surfaces cannot be immediately agglutinated by the wound secretions, nor can the granulations grow directly across the gap from one cut surface to another.

Granulation obliterates an open wound in the following way: As granulation tissue ages, its deeper and older layers contract. In a wound in the soft tissues this contraction lessens both the surface area and the depth by drawing the surrounding and underlying tissues into the defect. When a wound has healed, the scar will be much smaller than the original defect, and it is due to this contraction of the scar that the surface of a healed wound is often depressed. It is because the surrounding tissues cannot be drawn into the defect that deep cavities in bones heal very slowly, if at all.

When the granulation at the edge of the wound reaches the level of the surface epithelium, the latter ordinarily begins to grow over and cover the granulation, so that most surface scars are covered with epithelium.

Healthy granulations are of a bright-pink color and of a velvety appearance. They are very rich in blood vessels, which consist of newly formed capillary loops, and it is on account of these that granulations bleed so freely when injured. Even healthy granulations are

continuously bathed in a slight excretion of serum containing some white cells. The character of the granulation may be modified by either local or general conditions. Local infections, mechanical irritations, a constitutional disease, or general depression, all have a malign effect on the healing process, and it is to one of these that an abnormal or unhealthy condition of granulations is due. A fair estimate of the local or general condition can frequently be gained from the appearance of the granulations.

As granulation tissue matures, it is converted into scar. This is a contractile fibrous tissue, from which eventually most of the blood vessels disappear. As a result of contraction, a normal scar is usually much smaller than the original wound. Owing to its poor blood supply, it is whiter than the surrounding tissue. While scar naturally tends to contract, it cannot do so against any great resistance. It is not a strong tissue, and will stretch when a continuous strain is put on it. This is why, in some situations, scars may increase in breadth and length. Incisions on the face and neck should, when possible, be made in the direction of the natural cleavage of the skin. When this is done, the resulting scar will always tend to become narrower. When an incision is made across the line of skin cleavage, the scar stretches with age. Kocher, from observing the results of drainage incisions in various parts of the body, has worked out the cleavage lines to which incisions should correspond.

The time after injury at which a scar contracts and the blood vessels are obliterated is somewhat variable, and it may be long delayed. A scar that continues to increase in size and remains red long after the wound has healed is called a keloid scar, which is somewhat different from the true keloid tumor. Some individuals have a distinct tendency to form keloid scars, and sometimes a hint of this condition can be had from observing the scars resulting from former wounds.

Once after removing a large dermoid cyst from the floor of the mouth through a transverse incision under the chin, the scar was hardly visible at the end of a week. The patient, a girl, was sent home with the assurance that the scar would never show. A year later she returned with a red corded keloid scar, 5 millimeters high and almost 1 centimeter wide. Investigation showed that she had several similar scars on the thigh, resulting from boils that occurred years before. A knowledge of this at the time of the operation would have saved us from embarrassment.

**Treatment of Wounds.**—The ultimate result from an injury will depend on the extent of the injury, the reaction of the tissues, and the treatment it receives. Except shreds and absolutely detached pieces of bone, or a tooth or piece of bone that prevents the proper approxi-

mation of a fracture, no injured tissue should be removed from the face until it is absolutely certain that it cannot recover its vitality. This is particularly important in regard to all attached fragments of bone. The blood supply of the face is particularly rich, and the tissues recover and wounds heal in a way that has no parallel in the rest of the cutaneous surface of the body. On the other hand, the loss of even small quantities of tissue, especially bone, may cause deformities that can never be entirely corrected. If the wound has become infected, the repair of special structures may have to be deferred until the infection has been controlled.

The first point in the treatment of a recent wound is the control of the hemorrhage, if this be present.

In recent wounds all important structures should be repaired, and blood vessels, with the occasional exception of the important veins, should be ligated or twisted. As stated under hemorrhage (page 49), veins may occasionally be sutured. Motor nerves should be united by fine sutures. Injuries to salivary ducts are treated by making provision for the saliva to flow from the cut duct into the mouth (Salivary Fistula, Chap. XXXIII). Muscles that are completely divided should be sutured, but it is not always necessary that they be sutured individually. Lastly, the skin or mucous membrane should be accurately sutured. Where no special structures other than muscles are involved in wounds of moderate depth, the deep structures and the skin or mucous membrane may be all united by the same sutures.

Wounds should be closed in such a manner as to exclude dead spaces, in which the tissue fluids and blood may collect. This is an important preventive against sepsis.

Extensive loss of tissue on the face is to be replaced by plastic operation (Chap. XVIII). It is not necessary to wait until the wounds have entirely healed before undertaking to do this, but one should be guided by what is to be expected from the healing process, unassisted by any flap operation. The defects from absolute loss of tissue become smaller as granulation and scarring progresses, but undermined flaps retract so that the defect will, for a time, enlarge. Later these will be drawn toward, but not exactly to, their original position. According to the condition of the wound, the repair of these defects may be undertaken immediately, or as soon as the wound presents a clean granulating surface and the general condition of the patient warrants.

### BURNS.

Burns are really a variety of open wounds. Deep burns contain a foreign body—the burnt tissue. Burns are classified according to the depth to which the tissue is destroyed. The disfigurement resulting from a burn is dependent on the depth and extent, and also on the

amount of infection that followed. The heavy scarring often seen after a severe burn is the result of an excessive inflammatory process, due to a prolonged infection. Superficial burns, though less destructive, are more painful than deep ones. The pain should be controlled, which may be done more or less effectually by cold, moist applications or, better still, on the skin surface by the application of a saturated solution of picric acid in water, applied with cloths for several hours. The picric acid solution will relieve the pain almost instantly, but the disadvantage is of staining the skin yellow. With extensive burns, shock is often a serious complication (Treatment of Shock, page 58).

A burn is an aseptic wound, and its aseptic character should be preserved. It is not always possible to do this with dry dressing, as infection may occur at the junction of the skin and the slough. The skin always contains the organisms of sepsis. The application of a pack of alcohol or of a 5 per cent colloidal silver is non-irritating and non-toxic, and will render the eschar antiseptic. Later, when the eschar is impregnated with the silver salt, a dry absorbent dressing may be substituted. If the full thickness of the skin, with its glands, has been destroyed, the resulting defect should be remedied by skin grafting or by flap operation (page 217).

The pain of slight scalds of the mouth is partially relieved by alkaline antiseptic washes and cold applications. As a rule, they need little other treatment. Severe scalds of the mouth or pharynx, such as occur with children and insane people, are very serious, and liable to be fatal from edema of the glottis. The acute swelling in the mouth is to be relieved by incisions, especially into the dorsum of the tongue, and tracheotomy should be done if edema of the glottis threatens.

In burns that result from chemical caustics, the chemical agent remaining in the wound should be neutralized, and then the injury should be treated on general lines. Carboic acid is neutralized by alcohol or whiskey, lye by vinegar and oils (fine olive oil does not saponify readily), and all acids by an alkali, usually the bicarbonate of soda, preferably in solution.

X-ray burns, which occasionally appear after prolonged or repeated exposure to the ray, especially from the soft tubes that are used for treatment, or from exposure to radium salts, present a peculiar phenomenon, varying from a redness or a pigmentation of the skin to deep ulcers. The first form needs no special treatment. The ulcers are very indolent, and may require from one to two years to heal if left to themselves, and the scars are liable to be the seat of carcinoma. The best form of treatment for severe burns seems to be the removal of necrotic tissue and granulations, and the application of thick grafts



or flaps transferred from neighboring healthy tissue. According to F. C. Wood, even if such flap grafts slough, they sometimes leave the tissue in such a healthy condition that Thiersch grafts will then grow satisfactorily.

### SUTURES.

On the face and in the mouth, interrupted sutures are in most instances preferable to continuous sutures. And, except when buried,

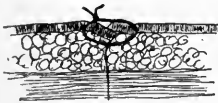


Fig. 17.

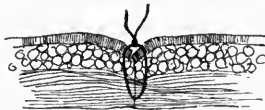

Fig. 18.

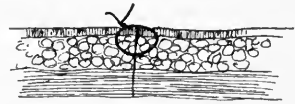

Fig. 19.

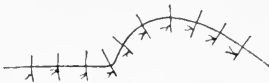

Fig. 20.

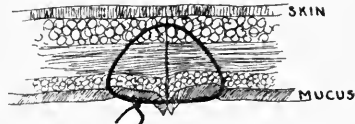


Fig. 21.

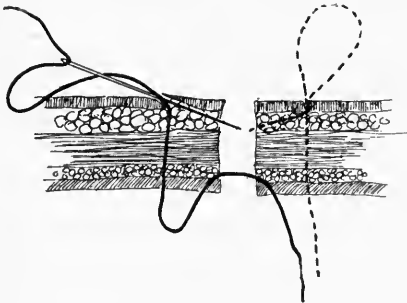


Fig. 22.

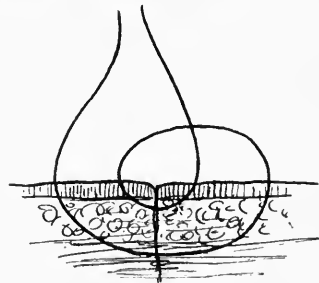


Fig. 23.

Fig. 17. Suture that causes skin edges to lap.

Fig. 18. A suture that penetrates too deep in comparison to its lateral extent may cause a depression at the wound edge.

Fig. 19. A properly placed suture.

Fig. 20. Illustrating how each suture should cross the wound at right angles.

Fig. 21. A deep suture suitable for a mucous surface that will not allow the mucous borders to overlap.

Fig. 22. A modification of the deep stay suture that Lane uses in the lip. This is tied on the mucous surface.

Fig. 23. A suture that approximates the deep and superficial tissues. This suture must be drawn loosely, or the tissue within the grasp of the short loop of the suture is apt to slough.

silkworm gut, horsehair, or silver wire are to be used in preference to silk or catgut. On the neck, continuous sutures may be used in the form of the ordinary whip stitch or the glover's stitch.

On the neck, metal clips may be used for the skin, but they do not approximate the platysma muscle. The subcuticular suture of silver wire, silkworm gut, or catgut, when accurately done, gives a nice ap-

proximation of the skin and of the adjacent part of the superficial fascia, and does not interfere with the superficial drainage of the wound. Both the subcuticular stitch and the wound clips are supposed to have the advantage of avoiding the possibility of stitch abscesses, and the former of leaving no stitch scar. We believe, however, that stitch abscesses that arise purely from stitch infection are the result of pressure, as are the stitch scars; that if non-capillary sutures are drawn only sufficiently tight to hold the tissues in contact, and are removed in four days, neither stitch abscesses nor scars will result. On the face the sutures that unite the skin edges should not be depended on to overcome tension. Where there is any resistance to the approximation of the flaps, it should be overcome by retention sutures.

In placing interrupted cutaneous sutures, there should be a relation between the depth to which each suture penetrates into the tissue and its width. A suture that embraces a large skin area and does not penetrate any depth into the tissue may cause the skin margins to overlap one another (Figs. 17 and 18). It is not necessary, however, that the greatest width of the suture should be on the skin surface (Fig. 19). Again, there should be a proportion between the width and depth of the suture and their distance from each other. As a rule, sutures should penetrate to a depth equal to one half of the whole of its width, and they should not be placed closer together than is necessary. If the tissues are held in place by a stay suture, fewer skin sutures will be required. If gaping occurs, very small sutures, including only the skin, may be used to reinforce when necessary. Each suture should cross the wound at right angles (Fig. 20). (Several plans of stay sutures are shown in Figs. 21 to 23.)

Through-and-through stay sutures, that cross the skin and mucous surfaces, cause scars, which, though they may ultimately become invisible, certainly detract very much from the pleasure of an immediate good result.

### DRESSINGS.

Dressings are applied to wounds for protection, to produce pressure, to absorb secretions, and to facilitate drainage, or to hold some medicinal agent in contact with the part. Dry, well-approximated wounds of the face require no dressings. The slight amount of secretion that dries at the edge is sufficient protection, while dressings applied to wounds of the face are cumbersome and useless. This applies more particularly to large wounds that confine the patient to the house. Approximated, dry, clean wounds may be covered with a few fibers of cotton, or one layer of gauze, and then painted with thin flexible collodion. Adhesive plaster may be applied to hold the gauze in place, but should seldom be in direct contact with the wound.

Cutaneous sutures of the face and neck should be removed in four days. When these cutaneous sutures are removed, the line of union is protected by a layer of gauze, pasted on with collodion. When it is desired to remove sutures that are covered with collodion and gauze or cotton, the latter must be raised with care, for otherwise the wound may be torn open. On clean wounds of the neck and under surface of the chin, dry gauze, covered with a quantity of cotton, is applied, and the whole is bandaged firmly in place.

If the secretions from a discharging wound are very free, dry gauze may be applied; but if scanty, the gauze should be moist, to encourage drainage. If there is any reason why the gauze should be moist, there is the same reason why it should remain so, and moist gauze should be completely covered with rubber tissue, oil silk, rubber adhesive, wax paper, or some other impervious covering.

There is some good to be derived from applying mild antiseptic solutions to infected granulating surfaces. The application we commonly use is a wet pack with saline solution (a teaspoonful of salt to a pint of water), frequently changed, which, by encouraging drainage, not allowing the dressing to stick to the wound, and not irritating the granulations, usually accomplishes all that is to be desired. If an active antiseptic is indicated, we use either 50 per cent alcohol or 5 per cent solution of colloidal silver. A 50 per cent solution of alcohol applied under an impervious covering will irritate the skin. Bichlorid of mercury is not active in the presence of albumin, and carbolic acid is dangerous. With the possible exception of alcohol (50 to 75 per cent solution), we know of no advantage that is to be derived from incorporating medicinal agents in the packs applied to the intact skin. Moist heat applied in the form of wet packs is beneficial to inflammatory conditions, though it favors suppuration.

When granulations are inclined to become covered with a dry scab that does not confine wound secretions, the process may be encouraged by an antiseptic dusting powder. The one we ordinarily use is the subiodid of bismuth.

Skin that is irritated by a wound discharge should be protected with an unguent. The ordinary unguentum zinci oxidi is as efficacious as any, and there is no reason why it should not be sterile.

## CHAPTER VI.

### INJURIES OF THE TEETH AND ALVEOLAR PROCESS.

Mechanical injuries of the teeth may result from abrasion, tension, or violence. The resulting condition and treatment will depend on the nature and extent of the injury.

#### MECHANICAL ABRASION OF THE TEETH.

Mechanical abrasion of the occlusal surfaces of the teeth is usually present after middle age, and increases with advancing age. The character of the food, mechanical impurities in the atmosphere, and the low resistance of the tooth substance are the principal agents involved in the process of mechanical abrasion. The wearing away of the tooth structure occurs most frequently in persons who are persistent tobacco or betel nut chewers, those who subsist on coarse, tough foodstuffs, and those who live in an atmosphere containing sand or grit. Workers in glass factories using sand blasts and the Bedouins of the desert show a marked degree of mechanical abrasion of the teeth. Pronounced cases of mechanical abrasion by any of the above named causes are usually found only in persons who have passed middle life. In some cases the crowns of the teeth may be worn away to the gums.

**Symptoms.**—When the tooth substance is slowly worn off, a chronic mechanical stimulation of the dentin-forming elements of the pulp results, which manifests itself in the production of secondary dentin. This new dentin is deposited in irregular masses in the pulp chamber, causing a slow progressive atrophy of this organ, which, in pronounced cases, may result in the total obliteration of the pulp canal. Mechanical abrasion rarely causes hypersensitiveness of the dentin or exposure of the pulp.

**Treatment.**—The proper treatment for mechanical abrasion consists in the restoration of the lost tooth substance by means of proper filling or capping of the abraded surfaces until useful occlusion is obtained. Should the dentin become hypersensitive, or the pulp exposed, devitalization of the latter and its replacement by some inert permanent material are the usual surgical procedures. Medicinal applications for the alleviation of pain resulting from this wearing away serve their purpose only temporarily.

### LOOSENING OR AVULSION OF THE TEETH.

In the process of separating the teeth, or in orthodontic procedures, too much strain may be brought on a tooth, and as a consequence, its pulp may die. As a result of violence, a tooth may become loosened in its socket or entirely avulsed.

**Treatment.**—A tooth which is simply loosened without fracture of the alveolar process will usually regain its normal solidity without treatment. A tooth that has been forced from its normal position, but which has not entirely left its alveolar socket, is called a displaced tooth. It should be replaced in its normal position, and held there by silk or wire ligatures, or metal bands, attached to the neighboring teeth, until it has become solid.

A tooth that has left its socket may sometimes be replaced. Before replantation, the tooth is opened by cutting off about one-eighth inch of its root. The root canal is cleaned, sterilized, and filled, and the tooth is washed in normal saline solution. It is now forced into the thoroughly cleaned socket, and held in place by a ligature or a metal splint until it has again become solid. The tooth should be replaced as soon as possible after the accident occurs, although there are many cases on record in which replantation was performed days and even weeks after the separation from its socket. In a multirooted tooth a broken-off root may be replaced by a porcelain root according to a method devised by Rhein.

A transplanted tooth is one which is inserted into a natural alveolus other than the one from which it originated. The preparation of the tooth and its replacement and retention are the same as outlined for a replanted tooth.

An implanted tooth is one which is inserted into an artificial socket made into the alveolar bone with special reamers, trephines, etc. The mode of procedure of preparing the tooth, etc., is the same as outlined for replantation.

In replantation and transplantation of a tooth which is freshly removed from its socket, as much as possible of the periosteum of the alveolus and of the pericementum of the tooth should be preserved. Such teeth must not be boiled before replantation, but they should be preserved in physiologic salt solution at body temperature. The alveolus is washed with the warm saline solution, or a 5 per cent colloidal silver solution, but no irritating antiseptics should be used. After the operation the mouth must be kept clean with an efficient mouth wash. The replaced tooth is in a majority of cases mechanically retained by the growth of connective tissue fibers, which encircle the tooth firmly, and it usually remains in place from four to seven years.

### FRACTURE OF THE TEETH.

As a result of violence, a tooth may suffer injury, varying from slight chipping of the enamel to a fracture of the body of the crown, or of the root. Decay may so weaken a crown, without necessarily destroying all of its enamel, that it may readily fracture on very slight pressure. Nature has not, except by the deposition of secondary dentin, made provisions for repair of the teeth, and therefore lost tooth structure must be replaced mechanically by the dentist if the normal outline of the teeth is to be restored.

**Treatment.**—If the crown of a tooth is fractured, it may be replaced with an artificial substitute; if the root is fractured, an attempt may be made in some cases to save it by banding. Callous union may occur if the pulp recovers.

### FRACTURE OF THE ALVEOLAR PROCESS.

Fractures of the alveolar process that are not associated with fracture of the body of the jaw are usually secondary to the displacement or extraction of one or several teeth. The fracture may involve a large section of the process and carry with it several teeth, or it may be splintered in the neighborhood of one tooth.

**Treatment.**—All fragments of the alveolus attached to the soft tissues should be replaced. If there are teeth in the fragment, these should be fixed to neighboring solid teeth. All detached fragments should be moved, as they will be ultimately thrown off, and until removed, are a source of irritation.

## CHAPTER VII.

### FRACTURES OF THE UPPER JAW.

As has been pointed out by Cryer, the maxillary bones include, surgically, the malar, the palate, the inferior turbinate, the lacrymal, the nasal, and the lateral masses of the ethmoid and the nasal septum, as any or all of them are liable to be involved in injuries characterized as fractures of the maxillary bones.

The nasal bones, with or without involvement of the septum, are more often fractured than any of the others, and most commonly without injury of the other bones. Either of the malar bones, with their zygomatic processes, may be fractured or displaced without extensive injury to neighboring bone structures. Fractures of the nasal bones should be considered as a distinct classification, and for lack of space cannot be described here; but fracture of either of the malar bones is usually associated with more or less injury of the body of the maxillæ, and they will be included with the latter.

#### CHARACTER OF THE INJURY.

Fractures of the maxillary bones may vary in extent from injuries to the alveolar process to a tearing loose of all of the facial bones by a transverse fracture at or near their attachment to the cranium, the latter being often associated with extensive fractures of the brain case and brain injury. The prominence of the cheek bone usually receives the force that causes such extensive injuries, and it is not uncommon to find that the malar bone and the body of the maxilla of that side are crushed.

**Displacement.**—The displacement is always due to the original violence or to gravity. The hard palate may be pushed upward until it infringes on the nasal fossa, and displacement of the alveolar process will vary with the direction of the force. Extensive fractures of the maxillæ, involving other facial bones, may be divided into two classes according to the character of the predominant displacement: (1) if a severe force is applied from in front in an upward and backward direction, such as the kick of a horse, the maxillæ may be driven in toward the base of the cranium with considerable comminution and impaction; or (2), if, as is most commonly the case, the force is applied to the prominence of the cheek, the malar bone will be more or less driven into the maxillary antrum, but at the same time there may

be extensive radiating fractures. If one of these is a transverse fracture through the orbits, the whole bony framework of the face may sag down, supported only by the soft tissues. It is with the latter kind that basal fractures are most liable to occur. In some instances, by taking hold of the upper teeth, the whole face can be made to move on the cranium, and we have seen the skin at the root of the nose puff out and in with each respiration, while the pulsations of the brain were plainly visible, transmitted to the skin through crevices in the vault.

**Diagnosis.**—There can be no difficulty in diagnosing fractures with displacement which extend into the alveolar process. Slight depressions or displacement of the malar bones might be overlooked on casual inspection, and if there is much swelling, it may be impossible to detect the displacement by palpation. In all cases of injury of the face the dental arches and the palate should be inspected, and the facial bones outlined digitally. This is best done by standing behind the patient, and with the thumb and fingers of both hands examining simultaneously the orbital borders of the intraoral and extraoral outlines of the malar, maxillary, and nasal bones, and of the zygomatic arches. A definite local tenderness that can be elicited by pressure made on a distant point or points, the force being transmitted through the bone, is always suggestive of a fracture at the tender point. Slight lateral deviation of the nasal bones may be detected by making a pencil mark in the center of the bony ridge, and then viewing it from above while standing behind the patient. The swelling that obscures the diagnosis may be modified by cold applications or by digital pressure under an anesthetic, but where available, an x-ray negative may at once settle the question.

### TREATMENT.

As with fracture of the mandible, treatment consists both in the care of the tissues and in the mechanical treatment of the fracture. These fractures are often accompanied by very severe shock, and may be but part of an injury that involves concussion or laceration of the brain or intracranial hemorrhage. Emphysema of the cellular tissue of the face is not an uncommon complication of fractures involving the nasal fossa or maxillary antrum. There may be considerable swelling, and if the patient is not seen until some hours after the injury has occurred, this can obscure the exact nature of the fracture and of itself cause obstruction of the nasal passages.

Any of the structures contained in the face may be injured—more particularly the maxillary division of the fifth nerve, the branches of the internal maxillary artery, and the lacrymal duct. Sepsis may follow, as these fractures, extending into the antrum or nasal fossa, are usually open. In caring for the fracture itself, the surgeon usually



does all that is necessary when he restores and retains the bones in their proper relations and keeps the involved cavities as free as possible from material that would promote sepsis.

**Care of the Tissues.**—Often the care of the patient is of greater importance. Emphysema is best combated by insuring free egress of air through the nose or mouth. In rapidly extending emphysema we have plugged the posterior nares, and the effect was beneficial. Cold, in the form of an ice bag, is the most efficient means of preventing or treating the swelling due to the infiltration of the tissues with serum. The cold should be so applied as to cool, but not freeze, the tissues. If, owing to swelling, breathing is labored, it can be partially relieved by dropping a solution of adrenalin chlorid into the nostrils. Until proper fixation is applied, breathing can sometimes be facilitated by placing in the mouth a large rubber tube that extends back to the oral pharynx. Injury to the maxillary nerve may be evidenced by an anesthesia over the area of distribution, or later by a neuralgia, but it is not common. Hemorrhage, though it may be sharp at first, is usually self-limited. Obstruction of the nasal duct that is not relieved with the subsidence of the swelling would need special attention later.

Sepsis is to be combated by frequent irrigation of the nasal and oral cavities, and if the maxillary antrum is widely open, this should receive the same treatment. If the antrum contains an infected blood clot, it should be opened and cleansed. In douching the nasal cavity, the patient should, if possible, be in a sitting or semierect position, and no forceful stream should be used. If the lower portion of the nasal fossa is kept clear, the discharge from its upper part will flow down and not collect. It should be remembered that when fluids are forced to the upper part of the nasal fossa there is danger of infection of the accessory sinuses. The most serious complication is a fracture of the base of the cranium, which, besides being often accompanied by brain injury that may be of itself fatal, leaves an open avenue to intracranial infection. In all severe cases, hexamethylene tetramine should be administered in fairly large doses to render the mucus and the cerebrospinal fluid antiseptic. Under no circumstances should any considerable quantity of attached bone be removed. The bones connected with the maxilla are well nourished, and, unless absolutely detached, will usually unite if replaced, while the loss of even small pieces will leave noticeable deformity. This holds true particularly in cases where the whole face is crumpled up by some severe blow in front, such as the kick of a horse.

**Mechanical Treatment of the Fracture.**—For treatment of fractures of the alveolar process see Injuries of the Teeth and Alveolar Process, page 82.

Injury to the palatal process is rare, and is due as a rule to a gunshot wound that will not need treatment.

Impactions must be carefully diagnosed, and the bones restored to their normal outline. For this purpose the antrum may be opened from the mouth above the canine fossa, and the bones pried outward or downward with a steel urethral sound. The malar bones, the zygomatic process, and the lower border of the orbit can be manipulated into place with least disfigurement by inserting a strong, sharp, steel hook through the tissues to engage on the various edges of the bones. If the impaction cannot be broken up in this way, resort may be had to a small, sharp chisel. Unless the bones are terribly shattered, there is little tendency for the deformity to recur. If there is this tendency, the bones can be wired in appropriate places (Fig. 24).

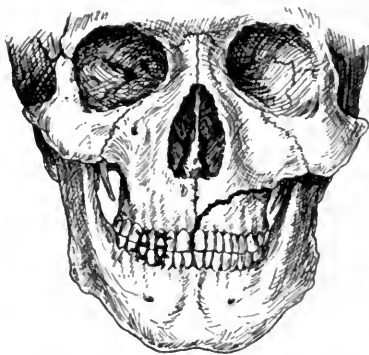

Fig. 24. Showing a method of supporting one maxilla, after fracture through the body, by wiring the lower to the upper jaw on the sound side

Transverse facial fractures, with a downward sagging of the maxilla, are best treated by supporting the facial bones by pressure exerted upward on the upper teeth or alveolar processes. It is not practical to do this by bandaging the lower jaw against the upper, because the support is inadequate, and because in such cases the nasal fossæ are almost invariably obstructed by swelling and the patient must breathe through the mouth. Goffres and Graefe have both devised methods that consist essentially of adjustable steel bars that pass from a head band and enter the mouth, and hook on to the upper dental arch. We believe the more practical and efficient method of supporting the maxillary and facial bones under these circumstances is to wire them in their appropriate places, or to use a Kingsley splint reversed, after the method suggested by Dr. John S. Marshall. It consists in applying a Kingsley splint to the upper jaw and supporting it from above with a head bandage. "Impressions of the upper and lower teeth were taken with

the modeling compound by first molding it upon the upper teeth and while it was yet soft forcing the lower jaw upward until a correct occlusion of the teeth was obtained. This impression was trimmed to the desired shape; a one-eighth-inch steel wire was imbedded in the sides on a line with the ends of the teeth, then bent backward upon itself opposite the cuspid teeth, and allowed to extend outside the cheek nearly to the lower border of the ear. From this was constructed a hard-rubber splint, with the wires attached. This splint can be made from silver swaged over metal dies, but if a metal plate is desired, the most perfect adaption can be secured by the electro-deposit plate,

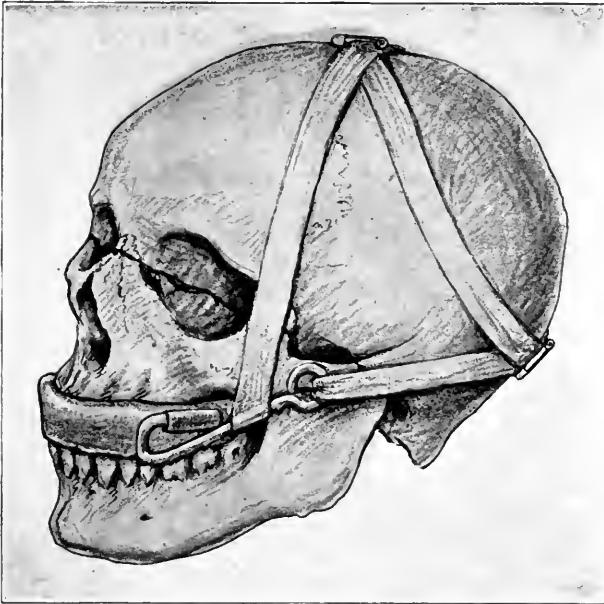


Fig. 25 Marshall's method of supporting the maxilla, in transverse fracture of the face, with a Kingsley splint. The arms of the splint, which are detachable, protrude from the mouth at each corner and lie close to the side of each cheek.

the wires being attached with solder. The splint is held in position by means of double elastic straps attached to the wire on each side and buckled to a close-fitting leather or net cap, which is reinforced with leather and laced firmly on the head. This proved to be a very successful appliance, as it held the fractured bones in their proper position and permitted comfortable breathing and free movement of the lower jaw, which enabled him to talk and, after a few days, masticate soft food. Deep indentations were made in the under side of the splint, in which the lower teeth fitted accurately when the mouth was closed. The object of this was to furnish a sure guide to the normal

position of the superior maxillæ. Without this the correctness of the adjustment of the bones could not have been verified. Its importance therefore cannot be overestimated."

If, at the time of taking the impression, the fragments of the upper alveolar process are not in perfect alignment, a reconstruction can be made, and the splint is made over this restored arch. If the patient has an upper plate that has escaped injury, it may be converted into a splint by attaching arms. (Fig. 25 shows the splint in use.)

This splint is to be retained until the bones have attained sufficient anchorage to hold them in position. If there is much loss of bone on either side of the nose in front, the lower part of the maxillæ may have only a fibrous attachment or may be drawn upward. To correct this and at the same time restore the bridge of the nose, we have transferred an osteoplastic flap, including part of the anterior wall of the frontal sinuses. This makes a bridge between the frontal bone and the maxillæ.

## CHAPTER VIII.

### FRACTURES OF THE LOWER JAW.

Owing to its position, the lower jaw acts somewhat as a guard to the rest of the face. It is more exposed to violence and is more often fractured than any other of the face bones. Owing to its loose connection with the skull, fractures of the lower jaw are much less likely to be complicated by skull or brain injury than a fracture of the upper jaw. It is a fracture that frequently occurs in fist fights, and naturally alcoholism is often a predisposing factor. It is much more frequent in men than in women.

#### CHARACTER OF THE INJURY.

The mandible may be broken by direct or indirect violence in any part. Because of the tooth sockets, and its more exposed position, fractures of the body are more common than those of the ramus and its processes, the latter constituting less than 5 per cent of the breaks. The former are more frequently caused by direct, the latter by indirect, violence. The bone is very hard and brittle, and splintering at the site of fractures is not uncommon. Fractures of the body usually communicate with the mouth cavity.

**Displacement.**—While the displacement of the fragments of the fractured lower jaw may have been primarily produced by violence, it is always maintained or modified by the action of the muscles to which the jaw gives attachment. In treating fractures of this bone, it is not of so much importance to be acquainted with the large assortment of the various forms of apparatus that have been devised for this purpose, as to understand the muscular actions that caused displacement. With this knowledge, a relatively simple armamentarium will be sufficient to get nice results in nearly all cases.

The lower jaw is a bar of bone, bent at the chin and at the angles, and somewhat loosely attached to the base of the skull at the condyles. The axis of motion in the simple action of opening and closing the mouth is not at the condyles, but near the upper openings of the inferior dental canals, which are situated in the middle of the ramus at the level of the occlusal plane and molars. On the intact jaw, the actions of its various muscles are nicely balanced; but when a fracture occurs, the action of certain groups is no longer opposed, and displacement is produced and maintained.

In the diagrammatic schemes here illustrated, no attempt is made to include the finer actions of the muscles, but only those which are responsible for the gross displacements that ordinarily occur. The displacement will depend upon the direction and position of the fractures or fracture; the amount of displacement in any one place will depend upon the amount of laceration of soft tissues covering the bone,

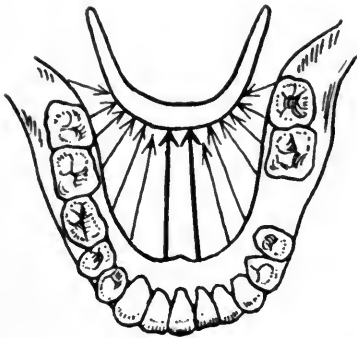


Fig. 26.

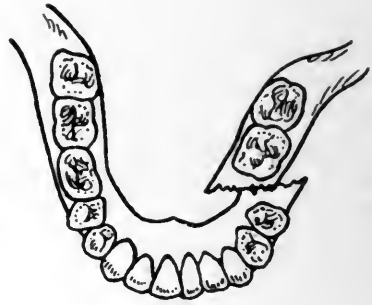

Fig. 27.

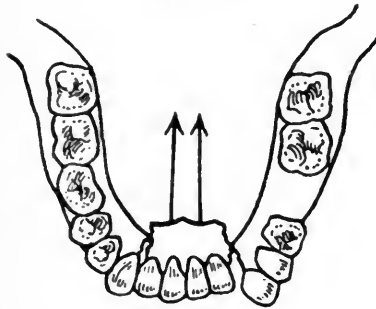

Fig. 28.

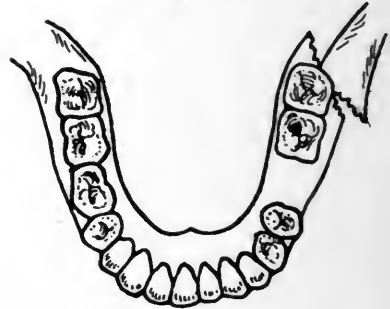

Fig. 29.

Fig. 26. The arrows show the direction of horizontal traction of the mylohyoid, geniohyoid, geniohyoglossi, and digastric muscles on the jaw. The light arrows represent the fibers of the mylohyoid muscles, and the two heavy arrows represent the geniohyoid, geniohyoglossi, and digastric muscles.

Fig. 27. Diagram showing possible horizontal displacement in a fracture in the bicuspids or molar regions.

Fig. 28. Diagram showing possible horizontal displacement in a double fracture in the mental portion of the body.

Fig. 29. Diagram showing possible horizontal displacement in a fracture of the body near the angle.

and the direction of the fracture. It will simplify the presentation of the subject to consider the displacement that may occur in the horizontal and in the vertical planes separately, and leave the reader to draw conclusions as to what will be the actual displacement in any particular instance.

The mylohyoid muscle, which forms the floor of the mouth, extends from the concavity of the body of the mandible to the body of the

hyoid bone, and the direction of its pull is represented by the finer arrows in Fig. 26. The geniohyoglossi, digastric, and geniohyoid muscles together make a strong muscular mass that extends from the back of the symphysis to the body of the hyoid, and their combined pull is represented by the two heavy arrows in Fig. 26. In a vertical fracture at the symphysis, the muscular balance will not be disturbed, and there will be no horizontal displacement. In a fracture or fractures

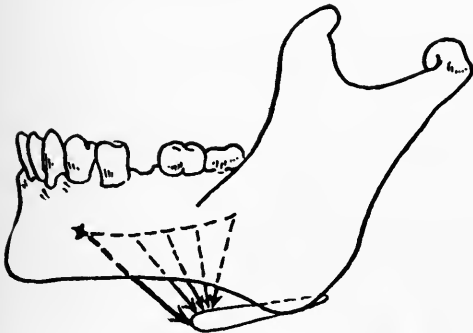


Fig. 30.

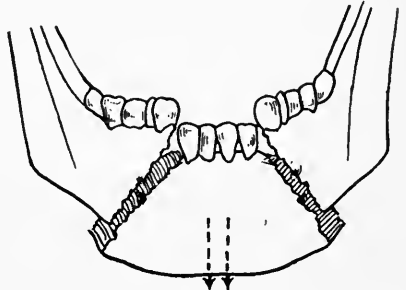


Fig. 32.

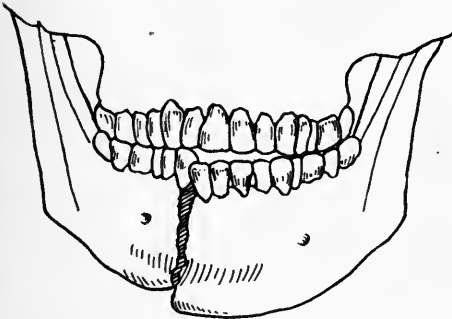


Fig. 31.

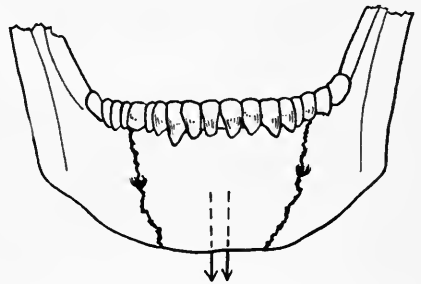


Fig. 33.

Fig. 30. Showing the direction of traction of the geniohyoid, geniohyoglossi, digastric, and mylohyoid muscles.

Fig. 31. Diagram of a fracture in front of the cuspid showing characteristic displacement.

Fig. 32. Diagram showing possible vertical displacement in a double fracture of the mental portion of the body.

Fig. 33. Diagram showing an instance in which, owing to the directions of the planes of fracture, there could be no vertical displacement.

of the body at any place between the symphysis and angle, granting that the mucoperiosteum is torn, and unless prevented by the direction of the lines of the fracture, the displacement will be as shown in Fig. 27. The portion of the mylohyoid attached to the smaller fragment will draw the latter toward the median line. The whole of the mylohyoid of the opposite side together with the muscles attached to the symphysis will draw the mental portion of the larger fragment backward and to the side of the fracture. If there is a fracture on both

sides, then the mental fragment might be pulled backward (Fig. 28), but as can be readily understood, the direction of the line of fracture may be such as to prevent this displacement. In fractures near the angle, the body may be drawn backward on the fractured side (Fig. 29).

The hyoid bone is situated on a lower plane than the attachment of the muscles to the inner surface of the body of the mandible, and therefore they all draw the bone downward as well as backward, most of the force being expended on the mental portion (Fig. 30). As long as the body of the bone is intact, until the temporals, masseters, and internal pterygoids voluntarily relax, these more powerful muscles neutralize the downward pull of the muscles attached to the hyoid bone. If, however, a break occurs any place between the angle and the symphysis, unless prevented by the direction of the line of fracture,

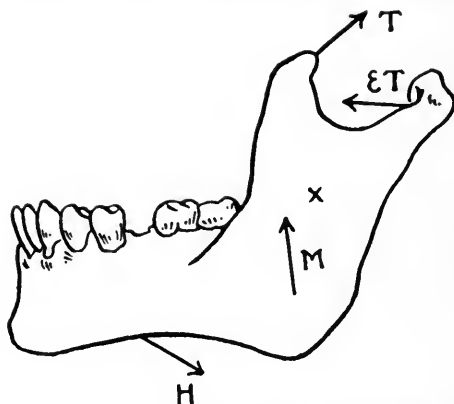


Fig. 34. Diagram indicating by arrows the direction of traction on the jaw of the various groups of attached muscles. T, temporal muscle; M, masseter and internal pterygoid muscles; ET, external pterygoid muscle; H, muscles attached to the hyoid bone; X, axis of motion in opening the mouth.

the mental fragment will be pulled downward as well as backward. If the fracture is single, there will be but a downward tilting of the mental fragment, greatest at the site of fracture (Fig. 31). If there is a fracture on each side of the symphysis, the mental fragment may be pulled bodily downward as well as backward (Fig. 32), but in the case of either the single or double fracture, the line of fracture may be such as to preclude displacement (Fig. 33).

In any fracture of the body, whether single or multiple, there is apt to be a combined vertical and horizontal displacement, but its occurrence will be governed by the principles just illustrated. In a double fracture of the anterior part of the body, the backward dislocation of the mental fragment might allow the tongue to fall back on the glottis and cause dyspnea.



The muscles of mastication are attached to the ramus of the jaw and its processes. Of these, the masseter, the temporal, and the internal pterygoid are concerned in closing the mouth, while the external pterygoid assists the mandibulohyoid muscles in opening the mouth. The direction of the pull of these various muscles is illustrated in Fig. 34. The internal pterygoid muscle passes downward, backward, and outward to the inner surface of the ramus, while the masseter passes downward, backward, and relatively inward to its outer surface. The masseter being the most powerful may, in fractures in front of the angle, cause an outward tilting of the lower end of the ramus. In a fracture at the angle the pull of the mandibulohyoid muscles will tend to draw the body backward. If a considerable part of the masseter and internal pterygoid muscles remains attached to the posterior end of the body fragment, this may be drawn upward, so that the lower

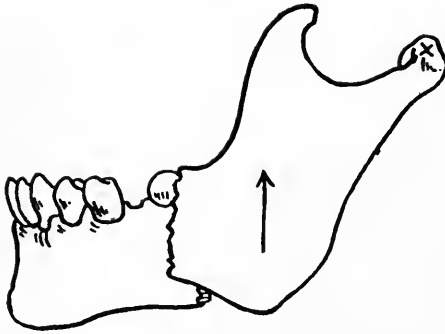


Fig. 35. Diagram showing possible forward displacement of the ramus in fracture of the body at the angle.

posterior molar tooth is locked behind the corresponding upper, the chin is depressed, and the lower incisors do not come up to occlusion. In a fracture of the posterior part of the body, unless prevented by the direction of the break or the presence of one or more occluding teeth in the posterior fragment, the lower end of the ramus may be tilted forward and possibly laterally. The direction of the lateral displacement will depend upon the direction of the break (Figs. 29, 35).

In fractures of the ramus itself, there is, as a rule, little or no displacement (Fig. 36), but a fractured coronoid process may be drawn upward and backward by the temporal muscle. In a fracture of the neck between the ramus and the attachment of the external pterygoid, the condyle may be drawn forward by the latter muscle.

The hyoid bone is not fixed, but its position depends upon the tone of the various muscles to which it furnishes attachment; therefore the act of swallowing, talking, or even moving the head will often influence

both the pain and the displacement of a fracture in the body of the lower jaw.

**Diagnosis.**—Where any considerable number of opposing teeth are present, the diagnosis of a fracture of the body is usually self-evident, even though the displacement be slight. In fractures behind the angle and in fractures of the body with no displacement, diagnosis is usually best made by the use of the x-ray and the noting of points of greatest tenderness. Sometimes there is sufficient displacement to be recognized by palpation, but crepitus, the sensation elicited from the grating together of the broken fragments, is rarely a factor in making

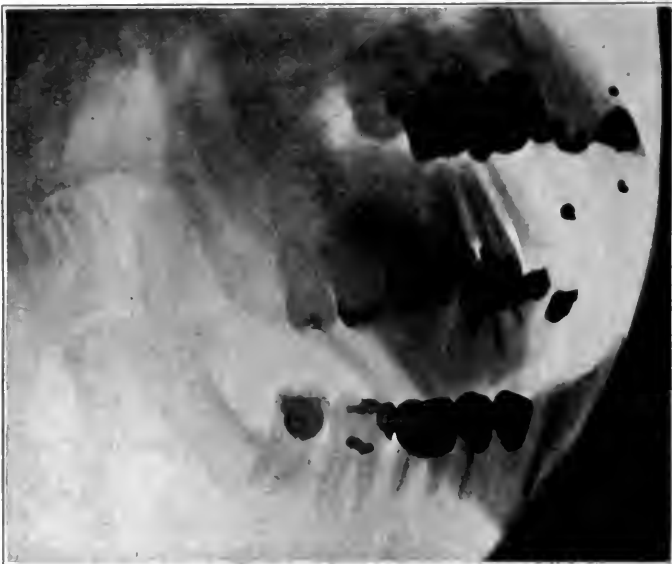

Fig. 36. X-ray of fracture of the ramus, sustained by falling on the face. There was no displacement of the body, and the exact nature of the injury was determined only by the x-ray. No fixation was needed in the treatment, as there was little pain and no displacement. The fracture is to be seen at the left side of the picture.

the diagnosis. If true bony crepitus is detected, it is to be taken as certain evidence of a fracture, but crepitus is to be sought only by the gentlest of manipulations.

A good x-ray gives the most accurate information with least inconvenience to the patient, but usually a fracture may be recognized or excluded by seeking for localized points of greatest tenderness. If a point along the jaw-bone is found to be tender to finger pressure, it may mean that there is a fracture at this site, or simply that there is a localized bruise. If, however, pressure upon the jaw-bone at several different points causes distant pain at one certain point,

that is also sensitive to local pressure, then this may be taken as strong evidence of a fracture at this site. For instance, in a fracture at the symphysis, there may be absolutely no displacement, but the chin will be found tender to pressure; and pressure on the jaws at the angles will cause discomfort at the chin, owing to the force being transmitted through bone to the site of fracture. If the site of suspected fracture is near or above the angle, the test is made by pushing the chin backward and drawing it from side to side.

The lower jaw is the most accessible of all the bones in the body, and deformities resulting from the malunion of the fractures are in themselves more noticeable than in almost any other part.

### TREATMENT.

Treatment of a fracture of the lower jaw includes two objects: the care of the tissues and of the patient, and the replacement and maintenance of the correct position of the fragments. Of these, the latter will be considered first. There are two ways of keeping the fragments in the correct position. One is to hold the broken fragments in their proper relation to the sound jaw and thus, indirectly, with each other; and the other is by means of dental splints, wires, or bone plates to directly fix the broken fragments to each other.

**Indirect Fixation.**—It has long been recognized that where there is a full or nearly full quota of teeth the dental arch of the uninjured jaw should make an ideal splint for the fractured jaw, if adequate means could be contrived to hold the two arches in occlusion. The older and very commonly recommended method of applying a chin cup and bandaging the lower to the upper jaw with a Barton or a four-tailed bandage is seldom efficient where there is any displacement. Hippocrates recognized that this was not applicable to certain forms of fracture. Any bandage or apparatus that presses backward on the chin can tend only to produce displacement, and extensive observation has proved that about equally good or bad final results are obtained by no treatment as by this method. With any form of fixation, a bandage, for a few days, will give a sense of security that is grateful to the patient. In case of fracture, in which there is no tendency to displacement, rest is all that is required (Fig. 36), and this may be at least partially secured by a broad chin bandage.

**Direct Fixation.**—This may be done by uniting the ends of the bones by means of wires, absorbable sutures, or metal plates, or by means of dental splints. It is seldom that a fracture of the ramus will require direct fixation. These are rarely open fractures, and the broad muscular attachment on its surface usually prevents displacement when the body is held in its normal position. In front of the

angle and in the body, the displacement at times necessitates the use of direct bone fixation.

**Wiring of the Lower to the Upper Jaw.**—It is to the dental profession that we owe many of the devices that will accomplish this with certainty. At least it is certain that by the members of this profession these means have been perfected and popularized. To Dr. Thomas L. Gilmer, of Chicago, the dentist owes the simple but extremely useful device, the soldered dental band, which consists of a band of thin metal made to conform to the circumference of the crown and which is cemented in place. To it may be soldered a ring, tube, or a bar. When properly applied, these bands cause no damage to the teeth, and will remain in place rather indefinitely. The adjustable band, which dates back to the early part of the last century, can be

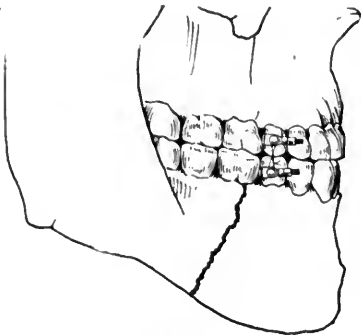


Fig. 37.

Fig. 37. Diagram showing fracture treated by wiring the lower to the upper jaw by means of Angle fracture bands.

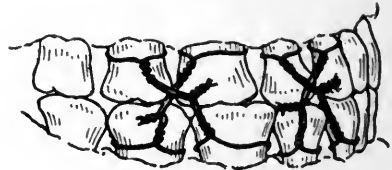

Fig. 38.

Fig. 38. Gilmer's method of treating a fracture of the body by fastening the lower to the upper jaw by means of wires passed around the necks of the teeth.—From "Oral Surgery."

applied and tightened with a wrench. Under the name of Angle's fracture bands, these may be obtained from the dental supply houses in two sizes, one to fit the cuspid and bicuspid and the other for the molar teeth. There is another adjustable band also furnished by supply houses, modified by Lukens.

As far as we know, Dr. Gilmer first advocated the direct fixation of the lower to the upper jaw by means of the teeth as a treatment of fracture of the mandible.<sup>1</sup> Where applicable, this is a very simple procedure, is efficient, and has a broader field of usefulness than any other means at the disposal of either the surgeon or the dentist. The fixation may be done by dental bands (Fig. 37), or by wires fastened directly to the necks of the teeth (Fig. 38). If bands are used, the jaws are fixed by silk or fine wire ligatures that extend be-

<sup>1</sup>Thomas L. Gilmer: Archives of Dentistry, September, 1887.

tween the bands, each having a lug or button on its outer surface for this purpose. The use of bands has certain points in its favor over the direct wiring of the teeth, but the latter is the more practical method; the materials required are nearly always at hand, and can be applied by any surgeon with a pair of artery forceps and a pair of scissors or wire cutters. There is this disadvantage in the method: in order to open the mouth the wires have to be cut, and if it is found desirable to continue the fixation, the whole procedure might be repeated on teeth that are sore from traction. However, if one will refrain from the exercise of unwarranted curiosity, the necessity of reapplying the wires will not often arise. The wire which we prefer is a soft iron wire that can be obtained on spools from the hardware shop, or in rolls at any florist, using No. 24 for the molars and cuspids, and No. 26 for the incisors. This iron wire is very pliable and

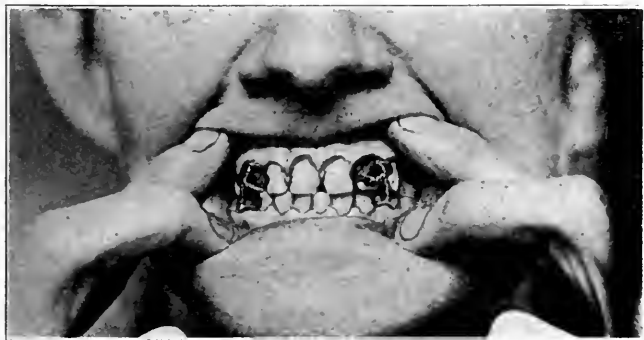


Fig. 39. Double fracture of lower jaw. Anterior fragment held up by wires passing from lower bicuspid to upper cuspids. As there is always a tendency to a backward displacement, one tooth below on each side should be wired to a tooth above and in front of it. The discoloration of the teeth is due to the iron wires. This is an objection, but the teeth can be cleansed.

does not stretch, but if it cannot be obtained, a soft brass, copper, or silver wire may be substituted. The wire is cut into lengths of about 45 centimeters each, is bent in the middle, and by means of forceps is passed from the lingual surface through the interdental spaces on each side of the tooth to be ligated. An assistant holds the intraoral loop of the wire well down on the neck of the tooth, while the operator, having obtained a firm grasp on each end, makes a twist of two full turns. This is the most important part of the application of the wire ligature. It should grasp the neck of the tooth so firmly as to preclude any motion. The ligature can be tightened with forceps, but it is better to get the tension while the first twist is being made. The serrations on the jaws of the forceps weaken the wire wherever they grasp it. The subsequent steps may be understood by referring to Fig. 38, or Fig. 39, which show the completed operation. While the

upper wires are being twisted with the lower, the teeth should be held in occlusion by pressure from below the chin. It is extremely important that the teeth be held in occlusion while the wires are being tightened. Wire ligatures put in by this method will not slip or become untwisted; but the incisor teeth offer poor anchorage, and, owing to its slight constriction at its neck, the cuspid is a difficult tooth to wire.

If the line of fracture is through, or just in front of, the cuspid socket, it often happens that a good purchase cannot be had on the teeth of the anterior fragment. Under these circumstances, we pass

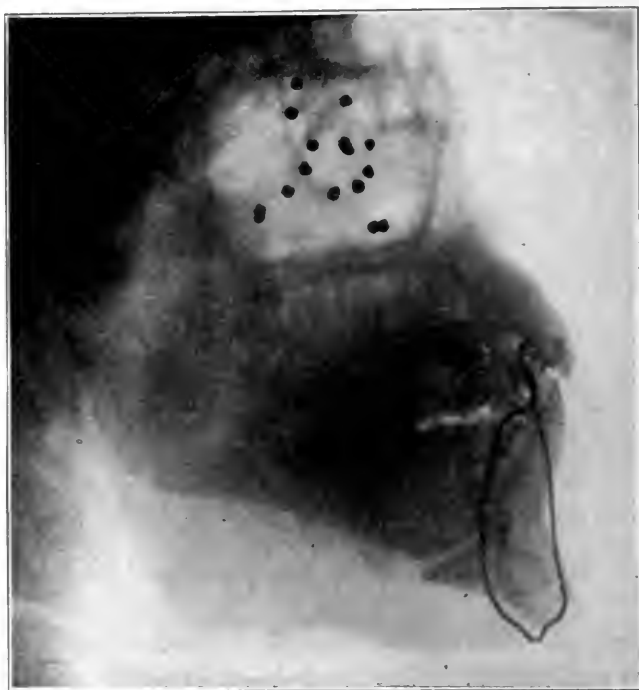


Fig. 40. X-ray showing a silver wire passed around the mental portion of the body of the jaw and fastened to a wire on the cuspid above. This holds the bone up very satisfactorily. The dark spots in the orbit are shot received years before, and causing no symptoms.

a silver wire around the body of the anterior fragment and fasten it to an upper cuspid (Fig. 40). Dr. Black passed a wire around the body of the jaw and around a splint on the lower teeth. Either of these methods can be done with a local anesthetic.

When possible, it is preferable to have the teeth cleansed of all tartar before applying bands or ligatures. No matter how desirable this may be, it is not always practical to do so. But in any case an efficient mouth wash should be constantly employed. The wires, less

so the bands, are liable to set up a simple gingivitis, but this usually at once subsides on their removal.

The teeth upon which traction has been made become loose in their sockets, but tighten up within a few days after the traction is released. Whether bands or wire ligatures are used, the sharp ends and corners are irritating to the inner surface of the cheeks and lips. A very efficient and easily obtainable protective is a gum formed by heating gutta-percha tissue over a flame until it melts into a mass, and then with wet fingers molding it over the projecting wires (Fig. 41).

If the teeth are wired while the patient is under a general anesthetic, the stomach should be emptied by means of a tube before the jaws are fixed together. Even if the patient has not eaten recently, there may be blood or food in the stomach. It is an easy and safe pro-

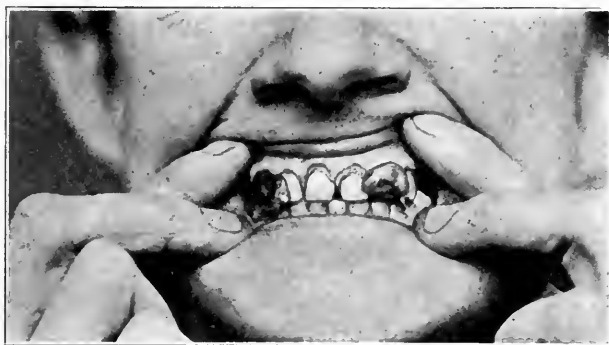

Fig. 41. Photograph showing gutta-percha gum covering the wires.

cedure to pass a tube and wash out the stomach while the patient is slightly under the anesthetic. Though it is our custom to leave an attendant to sit with wire cutters after such an operation, we have never seen it necessary to cut the wires. The patient will not vomit until the pharyngeal reflexes are restored; then, if the stomach contents are fluid, they will be emitted between the teeth or from the nose.

**Operation for Wiring the Bone for a Fracture at, or in Front of, the Angle.**—The skin having been cleansed and shaved, an incision is made under the border of the jaw 4 or 5 centimeters long. If this incision is continued on the posterior border of the ramus for any distance beyond the angle, care should be taken not to endanger the trunk of the facial nerve which crosses the posterior border of the ramus at the level of the lower border of the lobe of the ear. The incision extends directly to the border of the jaw throughout its whole extent, and the facial artery and vein are cut at the anterior border of the masseter muscle. These vessels should be caught with artery for-

ceps before being cut, and tied immediately after they are severed. The inframandibular branch of the facial nerve will often be divided by this incision.

The bleeding from small vessels in the tissues is always very free and should be controlled. With a knife, not with a periosteal elevator, the soft tissues, exclusive of the periosteum, are raised from both surfaces of the bone for a distance of at least 1 centimeter from the lower border and 2 centimeters on each side of the fracture. The insertions of the masseter and internal pterygoid muscles must be cut from the bone, but in no place should the bone be actually bared, as this would lessen its vitality. The most advantageous position for the drill holes should be selected according to the direction of the lines of fracture.

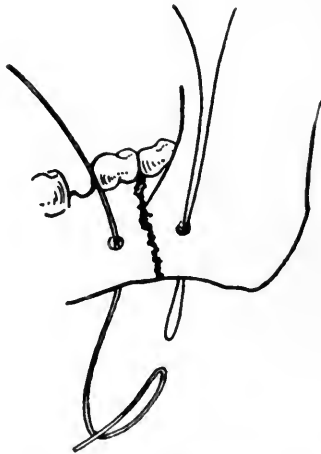


Fig. 42. Diagram showing method of passing the wire from the deep surface of the bone. The silver wire is passed through the first hole from the external to the mesial surface. Next a loop of finer wire is passed through the second hole in the same way, and the first wire is caught in the loop of the second and drawn through the second hole.

The drill holes should not be closer than 5 millimeters from the line of fracture or from the lower border of the bone.

At least in a general way, the wire suture should cross the line of fracture at right angles. Sometimes, in fractures that are oblique to the surface of the bone, it is possible to make each drill hole pierce both fragments.

While the bone is being drilled, it should be held with rat-toothed forceps that will grasp the bone without crushing or scraping its coverings. A flat retractor or a piece of flat metal should be held beneath the bone to prevent the drill from piercing the soft tissues. When one hole is drilled, the wire should be immediately inserted, or a piece of bent wire should be placed in the hole temporarily; otherwise it



will become lost to view. The drill holes should be large enough to admit the wire doubled. A convenient method of inserting the wire is shown in Fig. 42. A piece of soft silver wire about No. 20 should be used. We are not convinced that the braided Vienna wire, which is a cord made of fine silver wires twisted together, is superior or even equal to the ordinary soft virgin-silver wire (Fig. 43).

The wound is sutured with a few figure-of-eight silkworm gut sutures, the deep loops of which take a good hold on the cut cervical fascia. A small drainage tube or a folded piece of rubber dam tissue is inserted under the deep surface of the bone to the line of fracture, and caught in the wound with a suture. Such wounds are usually infected by communicating with the mouth, but osteomyelitis seldom re-

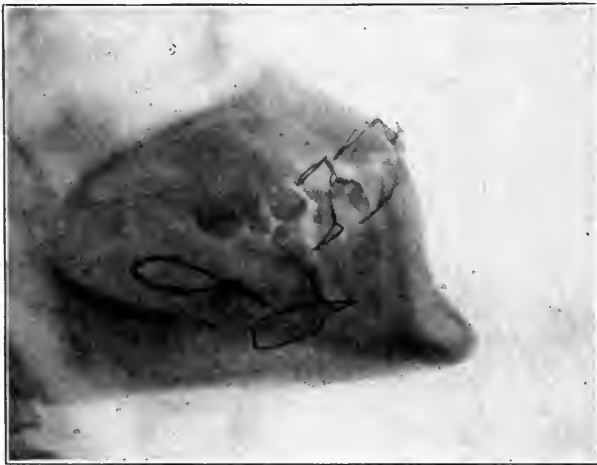


Fig. 43. X-ray of a jaw broken just in front of the angle on one side and behind the bicuspid teeth on the other, with no teeth in either posterior fragment. Both fractures wired through the bone, and the teeth in the anterior fragment wired to those above.

sults from a fracture of the jaw. The wound will usually heal with the wire in place. Sometimes it will be thrown off, but it is rare that it will have to be removed for a persistent sinus.

**Lane's Plates.**—Instead of using wire, the fragments may be fixed by the use of a small steel plate, 2 millimeters thick, 5 millimeters wide, and 2 centimeters long, which has a countersunk hole in each end. This is fastened to the bone by ordinary wood screws, the thread of which is cut up to the shoulder.

**Operation of Wiring the Jaw at, or in Front of, the Second Molar Tooth.**—At, or in front of, the second molar tooth, the jaw may be conveniently wired from within the mouth. The cheek is retracted, and an incision 3 or 4 centimeters long is made through the

mucous membrane at the bottom of the fornix of the vestibule. Without raising the periosteum, the incision is carried through the attachment of the buccinator muscle, nearly down to the inferior border of the jaw. A strip of gauze is packed into the wound, and a shorter incision is made on the inner surface of the bone at the junction of the gum with the mucous covering of the floor of the mouth. This incision is made directly to the bone, and to avoid injury to the structures in the floor of the mouth, particularly the lingual nerve, the point of the knife should never leave the bone. A spatula is placed in the inner incision to protect the soft structures from the drill. The wiring may be done either through the alveolar process or through the body. The bone may be much more conveniently wired through the alveolus and without a general anesthetic, but the result is not quite so satisfactory. In an oblique fracture, to have the wire cross the line of break at right angles, it may be necessary to put one hole through the alveolus and one through the body of the bone. When the alveolus is drilled, care should be taken not to injure the roots of the teeth. A tooth, the root of which is injured by the drill, may later have to be devitalized and filled.

After the wire is twisted, the bottom of the wound is drained from below, through a small external stab, by means of a drainage tube or a piece of rubber dam which is stitched to the skin. The wound may be packed with gauze soaked in a 5 per cent colloidal silver solution to control the hemorrhage. If the lower jaw is to be wired to the upper, the inner packing must be removed before this is done.

In wiring a fracture at the symphysis, the attachment of the geniohyoglossi muscles must not be cut, as this would leave the tongue without anterior anchorage. Bone fixation should never be resorted to where a dental splint or wiring the lower to the upper jaw can be conveniently substituted.

**Dental Splints.**—Probably the earliest attempt at making a dental splint was to fasten the teeth on both sides of the fracture to each other by means of a ligature crossing the site of fracture. Hippocrates recognized that to be efficient the ligature must be attached to teeth not immediately adjacent to the break.

The Hammond splint (Fig. 44) is still shown in many text books, but, useful as it was before the development of modern dental technic, other devices now replace it.

Modern dental splints, as a rule, require the technical skill of the dentist for their construction and must be made for the individual case. There have been a number of adjustable stock splints, placed at the disposal of the medical profession, but these are not likely to be at hand when needed, and less likely to give really good service. The

first requisite in the construction of a dental splint is an accurate reproduction of the dental arches and gums of both jaws. These are made from impressions taken in plaster of Paris, modeling compound, or wax. From an accurately made negative impression, a dentist who has never seen the case could pour the positive casts, reconstruct the broken arch, and make a perfect fitting splint. All except those splints which are banded to the teeth can be applied by the surgeon. We could not better present this part of the subject than to quote Dr. Gilmer's description of his method of taking impressions and reconstructing the deformed arch :

"Preparatory to the formation of a splint, it is necessary to secure correct impressions of both upper and lower teeth and jaws. The upper may be taken in plaster alone, but the lower can be better and more accurately made by first taking it in modeling composition; from the inner surface of this, a small portion is cut away, plaster substituted in the place of the composition removed, and the whole is again placed over the teeth. An impression thus secured, if well done, will be correct and sharp. By this means an impression cup of modeling composition is produced, which fits the part, and very materially simplifies the operation. The sharper these impressions, the greater the certainty of a true occlusion after the union of the fragments. The lower impression may be made either in sections or entire, according to the case in hand; of the comparative expediency of these two methods the operator must judge for himself. If the displacement be so great as to render it improbable that a good impression may be secured in entirety, it is better to take it in sections. In taking the impression of the lower jaw it is useless to attempt to hold the parts in position, since the setting of the bone will be done after the appliance is made; therefore, all time given this effort will be lost, besides in the majority of cases it is impossible to hold the parts in position while the impression is secured. From these impressions models are to be made (Fig. 45). If the impression has been secured in one piece, the cast from it is to be sawed in two on a line with the fracture (Fig. 46). The teeth of these two pieces are then carefully occluded with those of the upper model (Fig. 47).

"This is easily done, even though several teeth of each jaw are missing, as there is always an abraded surface of the teeth of one jaw which exactly corresponds with that of the other, but the greatest care must be exercised in fitting the parts together, as success depends upon the correctness of this part of the operation. If but the slightest difference is made in the occlusion, failure of perfect adaption is almost certain to ensue, as, the fragments not being held squarely together, an undue pressure will be brought to bear upon them at one point, while at another they will not touch; consequently, at that point where there is too great pressure, inflammation will set in, and death of the bone will follow. Union may take place, but if it does, the occlusion will be faulty. When the occlusion of the teeth of the two pieces is made with the teeth of the upper cast, those representing the broken lower jaw are to be united by the addition of a little soft plaster. If the work has been done well, this reconstructed model represents the jaw as it was previous to the acci-

dent. The foregoing description of impressions and models holds good either in single, double or triple fractures, unless the impressions have been taken in sections, in which case there is no division of casts to be made."

Dental splints are formed in various ways, according to the judgment of the operator and the case in hand. But those recommend

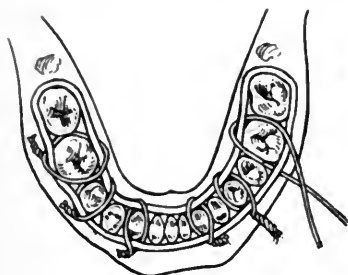


Fig. 44.

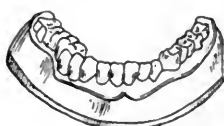

Fig. 45.



Fig. 46.

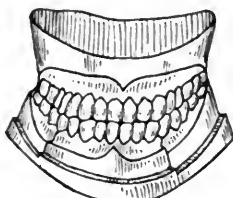


Fig. 47.



Fig. 48.

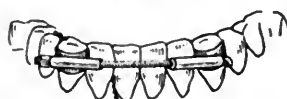

Fig. 49.

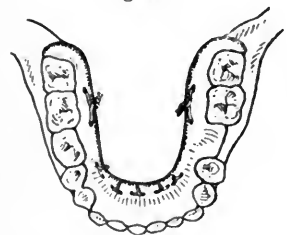


Fig. 51.

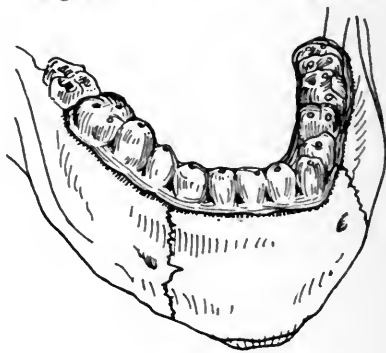


Fig. 50.

Fig. 44. Hammond wire splint. One of the earlier dental splints, but now little used in this country.

Fig. 45. Showing plaster reproduction of dental arch and alveolar process in a fracture of lower jaw. Irregularities in alignment are shown at the sites of fracture behind the right second bicuspid and at the site of the left first bicuspid.—After Gilmer.

Fig. 46. Showing plaster reproduction of the dental arch and alveolar process of the lower jaw, sawed, ready for adjustment.—After Gilmer.

Fig. 47. Showing completed reproduction in plaster of Paris of both dental arches and alveolar processes.—After Gilmer.

Fig. 48. The Gunning splint. This is designed to treat a fracture with the jaws separated.

Fig. 49. Angle's plan of fixing the fragments. This splint is more efficient if a running nut is placed on the bar at the inner end of each tube.—After Angle.

Fig. 50. Hullihan continuous dental splint.—After Angle.

Fig. 51. Gilmer posterior band splint in place.

themselves as preferable which are most simple of construction, and which take up least space in the mouth, having the requisite strength and other qualities which go toward making a splint serviceable.

For the construction of splints that are to hold the jaws apart, as the Gunning splint (Fig. 48), besides the impression of both arches separately, a "mush bite" should be furnished to the dentist. This is made by taking a mass of beeswax made plastic by heat, which would about fill the patient's mouth back to the last molars, when more than half open. This is placed in the mouth between the teeth, and the jaws are made to shut down upon it until the relative position of the dental arches that is to be maintained by the splint is obtained. In making this, the wax should receive a good impression of the teeth in the posterior fragments, while, if a separate impression of them has already been made, the anterior fragment may be disregarded. The wax is removed without distorting it and immediately placed in cold water. From the "mush bite" the dentist can gauge the proper relationship of the maxillary and mandibular halves of his splint.

One useful form of a dental splint is that devised by Dr. Angle, which is a bar passing across the line of fracture attached to bands on one or several firm teeth on each side (Fig. 49). If several firm teeth on each side are available, this makes a very efficient fixation, but it is somewhat tedious to apply when it is to be attached to a number of teeth. Attached to two teeth, it makes an excellent support for a union that is not strong or for a fracture near the symphysis.

The Kingsley splint (Fracture of the Maxillæ, page 87, Fig. 25) is not ordinarily a very satisfactory splint for the lower jaw, on account of the difficulty of securing it in place; but the Kingsley and other splints of this class—namely, those that have a gutter corresponding to the alveolar arch and exert counter pressure from below the chin—all have the advantage that they can be used on an edentulous or nearly edentulous jaw. The arms on a Kingsley splint that protrude from the mouth may be attached to the plate of an artificial denture, which would convert the latter into a perfect fitting splint.

Dr. HULLIHAN, a dentist, of Wheeling, West Virginia, described a continuous dental splint which he had constructed for a case of resection of the alveolus, which has since often been used for the treatment of interdental fractures of the body (Fig. 50). It may be made of metal or vulcanite, celluloid or hard rubber, and is modeled over a plaster or metal reproduction of the dentures. The splint is supposed to fit accurately, and is cemented into place. Such a splint may include all of the teeth in the arch or an adequate number on each side of the fracture. The antecedent of this splint was a metal gutter that, in a general way, closely conformed to the outline of the dental arch. Wire ligatures were placed upon appropriate teeth, and the ends of the wires were passed through the corresponding holes in the bottom of the gutter. The splint was filled with some sort of soft material or

wax that would set, and, having been forced into place, was held by twisting the wires together. Such a splint can be constructed by a tin-smith, and might be useful when a better one cannot be obtained, but today there are few communities where the services of a skilled dental technician cannot be procured.

Considering its comparative simplicity of construction, its ease of application, and its comfort to the wearers, the best and most effective of all splints of this class is the Gilmer posterior band splint (Fig. 51), the description of which we quote from the author :

"The least complicated splint that I have seen, and one by means of which I have achieved success in the treatment of single fractures, is what I have named the posterior band splint, and was devised by the author in the treatment of his first case of fracture in 1872. Although it does not permit the use of the jaw as some others do, this splint has an advantage in its simplicity and claims favorable notice from the fact that it allows the occlusion to be seen at all times. The posterior band splint is made by modeling the required shape in wax on the lingual side of the cast of the teeth and jaw, extending from the last tooth back on one side to the last tooth on the other, and from the grinding surface down on the jaw as far as a plate of teeth is usually allowed. It does not irritate the tissues like a set of artificial teeth, as no pressure is brought to bear upon it downward, and muscular action does not interfere to cause inflammation, as the muscles are at rest, or as nearly so as possible, while the splint is held securely in place by being fastened to the teeth. After being modeled, it is reproduced in vulcanite. When the piece is finished, holes are drilled into it so it can be wired to a number of the teeth, or to all, if thought necessary. The fracture is reduced by its application to the teeth and jaw, where it is securely fastened to the teeth by wiring. The jaws are brought together and held loosely by any suitable bandage. In a majority of cases, either by the loss of a tooth or space between the teeth, there will be sufficient room for the passage of a liquid diet. No fear of poor adjustment need be apprehended therefrom, as the upper and lower teeth will be occluded at all times, except when the patient is taking nourishment, and then but slightly parted. After a week, muscular contraction will be sufficiently overcome, under favorable circumstances a soft union will have taken place, and although the splint be removed for a short time, the fragments are not liable to be again displaced; however, it is not advisable to remove it, but the bandage may be still more loosely worn and liquid diet changed for semiliquid. With this splint the occlusion may be seen at any time after its application, and it may be ascertained whether it is correct or not; and if not, the work may be done over before it is too late. The teeth may be cleansed on their buccal surfaces at any time, and on their grinding surfaces after a week or ten days, since after this period the bandage may be removed for a few minutes with entire safety."

In using this splint, we have dispensed with the bandage almost from the first.

Effective splints of the character we have been considering, those that fix the fracture by means of splints attached to the teeth in the

broken jaw, have in common this advantage over wiring the jaws together—that they allow movement of the jaw almost throughout the treatment—but with the exception of the Kingsley and other splints that make counter pressure from the under surface of the chin, they are only applicable in cases of interdental fracture, with firm teeth in each fragment. If it is desired to overcome the pull of the chin muscles by dressing the mouth open, it may be done by the plan shown in Figs. 52 and 53.

In the description of the methods here given, no attempt has been made to include all of the splints, or the devices that have been pro-

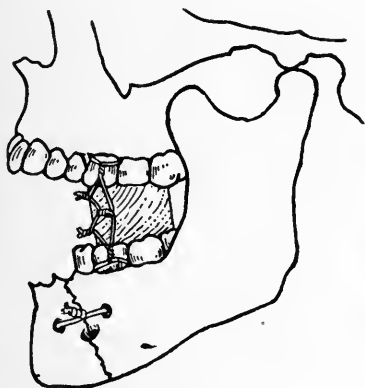

Fig. 52.

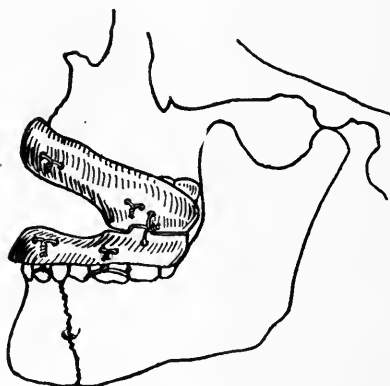


Fig. 53.

Fig. 52. Showing a block wired in place that keeps the posterior fragment depressed. This block may be utilized in fixing the lower jaw while making a section of the bone in the bicuspid region, and also to hold the mouth open after an operation to overcome restricted movement of the jaw.

Fig. 53. Showing a modification of the Gunning splint that may be used for any case in which the jaws are to be held apart. This is made in two pieces, which are fastened together after each half has been fixed in place. Its application is very much simpler than is that of the original Gunning splint.

posed or contrived. They are almost innumerable, some of them too simple to be efficient, and others quite fantastic in their complexity (one apparatus described included a corset, an intrascapular pad, an occipital pad, a jury mast, a chain, and a jaw piece, while various kinds of extension apparatus with weights and pulleys, or head pieces, are still being presented), but most of them are predecessors, modifications, or combinations of some one or more of the methods here described. By some one, or a combination of several of these, the fragments in almost every conceivable fracture can be held in position. Wiring the lower to the upper jaw, either by the teeth or by a wire passed around the lower jaw and fastened to the upper teeth, and when necessary, wiring the bones directly are the only plans of treatment that we now resort to in the treatment of fractures of the lower jaw.

**Care of the Tissues.**—Fractures of the body are nearly always compound, the possible exceptions being fractures in jaws that are without teeth at the site of fracture. Whether or not an open fracture of the body will become infected depends largely upon the amount of injury to the coverings of the bone and the amount of separation.

Fractures of the ramus or its processes are usually not open fractures. In every fracture of the body where there has been a distinct separating or splintering of the fragments, it is a safe procedure to drain externally by inserting a small drain through a stab wound, that

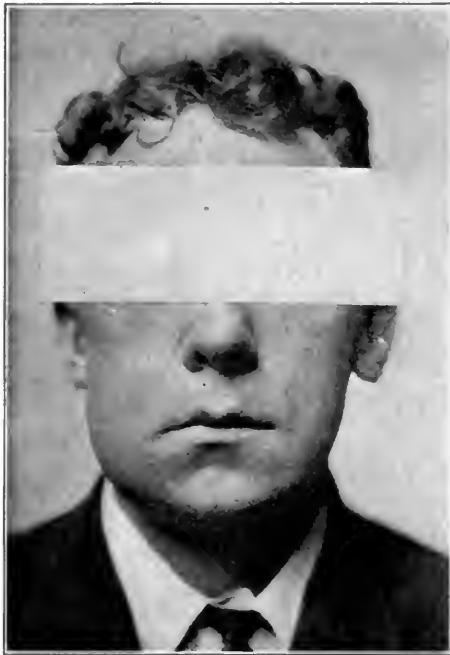

Fig. 54. Showing characteristic swelling that frequently occurs and often persists for months after an infected fracture. This may take place without any evident suppuration at the site of fracture. It is prevented by immediate drainage of the fracture as described above.

will communicate with the break, made under the jaw or chin. If suppuration does not supervene, the drainage wound will close without leaving a noticeable scar. If suppuration occurs, the bone and the soft tissues will both be conserved by this puncture. It can be done with a local anesthetic. (Fig. 54). The inferior dental artery may be torn across, but the bleeding will cease on adjusting the fragments. No attention is to be paid to an injury of the inferior dental nerve. If neuralgia should follow, it should be treated as outlined in Chapter XLII.



An ice bag applied for a few days over the site of fracture so as to keep the skin cool, not cold, will limit the inflammation and usually relieve pain. (For the care of accompanying injuries of the soft parts, see Chapter V.) Except for some special reason, no piece of bone that is still attached to the soft tissues should be removed. The establishment of drainage from below will give an attached fragment a fair chance to live and unite.

In open fractures that are seen, after suppuration has set in, free external drainage should be made from below, but fragments of bone should not be removed until they have become completely detached. Unless they are very large, they will usually work their way out from above or below. Except where it absolutely interferes with the approximation of broken ends, no loosened teeth should be removed. If too loose to maintain their position of themselves, they should be ligated in place. A tooth that has been avulsed may, under appropriate circumstances, with proper treatment be replaced. (See Injury of the Teeth and Alveoli, Chapter VI.)

The tissues themselves having been cared for, the next indication is the restoration of the broken bone to its normal outline.

**Treatment of the Individual Fractures.**—The most common site of a fracture is in the neighborhood of the mental foramen. Such a fracture may be associated with fractures in any part of the bone, often in a corresponding site, or just in front of the angle on the opposite side.

For the treatment of most single or double fractures in the anterior part of the body, a general anesthetic is not required. It is not required for fractures of the angle where the fragments are not held rigidly in a false position. In most cases where the bones are to be wired or fixed by plates, a general anesthetic is preferable, and in a fracture near the angle where the posterior end of the body is locked behind the upper molars by a spasm of the muscles of mastication, a general anesthetic may be indispensable.

There is usually little difficulty in manipulating an anterior fragment into place. When in a fracture at the angle the chin is depressed and the body is locked behind the upper teeth, the displacement can be overcome by placing the thumb on the occlusal surface of the molars with the fingers underneath the jaw and depressing the posterior end of the fragment as it is drawn forward.

In restoring the fractured arch, the occlusion of the teeth should be the guide to the position in which the fragments are to be placed (Figs. 55 and 56). This occlusion can always be determined by observing the facets that have been worn on the occlusal edges. When there is loss of bone, a new occlusion may have to be established.

In fractures through the canine fossa, owing to the fact that the incisor teeth are easily drawn from their sockets by the constant upward pull, it is sometimes impossible to hold the mental fragment up to occlusion. Success is more apt to follow if the strain is distributed over all of the teeth in the mental fragment, but it may be necessary to treat the fragment with the mouth open, or to pass a wire around the body of the bone, as described under methods (Figs. 40, 52, 53).

To fix the mouth wide open is, for a time, a hardship to the patient; but an opening of 1 or 2 centimeters is, as a rule, all that is needed, and this can be maintained with no great discomfort.

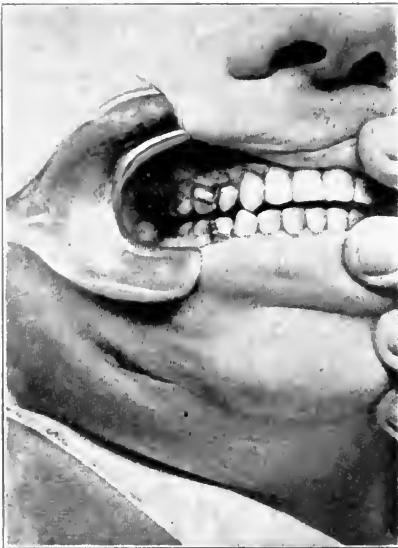

Fig. 55.

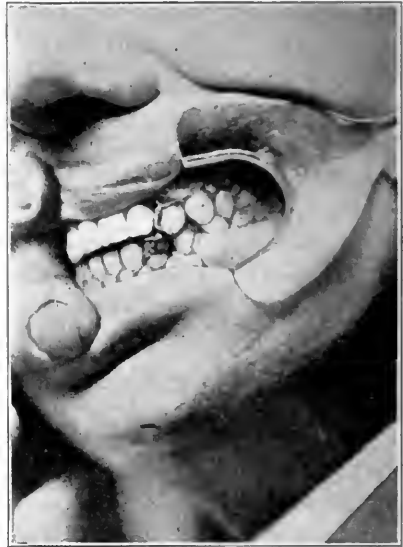

Fig. 56.

These two photographs illustrate a case of fracture of the lower jaw between the bicusps on the patient's left side, in which the right lower cuspid was placed behind (distal to) the upper cuspid. As a result, it will be seen that the teeth cannot come up to proper occlusion. When the teeth are brought into proper occlusion, it is usually very easy to hold them there, but it is often difficult to prevent further displacement when the natural occlusion is not established. These photographs are presented to emphasize the necessity of reestablishing the natural occlusion wherever possible. No dentist would ever make such a mistake, but it is one into which a surgeon may easily fall.

The deformity that usually results from the inadequate treatment of a fracture near the cuspid fossa is a depression of the mental fragment of about 5 millimeters or less at the site of fracture. With a full set of teeth, this is a distinct deformity, but if there are no teeth, this would be hardly noticed. A fracture exactly corresponding to the symphysis would be almost a curiosity. In fractures near the symphysis, there is, as a rule, little displacement; and some sort of a dental split, usually a bar or a wire fixed to two cuspid bands, as proposed by Dr. Angle, is used (Fig. 49).

For a fracture occurring anywhere behind the last tooth, dental splints are, of course, of no use. Here the body of the mandible is best held in place by wiring it to the upper jaw, and the treatment of the posterior fragment will depend upon the direction and character of the break. If the line of fracture is transverse from within outward, the posterior fragment will require no special attention; but if the fracture is oblique, then, if the periosteum is torn, there may be a forward, an upward, and an inward or outward displacement of the lower end of the posterior fragment (Fig. 57). To prevent this, it is usually necessary to wire the bone fragments or fasten them with a plate.

In fractures of the ramus situated within the attachment of the masseter and internal pterygoid muscles, there is rarely a lateral dis-

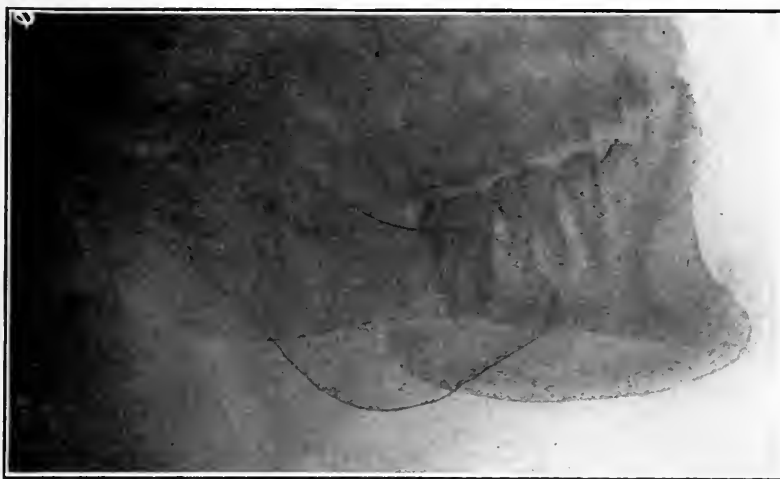


Fig. 57. X-ray showing tilting forward of the ramus in an oblique fracture of the body just in front of the angle.

placement. All that is needed is to give rest by fixing the lower to the upper jaw (Fig. 36).

Fractures of the coronoid process are the rarest of all and are usually associated with a fracture of the neck of the condyle. Such a fracture of itself would require but little treatment except fixation of the lower jaw for the control of the pain. If such a fragment were to later interfere with proper movement of the jaw by becoming attached to a fractured condyle, the coronoid could be removed.

When symptoms are present, a fracture of the neck of the condyle should be treated by fixing the lower to the upper jaw. If the condyle is drawn forward by the pull of the external pterygoid muscle, the displacement cannot be corrected, but the larger controllable fragment, the whole of the remaining part of the jaw, can be brought forward

to a corresponding position. This is done by fastening an inferior molar to a tooth above and in front of it—as the first lower molar to the first upper bicuspid. The correct position could be determined by an x-ray examination.

**Treatment of Fractures Complicated by Loss of Bone.**—Fractures in which there is considerable bone missing will have to be treated according to their location and the amount of bone lost. Unless the loss involves the full width of the body, these do not present any especial difficulty; for, as long as there are even small pieces of

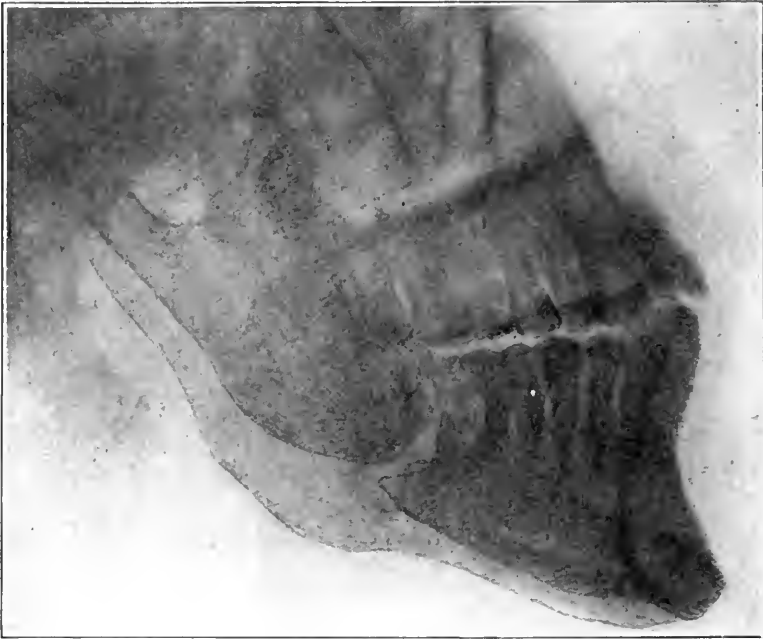


Fig. 58. X-ray showing a case in which there was a considerable loss of bone behind the first molar, and in which the ramus has tilted forward until the ends of the bone are in contact.

nourished bone in contact, these will unite, and sufficient bone usually fills in around them. However, until a strong union occurs, the weak place should be protected from any strain that would cause a refracture. If there are teeth on both sides of the weak place, this can be done by adjusting a dental splint. If the complete loss of substance is not greater than 1 centimeter, and is situated behind the bicuspids, by removing all teeth from the posterior fragment, the latter can be made to tilt forward until it is in contact with the anterior fragment (Fig. 58). In treating such a case, the anterior fragment must be held

fixed in its proper place until a firm bony union is obtained; otherwise it will be pulled around to meet the posterior fragment. It may be necessary in larger gaps to allow some displacement of the anterior fragment. Larger gaps in the lateral part of the body may be remedied by resecting the ramus and carrying forward the posterior part of the body. Gaps in the anterior part of the bone may be filled according to plans given in Chapter XXIX. Loss of substance in one ramus will not cause noticeable deformity or serious interference with function.

### TIME REQUIRED FOR UNION.

This depends upon the character of the fracture, the number of fractures, and the reparative effort of the individual. In single fractures, where there is little suppuration and no appreciable loss of bone, fairly good union usually occurs in three weeks. This will not be strong bony union, but will be sufficient to prevent pain or displacement, and with ordinary care will go on to completion without the aid of splints. While a double fracture should unite as quickly as a single fracture, there is more tendency to displacement, and greater firmness is necessary before the splints can be dispensed with. Such fractures should be kept fixed for at least five weeks. Suppurating open fractures and fractures in which there is considerable loss of bone will require longer fixation. A weak union of an interdental fracture, single or double, can be advantageously braced with a dental splint.

### DELAYED UNION.

Union may be retarded by lack of approximation or by lack of fixation of the fragments, by the interposition of detached bone fragments, by local infection, and by some fault in the vital reparative effort.

Syphilis, tubercle, pregnancy, or any general depression may be responsible for delayed union, but, at times, no cause can be found. Besides specific and tonic treatment, the administration of the extract of thyroid glands is supposed sometimes to influence union favorably. Besides general treatment, the alignment should be preserved by appropriate splints, and the ends of the bone may be irritated aseptically with an awl. Dr. Gilmer suggests that a coarse file be used for this purpose. As soon as a fibrous union that preserves the alignment is formed, splints may be dispensed with, as some movement often stimulates union. Non-union is rare. A genuine non-union might, after all constitutional remedies have failed, be treated by resection and wiring. Several months' trial should be given to simpler means before this is resorted to. In doing this, the least possible amount of bone should be removed from the ends of fragments.

### MALUNION.

Malunion is rarely sufficiently pronounced to warrant interference, but severe deformities should be treated as outlined in Chapter XX.

### FEEDING DURING THE TREATMENT OF A FRACTURE OF THE JAW.

Food and fresh air are important factors in the treatment of any fracture. With a fracture of the jaw, especially if the jaws are wired together, especial attention must be paid to the feeding. With an interdental splint, ordinary soft foods and chopped meat can be taken from the first. When the jaws are wired together, the diet must often be restricted entirely to fluids. Milk or butter-milk, where tolerated, should be given freely. Butter-milk is preferable, both because in quantities it is usually more easily digested by adults and because it does not form large curds in the stomach—if for any cause during the treatment vomiting should occur, large curds could not be ejected from the mouth. Fruit juice, vegetable soups, and meat juice should be given. Five hundred grams of perfectly fresh chopped lean beef with an equal quantity of water, soaked for six hours at an ice-cold temperature, will, when the fluid is pressed out, yield 500 cubic centimeters of rich beef juice which may be taken raw or put into soups. The juice expressed from broiled or baked meats is much more palatable, but not so economical. Of course, no dependence should be placed upon beef teas or clear soups.

## CHAPTER IX.

### DISLOCATION OF THE LOWER JAW.

The mandibular joint is made up of the condyle of the mandible below, and the glenoid fossa and articular eminence on the under surface of the temporal bone above. Posteriorly, the glenoid fossa is bounded by the delicate tympanic plate, which separates it from the external auditory canal. The roof between the glenoid fossa and the middle cerebral fossa is very thin. Between the condyle and the temporal bone there is an intra-articular fibrocartilage that divides the joint into two compartments. It is surrounded by a capsular ligament, while three other ligaments, which are described later, add to its strength (Figs. 59, 60).

#### KINDS OF DISLOCATIONS.

There are four varieties of dislocation at this joint that have been described: forward, which is the ordinary form, and usually uncomplicated by any fracture; and an upward, a backward, and an outward dislocation. Instances of the occurrence of any of the latter three varieties are extremely rare, and each of them is, of necessity, accompanied by a fracture. Albert states that the condyle may be dislocated backward below the external auditory canal, which could occur without a fracture. For convenience, the latter three will be considered first.

**Upward Dislocation.**—A severe upward blow on the chin while the mouth is open, or an upward blow under the angle, if the upper or lower posterior teeth are missing, might drive one or both condyles through the roof of the glenoid fossæ into the skull. In such an injury the movement of the jaw would be limited, and the ramus would be apparently shortened. Le Fèvre reports such a case.

Treatment would consist in trephining above the glenoid fossa, extracting the condyle, and possibly draining the middle cerebral fossa. The mandible could be retained in position by appropriate dental fixation. In one case of partial upward dislocation we simply wired the jaws together for five weeks.

**Backward Dislocation.**—A backward blow on the chin while the mouth is closed might drive the condyle against the tympanic plate with such force as to crush it into the external auditory canals. The chin would recede, and there would probably be bleeding from the ca-

nals; and an examination with an aural speculum would show obstruction of the canal. The condyle would be felt, or, with an x-ray examination, would be seen to be in an abnormal position. If the backward dislocation is unilateral, the chin will deviate to that side.

Treatment will consist in drawing the jaw forward and retaining it by dental fixation. (See methods under Fracture of the Mandible, Chapter VIII.) An attempt should be made to restore the auditory canal.

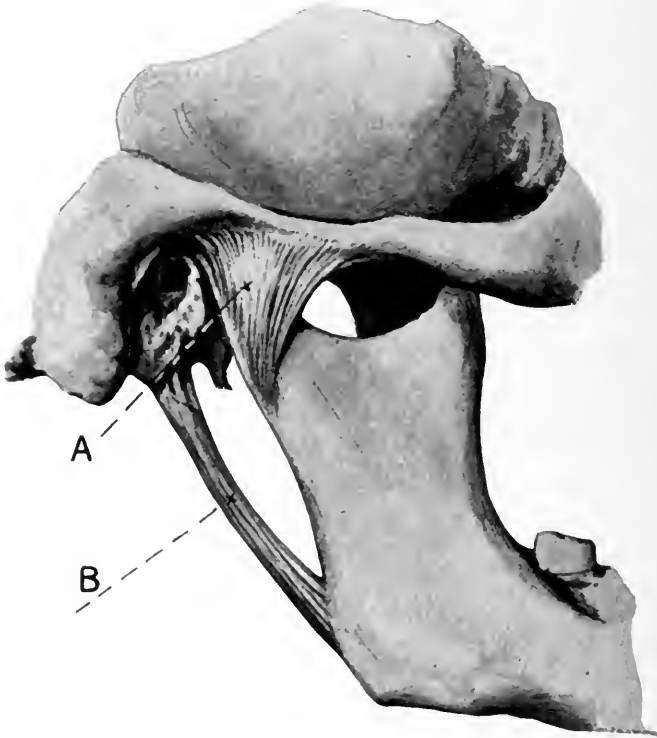


Fig. 59. Ligaments of the temporomandibular joint viewed from the external surface. A, capsular ligament; B, stylomandibular ligament.

**Outward Dislocation.**—Robert has reported a case of outward dislocation. The body was fractured in front of the angle, and the condyle was to the outer side of and above the zygoma. To reduce the dislocation, the ramus was pushed outward until the condyle was freed from the zygoma, and the condyle was pushed down and into place. The jaw should then be treated as in a fracture in front of the angle.

**Forward Dislocation.**—Even this form of dislocation is comparatively rare, and is more frequent in females than in males. It has



occurred as the result of drawing on the jaw in an attempt to deliver the head in difficult labor, but it is much more rare in children and in elderly people than in the prime of life. When the jaws are closed, the condyle rests in the glenoid fossa; but as the mouth opens, the axis of motion being in the neighborhood of the inferior dental foramen, the condyle travels forward on the articular eminence. If from any cause the condyle is forced but a little past the crest of the eminence, usually without a rupture in the capsular ligament, it may become locked in that position. This constitutes an anterior or the common dislocation of the jaw. The determining cause is usually an over-activity of the external pterygoid muscle, assisted possibly by the posterior fibers of the masseter, when the mouth is fully open. More rarely it is due to a backward blow on the chin when the mouth is

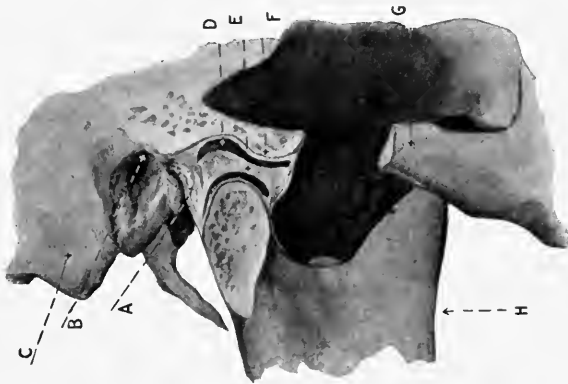

Fig. 60. Temporomandibular joint. A, capsular ligament; B, external auditory canal; C, mastoid processes; D, upper joint compartment; E, intra-articular cartilage; F, articular eminence; G, zygoma; H, mandible.

open, which, by forcing the body and lower part of the ramus backward, at the same time throws the condyle forward. The jaw has been dislocated in the act of drawing a tooth, but in this case the dislocation is more probably due to muscular action, or from opening the mouth too widely, than from the force used in the extraction. A unilateral dislocation has been produced by a blow on the posterior border of the ramus.

The amount of displacement varies greatly in different cases. In a few the coronoid process has become engaged under the malar bone, and this has been regarded by some as the factor that prevents reduction in all instances, which is true probably in but a very small percentage of cases. The condition in most anterior dislocations of the jaw does not differ materially from that in a dislocation of the hip or shoulder. In each of these joints the head of the bone is held in

a socket by the tension of the muscles and ligaments. If the head once crosses the raised border that surrounds the socket, the same muscular and ligamentous pull holds the head in its new position, and it is only by some manipulation that either relaxes or overcomes this muscular ligamentous pull that the head can be returned to its socket. This view with reference to anterior dislocation of the jaw has been expounded at various times, but it is most clearly presented by Dr. Lewis A. Stimson in his classic chapter on dislocations of the lower jaw; and we are in such full agreement with the views which he holds that we cannot help following his text rather closely. Perthes and Albert express no opinions radically different from those of Stimson, and in the main corroborate his views.

Besides the capsular, the joint is protected by three other strong ligaments: the stylo-mandibular, extending from the styloid process to the posterior border of the ramus; the external lateral, closely incorporated with the capsular ligament; and the internal lateral, which is attached above to the spine of the sphenoid and below to the spine of the mandible. Of these the external is the shortest and strongest, and is most closely concerned in maintaining the head in its false position when it becomes dislocated anteriorly, the other ligaments contributing. When the condyle occupies the glenoid fossa, the direction of the external ligament is downward and backward. As the condyle travels forward, the point of attachment of the ligament on the neck assumes a position directly inferior to its upper attachment. This would allow the ligament to become slack if the plane of the posterior surface of the eminence were not downward and forward. When the head reaches the crest of the eminence, the neck of the jaw and the ligaments are in the same plane, and the latter is tense (Fig. 59). For the head to travel farther forward without rupture of the ligaments, the axis of motion must, for the moment, change from near the entrance of the dental canal to the point of insertion of the external lateral ligament. The head first tilts forward on this new axis, and then by the continuance of the force slides onward, carrying the inferior attachment of the ligament with it until the ligament is again taut. Where an anterior dislocation has occurred, the direction of the combined pull of the muscles of mastication is such as to hold the lower attachment of the ligament forward. The muscles of mastication can no longer tilt the head backward, as they do under normal conditions, for now, with the ligament serving as a fulcrum, the posterior surface of the head is jammed against the eminence by the temporals, the internal pterygoid, and the anterior part of the masseter, thus pulling forward and upward on the long end of the lever. It is probable that in most anterior dislocations the ligaments are

not ruptured. Perthes holds this view, and Albert quotes Schnitzler as being unable to tear the ligaments in producing a dislocation on the cadaver. There are, however, undoubted instances where the capsule has been torn, and it is likely that this occurs in all cases of primary dislocation where the head travels well forward of the eminence. In these instances the head is held in its new position by the muscles and the stylo-mandibular and internal ligaments. The position of the meniscus in an anterior dislocation is a matter of some uncertainty. It is probable that it usually remains in place, the condyle slipping in front of it, but in some recorded instances this has not been the case. It is a very old idea held by Hippocrates, and many others since his time, that reduction is prevented by the coronoid becoming engaged under the malar bone. While there is on record one undoubted instance of this occurrence, it is rare. According to Perthes, however, in 50 per cent of cases the coronoid coming in contact with the zygoma helps to prevent the closure of the jaws.

**Symptoms of Anterior Dislocation.**—The mouth is at first held open, and chewing is impossible. The chin is slightly forward, swallowing and talking are difficult, and the muscles are usually tense. Most important of all, the absolute sign, the condyle may be felt, or seen by means of the x-ray, to be in advance of its natural position. In a unilateral dislocation, the chin deviates to the opposite side.

### TREATMENT.

The treatment consists in reducing the dislocation and holding the head in the socket by artificial means until the stretched or torn ligaments have time to unite or recover their normal tone. Reduction may be accomplished in one of two ways: (1) by traction that forces the ligaments and muscles to yield sufficiently to allow the head to pass the obstruction and slip into the socket, or (2) by manipulations that bring the head, in reverse order, into the various positions which it assumed while leaving the fossa. The latter course is the preferable way, requiring less force and inflicting less pain; while the former, by stretching the lateral ligaments, might inflict more damage to the joint than was sustained at the original injury.

**Reduction by Traction.**—This is accomplished by grasping the body of the jaw on each side, with the thumbs on the occlusal surfaces of the molars, and, while making downward traction on the rami, making an attempt to raise the chin and push the condyles backward into the sockets. The attempt may be made on one side at a time. In doing this, the thumbs must be protected by a thick wrapping of gauze, or otherwise they may sustain injury when the jaws snap together. If the reduction cannot be done with the unaided hands, as suggested

by Gilmer, a stout stick may be placed in the mouth, one end of which rests on the inferior molars of one side, while the upper molars on the other side are used as a fulcrum, and in this way the ramus may be pried downward. The teeth should be protected by rubber tubing or gauze while this is being done. The reduction is facilitated by an anesthetic.

**Reduction by Manipulation.**—It is not an uncommon occurrence for an anterior dislocation to become reduced spontaneously, and as Stimson points out, the most gentle methods that have been found successful are those which carry the condyle back through the positions it assumed while leaving the socket. In many instances, however, these manipulations were carried on without a true understanding of the mechanism that hindered reduction. Hippocrates supposed that reduction was prevented by the coronoid being engaged on the malar bone; and in order to free it, he depressed the chin and pushed the jaw backward, at the same time encouraging the patient to voluntarily relax the muscles. Galen and others have followed this method. For the most part, however, it was lost sight of, and the practice of using force to overcome the muscular and ligamentous resistance, as described above, has for a long time been the one now widely adopted. Maisonneuve, in 1862, after a careful study concluded that muscular spasm and the resistance of the ligaments prevented the reduction, and that these could best be overcome by direct backward propulsion after opening the mouth more widely. The spasm of the muscles should be overcome, either with the assistance of the patient or by aid of an anesthetic; and the ligaments are relaxed by depressing the chin and pushing backward on the rami. The theory of this is: that as the chin is depressed the lower end of the rami travels upward and backward, which relaxes the ligaments and disengages the condyle from the eminence. As the backward pressure on the rami is continued, the head glides over the crest of the eminence, and the reduction is complete. In some cases all methods short of cutting down upon the joint will fail. In one case reported by Stimson, the meniscus had become detached and was folded up in the glenoid fossa, preventing the head from entering. (For the technic of exposing this joint, see Chapter XXI.)

**Retention.**—When the dislocation is reduced, means must be taken to prevent its recurrence. The head cannot become dislocated until it rises up on the eminence, which does not begin until the mouth is opened at least 1 centimeter. This can be done, as suggested by Stimson, by the use of a head-to-chin bandage for three weeks. A very much neater way is to band an upper and lower tooth, a canine or first bicuspid, and unite them with a strand of braided silk that will allow the jaws to separate 1 centimeter. For an acute dislo-

cation this must be worn for three weeks. The silk or silkworm gut strand may have to be removed every few days, but if necessary, the patient can be taught to do this himself.

### UNREDUCED DISLOCATIONS.

According to Stimson, the prognosis of an unreduced anterior dislocation is not bad. The condyle and ligaments adopt themselves to the new position. Reduction should even be attempted some time after the dislocation has occurred. If function is poor, the joint should be opened, the fossa cleared, and the condyles replaced. If this cannot be done, both condyles may be excised. Mazzoni excised both condyles in one case eight months after the injury with good functional results. (For technic, see Chapter XXI.)

### CHRONIC DISLOCATIONS.

If proper means are not taken to prevent its recurrence, a dislocation may become chronic, the condyles slipping forward at any time when the mouth is widely opened. For such a condition Annandale opened the joint and stitched the meniscus to the periosteum in two cases. We think a simpler method of treating such a condition is to limit the motion of the jaw, as described above. We once had a patient wear this appliance for three months with good results.

### SUBLUXATION.

It is not an uncommon condition for the condyle to catch every time the mouth is widely opened and to recede with a cracking sound. In older persons it may be due to an antritis, but in young persons, with lax ligaments, it is in most cases either a subluxation or a catching of the meniscus. Besides general tonic treatment, the movement of the jaw may be limited until the ligaments regain a healthful tone.

## CHAPTER X.

### CONGENITAL FACIAL CLEFTS.

The general relation of open facial clefts to the embryonal fissures has long been established; but there are certain points that are still the subject of discussion, and the cause or causes of their partial non-closure are still to be determined.

### MORPHOLOGY.

After the fifteenth day from conception, the cavity, from which will be formed the future mouth and nose, is bounded above by a tubercle

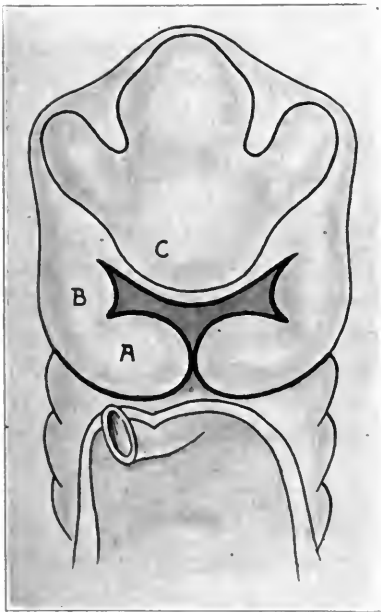


Fig. 61.

Fig. 61. Head of fetus at end of fifth week (after His). C, frontonasal process; B, maxillary process; A, mandibular processes.

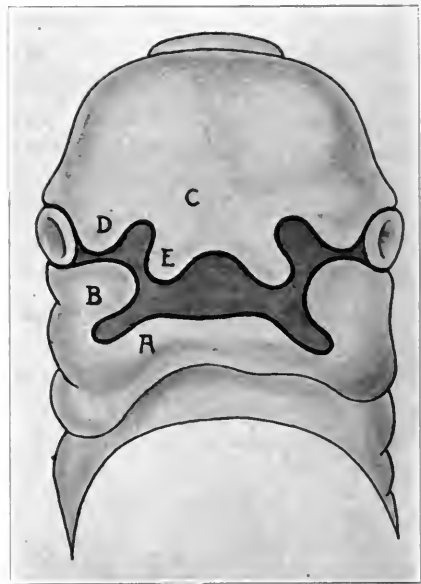


Fig. 62.

Fig. 62. Head of fetus in the seventh week (after His). A, the now united mandibular processes; B, the maxillary process; C, frontonasal process; D, lateral nasal process; E, globular processes attached to the nasal part of the frontonasal process. The central nasal processes are separated from the lateral on each side by the lateral nasal grooves, which represent the anterior nares.

projecting from the anterior part of the head, called the fronto-nasal process, and on each side by maxillary processes (Fig. 61). The

mandibular processes join in the midline about the fifth fetal week, and they together form the lower jaw, which represents the first pair of visceral arches. The maxillary processes do not meet in the midline, but remain wedged between the frontal and the mandibular parts. The cavity is now bounded below by the mandible, laterally by the maxillary, and above by the frontal processes. About this time there appear on the lower end of the developing frontal process three tubercles, which are in turn called the central and two lateral processes. Each lateral tubercle is separated from the central by a short fissure called the lateral nasal groove, or olfactory pit (Fig. 62). Farther on the lower border of the central processes are developed two other tubercles

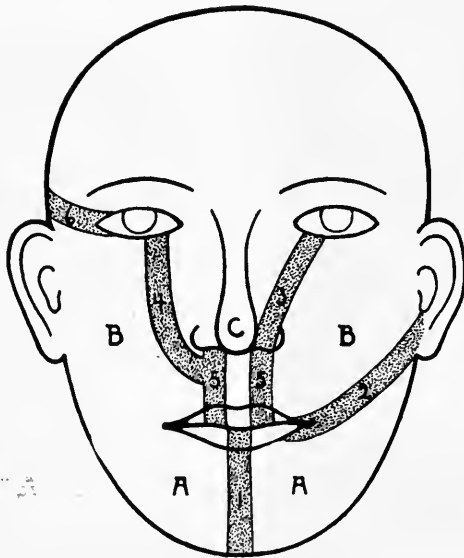


Fig. 63. Schematic diagram, modified from Merkel, showing plan of facial clefts.

which are called the globular processes, and these are separated from each other by a single central groove. From the frontonasal process with the nasal processes will be formed the forehead, external nose, and central part of the lip.

The maxillary processes are separated from the frontal, which now include the lateral nasal and globular processes, by the orbital fissure which extends to the mouth, in the upper part of which the eye is developed. Somewhere below its middle the orbital fissure is joined by the lateral nasal groove, and together they have been described by Merkel as a Y-shaped cleft.

The lower single limb of the Y opens into the mouth; while the external upper limb extends to the eye, and the upper median limb is the

lateral nasal groove which separates the lateral nasal from the central nasal process. The frontonasal and maxillary processes are separated from the lower jaw by a transverse fissure, the median part of which will be the future external mouth slit.

By the non-closure of any part of the Y-shaped fissures, the transverse mouth fissures, or the cleft that existed in the midline between the mandibular processes, or the median groove between the globular processes are produced any and all of the typical face clefts which are here schematically illustrated by a slightly modified diagram from Merkel (Fig. 63).



Fig. 64.

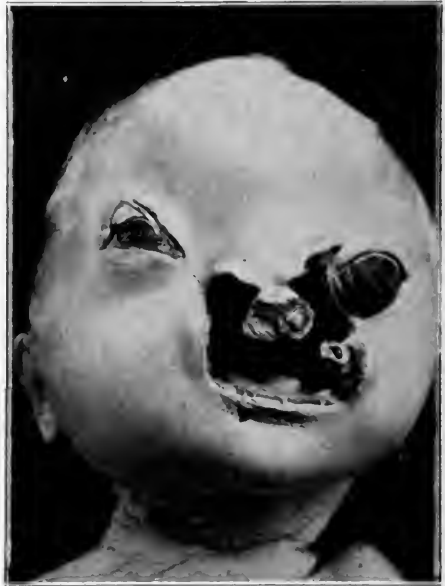

Fig. 65.

Fig. 64. Diagram of oblique facial cleft. The cleft shown in this diagram corresponds to the cleft 5-4-6 in Merkel's diagram (Fig. 63).

Fig. 65. Oblique facial cleft, complete into palpebral fissure on subject's left side. --From specimen in the Loudon Hospital Museum, photographed for this book, by courtesy of the curator.

**Types of Clefts.**—If the maxillary fails to unite with the frontal process throughout the entire extent of the fissure, there will be a cleft extending from the mouth through the lateral part of the upper lip to the eye and possibly beyond: obliquely facial cleft (Figs. 64, 65). If the maxillary fails to unite to the globular process, there will be a cleft extending through the lateral part of the lip toward or into the nostril: ordinary harelip (Figs. 66, 67). If the two globular processes fail to unite with each other, there will be a median harelip which is usually only a notch (Figs. 68, 69, and 70). From failure of closure of



the lateral parts of the transverse mouth cleft, an abnormally large mouth slit results: macrostomia (Figs. 71, 72, and 73). Finally, if the two mandibular processes fail to unite in the midline, a median cleft of the lower lip and possibly the jaw and tongue is the result (Fig 74). The failure of closure of any or all of the clefts may be so slight as to leave only a lip notch, or so complete as to involve the whole of the fissure, extending even into the base of the skull and brain, or to the ears or down to the sternum.

In presenting the above, the writer has followed the rather generally accepted theory that the lateral nasal process does not extend down to

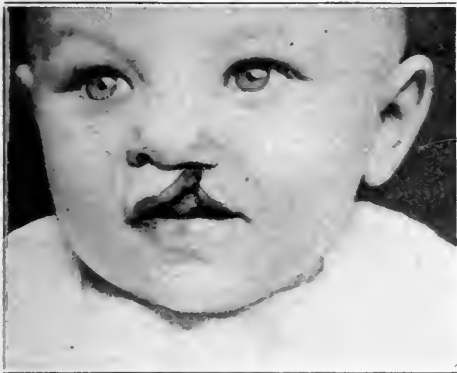

Fig. 67.

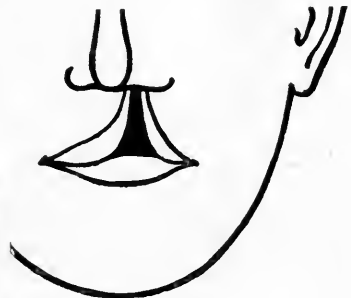

Fig. 66.



Fig. 68.

- Fig. 66. Diagram of ordinary harelip.
- Fig. 67. Almost complete single harelip.
- Fig. 68. Diagram of median harelip.

the mouth, that it takes no part in the formation of the lip, and that all lip clefts lie between the globular and the median nasal, and the maxillary processes, but this is one of the points that is disputed by Albrecht and his followers. They maintain that the lateral nasal process extends normally to the transverse mouth slit, that it forms part of the upper lip and the palate, and that a lateral lip cleft runs between it and the globular process. This cannot be absolutely disproved, but it is denied by the majority of embryologists; and Merkel asserts that the lateral nasal process under abnormal conditions remains entirely shut out from the formation of the lip and intermaxillary process. What

happens under normal conditions is not so plain, and the study of cases of oblique facial cleft does not solve the question. In these cases the cleft may extend through the lip directly to the eye, in which event it could be skirting a lateral nasal process throughout its entire extent;

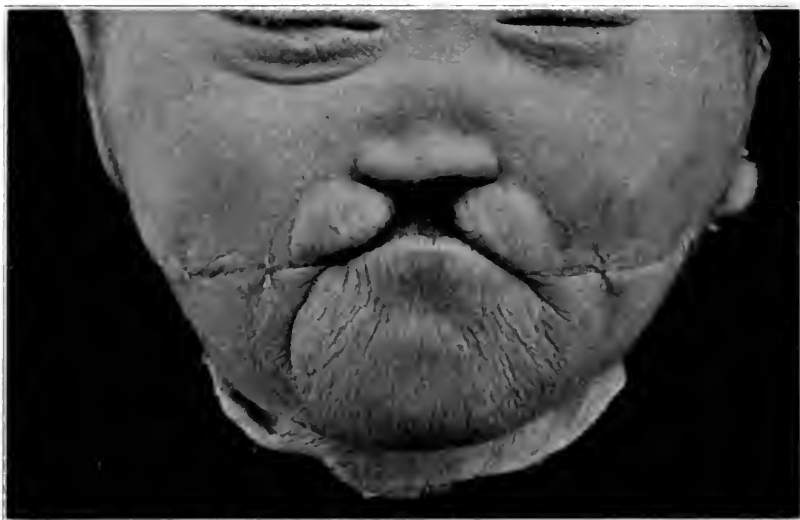

Fig. 69. Median fissure of upper lip due to absence of the intermaxillary processes.—From specimen in the Royal College of Surgeons Museum, London, photographed for this book, by courtesy of the curator.

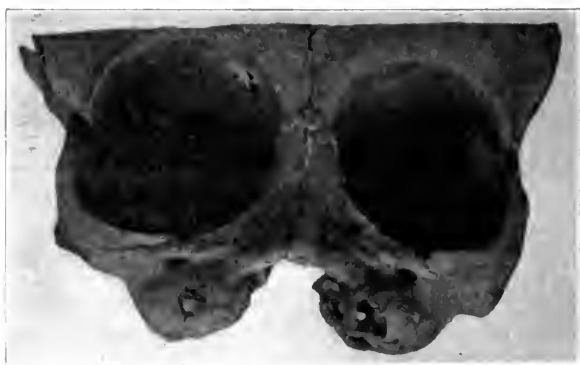

Fig. 70. Skull from specimen shown in Fig. 69.—From a specimen in the Royal College of Surgeons Museum, London, photographed for this book, by courtesy of the curator.

or it may extend through the lip into the nostril, and then around the ala to the eye, which would be utter disregard of any part of the lateral nasal process below the ala. These two varieties of facial cleft are depicted in Merkel's diagram (Fig. 63). The relation of the lateral

process to the lip and palate will be again considered with clefts of the latter.

The palate is a part of the face. Its anterior portion as far back as the incisive fossa is formed by the frontonasal process. The maxillary processes through their palate ridges extend to the midline be-



Fig. 71.

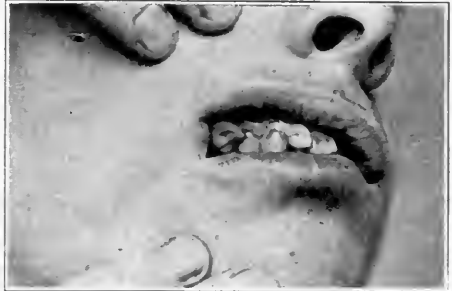

Fig. 72.

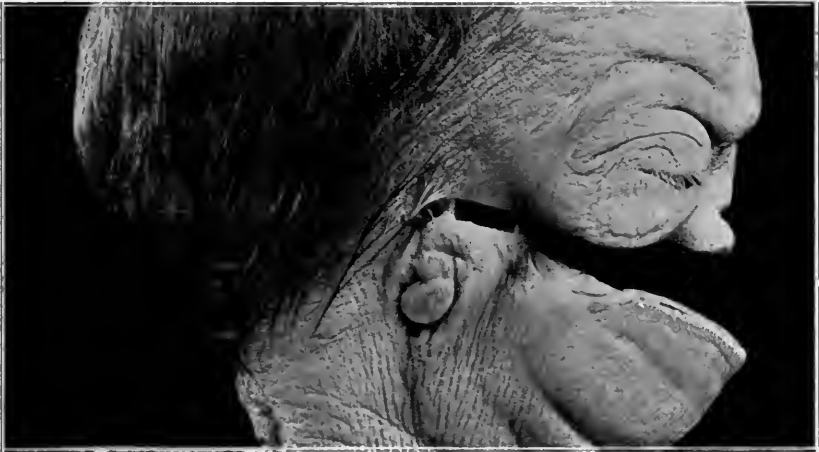

Fig. 73.

Fig. 71. Diagram of macrostomia.

Fig. 72. Macrostomia. Less degree than in the preceding.

Fig. 73. Macrostomia. The oblong opening behind the mouth slit is from the removal of a piece of tissue for examination.—From specimen in the Royal College Museum, London, photographed for this book, by courtesy of the curator.

hind the frontonasal process and form the remainder (Fig. 75). The palate, therefore, is made up of three parts which were originally separated from each other by another Y-shaped fissure. The vertical stem of this Y was posterior and lay between the two maxillary parts, while the two short oblique arms were anterior and separated the palate surface of the frontonasal process from the palate surface of the maxillary

processes (Fig. 76). These and face fissures are but different views of the same through-and-through clefts.

If the whole of the Y-shaped palate fissure fails to close, there results a complete cleft which is double anteriorly, while partial failures cause lesser clefts in various parts. These clefts will always be median behind the anterior palatine fossa and will be lateral in front of it, un-

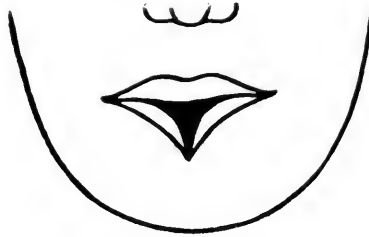

Fig. 74. Diagram of cleft of lower lip.

less there has been a complete failure of union between the globular processes, in which case there might be a median anterior palate cleft corresponding to median cleft of the upper lip. Such clefts are referred to by Lannelongue and Witzel. This anterior median palate cleft is the rarest of all typical clefts.

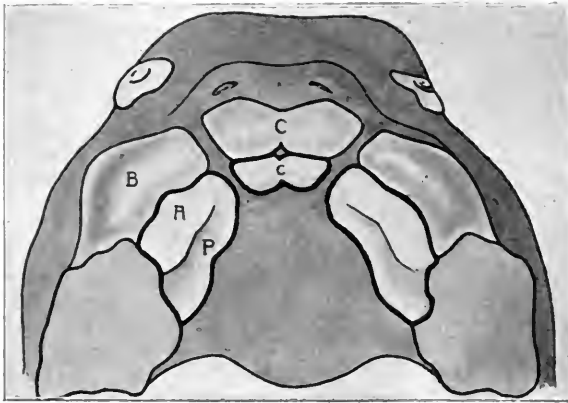


Fig. 75. Diagrammatic reconstruction of the palate in the sixth fetal week. C, C, intermaxillary part of the palate and central part of the upper lip derived from the frontonasal process; B, lateral part of the lip; A, alveolar process; P, palate process; all derived from the maxillary process.

We have had one median cleft, which was possibly due to a lack of development of the globular process. The cleft in the alveolus was median, but the columella had a slightly lateral attachment. There have been a few instances, where the two sides of the nose have been separated by a median longitudinal furrow, extending from the lip to the frontal bone. The exact embryological significance has not been

demonstrated. A mild form of this condition is sometimes seen in pointer dogs.

The part of the palate that is derived from the frontal process is represented by the intermaxillary bones and their mucous covering. These are continuous with the nasal septum which is derived from the same source. Later the septum joins the palate ridges when they meet in the midline, and thus the nose and mouth are separated into three cavities.

If the palate ridges fail to unite with each other, the nasal septum will also fail to unite with one or both of them, and through the resulting median cleft, the mouth cavity will communicate with one or both nasal fossæ accordingly. While embryologically the cleft is median

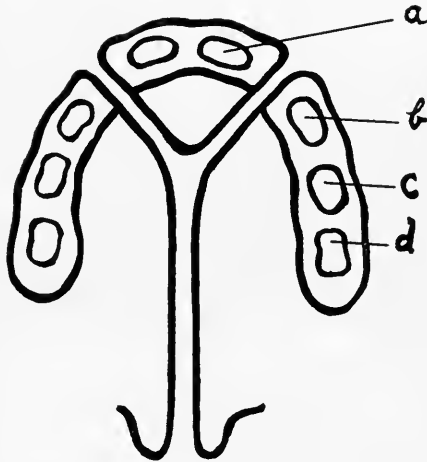


Fig. 76. Diagram showing Y-shaped complete cleft of the palate: a, central incisor; b, canine; c, first molar; d, second molar.

behind the incisive fossa, it is often thrown to one side by the greater development of one palate ridge.

Closure of the palate fissures occurs first anteriorly and extends backward, the two halves of the velum being the last to unite. It is complete in the ninth week, and any agency that interferes with the closure must have acted before this time.

#### RELATION OF THE ALVEOLAR CLEFT TO THE TEETH.

The varying position of the cleft in the alveolus with regard to the incisor teeth has been a subject of interest and the cause of much discussion. In the majority of instances, the lateral incisor is missing, and the cleft lies between the central incisor and the canine tooth. There may be two incisors in front and a canine behind, or the cleft may extend between two incisors, or there may even be two incisors

in front and a third incisor behind the cleft. Finally, there are reported at least two instances in the human and one in a dog in which the cleft ran behind the canine.

**Ferguson's Theory.**—The lack of an incisor at the site of the cleft was explained by Sir William Ferguson by the supposition that

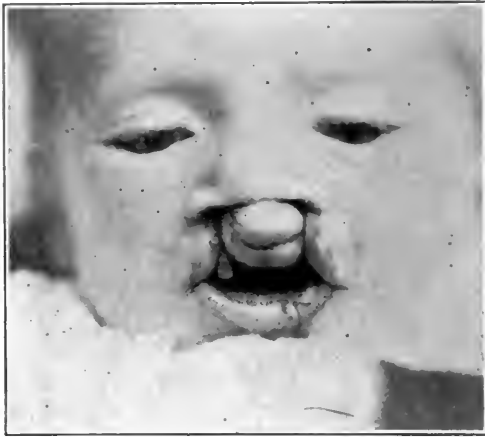

Fig. 77. Case of complete double cleft in which at birth a tooth hung from the lateral margin of the alveolar cleft by a thin pedicle of soft tissue.

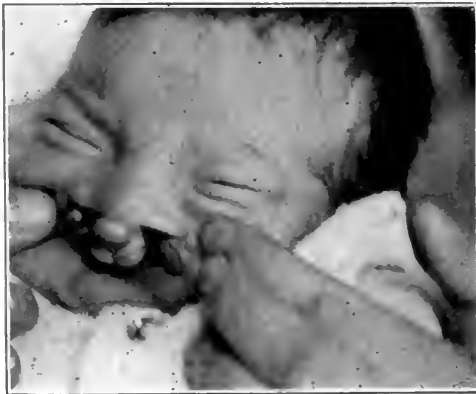

Fig. 78. Case of complete double cleft, in which tooth buds protruded from the outer border of the alveolar cleft on either side.

it had been lost in the cleft; and in this he is supported by Warnikros, and our observations demonstrate the possibility of such an occurrence. We have seen a number of cases where the tooth buds protruded into the cleft or were suspended by a slender pedicle (Figs. 77, 78).

**Warnikros' Theory.**—When an incisor is missing in a case of cleft of lip or palate that apparently does not involve the alveolar

process, according to Warnikros, it lies hidden in an occult bony cleft that does not involve the gum tissue.

**Kölliker's Theory.**—From Goethe to Kölliker all surgeons adopted the simple view that the cleft ran between the part of the maxilla that is derived from the original maxillary process, and the intermaxillary bone which is part of the original frontal process.

**Albrecht's Theory.**—Later Albrecht advanced the theory that the intermaxillary bone in development consists of not one part on each side, but two distinct pieces, each carrying an incisor, and that the cleft runs between these two pieces. Albrecht's theory is a pure hypothesis, and no direct evidence of each half of the intermaxillary bone developing from two centers has been discovered. However, as Sir William Turner, after discussing the question, has pointed out: "It should not be forgotten that it is quite recently that the embryological evidence of the origin of the intermaxillary part of the human upper jaw from a center distinct from that of the maxilla has been completed, and yet for nearly a century, on such minor evidence as was advanced by Goethe—namely, the suture on the hard palate extending through the nasal surface—anatomists have believed and taught that the upper human jaw represented both the maxillary and intermaxillary bones in any mammal. Where a question of human embryology hinges upon an examination of parts in a very early stage of development, we often have to wait for many years before an appropriate specimen falls into the hands of a competent observer."

Albrecht accounts for the occasional condition of two incisors in front of the cleft as an atavistic development of a third incisor; it is the central incisor that we are supposed to have lost, but a cleft behind the canine finds no place in his hypothesis. The latter condition must be explained on one of two suppositions: either a band has cut into the maxilla behind the canine, or the canine has developed from that part of the dental ledge that attached itself to the premaxilla. The majority of embryologists support the view championed by Kölliker.

Although this varying relation of the incisor teeth to the cleft has, in different instances, been advanced as an argument to support one or the other theory, it is probable that it is not pertinent to the disputed question as to whether each half of the intermaxillary consisted originally of one or two pieces. It seems likely that the original position of the tooth sacs of the incisors is not fixed in regard to the maxillary and intermaxillary processes, and that the papilla, from which the lateral incisor will develop, may spring from either border of the cleft. The dental ledges from which the teeth develop are formed by an infolding of the mucous membrane of the mouth, which occurs in the seventh fetal week. The relationship which it acquires to the

mesodermic tissue of the jaws is a secondary one. In the ninth week distinct evidence of the future separation into individual teeth can be made out. This latter occurs very shortly after the ossific centers of the maxillæ first appear, and a reasonable supposition is that, as the relation of the teeth to the bones is an acquired one, the relation of individual teeth to the cleft is somewhat accidental.

### CLINICAL TYPES OF CONGENITAL CLEFTS.

The deformity that is most commonly brought to the surgeon is complete single cleft of the lip and palate. If the cleft in the lip is



Fig. 79. Double cleft of the lip, incomplete on one side. In this case the alveolar process was cleft only on one side, but posteriorly there was a double cleft of the hard palate. This is a not infrequent occurrence.

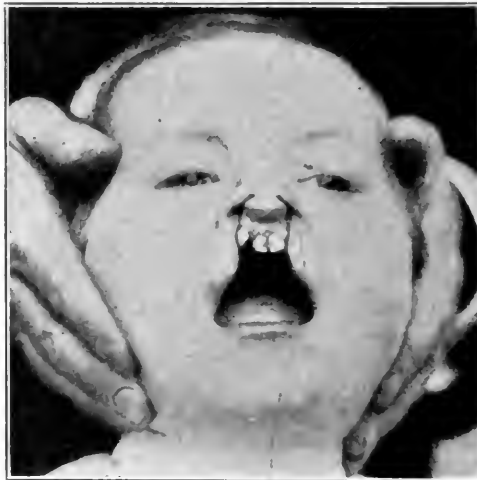

Fig. 80. Complete double cleft of the lip. This is here accompanied by a double cleft of the palate. The intermaxillary bone carries three incisors.

double, it may be incomplete on one side (Fig. 79). If it is a complete double cleft of the lip, there will also almost always be a complete double cleft of the palate (Figs. 80, 63, and 65). Cleft palate may occur without a harelip, or more rarely a harelip occurs without any bony cleft; but it often accompanies a cleft limited to one side of the alveolus.



Cleft of the velum alone is common enough, but cleft of the midpart of the palate with intact velum is very rare. Oblique facial clefts.

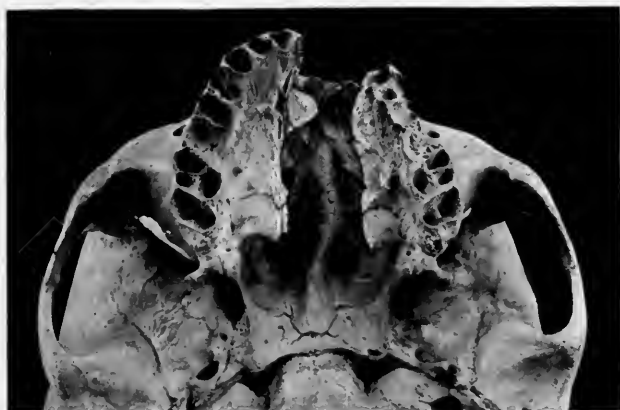

Fig. 81. Skull of an adult who had a complete single cleft of the lip and palate. This deformity had never been corrected as shown by the lack of approximation of the alveoli at the anterior part of the cleft.—From a specimen in the Royal College of Surgeons Museum, London, photographed for this book, by courtesy of the curator.

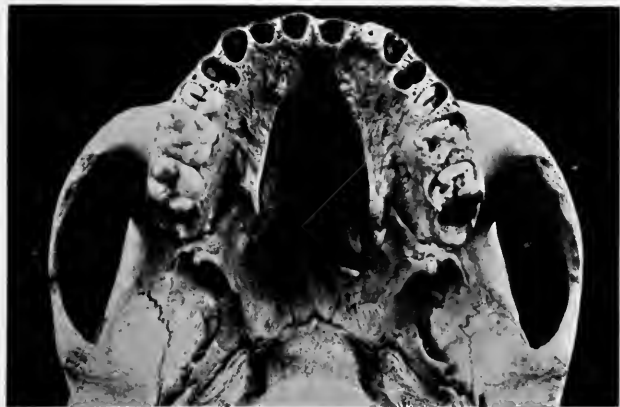

Fig. 82. Skull of an adult who had a double cleft of the palate behind the incisive fossa.—From a specimen in the Royal College of Surgeons Museum, London, photographed for this book, by courtesy of the curator.

macrostomia, and central clefts of the upper and lower lips or jaws are among the rare surgical curiosities.

#### THEORIES OF FAILURE OF CLEFT CLOSURE.

The exact reason for the failure of closure of the cleft has ever been a source of speculation.

**Heredity.**—The influence of heredity is very striking, but it has been difficult for us to compute its bearing with any exactitude in

our cases. In a large number of the cases the lack of knowledge on the part of the parents precluded the possibility of getting data on the subject. In spite of this, the proportion of cases in which the defect can be traced through the immediate or collateral branches of the family is very large, and the instances are often very striking. It is not at all uncommon to find patent facial clefts in two children of the same family, and in one instance, we saw a mother and child both with cleft palate; and she informed us her father also had one, but she knew nothing of his progenitors. Mr. Owen cites a family in which a number of cases had occurred during several generations, both in the immediate and collateral branches. We have seen a number of families who were so afflicted, and in such cases the defect is often manifested in various degrees. A mother may have a defective or absent lateral incisor, and the child show a complete cleft palate; one may have simply a peculiar enunciation, where others in the family may have harelip, etc. Heredity cannot be advanced as a cause, but simply as a transmission of a cause, and however interesting these observations may be, they shed little light on the etiology.

**Mechanical Cause.**—In speculating upon this subject, it seems fair to assume that the failure of closure of the clefts may be due to more than one determining factor, and in a study of the data at our disposal two possible causes stand out very prominently: (1) that some mechanical obstruction prevents the approximation of the cleft borders; (2) that some influence on the vital forces interferes with union after the borders are approximated. Of the mechanical influences that have been put forward as the possible cause of the defect, some could be sufficiently broad in their action to account for all instances of patent clefts; some could account for only certain limited clefts; while others could have no bearing on the subject. To the latter class belongs the explanation of Fein, who ascribes clefts of the palate to hypertrophy of the pharyngeal tonsil. This view is opposed by Tandler, who shows that between closure of the palate clefts and the first appearance of adenoid tissue two fetal months elapse.

The following may be included among the possible mechanical influences: Before the development of the palate ridges the tongue fills the whole mouth and nose cavity, and its failure to recede from the nasal part has been ascribed by Tandler, Dursy, and others as a cause. One specimen of pig embryo has been observed that seems to support this view. In conjunction with this theory Friedrich states that the tongue is still above the level of the palate in the second half of the second fetal month and that the cleft could be caused mechanically by the pressure of some underlying structure pressing upward on the mandible. In one case a left hand was tucked under the chin. In one

case preserved in the Hunterian Museum of London, the tongue is adherent by a bond of tissue to the anterior end of a palate cleft.

**Tumors.**—Tumors must undoubtedly be the cause in some instances. Broca found a tumor of the base of the skull the cause of a complicated harelip, and Lannelongue found a tumor of the tongue accompanying a cleft of the palate. Reasoning from the researches of Bland-Sutton, basicranial teratomata must also be occasional factors. When of sufficient size and appearing early, tumors might cause very extensive clefts.

Amniotic bands and adhesions are so often associated with clefts and deformities as to leave little doubt as to their causative influence. H. Fronhöfer and others have collected evidence which shows that amniotic bands and adhesions may be related to patent clefts, intra-uterine amputations, skin appendages, and other deformities. Broad adhesions of the amnion are present in most severe facial malformations. It is possible that amniotic bands and lack of liquor amnii are but the result of some vital defect.

**Supernumerary Teeth.**—Warnekros has made a valuable study of the teeth in individuals with palate cleft, and because in almost every instance he was able to demonstrate supernumerary teeth either showing in the mouth or buried in occult bone clefts, he concludes that supernumerary teeth, by requiring more room than is normally furnished, are always the cause of clefts of the palate.

One would hesitate to question the deductions from such careful and extensive observations if there was not such overwhelming contra-evidence. Warnekros does not seem to take into consideration the relation of palate clefts to extensive cranial clefts, defects of the brain, facial clefts, and other deformities that can have no connection with the teeth, nor does he seem to offer evidence that the formation of the teeth antedates the normal closure of the palate clefts.

The labiodental strand, or dental ledge, from which the teeth are formed, appears about the beginning of the seventh week. About the ninth fetal week, according to Röse, elevations appear on the free border of this ledge which mark the enamel organs of the milk teeth.

Whatever influence supernumerary teeth might have must be exerted before the time for closure of the alveolar part of the fissure, which, according to Zukerkandl, takes place at a period considerably earlier than the ninth week, and the ninth week is the time when the dental ledge first shows indications of separate tooth papillæ.

That supernumerary teeth can be present in the absence of patent facial clefts is well known.

Dr. Warnekros himself quotes from G. Köhne's treatise as follows: "Through tooth germs remaining latent, but which are always pres-

ent, there are developed in individual cases, owing to atavism, enamelless tooth peglets, peg teeth, and also quite normally formed teeth which remain hidden in the maxilla." Zukerkandl found enamelless tooth rudiments in the region of the incisor teeth in 20 out of 630 crania.

**Maternal Impressions.**—The possible influences on the vital processes that could cause failure of cohesion of the cleft borders are probably numerous, but to be effective they must act before the time when the clefts normally close. One of the oldest theories in this regard is that of relation to maternal impressions. While it is unwise to absolutely deny the possibility of such a cause, still there is little material evidence to support this view. Our experience, like that of most other observers, has been that in every instance the supposed maternal impression occurred after the time of normal closure of the clefts.

**Malnutrition.**—Another supposedly possible influence, and one that cannot be so quickly disposed of, is malnutrition. It is a matter of common observation that cleft palate and lip occur much more frequently among the lower and more ignorant classes, and apparently among those whose hygienic surroundings are poor. Among our cases, especially those occurring in families of the better classes, it has been a frequent observation that the mother, early in pregnancy, suffered excessively from nausea, or was in poor nervous condition.

It has been our observation that the occurrence of cleft palate in the negro is infrequent, but one such case having come to our notice. It is supposed that it is almost unknown among the aborigines of the Pacific islands. But Mr. Henry George, late technician of the Hunterian Museum, showed me a skull with a cleft palate that is supposed to be of a Polynesian.

The observations cited above can be considered as but little more than suggestive, and we do not believe that we are in a position to state that cleft palate is dependent upon poor hygiene. There is one supposed occurrence which, if true, would have been of definite value. It has been repeatedly stated that in the London Zoo, when pregnant lionesses were fed on meat containing bones too large to be chewed, the cubs often appeared with palate clefts, but when the mothers were fed on meat containing small or soft bones, the cubs were normal. This was advanced to support the theory that clefts might be dependent upon lack of proper nourishment. In discussing the subject, Mr. Arthur Keith, who is an officer of the London Zoological Gardens, informed the author that it was true that lion cubs born in the gardens frequently had cleft palate, but that careful experimentation both with the food and water failed to show any relation between the mother's food and the occurrence of the defect.

**Injury and Infection.**—It is probable that both injury and disease may influence the closure of these clefts. While we are not as yet prepared to furnish anything like exact percentages, we have been impressed with the proportion of cleft palate patients that have shown signs suggestive of syphilis. In the majority of infants in whom we have had the conjunctiva examined with the Czapski-Luedde pattern of the Zeiss Binocular Corneal Microscope, there have been observed aneurysmal dilatation and thickening of the blood vessels. The technic of the examination requires an anesthetic, and we have not as yet made a sufficient number of them to be of value. Many children thus afflicted show the Graves scaphoid scapula, which we believe bears a relation to congenital syphilis. So far, Wassermann tests have not been satisfactory in settling the question, for they have almost invariably

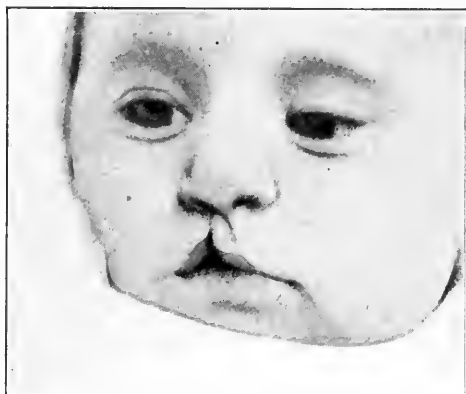

Fig. 83. Incomplete cleft of the lip with a depressed groove running up to a spread nostril on that side.

proved negative, even in patients who showed facial contour and other signs that are considered typical of congenital syphilis. One child, in whom the Wassermann was repeatedly negative, later developed active tertiary syphilis with positive Wassermann. Biondi suggested that atrophy of the edges of the cleft, due to inflammation, might prevent closure, and we are inclined to accept syphilis as one of the possible causes of such an inflammation.

In reference to injuries and ordinary infections, Moll has made a careful study of a large number of products of early abortions. He found in many cases evidences of infection and of faulty development. It is his conclusion that monsters and deformed infants may result from intrauterine injuries and infections that were not sufficiently severe to cause the immediate death of the fetus.

Mr. Keith has shown, from an examination of the material in the

various London medical museums, that cleft of the palate is rather common in monsters.

No explanation has ever been offered for the fact that palate and lip clefts appear on the left side twice as often as on the right. It is a common observation that lips and palates which are not actually cleft or which may be cleft in only a part of their extent may show a distinct line of irregular union that resembles a scar (Fig. 83). It may be accompanied by the broadening of the nostril and flattening of the ala that are typical of complete harelip. These are not true scars, for they show no scar tissue; nor do they ever contain mucous membrane with which all true lip clefts are edged. Trendelenburg regards them as an incomplete union, and they are to be compared with the median raphe of the scrotum and perineum.

### CONGENITAL LIP PITS.

A peculiar and rare facial deformity, which is, as far as we know, not directly related to the embryonal clefts, but which, when it has oc-

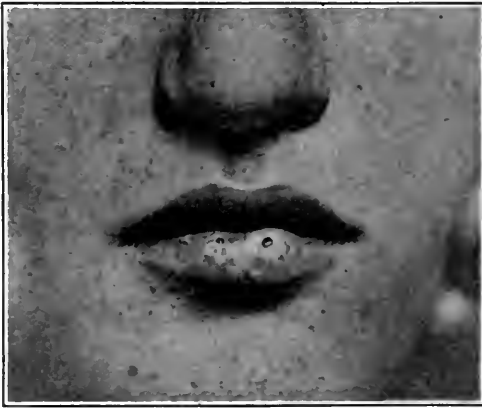

Fig. 84. Congenital lip pits in a girl who had a cleft palate. There were several instances of open clefts in her family, and her brother had a cleft palate with similar lip pits. In both instances the pits were dry, but cases have occurred in which the pits gave forth a mucous secretion.

curred, has usually been in conjunction with patent clefts, is lateral pits in the lower lip (Fig. 84). There may be slight depressions or deep pits, situated in fleshy teats from which fluid exudes. The fact that they are observed to occur in connection with double harelip gave rise to the idea that the lip cleft was in some way responsible for the pit and teat; but in the specimen shown there was no harelip, but there was a cleft palate. Mr. Arthur Keith, who has studied the subject, finds that the nearest explanation he can give for the occurrence of lip pits in the human is: a possible reversion to the mucous glands which are normally found in the lip of the shark.

## CHAPTER XI.

### CONGENITAL PALATE CLEFTS—PRINCIPLES OF REPAIR BY PLASTIC FLAPS.

In every case of congenital cleft of the palate situated behind the incisive foramen, regardless of whatever auxiliary means may be adopted, the final closure is done by bridging the deficit with flaps made from the soft tissue. Further, whether the operation is done on a young infant, a child, or an adult, except in certain extraordinary cases, the same general plan of operation is applicable in all cases.

This chapter will deal with: first, the general consideration of the construction of flaps from the palate tissues; and second, of flaps from extrapalatal sources.

The success of any operation or mechanical appliance for the restoration of the palate is mainly in proportion to its success in restoring or taking on the function of the velum. A velum that is too short is but a poor substitute for the normal condition.

#### ANATOMICAL CONSIDERATIONS.

The hard and soft palate together are collectively termed the palate, which is covered on both surfaces by mucous membrane and submucous tissue, etc. At the outer border of the hard palate, close to the alveolar process, and at the level of the posterior border of the last molar tooth is the opening of the posterior palatine canal, through which the descending palatine artery and large posterior palatine nerve emerge to enter the palate tissues. Other smaller palate nerves emerge from accessory foramina situated behind the opening of the posterior palatine canal (Fig. 7). Anteriorly, at the incisive foramen the nasopalatine nerve emerges with some terminal branches of the vessels of the nasal septum. In cases of double cleft palate, the distribution of these latter is confined to the intermaxillary bone. The maxillary tubercle is the prominence at the posterior end of the superior alveolar process. Behind and slightly internal to this tubercle can be felt the tip of the hamular process of the internal plate of the pterygoid process of the sphenoid bone. About 1 centimeter behind the hamular process the ascending palatine artery enters the velum subjacent to its oral mucous membrane.

The velum is intimately attached to the hard palate, not only by the palate aponeurosis, but by the continuity of its mucous coverings.

Besides the azygos uvulæ muscle, which occupies a median position, and portions of the palatoglossi and palatopharyngei, which form the anterior and posterior faucial pillars, the soft palate contains the terminations of the levator palati and tensor palati muscles. These latter, after arising from the base of the skull and skirting the lateral wall of the nasopharynx, enter the velum above the upper border of the superior constrictor muscle (Fig. 85). In the velum the contained muscles are intimately connected with the palate aponeurosis. The tensor palati descends between the external and internal pterygoid plates and is separated by the latter from the mucous lining of the nasopharynx. At the apex of the internal pterygoid plate its tendon turns at a right angle over the hamular process, which serves it as a pulley, and then

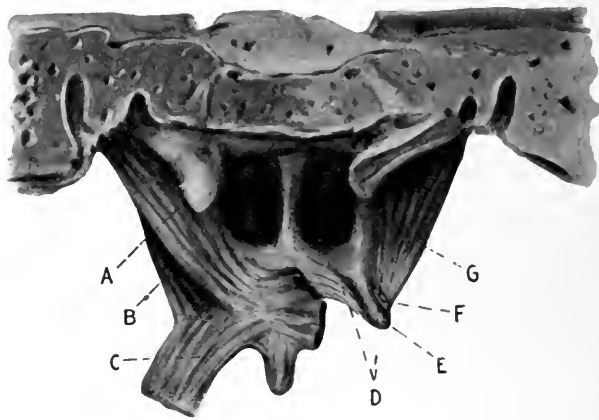


Fig. 85. Palate muscles. Essential palate muscles viewed from behind. A, levator palati muscle; B, tensor palati muscle; C, palatoglossus muscle; D, tendon of the tensor palati muscle; E, hamular processes; F, bursa; G, tensor palati muscle.

spreads out in the substance of the velum. Its motor nerve supply, which is from the fifth cranial, enters its posterior border and is well out of danger from cutting during a palate operation.

The levator palati muscle is situated behind the tensor, separated from the latter at its origin by the pharyngeal end of the Eustachian tube. As this muscle descends to enter the velum, it approaches the mesial plane and lies directly subjacent to the submucous tissue of the nasopharynx. Strange as it may seem, the motor nerve supply of the levator palati muscle is a matter of uncertainty. Most anatomists believe that it is innervated by the eleventh cranial through the pharyngeal plexus, while Spalteholz, Merkel, and some others maintain that it comes from the fifth cranial through a branch that passes back from the large posterior palatine nerve just after it enters the palate from



the posterior palatine canal. This lack of exact knowledge is unfortunate, since the preservation of the nerve supply of these muscles conserves good functional success of the operation. Our own dissections and observations, made after various complicated palate operations, lead us to the belief that, with but few possible exceptions, operations for all cases can be so planned as to avoid injury to the nerve of this muscle, regardless of which course it really pursues.

The soft tissues covering the hard palate consist of the mucous membrane, the submucous tissue containing lymph follicles, blood vessels, and nerves, and the periosteum. These are all fused together into a rather inseparable layer, but the whole is easily detached from the bone.

In front and laterally as far back as the maxillary tubercle, in the edentulous mouth, the soft tissues of the palate are continuous through

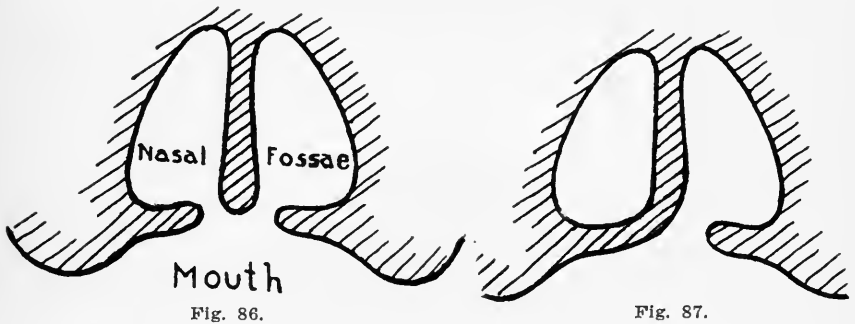


Fig. 86. Diagram of coronal section through a double cleft of the palate.  
 Fig. 87. Diagram of a coronal section through a single cleft of the palate.

the gums with the mucous lining of the vestibule. Where the teeth are in place, this continuity is carried on through the interdental portion of the gingivæ.

In a double cleft, the mucous tissues of the roof of the mouth are continuous with those of the floor of the nose and nasopharynx on both sides, while the nasal septum, attached anteriorly to the intermaxillary process, stands free in the cleft (Fig. 86). The nasal and oral blood vessels anastomose freely around the borders of the cleft.

In a single complete cleft, the mucous membrane and submucous tissues lining the roof of the mouth are continuous around one cleft border with the mucous membrane and submucous tissues on the upper surface of the palate process and velum, and at the other border with the mucous membrane and submucous tissues of the upper surface of the velum posteriorly, and of the lateral surface of the nasal septum anteriorly (Fig. 87).

### FLAPS MADE FROM PALATE TISSUES.

From the anatomical points just considered, it will be seen that flaps of soft tissue for the repair of congenital palate defects may, broadly speaking, be made in three different ways:

(a) The border of the cleft may be taken as the base of the flap, with the blood supply coming through the anastomosis with the nasal vessels (Figs. 109, 110). If there are no intervening teeth in the alveolar arch to interfere, such a flap may include the palate tissues, the gum, and even part of the cheek. Such a flap can be rotated until the raw surface is toward the mouth and the mucous surface is toward the nasal fossa. With care this flap can often be raised sufficiently without cutting either the posterior palatine nerve or the descending palatine artery, which latter will absolutely insure its blood supply. Such a flap can be turned from the upper surface of the velum (Fig. 112).

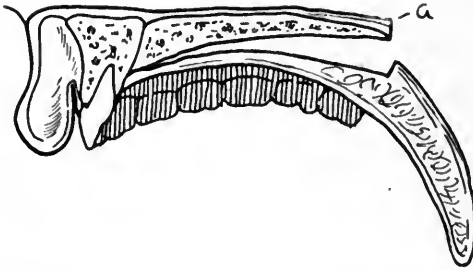


Fig. 88. Diagram illustrating a palate flap in which the velum has been detached from the palate process by cutting through the palate aponeurosis and mucous membrane at *a*.

(b) A flap can be raised with a narrow pedicle directed toward the termination of the posterior palatine canal, to be nourished by branches from the descending palatine artery (Figs. 113, 114). This flap may be cut to include the tissues covering the hard palate, or may be taken from the velum, or even from the cheek and gum. Flaps of the (a) and (b) varieties were first popularized in the Davies-Colley operation. The (a) flaps are used in conjunction with both (b) and (c) by Lane in his operations.

(c) A flap may be formed by incising the mucoperiosteum at the border of the cleft and raising the soft tissues from the under surface of the bone as far laterally as the alveolar process. If there are no teeth intervening, the gum and even a part of the cheek may be included (Figs. 109, 110). When this has been done, the flap will be still bound to the bone at the posterior border of the palate process, and to free it here, it is necessary to cut the nasal mucous membrane and palate aponeurosis along this line (Fig. 131). When these are sev-

ered, the velum and the mucoperiosteum of the palate are converted into one continuous flap (Fig. 88).

The fashioning of the last-described flap may be modified in several ways. An incision may be made along the nasal surface of the palate process, and part of the mucous and submucous tissues of this surface included in the flap that is raised from the oral surface of the palate process. On one side of a single cleft a large piece of mucoperiosteum may be loosened from the nasal septum and included in the flap (Fig. 89). The former method is to be utilized in cases of wide double cleft, and the latter in cases of wide single cleft.

Flaps fashioned after the manner described under (c) are those most commonly used, and are the ones employed in the classic operation, which for convenience may be termed the von Langenbeck operation. Such flaps are in many ways superior to those described as

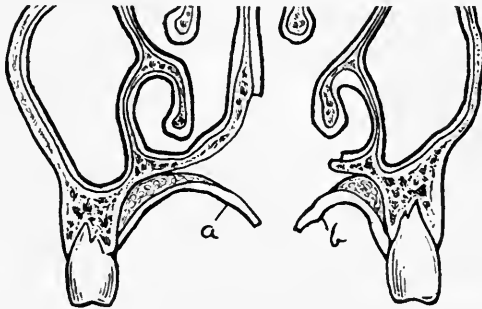


Fig. 89. Diagrammatic coronal section through a single cleft of the palate, illustrating: a, how part of the coverings of the nasal septum may be included with a palate flap; b, how part of the covering of the floor of the nose may be included with a palate flap.

(a) and (b). If properly made, the blood supply is nearly always good, and sloughing of the flap *en masse* is extremely rare. If there is failure of union, in part or throughout the suture line, the flaps simply drop back to their bed and adhere in their original positions and shape. On the other hand, sloughing, in part or *in toto*, of flaps made as described under (a) and (b) is not at all rare, and when a slough occurs in a large part of a flap, it may be very difficult to find tissues to replace it at a second operation. With (a) and (b) flaps, even failure of union of the suture line is disastrous; for the flap rotated from its original bed is, in case of failure of union, left without sufficient support, and it shrinks and becomes distorted by the contraction of the granulations on its raw surface.

If a (b) or a (c) flap on one side is used in combination with an (a) flap on the other side of the cleft, broad raw surfaces may be brought into apposition (Figs. 109, 111). The apparent advantage of

this is more than outweighed by certain disadvantages that are inherent to this method. It requires more handling of the tissues, which, with the double row of sutures, predisposes to suppuration and even thrombosis. Failure of union or loss of tissue renders second operation very difficult, and not the least consideration is the fact that it requires more time and is more difficult to make the (a) or (b) flaps.

Warren, of Boston, and von Langenbeck, the great Berlin surgeon, proposed operations for the correction of congenital clefts of the palate, which consisted essentially of loosening mucoperiosteal flaps from the hard palate and liberating the velum, and then suturing the denuded median borders of the flaps across the defect.

Their ideas are crystallized in what has come down to us as the von Langenbeck operation, which employs only the (c) flaps. On account of the conformation of the bony palate, the (c) flaps usually furnish sufficient tissue to close even wide defects.

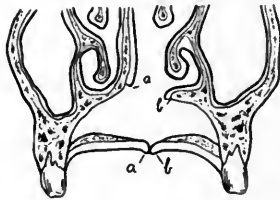

Fig. 90. Diagram illustrating how the flaps taken from an incomplete palate arch together may be of sufficient width to reach across from one side of the base of the arch to the other.

The cleft palate is an incomplete Gothic arch. When the mucoperiosteum of each side is incised at the borders of the cleft and the flap freed from the bone, which forms the sides of the incomplete arch, they can be brought straight across from one side of the base of the arch to the other (Fig. 90). If there is any deficiency opposite the junction of the hard palate and velum, this is usually compensated for by the lateral incisions (Fig. 138), which do not interfere with the blood supply and allow considerable relaxation of the flap.

The reconstructed palate, made with von Langenbeck flaps, is flat from side to side and may present wide gaps at the site of the lateral incisions. As healing progresses, however, the flap is drawn snugly up to the bone, and the edges of the lateral incisions are gradually approximated until, in time, the only abnormality that may be observed on inspection is the longitudinal scar in the midline. If, as should be the case, the periosteum is included in the flap, true bone is commonly reproduced at the site of the cleft, so that ultimately the bony arch may be completely restored.

**FLAPS MADE FROM OTHER THAN PALATE TISSUES.**

Flaps made from the nasal septum and from the floor of the nose are, strictly speaking, extrapalatal flaps, but for convenience these were included with flaps made from the palate tissues.

Extrapalatal flaps may be derived from intraoral and extraoral sources. Intraoral flaps are covered with mucous membrane, while the extraoral flaps include the skin. The former are usually derived from the inner surface of the cheek or the gums, though sometimes the tongue or pharyngeal wall has been pressed into service. The latter plan was first devised by Passavant. Von Mosetig-Moorhof went to the trouble of supplementing the velum with a flap turned from the posterior wall of the oral pharynx, and then cut a hole in the hard palate to allow of nasal respiration. In the edentulous mouth varying amounts of gum and cheek may be included with the palate flaps. When teeth are present, a buccal flap can advantageously be turned on to the palate, only behind the molar teeth or in front at the site of an alveolar cleft. When the normal mouth is opened to its widest extent, the limit to further excursion of the mandible is in the joint and not in the cheek, which can still be felt to be flaccid. Fairly generous flaps can be constructed from the mucous lining and buccinator muscle without inconveniencing the patient. The motor nerve supply of the muscle is from the seventh cranial, which comes from behind and around the outer surface of the masseter muscle (Fig. 192). The opening of the parotid duct is opposite the second upper molar tooth, and the blood supply of the cheek is everywhere good.

A flap that has its base at the upper lip can be taken from above and in front of the opening of the duct and utilized in closing an alveolar cleft or a defect in the anterior part of the hard palate.

The posterior end of the buccinator muscle is attached to almost the full length of the pterygomaxillary ligament, while posteriorly the ligament gives origin to a like amount of the superior constrictor muscle of the pharynx (Fig. 7). The ligament itself extends from the tip of the pterygoid process of the sphenoid to the inner surface of the body of the mandible and rests on the anterior part of the internal pterygoid muscle. The adjacent portion of the buccinator muscle rests on the inner surface of the masseter muscle, while the adjacent part of the superior constrictor muscle of the pharynx bears a similar relation to the internal pterygoid muscle.

Flaps which include the pterygomaxillary ligament, the anterior part of the superior constrictor of the pharynx, and the posterior part of the buccinator with their mucous coverings, may be satisfactorily and safely made according to either of the plans shown in Figs. 142, 143 or 154, 155.

The cutting of the pterygomaxillary ligament cannot interfere with the action of the upper part of the superior constrictor muscle of the pharynx in the formation of Passavant's pad, because the fibers that, by their contraction, produce this eminence are the pterygopharyngeus, and the part of the superior constrictor that arises directly from the pterygoid process. The lower fibers of the muscle are but temporarily crippled by cutting the pterygomaxillary ligament.

A piece has been stripped from the edge of the tongue and stitched into a palate defect. The tongue has been split longitudinally at its lateral border and incorporated into the palate. In both of these instances the mass of the tongue is later cut free from the palate.

Marshall illustrates a case of Rotter's, in which he turned a vertical flap from the middle of the forehead and bridge of the nose and, after

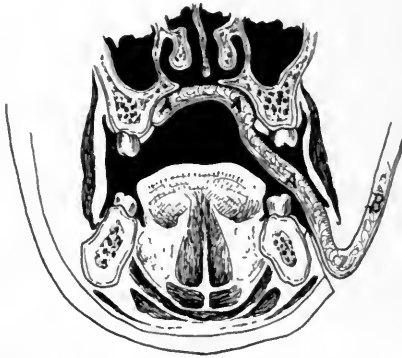

Fig. 91. Diagram illustrating a flap (AAA), which has been raised from the side of the neck and still attached to the cheek (B), can be brought through an incision in the lower buccal fornix and laid in a palate defect. It can be seen that this flap could be used for lining a cheek, instead of a palate defect.

grafting its raw surface with Thiersch grafts, left it in its original position until the grafts had taken. Later he turned the flap into the palate cleft through an incision made at the side of the nose and sutured it into the cleft, the tissues of the face being drawn together with sutures to efface the defect. He mentions that Blasius was the first to use extrapalatal flaps, and that Thiersch had done so in a second case.

We believe that the most available extraoral tissue is to be obtained from the neck. A long narrow flap of tissue can be raised from the side of the neck with its base at the lower border of the mandible. It should include the skin, superficial fascia, and platysma myoides muscle. As soon as the flap is liberated, the neck defect can be immediately effaced by drawing the edges of the wound together with sutures. The superficial tissues of the neck are usually very redundant, and the approximation can be further facilitated by undermining between the

platysma muscle and the deep fascia. Still further relaxation can be obtained by making an incision at the base of the neck parallel to the original wound and well to its outer side; this wound also serves for drainage. This flap is made 5 centimeters wide, and its length will depend on the sex of the patient. In a girl the tissue from the neck may be used, but in a boy or a man the flap must include the tissue of the upper part of the neck to well below the clavicle, as only the lower end of the flap will be free from hair. Through an incision in the bottom of the buccoalveolar cul-de-sac the flap is turned into the mouth and sutured into the palate, the jaws being temporarily held apart with an intraoral gag. Later the pedicle of the flap is cut, and the upper end of the neck wound repaired (Fig. 91). (For further details of turning flaps from the neck see Chapter XV, Figs. 156, 157, 158, 159, and Chapter XVIII, Figs. 193, 195, 196, 197.)

## CHAPTER XII.

### CONGENITAL CLEFTS OF THE PALATE AND LIP— PREFERABLE AGE AT WHICH TO OPERATE.

In the determination of the time at which operations for closure of clefts of the hard palate ought best to be done, two considerations confront us: the ideal, and the surgically probable.

#### CONSIDERATION OF VARIOUS AGES.

It was the belief of the older surgeons, the pioneers in this work, that the probability of surgical success is greatest when the cleft is relatively small and the soft tissues, from which the obturator is to be made, are comparatively well developed.

**At Twelve Years.**—At the age of twelve or fifteen we still have the excessive nutrition of growing tissue, the alveolus is well developed, the arch of the palate is high, and there is, relatively, a large amount of tissue in proportion to the cleft to be bridged. Further, it was supposed that by this time the intelligence of the patient and the desire for relief from the deformity would materially aid in obtaining the desired result. It was for these reasons that the older surgeons chose this age as the time of election.

Unfortunately, though the probability of obtaining a surgical result at this age be great, the result obtained is at best relative. The nasopharynx, nasal cavities, and the tongue of one so afflicted develop abnormally, and where speech has been attempted with a cleft palate, the imperfect enunciation that results is but partially corrected by a later restoration of the roof of the mouth and the velum.

**At Two Years.**—The "cleft palate speech" is a stigma that usually outlasts the most perfect late operation. This has caused more recent operators to seek an earlier period for repair, and by a number the age of two has been pronounced as ideal, because there is at this time a fair development of the mucoperiosteal covering of the bone with considerable arching of the palate due to the alveolar process, and because it is possible to narrow the cleft by orthodontic apparatus. Further, at this age the child's speech is but imperfectly developed; therefore the cleft palate habit is not fully formed, and successful operations at this age give excellent voice results.

**In Early Infancy.**—Still other operators, impressed with the fact that at birth there was simply the cleft, though relatively wide, and



that all the structures were normally developed, and that the longer growth went on with an open palate the farther these structures receded from the normal, sought a still earlier age for surgical interference. Close study of the subject showed that, besides better after results, the very early ages presented surgical advantages that had been at first overlooked. Certain of these advantages refer to the local conditions, while others concern the general condition of the patient.

### ADVANTAGES OF VERY EARLY OPERATION.

Of the local conditions that lend themselves in early operations, there are two: First, the absence of teeth and the lack of pronounced development of the alveolar processes—these make it very easy to go any distance in obtaining flaps of any size for the closure. Secondly, the bones are soft and pliable and exceedingly well nourished, which makes it possible to shift bodily the separated maxillæ and approximate

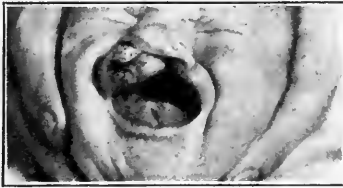

Fig. 92.

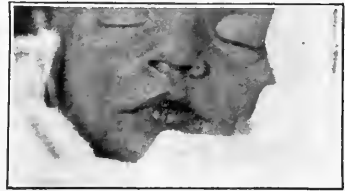

Fig. 93.

Fig. 92. Single complete cleft in an infant twenty hours old.

Fig. 93. Same infant eight days later.

the normal position. The first of these has been taken advantage of by an English school, led by Lane; and the second operation is an American development, long championed by Brophy.

Without going into a discussion of the relative advantages of the two methods, we want to call attention to the fact that, either of these operations being possible and both presenting high probabilities of surgical success, there are advantages in the early operation that decrease in direct proportion as the age of the unoperated child increases. Based on our own observation, these advantages are:

I. That the infant of twelve or twenty-four hours stands the shock of operations as well as it does the violence to which it is subjected during parturition, and that this resistance to shock decreases as the age of the infant increases.

II. If the cleft is confined to the lip and alveolus, the child will be in a condition to be nursed by its mother when it is five days' old. It is possible in most cases to preserve the flow of the mother's milk that

long by artificial means—not a breast pump—which gives the child all the immediate and late advantages that are derived from breast milk.

III. This very early repair of palate and lip saves the parents an immense amount of heartache and chagrin (Figs. 92, 93).

IV. The health of infants is always better after than before the repair of the cleft. We have seen a number of impressive instances of this fact, but the old observation—that cleft palate infants were apt to die through lack of development in other parts—is correct. The infants coming under our observation are on an average as healthy after early operations as are normal infants.

V. A normal nasopharynx and a normal voice are assured by early operation.

In the very early operations the ideal and the surgically possible meet, except that we must exercise some discretion about avoiding operation during the process of teething. We are convinced that the longer the operation is deferred the less advantage is to be gained from it, but also that there is no age at which, with appropriate technic, we cannot operate with advantage.

## CHAPTER XIII.

### CONGENITAL PALATE AND LIP CLEFTS—OPERATIONS IN EARLY INFANCY.

At twenty-four hours is the earliest we have operated for this defect, but judging from the fact that young animals, upon which the experiment has been made, show greater resistance to shock and less susceptibility to pain during the first twenty-four hours of life than they do during the second, we believe that the operation should be performed as soon after birth as possible.

#### PREPARATION FOR OPERATION.

The healthy infant requires no preparation, and if old enough to take nourishment, should be fed within two hours of the operation.

Starved infants with a subnormal temperature should, by proper feeding, oil rubs, etc., be brought into relatively good condition. In dispensary practice it is a good custom to take such debilitated infants into the hospital for a few days until the child shows signs of mending, and then to send it home, keeping close supervision of its food and care. Usually ten days or two weeks is sufficient to bring the child to an operable condition. At least in summer, it is not wise to keep an infant in the hospital any longer than is necessary.

Special nipples, carrying broad obturators, have been devised to enable such infants to suck from a bottle, but when it is intended to do an early operation, these are unnecessary, as the infant can be more quickly and more accurately fed by means of an eye dropper. Some of them, with complete clefts of the lip and palate, can do very well with an ordinary nipple and bottle.<sup>1</sup>

In the presence of any acute contagious disease, the operation should be postponed, but pus infections should be treated by appropriate surgical measures, general hygiene, and possibly by appropriate vaccines.

At the time of operation the child should be swathed in a light wool covering, which is enveloped in a sterile towel. The eyes and head should also be covered with a sterile towel that is held in place with an artery forceps or a safety pin. The child should be given only suf-

---

<sup>1</sup>The normal process of procuring milk from the mother's breast is not one purely of sucking. The infant takes the nipple and most of the areola into its mouth, and while it sucks, it also squeezes the breast with its jaws. It is only the latter part of the process that can be utilized by the cleft palate baby.

ficient anesthetic to prevent him from crying out, and that by an extremely careful anesthetist. Some form of a Junker apparatus is most convenient for this purpose. The author uses ether in all cases. The light should be good and preferably daylight, but usually artificial light and head mirror are more available. The operation may be done with the child lying flat upon its back, but we prefer to have the head hanging over the end of the table, resting in the hands of an assistant, or to have the patient on the side with the head of the table

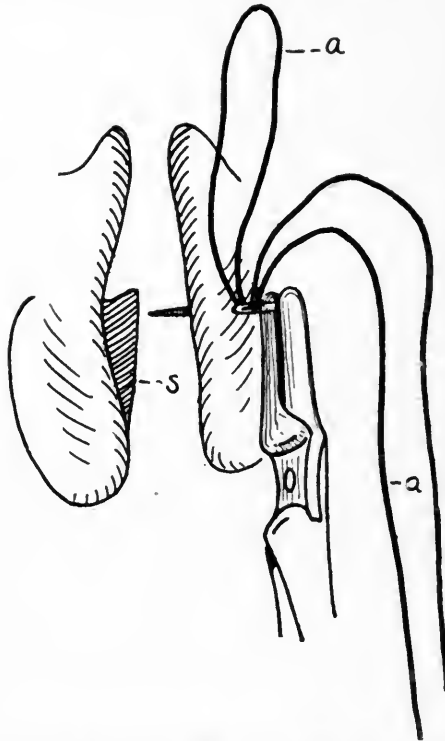


Fig. 94. Approximating the maxillæ by through-and-through wires. First step, placing a heavy silk loop through one maxilla posteriorly.

somewhat lowered. In either of the positions, the blood tends to flow away from the larynx.

There are two popular methods of operating on the cleft in early infancy, which are radically different in principle and execution. They can be very properly designated as the Brophy and the Lane operations respectively.

In the case of a single cleft, it should be determined at the time of operation that the nostril on the cleft side is patent posteriorly; this may be done by inserting a probe.

**BROPHY OPERATION.**

According to Heitmüller, Velpeau probably first suggested the early operation for cleft palate. Julius Wolff recommended that the operation be done as early as possible.

In 1861, Dr. Reeves, on examining a dead infant that had a cleft palate, observed that most of the tissue that goes to make up the normal palate was present and the width of the cleft depended upon the fact that the maxillary bones were spread apart. He suggested the pos-

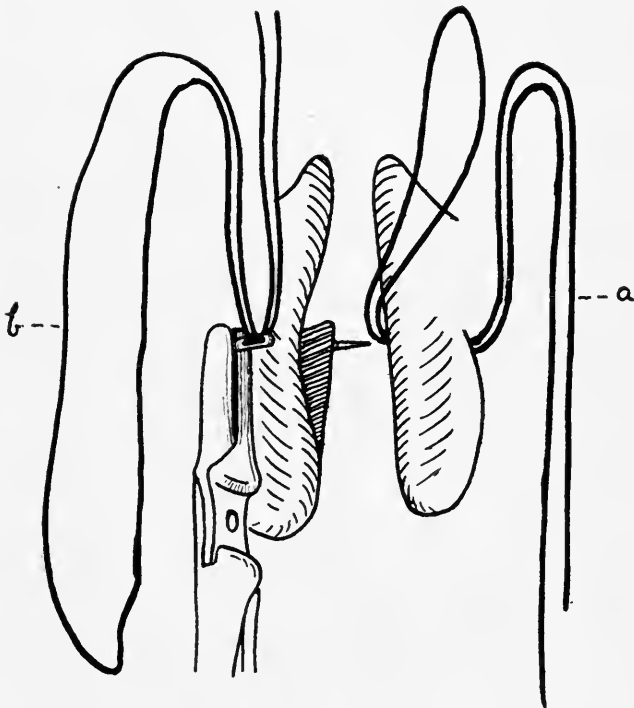


Fig. 95. Approximating the maxillæ by through-and-through wires. Second step, placing a heavy silk loop through the other maxilla posteriorly.

sibility of treating the deformity by approximating the separated maxillæ (Fig. 101).

Dr. Brophy, of Chicago, later devised the operation that made this practical. The technic that we have evolved differs somewhat from that used by Dr. Brophy but, in principle, is the same.

The operation consists of passing silver wires through the maxillary bones from one buccoalveolar cul-de-sac to the other. By twisting the wires over two lead plates and by lateral pressure on the bones and, when needed, by cutting the outer wall of the orbit through a very small mucous incision, the anterior end of the cleft is obliterated, and

the posterior part is narrowed. The parts of the maxillæ that are brought in contact should be denuded to the bone. If it is thought expedient, a mucoperiosteal flap can be raised from the hard palate on both sides and united over the anterior third of the cleft. If this is to be done, the mucoperiosteal flap should be freed, and the sutures in this flap inserted, before the anterior parts of the maxillæ are com-

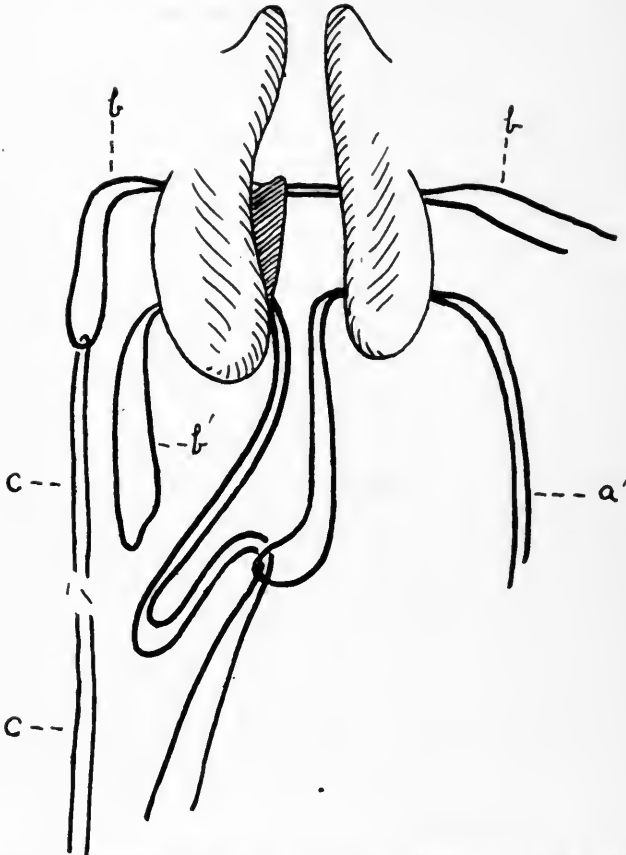


Fig. 96. Approximating the maxillæ by through-and-through wires. Anteriorly is shown how one loop (a') is passed over the ends of the second loop (b'). By drawing on the (a') loop, the (b') loop is made to traverse both maxillæ, (b) shows loop in position with wire; (C) ready to be drawn in place.

pletely approximated. The various steps of this operation are illustrated in Figs. 94-98.

The needle shown in Fig. 99 is held in a strong needle holder and inserted high up in the cul-de-sac, and with a little twisting motion it enters the bone without difficulty. As shown in Fig. 100, in young infants there is no space between the tooth and the orbit, and the needle either penetrates the upper part of the tooth sac or passes

along the upper surface of the floor of the orbit (Figs. 100, 103). The latter course is often evidenced by the appearance of a subcutaneous orbital hemorrhage. We have never seen any evil effect to follow from

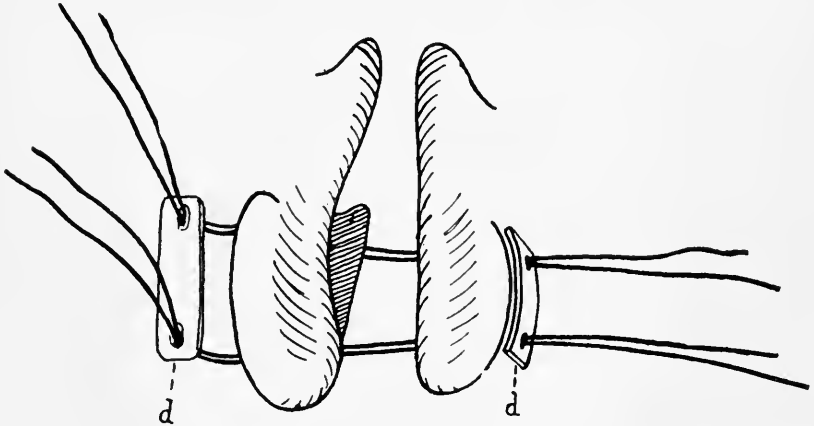


Fig. 97.

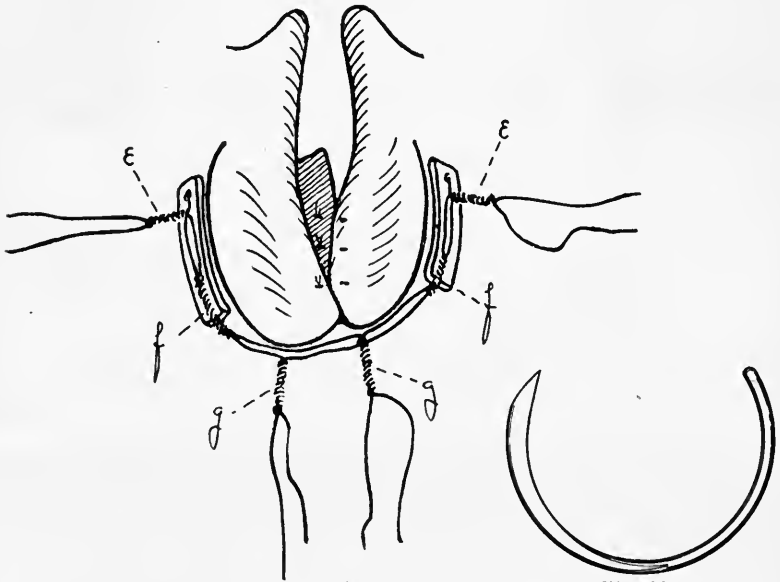


Fig. 98.

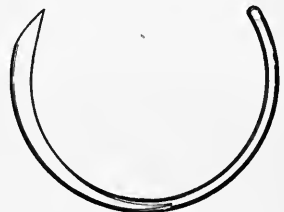


Fig. 99.

Fig. 97. Approximation of the maxillæ by through-and-through wires. Showing two double wires in position threaded at each end on a lead plate (d). If single wires are used, No. 20 is the proper size, while No. 22 or 24 is used double.

Fig. 98. Approximation of the maxillæ by through-and-through wires. This shows the maxillæ approximated. This is done by pressing the bones together and taking up the slack by twisting appropriate wires. The approximation of the cleft is made more sure by bringing two of the wires around the intermaxillary bone, and twisting them at (g-g).

Fig. 99. The needle we use in piercing the maxillæ is what is known as a  $\frac{5}{8}$ -circle, reverse-eyed Hagedorn. We use two sizes: one of a circle the size of a nickel, and the other of a circle the size of a quarter. Usually we grind off some of the broad cutting point.

this. The height at which the needle may be entered can be judged by noting the lower border of the orbit on the face (Fig. 103).

Dr. Brophy uses the needle illustrated in Fig. 104, and passes it through the gum, at a lower level than described above. Though this must do some damage to the developing deciduous teeth, it cannot directly injure the buds of the permanent teeth, which at this time are very small and lie to the median side of the large crowns of the teeth of the first dentition.

The wire we use is a very soft No. 20 virgin-silver wire. A strong braided silk, or silkworm gut, should be used as carriers for drawing

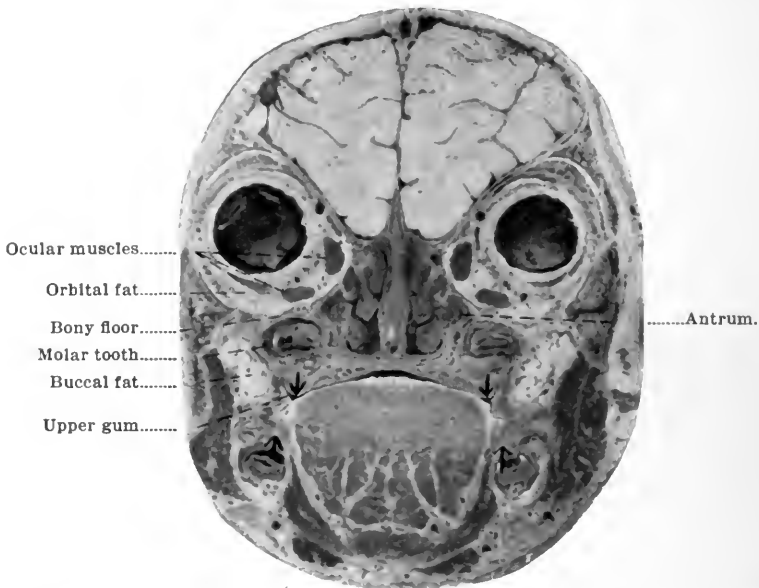


Fig. 100. Coronal section through frozen head of an infant at term, through the antrum. It will be seen that there is only a thin plate of bone between the tooth sac and the orbit, and that, in transfixing the maxilla, the needle must penetrate one of them. The antrum is still very small and lies mesial of the tooth sac of the second molar tooth. By the arrow points it will be seen that the upper jaw is narrower than the lower.

the wires through the bone. We believe that placing the wires above the floor of the orbit and the lead plates high up on the alveolar process has several substantial advantages. The orbit is relatively large for its contained structures, and there is plenty of room to pass the needle above the floor through the orbital fat without injuring the ocular muscles. The body of the maxillary bone is rather compact and less lacerated by the passage of the needle and wires than is the alveolar border. Where it is desired to narrow the posterior part of the cleft, the high position of the wires and plates gives a better hold for retention. It is a surgical impossibility to bring the borders of the palate



processes in contact with each other by this operation, and even in very young infants the posterior part of the cleft cannot be narrowed to any considerable degree without employing a crushing force. This




Fig. 101. Coronal section through plaster casts of the upper and lower jaws of a case of single cleft palate. By comparing the relative positions of the arrow points in this figure with those in the preceding, it will be seen that, while in the normal state the upper jaw is narrower than the lower, when there is a complete palate cleft present the maxillæ are spread apart until the upper jaw is wider than the lower. It is for this reason that it is perfectly proper to approximate the maxillæ artificially in operating on a cleft.

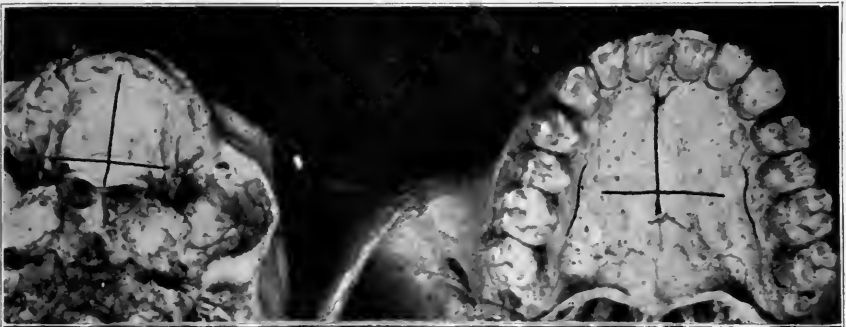

Fig. 102. A study of the growth of the palate from infant to adolescence. The cross on both palates is the same size, 13 mm. in length and 20 mm. in width, which are the full dimensions of the infantile palate. The measurements on the infantile palate were taken from the anterior palatine canal to the posterior nasal spine, and between the posterior palatine canals. When the cross of the same dimensions is laid on the adult palate, taking the anterior palatine canal as the fixed point, it will be seen that the cross piece is at the level of the posterior borders of the second bicusps, which is the original position of the posterior palatine canals, and that while there is a slight lateral and forward growth of the palate, the great part has been backward; which was to be expected because it corresponds to the direction of growth of the alveoli of the upper and lower jaws.

can be done by covering the jaws of a pair of long sequestrum forceps, inserting them through the mucous membrane at the upper fornix of the vestibule on each side, and getting a grasp on the bodies of the maxillary bones (Figs. 105, 106). If any pressure is exerted on the

alveoli, they will fracture into the tooth sacs, and the teeth will be expelled. The borders of the anterior part of the cleft can be closed by simply pressing open the alveoli with the fingers or with the handle of a knife, and taking up the slack in the wires by twisting them on each side alternately. No attempt should be made to draw the bones together by simply twisting the wires, and both wires must share equally in the twist, otherwise one of them is apt to snap at the plate.

With increasing observation, we are more and more inclined to simply obliterate the anterior part of the cleft and allow the posterior portion to take care of itself until the flap operation is performed. At

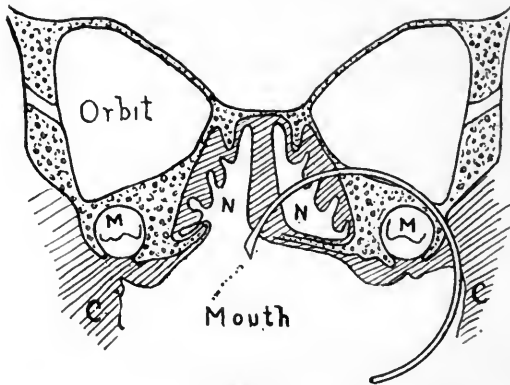


Fig. 103.



Fig. 104.

Fig. 103. An accurate diagrammatic reproduction of a section of a frozen head of an infant with a single cleft of the palate. This illustrates how a  $\frac{5}{8}$ -circle needle can be made to pass from the upper buccal fornix, through the orbit and into the cleft.

Fig. 104. Brophy needle. Dr. Brophy has two of these made, right and left. The shank of this needle is shorter than the original instrument.

the age of ten months or two years, it is usually easy to close the posterior part of the cleft by a von Langenbeck operation. In the Brophy operation there is little hemorrhage, and unless too energetic efforts have been made to close the posterior part of the cleft, there is no shock.

The objection that has been argued against this operation, that it unduly narrows the palate and the nasal passages, is not necessarily true; for the maxillary bones are already spread apart, and the operation attempts simply to restore them to the natural position. However, it is very easy in some cases to carry the operation to the extent of obstructing the anterior part of the nasal fossa and cause nasal obstruc-

tion on one or both sides. This point should be carefully watched, and each nasal fossa should, in a young infant, admit a probe with a head 2 or 3 millimeters in diameter. G. V. I. Brown cites experiments carried on in the Parke-Davis Laboratories, which demonstrated that puppies, in which the nasal fossa had been obstructed in this manner, developed very poorly. We feel sure that the infant has suffered in a similar manner. The deciduous teeth are usually lost soon after the operation; but this often happens in cleft palate cases where no operating has been done, and is a minor consideration. In doing the op-

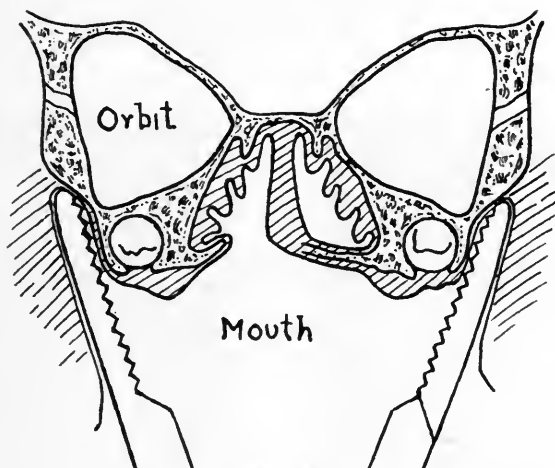


Fig. 105.

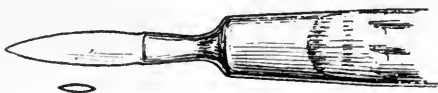

Fig. 106.

Fig. 105. Showing position of the jaws of the forceps in forceful approximation of the maxillæ.

Fig. 106. Double-edged knife we occasionally use in cutting the maxilla. The knife is thrust high into the body of the bone through a small mucous opening, and moved forward and backward in the bone.

eration, Dr. Brophy draws two wires through each hole in the bones, principally to have a reserve in case one wire breaks. If a soft No. 20 wire is used, and the wires are twisted only to take up the slack that is gained by pushing the maxillæ together, there will be no danger of their breaking short. The prominent intermaxillary part of the alveolus can be held back, either by twisting two of the long ends of the wires around the front of the gum (Fig. 98), or by passing a separate finer wire through the alveolus on each side of the cleft. If the needle pierces the alveolar process of the intermaxillary bone, it should be in the midline. By doing this, injury to the buds of the

permanent central incisors will be avoided. In either case it is better to pass the wire through the frenum and make the twist at one side, as this places the wire higher on the bone. The twisted ends should be cut short and bent so as not to stick into the cheeks.

The operation illustrated above is the one we performed for a number of years on every wide complete cleft in an infant under three months (Figs. 107, 108). Of late we have been satisfied, in very young infants with single clefts, to forcefully approximate the maxillæ and pass one wire through the anterior part of the jaws, bringing it around in front of the intermaxillary bone without the lead plates. This is a simpler operation, and we believe here that the results are equally satisfactory.

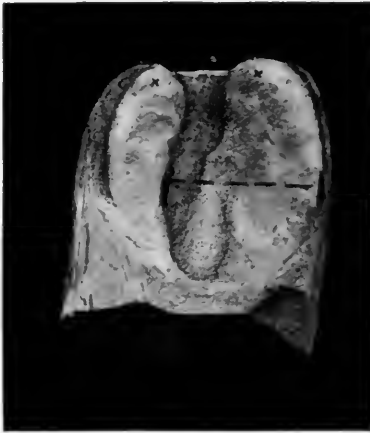

Fig. 107.

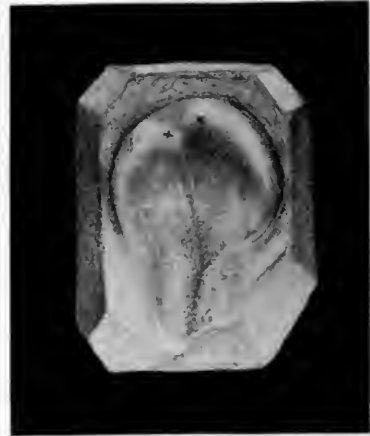

Fig. 108.

Fig. 107. Wide single cleft in a very young infant. Result of the Brophy operation shown in next figure.

Fig. 108. Shows the result that may be obtained by the Brophy operation, in a very young infant. In doing this, the nasal passages should not be obstructed. Although this infant did well in every way, still drawing together the maxillæ to the extent here shown may produce nasal obstruction.

The closure of the posterior part of the palate and velum is done later by the ordinary flap-sliding operation at any time between the sixth and eighteenth month, or even later. It is easier to do it at a year or eighteen months than at an early period. It should be done before the end of the second year. The health of the child, the season, and the state of dentition are all to be considered.

It is our custom to repair the lip at the first operation for the following reasons: Nasal breathing, which is the most important result of the operation, is thus established earlier. While these young infants stand one operation remarkably well, they are apt to do very badly if a second operation is undertaken within a few weeks after the first.

Lane, who we believe does many more early cleft operations than any one else, always closes the lip when he closes the anterior part of the palate, and maintains that the healing, the cosmetic, and the vital results are superior.

**LANE OPERATION.**

In this operation no attempt is made to narrow the bone cleft, but the defect is closed entirely by flaps formed of the soft tissue. Advan-

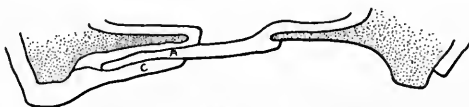


Fig. 109.

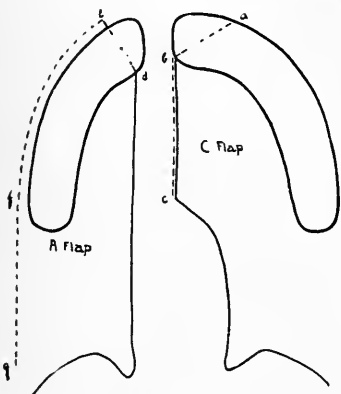


Fig. 110.

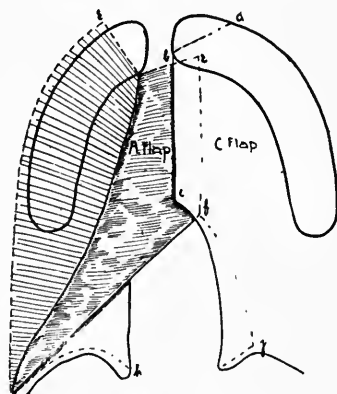


Fig. 111.

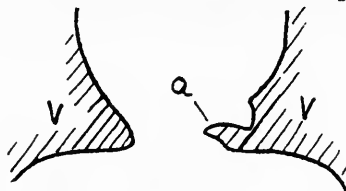


Fig. 112.

Fig. 109. Illustrating what we have for convenience designated as (a) and (c) flaps. In an (a) flap the palate is incised at the alveolar border, and the flap remains attached at the cleft border. In a (c) flap the palate is incised at the cleft border, and the flap remains attached at the alveolar border.

Fig. 110. Diagram showing the Lane method of closing a single cleft of the palate. An (a) flap is outlined on the same side as the cleft by the incision (d-e-f-g), and undermined as far as the border of the cleft in the hard plate. A (c) flap is outlined on the side opposite the cleft by the incision (a-b-c). This is undermined to the alveolar border. The (a) flap is swung under the (c) flap, as shown in the next figure, and broad raw surfaces are sutured together. The alveolar part of the cleft is filled with tissue turned from the tip.

Fig. 111. Lane's method of closing a single cleft. This shows the (a) flap swung into position under the (c) flap, closing the anterior part of the cleft. At a subsequent operation he makes the incision (g-h) through the mucous and submucous tissue, and loosens the posterior part of the (a) flap as far as the cleft border in the velum. At the same time another (a) flap is turned from the upper surface of the velum on the opposite side as outlined by (c-f-j). This second (a) flap, being turned from the upper or nasal surface of the velum, allows its raw surface to lie in contact with that of the (a) flap of the opposite side. By this means the cleft in the velum is closed.

Fig. 112. Lane's operation. Illustrating how the (a) flap is turned from the upper or nasal surface of the velum. V, V, cleft velum; a, flap.

tage is taken of the fact that, there being no teeth to interfere, the surgeon can go past the gums and on to the cheeks to obtain extensive flaps. These flaps are made in several different ways. (See Chapter XI for the general principles of the making of plastic flaps.) The writer has seen Mr. Lane operate as follows:

For a through-and-through single cleft, to close the anterior part, he makes an (a) flap with its base at the cleft and a (c) flap (Fig. 109); the (a) flap is rotated under the (c) flap and sutured (Figs. 110, 111, 112). This is a modification of the Davies-Colley operation.

For a cleft behind the alveolus, he makes two (b) flaps attached posteriorly with the blood supply from the descending palatine arteries,

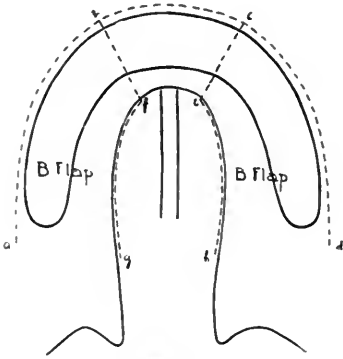


Fig. 113.

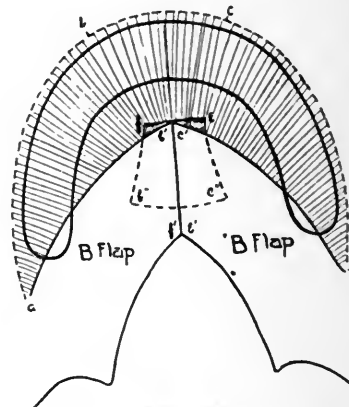


Fig. 114.

Fig. 113. Lane's method of closing a cleft behind the incisive foramen. The two (b) flaps are outlined by (g-f-b-a) and (h-e-c-d). These are freed from the alveolar and palate processes as far back as the descending palatine artery. An (a) flap is outlined by (f-b-c-c), with its base at the anterior end of the cleft. To close the cleft in the hard palate, the (a) flap is turned back until its mucous surface is toward the nasal fossa, and the two (b) flaps are drawn to the midline until their raw surfaces rest on that of the (a) flap.

Fig. 114. Flaps in place, as described under the preceding illustration. At a subsequent operation the cleft in the velum is closed, as described under Fig. 111.

and an (a) flap which includes the covering of the anterior part of the gum (Fig. 113). The anterior flap is turned backward until it lies on the anterior part of the cleft with its raw surface toward the mouth; and then the two lateral (b) flaps are brought toward the median line, their raw surfaces partly overlying the rotated anterior flap, and all are sutured in place (Fig. 114).

For a wide double cleft, he makes an (a) flap on one side and a (b) flap on the other, rotating the (a) flap until its raw surface is toward the mouth; the (b) flap is drawn to the median line, and they are sutured, raw surface to raw surface (Figs. 115, 116).

He fills the anterior part of the alveolar cleft with flaps turned from the edge of the lip cleft.

The cleft in the velum is repaired at a later date by two flaps made as described under Fig. 111.

When the molars have erupted, the operation will differ but little from the Davies-Colley operation.

Mr. Lane uses fine silk and small curved needles, with flat shanks, for fixing the flaps.

It will be seen from the above description that, in constructing the new palate, the nasal, as well as the oral, surface is covered with mucous membrane and that everywhere broad denuded surfaces are approximated. The making of these flaps is accompanied by comparatively little bleeding. When the posterior palatine artery is to be cut,

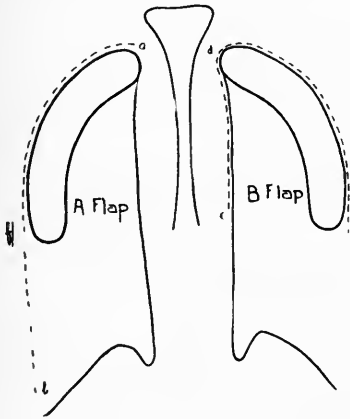


Fig. 115.

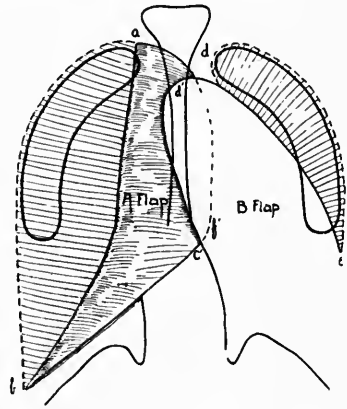


Fig. 116.

Fig. 115. Lane operation for complete double cleft. The operation is similar to that for single cleft except that one side in the latter (a-b) flap is substituted for the (c) flap used in the former.

Fig. 116. Lane's method of closing a double cleft. Flaps in place for closure of the hard palate portion of a complete double cleft. As with the single cleft, the alveolar part of the cleft is closed with flaps, obtained in freshening the edges of the lip cleft.

it is first freed and caught with an artery forceps, which is easily done, as it runs for a space in a groove in the palate process.

The above descriptions are less complete than those given in his brochure on the subject, but they are sufficient to illustrate the principles involved.

The description of the technic we have given differs from that given by Mr. Lane, in the paper referred to, in that the operations here described are performed in two stages. This was the manner in which he was doing it at a later date, when we made a special trip to his clinic for the purpose of getting his technic at first hand.

We are convinced of the wisdom of the two-stage operation, for, in the few cases we had attempted to do the operation at one sitting, we invariably had failure of union in the posterior part due to a sloughing of one flap.

### CHOICE OF OPERATION.

Granting that the Lane operation is to be performed in two stages, we are sure that, at least in ordinary hands, when the lip is repaired at the same time as the maxillæ are approximated, the Brophy operation is superior for the following reasons: It requires less technical skill, aims at the restoration of a more natural anatomical condition, and, we believe, is less of a strain on the vital powers of the patient.

If, in the Lane operation, a failure does occur, it is due to sloughing and a loss of a part of a flap, and the damage is extremely difficult to repair.

A bone slough following a Brophy operation is very rare, but when it does occur, the damage is irreparable.

### AFTER-TREATMENT.

As a general proposition, with the exception of the special care of the mouth, these babies are to be treated as if no operation had been done.

Very often after doing the early operation on the lip, it will be found that there is a nasal obstruction either from mucus in the nose or, in the case of double harelip, from the temporary closure of the alæ of both nostrils. These babies will not, when asleep, breathe through the mouth, even if the lower lip is held to the chin with a suture, as has been recommended; the tongue will fit up against the new alveolar arch and absolutely preclude inspiration. If this condition is allowed to continue, they are restless and do badly. We were often greatly annoyed by this and on two occasions went so far as to cut the sutures that held the ala in place. Attempts to hold the nostril patent with a bent wire were unsatisfactory, because it was not very efficient, and also because it caused the nostril to spread and injured the cosmetic result. It was not until we hit upon the use of the breathing tube (Fig. 185) that we were able to overcome the difficulty. This breathing tube is worn almost constantly for the first few days, being removed only for feeding. Usually after the first two or three days, it is not necessary to have it in place constantly, but it is returned to the mouth, whenever it is noticed that the lower lip sucks in on inspiration. After five days, the nostrils usually open sufficiently to allow the tube to be dispensed with.

For depression due to loss of blood, saline solution can be given hypodermatically. We seldom resorted to this, but as a routine practice have saline solution placed in the rectum.

At the operation the child, almost invariably, swallows blood. An attempt may be made to remove this with a stomach tube, but we pre-



fer to give 4 cubic centimeters of castor oil with .06 cubic centimeters (gtt. 1) of paregoric within a few hours after the operation. As soon as the infant cries, water is given, and when this no longer satisfies, the child of forty-eight hours or more is fed. Usually feeding is commenced within four or six hours after the operation. If human milk is available, it can be given. After a rather extensive trial we have come to the conclusion that, for the time being, most of these babies do better and lose less weight if fed on "Eagle Condensed Milk" than with modifications of fresh milk. After two days the child should be encouraged to take the breast, if the flow of milk has been preserved. However, it will never be able to gain sufficient nourishment in this way, and the nursing should be immediately supplemented with milk removed with a breast pump or with condensed milk from a spoon, bottle, or dropper. Older infants may require an anodyne during the first forty-eight hours after operation. This is rarely the case and should not be resorted to until it is certain that it is not food, water, or other ordinary attention that the child wants and that a little comforting in the nurse's arms will not quiet it. Then and then only may a small dose of paregoric or morphin be given. When avoidable, such a child should not be petted or handled.

The mouth and nose are gently irrigated with saline each two hours during the day and at feeding times at night. The irrigation is done with a douche can and with the child held on its side over a bucket. If it does not cause the child to vomit, the irrigation is made after the feeding. If it causes vomiting, it is done before feeding. If in older babies the irrigation causes the child to be afraid and to cry afterward, it is omitted. If there is any local evidence of infection, the part is painted after each irrigation with a 10 per cent colloidal silver solution. The line of sutures on the lip is painted with the colloidal silver as a routine practice. Everything that is used about the child's mouth is to be sterile.

The temperature after the operation may rise anywhere from 99° to 103° F., or even more, but usually subsides to about 100° and remains there for a few days. As a rule the elevation of temperature needs no treatment. In good weather, older babies, those two weeks old or more, are taken out of doors in a perambulator within a few days after the operation.

In dispensary practice it sometimes takes nice judgment to determine whether the danger of hospitalism or of improper care at home is more to be feared. Such babies are usually kept at the hospital ten days or two weeks, but where the child will receive intelligent care at home, after the operation has been done at the hospital, it may be sent home within a day or two.

### MORTALITY.

The immediate mortality of the Brophy operation is very low. We have twice lost three months' children within twelve hours after operation. We have seen a few infants die some weeks or months after operation; but this has occurred only among cases in which the nutrition of the infant was persistently bad beforehand, and the operation was undertaken in the hope of improving the condition. In these latter cases death could not be attributed directly to the operation, although no doubt it had been a contributing factor. We think it fair to state that we have seen a much larger percentage of deaths among infants that we were trying to get in shape for operation, than in the first few postoperative months.

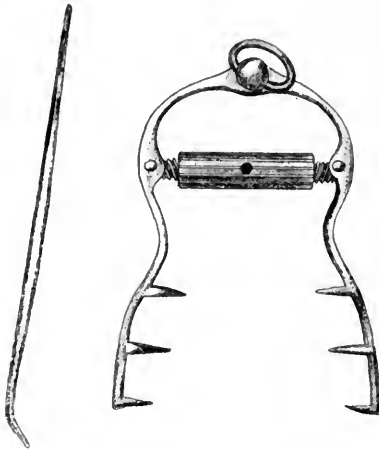


Fig. 117. Roberts' modification of Hammond palate clamp.

Roberts has made a modification of the Hammond clamp for gradually approximating a bony cleft. In this clamp (Fig. 117), the teeth project like hooks above the upper edge of the jaws. The clamp can be applied under anesthesia, the mucosa of the upper fornix being first incised to allow the clamp to fit snugly high up on the body of the jaw. The clamp is tightened a little each day or so, as the segments of the jaw come together. We have never used this clamp, but Dr. Brown once constructed one for us with hard rubber jaws, which were pressed together with a rubber band. We gained something by its use, but not much. The Hammond-Roberts instrument is much more powerful. Roberts remarks, "Theoretically the method is valuable; but its practical usefulness has not yet been established." It seems to us that the two points to consider in its use are: how much will its continued use fret the baby, and how much will the instrument irritate the soft tissue.

## CHAPTER XIV.

### CONGENITAL PALATE CLEFTS—PLASTIC OPERATIONS IN ORDINARY CASES AFTER EARLY INFANCY.

Aside from the general condition of the patient, the first thing to be determined is the plan of operation that is applicable to the given case; and the conclusion is to be reached by a comparison of the amount of available tissue with the width of the base of the posterior part of the palate arch. The width of the cleft bears only indirectly upon the question. The width of the arch is to be measured from the proposed site of one lateral incision to the other—from  $a$  to  $a'$  (Fig. 118). The amount of the palate tissue available is determined by measuring from the site of the lateral incision to the edge of the cleft on both sides. If in a healthy individual the sum of the available palate tissue is equal to five sevenths or more of the width of the arch between

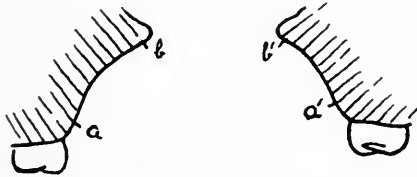


Fig. 118. Diagram of a section through a cleft palate. The distance between  $a$  and  $a'$  is the width of the palate;  $a$  and  $a'$  mark the sites of the lateral incisions. The distances between  $a$  and  $b$  and between  $a'$  and  $b'$  give the amount of available palate tissue.

the two lateral incisors, the case is a proper one for the simple von Langenbeck operation. That is, if the direct distance from one lateral incision to the other is, for example, 35 millimeters and the sum of the widths of the available tissue for flaps is 25 millimeters, then the proportion is 25 millimeters of palate tissue to 35 millimeters of palate width. Here the 10 millimeters of missing palate tissue, plus the 5 millimeters that will be lost by paring the edges, will be compensated for by the spreading at the site of the lateral incisions. If the proportion of tissue is smaller, the chances of success will be greatly increased, if it be treated by one of the operations given under "Difficult Cases," Chapter XV. We have seen a few cases that were difficult to close when the proportion of palate tissue to palate width was greater than 5 to 7.

### PREPARATION FOR OPERATION.

Before the operation is undertaken, it should be determined whether the patient is in a good physical condition, is at the time free from a cough or "cold," is not cutting teeth, and is not likely to break out with some eruption or contagious disease. Children that are known to have been exposed to one of the last should not be subjected to the operation until after the time of incubation has passed. The subjects of active syphilis should, for the time being, be excluded from operation. Phthisical persons should not be subjected to the depressing effects of any surgical procedure, unless there is some special indication for doing so. In one of the latter, a middle-aged woman, we repaired the palate, for the reason that, having no upper teeth and on account of the cleft, she was not able to wear a plate, and her depressed physical condition was partly due to faulty nutrition.

If there are decayed teeth in the mouth, they should usually be treated or removed, and if the teeth are not free from tartar, they should be cleaned by a dentist before the operation. If there is any persistent source of pus in the mouth, it should be treated, if necessary, by appropriate vaccines. This refers also to suppuration of the accessory sinuses of the nose.

Having eliminated all acute diseases and all evident possible sources of irritation and infection, the mouth of the older child or adult may be rinsed frequently for twenty-four hours before the operation with a mild antiseptic wash. Food and water should be withheld for a sufficient time before the operation to be certain that the stomach will be empty, and if indicated—not as a routine practice—a laxative may be given. It is our practice to give water in reasonable amounts up to an hour before, and some form of liquid food exclusive of fresh milk about four hours before the operation.

### POSITION AND LIGHT.

During the operation the patient may be sitting erect, lying flat on the back, lying on one side, or lying on the back with the head hanging over the end of the table. The latter is known as the Rose position, and this, or the lateral position, is the one we prefer. Both of these positions have one great advantage: the blood drains away from the larynx. The Rose position may be modified to this extent: the head rests on a pillow on the surgeon's knees or in the hands of an assistant, which lessens the strain on the unconscious patient's neck. To support the head on the lap comfortably, there must be a proportion between the stature of the operator, the height of the operator's stool, and the height of the table. It is well to have arranged this detail before the operation is undertaken. The pad upon which the patient lies should

extend beyond the table so that the neck will be protected. This pad may, very satisfactorily, be made of folded blankets covered with rubber. A pillow placed under the shoulders is unsatisfactory as it does not stay in place. With the patient in the lateral or in the Rose position, the instrument table is to be placed to the right of a right-handed operator. The anesthetist stands behind or to the patient's left, and the assistant to the right, both facing the surgeon. If the head is to be supported in the hands of a second assistant, he sits to the left between the surgeon and the anesthetist. The light should be good—daylight from a side window. This is preferable to artificial light, but as a rule in cities, in winter, electricity is more dependable. If the light is from a cluster, the patient should be placed in such a relation to it that the light will fall directly into the mouth. Unless the operator is very accustomed to its use, a head mirror is not satisfactory, as it destroys the sense of perspective, but an electric headlight is not open

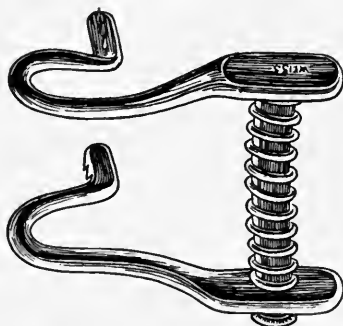


Fig. 119. Lane gag.

to this objection. A hand light is not as good for this purpose. It is absolutely essential to good work that the light be excellent.

### INSTRUMENTS AND MATERIALS.

Next in importance to the light is the mouth gag. The profusion of varieties presented in any instrument catalogue should by their number suggest caution to the surgeon in selecting one. Rather than waste time with a poorly adapted gag, it is better to place a block of wood or cork between the molars on one side and then firmly wire a tooth in the lower jaw to a tooth in the upper jaw, just in front of the block. Roughly, gags may be divided into two classes: those that are designed solely for the purpose of separating the jaws, and others that, besides holding open the mouth, are supposed to depress the tongue. Of the former variety there are two general types: the kind which rests on the incisor teeth, and those which are inserted between the molars. As a rule the former is more satisfactory where it can be

used, but it is hardly applicable to clefts that involve the alveolar process. If a posterior gag is used, the Lane type (Fig. 119) is preferable to the ordinary kind. Whatever kind is selected, see that it is strong enough and has a reasonable inclination to stay in place. Of the gags that are intended to depress the tongue, we are familiar with three varieties that are useful if the size and shape of the particular model at hand corresponds to the patient's mouth. One is the White-head gag (Fig. 144), which comes in two sizes, but which, taking its bearing at the incisor teeth, is not suitable to cases of through-and-through cleft. The same holds true of the Murdock gag, which has lately appeared with a tongue depressor attached. Mr. Owen's modification of the Smith gag, which is made by Weiss of London, and comes

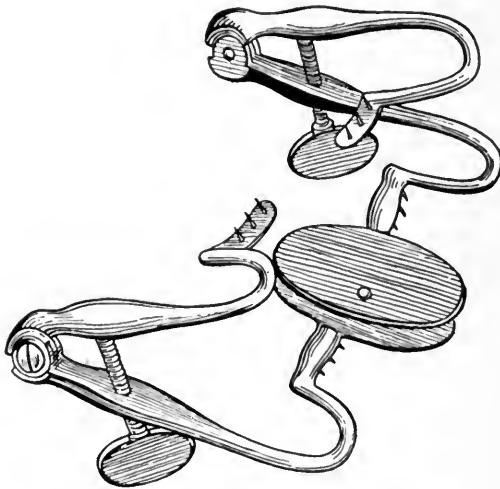


Fig. 120. Owen's modification of Smith gag.

in three sizes, is shown in Fig. 120. The spiked rests are applied to the gums behind the molars, and if the gag fits properly, they will not slip. The simplest of all is Dr. Brophy's oral speculum. While its very simplicity recommends it, it does not give as much working room as do the other two, and to assure having one to exactly fit a given case, it is necessary that quite a variety of sizes and shapes be at hand.

Having provided for a satisfactory light and gag, the rest of the necessary armamentarium is rather simple, and should consist of a small pointed knife that is sharp enough to cut a suspended hair as freely as a razor. This knife must be re-sharpened for each operation. It is very rare that a new knife, as it comes from the dealer, is sharp enough to be perfectly satisfactory. It saves the edge of the sharp knife to have a second for making the lateral incisions.

There should be at least one dozen artery forceps for sponging and clamping ligatures to the head cloth. One or two of the forceps should be pointed.

For a needle holder we use an ordinary Halsted artery forceps, but with it use a needle that has a flat shank. An artery forceps will hold a flat-shanked needle a little obliquely, which is an advantage. The artery forceps will not prevent a round needle from turning. One pair of plain dissecting forceps is needed for manipulating the needles, and a pair with long mouse teeth is useful for catching small pieces of tissue that are to be removed. There is a forceps that combines these two

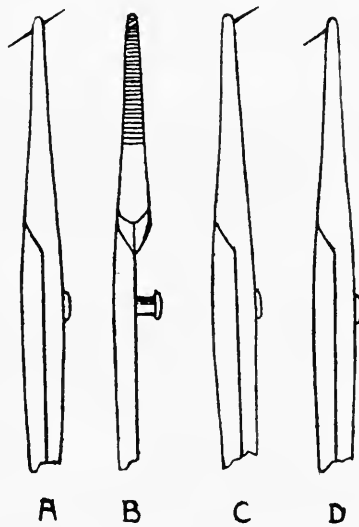


Fig. 121. An easily constructed tenaculum for handling palate flaps. The one shown above (A) is made to both push and to pull on the flaps, but this double-ended needle is liable to catch in the tissues. We prefer to use two, one to push and the other to pull (C and D). They are made by filing a groove in the end of the blade of a Halsted forceps (B) and setting in the point of a fine cambric needle.

features. The flaps themselves should never be grasped with any kind of pressure forceps. Several varieties of hooks and tenacula have been devised for this purpose, but the scheme shown in Fig. 121 can be prepared by anyone and is extremely satisfactory.

For cutting the palate aponeurosis and nasal mucous membrane from the posterior border of the hard palate, the straight knife is efficient only when the cleft extends well forward into the bony palate. Nevertheless, in all cases, a pair of thin-bladed sharply curved scissors are more satisfactory. The curved knives made for this purpose are difficult to sharpen, and the angle knives tend to split the velum longitudinally. The scissors shown in Fig. 122 are tonsil scissors, one pair of which were especially ground for infants' mouths. Any pair of small

scissors that are curved on the flat or side will do, provided the curve is sufficiently sharp.

Unless the tongue-depressing device on the gag is absolutely satisfactory, a narrow-curved spatula is required for controlling the tongue.

The kind of elevator used will depend somewhat upon whether the operator chooses to begin freeing the mucoperiosteal flap from the cleft border or from lateral incisions made at the outer border of the palate. For the latter procedure, the most satisfactory are those devised by Dr. Brophy (Fig. 123). The acute angle of the second one is very useful in freeing the anterior part of the flap in a highly vaulted arch. Freeing the flap from a lateral incision is the more rational and satis-

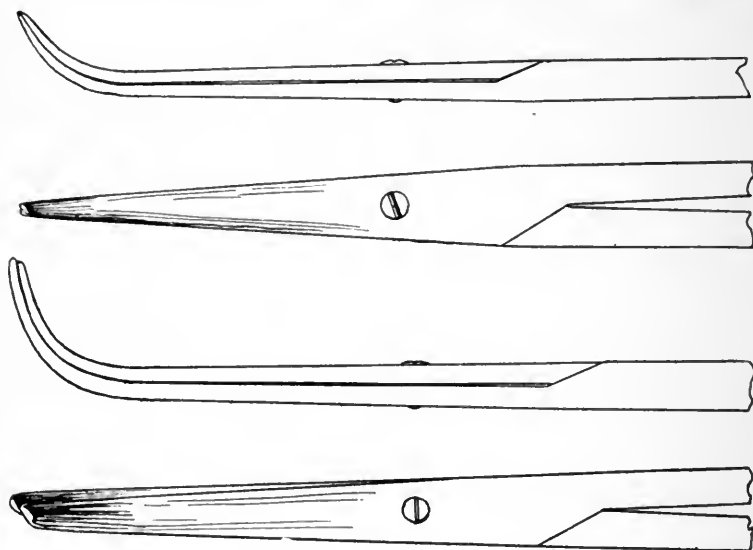


Fig. 122. Tonsil scissors that may be used for cutting the palate aponeurosis. The smaller pair have been ground for an infant's mouth.

factory procedure, and a very good instrument for this purpose is the one devised by Dr. Willard Bartlett (Fig. 124). With ordinary care it will not cut the descending palatine artery and will work both anteriorly and posteriorly through a small incision (Fig. 125).

It will be noted that all of the instruments mentioned are unpaired and can be used at either side of the palate.

**Sutures.**—In the selection of suture material, we have traveled somewhat in a circle. It is well recognized that silver wire is tolerated better in tissues exposed to sepsis than any other suture material. However, the ordinary way of inserting it with silk carriers is cumbersome and time consuming, and it is not always convenient to be dependent upon a special instrument, such as the Owen needle. We



used horsehair for some time, but abandoned it on account of the fear of tetanus. Its elasticity, the ease with which it is handled, and its non-irritating character all unite to make horsehair an excellent suture. Later we used a fine silkworm gut, but noticed that not infrequently sepsis apparently had its origin at a suture hole. We are now using a No. 30 soft-silver wire, threaded directly on a Ferguson needle. With a little care it can be made to follow the needle without tearing the tissues, and in using it in this way, we believe we have overcome the only objection to its use. To use silk and linen seems objectionable because by their capillarity they promote sepsis. There is little unan-

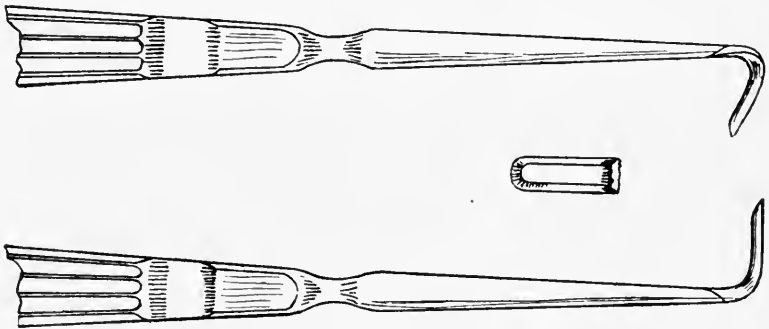


Fig. 123. Brophy palate elevators.

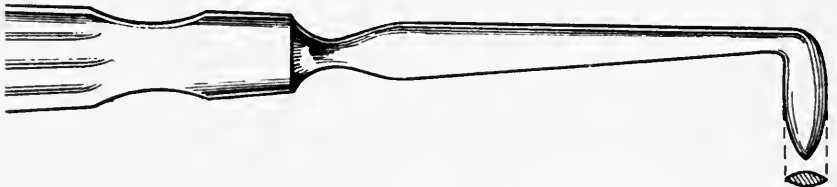

Fig. 124. Bartlett elevator.

imity of opinion about palate suture material. Among the operators of large experience: Lane uses silk, Judd, of Rochester, uses linen, Brophy uses horsehair, while Gilmer and Owen both use silver wire. In using silver wire, the sutures are at first twisted but loosely, or held to one side with forceps. After all are in place, they are twisted to the proper tension.

In most instances we use a small Ferguson needle which has a flat shank. The needle shown in Fig. 126 is extremely useful and sometimes almost indispensable in repairing a partial union after a primary operation, when the defect is situated in the hard palate and the edges of the flaps are thick and inverted in the nasal fossa (Figs. 127-130). The variety of right and left-curved needles on handles that are offered

by instrument makers for palate suturing are absolutely unnecessary, and many of them, on account of their bad lines, are impossible.

If retention sutures and lateral plates are to be used, small pierced shot are the most convenient means of fixing the retention sutures in the lead plates. The lead from which the plates are cut is about 1 millimeter thick. The lead plate can be obtained from a plumber and rolled or beaten out to the desired thickness. The shot can be bought from an instrument dealer, or ordinary shot can be drilled out by hand.

**Sponges.**—Though very satisfactory, marine sponges are no longer popular. For sponging off the flaps, small wads of absorbent cotton, that have been wet and wrung out very thoroughly by squeezing, are very satisfactory. For removing the blood from the nasopharynx, loosely folded squares of dry gauze, 5 centimeters wide, and four thicknesses of gauze, are better adapted. Unless the sponges are

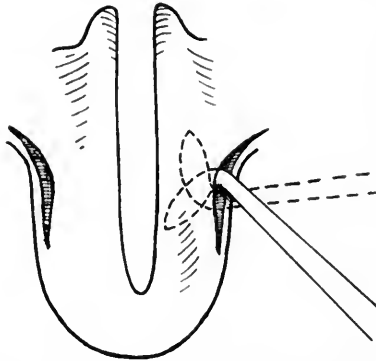


Fig. 125. Method of use of Bartlett elevator.

rewashed during the operation, there should be a large supply to provide for excessive bleeding and emergencies. We find it convenient to have on hand some folded strips of gauze to temporarily pack the lateral incisions, when bleeding is free. These are to be removed before inserting the sutures.

The instruments, sponges, and sutures should be laid out in an orderly way on a table to the right of a right-handed operator and should be well within his reach and view.

### FLAP-SLIDING OPERATION.

The patient, being anesthetized, is placed in the desired position, and the hair is covered with a rubber cap; over this is placed a sterile protective cloth that covers the nape of the neck behind and the eyes in front, enveloping the whole head. This is put on firmly so that it will not slip and is pinned, or is clamped with artery forceps. Whether or

not there is a tongue depressor on the gag, a traction suture is passed through the tongue, the two ends being knotted together so that it will not slip out. This suture should transfix the tongue at least 1.5 centimeters from the tip and be of soft silk that will not cut through.

Being satisfied with the view that can be obtained of the palate, including the uvula, and that the tongue depressor is not interfering

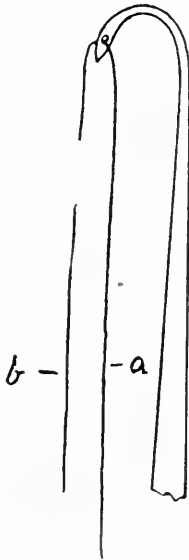


Fig. 126.

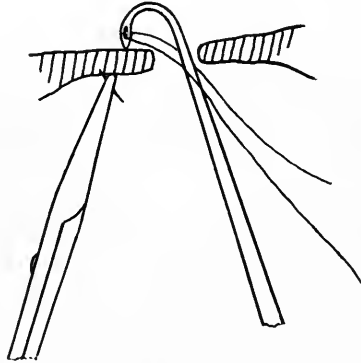


Fig. 127.

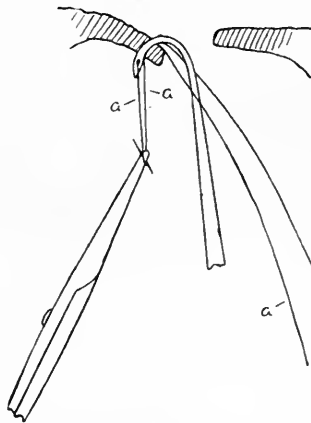


Fig. 128.

Fig. 126. Shepherd's crook needle.

Fig. 127. The palate flap may be steadied with a prod while the shepherd's crook needle is inserted.

Fig. 128. McCurdy's method of using shepherd's crook needle. First step: The threaded needle is passed through the cleft, and the palate flap is transfixed from its upper surface. Second step: The loop (a-a) is caught, and the suture end (a) of (a-a) is withdrawn through the palate, so that it hangs in the mouth but is not withdrawn from the eye of the needle.

with respiration, the mucus is sponged from the nasopharynx, and the operation proceeds somewhat as follows:

A lateral incision is made on either side opposite the position of the last molar tooth. If the patient is lying on the side, the lateral incision is made on the side of the palate that is next to the table. If

the molar tooth has erupted, the incision is made 4 millimeters from the gingival border. If the tooth has not erupted, the incision is carried along the line of junction of the palate surface with the most prominent part of the gums. The incision is made just median of the last two molar teeth, extends directly to the bone, and is made as close as possible to, without absolutely denuding, the necks of the teeth. Behind the last molar tooth the incision is carried along the crest of the alveolar process. As Mr. Owen tersely puts it: "The closer these incisions are made to the teeth, the less chance of wounding the de-

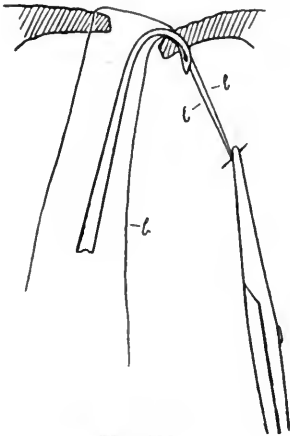


Fig. 129.

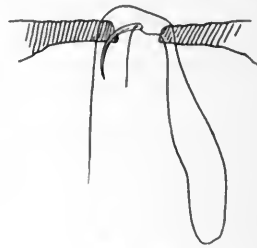


Fig. 130.

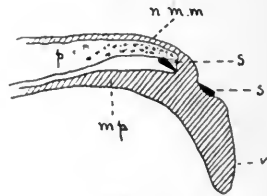


Fig. 131.

Fig. 129. McCurdy's method of using shepherd's crook needle. Third step: The needle still threaded is withdrawn from the first flap, turned 180 degrees in the axis of its handle, and inserted into the second flap from its upper surface. Fourth step: The loop (b-b) is caught, and the suture end (b) of (b-b) is withdrawn from the eye of the needle. Fifth step: The unthreaded needle is removed.

Fig. 130. After placing a suture with the shepherd's crook needle, it can be converted into a vertical mattress suture by the use of a small needle.

Fig. 131. The blades (S, S) of a pair of curved-on-the-flat scissors in position to cut the palate aponeurosis and nasal mucous membrane from the posterior border of the bony palate. (mp) is the mucoperiosteum separated from the bony palate; (p) is the bony palate; (v) is the velum.

scending palatine arteries, the broader will be the flaps, and the less likelihood of their blood supply being seriously interfered with."

In the original von Langenbeck operation, which with us is the method of choice, the elevator that dissects the palate flaps is inserted through the lateral incision. In raising the flap, the point of the elevator, which should not be sharp, is kept close to the bone so that the artery and nerves will be lifted with the flap. Just in front of the opening of the posterior palatine canal they lie in a distinct bony groove. While these are to be lifted from the groove, the point of the elevator should dig into the opening of the canal. The vessels will

stretch, and the nerves yield until the flap can be moved toward the median line for an astonishing distance. It is usually practical to break through into the cleft with the elevator at the junction of the nasal and palate mucous membranes, thus doing away with the necessity of paring the borders of the cleft in the hard palate. If it is considered desirable to pare the borders of the cleft in the hard palate, it is done as follows:

In the case of a double cleft, a strip of tissue may be removed down to the bone, from the mucoperiosteal edge, on both sides, by reversing the position of the knife and cutting anteriorly as far as the limit of the cleft (Figs. 132, 133).

In a single cleft, part of the mucous covering of the nasal septum may be utilized with the palate flap on the side to which the nasal septum is attached. An incision is carried through the mucous covering along the surface of the septum parallel with the palate (Fig. 89). The height above the palate, at which this incision is made, will depend upon the amount of flap that is needed. If this incision on the septum is to be made at a considerable height above the palate, unless one has an especially constructed knife, it is best made by passing a small tenotome through the opening of the nostril on the cleft side and incising the mucous covering of the septum from behind forward, and then connecting the anterior and posterior ends of this incision with those at the palate border.

In clefts that extend well forward into the hard palate, it is often convenient to free the extreme anterior part of each flap by working from the cleft border. For this purpose, the Brophy elevator, that has the blade bent at an acute angle (Fig. 123), is especially useful.

The mucoperiosteal flap having been dissected from the surface of the bone on one side, the next and absolutely essential step is to free the velum from the hard palate by cutting the palate aponeurosis and the nasal mucous membrane at the posterior border of the palate process. This may be accomplished in clefts that involve both the hard and soft palates by passing a knife between the palate process and the mucoperiosteal flap and cutting upward and backward. In all cases, however, it is more conveniently done by passing one blade of a pair of sharply curved scissors between the bone and the flap and the other blade into the nasopharynx (Fig. 131). The mucoaponeurotic layer should be severed from the hard palate as far as the lateral incision. When the velum is freed, it should be possible to carry the median edge of the half palate well past the median line without tension. If it is not sufficiently movable, the fault will probably be that the aponeurosis has not been entirely severed. If the tension is due to contraction of the tensor palati muscles, it can be relieved by Billroth's plan of in-

serting a small chisel guided by the finger into the lateral incision, and fracturing the hamular process at its base. This will not permanently cripple the action of the muscle. The lateral incision is not to be ex-

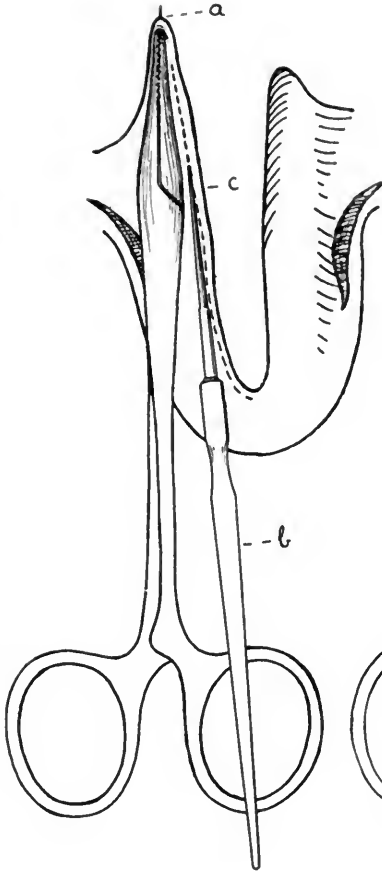


Fig. 132.

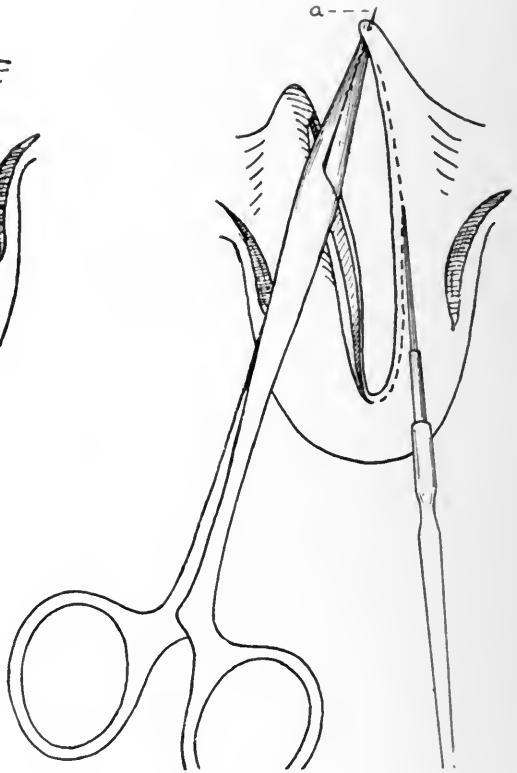

Fig. 133.

Fig. 132. Prod and knife in position for denuding the left cleft border. In elevating the mucoperiosteal flaps from the hard palate, they are at the same time freed from their continuity with the nasal mucosa. Therefore it is unnecessary to extend the cuts anterior of the junction of the velum with the hard palate.

Fig. 133. Knife and prod in position for paring the right cleft border. Ribbon of tissue is shown hanging from the left border of the cleft. If the border of the cleft in the hard palate has been freed with the elevator, the paring is done only in the velum.

tended straight backward indefinitely. At a point 1 centimeter behind the hamular process the ascending palatine arteries may be cut, and with them possibly the nerve supply of the levator palati muscles. If

further freeing is necessary, it is better to carry the incision backward and outward to the outer side of the anterior border of the ramus of the mandible. This may later cause some stiffness in opening the mouth, but this can be later overcome by a soft rubber dilator. If partial failure occurs after operation, it is usually at the junction of the hard palate and velum, and therefore, the flaps should be sufficiently free in this part. The distance to which the lateral incision may be carried anteriorly will depend upon whether the trunk of the descending artery has been injured in loosening the flap. If the artery has not been cut, the incision may be prolonged forward any distance without endangering the blood supply, but unless it is certain that the vessel is intact, the incision should not be extended in this direction. If for lack of this incision it is found impossible to coapt the edges of the flap in front, it is better to unite the posterior part, and postpone the anterior part to a later operation, than risk the misfortune of a sloughing of this part of the flap. The freeing of the flaps should be completed at this time. To extend the lateral incisions after completing the suturing is to court hemorrhage that may require repacking. Having ascertained that the palate flap is sufficiently freed, bleeding is controlled by temporarily packing the lateral incision with a strip of gauze. The freeing of the flap having been completed on one side, and hemorrhage controlled, it is repeated on the other. When methodically and properly done, this part of the operation takes but a few minutes. Whether the performing of the whole operation will require thirty-five minutes, or an hour or more, will usually depend entirely upon the care which has been given to each detail at the proper time. Very occasionally anesthetic difficulties or hemorrhage will be an unavoidable cause of delay. There are a few operators of considerable experience who free the flaps by inserting the elevator from the cleft border, without making lateral incisions, but this is not the practice of the majority.

During the whole course of the operation, bleeding is to be controlled mostly by temporary pressure; occasionally an artery can be caught with toothed forceps, but rarely can a ligature be applied. Sometimes a bleeding vessel can be included in a suture, but this procedure is not to be recommended where there is any danger of limiting the blood supply of the flap. Although several writers have stated that it is of little consequence, the cutting of the descending palatine arteries is to be dreaded more on account of the danger of ischemia than from hemorrhage, which is usually controlled by temporary pressure or packing under the flap. Plugging the canal has been recommended to control bleeding from this artery, but we have never found it necessary.

During the operation, the nasopharynx is to be kept free from

blood. If one can satisfy himself that he can sterilize marine sponges, they are more efficient than any of the newer substitutes.

The flaps having been properly loosened on both sides, the next step is paring the borders of the cleft in the velum. The prod (Fig. 121) is held in the left hand, and is inserted into the uvula near its tip, taking a good hold (Fig. 132). By pushing downward and backward, the cleft edge of the velum is made tense. The point of the knife, with its cutting edge toward the uvula, transfixes the velum at its base about 2 millimeters from the cleft edge and cuts a ribbon of tissue from the

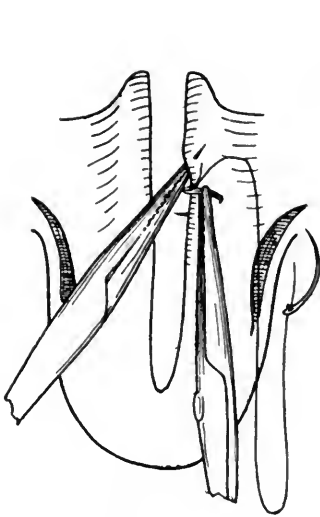


Fig. 134.

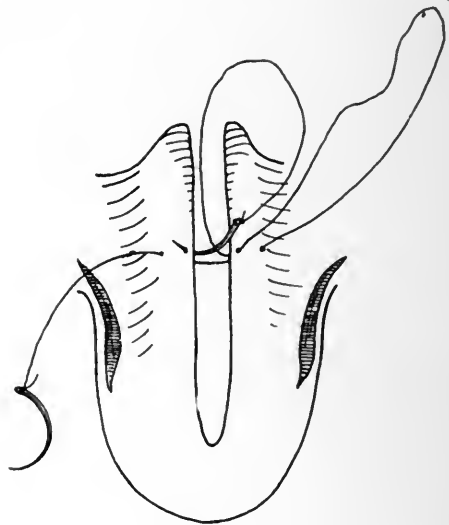


Fig. 135.

Fig. 134. Shows first insertion of the needle at the junction of the hard and soft palate.

Fig. 135. Showing the last insertion of the needle for the superficial part of the vertical mattress suture. This suture has the advantage of approximating broad raw surfaces.

free border, as far as the base of the uvula, that leaves a raw surface 5 to 8 millimeters wide. The median border of the cleft velum is one edge of a prism, and a slight variation of the angle at which the knife is held will make a considerable difference in the width of the resulting raw surface. We have for some time ceased to pare and unite the two halves of the uvula, for the reason that, when this is done, the latter shrinks to a small nodule, while the two halves of the uvula, if not molested, help to fill in the space to an appreciable extent.

We advocate postponing the denuding of the cleft border until after the flaps are freed from the bone, for the reason that, by doing



so, the raw surfaces are exposed for a shorter time before being coated by sutures. In actual practice it will be found that, after the palate flaps and velum have been freed from the bone, they become much elongated, and it is now difficult to hold them tense while the denudation is made. It is of the utmost importance that the sutures be not drawn too tight. This is apt to cause sloughing and non-union. The



Fig. 136.

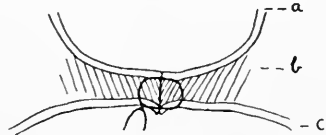


Fig. 137.

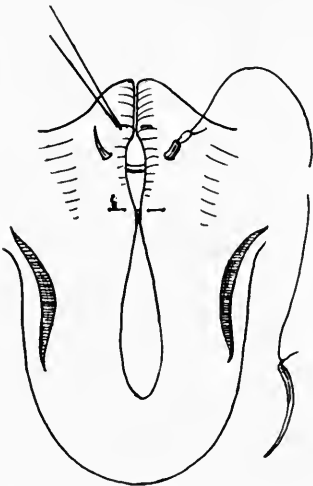


Fig. 138.

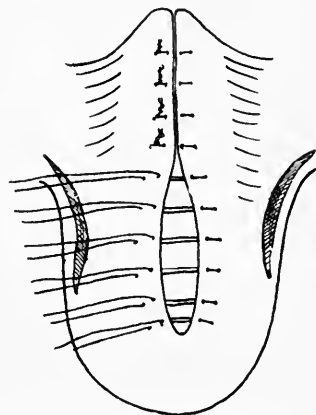


Fig. 139.

Fig. 136. Showing detail of vertical mattress suture in place, in the mucoperiosteal flap from the hard palate.

Fig. 137. Showing detail of vertical mattress suture in place in the velum. a, mucosa of nasopharynx; b, velum tissue; c, oral mucosa.

Fig. 138. Each suture is used to make the velum tense while putting in the next suture.

Fig. 139. The velum sutures are tightened before the sutures are placed in the mucoperiosteal flaps. The latter are all placed before any of them are tightened.

use of silver wire has the advantage that it can be accurately twisted to exactly the desired tension. After the operation the tissues will swell, and allowance must be made for this.

If the lead plates are used in connection with retention sutures, the packing should not be left in place after the operation is completed, as the palate flap is apt to be constricted between the packing and the

plate. In any case, the packing should be removed in twenty-four hours, as it promotes sepsis and has been responsible for extensive sloughing. Care should be exercised not to catch the packing gauze in a suture, as this would prevent its removal. It is safer to remove it before inserting the sutures. Packing that is to be left in place may be saturated with a 10 per cent solution of colloidal silver (Credé), or iodoform.

The various steps of paring the flaps and suturing and of applying the retention sutures and lead plates are adequately explained by Figs. 133-141.

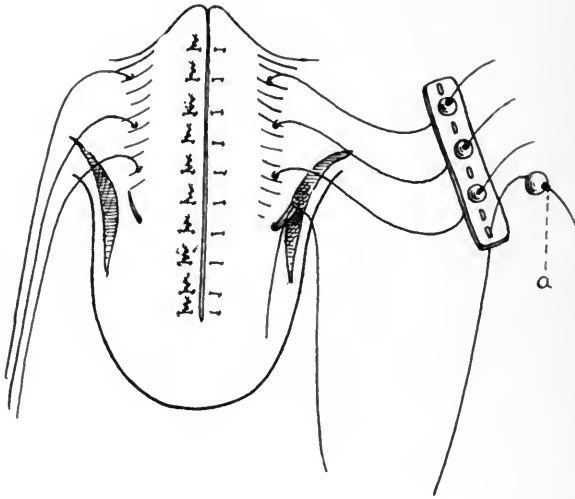


Fig. 140. Showing the method we formerly used in placing lead plates for supplementary support. For reasons stated in the text, we have abandoned the use of any form of supplementary support to the suture line.

When the operation is finished, the pharynx should be sponged out, and a careful inspection made to exclude active bleeding. This is done by lowering the head, with the patient turned well on one side. Then the blood would run into the hollow of the cheek and not collect in the pharynx.

### RETENTION DEVICES.

Before closing, it is proper to review briefly the subject of stay sutures and various other supplementary means of protecting the suture line and of relieving tension. It is an absolute essential of the operation that the flaps be freed so that they can be approximated without tension, and there is no contrivance that will compensate for a failure

in this respect. It is possible, however, but is by no means universally conceded, that, after the flaps have been properly freed and sutured, something more can be done by guarding against tongue pressure, the pull of the palate muscles, and the strain of coughing and vomiting. Tongue pressure may be eliminated by using silver-wire sutures, the ends of which are allowed to point downward in such a way as to cause discomfort when the tongue presses on the palate. Another device for guarding against tongue pressure, but which can only be used when molar teeth are present, is to have a vulcanite plate made that is fitted to the dental arch and which itself does not rest against the newly made palate. We have never tried this plan as it protects against tongue pres-

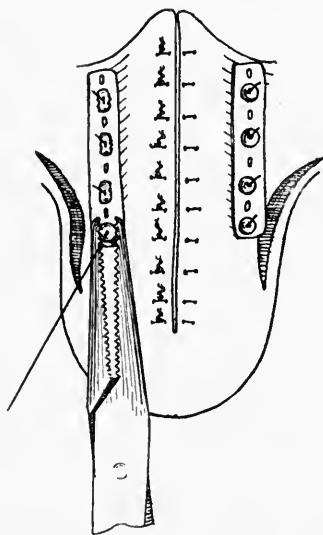


Fig. 141. The last shot being crushed on the lead plate stay suture.

sure only and it is not conducive to free drainage or cleanliness. Packing of the lateral incisions has been advised by some, but this is objectionable because, if left in place, the packing becomes foul and is conducive to sepsis and even to sloughing; the disturbance of changing would outweigh all of its advantages.

Charles Mayo has advocated the use of a piece of tape around the new palate through the lateral incisions, which is made into a band by means of a stitch or ligature. In this way the tissues are held toward the median line by the pressure of the tape band. We have had opportunities of observing very disastrous sloughing from use in less skillful hands. Judd, who now does much of the palate operating at the Mayo clinic, informs us that he does not use it.

Fillebrown, Brophy, and others have devised modifications of the old quill or lead plate suture, while especially constructed clamps have also been made. We formerly applied lead plates, as illustrated in Figs. 140, 141, but have discontinued their use, because they occasionally caused sloughing in spite of every care. It is our present belief, after a rather extensive observation, that, although these mechanical adjuncts may be helpful, in some cases they will cause sloughing. We have discarded them all, now depending entirely upon the sufficient freeing of the flaps.

#### **AFTER-TREATMENT.**

The patient is given water as soon after the anesthetic as desired, and a purgative is administered as early as possible to get rid of the blood that has been swallowed. Liquid food or soft jellies and gruels are given for ten days, and for the first few days all food and water should be sterile. The patient is not allowed to talk for ten days or two weeks. He is allowed to get up on the second or third day, unless there is fever. A mouth wash and a nasal douche are used from the first. In young children, simple saline solution is used, but older children and adults may use a mild mouth wash after each feeding and frequently between times.

The alkaline antiseptic solution (N. F.) diluted with three parts water makes an agreeable nasal wash, which is allowed to flow into the nose from a syringe or douche cup, while the head is held erect.

Lead plates may be removed at the end of two weeks, and the sutures at any time later. It is not well to make too frequent inspection of the palate during the first few days following the operation; and a tongue depressor should not be used, as it might cause gaping or even vomiting, which would be a strain on the line of union.

#### **POSTOPERATIVE HEMORRHAGE.**

Our observations coincide rather closely with Mr. Owens', in that we have but once had serious hemorrhage follow this operation. In this case it was controlled by packing. It seems to us that the use of an anodyne, packing the lateral incisions, and, if necessary, allowing the patient to sit up until syncope comes would control hemorrhage in most any case, except possibly of pronounced bleeders. If necessary, the patient should be anesthetized, the suture line opened, and the bleeding point found; or the packing could be sutured in place.

#### **NON-UNION.**

Except where tape, packing, plates, or some other means of retention have been used, sloughing at any place, beyond the grasp of the sutures, rarely occurs. A mild grade of sepsis following the operation

is not infrequent and is the usual cause of total or partial failure after a well-performed operation. It is evidenced by the persistence of a temperature of  $101\frac{1}{2}^{\circ}$  F., or over, and by a fetid odor. The sloughs fall away in three to four days, and if there is a failure of union, it will usually be evidenced by this time.

Besides the use of potassium permanganate solution locally, we think the use of small doses of quinin and calomel, continued for twenty-four or forty-eight hours, is helpful in this condition.

### REOPERATION.

After a non-union due to sepsis, Mr. Owen recommends reoperation at the end of two weeks; for at this time the flaps are still soft, and he believes that the patient has developed a resistance to the particular infection. We have followed this plan successfully, but thought there was excessive reaction following the second operation. We certainly would refrain from doing it in infants or young children. Unless there has been extensive loss of tissue, the flaps can usually be freshened and reapproximated without difficulty. In refreshing the edges of the flaps for a secondary operation, the edges must be denuded down to the normal tissue, as there is at the base of every granulating surface a plane of scar tissue that interferes with the rapid union that is necessary for success. Small defects may sometimes be made to close by touching the edges (more than once if necessary) with the actual cautery.

### MORTALITY.

We have had but one fatality from this operation. In this case there was good reason to believe, both from the symptoms and from other cases developing in the ward, that the child died of scarlet fever.

### RESULTS.

The later functional result will depend both upon the length and mobility of the velum and upon the ability of the patient to develop the use of the superior constrictor of the pharynx, and tongue, as aids of the velum, which latter after a late operation is always short.

As a general rule, the earlier the operation is performed the better will be the functional results. (See Speech Training, Chapter XVII.)

## CHAPTER XV.

### CONGENITAL PALATE CLEFTS—OPERATIONS FOR EXTRAORDINARY CASES.

With very few exceptions all cases of congenital cleft palate can be closed by the original von Langenbeck operation, described in the preceding chapter, but in some instances certain accessory procedures are advisable and even necessary. In a few cases, usually those in which large parts of the tissues have been lost after previous unsuccessful operations, it is necessary to employ radically different measures.

While the von Langenbeck operation will close almost every cleft, still, after a child with a cleft palate has passed the tenth or twelfth year, the velum will not have developed to the normal length. If the flaps are simply brought together in the median line, inability to completely shut off the nasal pharynx usually results, which is accompanied by what is recognized as the "cleft palate" speech. As the age of the unoperated case increases, this deficiency is apt to become more marked.

#### KÜSTER'S OPERATION.

The operation proposed by Küster, a modification of which is illustrated in Figs. 142, 143, to a certain extent overcomes this difficulty and is advisable in all cases of healthy individuals who have passed the age of eight or ten years and in whom there is sufficient palate tissue to allow its execution.

If the sum of the available palate tissue is in a proportion to the width of the palate of less than 5 to 7 (page 167), or even in this or near this proportion; if the patient himself, or the palate tissues, are not in the best condition, one of the two following accessory operations will be expedient.

#### TWO-STEP OPERATIONS.

The simplest modification of the von Langenbeck operation is to do it in two steps. In the first stage the mucoperiosteal flaps are loosened from the bone through lateral incisions, and the velum is detached from the posterior border of the palate process; but no incision is made at the cleft borders. The space between the flaps and bone is packed with gauze for a few days, when the operation is completed in

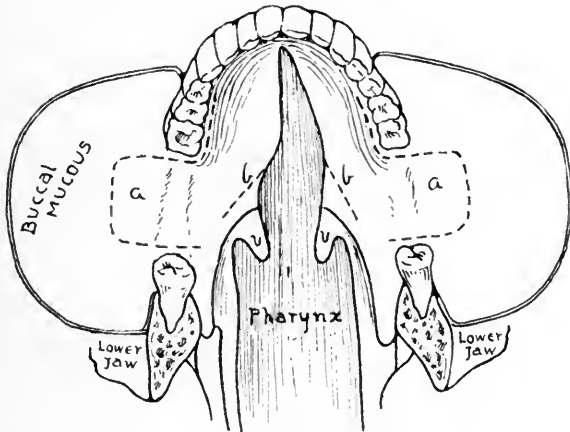


Fig. 142.

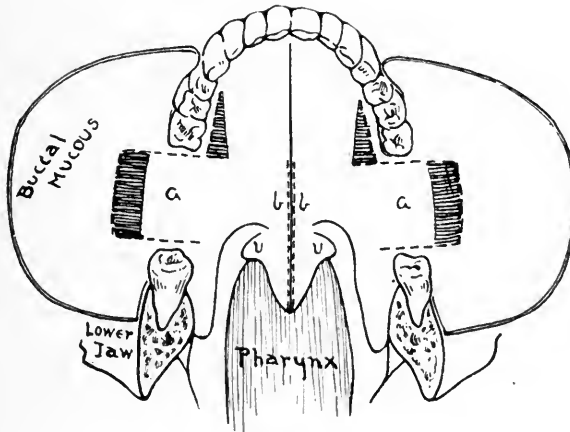


Fig. 143.

In Figs. 142, 143 Küster proposed the plan by means of the incisions (b-b) of lengthening the velum, but there is rarely sufficient palate tissue to permit of this being done without leaving such wide gaps at the site of the lateral incision that subsequent scar contraction renders the velum too tense to move freely. The figure shows a modification which obviates the latter difficulty.

(a) shows incision at lateral border of hard palate through the mucoperiosteum carried behind the maxillary tubercle and straight out on the buccal mucus for 1½ centimeters, then backward to the level of the lower jaw, and then inward; again cutting the pterygomaxillary ligament. The mucus, pterygomaxillary ligament, and buccinator muscle are cut through, and the flap is dissected up until the space between the internal pterygoid and tensor palati muscles is opened. The hamular process is cut across at its base.

The cleft borders of the velum are not freshened in the usual way; but the incisions (b-b) are made on each side through the whole thickness of the soft palate, and the flaps behind these incisions are rotated backward. In this way the incisions (b-b) are opened, and the raw surfaces thus exposed are sutured to each other at the median line (Fig. 143). As the two halves of the velum are carried toward the median line, the flaps (a-a) are drawn inward, and there will be no subsequent scar contraction to render the velum tense and comparatively useless. The space between the upper and lower jaw is still covered, and opening of the mouth is but slightly interfered with. This operation gives a longer velum than is obtained by the simple von Langenbeck operation, and therefore a better functional result. It will not permanently cripple the action of the superior constrictor muscle of the pharynx.

the usual manner. This procedure causes the tissues to stretch and thicken, and also increases their blood supply. It is our custom to saturate the packing gauze with a 10 per cent solution of colloidal silver (Credé) and to stitch it in place. It is applicable in cases in which the cleft is of more than moderate width compared to the available soft tissues of the palate, and also in cases where these tissues are thin and atrophic. The objection to this procedure is that, if for any reason the second operation cannot be performed within four days, the pack-

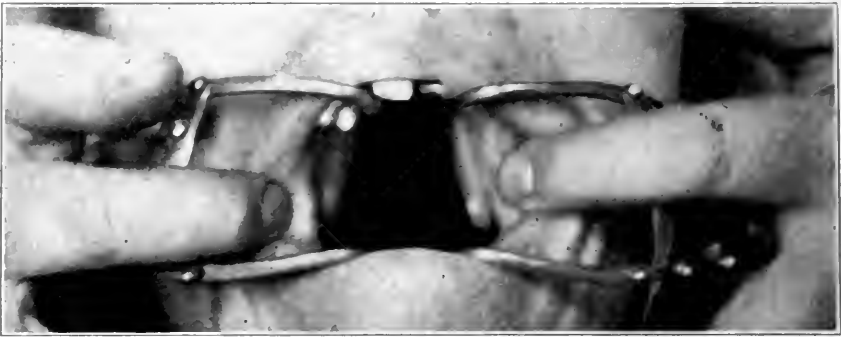


Fig. 144.

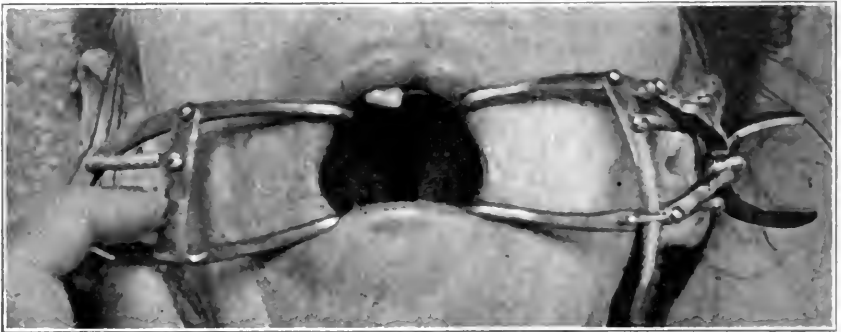


Fig. 145.

Showing amount that the cleft had been narrowed by packing under the flaps through lateral incision.

ing must be withdrawn. If allowed to stay in longer, there will be shrinking of the flaps. Figs. 144, 145 are of a case of wide cleft in an adult before and after this step and show the amount gained. Figs. 146, 147, 148 are of casts made of this case before the first and after the final operation. The dotted lines show the exact location of the lateral incisions which, where practical, were carried to the outer side of the gums. The patient was forty odd years of age; and the operation was done because she was losing her teeth on account of pyorrhea alveolaris,



and without a restoration of the palate she would not be able to wear artificial dentures. This case was one of those rare instances in which, although there was complete palate cleft, the patient learned to enunciate almost perfectly by using the base of the tongue against the pos-

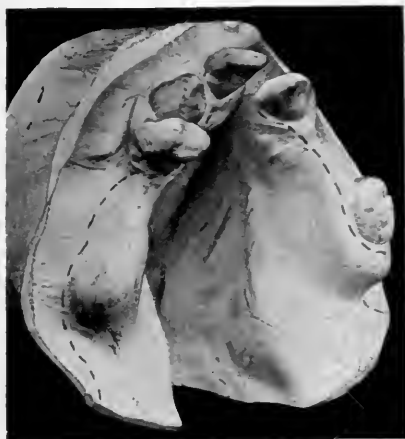

Fig. 146.

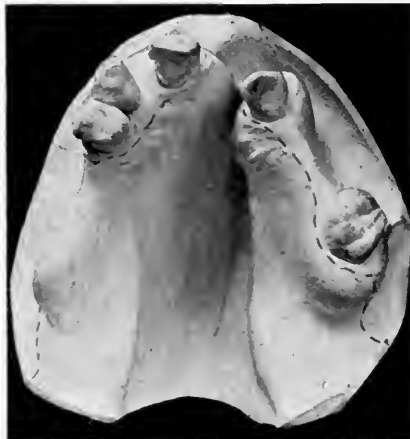

Fig. 147.

Showing two views of a wide cleft—before operation—that was operated on in two stages. The dotted lines show the outline of the lateral incisions.

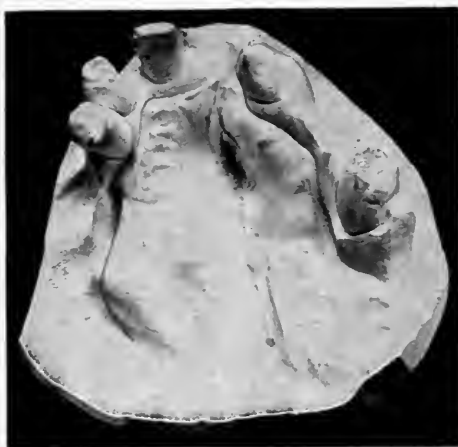

Fig. 148.

Fig. 148. Same case as shown in preceding figures after closure of the cleft.

terior wall of the pharynx to produce those sounds that ordinarily require the closure of the nasopharynx by the velum.

Figs. 149 and 150 are of casts before and after the closure of a wide cleft in an edentulous mouth by this method. The previous attempts by

the ordinary means had been almost complete failures. The case was that of a tubercular adult, whose home surroundings were such that without teeth she could not get proper nourishment. All of the teeth in both jaws had been removed before we first saw her. Fig 150 shows the final successful result.

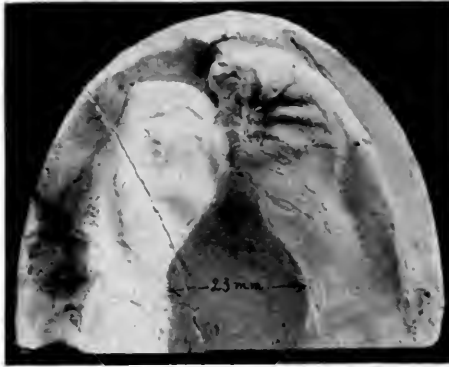


Fig. 149.

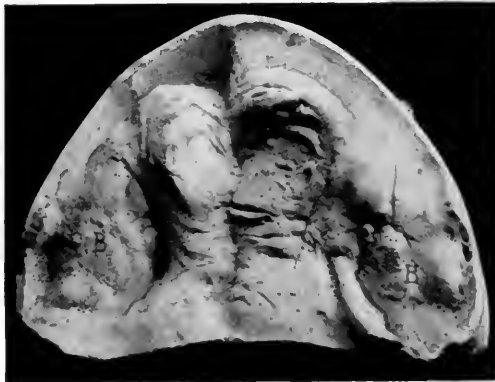

Fig. 150.

Fig. 149. Showing a very wide cleft that was closed by a two-step operation by first packing under the palate flaps.

Fig. 150. Showing exposed bone which later became covered with mucosa drawn from the neighborhood by scar contraction.

Another plan consists in driving a chisel through the palate process at the ordinary sites of the lateral incision and forcing the processes toward the midline. These lateral wounds are packed with gauze for a few days, when the palate cleft is closed in the ordinary manner.

#### APPROXIMATION OF THE MAXILLÆ.

Dr. G. V. I. Brown, of Milwaukee, and Prof. Herman Schroeder, of Berlin, have devised methods of narrowing the cleft in children by

means of orthodontic apparatus. Brown recommends this in cases of eighteen months to two years as a substitute for the early Brophy operation, while Schroeder uses it up to nine or ten years.

Figs. 151, 152 illustrate a case of a boy of six years with a cleft that was wide in proportion to the available palate tissue. The result in three weeks is shown in Fig. 152. The amount gained at the posterior

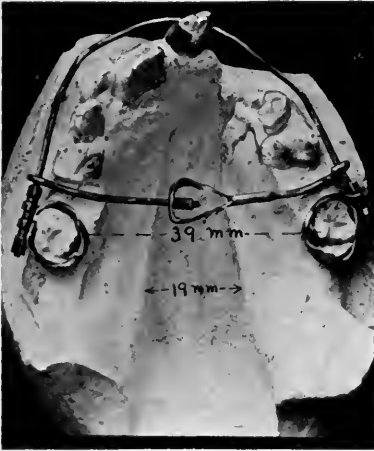


Fig. 151.

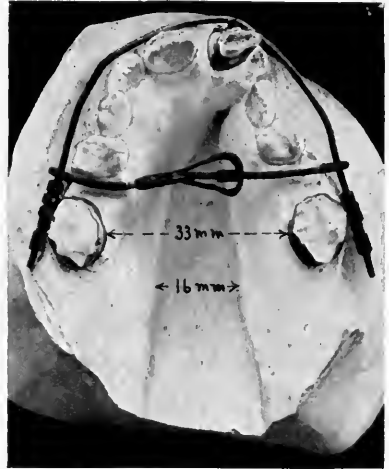


Fig. 152.

Showing plan of narrowing cleft by traction. This apparatus was constructed and applied at our request by Dr. LeGrand Cox of St. Louis.

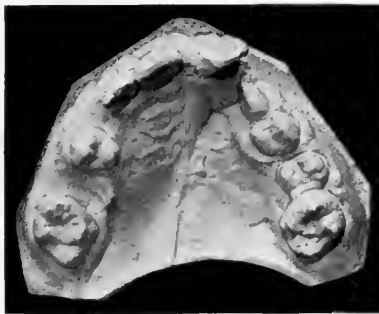


Fig. 153.

Fig. 153. Final result in case shown in preceding illustrations.

part of the cleft palate is shown in numerals, while it will be seen that the projecting intermaxillary process was pulled back into place and the alveolar part of the cleft approximated. Fig. 153 shows the final result which was obtained without difficulty by the ordinary operation. After removing the clamps, the maxillæ later spring back to near their original positions.

### REPAIR BY FLAPS FROM OTHER THAN PALATE SOURCES.

There still remain those cases in which much or most of the soft tissues covering the palate processes have been lost from sloughing after previous unsuccessful operation, and these can only be repaired by

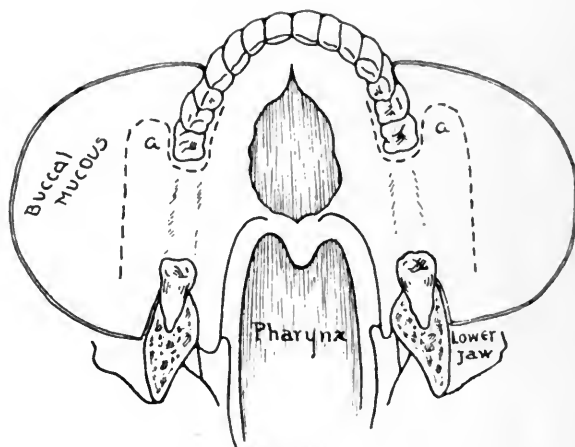


Fig. 154.

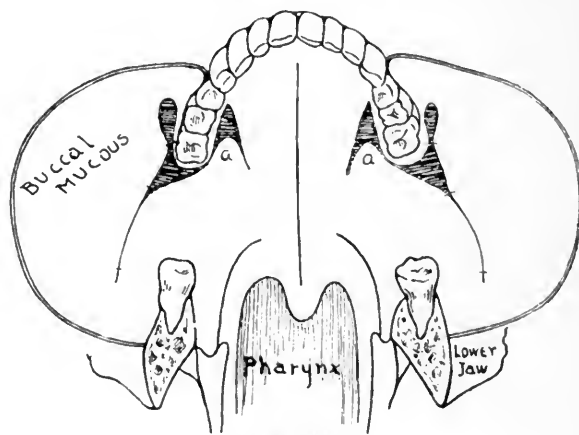


Fig. 155.

Showing method of gaining tissue from the cheek lining. Fig. 154 shows the incision that is made at the side of the hard palate through the mucoperiosteum, carried behind the maxillary tubercle, then skirting the alveolar process forward to the anterior border of the masseter muscle. It is then carried outward in the buccal mucous for 1 centimeter, and then backward. It cuts through the mucous membrane and the buccinator muscle, which structures are raised in a flap as far inward as the tensor palati muscle. The hamular process of the pterygoid process is fractured at its base. As the palate tissues are moved toward the median line, the flaps (a-a) are transferred to the palate, and the defect in the cheek is partially effaced by two sutures. In taking up this cheek flap, the anterior borders of the ramus of the jaw and of the internal pterygoid muscles are exposed, and the space between the internal pterygoid and tensor palati muscles is opened by passing in a blunt instrument and pushing the velum toward the median line. Fig. 155 shows the completed operation.

flaps derived from some extrapalatal source. The following procedures are applicable in certain cases where palate tissue has been lost from ulceration or at an operation for the removal of a growth.

If the posterior border of the velum has been preserved—and this is a part we have never observed to suffer from a postoperative sloughing—the velum and the posterior part of the hard palate can be reconstructed by the procedure illustrated in Figs. 154, 155.

In taking up the flaps in a secondary operation, any tissue that immediately turns to a dark purplish red is to be discarded at once, for it is granulation or scar tissue that will not survive after being raised from its bed. The operation illustrated in Figs. 154, 155 is possible even after lateral incisions were made at the outer border of the velum at a previous operation, for the nutrition of the flap will come from its attached posterior part.

The cleft in the hard palate may be restored by a flap turned from the buccal surface of the cheek or from the neck. If there is a hare-lip, the border of the lip cleft makes a convenient base for the pedicle of the buccal flap. In a child a fairly extensive flap may be taken from the inner surface of the cheek without causing any inconvenience or deformity. This flap should include enough submucous tissue to insure the blood supply.

The plans of operation illustrated in Figs. 154, 155 are applicable only in cases in which some of the mucous coverings of the palate has been preserved on each side. If this tissue has been lost through the whole of its transverse extent, then repair can be made only by means of a flap obtained from an extraoral source. If this is the case, the edges of the defect and the scar-covered surfaces of the palate processes are denuded, and special care is taken to remove all scar bands that draw the velum forward. It is just as easy to fill a large gap as a small one with a flap from the neck, and the longer the palate the better the result. (For general plan of making the neck flap, see page 219.)

In planning the length of the flap, it is to be remembered that it must reach from the lower border of the cheek to the roof of the mouth and then to the edge of the palate defect without tension while the mouth is partially open. If, after the flap has been fastened, it is found to be too short, it may be lengthened by extending the cuts upward on the cheek, but this will leave scars in a conspicuous place. There will be no question about its antero-posterior extent, for the flap should be made nearly 5 centimeters wide to insure the blood supply. The flap is sutured with silkworm gut or silver wire, skin edge to mucous edge, across the anterior border of the velum, the lateral border of the defect of the side opposite to that from which the flap is

turned, and across the posterior border of the remaining mucous tissue of the hard palate. These sutures should not be too numerous or drawn tight. Eight or ten days later the flap may be cut across at the palate border, and the pedicle again turned on to the neck for the repair of the upper part of the external wound.

Before the flap is cut across, it is well to test the local blood supply of the implanted part by gently constricting its base with a pair of forceps.

While the flap is in place, until the base is cut, the jaws must be held apart to prevent the teeth from shutting off the blood supply. This may be done by wiring a block of wood or a piece of a rubber stopper between the bicuspid teeth on one side. It is very much safer and more satisfactory, however, to have an accurately fitting piece of

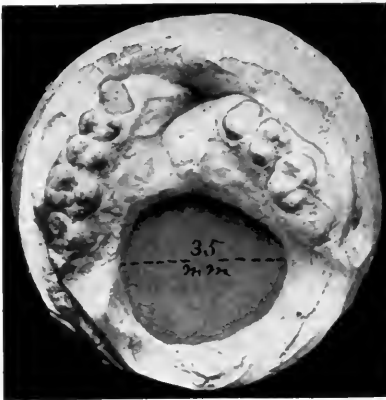

Fig. 156.

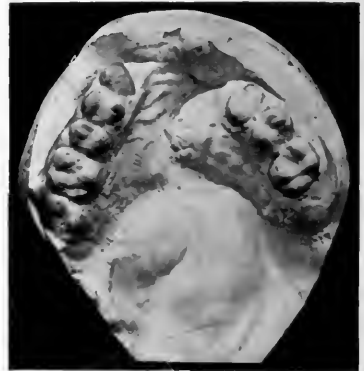

Fig. 157.

Showing extension defect resulting from postoperative sloughing, and the result obtained by the use of a flap from the neck.

metal, made beforehand by a dentist, which is fastened by wires to rings on tooth bands above and below.

Fig. 156 shows condition after a second failure with extensive postoperative sloughing, following attempts to close the cleft by the von Langenbeck operation.

Fig. 157 shows restoration by the method just described.

Fig. 158 shows the neck flap in place in the mouth before being cut loose. Fig. 159 shows the condition of the neck one week after the flap was taken from the neck, but before the pedicle was released from the mouth.

Owing to the abundance of tissue obtained, this gives a longer velum and a better functional result than is ordinarily obtained in adults by the von Langenbeck operation. It leaves but a linear scar to show where the tissue has been removed from the neck. In a num-

ber of cases where we have resorted to skin flaps from the neck for the repair of mouth and palate defects, no inconvenience has been observed as a result of transplanting skin into the mouth. It soon takes on an appearance which closely resembles normal mucous membrane.

In one case we successfully resorted to this method in restoring part of the velum, the fauces of one side, and part of the oral pharynx,

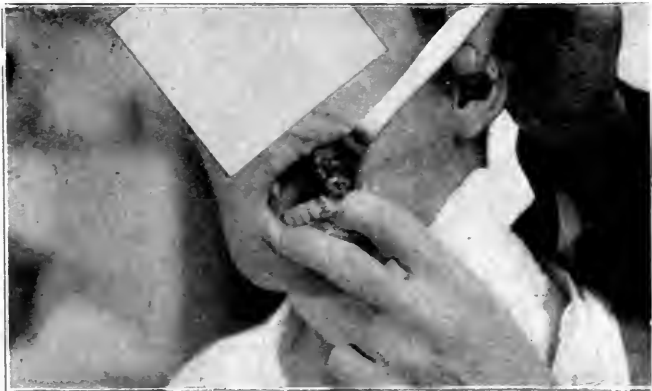

Fig. 158. Shows permanent gag in place, and neck flap sutured into the palate defect.

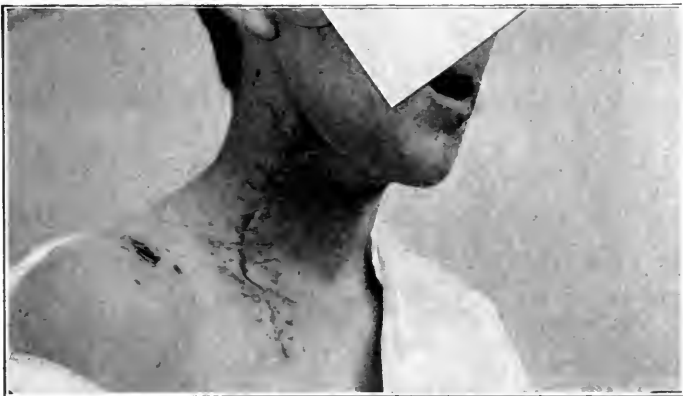

Fig. 159. Shows neck defect almost entirely obliterated by drawing the skin edges together. The upper triangular defect still remaining is closed with the pedicle of the flap, after it is cut and withdrawn from the mouth.

after an excision of a malignant growth. In another we failed to close a palate defect after taking a flap from both sides of the neck in turn, owing to progressive sloughing of the flap. This was in a syphilitic child.

The idea of repairing palate and other intraoral defects with epithelial tissue from other sources is not new; Blaisus, Thiersch, Rotter, and other surgeons having reported such cases.

## CHAPTER XVI.

### CONGENITAL CLEFTS OF THE LIP AND ALVEOLAR PROCESS—OPERATIVE CORRECTION.

Cleft of the lip and cleft of the alveolus are presented together, because the latter seldom occurs in the absence of the former and because, surgically, the closure of the alveolus is related more intimately to closure of the lip cleft than to the palate cleft when the latter is present. In the presence of cleft palate there is nearly always at least an occult bony cleft in one or both sides of the alveolus. This is sometimes evidenced by a simple irregularity of the teeth or a notch.

In discussing the treatment of alveolar cleft it is convenient to do so as follows: single or double clefts in young infants; single cleft at

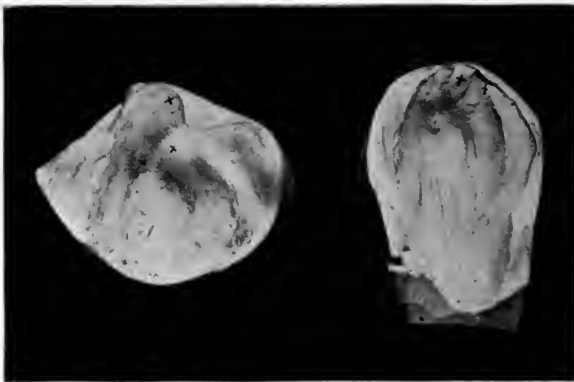


Fig. 160. Showing a condition in which the end of the alveolar process to the outer side of an alveolar cleft is situated behind the intermaxillary bone. To correct this, the end of the alveolar process of the maxilla must be loosened and pushed outward, as shown in the second figure, before the intermaxillary bone can be replaced.

later periods; and double cleft at a later period. In each the following rule holds true: The intermaxillary bone is never to be removed but is to be placed in the best attainable position, usually the cleft borders being denuded to the bone so that raw surfaces will be in contact when the gap in the process is closed. When the process is replaced, the attachment of the nasal septum and columella should be in the midline. It is usually much more satisfactory to wire the process in its new position than to trust simply to lip pressure maintaining it there. In infants the bone may be pierced by a strong needle, but in older individuals the bone will have to be pierced with a drill or better still



with a fine trocar and cannula. The latter idea is borrowed from Dr. Allison, who uses it in wiring the tarsal bones (Fig. 161). In infants the needle must be inserted above the tooth buds; in older children and adults the bone is pierced between the roots of two teeth.

### CORRECTION OF ALVEOLAR CLEFTS IN INFANTS.

The alveolar cleft, as well as the lip, should be repaired at the same time as the Lane or Brophy operation is performed. The latter operation usually consists in little more than re-establishing the continuity of the alveolus, and we doubt whether any more extensive bone shifting

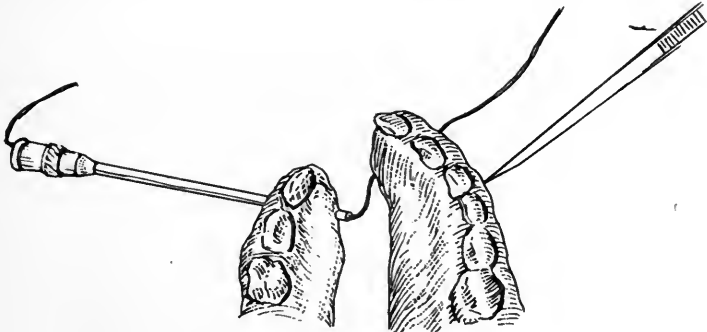


Fig. 161.

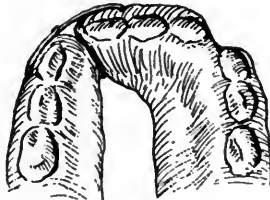


Fig. 162.

Fig. 161. Correction of alveolar cleft. A small chisel is inserted between the roots of the cuspid and incisor, and the bone is fractured up into the nasal fossa. Before doing this, a wire is inserted through the alveolar process on each side of the cleft by means of a trocar and cannula.

Fig. 162. Shows the fractured part of the alveolar process bent over to fill the gap, and the wire twisted to hold the bone in place.

is ever necessary or always advisable. In early infancy it is not necessary to cut the nasal septum in order to replace the intermaxillary bone. If the cleft is limited to the alveolar process, it may be necessary to remove or incise some of the palate process of the maxilla, just behind the cleft, before the protrusion can be pushed back into line. This is done submucoperiosteally with a small chisel or bone forceps. In some cases the alveolar process to the outer side of the cleft will have traveled toward the median line, and it is necessary to pry it outward in order to make room for the intermaxillary process (Fig. 160).

### CORRECTION OF SINGLE ALVEOLAR CLEFTS AT LATER PERIODS.

Before six months, when there is also a palate cleft, the protruding process can be pushed back by thumb pressure. In older children the protruding process may be brought back into place by an orthodontic apparatus (Figs. 151, 152), or more quickly by fracturing the alveolar process up into the floor of the nose, by inserting a chisel between the roots of the cuspid and lateral incisors of the side opposite to the cleft (Figs. 161, 162). Many surgeons simply repair the lip, depending upon the pressure of the lip to force the process back into place. We

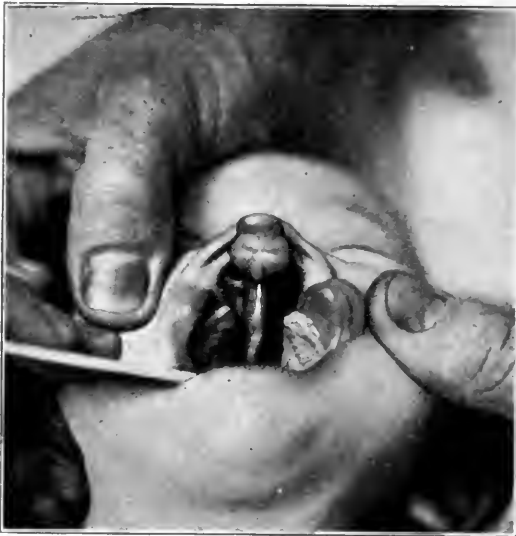

Fig. 163. Complete double cleft in an infant. White line shows where the mucous membrane is incised at the lower border in order to remove a V-shaped piece from the septum.

do not believe this is to be recommended because of the difficulty of making a satisfactory lip repair over the protruding process.

### CORRECTION OF DOUBLE ALVEOLAR CLEFTS AT LATER PERIODS.

In double complete cleft, the intermaxillary process travels forward at the expense of the columella; and to replace it after early infancy, the septum must be incised behind the intermaxillary bone, or a V-shaped section must be removed at this site (Figs. 163, 164, 165). This shortening of the columella is more apparent than real, and usually, in replacing the intermaxillary bone, it has been moved too far back. The result of this is that the end of the nose is drawn in and the inter-

maxillary is rotated until the contained incisor teeth point somewhat backward. Only a very small section should be removed from the nasal septum, and in repairing the lip, the lateral portions should be brought forward to the apparently still prominent prolabium. This will

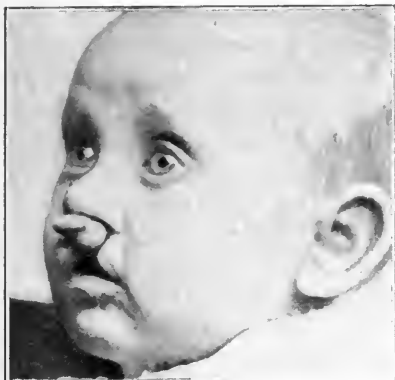

Fig. 164.

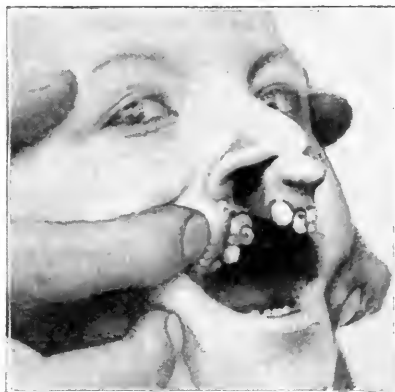

Fig. 165.

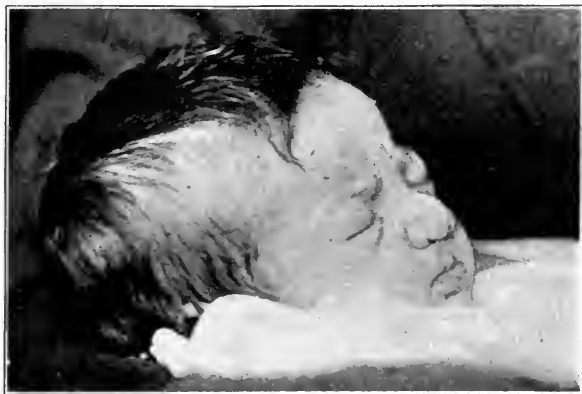

Fig. 166.

Fig. 164. Showing permanence of intermaxillary bone and short columella. Infant of 9 months.

Fig. 165. Showing same condition as in the preceding illustration. Child 5 years old. This condition will persist as long as the lip cleft is unrepaired.

Fig. 166. Showing the drawing in of the nose after replacing a protruding intermaxillary process. This condition improves very much in time, and the earlier the operation is done the better.

preserve the prominence of the lip and partially prevent the flat appearance that is so frequently seen after an operation for double cleft of the lip and alveolus (Fig. 166). In young infants this is not difficult to do, but later there are intraoral conditions that may make it impracticable to get immediate union between intermaxillary and palate

parts of the alveolus. As a rule, some of the alveolar tissue is missing, so that in order to obtain firm bony union between the intermaxillary and the maxillary bones it is necessary to place the former farther back than it belongs. In young infants the anterior part of the two halves of the palate can be approximated by a Brophy operation so that the intermaxillary will sit in front of, rather than between, the maxilla. At later periods it is better simply to set the intermaxillary bone back to its proper position without denuding the cleft borders. After the lip wound has healed, an electric or Paquelin cautery blade may be thrust into the cleft on either side. If the lining mucosa is destroyed, this will be followed by bony, or strong fibrous, union.

### CORRECTION OF HARELIP.

We repair the lip at the same time as the alveolar cleft. There have been so many various operations proposed for the repair of hare-

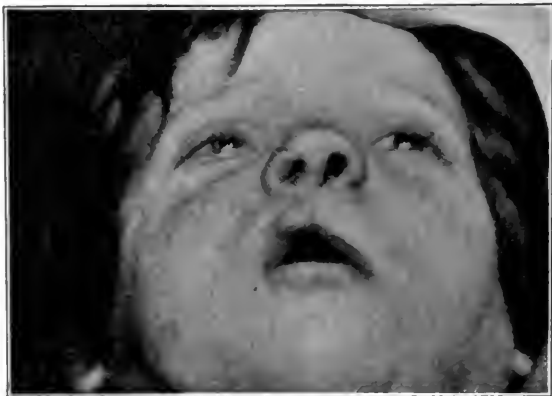

Fig. 167. Showing constriction of nostril that may occur from an infolding of the upper part of the ala.

lip that one seeking help from the surgical textbooks is likely to be confounded by the wealth of ideas suggested. But four will be presented here, for the reason that one of the number will be found adequate for almost every case, and that we believe they will not only give the best results, but the plan of each of these is easily carried out. Among others, we have discarded the time honored Nélaton operation because it will seldom give an accurate result.

Regardless of the plan of operation chosen, it is a good practice to outline the cuts by scratching on the skin with the point of a knife before actually making the incisions, and the use of some sort of a measure or of a pair of compasses will give greater accuracy. In this way one is not confused by the flow of blood, as may be the case when he attempts to plan and cut at the same time. It is very pretty to watch

a skilled operator make his flaps with two or three quick cuts, but the average surgeon will get far better results by the method suggested above. It is usually necessary to undermine the lip in order that it may slide over to its new position without tension. The lateral segment of the lip is often closely attached to the alveolar process by a sort of frenum; this is cut, and the lip and cheek are freed from the maxilla with an elevator that hugs the bone closely. If necessary, the opening in the mucosa at the fornix may be enlarged. The ala should not be freed higher than is necessary as when it is entirely detached it tends to fold inward and to obstruct the nostril (Fig. 167).

An almost absolute essential to the making of accurate incisions is a thin narrow-bladed knife that has an edge so sharp and smooth that it will not drag on the lip in cutting. After the flaps have been outlined, before the cuts are made, at least in infants, hemorrhage should

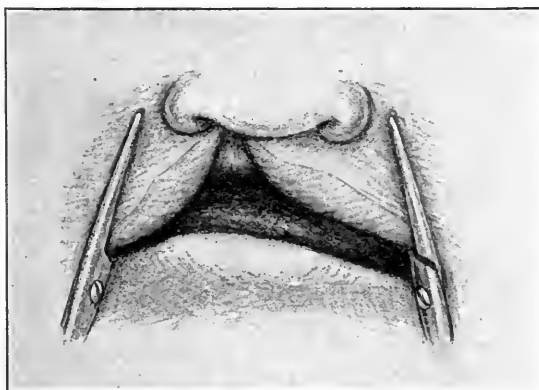


Fig. 168. Showing method of partially controlling hemorrhage while paring the cleft borders.

to a certain extent be controlled. This is done by grasping each half of the lip with a pair of straight-sided tenaculum forceps that are held tight enough to constrict the tissues without crushing them; artery forceps may be substituted for these (Fig. 168). The intraoral prong of each pair of forceps is thrust through the mucous membrane at the upper fornix and into the tissues of the face.

### ROSE OPERATION.

This consists of the removal of a semioval-shaped piece from each side of the lip cleft so that when the two concave raw surfaces are pulled straight and approximated the lip notch is obliterated. The originator of this operation used it for all sorts of clefts, but it is especially appropriate for cases of partial cleft, for notches remaining after previous operations, and for cases of complete harelip in which little

of the lip tissue is missing. It has the virtue of simplicity and is easily performed (Fig. 169). In making the incisions, the following points are to be borne in mind:

1. The full thickness of the lip is to be incised, no more being taken from the cutaneous than the inner surface, and vice versa.
2. The incision must traverse the mucous border of the lip at a place where the latter is of the full normal breadth. Sometimes close to a lip notch the mucous border is narrower than at the other parts.

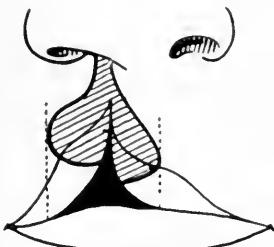


Fig. 169.

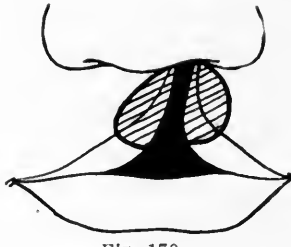


Fig. 170.




Fig. 171.

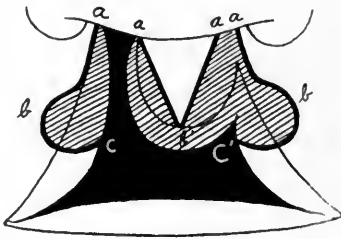


Fig. 172.

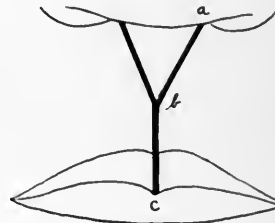


Fig. 173.

Fig. 169. Outlines of incisions in a Rose operation for partial lip cleft, in which there is also a spreading of the nostril of that side. By the vertical dotted lines it is seen that the incisions extend laterally as far as the widest part of the cleft. It will also be seen that the length of each cut within the vermillion border of the lip is the same. If the lengths of the two curved incisions were measured, it would be found that they were of the same length on each side. These are the three important points in designing the incisions of a Rose operation.

Fig. 170. Incisions for Rose operation of a complete single cleft.

Fig. 171. After making the incisions for the Rose operation, the ala is replaced with one suture, and the newly pared borders are approximated and put on the stretch by a tension suture placed at the mucocutaneous border.

Fig. 172. Rose operation for double harelip, incomplete on one side.

Fig. 173. Completed Rose operation for double harelip.

3. The convexity of the lip incisions on each side of the cleft must extend laterally as far as the widest part of the cleft, which latter is always at the lip border (Figs. 169-173). When the new lip is completed, there must be a teat at the lower end of the suture line. This is to allow for scar contraction. In this, as in other operations, the borders to be united are approximated by stay sutures at each end; by drawing upon these, slight inequalities in length between two borders are thus equalized (Fig. 171). The outer surface and red border

of the lip are united by a fine continuous running suture that includes only the skin or mucosa. The deep approximation is made with one or two modified Lane sutures (Fig. 22). The Rose operation is particularly adapted to the correction of the result of a poor operation (Figs. 174, 175).

### OWEN OPERATION.

This is more appropriate for single clefts with widely diverging borders, and is the one we prefer for most cases of complete single harelip. When properly done, this gives a very good lip that is not tight at its lower border, and as the scar crosses the mucous border at the angle of the mouth, it is not very noticeable. The incisions and the manner of suturing are shown in Figs. 176, 177, 178. The transverse incisions are usually made about midway between the mucocutaneous

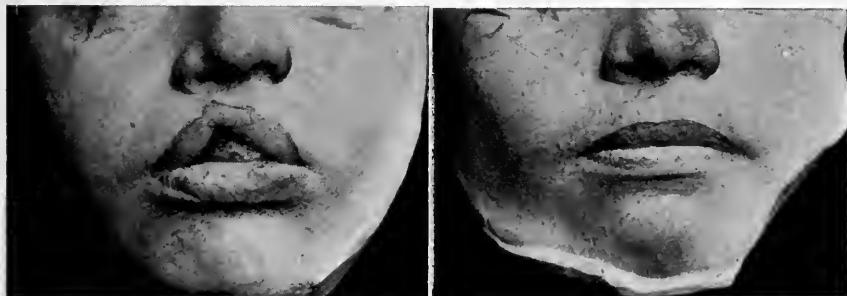

Fig. 174.

Fig. 175.

Fig. 174. Cast of lip and nose of a girl sixteen years old, who had a very poor operation done at three years.

Fig. 175. Same case as shown in preceding figure. Cast made some months after a Rose operation.

border and the nose. As with the Rose operation, it is important that the incision traverses the lip in such a way that it is the same distance from the lip or cleft border, on the cutaneous as on the mucous surface.

### OPERATION FOR DOUBLE HARELIP.

For those cases in which the cleft is complete on one side but partial on the other, we use the Rose operation (Fig. 172). For complete double harelip where the clefts have a complete mucous border, the plan shown in Figs. 179, 180 is simple and satisfactory.

After operation no dressing but a dusting powder is placed on the suture line, or it is painted with alcohol or colloidal silver.

After completing any operation for harelip, some plan should be adopted to take off the pull of the buccinator muscles. Several plans

of doing this have been used; one is simply to place a single strip of adhesive plaster across the lip and cheeks from ear to ear. To avoid placing the adhesive plaster across the lip wound, common dress hooks may be sewed on the ends of the two shorter strips, one set of the hooks resting on each side of the lip wound. These are laced together with silk thread. This will not prevent slipping of the ala of

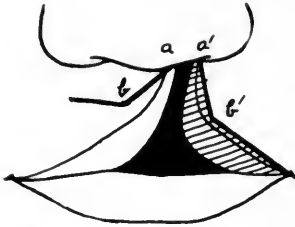


Fig. 176.



Fig. 177.

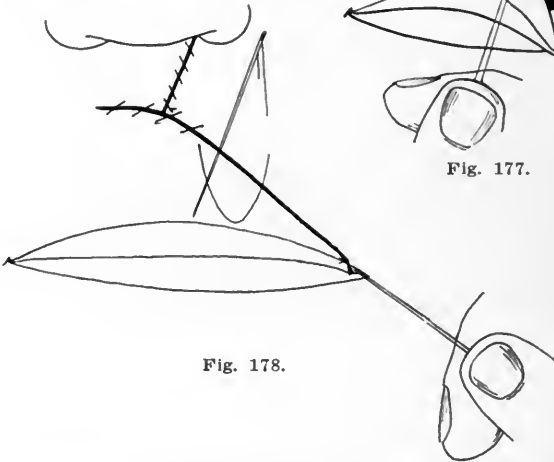


Fig. 178.

Fig. 176. Incisions for the Owen operation on a single harellip. The important points are to make the transverse cut parallel with the mouth slit; to make (a-b) equal to (a'-b'); so to place the point (b) that the flap will be of the proper width to fill the gap below (b').

Fig. 177. Owen operation. Nostril has been approximated by one deep suture, and the borders of vertical part of the cleft by another, at their lower end. The latter is used as a traction suture to approximate and make even the cleft borders while the superficial sutures are put in place.

Fig. 178. Owen operation for single harellip. Suturing of the transverse incision.

the nose, and even silk threads resting over the lip wound are objectionable; therefore the transverse straps have been rather generally abandoned. Placing narrow strips of adhesive plaster from under the chin, around the cheek, across the bridge of the nose, and on to the forehead on both sides will draw the cheeks toward the nose and somewhat relieve the strain. It has the advantage of not covering the lip, but it will not entirely prevent spreading of the nostrils. These straps should be retained and, when they slip, replaced for eight or ten days.



Twice we have seen a well-placed nostril spread wide open on the fifth or seventh day when the straps were prematurely removed. On account of the occasional slipping of the ala, even with these straps, we have adopted Gilmer's modification of Garretson's use of lead plates (Fig. 181).

### CORRECTION OF DEFORMITY OF THE NOSTRIL AND NOSE.

In repairing a harelip, the restoration of the nostril and ala is usually the most difficult part of the operation. Even in cases of slight lip notch there is usually some spreading of the nostril with a displacement of the columella, septum, and tip of the nose to the opposite side; in complete single cleft the ala of that side may be absolutely flat, with a still greater displacement of the septum and nose. In double harelip the nose remains in the midline, but both alæ are spread laterally.

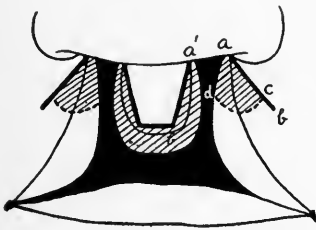


Fig. 179.

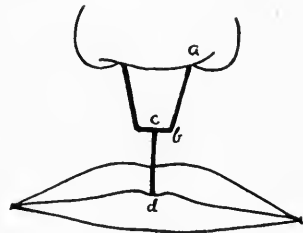


Fig. 180.

Fig. 179. Operation we use for complete double harelip. The tissue within the cuts (c, d, a) is discarded on each side, as is the border of the prolabium.

Fig. 180. Operation for complete double harelip completed.

In planning the incisions, we aim to make the inlet of the nostrils smaller than normal, for it usually happens that, in spite of careful approximation and suturing, the ala slips and the nostrils widen within a week. The incision is made close to the lower border of the ala, but the least possible amount of tissue is removed from within the nostril; for it is easy to block the nostril by an infolding of the upper border of the ala cartilage (Fig. 167). If this occurs, the impinging part of cartilage may be removed submucously. Often, immediately after suturing the ala in babies, the external opening is reduced to a mere slit or is completely closed; but this begins to open in a few days, and gradually the proper shape of the nostrils is restored. If, however, the nostril is blocked by an infolding of the upper border of the ala cartilage, it never completely corrects itself. To prevent slipping of the ala, after it has been properly placed, is difficult, some slipping occurring in most cases. In addition to careful, deep suturing, so far,

the most effective plan we have tried has been the lead plates (Fig. 181). These must be placed a little distance from the ala and are held in place with a shotted silver wire.

In reoperating on a case in which the nostrils spread, the ala is dissected loose from the cheek and replaced after removing a diamond-shaped piece from the floor of the nostril and upper part of the lip. If the ala is much spread in an adult or older child, we have found it expedient not only to free the ala from the maxilla but also to carry an incision outward just below the ala out through the full thickness

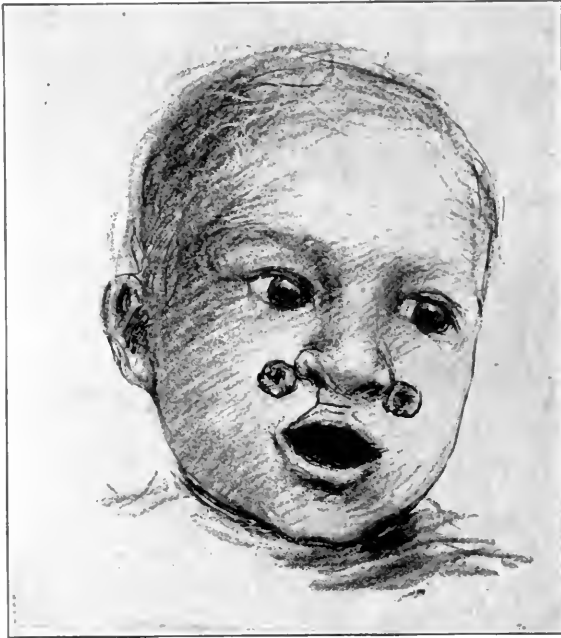

Fig. 181. Showing lead plates on cheek. Through these is passed a silver wire that traverses the tissues of the face above the level of the lower border of the alæ. These wires are shotted.

of the cheek for 15 millimeters; this usually allows of easier adjustment of the ala.

In young infants the columella, the septum, and the nose itself will be drawn to the midline when the intermaxillary bone is restored to its proper position. When the lip cleft has been allowed to persist, unoperated, or only partially obliterated, the external nose and septum become permanently distorted; the columella can be drawn over with the lip, but the lower anterior part of the septum with the external nose will remain in its lateral position. When this distortion is sufficient to be noticeable or causes partial nasal obstruction, it may be corrected as follows:

Through the upper fornix, the lip is dissected up as far as the lower part of the anterior nasal spine of the maxilla. A chisel with a blade about 1 centimeter broad is placed against the base of this spine; it and the lower part of the septum are cut straight backward for about 4 or 5 centimeters. With a small hooked septum knife, the septum is again cut completely through from near the nasal spine of the frontal bone vertically downward to intersect the first cut (Fig. 182). Having freed a triangular flap of septum, a thin, soft-silver wire is passed through the lower part of the septum near the nasal spine, and the septum and spine are held in their proper position by anchoring this wire to a bicuspid tooth (Fig. 183). This will draw the septum and

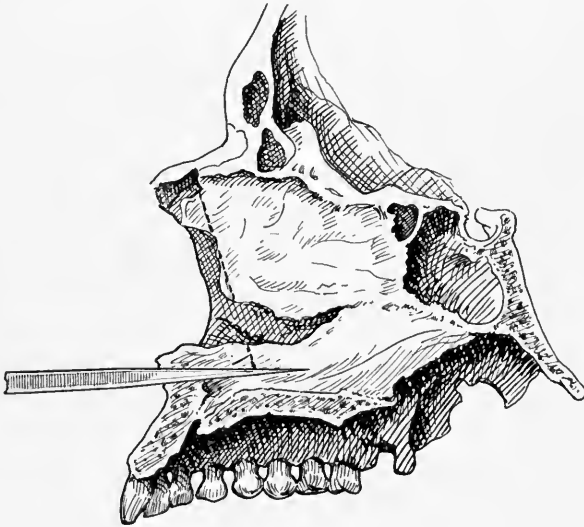


Fig. 182. Correction of a deflected septum. Dotted line shows line of incision through septum, made with hooked knife. Chisel in place shows how the bone of the septum is cut from the maxilla.

the tip of the nose to the midline. If the nasal bones share in the deviation to a marked extent, they may be brought over by laying a thickly folded towel against one side, fracturing the bones by striking them with a mallet.

This plan of replacing a deviated nose was, as far as we know, first practiced by Dr. E. M. Senseny, and we have found it fairly satisfactory. If the nasal bones are not prominent, especially in children, we cut the nasal bones *en masse*, subcutaneously from the maxillary and frontal bones. This is done by inserting a narrow straight chisel into each nostril, in turn, and applying the edge to the junction of the lower border of the nasal bones with the maxillæ. It is driven upward on each side, as high as the frontal bone. The chisel is guided

by feeling one corner under the soft tissues of the face as it travels upward. The attachment of the nasal bones to the frontal is not cut entirely through. The nose is shifted in its proper position by thumb pressure. To hold the nose in the proper position, two holes are drilled through the skin and nasal bones on the side to which the nose has deviated. The two ends of a No. 24 soft-silver wire are, in turn, threaded with a long, straight needle and passed through the two holes in the bone, through the nasal chambers and septum, through the tissues of the cheek, into the vestibule of the mouth in front of the last upper molar tooth. Here they are anchored at proper tension to a wire band on the last upper molar (Fig. 184). By incising the skin down to the bone between the two drill holes, the external loop of the wire becomes buried. This is the only satisfactory plan we have ever

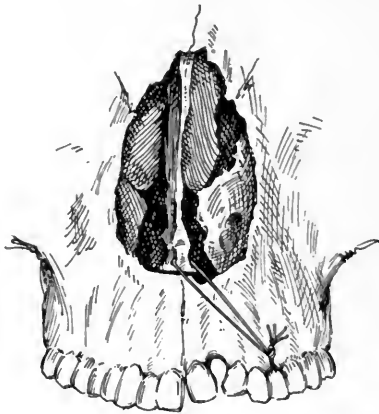


Fig. 183. Correction of a deflected septum. The septum having been freed, as shown in the preceding figure, it is anchored in its new position to a bicuspid tooth with silver wire.

tried for holding the nose in position. In our hands, external appliances have been very unsatisfactory. We also use this plan for readjusting the nose after a malunion from fracture.

#### DIFFICULT RESPIRATION AFTER A LIP OPERATION.

It often happens that, after an operation for harelip, especially in an infant, there is difficult respiration, evidenced by restlessness and by sucking in of the lips at each inspiration. If this is not relieved, the child emaciates rapidly, and we believe this has been the cause of postoperative depression in some of our earlier cases. Suturing down the lower lip is seldom satisfactory, and we have resorted to the practice of using a breathing tube (Fig. 185) in every case of harelip operation in an infant. The tube is removed at first only for feeding; but

usually after a few days the nostrils become free, and the breathing tube may be dispensed with.

#### AFTER-TREATMENT.

The wound is covered with a simple dusting powder, and crusts are not allowed to collect. If retention straps are used, they are readjusted when needed, and retained for nine days. The child must be

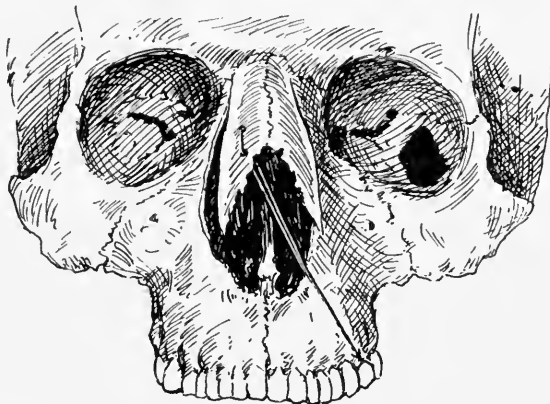


Fig. 184. Correction of deflection of the nose. Diagram showing a displaced nose held in its new position by a silver wire passing from the nasal bone on one side through the septum, nasal cavities, and soft tissues of the cheek, and anchored to a molar tooth of the opposite side.

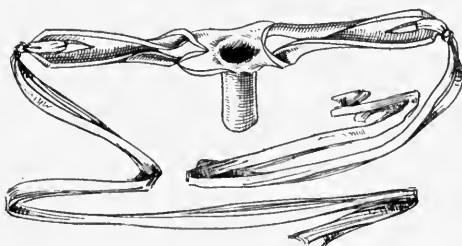


Fig. 185. Breathing tube made of soft one-fourth-inch gum tubing, to be used in case of difficult respiration after operation for harelip. The tube is inserted in the mouth and above the tongue, and the tapes are tied behind the head.

prevented from picking the lip. The infant's sleeves may be pinned to the diaper at the elbow. With older children, a pasteboard tube may be slipped over the arm from the wrist to the axilla; this will prevent the elbow from bending. The child's arms should not be bound to the side with tight wrapping as it interferes with the respiration and the natural voluntary movements. Infants should be given plenty of fresh air, and in good weather their daily outings should be resumed a day or two after operation.

The superficial sutures may be removed on the fifth or sixth day, but the lip should not be turned back to remove the deep stay sutures for ten days or two weeks; the wire in the alveolus may remain much longer. The lead or silver plates are removed after ten days.

### RESULTS.

We have never seen a complete failure of a harelip operation, although they have occasionally been infected. This is more apt to occur where the stay sutures include any part of the skin. The resulting abscesses discharge spontaneously. Gilmer has recently told us of a case in which the lip failed to unite purely on account of inanition, the child's temperature remaining below 95° F. for several days after operation. Slight defects are apt to result after operation, especially when it is done in very early infancy. If the defect is a notch at the lip border, it may be corrected by a Rose operation at the time the palate is repaired.

## CHAPTER XVII.

### OBTURATORS, ARTIFICIAL VELA, AND SPEECH TRAINING.

In order to treat intelligently a cleft of the velum, either by operation or by the construction of an obturator, it is necessary to have at least a general idea of the physiological action of the muscles concerned, both in the normal and in the cleft palate.

#### PHYSIOLOGICAL ACTION OF THE MUSCLE CONCERNED.

The velum is a flap valve which, when raised by the levator palati muscles, helps to completely or partially close the nasal from the oral pharynx in order that the sounds emanating from the larynx may be modified in the mouth by the lips, cheeks, tongue, teeth, etc. (Fig. 186). A very few sounds known as nasals, such as *m*, *n*, and *ng*, do not require the closure of the nasopharynx (Fig. 187).<sup>1</sup>

This closure of the nasopharynx, which also occurs during deglutition, is not accomplished entirely by the velum, but partly by the posterior pharyngeal wall coming forward to meet the velum in the form of a definite protrusion, known as Passavant's cushion, which was first described by Passavant in 1868. This protrusion is due to the contraction of the upper part of the superior constrictor muscle of the pharynx, that part which arises from the pterygoid process, and is called the pterygopharyngeus. Röse has denied that the so-called "Passavant's cushion" is due to the action of the superior constrictor of the pharynx. Dr. Warnikros points out that, "such notable anatomists as Tourtual, Luschka, and Zuckerkandl; such physiologists as Hermann, Landois, and Munk; such singers and laryngologists as Voltolini, Zaifal, Kingsley, Fränkel, Wendt, and Myer have in the past tested Passavant's observation very exhaustively and have recognized it as being thoroughly correct." We have seen cases where the action was very plainly visible. In Fig. 186, Kingsley illustrates the pad helping to close the nasopharynx, while in Fig. 187 the passage is shown to be open. The lower part of the superior constrictor muscle of the pharynx (Fig. 188) also takes part in narrowing the cavity of the oral pharynx. In Fig. 188 by K. Warnikros, *a* shows the outline of this

<sup>1</sup>For a clearly illustrated description of the mechanism of speech, see Kingsley's *Oral Deformities*.

part of the constrictor when at rest, while the dotted line *a* shows the outline of the muscle during contraction. When it is remembered that the palatopharyngei and the palatoglossi muscles lie within the circle of this muscle, it will be understood how it is that the contrac-

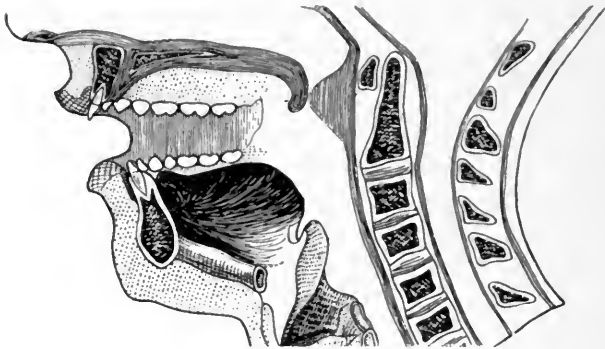


Fig. 186.

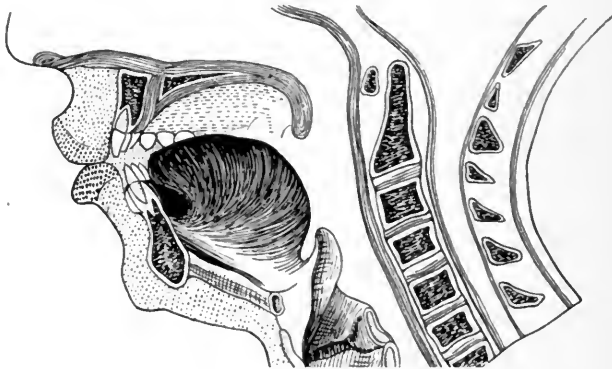


Fig. 187.

Fig. 186. Position of the velum and Pasavant's cushion in making the sounds *ah*. The velum and cushion close the opening also in making the sounds *oo, o, a, e, u, i, b, p, t, d, k, g, f, v, s, z, sh, zh, th, ch, j, l, and r*.—After Kingsley.

Fig. 187. Position of the velum in making the sound *m*. The opening into the nasopharynx also remains open in making the sounds *n, ng*.—After Kingsley.

tion of this part of the superior constrictor can narrow the width of a cleft in the velum during the effort of speaking.

The tensor palati muscles, as their name implies, by their action render the velum tense, but in the presence of a cleft their contraction causes the cleft to become wider. During normal nasal respiration the velum is held against the pharyngeal part of the tongue mainly by the action of the palatoglossi muscles.



## OBTURATORS AND ARTIFICIAL VELA.

From this meager description it must be clear that operations for the correction of velum clefts must aim at producing a velum that is long enough to do its share in closing the nasopharynx; that in doing this the velum must be left sufficiently pliable to move freely in response to its various muscles; and that these muscles must not be crippled or their nerve supply cut. It can also be understood how an inadequate velum can be supplemented by an obturator that closes the




Fig. 188.

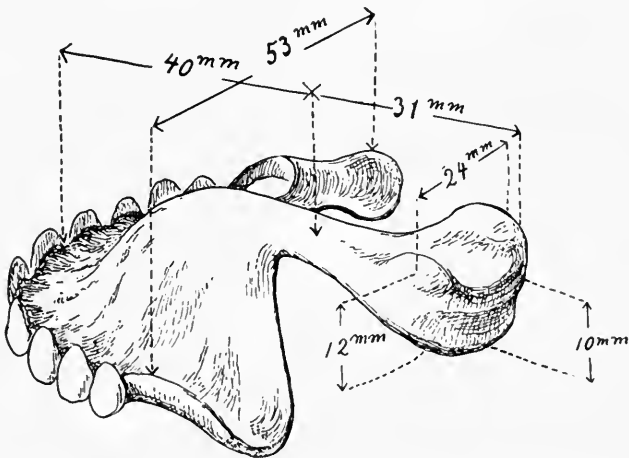


Fig. 189.

Fig. 188. Diagram illustrating the contraction of the superior pharyngeal constrictor in the formation of Passavant's cushion.—After Warnikros.

Fig. 189. Obturator for a cleft palate.—After Warnikros.

cleft and partially fills the space behind a short velum. For such an artificial velum or obturator to be effective, it is not necessary that it fill the entire passage between the nasal and the oral pharynx. It must occlude the space that is still left when the contraction of the superior constrictor muscles forms Passavant's cushion and constricts the transverse diameter of the pharynx and approximates the borders of the velum cleft.

Fig. 189 shows an obturator constructed by Warnikros for a patient with a cleft. Such obturators are usually made of vulcanite,

but the part filling the velum may be of flexible rubber. Once partially occlude the nasopharynx, and the diligent patient, by efforts at correct speech, will develop the actions of the muscles to the extent that later a smaller obturator is sufficient. Fig. 190 shows the obturator that was worn by this same patient subsequently.

Fig. 191, also from Warnikros, shows an obturator constructed to compensate for a short velum after operation. If there are teeth present, such obturators may be constructed to also occlude a cleft in the hard palate, but if all the teeth are absent, the presence of an anterior

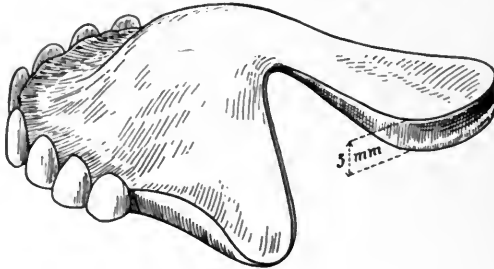


Fig. 190.

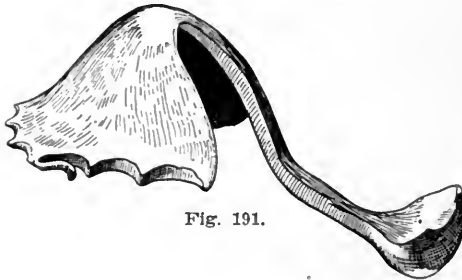


Fig. 191.

Fig. 190. Obturator that replaced the obturator shown in the preceding figure after the palate and pharyngeal muscles had been trained.—After Warnikros.

Fig. 191. Obturator made to supplement a short velum.—After Warnikros.

cleft renders the problem much more difficult. It has been our observation that under these circumstances obturators are of little benefit.

### “CLEFT PALATE” SPEECH.

When a person has learned to speak with a cleft in the velum, even after the most perfect operation, there will remain the stigma of the “cleft palate” speech, which is due to the escape of air through the nasopharynx during the effort at producing sounds that require its closure. This is due to two causes: The cleft velum is shorter than the normal velum, and this defect is rarely remedied by operation;

further, the patient who has learned to speak with a cleft velum must be re-educated to the proper use of the newly constructed one. In some cases in the presence of a cleft, by diligent effort, the patient will develop the use of the superior constrictor muscle to an ultra normal degree. Such persons will give the best postoperative results, both on account of the muscular control that has been acquired and because the same determination that produced this control will be helpful in mastering the use of the new palate. This also applies to obturators.

Older children who have cleft palates are often found to be backward mentally, simply because they are ashamed to ask questions on account of the difficulty of speech, and because they have not the same incentive to study as children who are corrected and chided for their mistakes in recitations on account of their teachers not being able to understand them. Several schemes of postoperative speech training have been devised, among which is the teaching of a foreign language that has not been previously attempted by the pupil. A simple and rather effective plan, devised by Bigelow, is given below, and is the one we employ.

### SPEECH TRAINING.

Begin with the only consonant which a patient can usually best articulate, namely *t* in *tar*, and gradually lead to the rest, constantly referring to the acquired *t* as a point of departure. The great difficulty in pronouncing correctly with a cleft palate is in distinguishing the nasals from the mutes: thus *p-b* from *m*; *paɸ* or *bab* from *mam*; *t-d* from *n*; *tat* from *nan*; *k-g* (hard) from *ng*. *Tar* is well pronounced by most beginners with an obturator. When the beginner can pronounce *stark* and *car*, he has the key to most of what here follows. The above words should be practiced carefully and should be spoken loudly, or, as the elocutionists say, "exploded."

1. *tar artar kar arkgar kar*
2. *kar arkar arkgar kgar gar*
3. *kar arkar arkdar kdar dar*
4. *kar arkar arkpar kpar par*
5. *kar arkar arkbar kbar bar*
6. *kar arkar arklar klar lar*
7. *kar arkar arksar ksar sar*

Practice all the above with the following vowels:

8. *o* as in *coke*.

Thus, instead of *kar*, *akar*, *ko-oko-oklo-klo-lo*.

9. *a* long as in *cake*.
10. *i* as in *kite*.
11. *e* as in *keep*.
12. *u* as in *suit*.

13. *kar arkar arngar arkar arngar kar ngar bar mar*

14. *tar artar arnar artar arnar tar nar dar mar*

15. *par arpar armar arpar armar par mar sar rar*

Practice reading loudly from a book.

A patient, painstaking teacher and a docile, earnest pupil are two factors that go a long way toward success. If, after a thorough trial of this training, a good enunciation is not acquired, the surgeon may recommend an auxiliary obturator (Fig. 190).<sup>2</sup>

### POSTPHARYNGEAL INJECTION OF PARAFFIN.

This has been used to supplement a short velum. Warnikros objects to this for fear that it would interfere with the action of the superior constrictor muscle, while from observation of results of paraffin injections that have come to our notice, we have refrained from using them.

### OBTURATORS VERSUS OPERATION.

The once rather spirited dispute between those who favored the use of obturators versus those who favored operative treatment of clefts is all but settled in favor of the latter. If any further argument were needed against the routine treatment by means of obturators, it could be found in the fact that Gutzmann, with his exceptional opportunities of observation on this point, has come to the conclusion that the operative results are the best.

Only in exceptional cases is the subject of operative risk to be taken into consideration in making a choice, although there is a certain risk in any operation, and the death rate from cleft palate operation per se is almost nil; and an open palate must more or less predispose to infections of the respiratory tract and middle ear. It is to be hoped that the knowledge of the immense advantage of the early operation will soon become so disseminated that before many years a child or an adult with an unoperated cleft will be as rare as are cases of large ovarian cysts today.

<sup>2</sup>We frequently recommend that these patients attend classes in a deaf-and-dumb school, or obtain the services of a teacher from such a school.

## CHAPTER XVIII.

### REPAIR OF ACQUIRED DEFECTS IN THE LIPS, CHEEKS, AND PALATE.

Defects in the soft tissues of the face and mouth are repaired by the sliding, or transplantation, of flaps of mucus- or skin-covered tissue, which are grafted into a new position. These flaps may be made from neighboring tissue, from tissue transplanted from some distant site, or even with tissue obtained from some other person. The latter procedure is almost entirely confined to the transplantation of pieces of skin or of the superficial layers of the skin.

#### TRANSPLANTATION OF SKIN- OR MUCUS- COVERED FLAPS.

The surgical possibility of transplanting skin- or mucus-bearing flaps for the correction of tissue defects depends upon the following facts:

The skin and superficial fascia are redundant and elastic. The nutrition of a flap can be maintained through a relatively small pedicle, if it is accompanied by a layer of the subcutaneous fascia, and especially if this pedicle contains a distinct artery and vein. A flap of skin from which all subcutaneous tissue is removed, and which is not connected by a pedicle, is known as a Wolff graft. Its life is much less certain than that of a flap that retains a blood supply, but it has this advantage: that it can be obtained from a distant site, such as the thigh. Grafts made of thin shavings from the epidermis are used to cover raw surfaces from which the skin is missing. These are known as Thiersch grafts. After a flap has united in a new position and a new blood supply is obtained, the pedicle can be cut without injury to its nutrition. Skin transplanted into the mouth is a practical substitute for mucous membrane.

As concerns the mechanical repair, it matters little whether a defect is the result of the excision of a scar or tumor. In the following an attempt will be made to present the simplest effective methods of repairing the various defects that may occur from disease, accident, or surgical operation about the lips, cheeks, and neck.

Flaps should be made ample in size. When possible, they should be so planned that they may be enlarged should it be found necessary. While it is certainly true that face flaps will stand a great amount of tension without sloughing, it is equally true that the result is better,

as regards both the comfort and appearance, when the tissues are not overstretched. The blood supply of the face tissues is particularly good, but nutrition should always be considered in planning flaps.

**Preparation of the Margins of the Defect.**—One of the first essentials in the repair of the face or neck lesions is the removal of all of the original diseased tissue, and except in extraordinary cases, this refers also to scar tissue. If this defect is the result of syphilis, the patient should be thoroughly treated before an operation is undertaken. It was an old rule that operative correction of defects or postsyphilitic lesions should not be attempted until months after all active manifestations had disappeared. Whether the use of salvarsan will safely permit of earlier operating remains to be determined. We have operated successfully a short while after treatment with salvarsan, but we have seen cases of tertiary syphilis that were not cured by this treatment. Before an operation is undertaken on a syphilitic, the patient should give a negative Wassermann reaction.

These are in many cases elective operations, and such should be performed only when the general condition of the patient is the best possible.

**Preservation of the Epithelial Lining of the Mouth.**—In repairing defects of the lips and cheeks, the oral as well as the external aspect is to be considered, for, if an extensive raw surface is left within the vestibule, subsequent contraction will modify the result.

**Preservation of the Motor Nerves.**—When flaps are liberated by deep incisions, some nerves will be sacrificed, but the motor supply of the orbicularis palpebrarum muscle should not be endangered. If the external incision does not extend behind a line running from the lobe of the ear to the middle of the lower border of the orbit, the ability to close the eye will not be menaced (Fig. 192). When there has been an extensive reconstruction, the nerve supply of the buccinator, orbicularis oris, etc., of that side is relatively not so important, for the newly made cheek and lip remain stiff with scar tissue and will not be drawn aside by the opposite buccinator as in Bell's palsy. The nerve supply of the upper part of the orbicularis oris and the muscles that raise the lips and control the nostrils runs deep to the zygomatic and levator anguli oris muscles, so that a superficial flap can be raised from the area between the orbit and mouth without cutting the motor supply of these muscles. In sliding flaps made from the face tissues, the most important thing is free undermining. When done in the proper plane, this cuts no motor nerves and few vessels, and leaves no visible scar. External incisions for releasing face flaps should be made only when undermining by itself will not suffice. For cutaneous flaps the undermining should be done super-

ficially to the muscles of expression. On the side of the face the masseter, the temporal fascia, or the zygoma should not be laid bare, for, after leaving the parotid gland, the nerves lie in contact with these structures.

**Cheek Flaps.**—The first procedure in freeing a flap which includes the full thickness of the cheek is to cut the mucuous membrane and buccinator from the bone. Posteriorly they are to be cut along the inner surface of the anterior border of the masseter muscle, which will not cut the motor supply of the buccinator. In raising the flap from the masseter muscle, it is to be remembered that the parotid duct and

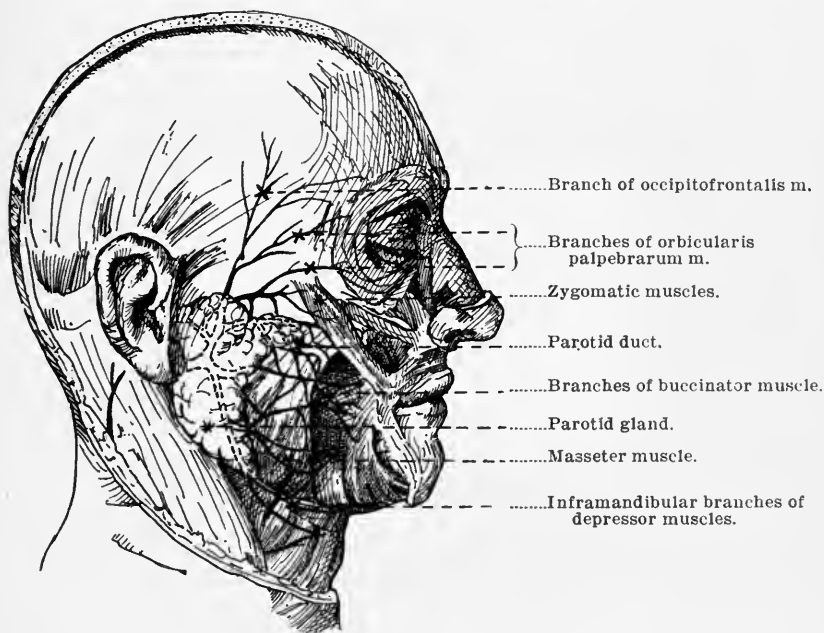


Fig. 192. The facial branches of the seventh nerve and of the parotid duct.

motor nerves lie in immediate contact with its external surface and should be either lifted from the muscle or left in place, as the case may be, without being cut.

**Flaps from the Neck.**—In obtaining long flaps from the neck, the platysma myoides muscle should be included. The jugular vein, the cutaneous branches of the superficial cervical nerve plexus, and the sternomastoid muscle lie just beneath the platysma muscle and are to be used as guides, as in children and delicate women the fibers of the muscle may not be visible. If the neck defect is to be closed by drawing over the neighboring skin, these sensory nerves are to be left in place, but if the space is to be covered with Thiersch grafts, the

exposed nerve had best be removed. In a well-nourished adult a flap 5 centimeters wide, with its base at the lower jaw, can be made to include the tissue down to 6 centimeters below the clavicle. After undermining the platysma on both sides of the defect, unless there is too much fat, the remaining skin can be brought together with sutures so as to leave only a linear scar (Fig. 159). The scar may be thick and corded, but later, after the tissues have become adjusted, it may be excised, leaving only a smooth line scar. It is usually well to make a counter-opening on each side at the bottom of the undermining pocket, which will serve for relaxation and drainage. If it is found difficult to approximate the edges of the defect, these drainage wounds may be extended by linear incisions parallel to the line of suturing. As these wounds gap, the tension will be released; they will later close without suturing. If the lower end of the flap appears

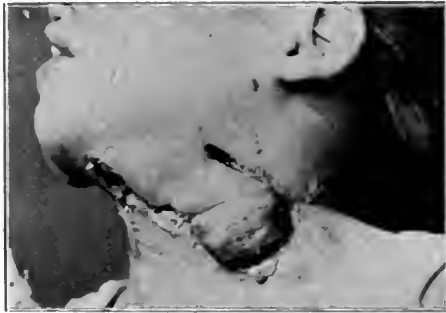

Fig. 193. Neck flap, circulation of which was doubtful, sutured in place. Two days after making the flap, it shows a slough at its lower end.

turgid, its skin surface should be lightly scored with a sharp knife with cuts, 2 millimeters apart, which produce free bleeding. As a rule a flap sloughs, not from want of arterial supply, but from tardiness in the establishment of a venous return. After scoring the flap as described, the turgescence may disappear. If still in doubt as to its vitality, the flap may be sutured back in place for two days, when the question will have been settled with all certainty (Fig. 193). If the flap is of such size that the resulting defect cannot be obliterated by suturing its borders, or by sliding other flaps from the neighborhood, then the raw surface should be immediately grafted according to the method of Thiersch.

A plan we have used consists in raising the flap, controlling the bleeding by twisting the vessels, and then covering the raw surface with Thiersch grafts. The grafted area is covered with several thicknesses of silver leaf and then with two thicknesses of gauze, wet with



a 10 per cent colloidal silver solution. Next, the flap is sutured by its edges to the edges of the defect, and two days later the flap is freed and transferred to the desired position. The rationale of this procedure is that the silver leaf and colloidal silver are antiseptic and non-irritating. The silver leaf prevents the gauze from sticking and displacing the grafts, and the gauze prevents the under surface of the flap from becoming coated with silver. Leaving the flap in its old position should assure its vitality before it is transferred, and suturing it there prevents it from shrinking and makes it an excellent mechanical protection to the grafts in a region where it is ordinarily difficult to prevent friction of the dressings from displacing them.

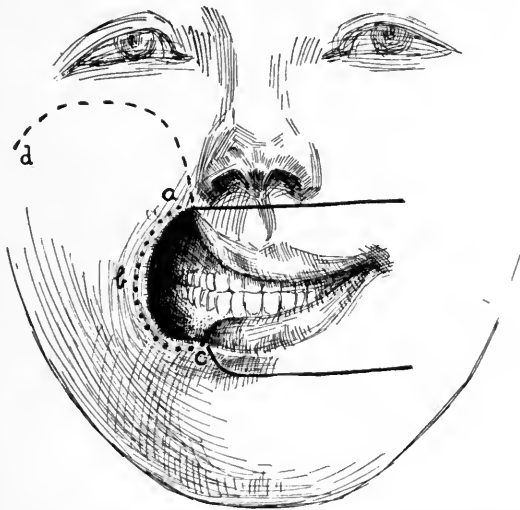


Fig. 194. Scheme for incision for obliterating a defect at the corner of the mouth.

**Flaps from the Shoulder and Chest.**—In turning very large flaps from the shoulders, chest, or back for the repair of the neck and lower part of the face after extensive burns, the desired flap may be outlined, and freed by beginning the dissection at its lower end. If at any time during the dissection the circulation in the freed parts seems deficient, it is better to graft the defect and replace the flap as described above, and wait two days before completing the flap and putting it into its new place. The sloughing of a large flap is such a serious disappointment to both the surgeon and the patient that no unnecessary hazard should be taken. The flaps should be transferred to their new position within two days of being raised; otherwise contraction will greatly lessen the size of the flap.

**Blood Supply of a Transplanted Flap.**—Before cutting the base of a transplanted flap, it should be gently pinched with forceps, and

at the same time its color observed. In this way the surgeon can satisfy himself that the circulation through its new attachment is sufficient. Transplanted flaps should be sutured with through-and-through interrupted sutures of fine silkworm gut or silver wire, and especially in the case of long flaps, the sutures should be drawn but very loosely. The circulation in these new flaps is poor at best, and tight sutures may be the determining cause of sloughing along the line where union was expected.

#### AFTER-TREATMENT.

After operation on the face, if possible, for the first few days the patient should be kept in a position that will allow the saliva to

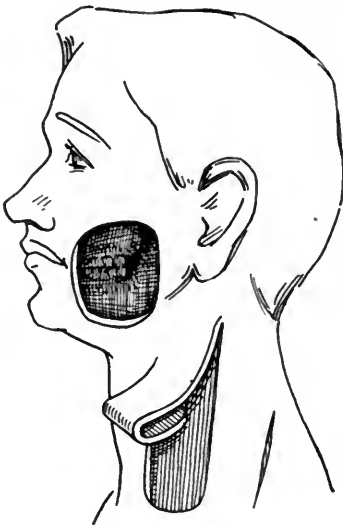


Fig. 195.

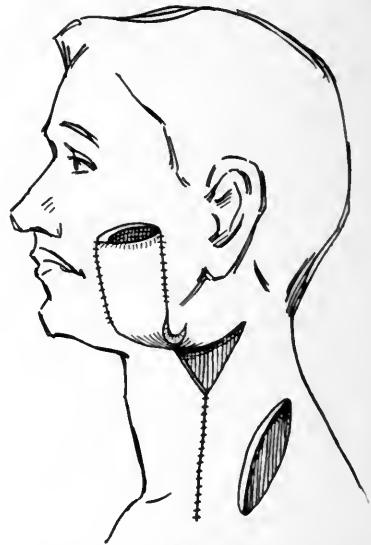


Fig. 196.

Fig. 195. Diagram of a cheek defect and a flap from the neck. The lower end of the neck flap has been doubled on itself so as to be covered with skin on both surfaces.

Fig. 196. Shows second step in closing cheek defect. The part of the flap that was shown doubled upon itself in the preceding figure has been sutured by its free borders, both to the mucous membrane and to the skin. Nothing further can be done until the flap obtains sufficient nourishment from its new attachment.

drain away from the wounds, and no external dressing is to be applied to face wounds. In summer any exposed space under a pedicle should be carefully packed with gauze. It is difficult to keep light summer dressings in absolute contact with the under surface of the chin, and it would be embarrassing to find neck spaces fly-blown.

#### CLOSURE OF DEFECTS AT THE ANGLE OF THE MOUTH AND OF THE CHEEK.

If the defect is bordered by scar, this is to be excised. To obtain the flaps, the mucous membrane and buccinator muscle are to be de-

tached from the bone at the upper and lower fornices, and the cheek undermined up to the opening of the infraorbital canal and down to the lower border of the mandible. If after this the cheek defect cannot be closed by suturing the outer part of the edge (a-b) to (b-c), the incision (a-d) may be made in the cheek (Fig. 194). After the cheek defect is obliterated, the lips with their mucuous lining may be drawn into proper place by making one or both of the transverse incisions illustrated. Particular care should be taken in locating the corner of the mouth. If the incisions along the upper and lower lip extend beyond the mouth slit on the unaffected side, that corner of the mouth will be drawn toward the median line, and the new angle

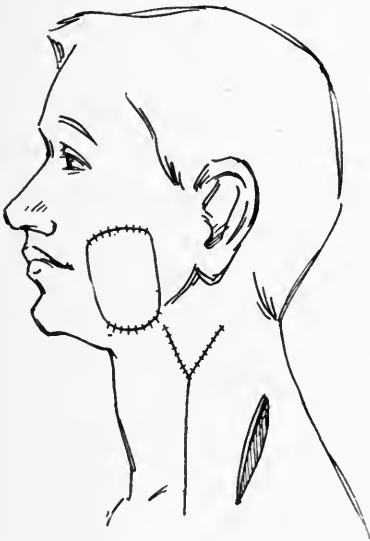

Fig. 197.

Fig. 197. Final stage in closing a cheek defect by a neck flap. Having determined by pinching the pedicle that the flap is obtaining sufficient nourishment from its new attachment, the pedicle is cut close to cheek attachment. The upper and lower borders of the cheek wound are freshened, as in the upper border of the flap where it was bent on itself. These are sutured. The triangular defect in the upper part of the neck is freshened, and the pedicle of the flap is fitted into it.



Fig. 198.

Fig. 198. The Serre operation for restoring the angle of the mouth after it has been depressed by a scar.

of the other side will have to be adjusted accordingly. In this way, when much of the lip is missing, a smaller symmetrically placed mouth slit will result. Without the incision (a-d), this operation will cut only the mental branch of the inferior dental, and possibly the infra-orbital, nerve. If there is not sufficient mucous lining to the new cheek to insure of subsequent free opening of the mouth, a lining of skin is to be made by transplanting a flap from the neck. This is done in about the same way as a flap is obtained from the neck for repairing a palate defect, but the flap is sutured to the raw area on

the inner surface of the cheek (Fig. 91). In any case, external drainage through a stab wound at the lower border of the jaw is desirable.

For more extensive defects of the cheek, Israel proposed using a flap turned from the neck, the non-hairy part of which is sutured into the defect around three sides of its border, with the skin surface toward the mouth. Some time later, when the flap is well nourished from

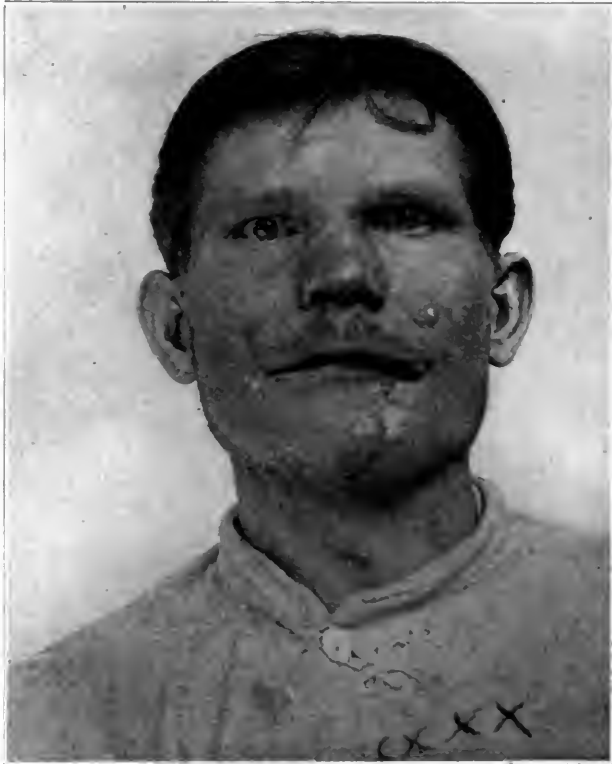

Fig. 199. Showing result of the Burow-Stewart operation for restoration of the lip and chin.

its new attachment, the flap is cut at its base, and the pedicle of the flap is turned into the defect, skin side toward the face. Another ten days or two weeks would have to pass, before the continuity of the two halves can be cut and final repair made. We have never tried this for the reason that in two or three weeks the raw surface of the pedicle would contract and would be difficult to manage. If the cheek could not be closed by simply undermining down into the neck, we would prefer to do the operation shown in Figs. 195, 196, 197. This

can be completed in two steps and does not use a raw surface that has been contracting for a week or more, as does Israel in his operation.

Some have closed a defect in the cheek by splitting the border of the tongue and suturing the raw surface into the defect. Later the remaining part of the tongue is cut loose. This is applicable only in young, healthy subjects, for any anchoring of the tongue may predispose to pneumonia.

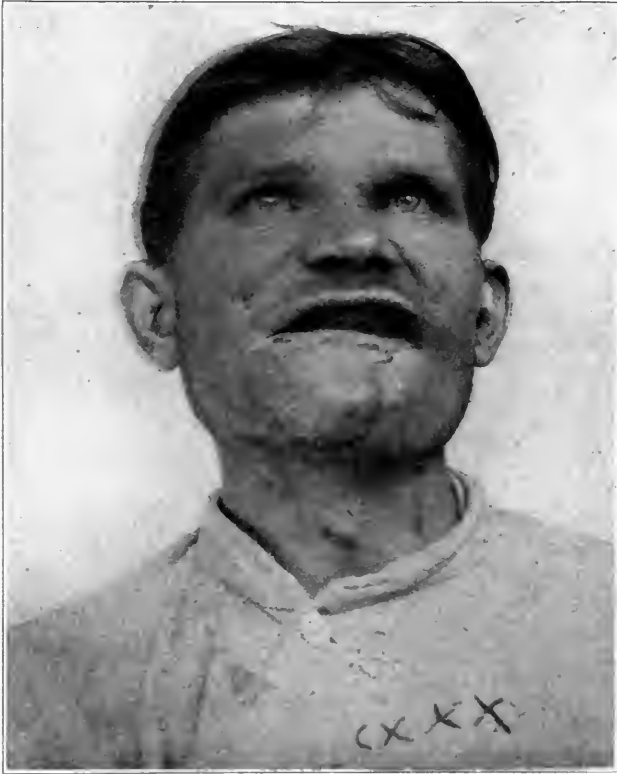

Fig. 200. Showing ability to elevate the upper lip after the Burow-Stewart operation.

If the corner of the mouth is drawn down (Fig. 198), it can be restored to a good position by an operation that bears the name of Serre.

The two incisions around the mouth are made so that the distorted portion of the lips can be freed and laid on the cheek in the desired position. This will give an index to the position and length of the incision in the cheek. The flap (a) is then drawn down to occupy the place from which the corner of the mouth was removed, and the latter is sutured into the defect left in the cheek.

## RESTORATION OF THE LOWER LIP.

The upper lip or the lower lip and chin can be restored with mucous lining by the operation described by J. Clark Stewart. According to Esmarch and Kowalzig, the idea of removing a triangular flap from the cheek belongs to Burow, and in presenting it Esmarch and Kowal-

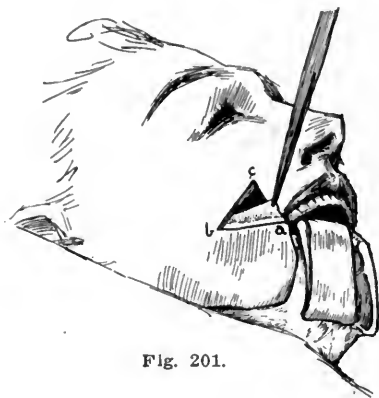


Fig. 201.



Fig. 202.

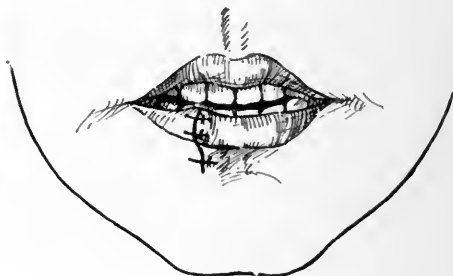

Fig. 203.

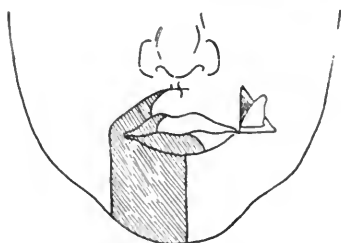


Fig. 204.



Fig. 205.

Fig. 201. The Burow-Stewart operation for restoring the lower lip.

Fig. 202. Showing V-shaped excision. The lines of the excision are concave, which causes a protrusion rather than a notch at the site of excision when the borders are approximated.

Fig. 203. Showing restoration after V-shaped excision.

Fig. 204. Showing possible defect after excision about corner of mouth and chin.

Fig. 205. Restoration after excision shown in the preceding figure.

zig suggest the advantageous possibility of using the mucous lining of the discarded areas as covering for the free border of the new lip (Figs. 199, 200, 201).

The whole, or nearly all, of the lower lip and the covering of the chin having been removed, the cheek is freed from its attachment

by an incision along the lower border of the bone. In a carcinoma operation this incision would have probably been made already in getting at the glands in the neck. Next, an incision (a-b) (Fig. 201) is outlined with the point of the knife, its length corresponding to less than half of the width of the gap in the lip. If less than three fifths

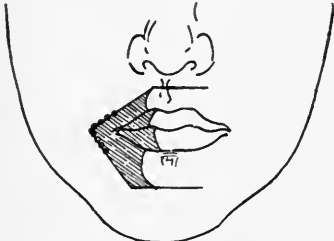

Fig. 206.

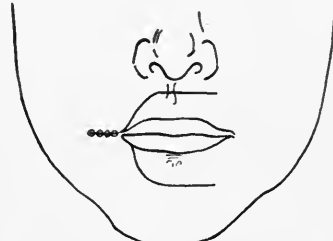

Fig. 207.

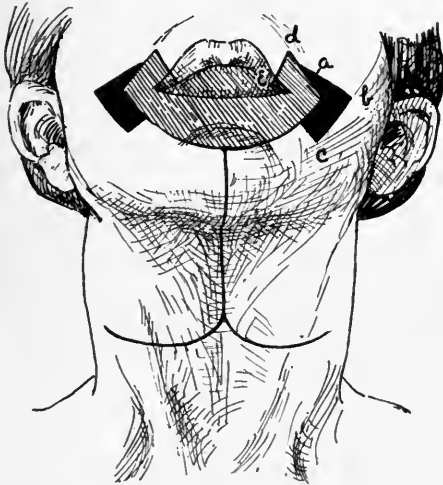


Fig. 208.

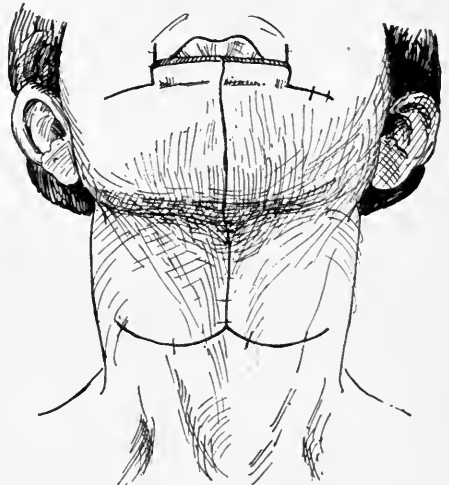


Fig. 209.

Fig. 206. Showing possible excision of corner of mouth.

Fig. 207. Restoration after excision shown in preceding figure.

Fig. 208. Showing excision about lower lip and chin, with median incision in the neck that would expose the submental and submaxillary lymph nodes. The neck flaps are undermined, and the buccinator and mucosa are freed along the lower fornix. (da) is united to (de), and (ab) is united to (bc).

Fig. 209. Showing restoration after the excision shown in the preceding figure. This leaves the lower lip redundant, but as it is not lined with mucous membrane, it will contract.

of the lip has been removed, the plastic operation need be done only on the same side, in which case the incision in the cheek would be made less than the width of the lip defect. The incisions (a-c and c-b) are made through the full thickness of the cheek, the point (c) being at the level of the ala of the nose. From the triangular flap (a-b-c) the skin and muscles are removed, leaving only the mucous

membrane and its submucous tissue attached at the base (a-b). This flap of mucous membrane is to be the covering of the free border of the new lip. It now remains to free the cheek so that the lip flap can be brought to the median line. This may require incising the mucous membrane and buccinator muscle along the full length of the upper fornix and along the inner surface of the masseter muscle, and also some undermining of the cheek. The operation is done on both sides if more than three fifths of the lip is excised. The borders of the cuts (a-c and c-b) are sutured, the new lip is sutured in the median line, and the mucous covering of its free border adjusted. Drainage should be provided on each side at the lower border of the flap. With a V-shaped excision of a small part of the lip this procedure is not necessary (Figs. 202, 203). Except for very early and

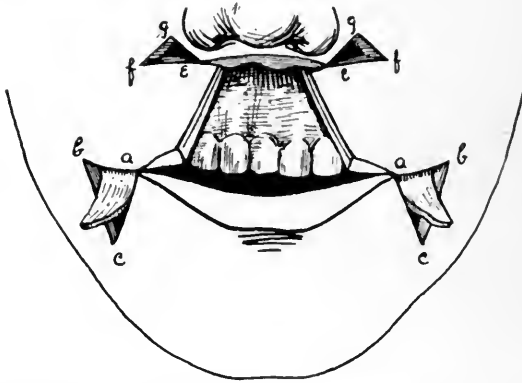


Fig. 210. Restoration of the upper lip. The triangles (*e f g*) are excised to the bone, (*e f*) being half the distance from (*e*) to (*e*). In excising the triangles (*a b c*), the mucous membrane and submucous tissue is left attached to the new flap at (*a b*). (*a b*) on each side is to be half the width of the lip defect. After undermining the tissues (see Restoration of Lower Lip), the raw edges (*a e*) and (*a e*) are sutured in the midline, the now linear cuts above and below are closed, and the mucous flaps adjusted to the free border of the new lip.

very inactive carcinomata, the V-shaped excision is not a commendable procedure. Figs. 204-209 show other plans of restoration of the lips and contiguous structures.

### RESTORATION OF THE UPPER LIP.

The upper lip can be reconstructed by the plan shown in Fig. 210.

### PERFORATIONS OF THE PALATE.

These are nearly always syphilitic and may vary from linear defects, surrounded by absolutely normal tissue, to loss of most of the palate processes and all of their mucous coverings.

Small defects in the palate, up to the size of the end of a finger, are easily closed by making a lateral incision down to the bone on each



side as close to the teeth as is possible without exposing the necks. The mucoperiosteal covering is raised, as in making flaps for repairing a congenital cleft. The edges of the defect are freshened and sutured together (Figs. 211, 212). If the palatine arteries are uninjured and have been raised with the flap, the lateral incisions may be made to approach each other very closely in front. These perforations extend into the nose; the nasal discharge may be prevented from accumulating above the palate flap, and drainage is assured by passing a piece of rubber dam from the mouth through the lateral incision between the flap and the bone on each side.

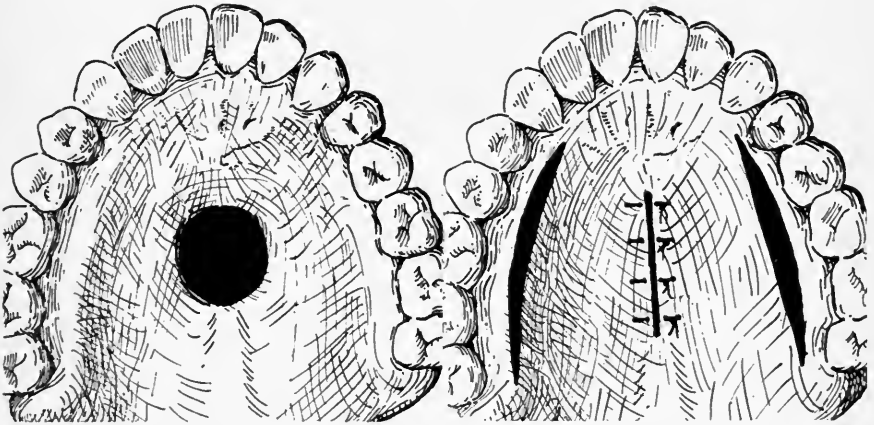


Fig. 211.

Fig. 212.

Fig. 211. Diagram of defect in hard palate.

Fig. 212. Restoration of defect shown in preceding figure, showing relative extent of the lateral incisions.

For more extensive perforations some plan of flap transplantation will have to be adopted (Chapter XI).

It has been recommended to treat small perforations by freshening the edges with the actual cautery and allowing the hole to close by granulations and scar contraction. For holes up to the size of a pea in the velum, this will be effective, but we have never had much success with it in the hard palate, even with the smallest openings.

The variations in the procedures that may be resorted to for repair of defects is almost unlimited, but the preceding gives an outline that will suggest certain possibilities.

## CHAPTER XIX.

### IDEAL OCCLUSION AND MALOCCLUSION OF THE TEETH—IRREGULARITIES IN THE GROWTH AND RELATION OF THE JAWS.

The relation of the upper and lower dental arches to each other, as well as the positions of the individual teeth in each arch, influence and are influenced by the size, shape, and positions of the jaws. It is for this reason that occlusion and malocclusion must be considered together with deformities and malrelations of the jaws (Fig 213).

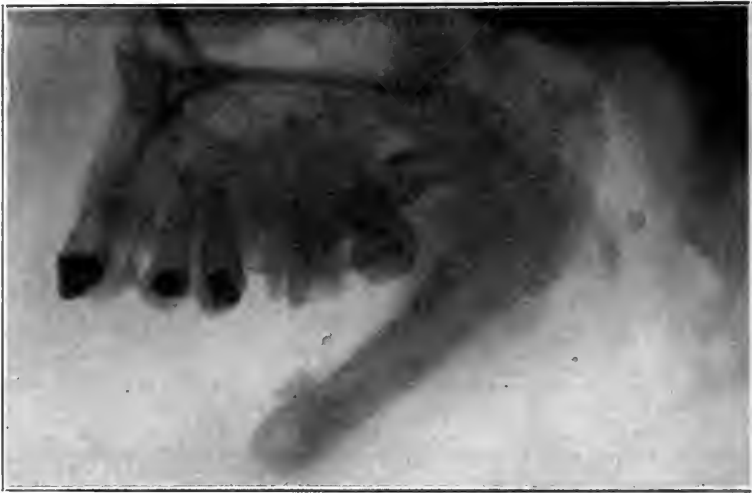

Fig. 213. X-ray showing a very much undeveloped jaw of a young woman, twenty-two years old, who at the age of three years lost the teeth and a portion of the upper border of the body from necrosis, evidently all of the germs of the permanent teeth except those of the third molars. The latter teeth are seen to be the only ones that have developed. The body of the jaw has developed but little since it suffered the injury. The lower third molar can be seen growing apparently from the ramus. This case was referred to us by Dr. L. S. Chaudet. The offer to attempt to graft a rib in the lower jaw to allow her to use artificial teeth was refused.

### IDEAL OCCLUSION.

What has come to be considered the ideal occlusion is a condition in which the crowns of the upper incisor teeth slightly overlap the lower; in which the individual lower teeth are partly in advance of the corresponding teeth of the upper jaw; and in which the crowns of the lower molars are slightly nearer the mesial plane than are their fellows above, so that the lingual cusps of the upper teeth fit between

the buccal and lingual cusps of the lower (Fig. 214). The individual lower teeth are closer to the symphysis than the upper, because the crowns of the lower central incisors are narrower than the corresponding upper. As a result of this, the lower cuspid and bicuspid and cusps of the molars are each just in advance of its fellow above. In spite of the greater width of the lower jaw, the lingual cusps of the lower molars occlude to the inner side of the upper, by reason of the obliquity at which the lower molars are set (Fig. 8).

### MALOCCCLUSION.

The term malocclusion is commonly used in reference to the permanent dentition only. It may indicate any irregularity in the alignment of the teeth in either or both jaws, or an irregularity in the relation of

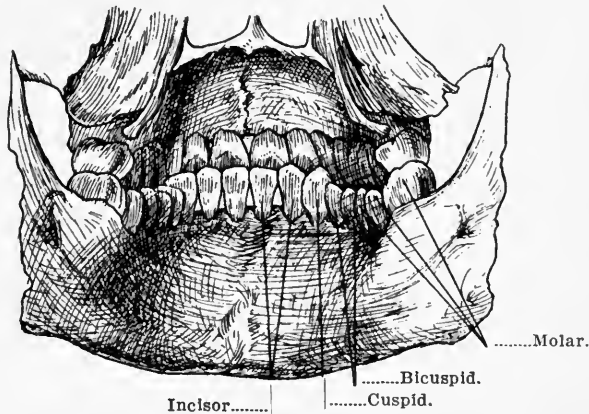


Fig. 214. Occlusion of the teeth viewed from behind. It will be observed that the lingual cusps of the lower molar occlude slightly mesial to the lingual cusps of the upper, and that the incisor occlude behind the corresponding upper teeth.

the teeth in one jaw to those in apposition. The latter condition may be due to a disproportion in the jaw-bones, and it is not necessarily accompanied by any irregularity in the alignment of the teeth. It is a subject of primary interest to the orthodontist, but to the surgeon only in so far as the irregularity is an indication or a cause of bony deformity not confined to the alveolar processes. All malocclusions should receive consideration, and their prevention is of greater importance.

### CAUSES OF IRREGULAR SETTING OF THE TEETH.

Among the many causes to which irregular setting has been ascribed, some are rather difficult of proof and hardly within our direct control. But there are three that are quite tangible, and some one of these is, no doubt, responsible for almost all of the cases. These are: (1) Abnormal pressure on the erupted crowns, such as continued

thumb-sucking, tongue-sucking, lip-biting, scar-contraction, etc. (2) The withdrawal of normal counter-pressure—the most common instance of this is mouth-breathing—where the pressure of the cheeks upon the outer surface of the upper teeth is not counterbalanced by the tongue, as it is when the mouth is closed. (3) The premature removal of the deciduous and permanent teeth, by deranging the natural spacing, is responsible for many irregularities in the setting of the second set of teeth (Fig. 215). Irregular dentition is another cause, but it is one over which we have little control. The bearing of atavism will be considered in the next paragraph.

### MALRELATION OF THE DENTAL ARCHES AND OF THE JAWS.

Moderate irregularity of the erupting teeth in front of the permanent molars is usually spontaneously corrected. But malrelations be-

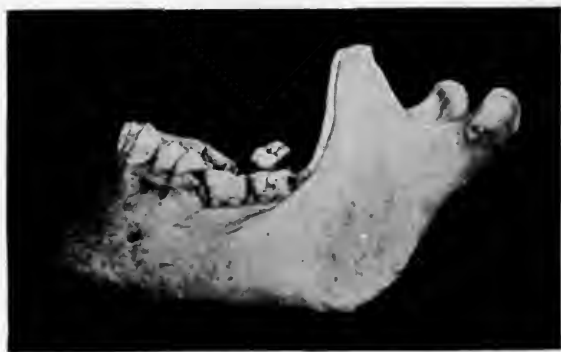

Fig. 215. Showing deformity of the jaw due to early extraction of the first permanent molar tooth.

tween the upper and lower first permanent molars, if untreated, are often followed by increasing malrelation of the jaws themselves. In some cases the malrelation of the teeth is primary deformity, but we believe it may be, for a time, simply the first noticeable indication of disproportion in the bony arches. It is only later that the lack of proper intermeshing of the teeth becomes a factor in the continuously increasing deformity. We believe that atavism may be the primary factor in some cases. When the world was younger and the nations did not mix, very distinct facial types were developed and preserved. In the higher of these types the lower part of the face was proportionately small and protruded but little (Fig. 216). In others, less removed from the animal type, the jaws were the predominant features (Fig. 217). The present generation of white Americans is essentially a mixed race, and if we will grant that we can inherit different features from different

ancestors, we think it must almost be granted that we can have jaws that are disproportionate in size. For instance, this is the only explanation that we can offer for the condition sometimes found in which the lower jaw is so large that the molar teeth have not been crowded forward into part of the space that was originally occupied by the deciduous molars, and permanent interdental spaces remain in the bicuspid regions (Fig. 218). We know of no growth in the length of the bone that can occur at this site. The skull illustrated in Fig. 219 shows what is possibly an atavistic retraction.

Disease or trauma may also be the factor that determines the overdevelopment or underdevelopment of either jaw. If from any cause there is a nasal obstruction which causes mouth-breathing, the upper molar teeth are deprived of the support of the tongue and the lower



Fig. 216.

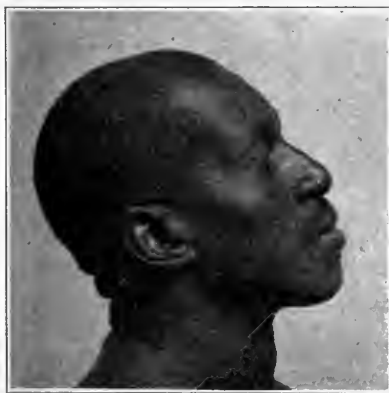

Fig. 217.

Fig. 216. Greek profile.—After Farrar. Here we have a high forehead, continuous with a long, straight nose, a short upper lip, somewhat retreating, and a full curved chin.

Fig. 217. Negro head showing prominence of the lower part of the face.

molars. In children this allows the cheeks to press the teeth, alveolar processes, and maxillary bodies inward. As the upper jaw narrows, the height of the palate arch increases, the septum buckles, and the width of the nasal fossæ is lessened. The original trouble might have been lack of development of the maxillæ, adenoids, bony occlusion of the posterior nares, or any other obstruction. But no matter what, the resulting mouth-breathing tends to still further lessen the size of the nasal passages.

The normal adult relation of the dental arches is not obtained until the bones are full-grown and the jaws are separated by a complete quota of teeth. An exception may possibly be made of the third molars. The development of the face as a whole has an essential bearing on this relationship. For, as the maxillæ grow downward, it changes

the plane of the hard palate from above the temporomaxillary joint, as found in infancy, to a considerably lower level, best shown in an edentulous skull of age. The body of the mandible is carried to a still lower level by the interposition of the teeth and alveolar processes. The ramus of the lower jaw is formed to compensate for this change in position of the body. Until the ramus appears, there can be no real angle. Non-traumatic malrelations of the dental arches, or a portion of them, are as a rule early determined, and if not controlled, they increase with growth. As before mentioned, the teeth, properly apposed to each other in normal succession with concurrent growth of the bone,

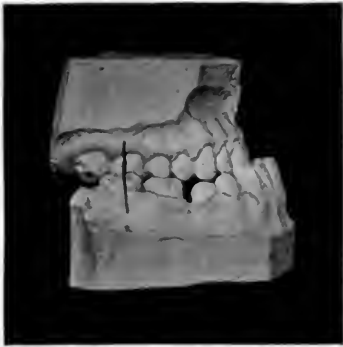

Fig. 218.

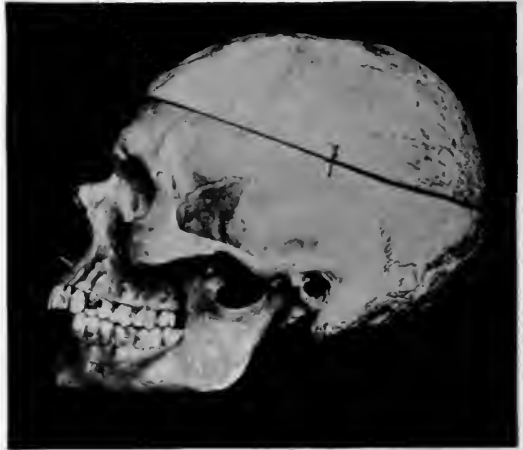


Fig. 219.

Fig. 218. Protrusion of the lower jaw, due partly to interdental spaces in the bicuspid region. Part of the protrusion is due to a sliding forward of the body as a whole, as shown by the relation of the upper and lower molars.

Fig. 219. Retraction of the lower jaw. Note that the deformity is due mostly to a shortening in the ramus, which is usually the case. In this skull, however, all of the vertical diameters—the height of the forehead, the height of the orbit, and the height of the ramus—are short in comparison with the transverse diameters, and the maxilla is prognathic. Yet, when considered alone, the prominence of the nasal bones and the shape of the cranium would place the skull very high in the scale of development. This we take to be a plain instance of atavism, and the malocclusion an accident dependent upon this atavism.

are the factors that establish the normal jaw. It is to faulty succession or position of the teeth and irregularities of bony development that most of these deformities of the bone are due. Atavism, trauma, or disease is the determining factor.

As in certain cases an abnormal angle is both a contributing cause and a result, a study of this angle and the factors which control it is opportune. During the period of complete permanent dentition the angle of the jaw is, as a rule, about 100 degrees. In youth and extreme old age this angle is greater. From youth to adolescence these changes are accomplished by a deposition of bone, in old age by a process of absorption, although in childhood the bone may be bent in any

part. At birth the body of the mandible is straight and rests squarely against the maxillæ. From the cutting of the first incisors until the third molars are in occlusion, there is a space, posterior to the occluding teeth, which is an unsupported arch, upon which most of the power of the internal pterygoid and masseter muscles is expended (Fig. 220). The body of the lower jaw is not normally called upon unaided to resist the action of the masticatory muscles, nor is it capable of doing so. These, drawing on the angle, tend to cause a yielding upward in the body of the bone in the space between the teeth and the ramus.

**Protrusion of the Lower Jaw.**—The bending at the angle, when the body is unrestrained by proper interlocking of the teeth, allows the angle to open and the jaw to push forward. If, during this period, the inferior incisors are not firmly locked behind the superior, we have the

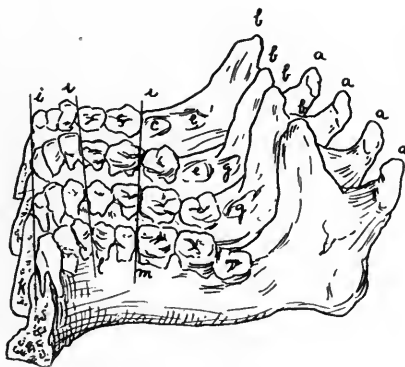


Fig. 220. Diagram by John Hunter, illustrating the normal growth of the mandible. It will be seen that the bicuspid teeth occupy less space than did the deciduous molars which they replace. The extra space is used partly by the permanent cusplids and partly by the first permanent molar moving forward. If the teeth are not crowded into this space, bicuspid internal spaces may result. In the younger bones it will be seen that there is quite a space between the ramus and the last occluding tooth.

beginning of a forward protrusion, which, if unresisted artificially, may result in the undershot jaw.

**Retraction of the Lower Jaw.**—The growth of the mandible is accomplished by the deposit of bone on the outer surface of the body and at the epiphysis of the condyle, and also on the posterior border and tip of the coronoid process and on the posterior border of the ramus, with an accompanying absorption of their anterior borders, which brings about a backward march of the ramus (Fig. 220). If the lower jaw fails to develop in proportion to the upper, we have it, as a whole, retracted. Some observations have led us to believe that a short ramus is, at least partially, responsible for all cases of retraction of the body. Any early interference with the movement of the temporomandibular joint is always accompanied by a retraction of the lower jaw.

**Open Bite.**—We have already spoken of the yielding of the much-strained jaw body. There is a deformity, which appears to come from the yielding of an abnormally soft bony arch between the occluding molars and the ramus, when the body is prevented from sliding forward by the upper incisors. The softened arch bows upward and then hardens, retaining this shape. When the teeth belonging to the bowed section attain full eruption, they are on a plane above the normal, and, occluding themselves, cause the open bite in the anterior portion of the jaw (Figs. 221, 222). Although true as far as it goes, we believe this is probably but a partial explanation of the etiology. These are fairly common cases. All except one of the cases of this kind that we have

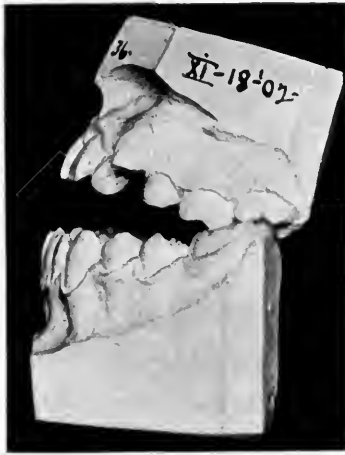

Fig. 221.

Fig. 221. Open bite in a young white boy. It can be seen that the separation between the upper and lower incisors is due to the erupting first permanent molar.—Case of Dr. Lischer.

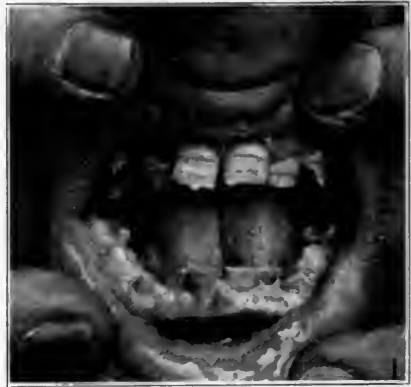

Fig. 222.

Fig. 222. Open bite in a young negro boy showing rachitic malformation of the teeth. Second molars are in contact.

observed have shown evidence of early rickets, which we think is the ordinary etiological factor.

In most of the cases we have observed, the open bite seemed to be due partly to a bending of the lower jaw in front of the second molar and partly to lack of development of the alveolar process on the anterior part of the upper jaw.

Fracture, malunion, or distortion of the jaw may cause open bite. Inability to close the mouth from lack of muscular force is a thing almost unheard of. After an excision of one Gasserian ganglion, or cutting of its posterior root, there is usually paralysis of the muscles of mastication of that side, due to cutting the motor root, but the muscles of the other side carry on function satisfactorily.



Contracting scars from burns on the neck and chin can greatly deform the developing jaw-bone.

### ORTHODONTURE IN THE TREATMENT OF MALRELATIONS OF THE JAWS.

Before the twelfth or fourteenth year all of these conditions can be more or less perfectly corrected by orthodontic appliances; the success largely depending upon the age at which the treatment is begun—the earlier the better. As soon as any limitation of motion of the joint is noticed, systematic forced movements should be practiced. All children who have suffered injury of the joint or have had profuse supuration in that neighborhood should be watched carefully. For even when the limitation finally results in a true ankylosis, it develops gradually and often goes unnoticed until the child is seen to be forcing food between the almost closed teeth.

The ability of the orthodontist to change the position of the teeth and the shape of the bones is dependent upon the same factors that permit of progressive malocclusions. In the growing bones abnormal pressure in any direction will cause a tooth to move its position. If this pressure is gentle and continuous, the alveolar bone will apparently move with it, being absorbed and redeposited to keep pace with the tooth. Some of the force is transmitted to the bones themselves, and in the very young the shape of the jaw-bones will be influenced by pressure applied to the crowns of the teeth.

### INDICATIONS FOR SURGICAL OPERATION.

After the bones have hardened, or after bony ankylosis has occurred, appliances will accomplish nothing, and when the deformity is pronounced, these cases are legitimate and proper cases for surgical interference. If the teeth are ever lost, it is impossible to make satisfactory artificial dentures for such mouths.

We have seen both disposition and nutrition radically influenced for good, and in the case of women, the resultant good cannot be overestimated. We would advise no one to undertake any cases without first having the fullest confidence of his patient, for during the convalescence trying complications might arise in which the surgeon will find his patience and his resources taxed to the limit. Operations on cases of moderate deformity should not be undertaken lightly, for the unforeseen accidents of surgery can here put the operator in a most unenviable position. It is real surgical work, although for its completion orthodonture is indispensable; and the earlier a competent, congenial orthodontist is associated in the case, the better it will be for both the surgeon and the patient.

## CHAPTER XX.

### TREATMENT OF DEFORMITIES AND MALRELATIONS OF THE JAWS.

The nasal fossæ are bounded by the maxillary bone and by bones attached to the maxillæ; therefore deformities of maxillary bones are apt to influence the size, shape, and patency of the nasal fossæ.

#### DEFORMITIES OF THE MAXILLÆ: OSSEOUS OBSTRUCTION OF THE NARES.

Nasal obstruction may be due directly to deformity or to lack of development of the maxillæ. If to bony occlusion of the posterior nares or, as in one case that was sent to us, to a congenital backward displacement of the maxillæ, the velum and mucoperiosteal covering of the hard palate are to be split in the median line. The bone, including the palate process, is to be removed until ample breathing space is established. Then the palate and velum are to be immediately sutured, as in an operation for congenital cleft palate (Figs. 132-141). In clearing such a bony obstruction, it is not necessary to preserve the whole of the nasal septum. The nasal fossæ can be converted into one cavity by a submucous removal of the bony part of the septum, while its mucous covering may be used to line the newly made part of the passage.

If the nasal obstruction is due simply to lack of size of the nasal fossæ and there are erupted molar teeth in both maxillæ, then the treatment proposed by G. V. I. Brown might be indicated. It consists of placing a jackscrew across the mouth from one upper molar to another. As the screw is spread, the intermaxillary suture is opened, the maxillæ separate, and the nasal obstruction is relieved. This operation can probably be successfully done before the tenth or twelfth year, and the jackscrew or some retaining appliance must remain in place until the opened suture is filled with bone, which requires some months. This is, of course, work that requires the technical skill of a dentist.

#### RETRACTION OF THE LOWER JAW.

Maxillary prognathism without corresponding projection of the lower jaw is extremely common. When it is sufficiently pronounced to be a deformity, to correct it, we are not called upon to attempt to raise the profile to the standard set by the Greek sculptors, which would be a surgical impossibility. We may, however, bring forward the lower

jaw to a harmonious outline, thus placing it within the limits of an accepted type, which is usually a possible procedure.

Artists have formulated laws of correct facial outline which should somewhat guide us in this work: (1) The septolabial angle should be ninety degrees. An exception to this is the case of the overhanging Roman nose, where it may be greater. (2) The lower lip should not protrude beyond the upper. (3) The distances between the hair-line and the root of the nose, between the root of the nose and the subnasal angle, and between the latter and the tip of the chin should be about equal. None of these rules, however, are absolute.

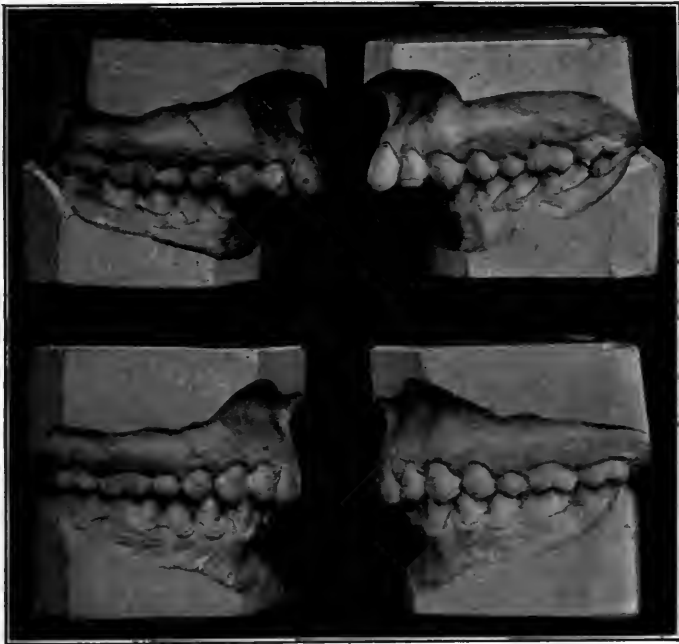


Fig. 223. Retraction of the mandible corrected by orthodontic appliances.—After Lischer.

**Correction by Traction.**—Before twelve or fourteen years moderate retraction of the mandible can be corrected by orthodontic appliances by gradually drawing the lower teeth and jaw forward until a new occlusion has been established (Figs. 223, 224). This is apt to leave considerable obliquity of the chin, which, when pronounced, can be treated as described later (page 246).

**Correction by Surgical Operation.**—In operating, the surgeon must not attempt surgical impossibilities or be misled by false issues. Occlusion, normal or abnormal, is the result of pressure and counter-pressure, of growth and apposition, and can never be established simply

by bone-cuts. The real issues ordinarily at stake are facial outline (which includes both the profile and the lateral breadth) and the ultimate occlusion, while immediate occlusion is a secondary consideration. To do his work correctly, it is necessary that the surgeon shall have at least a theoretical knowledge of occlusion and of the scope and limitations of orthodontic operations.

In the operations to be described, we have to deal with an upper cubical jaw and a lower one that is a hoop of bone capable of almost any kind of adjustment; and it is upon the latter that our efforts must be expended. It must have occurred to almost every thinking observer that it would be easy to correct the open bites and under-hung jaws if one could but cut through the bone that carried the nerve and blood supply to the teeth. The ultimate result of such a cut has been the

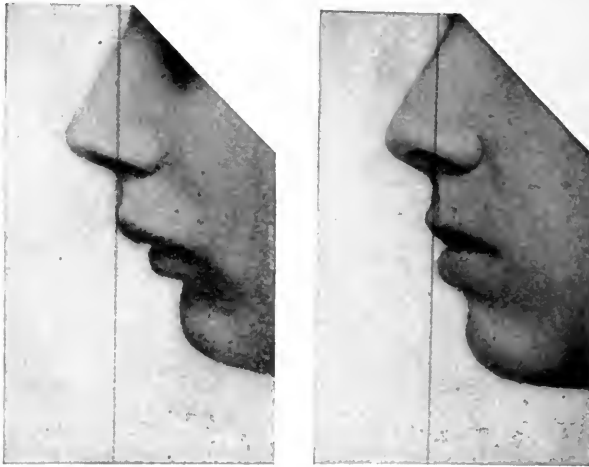


Fig. 224. Retraction of the mandible corrected by orthodontic appliance.—After Lischer.

cause of much contention among orthodontists for years. A fear of necrosis or non-union of the fragments has held them in check; without reason, we think we can show. Ununited fracture of the lower jaw is rare, and in the whole of the "Surgeon General's Index" there is not reported a single case, in English, German, or French literature, of necrosis or loss of teeth from sections of the vertical or horizontal ramus. Yet this is a recognized procedure for ankylosis. Esmarch recommends the removal of a section from the horizontal ramus for this trouble, because of the liability of the bones reuniting after simple section. This is the method advised in the standard textbooks of today. We do not think that we need to concern ourselves with the consequences of cutting the inferior dental nerve and artery. Our experience, which covers quite a number of cases, bears out this conclusion.

In retraction of the lower jaw we have a condition in which the inferior dental arch, as a whole, bears an abnormal relation to the upper; and it is reasonable in correcting it to move it as a whole. This can be done best by making a cut through the vertical ramus. After the cut is made, the jaw is moved forward to the position desired. Occlusion and facial outline are both to be considered, and the jaw is to be steadied in place by inserting soft cement between the grinding surface of the teeth and fastening the lower to the upper with wires. Artificial fixation at the site of the cut is unnecessary. As to the location and direction of this cut, we have done considerable investigating, but

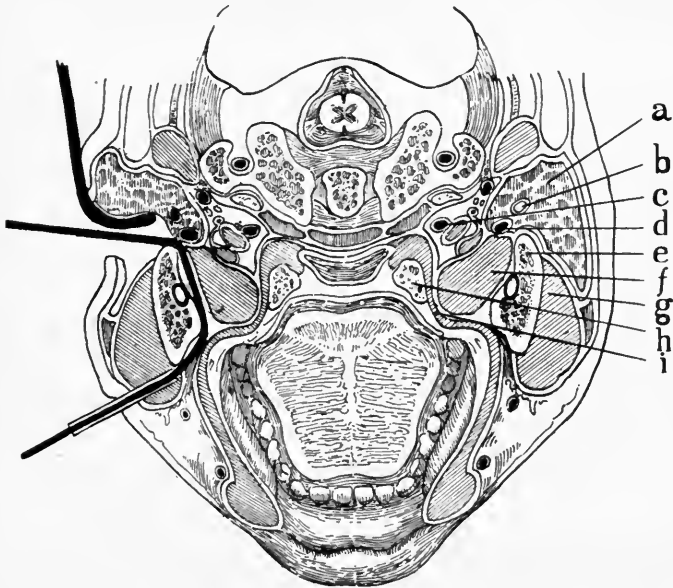


Fig. 225. Transverse section of the face at the level of the occlusal surfaces of the molars. On the left is shown the wound through the skin and fascia. The parotid gland is drawn back with a retractor, and the wire saw is seen passing around the ramus and out through the cheek. Where it emerges, the skin of the cheek is protected by passing the saw through a thin metal tube. On the right side are indicated: a, parotid gland; b, temporomaxillary vein; c, internal carotid artery; d, external carotid artery; e, ramus of the jaw containing the inferior dental nerve and vessels; f, internal pterygoid muscle; g, masseter muscle; h, tonsil; i, wall of the pharynx.

space will not allow us to do more than state our conclusions. This operation can be done above the entrance of the inferior dental nerve and vessels into the canal, thus avoiding their section. Here, however, one may be crowded for space and run the risk of injuring the parotid gland, large vessels, or the facial nerves. This section may be made in the line of the grinding surface of the inferior molars (or, preferably 5 millimeters above), with little risk of injuring any important structures except the inferior dental nerve and artery. In cutting the nerve where it enters the canal, which is at about this point, it has the best opportunity of reuniting.

## OPERATION FOR RETRACTION OF THE LOWER JAW.

**Cutting the Bone.**—The operation is done in this manner: An incision 2 centimeters long is made through the skin over the posterior border of the mandible. The skin is drawn forward, and the parotid sheath is opened at the anterior border of the gland, which latter is drawn backward until the posterior border of the ramus can be felt. A large, strong, curved needle on a handle, threaded with a heavy silk

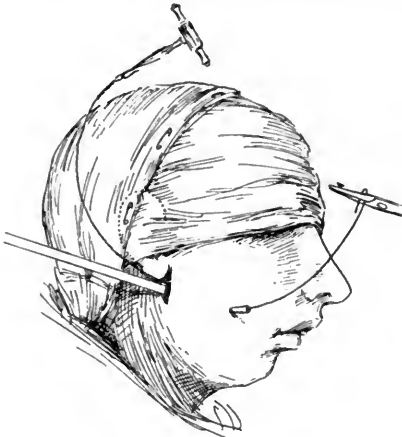

Fig. 226.



Fig. 228.




Fig. 227.

Fig. 226. Subcutaneous section of the ramus. Showing points of entrance and exit of the wire saw.

Fig. 227. Needle used for passing a carrier around the ramus of the jaw. It is important that the curve of the needle extends up to the point. If the point end of the needle is somewhat straight, the needle is very apt to pierce the buccal mucosa and enter the mouth.

Fig. 228. Dilator used for stretching the muscles and also for stretching bands about the joint. It is made from a uterine dilator, in which the dilating prongs are shortened and then covered with 3 millimeters of solder. Great care must be exercised in using this instrument to avoid avulsion of the teeth or fracture of the jaw.

carrier, is now passed between the parotid gland and the masseter muscle behind the ramus, hugging the bone closely. It passes forward between the ramus and the internal pterygoid muscle and emerges through the cheek without penetrating the mucous lining of the mouth. The diameter of the curved part of the needle should be a little greater than the width of the ramus. It is followed by a Gigli wire saw with which the bone is cut through (Fig. 226).

Hemorrhage is controlled by packing the space with sterile or mildly antiseptic tape, which is left in place for two days. In this operation the parotid gland is pushed out of the way, as is also the cervicofacial division of the facial nerve, which lies at the posterior border of the jaw. The temporomaxillary vein is also avoided, and the external carotid lies well out of the way. These anatomical points were verified by thirty special dissections (Figs. 225, 226).

The needle used is full-curved. The curved portion, being almost one half of a circle of 4 centimeters in diameter, must extend to the point in order to round the anterior border of the ramus without pene-

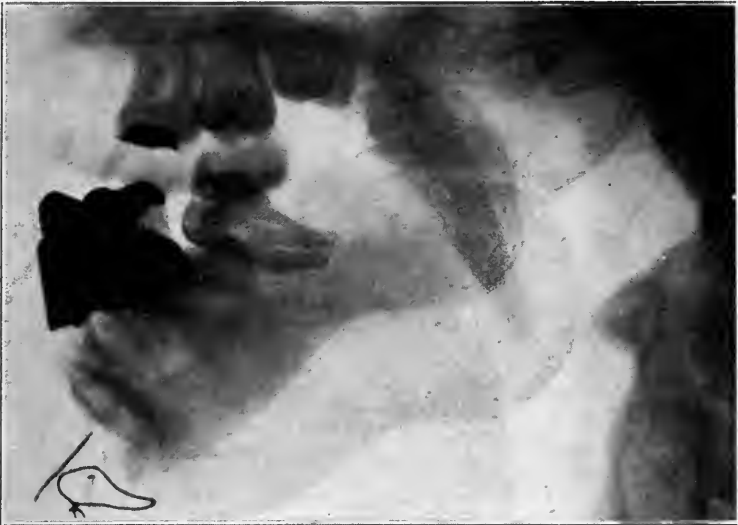

Fig. 229. X-ray showing condition of the ramus some time after section. Notice the obliquity with which the part of the ramus above the saw cut meets the lower portion. Compare with Fig. 257, Chapter XXI, which shows the same ramus before section. In this case there was no operation performed on the ankylosed joint, and on that side there is only a fibrous union between the divided parts of the ramus. Later this union became so close that it was necessary to excise the ankylosed joint. The nail and wire at the chin were used to hold a piece of costal cartilage in place.

trating the mucosa. The point is so formed that it will dissect the soft structures from the inner surface of the bone rather than penetrate them (Fig. 227). In this way bleeding is avoided, and there will ordinarily be no danger of penetrating the mouth. To prevent damage of the skin, after the saw is in place, a short, small steel tube is passed over the anterior end of the saw, through the skin and down to the bone. Posteriorly, the parotid gland is held back with a small retractor. In cutting the bone, the saw is held as straight as possible, and the operator should be familiar with the tricks of the Gigli saw (Figs. 225, 226).

This operation presents three distinct problems: (1) the cutting

of the bone, which is the easiest of the three; (2) the placing of the jaw in its new position; and (3) holding it there.

**Adjusting the Bone.**—The posterior part of the occlusal plane of the molars inclines upward and backward. On account of this obliquity the body of the lower jaw can be brought forward only by lengthening the ramus; theoretically, the line of the saw-cut should be slightly downward and forward, about 5 millimeters lower in front than behind, so as to allow the body to be moved downward as well as forward without completely separating the several fragments. As a matter of fact, however, x-rays show that the fragments of the ramus remain in contact at the posterior border in the operations we have done, and it is very difficult to exactly gauge the positions and directions of the cuts.

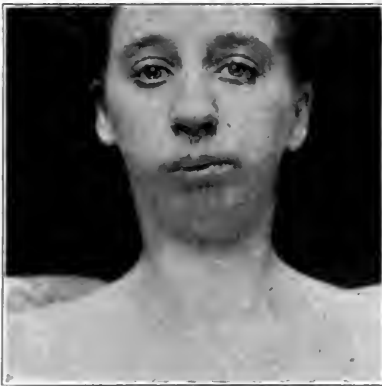

Fig. 230.

Fig. 230. Showing deviation of the chin, which may occur with retraction of the jaw, due to limitation in motion.

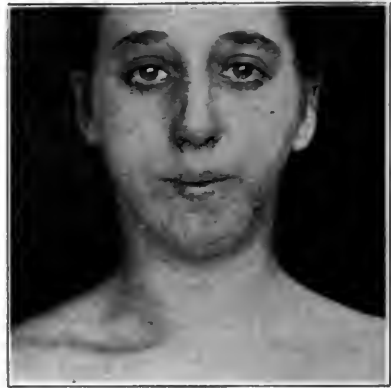

Fig. 231.

Fig. 231. Case shown in Fig. 230, after operation. The chin has been placed symmetrically.

It is only the posterior part of the body that moves downward, and the rotation thus produced lessens the obliquity of the plane of the chin, which is a very distinct advantage.

In order to lengthen the ramus, it is necessary to stretch the masseter and internal pterygoid muscles. This may be accomplished by inserting a fulcrum, such as a piece of pine, between the molars on each side and forcing the chin upward. (Another plan is the use of the dilator shown in Fig. 228.) We have even found it necessary to use a one-half-inch piece of pine board, two inches wide and eighteen inches long. The end of the board was placed back between the last molars, and a small piece of wood was placed transversely between the board and the upper bicuspids, this latter being done to prevent injury to the incisor teeth. By means of this lever the muscles were cau-



tiously stretched until the jaw could be brought forward. Even after this it may be necessary to grind or remove the posterior occluding molar teeth, and if this is necessary, it should be done at the time of the operation. As the bone is dragged forward, the saw-cuts gap in front, while the fragments remain in contact at the posterior border. This bone-gap must be filled with granulations. The resulting bone-scar tends to contract for months afterward, and unless permanent interlocking of the teeth is early established in the new position, some very hard-earned ground will be lost (Fig. 232).

In placing the body of the jaw, it is important that the chin is brought to the midline. Very often a retracted jaw deviates to one side, and in replacing it the general contour of the face is a better guide than the teeth (Figs. 230, 231).

**Intraoral Fixation.**—As for means of fixation, we use the teeth,

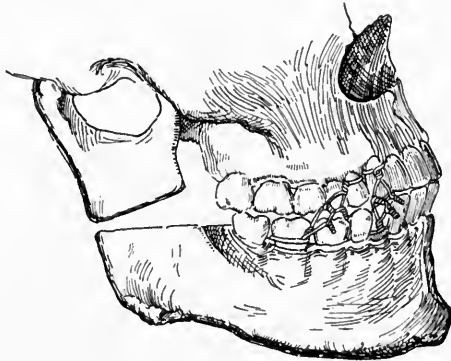


Fig. 232. Showing jaw wired in its new position after section of the ramus.

having never had satisfaction from any external adjuvant that we have tried. If the work is properly done, the teeth are sufficient. We have used all kinds of bands, but have found that the finest grade of soft iron wire, such as that used by florists, replaces these to advantage. An iron wire is passed around the crown of each of the selected teeth, fastened by two full twists. Next, the ends of an upper and a lower wire are twisted together, maintaining the tension while making the first twist. To hold the jaw forward, the upper first or second bicuspid is wired to the last available molar in the lower jaw with a No. 22 or 24 wire. This puts the pull in the right direction, and the strain is received on all of the molars in both jaws. To hold the chin up, the lower canines or first bicuspids are wired to the teeth directly above with a No. 24 iron wire, or preferably two bands that have been placed on these teeth before operation. We have settled on this iron wire after trying almost every available material; for it is strong, does not

stretch, is very pliable, and unless nicked by sharp-toothed instruments, will stand all necessary twisting. Unless there are a number of interlocking points of occlusion, quick-setting cement should be placed between the occlusal surfaces of the grinders; for, if the wires are exclusively depended on, the retention will be painful and unsatisfactory (Fig. 232).

In operating, place the jaw well forward, disregarding the immediate occlusion unless it interferes with your ends; if it should, grind or remove the offending teeth. One of the most noticeable features of these cases is the obliquity of the chin. If we bring the incisors into occlusion, we have made use of only half of our opportunity; for, be-

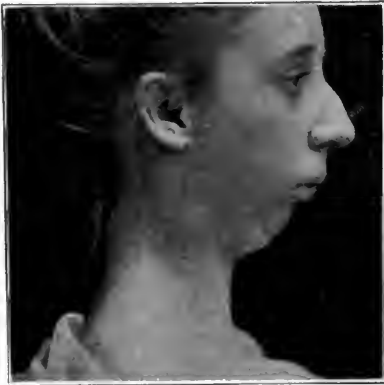

Fig. 233.

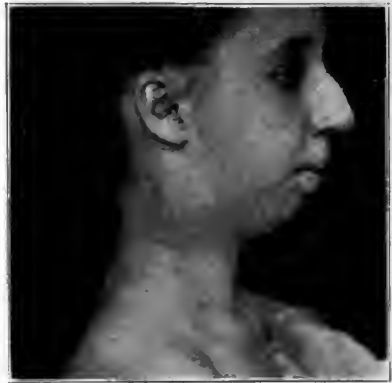

Fig. 234.

Fig. 233. Showing obliquity of chin in retraction of the lower jaw.

Fig. 234. Same patient as shown in Fig. 233, after bringing the jaw well forward. The obliquity of the chin is seen to persist, and something further will have to be done to render the result ideal. It was the result here shown that started the investigations that led to the transplantation of cartilage to correct chin obliquity.

sides the receding chin, there may or may not be an increased subnasal angle and an oblique chin (Figs. 233, 234).

Retraction of the mandible may be due to early ankylosis of the joint, which it always seems to accompany. In this case we have found it advantageous to do the operation for ankylosis, described in Chapter XXI, and at the same time bringing the jaw forward after cutting the ramus on the sound side. We have had to resort to the operation for ankylosis after bringing the jaw forward.

### OBLIQUITY OF THE CHIN.

If, as will often be the case after an orthodontic or a bone-cutting operation for a receding jaw, the obliquity of the chin is so pronounced as to detract materially from the result, it may be improved by either injecting paraffin into the chin or inserting a piece of cartilage or rib.

We studied and thought over the subject for three years before we attempted to correct this chin obliquity.

**Paraffin Injection.**—Until rather recently, we had no experience with the injection of paraffin; a continuously increasing observation of poor results from attempts to correct nasal deformities made us extremely wary of the procedure. Of late, however, we have taken up the use of paraffin and have been forced to the conclusion that its injection has a limited place in surgery, and if the operation is properly done, is as little likely to be followed by objectionable results as some other surgical operations. We think it might be the proper procedure

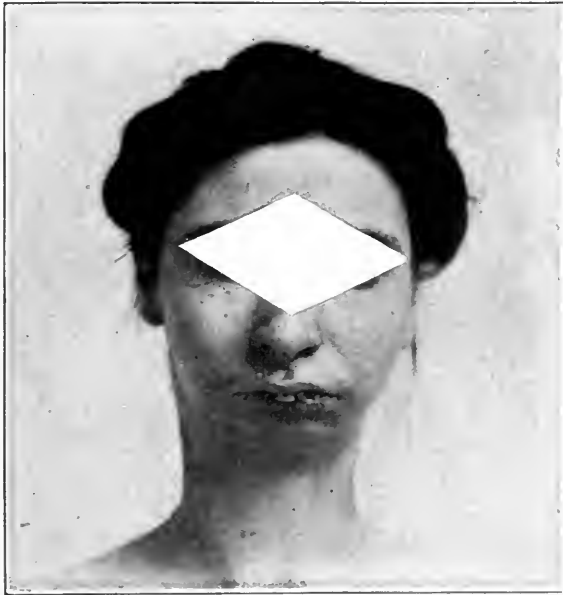

Fig. 235. Girl, twenty years of age. Complete bony ankylosis of left side, resulting from periarticular suppuration, following scarlatina at five years. Lower teeth had been removed to allow for a feeding space.

in certain cases of chin obliquity to place the paraffin deep in the tissues just in front of the periosteum. The materials required are: soft paraffin, melting at about  $120^{\circ}$  F. (there is paraffin on the market labeled to melt at  $110^{\circ}$  F., but experiment will show that it takes a temperature of about ten degrees higher to melt it); and a regular paraffin syringe, in which the piston is threaded and travels only by a screw. In children the operation had best be done under ether, but in adults a local anesthetic can be used. A 1 per cent solution of novocain in normal saline, to which, after boiling and cooling, is added 1 part of adrenalin chlorid to each 150,000 parts of the novocain solution, is to be injected into the tissues. After waiting for twenty minutes,

for the excess of solution to be absorbed, the paraffin injection may be made. Before attempting to make a paraffin injection, the surgeon should practice with his assistant until the paraffin can be handled without a hitch. The sterile paraffin is melted and drawn into a hot sterile syringe, all air being expelled. Air in the syringe will cause the paraffin to shoot out in jets, and the quantity injected will not be under the operator's control. The syringe is then placed in a basin of sterile water at a temperature of 125° F. The water and the syringe are allowed to cool until the paraffin can be forced out of the needle in a plastic thread. This is the form in which the paraffin should enter the

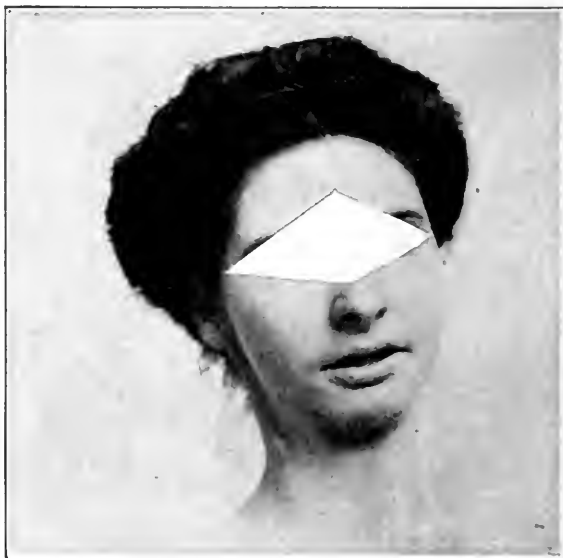

Fig. 236. Case shown in Fig. 235, after bringing body of the jaw forward and transplanting costal cartilage into chin.

tissues. Blocking in the needle may be overcome by dipping the needle in hot water or by applying to it a hot wet sponge.

In making the injection, and in practicing beforehand, the assistant should handle the syringe and make the injection—the surgeon inserting the needle, directing the amount, and controlling the paraffin in the tissues by finger pressure. The paraffin hardens quickly, and it is easier to make several injections than to remove it when in excess or misplaced. Judging from several instances in which we have dissected out misplaced paraffin from the eyelids and around the nose, the paraffin becomes incorporated in a growth of firm fibrous tissue, the shape of which cannot be changed by pressure.

**Transplantation of Bone or Cartilage.**—To fill out the chin with

bone or cartilage, an incision is made under the chin, and all of the tissues excluding the periosteum are reflected from the mental portion of the mandible. Bleeding should be controlled by pressure. Next, the seventh or eighth costal cartilage is exposed, and a section removed, including its perichondrium. This should be done without wounding the pleura or the intercostal vessels, though we have several times wounded the pleura in a dog without any apparent evil consequences. The cartilage is picked up with toothed forceps and trimmed with a cutting bone forceps; the finger with or without gloves should not be

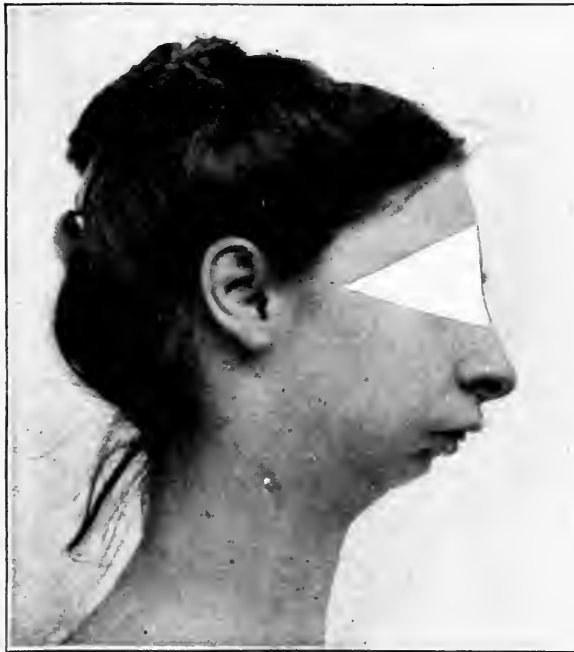

Fig. 237. Case shown in Fig. 235. Profile before operation.

put into either wound. As soon as each skin wound is made, the knife that cuts through the skin should be discarded, and the skin excluded from the operating field by attaching sterile cloths to the cut edges with tenaculum forceps or safety pins. The cartilage can be fastened to the bone with one or two wires or nails. The bone and cartilage having been drilled, the wound is closed without drainage by deep through-and-through silkworm gut sutures. If suppuration should occur, neither the sutures nor the cartilage are to be removed unless the infection be of a virulent character. We have had two pieces of cartilage and one piece of the tibia stay in place and unite to the soft tissues by its perichondrial or periosteal surface when there was suppura-

tion occurring in its deep surface. In one of the cartilage cases, an injection of Beck's bismuth paste stopped the suppuration.

The transplantation of cartilage or bone is not difficult. In one dog Dr. Coughlin and the writer transplanted thirteen pieces without a single one suppurating. The perichondrium must be preserved (Figs. 235-238).

### PROTRUSION OF THE LOWER JAW.

Protrusion of the lower jaw may be from overgrowth, from sliding forward, or from a combination of these.

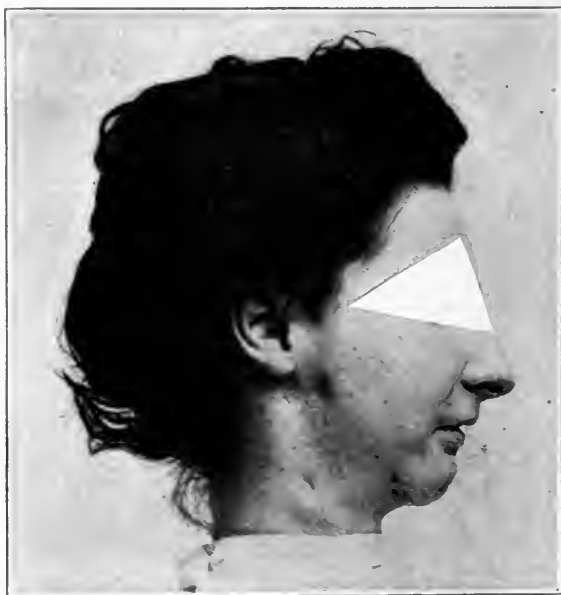

Fig. 238. Case shown in Fig. 235, after operations. The scar on cheek is from suppuration at the site of wound for cutting ramus. The dark spot under chin is wound through which the cartilage was inserted. Neither this nor the cheek wound had entirely healed at the time the photograph was taken. Later this scar became almost invisible.

The lower jaw may protrude a considerable distance beyond the upper. When the protrusion is marked, especially if there are interdental spaces in the bicuspid region, the lingual inclination of the incisors is extreme (Fig. 218). This is due to pressure of the orbicularis oris muscle.

**Correction by Traction.**—To correct this condition, different means must be adopted. If seen early, before the twelfth year, in many cases the jaw can be forced back to its proper position by a chin and head cap connected by elastics and worn for several hours each day, after the plan suggested by Angle. That this will be successful in

every case, we are not sure. If seen after the bone growth is completed, a different means of correction must be adopted, which is the removal of a piece of the jaw-bone on either side (Figs. 239-243).

**Correction by Surgical Operation.**—Where the lower jaw as a whole occupies a forward position, there will be also lateral protrusion, for two reasons: (1) The broader posterior part of the lower jaw is brought opposite the narrow anterior portion of the upper; and (2)



Fig. 239.

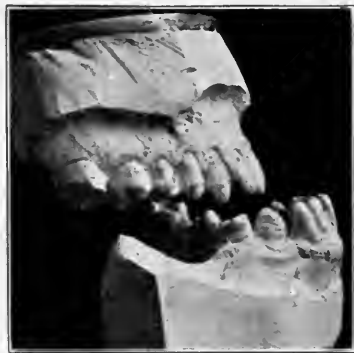

Fig. 240.




Fig. 241.

Fig. 239. Protrusion of lower jaw in man, 27 years of age. Lower jaw is abnormally large, and upper jaw abnormally small. When the mouth closed, no tooth in the lower jaw touched any tooth in the upper jaw.

Fig. 240. Same case as shown in the preceding figure.

Fig. 241. Case shown in the preceding two figures after operation. On the right side a section of the jaw-bone was excised behind the first molar tooth.

when this occurs, the impact of the jaw is taken, not on the buccal cusps of the lower molars, as is normal (Fig. 214), but on a part nearer the lingual cusps. This tends to rotate the lower molars lingually, which is accompanied by an outward rotation of the lower border of the bone. Thus we have a real spreading at the lower part of the body. This lateral protrusion must also be corrected or compensation made.

Sections of bone of the proper size are removed, and the fragments brought together. The cuts are illustrated in Figs. 244, 245, by the lines (aa). The sections (dd) are removed, then the fragments (cbc), shown in dotted lines, are moved in and back to form the new arch (c', b', c'). The lateral fragments rotate on an axis corresponding, not to the last molar tooth, but to the temporomandibular articulation (oy). Now, as the distance from the cut to the last molar (xx) is about one half that from the cut to the axis of rotation (xy), the anterior end of the fragment will move in twice as far as does the last molar, which is about in proportion to the usual displacement of the

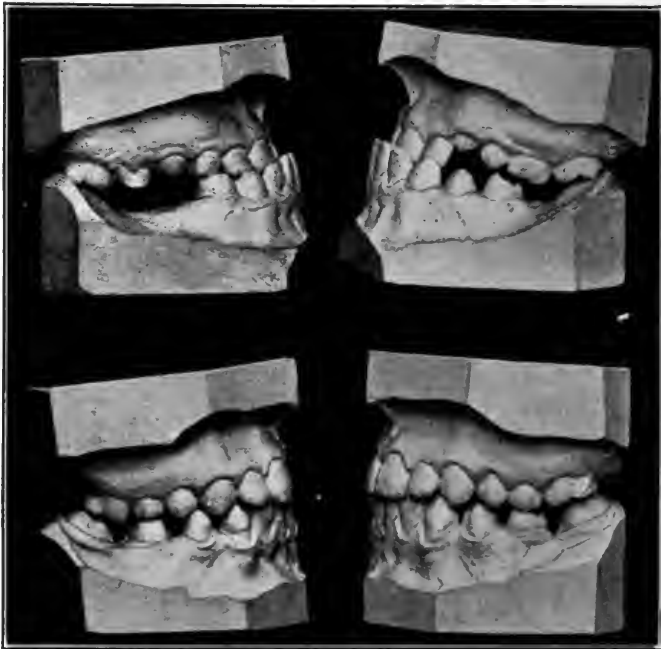


Fig. 242. Protrusion of the lower jaw. Correction by orthodontic appliance.—After Lischer.

two points. By this operation both the lateral and the forward protrusions are corrected.

In determining the location of the cuts and their directions, plaster models and x-ray should be used. Still, here, as everywhere else, the eye and the finger of the operator must be the surgeon's most useful guides and instruments of precision. While one can bring forward a retreating chin with every assurance of improving the facial outline, in setting back a protruding chin so that the lower incisors will be in normal occlusion with the upper, one might destroy the one strong feature in an otherwise weak face.



Often protrusion of the lower jaw is accompanied by an abnormally small upper jaw; therefore the chin should be brought back only far enough to be in harmony with the other features, leaving it to the orthodontist to bring forward the upper incisors if necessary, but the orthodontist should be in consultation in the case from the first. Indeed, in some cases it would be of considerable advantage to have the upper jaw expanded and the upper incisors and canines brought forward before the operation on the lower jaw.

The contraction of the upper jaw is probably due to the fact that the tongue finds an abnormal amount of room within the lower dental arch, which allows the upper arch to contract or fail of full development. If the size of the lower arch is suddenly contracted, the tongue will be deprived of some of its accustomed intraoral space and must be

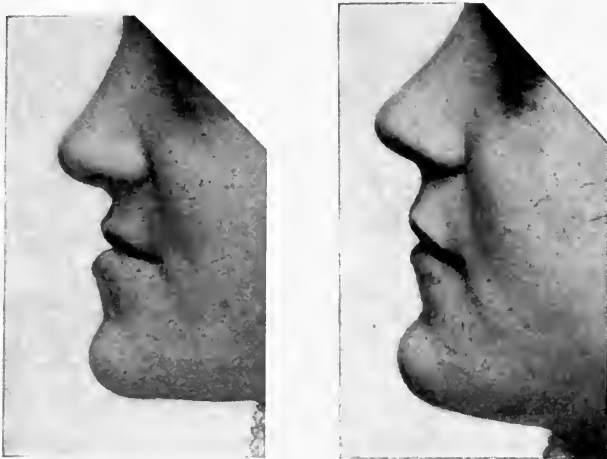

Fig. 243. Protrusion of the lower jaw corrected by orthodontic appliance.—After Lischer.

forced back into the oral pharynx. We have never seen more than a temporary respiratory embarrassment from this, but it is a point to be borne in mind.

In operating for protrusion of the lower jaw, the bone may be cut in the ramus or the body. In first considering this operation, we dismissed the ramus for the reason that in the case in hand much of the protrusion was due to overgrowth of the body, and we feared that, if we cut the ramus and forced the body back, the space behind the angle might be crowded when the mouth was opened.

Dr. W. Wayne Babcock, of Philadelphia, reports two cases which he corrected by operation upon the ramus. From the illustrations, however, we believe that in his cases the deformity was due wholly to a sliding forward of the body and not to an overgrowth of the bone.

If our conception of the pathology is correct, it is perfectly reasonable to correct such cases by sliding the body back into place. Dr. Babcock was led to adopt this procedure for fear that, if the anterior attachment of the tongue was moved back, there might be respiratory embarrassment; for, if this followed the operation on the ramus, it could be corrected by drawing the jaw forward.

In operating upon the body, the bone may be cut submucously without extending the incision into the mouth, in which case the wound should remain sterile. The open operation, in which the bone and its coverings are sawed through right into the mouth, is not fraught with the dangers that some commentators on this operation have conjured up. It is a fact, known to all of any clinical experience, that nearly

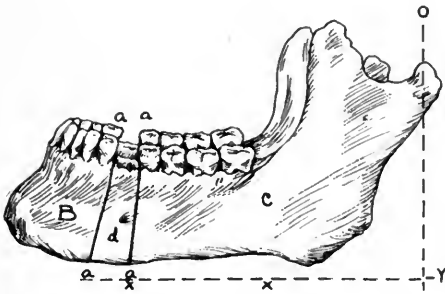


Fig. 244.

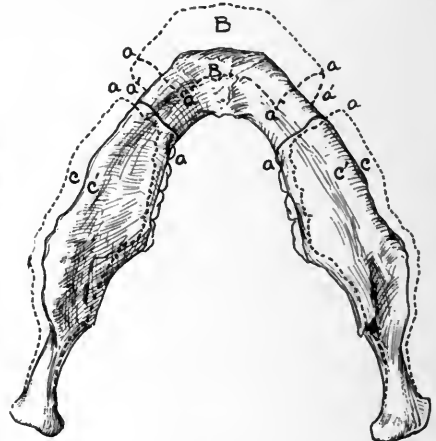


Fig. 245.

Fig. 244. Abnormally long jaw with interdental spaces in the bicuspid region. Showing position of cuts for correction.

Fig. 245. Reconstructed jaw, showing how both forward and lateral protrusion are corrected by removing bone sections. The dotted lines indicate the jaw-bone shown in the preceding figure.

all fractures of the body of the jaw-bone are open fractures and that, unless there is splintering or comminution, these open fractures unite about as quickly as do closed fractures. Even when there is considerable suppuration, healing and union usually follow quickly after inferior drainage is established and the pieces of dead bone are removed.

While the subperiosteal operation has much to commend it, not all of the points are in its favor. The sawing can be more accurately done with a straight than with a wire saw, and none of the remaining bone is deprived of its periosteum. Should there, during the subperiosteal operation, be established through accident a communication between the wound and the mouth, necrosis of the bone might occur; a thing most improbable when the periosteum is left intact on the remaining bone and free drainage is provided.

As before stated, the site of the bone-cuts, the size and shape of the sections to be removed, and the means of retaining the newly constructed jaw are determined before the operation. We think the site of election is at the second bicuspid, but one may be deterred from sacrificing these teeth by the presence of other natural or acquired interdental spaces. We once removed a section at the site of a missing second molar on one side. If the submucous operation is to be done, the teeth are to be removed at least four weeks before the operation, but if it is to be an open operation, the teeth may be removed at the same time. In operating on the ramus, no teeth need to be removed.

### TRANSMUCOPERIOSTEAL OPERATION FOR PROTRUSION OF THE LOWER JAW.

The mouth having been properly prepared, the shoulders are raised, and the head drawn back.

**Fixing the Jaw.**—In order to render the jaw rigid, a pine block is inserted between the molar teeth, on one side, behind the site of the proposed bone section. The jaws are closed firmly on the block, and



Fig. 246. Adjustable double-bladed saw, which is very useful when the case permits of making parallel cuts through the bone.

held there by wires passing between the molars. (See Fractures of Mandible, Fig. 52.) This will fix the lower jaw, which a gag will not do.

**Cutting the Bone.**—Corresponding to the site of the bone which is to be removed, the skin lying under the border of the jaw is drawn upward, and a cut 2 or 2½ centimeters is made parallel with this border. This will render the scar inconspicuous when the operation is complete. The incision extends through the skin, fascia, and platysma. The tissues are dissected from the outer surface of the jaw-bone, but without on any account injuring or even exposing the periosteum. The dissection is continued upward until the mouth is opened through the buccoalveolar cul-de-sac, the mucous covering of the gum being left intact.

Before inserting the saw-blade, the exact position of the first saw-cut is determined, and a flat piece of metal may be inserted into the wound and turned on edge so as to rest against the bone just to the outside of and parallel with the first cut. This will serve as both a

guide to the saw and a protection from the soft tissues which would deflect the blade from its proposed course. The handle of a knife or the blade of another saw can be used for this purpose; but if the edge that rests on the bone is toothed, it will not slip, and if the protector is fixed on a right-angled handle, it can be used with greater ease. No matter what kind of a saw is used, for obvious reasons the bone should not be cut entirely through in any place until the fixation holes are drilled near the lower border and all of the other saw-cuts are at least three fourths of the way through. We have a mechanical saw, very narrow and probe-pointed (a nasal saw modified), run by an engine and cable, that cuts very rapidly; but a sharp narrow-bladed metacarpal saw will suffice, and is probably safer. We use also an adjustable probe-pointed double-bladed saw, which is ideal for making parallel cuts, but not otherwise (Fig. 246).

### **SUBMUCOPERIOSTEAL OPERATION FOR PROTRUSION OF THE LOWER JAW.**

If the interdental spaces are not sufficiently large, the teeth from the sites of the proposed bone sections must be removed at least one month before the operation so that the gum tissues will be entirely healed. It is even better to wait until considerable absorption of the alveolar process has taken place.

The mouth is prepared for operation as usual. The exact site of the piece of bone to be removed should be marked on the skin with a pencil or a knife scratch. This will correspond to the center of the skin incision. After the skin of the face and neck is prepared, a sterile cloth or towel is sewed across the face from ear to ear on a line running between the mouth and the chin. This towel is turned upward over the ether mask and prevents contamination from coughing or vomiting. It is not necessary to fix the jaw, as it can be held up with the fingers of an assistant.

**Cutting of the Bone.**—An incision 3 or 4 centimeters long is made along the under border of the jaw down to the periosteum. The soft tissues are dissected from the periosteum half way up the inner and outer surfaces of the body of the jaw; from here up to within a short distance of the necks of the teeth, the dissection is subperiosteal. If the necks of the teeth should be exposed, there would be a communication between the wound and mouth. It is easier to make the whole dissection subperiosteally, but the vitality of the bone is better assured when the exposed ends are not entirely deprived of this source of nutrition. At the site of the interdental spaces a curved, blunt needle is passed over the alveolar border of the jaw, hugging the bone closely; on no account must this be allowed to penetrate into

the mouth. It is followed by a silk or linen carrier which in turn draws a Gigli saw into place<sup>1</sup> (Fig. 247).

The ring on one end of the Gigli saw is to be cut off, and the end bent into a sharp hook; this takes less room than the ring and is less liable to injure the mucoperiosteum of the gum. The eye of the operator is his only guide in making the cuts. Before making the cuts, the bone should be drilled for wires, and no saw-cut should be completed until all of the others in both sides are almost entirely through; otherwise one will be dealing with fragments that are difficult to control. For this reason it is better to use four saws. It is better to remove too little than too much bone; for, though the jaw-bone is extremely hard, it can be rongeuired away with a good instrument or a

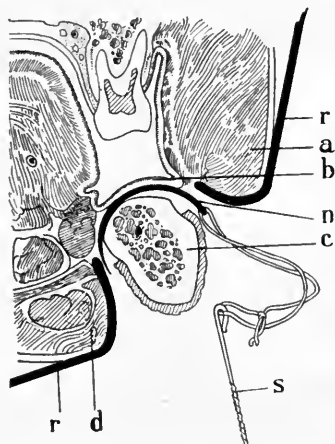


Fig. 247. Submucous resection of the lower jaw. Coronal section through the body of the jaw and the surrounding tissues. a, tissues of the cheek; b, mucoperiosteum of the gum raised from the body of the jaw; c, body of the jaw, covered with periosteum on its lower part; d, submaxillary tissues; n, curved needle passed over the body of the jaw; r, retractors holding back the cheek and submaxillary tissues; s, wire saw, with ring replaced by a sharp bend, attached to the needle by a silk carrier.

coarse bone bur. While doing this, each fragment can be held with a pair of sharp-toothed lion forceps that will grasp the bone but will not tear its coverings.

If only the alveolar portions of the bone are left in contact with a V-shaped space left open below, the chin fragment of the jaw may later become tilted downward, as the alveolar bone will not form firm union.

**Adjusting the Bone.**—The bone sections having been removed, the new arch is formed by wiring the remaining fragments with

<sup>1</sup>The instrument common on the market is an imported Gigli saw made with two running spiral threads on a round wire, which is of such inferior quality that at one time we about abandoned the use of the Gigli saw. Of late, however, we have procured some saws which are made of a twisted square wire, with four threads. This saw cuts for a much longer time without clogging, and the quality of the steel seems to be better.

silver wire, which was put through the holes drilled before the saw-cuts were made. The final twisting of these wires is not done until the intraoral fixation is made.

**Intraoral Fixation.**—The means of splinting the fragments is important. HULLIHAN, in 1850, for a case in which he had resected and replaced the alveolus, devised a continuous metal splint, cemented over all the teeth in the lower jaw (Fig. 50). We first tried wiring the bones, and also the lower jaw to the upper. In commenting on a case of this kind on which we had operated, Dr. ANGLE suggested a metal splint made in three sections, which is to be cemented over the teeth before the operation. The portions of each side to be removed were not to be covered by the splint, and the adjacent ends of the splint were to serve as guides in the sawing. When the bone is removed, the ends

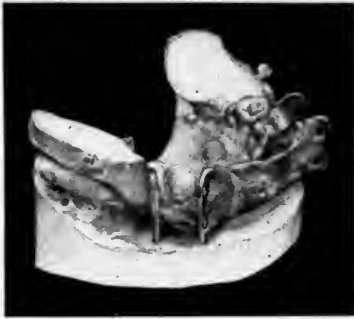

Fig. 248.

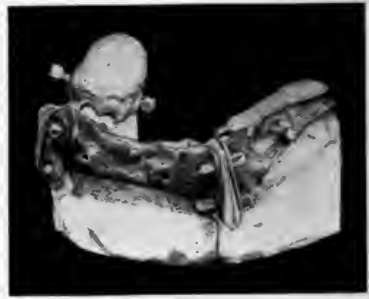

Fig. 249.

Fig. 248. Lateral view of Angle splint, showing flanges drilled for bolts, and also bicuspid teeth that were removed at operation.

Fig. 249. Angle splint after operation, lateral view. To allow for inaccuracies, the distance between the flanges was made larger than the section of bone to be removed. After operation the space between the plates was filled with a piece of lead plate, beaten and cut to the proper shape.

of the three pieces of splint are fastened together. We have not found it practical to make the splint serve as a saw guide, but Figs. 248, 249 show a modification of Angle's idea, made for us by J. A. BROWN, D. D. S., which worked satisfactorily. The use of such a splint allows the mouth to open. We would not dispense with the lower fixation in this operation. Proper fixation here consists of fastening the cut bones with silver wire or with chromicised catgut at their lower borders, and for the upper fixation using the Angle splint, or wire. In wiring, the teeth adjacent to the cuts should not be used. It will be much better to have bands, carrying rings on their buccal surfaces, attached to teeth just beyond those bordering on the cuts. That is, if the bone section is removed from the site of the second bicuspid, the cuspid and second molar will carry the bands. Bands are placed

on upper teeth that will correspond to the bands below after the jaw is cut. The fixation is made by passing a wire between the two lower bands and between each of the lower bands and the one above (Fig. 250). Here solidity will be gained by placing cement or softened gutta-percha at proper places between the occlusal surfaces, but space must be allowed for the taking of liquid food. We consider this the best plan of fixation.

The intraoral fixation and the lower fixation should be done together so that neither one will throw the other entirely out of balance, as might be the case if the cuts are badly made. The teeth can be moved later, and it is not necessary to have absolutely accurate bony contact.

The bone wires are twisted, bent down, and cut at the lower border

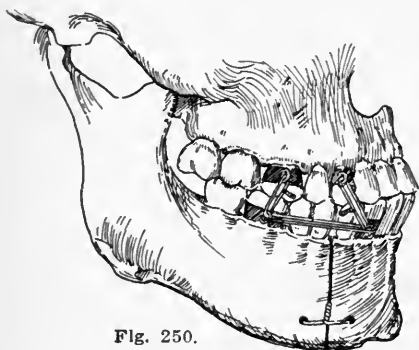


Fig. 250.

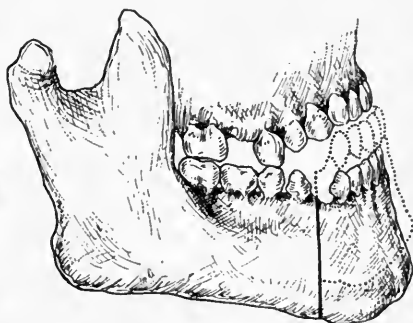


Fig. 251.

Fig. 250. Fixation of the jaw by wires and bands, after removing a section from the body. (The lower wire should be shown, bent downward.)

Fig. 251. Reconstruction of an open bite in a boy 16 years of age, due possibly to the very early crumbling away of the crowns of the deciduous molars which had occurred. Showing correction by simple section of the body of the jaw on each side.

of the jaw so that they can be found if it is necessary later to remove them.

The deep part of the wound is closed with interrupted No. 00 tanned gut, and the skin is closed with interrupted silkworm gut. A small spirally split tube or fold of rubber dam is to be led to the bone cut and sutured into the skin.

If the wound heals primarily, the sutures may be removed in four days. If the wound suppurates, unless there is a virulent infection, some of the sutures should remain until there is no danger of the wound gaping.

### BABCOCK'S OPERATION FOR PROTRUSION OF THE LOWER JAW.

If the protrusion is due entirely to a sliding forward of the body and there are no abnormal interdental spaces or supernumerary teeth,

the means adopted by Babcock is surely the simpler and proper operation. Dr. Babcock exposed the ramus and cut it with a chisel, but we think the method of cutting the ramus, described under Retraction of the Jaw, has several advantages over the open operation. The jaw is to be fixed as after the operation of bringing the body forward, but the posterior wires must be so applied that they will hold the body backward, in place of forward. The teeth should be made to interlock so that the lower jaw cannot again push forward before the permanent callus completely fixes the bone.

### OPEN BITE.

**Correction by Traction.**—A slight open bite in a child under twelve years may be corrected by the orthodontist. In older persons, the anterior teeth may be lengthened by porcelain crowns.

**Correction by Surgical Operation.**—If it is decided that an operation on the jaw-bone is necessary, a study of plaster reproductions of the dentures will reveal the character of the operation indicated.

### OPERATION FOR OPEN BITE.

In some cases all that will be required is a simple section of the jaw on both sides, in front of the first tooth that occludes with those above. Then the anterior fragment can be moved up to occlusion (Fig. 251). In others it will be necessary to remove a V-shaped section from the bone on each side, just in front of the first occluding tooth. The apex of this V-shaped section is at the lower border of the jaw, and usually a tooth must be extracted from the site of the section on each side (Fig. 252). The bone-cutting can be done from within the mouth with a Gigli saw or cross-cut fissure bur, but we believe it better surgery to operate from below as in the open operation for protrusion of the lower jaw. The method shown in Fig. 253 has the advantage of not shortening the lower jaw.

As before cited, the open bite is partially due to deformity of the upper jaw, and the surgeon must not expect to be able to entirely correct it in all cases by an operation on the lower jaw. A better result will come from restoring the lower jaw to its proper form and correcting the remaining open bite, either by bringing down the upper incisors with an orthodontic appliance or by extending them with porcelain crowns.

**Fixation.**—The fixation is to be made as after a section of the body of the mandible for protrusion. If the teeth in the chin fragment are very poor so as to afford an insufficient anchorage, the mouth may be dressed open by means of a splint previously made on reconstructed plaster dentures. This will prevent the chin fragment from



being pulled down by the digastric and geniohyoid muscles. If the upper teeth will afford good anchorage, two silver wires may be passed entirely around the chin fragment and anchored to the teeth above (Figs. 40, 53).

### ATYPICAL DEFORMITIES.

In the classification of jaw deformities here given, we do not wish to convey the impression that we have systematized the whole subject, but rather, for convenience, we have made this grouping from the cases which have come under our observation.

There are other deformities which will have to be considered individually, although on the general lines which have been laid down

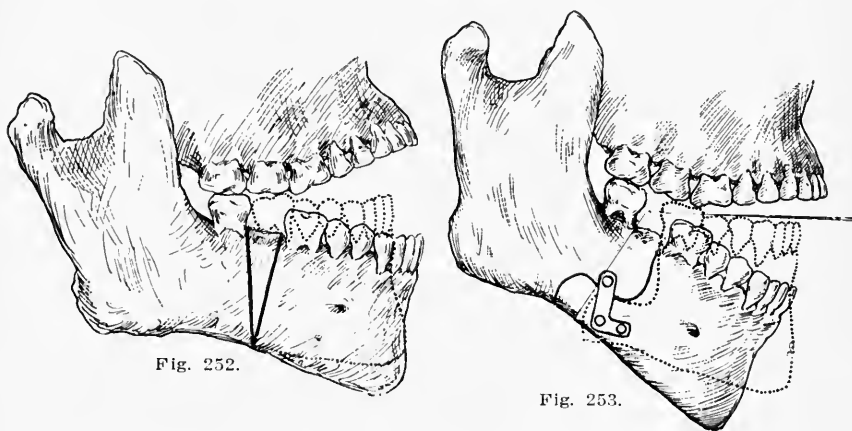


Fig. 252.

Fig. 253.

Fig. 252. Open bite of an extreme type in a young man, showing how correction might be made by a V-shaped excision. This would have the disadvantage of shortening the jaw considerably, as shown in the reconstructed jaw indicated by dotted lines. The operation, shown in Fig. 253, was done in this case.

Fig. 253. Showing operation by S-shaped bone-cut, that lengthens the jaw-bone and gives a better closure of the mouth. The silver splints at the site of the bone-cut are absolutely necessary, and increase the risk of sepsis. The bone spaces will fill in satisfactorily, but the transverse part of the "S" cut must be in hard bone.

here. Contraction of scars from burns on the neck and chin can greatly affect the shape of the lower jaw. Although the title of the chapter does not include them, deformities arising from unreduced unilateral or bilateral dislocations, malunion of fractures, etc., are germane to the subject. They are to be corrected on these same lines.

### PREOPERATIVE CONSIDERATIONS.

The instruments should always include tooth forceps and means for grinding the teeth. If the surgeon is not familiar with the use of these, there should also be present someone who knows how to use them. The surgeon should be thoroughly familiar with the strength and twisting endurance of the wire he is using.

Before operating, the patient should be in the best possible condition; the air-passages should be free, and foci of suppuration in any part of the body should be rigidly excluded.

The surgeon, by prolonged study, should have made himself thoroughly familiar with the anatomical conditions which he will treat.

#### **AFTER-TREATMENT.**

After the operation there will always be sufficient space between the teeth to take liquid and, in most cases, semifluid food. Nutrition and hygiene should be kept at the top notch. Rigid mouth asepsis before, during, and after the operation is the best preventive of sore and painful mouths.

## CHAPTER XXI.

### DISEASES OF THE TEMPOROMANDIBULAR JOINT— LIMITED MOVEMENT OF THE JAW.

The temporomandibular joint is a diarthroidal joint more or less subject to the same diseases as are other joints of the same character.

#### DISEASES OF THE TEMPOROMANDIBULAR JOINT.

It is particularly liable to be affected by suppurative processes in its immediate neighborhood. We have also seen cases in which the joint has been destroyed, probably as the result of gonorrhœal arthritis, metastatic septic arthritis, or arthritis following scarlatina. We have seen destruction of the joint apparently following simple injury. Tubercular arthritis of this joint is probably very rare. The joint is sometimes affected along with others in hypertrophic arthritis, but the most common affection of which people complain, for which they seldom seek relief, is "cracking" of the jaw. This may be acute or chronic. It seems to be due to a laxity of the ligaments which allows the intra-articular fibrocartilage to become caught by the condyle, causing either a cracking sound or a distinct momentary locking. Sometimes in the more acute cases it is accompanied by quite disagreeable sensations.

**Treatment.**—For any disease that demands an operation within the joint capsule, the plan of approach that is detailed under the Treatment of Ankylosis would be appropriate.

It is somewhat difficult to distinguish between an intra- or periarticular suppuration, and usually the pus is liberated only when it begins to point. The joint could be opened by a transverse incision along the lower border of the zygoma, from its middle back to the tragus. With care, by drawing back the tissues with retractors, the auriculotemporal nerve and the temporal artery can be avoided.

The most effective treatment of acute joint troubles is rest, with or without the application of heat or cold, which treatment is easily adapted to this joint.

In an acute painful condition the patient will hold the jaw fairly quiet, but in many subacute processes help can be gained by artificially limiting the movements of the jaw.

As the mouth opens, the condyle of the jaw glides downward over quite a large arc. By limiting the amount that the mouth can be opened, the condyle can be confined to the posterior part of the fossa;

the damage to an inflamed joint can in this way be lessened, and the ligaments given a better chance to recover. A head-and-chin bandage will partially control the motion of the jaw, but a more acceptable plan is to place a band on an upper and a corresponding lower bicuspid tooth, each band to have on its outer side a small ring through which is threaded a silk ligature which will limit the amount of opening.

At first the jaw may be allowed to open 5 or 10 millimeters, and later, as the condition improves, the excursion can be increased. The ligatures break frequently, but the patient can be taught to have some one at home replace them. Three weeks is the longest that we have ever continued this treatment for anything but a chronic dislocation, and have thought that quite as much was gained from the habit of not opening the mouth wide as from the actual treatment. If this treatment is adopted for some very active inflammation that might be followed by adhesions, the means for overcoming adhesions should be instituted as soon as the acute process has subsided.

### HYSTERICAL CLOSURE OF THE JAWS.

Inability to open the mouth may be a hysterical phenomenon, which is most common in young women. The clinical history of the case and the lack of a definite lesion are the bases of the diagnosis. The patient is of a "nervous" temperament and usually gives a history of having had similar attacks before, usually recovering rather suddenly. The attacks are, as a rule, associated with some mental strain or worry, and while the attack lasts, which may be for weeks, the amount of opening varies. Here, as with every other supposed hysterical manifestation, the diagnosis should be made only after very careful consideration.

The treatment consists in general treatment of the patient, encouragement, and the assurance that the condition will disappear.

### LIMITATION DUE TO REFLEX IRRITATION.

An inflammatory process in the posterior part of the floor of the mouth, the cheeks, pharynx, or of the external auditory canal may prevent the patient from opening the mouth on account of the pain it causes, but the limitation may be entirely involuntary with no pain, due to reflex irritation of an intraoral lesion. Disease of a lower tooth is the most common cause of reflex spasm of the muscles of mastication, but an upper tooth or an ulcer on the tongue may cause the same thing. When the source of irritation is removed, the spasm is almost at once relieved. Irritation from the third molars is a common source of such a spasm. The attacks may recur several times with varying intensity before the source of the irritation is discovered. This point

should be remembered in making a diagnosis of hysterical spasms. There may be one or several muscles involved in the spasm. If the cause is not evident, the vitality of the teeth should be tested, and any treatment that is indicated should be instituted.

Prinz's electrical reaction is the most delicate test of the condition of the pulps, while the x-ray might locate pulp-stones, enlargement in the roots, or chronic alveolar abscess.

The limitation may be directly mechanical, due to inflammatory masses, new growths, or malunion of fractures, and it should not be forgotten that tonic spasm of the jaw muscles is an early symptom of tetanus.

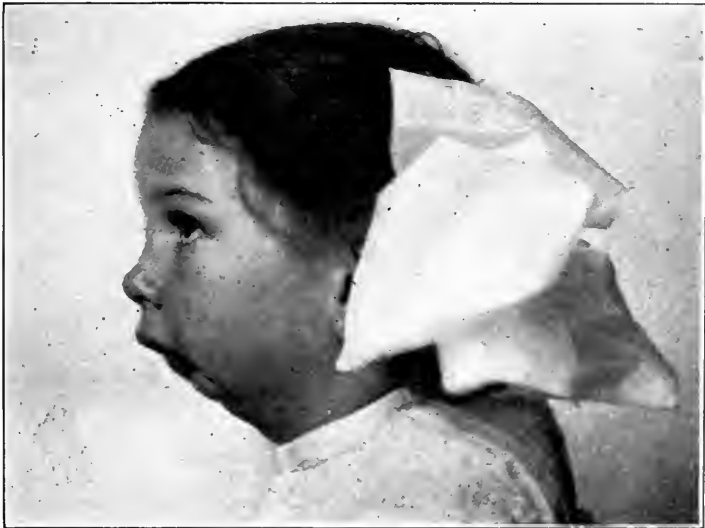

Fig. 254. Showing child at five years, who, probably as the result of injury, had a double fibro-osseous ankylosis existing for two years. A resection was made of both joints, which gave a free opening of 2 centimeters. No attempt was made to bring forward the body of the jaw, for, on account of the age of the child, we thought the jaw would develop after an opening was established.

#### LIMITATIONS DUE TO SCAR BANDS OR ANKYLOSIS.

The conditions described above, including inflammatory obstruction, are transitory. If the limitation is due to scar bands or an ankylosis, the condition will be permanent until some successful means of correcting it is adopted. The scar bands that bind the jaws together may be situated anywhere between the symphysis and the joint. An ankylosis may be true, in which case one or both joints are replaced by a bony union; or it may be false, due simply to intra- or periarticular scar bands and adhesions. If an ankylosis or a very great limitation has occurred early, there will be retraction of the chin due to lack of development of the mandible (Figs. 233, 237, 254, 265).

Ankylosis, either true or false, may result from injury or disease. In young persons the disease is usually an articular or periarticular suppurative process and may follow any of the acute infectious diseases, especially scarlet fever. It may be due to scars resulting from extensive intraoral ulceration. In many of these cases the ulceration is supposed to have been the result of salivation, but from the appearance and extent of those we have observed, we are more inclined to credit them to noma. In any case in which there has been an injury to the joint, a periarticular suppuration or deep intraoral ulceration, the movement of the jaw should be watched for months afterward. Any limitation of motion that persists or increases after the acute process subsides should be treated by gentle forced movement. In many cases a piece of rubber inserted between the jaws and allowed to remain for a short while several times a day will stretch adhesions and newly formed scars. An ordinary rubber bottle-stopper is very

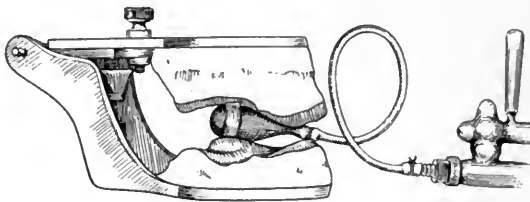


Fig. 255. Showing an apparatus, which was made for us by J. A. Brown, for a gentleman who had a strong fibrous ankylosis of long standing, and whose remaining teeth were loose. It consists of an upper and lower vulcanite plate which fit evenly over the gums and teeth. Between these is placed a small thick-walled rubber bag attached to an air-pump by a tube. Dilatation is accomplished by forcing air into the bulb. This is in use at present, and is accomplishing a satisfactory result. The bulb is held in place by a strip of elastic dam. The bulb must be made very thick and strong, and it must not touch the tongue or palate.

useful for this; another plan is the insertion, between the molars, of sections of a large laminaria uterine tent, which swells by absorption of saliva but which is soft enough not to injure the teeth. If this means is adopted, the surgeon should assure himself that the tent has not been impregnated with any antiseptic. If the scars are firm, but if on examination it is found that the jaw can be made to move a perceptible amount more than the patient ordinarily moves it, dilatation with rubber or laminaria tents should be tried as long as anything is being gained. This forced dilatation should not be brutal in its severity, for what cannot be gained by patient and gentle means, as a rule cannot be gained by excessive force.

In a few selected cases in which the adhesions are intra- or periarticular, wide excursion can be accomplished by forceful dilatation under an anesthetic, but this must be done with great care; for teeth may be pushed clear out of their sockets, or the jaw may be broken.

The latter accident may occur with little force in a delicately formed jaw where there is a deep socket of an unerupted third molar. Both of these accidents have occurred with us.

Where there are no teeth or where the teeth are loose in their sockets, some other plan of dilatation will have to be adopted (Fig. 255).

### OPERATIVE TREATMENT OF ORAL SCAR BANDS.

Narrow bands may be cut or dissected out, and the buccal mucous membrane can be stitched in such a way as to fill the gap that is left; but no permanent good can be expected from simply cutting dense adhesions, which leave a broad, raw surface to granulate. As the wound heals, it will contract, and the condition will be not in the least improved. The introduction of rings into these scars before cutting them, and other such tricks, are but poor substitutes for a proper operation that recognizes and eliminates the cause of the fixation. If, at the site of the attachment of the scars to the jaw bones, the buccoalveolar fornix is preserved above and below—that is, if, as is seldom the case, the scar is attached high up on the maxilla and low down near the lower border of the mandible—the operation proposed by Le Dentu will be more or less effective.

It consists in a submucous cutting of the scar band above and below at its maxillary and mandibular attachments. The mouth is then opened and held open until the cut ends of the scar band find new attachments lower down on the maxillæ and higher up on the body of the mandible. We have never performed the operation, because we have never seen what we thought an appropriate case. As a rule, the fornix is abolished, the band being attached at the gum margin, and too often, on removing or releasing the scar, it is found that changes have occurred in or near the joint that must be remedied before the mouth can be opened.

For all cases of closure of the mouth by intraoral scar bands, we prefer the following procedure, because, being based on good surgical principles, when properly done, it will disappoint neither the patient nor the operator.

### OPERATION BY FLAP TRANSPLANTATION.

The scar, or nearly all of it, is excised, and the soft tissues dissected from the periosteum of the jaws, above and below, to restore the natural depth of the cul-de-sacs. Scar that extends through the cheek to the face, especially at the corner of the mouth, is treated at the same time. To satisfactorily remove some intrabuccal scars, it may be necessary to turn up the cheek in the form of a flap by an

incision running from the angle of the mouth to the border of the jaw and then back along this border, as in operating for carcinoma of the inner surface of the cheek. This will be followed by paralysis of the depressor anguli oris muscle of this side, which does not cause a very noticeable deformity.

If one is certain that after removing the scar the nutrition of the lower lip will be preserved, the lip and chin can be split in the median line, and half of it turned aside with the cheek. We think its nutrition may be considered safe if the coronary artery is intact. In removing the scar from the inner surface of the cheek, the opening of Stenson's duct should be identified and preserved. The next step is to turn a flap from the neck (p. 219; Figs. 91, 195, 197) and suture it to

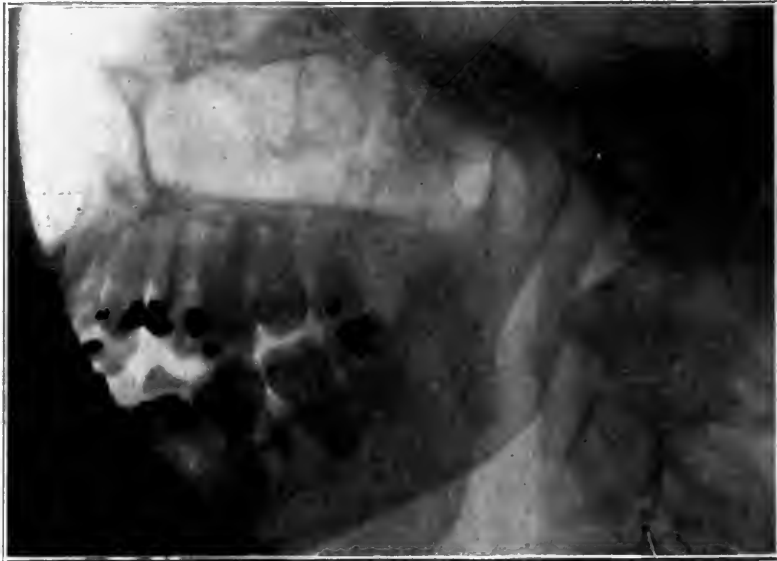

Fig. 256. X-ray showing condyle, coronoid process, and ramus in a normal joint.

the raw surface in the cheek instead of across the palate. Especial care should be taken to stitch the edge of the flap high up on the outer surface of the maxilla so as to be certain to restore the cul-de-sac. Later, scar contraction of the uncovered granulating surface of the bone will pull down the border of the flap and lessen the depth of the newly made fornix. If the raw surface entirely surrounds the opening of the parotid duct, a small hole is to be made in the flap, and the edges sutured around the mouth of the duct. If the opening of the duct cannot be identified, drainage through the flap must be provided. Otherwise healing will be complicated by having the space between the flap and the cheek fill first with saliva and then with pus and saliva.



The epithelial lining of the cheek having been restored, any deformity or deficiency of the cheeks or lips is repaired by flaps that were planned before the operation.

After ten days, if extensive primary union of the transplanted flap has occurred, after a longer period if one is not certain that the new blood supply is ample, the base of the flap is cut, and the defect in the neck repaired. If, after the scar has been removed and the resulting defect filled by a well-nourished flap of skin and subcutaneous fascia, the mouth can be opened a desirable distance, the surgeon may feel satisfied that the contraction will not return. The transplanted skin

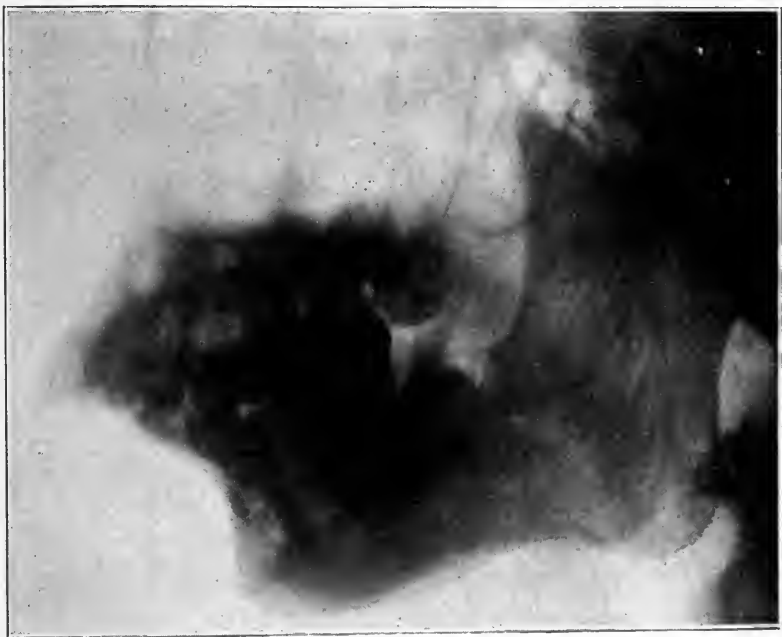

Fig. 257. X-ray showing true bony ankylosis of the joint.

soon takes on an appearance somewhat resembling the mucous membrane, and in our experience has never shown any irritation in its new location. If, after excising the scar, it is found that the mouth cannot be opened sufficiently, an operation on the joint will be required. The patient should be cognizant of this possibility before the first operation is performed. An operation that restores movement at the natural joint site seems to us better surgery than an excision of a section of the ramus or the body. The one to be described, besides restoring the function to a greater mass of the muscles of mastication, is followed by no visible scar.

It consists in freeing the ramus from the base of the skull and inserting between the bones a flap of subcutaneous fat-bearing fascia.

Before operation it should, if possible, be determined whether the joint damage is one-sided or bilateral. This may usually, but not always, be ascertained by good negatives (Figs. 256, 257). It has been our observation that, in an unilateral close fibrous ankylosis, in attempting to open the mouth, the chin deviates to the ankylosed side. This is due to a slight twisting motion at the damaged joint, while the uninjured condyle travels on an arc with the other one as a center.

### OPERATIONS FOR ANKYLOSIS OF THE JAW.

The hair is shaved to a point 5 centimeters above the level of the ear and back to the level of its posterior border. The parts, including

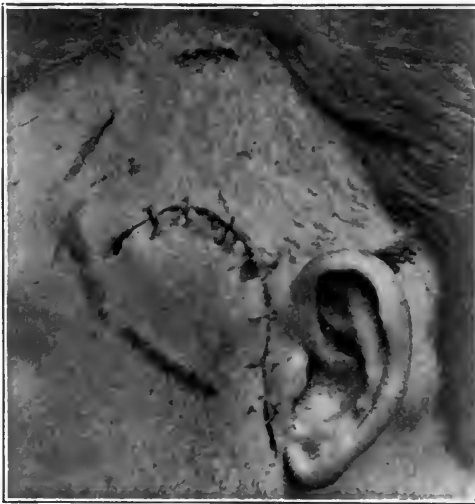

Fig. 258. Showing line of incision for excision of the temporomandibular joint. The area within the broad pencil marks was temporarily anesthetic afterward.

the remaining hair, are cleansed, and in women the hair is braided so as to draw it away from the field of operation. After the final preparation of the skin, the hair in the neighborhood is plastered down with sterile adhesive plaster. Before applying the sterile cloths, the incision is outlined with the point of a knife. This incision extends from in front of the lobe, upward just in front of the ear to a point 1 centimeter above its upper free border. From here it curves forward and then downward to a point  $2\frac{1}{2}$  centimeters directly in front of the upper end of the attachment of the ear (Fig. 258). After this incision is outlined, the field is protected above, behind, and below by sterile cloths that are pinned in place, but the whole of the facial distribution

of the seventh nerve should be left entirely within the operator's unobstructed view. The anesthetic had best be carried on by a spraying ether vapor.

The incision already indicated is carried through the skin only, and the skin flap thus outlined is dissected downward, retaining with it only sufficient tissue to insure its nourishment; the subjacent superficial fascia is to be used in making the new joint.

The second step consists in incising the superficial fascia down to the temporal and parotid fasciæ and the zygoma along the line of the skin-cut, dissecting it up from the subjacent tissues to the same extent as the skin flap. In doing this, only the posterior three fourths of the incision in the superficial fascia should be made at first, as the anterior end of the incision will cross the branch of the seventh nerve that sup-

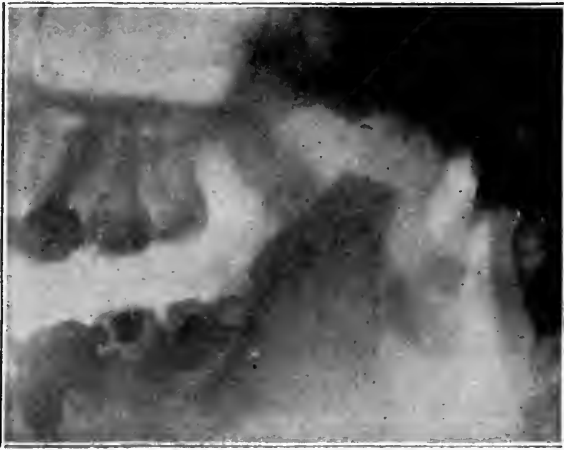

Fig. 259. X-ray showing condition after the condyle and coronoid process are removed for ankylosis.

plies the anterior belly of the occipitofrontalis muscle. This flap should contain the temporal artery to insure its vitality. In extending the incision forward, a section of fascia should be grasped sharply in a pair of pointed artery forceps before being cut. If a motor nerve is sharply pinched, there will be a contraction of the muscle it supplies. If necessary, the fibers to the occipitofrontalis may be cut or stretched, but on no account should fibers to the orbicularis palpebrarum be disturbed.

The posterior part of the masseter, with the fascia covering it, is to be freed from the zygoma, and the muscle dragged downward and forward with a small, strong, hooked retractor. This will expose the site of the joint, which may be found surrounded by dense adhesions or an overgrowth of bone, or there may be a true ankylosis.

If by cutting the periarticular bands the mouth can be opened and the interior of the joint appears normal, this might be all that would be needed, but we have never encountered such a case. Usually the condyle will have to be resected, or the bony connection dug out with grooved chisels and a small rongeur (Fig. 266). To one accustomed to



Fig. 260.

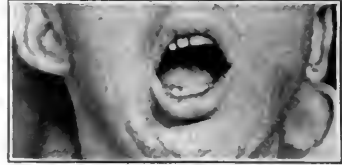

Fig. 261.

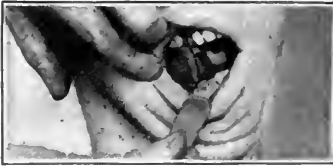

Fig. 262.

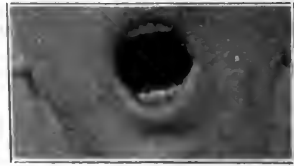


Fig. 263.

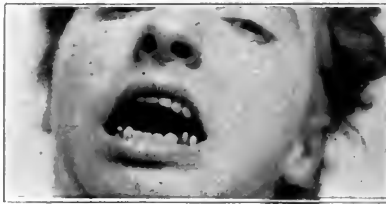

Fig. 264.

Fig. 260. Showing opening of the jaws in a case of fibro-osseous ankylosis in a young man 22 years of age, in whom the joint on one side had been injured 11 years previously by the kick of a mule. The movements of the jaw had gradually lessened until the opening between the incisor teeth was 1 centimeter.

Fig. 261. Same case as shown in Fig. 260, after excision of the joint. Opening between the incisor teeth 24 millimeters.

Fig. 262. Case shown in Fig. 260, immediately after operation. Mouth held open with a pine block.

Fig. 263. Case shown in Figs. 260-262, one year and nine months after operation. Opening between incisor teeth 35 millimeters.

Fig. 264. Showing opening that was obtained in a case of single complete ankylosis, after cutting the ramuli and drawing forward the body. Later this opening decreased, and the ankylosed joint was reconstructed with a permanent good result.

work with them, burs driven by an engine would do effective work, but it is to be remembered that the internal maxillary artery and part of the third division of the fifth nerve lie immediately subjacent to the bone (Fig. 259).

The serious question has occurred to us, in removing both condyles simultaneously, of the possibility of the masseter and internal pterygoids

drawing the mouth permanently open. In one case of a five-year-old child we removed both condyles at the same time, and the child closes its mouth perfectly. Simple excision of one or both condyles for ankylosis is an old operation and, as far as we know, has not been followed by inability to close the mouth.

A true ankylosis will usually obliterate the sigmoid fossa and involve the coronoid process. If possible, a part of the insertion of the temporal muscle should be preserved, but this is rarely the case. The

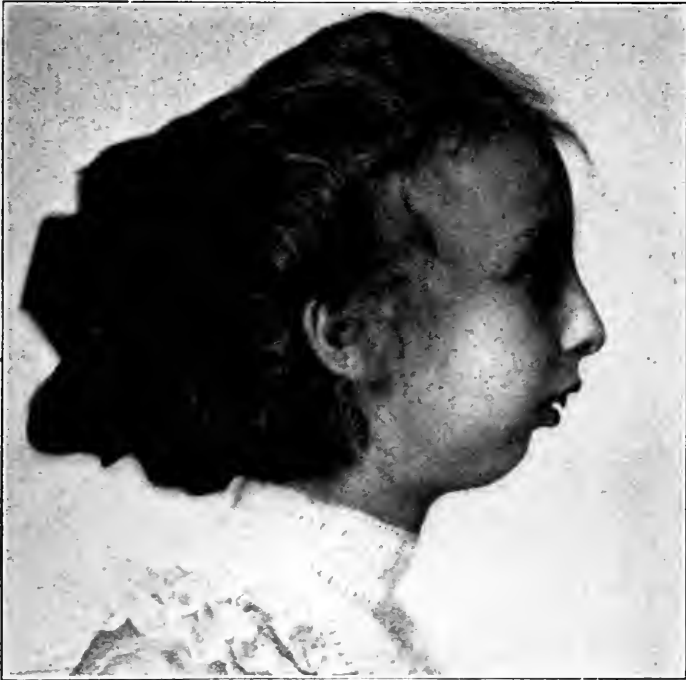

Fig. 265a. Shows girl of 16 years, in whom, as a result of an infectious arthritis, there was an almost complete fibro-osseous ankylosis of the right side—first noticed at 3 years. At 16 years she had an opening of 3 millimeters on the right and of 4 millimeters on the left in the cuspid region. The right condyle was excised, and a new joint made. The left ramus was sawed in two, and the body dragged forward and wired in its position. Later a piece of her seventh costal cartilage was implanted in front of the mental part of the body of the jaw. Shortly after unwiring the jaw, she had an opening of 18 millimeters.

ankylosis having been freed, the mouth is opened. Even where there has been no injury or disease of the joint of the opposite side, this may not be easy and may require a strong dilator. Judgment must be used; for it is in just such a case that the jaw may be fractured or several teeth pushed out. If the mouth cannot be opened, the operation must be repeated on the other side. A 2-centimeter space between the cuspids is a practical amount. If the jaws are forced too wide apart, the muscles of mastication might be injured beyond recovery.

If the bony and ligamentous resistance has been overcome, the amount of the opening will subsequently increase with use (Figs. 260-264). The joint is made permanent by suturing the flap of superficial fascia to some soft tissue at the bottom of the defect, left after removing the condyle. Before doing this, hemorrhage must be controlled so as to obtain a clear view. The artery, vein, or nerve might be injured in passing this suture. If the original incision has not been carried sufficiently high on the temple, the facial flap may be too short; it could be lengthened by cutting downward in front, but injury to the palpebral



Fig. 265b. Case shown in Fig. 265a, eight months after first operation. She has an opening of 22 millimeters, has gained considerably in weight, and her general appearance and mode of dress show her improved disposition.

fibers of the motor nerve must be avoided. If the flap is absolutely too short, the zygoma may be cut, and a section of the temporal muscle substituted for it. The flap having been sutured into the new joint, the skin wound is closed with a rubber dam drain extending to the depth of the new joint and let out in front of the tragus. This drain should be sutured to the skin. Usually our next step is to fix the mouth open by wiring a smooth block of pine wood between the molars on one side, that will separate the jaws about 2 centimeters. This will cause some discomfort, but will insure a free opening. The patient will be able to close the jaws within twenty-four or forty-eight

hours after removal of the block. A free motion will develop and will increase with time. If there is the retraction of the chin that always accompanies a very early ankylosis, the ramus is sectioned on the sound side, and the body is drawn forward and held in place by wiring the upper to the lower teeth (Fig. 38). At the end of ten or twelve weeks the wires are removed, and the opening gradually restored with rubber wedges (Figs. 265a, 265b).

As with any operation around the parotid gland, a temporary paralysis of the muscles supplied by the seventh nerve may follow, becoming




Fig. 266. Showing cavity remaining after removing ankylosed condyle. Also flap of fascial tissue that is to be sutured to the bottom of the cavity.

evident within the first two days. This is chiefly evidenced by the eye remaining open while asleep. It should not cause worry, for, according to our observation, it always disappears in three to five weeks. Paralysis due to direct injury of the nerve comes on immediately. If one were unfortunate enough to cut the whole supply of the orbicularis palpebrarum, the nerve should be sought and sutured immediately. In one case we had a partial injury to the nerve supply of the muscle, but ability to completely close the palpebral fissure was restored within six months.

## CHAPTER XXII.

### EXTRACTION OF TEETH.<sup>1</sup>

The primary causes which lead to the extraction of teeth may be summed up as follows:

1. The ravages of dental caries that are beyond repair.
2. Diseases of the alveolar process: viz., tumors, pyorrhea alveolaris, alveolar abscess, etc.
3. Irregular position of the teeth. This will include cases which require removal of the teeth preparatory to correction of deformity of the jaw-bone.
4. Impaction of the teeth.
5. Accidents to the teeth or their surrounding structures.

These various indications hold good for permanent as well as for temporary teeth. The extraction of temporary teeth is indicated when they are so affected with disease that they cannot be restored artificially; a simple inflammation of the pulp should never be the reason for its extraction. The irrational extraction of temporary teeth frequently causes irregularities of the coming-in permanent set, which cannot be corrected by future treatment (Fig. 215).

Before undertaking the extraction, the field should be cleaned, and adhering deposits are to be removed. The painting of the soft structures within the immediate neighborhood with tincture of iodine is to be recommended. If a forceps is used, it should never engage the soft tissue; the overhanging soft gum tissue should be removed with a knife or tissue elevator prior to the extraction proper. The forceps must engage the tooth firmly; both combined form a lever. The extraction should be carried out slowly and always in the line of least resistance. If a tooth root should break, an effort should be made to remove the remaining part at once; but very small fragments left in a non-infected socket may eventually become absorbed or thrown off.

The instruments employed for the extraction of teeth are forceps, elevators, screws, and in different cases, the chisel and mallet. A very large variety of forceps and elevators have been devised, but a few well-selected instruments will suffice for all but very extraordinary cases. Dental forceps are made after two general patterns:

<sup>1</sup> For the selection of the types of forceps and elevators presented, and for the rules to be followed in normal extraction of the individual teeth, we are indebted to Dr. Herman Prinz.



the English, or knuckle joint; and the American, or interlocking joint. The English pattern of forceps is to be preferred, as it will not obstruct the view of the field of operation and is not so liable to catch the soft tissues of the lips.

For the extraction of the upper ten anterior teeth,—viz., incisors, canines, and bicuspid,—one single forceps is usually sufficient (Fig. 267). The upper first and second molars require a special forceps



Fig. 267.



Fig. 268.



Fig. 269.



Fig. 270.



Fig. 271.

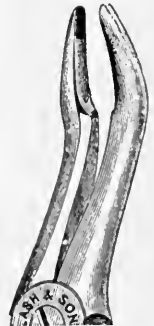

Fig. 272.

Fig. 267. Forceps for the ten anterior upper teeth.

Fig. 268. Right and left upper molar forceps.

Fig. 269. Bayonet root forceps.

Fig. 270. Hawk-bill forceps adapted to the removal of the lower ten anterior teeth.

Fig. 271. Hawk-bill forceps for lower molars.

Fig. 272. Slender bayonet forceps for upper root extraction.

(Fig. 268) for either side, on account of the shape of the roots. For the extraction of the upper third molars (Fig. 269), a heavy-patterned root forceps is well adapted. The lower ten anterior teeth may be readily removed with one forceps of the general shape of the hawk-bill pattern (Fig. 270). For the lower molars on either side a hawk-bill forceps with suitable modification of the beak is suitable (Fig. 271). Both lower third molars may frequently be removed with this same forceps; however, an elevator is, in most cases, best adapted

for such purposes. The roots of all the upper teeth may be removed with a forceps which is built upon the principle of a slender bayonet style (Fig. 272). For the extraction of the roots of the lower teeth, the same forceps (Fig. 270) which is employed for the removal of the lower anterior teeth may be used with advantage. A few elevators for the extraction of upper and lower stumps or misplaced teeth are very serviceable. Some suitable patterns are illustrated in Figs. 273, 274. A most suitable instrument for the removal of an impacted lower third molar is the Lecluse elevator (Fig. 275).

Regarding the position of the patient, it is well to bear in mind that the light on the field of operation must not be obstructed; consequently, the patient should face the source of light. For the removal of the upper teeth, the patient is seated on a high chair, head leaning slightly backward; while for operations about the lower teeth, a low

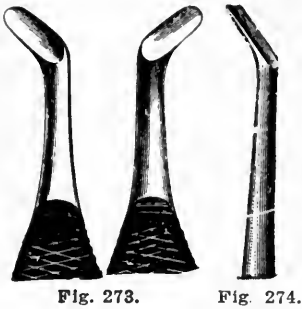



Fig. 273. Right and left elevators for removing stumps of lower roots.  
 Fig. 274. Bit of universal stump elevator.  
 Fig. 275. Lecluse elevator.



chair is to be preferred. The operator usually stands on the right side of the patient, the right hand firmly grasping the forceps, while the left hand is employed to draw the soft tissues well out of the way. In using the hawk-bill forceps for lower teeth on the left side of the mouth, the operator should stand on the left side, slightly in front of the patient.

When under ether, the extractions are made in the recumbent position.

In applying the forceps to any tooth, one beak is first placed on the palatal (or lingual) side. The tooth is then grasped by slightly closing the handles of the forceps, and the instrument is pushed up (or down) as far as possible under the gum. The sharp edges of the beaks may be pushed even slightly under a weak alveolar process, and a firm grasp of the root is thereby readily obtained. This is

of especial importance in the extraction of teeth, the crowns of which have been weakened by decay. If the forceps grasp the crown, it is very apt to be crushed, and the extraction of the root is made difficult; but if the crown, be it ever so delicate, is used as a guide for placing the edges of the beak well down on the neck or upper part of the root, success in extracting the root is more likely to follow. An effort is now made to slightly rotate the tooth, or slight lateral motion is applied. Rotation of the single-rooted teeth is usually successfully accomplished, while the molars require a definite lateral motion, usually first inward, which is followed by an outward and downward (or upward) movement. Care should be exercised in not applying too much force laterally, as the tooth may readily break. The extraction of teeth is not a matter of applying crude force; delicate movements of the whole hand governed entirely by the wrist are the essential features of this operation.

The above armamentarium is very small compared with the number of kinds of instruments that have been devised for the extraction of teeth. It is, however, proper to state that one pattern of forceps may be used for almost every extraction. This is especially the case when a general anesthetic is used; then the surgeon can go back and extract roots that may have been fractured. One, patterned after the heavy bayonet forceps shown in Fig. 269, is very useful for universal application.

### REMOVAL OF THE INDIVIDUAL TEETH.

The removal of the temporary teeth is usually accomplished without much difficulty. Children require careful handling; kindness and persuasion will do more with an unruly child than roughness and display of temper. The root forceps and the elevator are the usual instruments employed in the extraction of temporary teeth. In deep fractures of the root, a small brass wood-screw, screwed in the root canal and then grasped with a flat-nosed plier, is often extremely serviceable. These roots must be extracted without lateral motion in a straight line in the direction of the long axis of the root. The upper first bicuspid breaks more often than any other tooth, on account of the often thin, flat roots. Usually this root is bifurcated at its upper half, and consequently it should not be rotated during the process of removal. The canine is the strongest single-rooted tooth in the mouth, and frequently great force is required in its luxation. Slight rotation is always indicated whenever possible. In the extraction of the first and second molars slight palatine and buccal motion is essential for their luxation; the final removal should take place in a downward and outward line. The third upper molars, if not misplaced, are usually

very easy to extract. The mouth should not be opened too far; otherwise the tightly stretched muscles will obliterate the field of vision. The last upper molar is frequently misplaced, usually posteriorly or buccally, and its roots are often curved posteriorly and frequently united together. However, three—sometimes four, and very rarely five—slender single roots may be present. If the tooth can finally be engaged by the beaks of the forceps, usually no difficulty is experienced in its removal (very slight lateral motion is essential, and it should always be taken out in the direction of the long axis of the crown). Under no condition should an elevator be used for the removal of this tooth, as the maxillary tubercle will very readily break when power is brought against it. If the tooth fractures at the neck, it is often necessary to separate the roots by means of a chisel and mallet; this procedure is preferable to trying to extract all of the roots with the forceps at once, which usually results in crushing them. In forcing the root forceps high up into an alveolus in this region, special care is necessary to prevent the pushing of the root into the antrum.

The lower incisors and canines are readily removed by firmly grasping them in the hawk-bill forceps and tilting labially; the thin alveolar process on the labial side will yield to pressure, and the teeth can be taken out without much force. The lower bicuspid are loosened by a slight lateral motion and by slight rotation. They are single-rooted, and consequently, little danger of fracturing their roots is experienced. To extract the lower molars on the right side, the operator stands back of the patient, while, when operating on the left side, he occupies a position on the same side, slightly toward the front of the patient. The lower molars usually have two distinct roots; consequently, these teeth cannot be rotated in their sockets. A slight lateral motion is possible, although a heavy external and internal oblique bony line may offer much resistance.

Great difficulty is frequently associated with the removal of the lower third molar tooth. If the tooth is normally erupted,—if it is in perfect alignment with the other teeth,—it is easily extracted with the forceps, or the Lecluse elevator. The roots of this tooth may be separate, but more often they are united in a cone; and they are almost always curved posteriorly. As a consequence, the movement of luxation should be antero-posteriorly so as to avoid breaking. If the elevator is employed, the operator places himself back of the patient when the right tooth has to be taken out, and near the left side for the extraction of the left tooth. The sharp point of the elevator is inserted between the second and third molar, the flat side facing the last molar, while the oval side is placed against the second molar, which acts as a fulcrum. The point is pushed downward and inward

and slightly forward between the teeth. Forward and downward pressure is exerted on the handle, so as to loosen the tooth and lift it out in a semicircle, lifting the crown toward the ramus of the mandible.

If the first molar is missing, it is well to place a wedge between the remaining teeth, so as to prevent the possible luxation of the second molar. This wedge may be cut from a piece of soft pine wood, or a piece of softened dental modeling compound is pressed into the space, removed, chilled, trimmed, and replanted. During the extraction, this wedge and the second molar are held in place by the fingers of the left hand. Before making an attempt at removal of an impacted lower third molar, it is essential to cut away all overlining gum tissue so as to expose the crown as fully as possible. All overhanging bone structure must be cut away with chisels or burs; otherwise the tooth is sure to break, or—in rare instances, if too much force is employed with an elevator or, more so, with the old style Physick's forceps—fracture of the jaw at its angle may take place, or avulsion of the two molars may occur. The x-ray is of the greatest importance in diagnosing these malposed teeth. In rare instances—viz., in such cases where the third molar has assumed a horizontal position and is pressing against the second molar below its crown—it is advisable to remove the second molar. When this source of irritation is removed, usually no further disturbances of the misplaced molar are to be expected, as there is now sufficient room for its forward movement. While this method of surgical procedure is objected to by some operators, it has, nevertheless, given excellent results in a number of cases, which otherwise meant serious complications.

### IMPACTED TEETH.

A tooth is spoken of as being impacted when its eruption is partially or wholly obstructed by bone or by some other teeth. This may occur in the anterior part of the jaw, when the crown of a misplaced tooth impinges against the root or crown of some other tooth. The most common example of a misplaced tooth is an upper canine tooth situated in the palate. Occasionally a permanent tooth remains impacted because its preceding deciduous tooth for some reason fails to be thrown off (Fig. 283).

The teeth that are most frequently impacted are the third molars, which, in most instances, is probably due to a disproportion between the size of the jaw-bone and the dental arch. A third molar may remain entirely buried in the bone, or its complete eruption may be prevented by one cusp pressing against or locking under the crown of the second (Figs. 276, 277).

**Indications for Treatment.**—An impacted tooth should not be

removed without some special indication; such a tooth might erupt and become serviceable after the superimposed tooth is lost. In some cases, such as neuralgia or an infection around the unerupted tooth, the indications for removing an impacted tooth are very evident. In other cases, impacted teeth are removed on account of some symptoms present that might or might not be dependent upon the impaction, but about which an exact diagnosis cannot be made.

**Treatment.**—An impacted tooth may be treated in one of three ways, according to the circumstances of the individual case. One is to remove the obstructing tooth, thus allowing the impacted tooth to erupt. Another plan, practical in some cases in which the impacted tooth belongs to the anterior part of the arch, is to move the obstructing tooth or teeth by orthodontic appliances and to allow the impacted

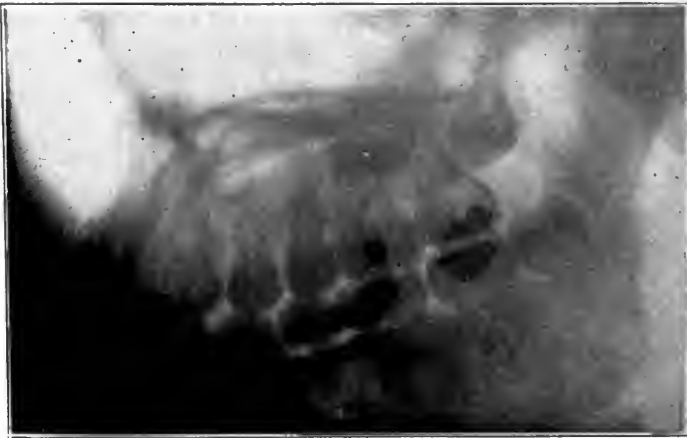

Fig. 276. Impacted upper third molar.

tooth to erupt. The third plan is to remove the impacted tooth. Removal of the obstructing tooth is indicated: if the latter is a deciduous tooth, or if it is diseased and there is reason to believe that the impacted tooth will become serviceable. Very frequently, in the case of an impacted third molar, the obstructing second molar is removed. This may be primarily because of the difficulty of removing the third molar, or because of damage that the second molar has suffered from pressure upon its root by the third molar. Removal of the second molar for impaction of the third is an old practice and often a very good one. Shifting of the obstructing teeth is indicated in young persons, when the obstruction is due to a contraction of the dental arch.

**Removal of an Impacted Tooth.**—When it is not desirable to remove the obstructing tooth, the impacted tooth may be removed in one of two ways. The area of bone beneath which the impacted tooth

is situated is exposed by turning back a semilunar flap of muco-periosteum, with its base toward the palate or toward the body of the jaw-bone. It is somewhat customary in cutting down upon a tooth, or foreign body in any part of the body, to make a linear incision directly down upon the object, but a clearer view and a larger operative field will be obtained by making a semilunar cut and turning back a flap that will freely expose a sufficient area of bone. After exposing its neck, the tooth may be cut in two with a fine drill or a cross-cut fissure bur. After doing this, it is usually easy to remove first the crown and then the tooth with forceps. The section of a tooth, especially a cuspid, is frequently a tedious process, and it is usually a much quicker operation to remove the thinner layer of superimposed bone and lift the tooth out somewhat laterally. This can be done by the use of small gauges and bone burs, but an equally or more satisfactory operation can be done, often in a few minutes, by removing



Fig. 277. Impacted lower third molar which has been released by the extraction of the second molar. This was in a patient over forty years of age, and the root of the second molar was eroded by the pressure of the third molar. This caused an intense neuralgia, for which the patient sought relief. The third molar has since erupted.

the bone from over the full length of the root with a few bold strokes with a fair-sized grooved chisel. In many instances, an impacted third molar can be removed with a Lecluse elevator after carving out a cavity above in the base of the ramus, but if an anterior cusp is locked within the constriction of the neck of the second molar, then the excavation in the ramus must extend beyond the apices of the roots, before the engaged cusp can be liberated.

**After-treatment.**—After removing an impacted tooth, if the remaining space is large, it may be filled with a light packing, which may also be placed under a semilunar flap. This will control hemorrhage. This packing may be removed in one, two, or three days, after which no special treatment is required. If a large piece of the alveolar process is broken loose, this should be pushed back into place.

If the antrum is freely opened, in the extraction of an upper molar, it might be washed out with saline for a few days afterward.

## CHAPTER XXIII.

### INFECTIONS AND INFLAMMATIONS OF THE MOUTH.

The question arises whether a systematic review of the diseases of the mouth should be presented in a work on surgery; but as many of them are best treated by surgical means and any one of them may influence a surgical result, we do not believe the best work can be done without at least the ability to recognize the various lesions that may appear, even though many of them are strictly non-surgical.<sup>1</sup>

The mouth is subject to a great number of diseases, some of which are purely local, while others are local manifestations of a general disorder. However, even among the diseases that are caused by local infections, there are very few but what are more or less dependent upon, or are influenced by, the state of the digestion or metabolism of the individual.

The close relation that exists between diseases of the digestive tract and irritations of the mouth is probably explained by the fact that toxins absorbed from the stomach and intestines are partially excreted in the saliva, and that much of the septic material of the mouth finds its way to the stomach and intestines.

It is not too much to assume that every disease has one or more specific causes. Those of which the cause is known are classified accordingly. At present there are still many, recognized only through their symptoms, and these, like tumors, have to be classified according to their lesions. This symptomatic arrangement is far from satisfactory; for in some instances the changing complex carries a case from one classification into another. The result is that in some instances a number of different affections are placed under the same heading, while in others the different clinical manifestations of the same disease are called by as many different names. Because our clinical practice does not always keep pace with our knowledge, different diseases with known causes may still be grouped under one heading, if their symptoms are somewhat similar. Thus, we still find it convenient to speak of a phlegmonous stomatitis, referring to certain symptoms that we know are produced by some kind of a pus-producing organism, in spite of the fact that it is possible in almost every instance to determine the exact nature of the infection by a microscopical examination.

<sup>1</sup>In writing this chapter, we have consulted several of our friends who also have frequent opportunities to observe mouth lesions. We have drawn upon Butlin, Bruck, and Pfaundler and Schlossman, as well as upon our own observations.



A strict categorical arrangement of mouth lesions is not easy to make, and if the plan were followed to its ultimate possibilities, the attempt might land one in the predicament of the man who differentiated 97 varieties of pemphigus.

In the following, all diseases known to be due to a specific infection are classified accordingly, but the various recognized symptoms that appear without recognized cause, or which we know may be due to one of a number of causes, are classified according to the most prominent characteristic of the lesion.

### STOMATITES.

**Acute Catarrhal Stomatitis.**—Under this head should be included all acute inflammations of the mouth, characterized by simple redness and soreness of the mucous membrane. They may be caused by the irritation of cutting teeth, by thermic or chemical irritants, by spices, alcohol, or tobacco, or by disturbances of the digestion, or metabolism. They may be but a local manifestation of some general disease, drug or mineral poisoning—such as mercury, lead, or iodine.

As a rule, a dusky-red color precedes an indistinct grayish-white filmy discoloration due to cloudy swelling of the epithelium. After desquamation, the mucous membrane remains intensely red. The patient complains of discomfort, especially on eating hot or spiced foods, and this may be a reason for children refusing to eat or nurse.

The sense of taste is diminished, and the tongue is furred. The flow of saliva is usually increased, but the mucous membrane may be rather dry. The whole mouth may be affected, or it may be limited to the gums, the neighborhood of the oval or lingual tonsils, or to some other part.

The prognosis will depend entirely upon the cause. Most cases heal quickly without treatment, while others may go on to a chronic form. The latter are dependent upon some persistent defect in the digestion or metabolism, or some other continuous irritation.

The treatment consists in control of the cause, abstinence from irritating foods, possibly the administration of a purge, attention to the digestion, and the use of some alkaline wash, such as the alkaline antiseptic solution (N. F.), diluted with three parts water.

In bottle-fed infants, special care should be given to the cleanliness of bottles and nipples.

**Method of Washing a Baby's Mouth.**—The proper method of applying a lotion to a baby's mouth is a matter of importance. It is questionable if the prevalent practice of daily washing babies' mouths is necessary or even commendable. If a lotion is to be applied to a baby's mouth, it should be done as follows:

The infant is turned face downward on the nurse's lap. The finger of the nurse, covered with cotton which is wet with the lotion, is placed in the baby's mouth, and he is allowed to champ upon it. In this way no mechanical damage will be done. It is needless to say that the medicament should not be poisonous. If the baby objects, the solution may be sweetened.

**Chronic Stomatitis.**—This is often found in persons who neglect their teeth, especially users of alcohol, tobacco, and overspiced or overheated food.

The affected part of the mucous membrane is usually somewhat drier than normal, in some cases so dry as to cause discomfort and difficulty in swallowing. It may be slightly infiltrated or atrophied; in the latter case the dilated blood vessels will be apparent. There may be salivation or disturbance in taste.

Chronic stomatitis is very resistant to treatment. Often little can be done toward a permanent cure. The symptoms can be relieved by the withdrawal of the irritants, the use of an alkaline antiseptic mouth wash, and the occasional painting of the affected areas with a 2 per cent silver nitrate solution.

Chronic or subacute gingivitis arising during pregnancy usually subsides at time. Leucoplakia may arise in any part of the mouth, but is most common in the tongue (see p. 442). (For septic or phlegmonous stomatitis, see p. 340.)

Exudative stomatitis is characterized by the formation of serous, seropurulent, or hemorrhagic blebs or bullæ, or by a fibrinous exudate. An eruption of vesicles occurs in herpes and pemphigus, after scalds or burns, erysipelas or a mouth disease, or smallpox and chicken-pox, while a local fibrinous exudation may among other causes be due to the staphylococcus or the streptococcus.

**Herpes.**—Among the causes enumerated are digestive disorders and some acute infections, such as coryza, grippe, pneumonia, malaria, epidemic cerebrospinal meningitis, etc. In some cases the eruption comes without any assignable cause; in some it accompanies specific fever; in others, some digestive disturbance; while alcohol seems also to be a causative factor. Recurrent herpes of the tip of the tongue is seen in syphilitics. Regardless of the cause, herpes of the face and mouth seems to be a trophoneurosis of the fifth nerve.

It has its counterpart in the herpes zoster that is distributed over the course of an inflamed nerve in other parts of the body. The lesion consists of a crop of vesicles varying from the size of a pinhead to almost any size. They occur most frequently on the lips, often in conjunction with herpes of the face, but they may come on the inside of the cheek or on the tongue, palate, or pharynx. The vesicles always

occur in clusters, and their appearance is often accompanied by fever. At first the content of the vesicles is a clear fluid, but later it becomes turbid. On the lips and face they tend to dry up in a few days, leaving little crusts which are renewed when disturbed. In the mouth the vesicles always burst early. The covering of the vesicle forms a pellicle which can be detached, leaving a small circular excavation, which is at first blood-stained and later becomes yellow. They are surrounded by a well-marked red zone. The pellicle is composed of the corneous layers of the epithelium, thickened by infiltration.

Herpes of the lip gives but little discomfort, but herpes within the mouth may be accompanied by great pain, which is worse during the act of eating. In most cases an attack lasts but a few days, but especially in the mouth, it may have a marked tendency to recur. Rarely it is both persistent and painful and may be the cause of ill health from pain, loss of sleep, and lack of food. Most cases require little treatment. A soothing lotion or ointment may be applied. Butlin, acting upon the theory that recurrent cases were due to an infection, uses an active antiseptic treatment from which he has obtained the best of results. In one persistent case, accompanied by great pain, he had the parts thoroughly dried, and then, with a clean, soft rag, a mixture of carbolic acid, spirits of chloroform, tincture of myrrh, and cologne water was rubbed into the surface frequently. The pain of the first few applications might be relieved by previously painting the surface with a weak cocain solution. If the benefit from this application is due entirely to its antiseptic value, the same result might be obtained from a 2 per cent solution of silver nitrate or chromic acid, or a 10 per cent formol solution.<sup>2</sup> Though a most powerful and at the same time a penetrating antiseptic, its application to a raw surface is rarely justified without a previous application of cocain.

Butlin refers to good results in one severe case from rubbing in an ointment of:

Cocain, gr. v.

Boric acid, gr. x.

Vaselin, ℥ii.

Lanolin, ℥vi.

The tongue is dried before each application. This can hardly be considered an actively antiseptic preparation.

**Pemphigus.**—It is not known, when occurring in the mouth, whether this is a pure trophoneurosis or an infection. Clinically, a number of lesions on various parts of the body, characterized by the formation of large bullæ, is called pemphigus. According to Crocker,

<sup>2</sup>A 10 per cent formalin solution is a 4 per cent solution of formaldehyde, which is made by adding one part of formalin or formol to nine of water.

Martins made as many as 97 varieties and subdivisions. Under these headings must have been included a number of different diseases and infections. It appears generally in the mouths of middle-aged or elderly persons and first shows itself in the form of bullæ, which often escape observation. On the soft palate or cheek, not so frequently on the tongue, there are seen grayish or yellowish excoriations with the pellicle of bursted epithelium still clinging to them. There is salivation, pain on swallowing, and an abominable fetor. The lesions heal without scar and have a tendency to recur. Elderly persons may be very much depressed by the disease. The local treatment is similar to that of herpes.

**Aphthous Stomatitis or Mucolofibrinous Stomatitis.**—The latter term is proposed by Pfaundler and Schlossman, as a contraction for Frankel and Krause's more elaborate one of stomatitis fibrinosa maculosa disseminata, because the word aphthæ simply means inflamed, and the term has in the past been applied to a variety of lesions. Aphthæ is now recognized as a contagious disease. It comes with fever and appears as spots or plaques, varying in size from a pinhead to a pea. They are at first vividly red and later somewhat whitish or yellowish, and are surrounded by a red area of infiltration. They appear in various parts of the mouth, especially in the vestibule, fornicæ, and floor. In some cases the more posterior parts of the mouth and tonsils are affected. The spots may be scanty, or very numerous and multiply themselves. They form several crops and have a tendency to coalesce. The eruption is not vesicular, but is from the first onset a fibrinous exudation, which is deposited within the epithelium itself. The plaques increase for the first three days and are accompanied by salivation and considerable pain. The neighboring lymph nodes become enlarged, and there is a decided fetor. The exudate then shrinks and is discharged, leaving red spots, which gradually disappear, leaving no scar.

The treatment consists in fresh air, administering to the comfort of the patient, proper feeding, attention to the digestive tract, and the use of an alkaline antiseptic mouth wash.

Infants may be given a teaspoonful of a  $\frac{1}{2}$  per cent solution of potassium chlorate every two hours. In persistent cases the spots should be touched with a 2 per cent solution of silver nitrate once or twice a day. The attack may be severe, and the patient may have considerable depression.

**Pellagra.**—Pellagra is accompanied by a chronic stomatitis in most cases. Pellagra is characterized by a chronic sunburn-like dermatitis on the hands and face, most cases showing a definite pigmentation. It is accompanied by diarrhea, general weakness, and mental symp-

toms, varying from melancholia to mania. It lasts from months to years, showing acute exacerbations in spring and fall, and at present usually terminates fatally.

Fordyce's disease is the name given to a distention of the sebaceous follicles which occur on the mucous surfaces.

Erythema multiforme also occurs in the mouth.

**Lichen Planus.**—The eruption in the mouth consists of plaques which appear in the form of white dots, of patches and streaks, or of a white milky network. In some instances the plaques are discrete, and in others united by an indurated base. It is most common on the flexor sides of the forearms, lower abdomen, waist, calves, ankles, and mucous membrane. Hardaway states that it never occurs on the face. When it occurs in the mouth, it has been confused with leucoplakia (see p. 444).

**Bednar's Aphthæ.**—This name has been given to certain usually definitely localized excoriations of the posterior part of the hard palate of infants, which become covered with a fibrinous exudate due to a pus infection. The lesion usually consists of larger or smaller symmetrically placed ulcers, situated on each side of the posterior part of the hard palate. Between these there is often a long, narrow ulceration corresponding to the median raphe. The two laterally placed ulcers may join the median longitudinal one, giving the general outline of a butterfly with outspread wings. However, the shape and location of the lesion is accidental, and similar ulcers might be produced in any part of the mouth. It may result from mechanical efforts at cleansing the mouth.

The destruction of the epithelium is due to a necrosis which opens both lymph and blood vessels. This may open the way to a general infection. In infants with a single cleft palate who have been allowed to champ on a nipple, it is rather common to see a long yellow streak on the oral part of the nasal septum, from the habitual use of a pacifier or a nipple that rests against the hard palate.

Treatment consists in the withdrawal of the irritant and in painting the ulcers daily with a 2 per cent silver nitrate solution. Cure usually results in a few days.

**Mineral Poisons.**—Mercurial stomatitis is the most common of the toxic inflammations of the mouth. Bismuth poisoning will produce a similar condition, while phosphorus produces a periostitis that may later involve the mucous membrane. (See Mineral Poisons, Chapter XXIV.)

The mercury may have been taken in the form of calomel as a purge; or for the treatment of syphilis; or may have been inhaled in certain occupations. Some persons are much more liable to show

toxic symptoms than are others. There is an increased salivation, the saliva containing mercury. A stomatitis follows, first occurring around the gingivæ, accompanied by an irritation of the root membrane.

It may go on to ulceration, gangrene of the soft tissues, loss of teeth, and necrosis of the bone. It rarely or never occurs except when teeth are present, and is much more liable to occur when the teeth are decayed or the gingivæ are irritated by tartar. The salivation and fetor may be very pronounced.

The mucous membrane of the gums, sides of tongue, and floor may present shallow irregular ulcers that have somewhat the same character as those seen in stomacæ.

The diagnosis is made: on the appearance of the mouth; the history of the administration of mercury or the exposure to the fumes of mercury; and where it is a matter of sufficient interest, the demonstration of the presence of mercury in the saliva.

### GANGRENE (SLOUGH).

Sloughing is caused by some interference with the circulation. Within the mouth it may follow mechanical pressure, but is more apt to occur when the tissues pressed upon become infected. The mineral poisons, mercury and bismuth, cause sloughing, as may certain infections. Within the mouth the gangrene is necessarily moist.

Gangrene, or slough, is the death of tissue, and the extent of the slough will correspond to the area in which the circulation becomes permanently blocked. If the agent of injury acts on a certain limited area, the slough will not extend beyond this area. An example of this is the death of tissue, due to pressure of a lead plate, or of tight sutures. Only that tissue will die which is pressed upon by the plate or sutures. This is a self-limited gangrene. A transplanted flap with an insufficient circulation gives another example of the self-limited gangrene. If the agency or injury is progressive, then the area of gangrene may extend accordingly. This constitutes a spreading gangrene. A spreading gangrene is usually due to some infection, but an infection may cause only a limited gangrene.

In a limited gangrene the slough is early separated from the live tissue by a sharp line of demarcation. The dead area first becomes of a darker color and then bluish or purplish. Later this changes to a slate color, and as decomposition progresses, the slough turns a light yellowish gray. A progressive gangrene, due to a spreading infection, will show no sharp line of demarcation and as it extends will show all stages of putrefaction. After the second day, there is always a foul odor, and if the gangrene is of any considerable extent, an acrid discharge.

**Treatment.**—A limited gangrene needs no special treatment. The dead tissue will separate spontaneously, but when the sloughs are large, they may be removed close to the live tissue with scissors. A peroxid of hydrogen or permanganate of potassium mouth wash will help to control the odor. In a progressive infectious gangrene, active measures must be adopted to overcome the infection; these may include the destruction of a certain amount of healthy tissue around the diseased area.

### NOMA (CANCRUM ORIS).

This is a progressive gangrene of the mouth, which is most apt to occur in children, especially young girls between the ages of three and twelve years, though it also occurs in adults. It is usually seen in debilitated subjects and most often follows some infectious disease, such as measles, whooping cough, typhoid, or tuberculosis, or the mercurialization of syphilitic children. A specific cause has not been demonstrated. There has been some evidence presented that would suggest that noma is due to the blocking of the circulation by the invasion of the tissue with the same spirochete that, with *Bacillus fusiformis*, causes Vincent's angina and possibly ulcerative stomatitis. In certain epidemics an apparent relationship to diphtheria was thought to be observed. A bacillus closely resembling the Klebs-Löffler bacillus, which is the cause of diphtheria, has been demonstrated in the lesions, but as far as we know, diphtheria antitoxins have never shown any curative effect.

It has been observed to originate in an indurated spot, usually near the lips. This becomes dark, soon softens, and breaks down. The ulcer spreads, and sooner or later it involves the full thickness of the cheeks. The gums may be involved, exposing the bone, but the tongue is rarely attacked. A very early perforation, in which the outer surface of the cheek is involved to the same extent as the inner, has been regarded as a favorable symptom, but it does not always mean that the sloughing process has ceased. Other such spots may appear, even when the primary slough has become limited. After perforation of the skin the cheek may become somewhat edematous, but remains pale. The process usually spreads rapidly, and before death occurs, it may have involved the tissue to the forehead and neck, leaving a black stinking mass of putrefying flesh, with the teeth falling out and the bones exposed (Fig. 278).

The lymphatic nodes are early involved, and though the temperature is nearly always high, the child for some time shows little signs of subjective disturbances, save for languor. Death from sepsis or pneumonia usually results in a few days. The diagnosis is easily made

after the first few hours. The gangrene seldom stops spontaneously. When death does not result, the scarring will be proportionate to the extent of the tissue destruction. There may be only a slight stellate scar or a horrible deformity. Noma also appears upon the vulva and around the anus.

**Treatment.**—The whole diseased area should be destroyed well into the healthy tissue with an actual cautery, and to the remaining scar may be applied a 10 per cent solution of formalin at the time of operation, and as often afterward as is practical. Formaldehyde is a

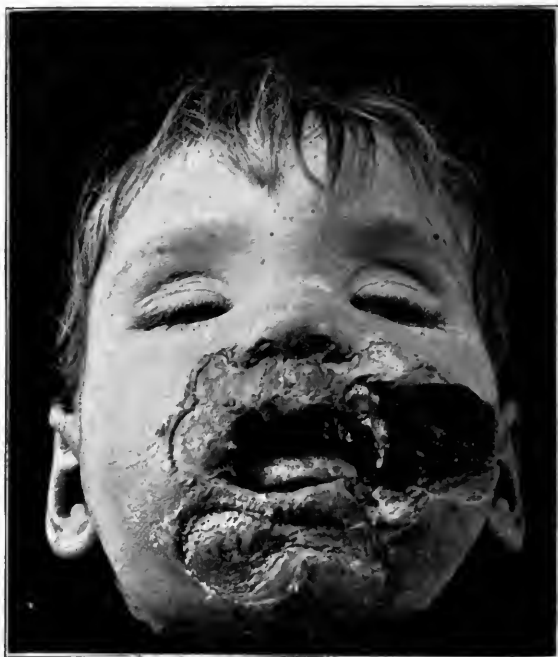

Fig. 278. Noma. A piece has been removed from the left cheek for examination. Photographed for this book by courtesy of the curator of the Hunterian Museum, London.

powerful and penetrating antiseptic—much more so than alcohol, which has been recommended for this purpose. If it is true that noma is caused by the same agency that causes Vincent's angina, then, by analogy, the frequent application of methylene blue to the raw surfaces and to the mouth, after operation, might be beneficial. Excision of the gangrenous area with a knife with immediate suture has been practiced, but the results are very bad with either treatment. If the patient survives, some sort of a plastic operation will usually be indicated.



## SPECIFIC INFECTIONS.

**Measles.**—Measles show Koplik's and Rehn's spots. The former appear as white specks, the size of a pin point, surrounded by a narrow red areola. They are seen only by daylight situated on the buccal mucous membrane opposite the molar teeth. Later, as the case advances, the white specks disappear, and the areolæ coalesce, leaving a red area. Rehn's spots are situated on the hard and soft parts of the palate and resemble the measles rash in the skin. The tongue is furred.

**German Measles (Rubeola).**—Carr and Orcheimer describe red spots appearing on the uvula the first day, but not on the hard palate.

**Scarlatina.**—Besides the scarlet-red swollen pharynx, tonsils, and velum, scarlatina presents a punctate red rash on the hard palate. The tongue on the fourth day after the onset presents the so-called "strawberry" appearance, due to the prominence of the dark-red filiform papillæ.

**Variola and Varicella.**—In smallpox and chicken-pox the eruption may appear on the palate at the same time as it appears on the skin. Though it is of the same character, the umbilicated vesicles soon rupture and leave in their place shallow ulcers, from which are seen hanging shreds of the pellicle.

**Scurvy.**—This is a disease that is only occasionally observed at the present day; though in the days when the crews of sailing ships were often liable to long periods of a diet of "salt horse," dried fish, and Liverpool "pan-tiles," scurvy was not at all uncommon. It seems to depend for its development upon the lack of fresh vegetables and fruit, coming most commonly with a continued diet of salt meat, fish, and bread. It is not improbable that it is due to some infection. The most characteristic symptoms are malaise, a petechial skin eruption which is not elevated and which turns brown, indistinct swellings along the shafts of long bones due to subperiosteal effusions, and a condition of the gums described below.

A characteristic condition of the mouth is almost constant in scurvy. The gums become swollen, spongy, and detached from the teeth, beyond which they project in loose purplish masses that sometimes ulcerate. The teeth become loose, and the breath is fetid.

According to Buzzard, in the absence of teeth, either from a part of the mouth or in toothless infants or old persons, these changes do not occur, but the gums only are pale.

The local treatment is similar to that employed in stomatitis. The general treatment consists in fresh air, fresh vegetables, and fruits—for infants, raw milk.

Loose teeth may be protected by interdental splints (see p. 322).

**Gonorrhœa.**—Gonorrhœa, apparently, occasionally occurs in the mouths of new-born infants—rarely in adults. The mucous membrane is swollen and red, and in places there occur superficial ulcerations. The secretions are said to show the presence of the gonococcus, and a purulent stomatitis in the newly born should be examined for it.

According to Pfaundler and Schlossman, there is often present in the mouths of infants a coccus closely resembling the gonococcus, and to them the evidence so far produced is not conclusive that the disease described under this head is a true gonorrhœal stomatitis.

Treatment consists in cleansing the mouth with a 10 per cent borax solution and in touching the ulcers with a 2 per cent solution of silver nitrate. The prognosis seems good, and the disease usually disappears in a few days.

**Diphtheria.**—The mucous membrane of the mouth is not often affected by diphtheria, though it may be secondary to a severe infection of the tonsils.

Butlin reports a case of primary diphtheria of the tongue. The uncomplicated diphtheritic membrane is at first a thin, white film which appears to be laid upon the normal mucous membrane and which reappears when removed. When on the tonsils, it tends to spread to the uvula and pharynx. As the disease at first is almost afebrile, it cannot be differentiated from Vincent's angina. It causes an enlargement of the lymph nodes. The high fever and thick opaque membrane often observed are due to a mixed infection with pus organisms. Diagnosis is to be made by finding the Klebs-Löffler bacillus by culture.

A. T. Bristow describes a pseudo diphtheria bacillus, which was frequently found by him—once on impure culture. They were isolated in 23 out of 136 cultures examined and could be distinguished from the three Klebs-Löffler bacilli only by animal inoculations and by the behavior of the bacilli to sugar.

**Anthrax.**—Anthrax is due to the local infection, with the anthrax bacillus, and has occurred in butchers who have held a knife in the mouth while butchering an infected sheep. In the cases reported, the mouth has shown black vesicles, and somewhat resembled a gangrenous stomatitis.

**Glanders (Farcy, Malleus).**—This is an infectious disease rather peculiar to the horse, and caused by *Bacillus mallei*. It is sometimes transmitted to man by direct contact. The disease attacks the mucous membrane of the nose and mouth, is characterized by the formation of nodules,—rarely diffuse indurations,—which break down and form ulcers. It may be either acute or chronic, and its manner of outset may vary greatly. In the acute variety there is intense pain and early suppuration of the mucous membrane and lymph nodes, accompanied

by high fever. The diagnosis is made possible from the history of exposure, the formation of ulcers, and the presence of the specific bacillus. The acute form is almost invariably fatal, while in the chronic form the death rate is about 50 per cent. The treatment consists in active local antiseptis.

A. T. Bristow cites the case of a man who was operated upon for a sinus leading to dead bone in the jaw. After curetting and removing the dead bone, the sinus healed. Later an abscess developed in the leg and one in the arm, which when opened gave pure cultures of *Bacillus mallei*.

**Leprosy.**—Leprosy is due to the infection from *Bacillus lepræ*. It is very chronic and usually first invades the nose. It is characterized by swellings which undergo atrophy, but usually break down, forming ulcers which, like syphilis, destroy all tissues. These form scabs and also give off a secretion that emits a peculiar, sweet, unpleasant odor. Scars follow, which contract and cause distortions. In the mouth it usually attacks the uvula and soft palate, forming anesthetic nodules which tend to ulcerate. Diagnosis is to be made from the general symptoms and findings of *Bacillus lepræ*.

**Foot and Mouth Disease.**—This usually appears as an epidemic, and Siegel and others have shown in a special report on the subject the direct connection between this disease in man and cattle.

The characteristics of the disease are fever—often beginning with a rigor accompanied by pain in the back and epigastrium—nausea, and anorexia. There is a superficial inflammation affecting especially the tongue—the rest of the mouth, pharynx, and nose to a less extent.

Small vesicles form in the lips, gums, and tongue—seldom on the pharynx or palate. The vesicles are at first clear, but later become opaque. When the vesicles burst, there are left behind dusky superficial ulcers or erosions. In bad cases the remaining ulcers are covered by a white fibrinous exudate, and the tongue may become so swollen as to protrude from the mouth. In severe or fatal cases the bacillus has been found in the intestines and internal organs.

It is to be distinguished from scurvy by the discovery of the bacillus of Siegel, which is found in the earlier stages of the vesicles in the tongue. There is salivation and pain on eating, and the measly or vesicular eruption may appear on the limbs. The most important point in treatment is prevention.

The disease is transmitted both by the milk of infected cows and by contact. The mouth should be kept clean, and a 1 or 2 per cent solution of potassium permanganate should be used as a mouth wash very frequently. Haubner advises painting the separate vesicles with a 3 per cent solution of carbolic acid, using a camel's hair brush from

which the solution does not drip. The mouth being the first point attacked, the spread of the infection may be somewhat limited by the local treatment. The general care of the patient should receive careful attention, for the disease is often fatal.

**Scleroma.**—This is a disease that seems to be produced by an infection with the scleroma bacillus of Frisch. It usually begins in the nose, but can spread to the pharynx, lip, face, and forehead. The nose may become thickened like a bulb. It is characterized by the formation of swellings which at first do not indurate and never suppurate. The mucous membrane is at first soft and red; but later the infiltration becomes as hard as cartilage, and the mucous membrane is pale, shrinks, and is scarred. In the oral pharynx these scars may cause considerable distortion. The soft palate may be drawn backward, and the uvula obliterated.

If the pillars are affected, the tongue is drawn upward and backward. When the cheek is attacked, fibrous ankylosis may result. It is to be differentiated from diffuse gumma by its lack of ulceration, its chronicity, and its final hardness; from sarcoma by its bilateral distribution, its chronicity, and its atrophic tendency. The finding of the scleroma bacillus fixes the diagnosis.

The treatment is symptomatic only, as no cure has been found.

**Chronic Ulcerative Stomatitis (Stomatocace).**—This is an aggressive ulceration of the gums and neighboring tissues—that never occurs except in the presence of teeth. This is not the only affection that depends upon the presence of teeth. Neither the mercurial stomatitis nor the oral manifestations of scurvy are present in the edentulous. The disease has often been epidemic in barracks and asylums, but is almost always a disease of children. When it has appeared in barracks, the officers have not been affected, and it is therefore thought to be due rather to bad hygiene than to direct contagion. The lesion starts with a cushion-like red swelling on the gums near a tooth. As the gum swells, it separates from the tooth and later becomes discolored with a yellow purulent exudate within the superficial layers of the mucous membrane. Beneath this exudate the tissues become necrotic, and in a short time the infiltrated area has been replaced by an ulceration. As the ulcer extends, the tooth may become loose in its socket and thrown off. A yellowish-brown or dirty-gray exudate adheres to the floor of the ulcer, and if detached, there is free hemorrhage. Blood can often be detected between the child's lips. The neighboring parts of the oral or lingual mucous membrane, which lie in contact with the original ulceration, soon become involved in the same process. The palate is not often involved, but it may spread to the tonsils or even to the pharynx and larynx. The tongue becomes thick and coated, and

there may be swelling of the lips and cheek which is visible from the outside. The lymph nodes are enlarged, and there is a penetrating fetid odor perceptible from a distance.

Especially in children the general condition is severely affected—pain, fever, and lack of appetite being marked. If treated, the prognosis is good, but septic complications are possible. Bruck regards this as an idiopathic disease due to the inroads of organisms usually present in the mouth. But Pfaundler and Schlossmann would lead one to conclude that Bernheim and Prospischill have demonstrated the disease to be due to *Bacillus fusiformis* and to a spirochete acting in conjunction, the same cause being assigned to Vincent's angina. Many, however, are not ready to accept this explanation of the etiology. It is more than probable that ulcerations clinically somewhat similar, but due to different causes, are grouped under this head. In two cases that have come under our observation, *Bacillus fusiformis* and its associated spirochete were demonstrated; and one of them, on whom methylene blue was used locally, promptly recovered under this treatment. The treatment consists in the use of an actively antiseptic mouth wash, such as a 1 or 2 per cent solution of potassium permanganate, and after cocainization, the daily applications to the ulcers of a 10 per cent solution of formalin. Internally, potassium chlorate should be administered in the form of a solution for the first three or four days, but not continued on account of the danger of renal irritation. If it is true that the disease is but another manifestation of Vincent's angina, then the application of the basic aniline dye should make an effective local treatment. With children the feeding becomes difficult on account of the pain. The local application of a 2 per cent solution of cocain has been resorted to, but a minimum amount of the drug should be used. Fresh air is an important factor, and children should be kept in the open air, the beds being moved outdoors or next to an open window.

**Vincent's Angina (Angina of Plaut).**—This is a form of oral infection and tonsillitis, which of late has attracted considerable attention. It is apparently caused by the combined effect of a spindle-shaped bacillus, described by Plaut and Vincent, and a spirochete. According to Pfaundler and Schlossmann, the disease was first described by the Russians, Szimanowsky and Filatov. Often the bacillus and the spirochete have been found in the mouth as a saprophyte. Ellermann has succeeded in cultivating the bacillus as a strict anaerobe. It is probable that, like many other organisms, it only becomes pathogenic under certain favorable circumstances. Vincent states that the disease does not appear after the thirty-fifth year, but exceptions to this have been reported.

W. Eichmeyer states that *Bacillus fusiformis* and the spirochete are

always present, but at times other organisms predominate. He states also that the disease belongs to the same group as ulcerative stomatitis, as shown by a similarity of clinical and anatomical findings; that Vincent's angina may begin as an exudative stomatitis and may continue as a typical ulcerative stomatitis, and may extend to the fauces. He concludes that not only are Vincent's angina and ulcerative stomatitis identical in their etiology, but that noma is due to the same organisms. *Bacillus fusiformis* is found with the spirochete in a number of other conditions. It is present in one quarter of the cases of diphtheria, and is less frequently found in scarlatina, gingivitis marginalis, stomatitis varicellosa, parulis, and morbus maculosus Werlhofii. He states, however, that the spirochete and *Bacillus fusiformis* are not found before the teeth are present.

The affection is characterized by the formation of ulcers covered by a pseudomembrane, formed by a necrosis of the superficial layers of the mucous membrane. This typical appearance is not always present; when ulceration is present, it may be superficial or deep. In some cases the lesion involves the tonsil, commonly only the upper part and on the inside, spreading to the soft palate and possibly to the pharynx and larynx. In others it will be found farther forward, usually near carious teeth. We have seen it the cause of a gingivitis, involving the whole of both gums, the latter probably being identical with the stomatocace. The patches are of a grayish-white color, surrounded by a red zone, but separated from each other by healthy tissue. Removal of the membrane shows an ulcer of varying depth, which bleeds freely and is soon covered by a new membrane. The ulcers show a crater-shaped edge and have a tendency to involve the deeper tissues more than the surface. The infection is often limited to one side. There is swelling of the lymph nodes, salivation, fetor, and often some fever.

The prognosis is usually good. It rarely causes marked constitutional symptoms, but most observers have found it to be remarkably stubborn, often requiring weeks for its cure.

The treatment consists in removing or filling carious teeth or keeping the mouth clean with an alkaline antiseptic solution or a 1 per cent solution of permanganate of potassium. The local application of one of the basic aniline dyes—methylene blue or violet—applied dry in a cotton swab daily, will effect a cure in a few days. Chaufford seems to have first proposed the use of methylene blue for this purpose. A 10 per cent solution of formalin will do the same thing, but is very painful.

**Desquamation.**—This follows all of the stomatites, but may be caused by the use of chemical irritants. It may result from an irri-

tating mouth wash. Occasionally a neurotic, usually a woman, will for some purpose burn the mouth repeatedly with an escharotic, producing a localized desquamation. It is much more common to find such self-inflicted burns on the surface of the skin of some other part of the body. Though, from location, its repeated appearance, its irregular outline, and its lack of resemblance to any familiar clinical picture, the attendant may suspect the true nature of the trouble, it is difficult to prove, and is usually unwise to make a direct accusation.

**Tuberculosis.**—This occurs in several forms, but in all instances is caused by an infection with the tubercle bacillus. When the infection occurs, the tissues immediately surrounding the focus form a mass of granulations known as a tubercle. The histological structure of a tubercle is usually, though not always, strongly suggestive of the cause. In mouth tuberculosis the giant cell is not common, and therefore microscopical examination of the tissue is not always helpful. Later, this tubercle, which in its center is poorly supplied with blood, usually caseates or ulcerates. There are two varieties of tuberculosis of the soft tissues of the mouth which give a different appearance and clinically run very different courses. They are lupus and the ordinary tubercular inflammation. Lupus is characterized by the formation of groups of superficial tubercles and a tendency to scarring and contracting, and little aptitude for very active ulceration. Lupus of the face is usually present with lupus in the mouth. In ordinary tuberculosis of the mouth ulceration is, after the first stages, often the most prominent characteristic. At first there are always one or more tubercles, but these may ulcerate so rapidly as to escape notice. (For characteristics of the tubercles and the ulceration see Tuberculosis of the Tongue, Chapter XXXIV.) The ulceration may be so rapid that it is difficult to detect the outlying area of tubercles. The infection may occur in any part of the mouth, but it is peculiar that tuberculosis of the maxilla and roof of the mouth is not nearly so virulent as, and runs a much milder course than, tuberculosis of the tongue, floor of the mouth, or mandible. While early in their course these tubercular lesions cause little inconvenience and are free from pain, in their later stages they are both extremely painful and tender, and cause salivation and fetor.

A provisional diagnosis of tubercular lesions is to be made partly from their clinical characteristics and partly from serum reactions. An absolute diagnosis is obtained from the demonstration of the tubercle bacilli. Every patient suspected of tuberculosis of the mouth should be given a thorough physical examination. It is to be remembered that tuberculosis can arise in a syphilitic, and gumma, carcinoma, or any other lesion in a phthisic. It has been observed that gummata show a greater

predilection for the dorsum of the tongue, while the tubercles are more apt to occur in the tip or edges; but this is only relative, and does not warrant conclusions in the individual case. The same is true of the fact that the tubercular lesions early, carcinomata late, and gummata very rarely cause enlargement of the lymph nodes. The exceptions to these rules preclude them from being relied upon for final decision.

The von Pirquet and other reactions of the same character can be used only as contributory evidence; for after two years they are frequently present when there is no evidence of an active tubercular lesion, and are sometimes absent during certain stages of an active tuberculosis. Koch's serum reaction is, we believe, more reliable. If one will adopt the rule of excising all isolated subacute or chronic lesions of unknown cause, then the preoperative diagnosis of tubercular lesions of the mouth is not so important. If one hesitates to do this, then the scrapings of the tissue should be examined for tubercles, and if this is negative, an emulsion is to be injected into guinea pigs.

The local treatment of a tubercular infection of the mouth will vary with the character of the lesion, its location, and the general condition of the patient. Lupus anywhere is to be treated with such milder measures as the Finsen light, curetting, the application of lactic acid, or the x-ray. Tubercular nodules and small ulcers are to be excised, and the defect closed by immediate suture. In the roof of the mouth and upper jaw, larger ulcers may be scraped, and the surface repeatedly painted with lactic acid. On the tongue, or the floor of the mouth or lower jaw, the ordinary tubercular infection is in the majority of cases as fatal as cancer, and it should be treated accordingly. A possible exception to this may be made in patients with pulmonary or general tuberculosis, but even there, patients can be made immensely more comfortable. The general treatment should be the same as in any tubercular infection, and one of the first things gained by excision is freedom from pain, rest, and ability to take food. Specific vaccines may be employed by those familiar with the methods.

**Syphilis.**—In all of its manifestations syphilis is due to the infection with *Spirochæta pallida*, which is transmitted only by contact. The primary lesion, the hard chancre, is often situated on the lip, seldom on the cheeks or tongue, but sometimes on the tonsil. It first appears as a crack or superficial abrasion, surrounded by some induration. Later the induration increases, but is partially destroyed by ulceration. Within the mouth a fully developed chancre is usually rather round and presents either a grayish granular surface due to purulent secretion that covers it, or is occupied by a concave ulceration. It has a sharp outline and a hard base. It is painless and causes early enlargement of the lymph nodes. Without constitutional treatment it



heals slowly, usually lasting six weeks. Sometimes the secondary lesions appear before it is healed.

The secondary manifestations of syphilis in the mouth may be of an erythematous or of a papular or ulcerative type. The pharynx is usually affected in secondary syphilis. The soft palate and tonsils are reddened, but there is little or no pain. By itself diagnosis of the syphilitic erythema would be difficult, but it usually occurs in conjunction with other manifestations. The mucous patch is a rather common intraoral secondary lesion, but is not found here as constantly as around the natal and genital cleft. Within the mouth they occur on the edge of the tongue, on the under surface near the tip and on the dorsum, on the uvula and palate arches, sometimes on the tonsil or posterior pharyngeal wall, but most commonly of all on the inner surfaces of the lips, where one can often see the papules on the outer surface passing into mucous patches. They appear as large or small, round or irregular plaques of a grayish-white color covered by a sticky secretion. The mucous membrane around the plaque, unless irritated, is not conspicuously red. They may disappear quickly, especially under constitutional treatment, but they may recur or be remarkably persistent. Years after the lesions have healed, round pearly-white smooth patches may be present. These are sometimes called Erb's scars. Tertiary lesions are due to a gummatous infiltration, which is much inclined to ulcerate with total destruction of the infiltrated tissue.

Gummata usually do not appear for many months or years after infection. They may occur in any part of the mouth, but are more common on the upper surface of the velum, the tonsil, posterior pharyngeal wall, palate, and tongue. They may be single or multiple, the size of a pea or a hazelnut. Gummata are sometimes diffuse, giving the tissues a leathery feeling, but are more often circumscribed, in which case they can be felt as distinct nodules. When a gumma breaks down, it forms an ulcer with sharp edges. If the whole gumma disintegrates, the edges of the ulcer will be formed by healthy tissue, but more often it shows induration. If the gumma is deeply situated, there will result an ulcer with deeply undermined edges, or it may communicate with the surface by a small opening. A serpiginous or scalloped border is a very common characteristic of gummatous ulcers. An ulcer that heals at one edge as it spreads at another is usually due to gumma, but may be due to tubercle. On the hard palate the ulcer often extends through to the nasal cavity. Gummatous ulcers are sometimes extremely painful. In healing, large ulcers often cause considerable distortion. This is especially true when the ulcer involves the opening between the naso- and the oropharynx (see Chapter XXXVIII).

The diagnosis of syphilis is to be made on the history of the case,

and the appearance, grouping, and sequence of the symptoms. Recently we have had placed at our disposal the Wassermann and the Noguchi serum reactions, which are almost certain. Though only 60 per cent of syphilitics will give positive reactions, it is very rare that a positive reaction cannot be obtained in the presence of any active syphilitic lesion. One or the other, or both, should be employed in every doubtful case. In the primary and secondary lesions a diagnosis can be made or excluded by finding or not finding the spirochete when a proper technic is used. In the tertiary lesions the spirochete is not evident.

Chancre may be mistaken for carcinoma, or the reverse. Chancre has a history of an acute onset and is short-lived, especially under antisyphilitic treatment. Aphthæ and other acute mouth lesions may be mistaken for mucous patches or secondary ulcers, but the former are always more acute in their course. Whenever there is the possible suspicion that we have to deal with a primary or secondary syphilitic sore, scrapings from the surface should be examined for *Spirochæta pallida*, and the patient should be subjected to a rigid general examination. Gummata are to be differentiated from phlegmonous infiltrations by their subacute course; from new growths, especially carcinomata, by the general history and examination of the case, the fact that they are often multiple, and when there is the least doubt, by the Wassermann reaction. From actinomycosis they are to be differentiated: by the manner in which they break down—the former ulcerates and the latter forms sinuses; by the history; and by the finding of the fungus in the actinomycotic discharge. Both yield to the internal administration of the iodids. Both the primary and the secondary lesions can transmit the disease; the patients should be warned to care for themselves and others accordingly. Tertiary lesions, though they contain a few spirochetes, do not seem capable of communicating the contagion.

The treatment of syphilis is essentially medicinal and should be carried on by a competent internist or specialist. When a chancre appears, general infection has already occurred, but it can be limited by immediate excision of the primary sore and institution of treatment with either mercury or salvarsan. Secondary sores are to be treated by mercury or salvarsan, the use of a cleansing mouth wash, and the withdrawal of local irritations. Persistent mucous patches which do not yield to constitutional treatment will, according to Butlin, always disappear with the repeated applications of a 2 per cent solution of chromic acid. The treatment of tertiary lesions, gummata, is with increasing doses of iodids with mercury, and the administration of salvarsan.

## PARASITES OF THE MOUTH.

Both animal and vegetable parasites give rise to disease within the mouth. The latter, which cause the mycoses, are the most common. To this class probably belongs the tubercle bacillus. Occasionally animal parasites, such as *Cysticercus cellulosæ*, *Echinococcus* (Hydatids), *Trichina*, and *Filaria medinensis* (Guinea-worm), are found. *Spirochæta microdentium*, *Spirochæta macrodentium*, and *Spirochæta refringens* may be constant inhabitants of the mouth.

**Thrush.**—This disease was recognized and described by the Hippocratic writers under the general term of aphthæl, from which, even at the present day, many do not make a distinction—among the latter is no less an observer than Butlin. It is caused by growths of the fungus, *Oidium albicans*, which is most commonly found in the mouths of unhealthy, unclean infants, but is also found in debilitated and old persons. The favorite sites of onset are the anterior part of the tongue, the gums, and the cheeks. It thrives best in infants who receive starchy foods. It is very contagious and spreads easily by the use of unclean nipples, pacifiers, etc. It often occurs in the mouths of infants with cleft palate. The disease first begins by the appearance of pinhead white spots that spread and unite, forming patches. The patches cannot be easily removed, for the fungus grows not only on the surface, but into the epithelium and the underlying connective tissue. When torn off, it leaves the underlying mucous membrane red, softened, and bleeding easily. The mucous membrane between the patches shows a simple stomatitis, which usually precedes the specific infection. After persisting some time, the color of the growth becomes yellow or brownish and scales off easily. The onset of the disease is painless and, therefore, is overlooked.

If it has not preceded the infection, gastrointestinal disturbances are likely to follow, high fever may be present, and soreness may interfere with sucking. The growth is usually restricted to the mouth, but it may continually spread to the nose, larynx, pharynx, esophagus, and stomach. It usually responds quickly to treatment, but sometimes recurs rapidly. In debilitated infants or adults the recurrence is a sign of lack of general resistance and is a bad symptom. Occasionally the fungus is carried into the blood, producing a general infection, which is the most serious form of the disease. In its passage into the tissues, the fungus may be accompanied by pus organisms, giving rise to a mixed infection. The fungus, accompanied by pus organisms, may follow the Eustachian canal into the middle ear, causing a suppurative otitis media. Injudicious efforts at cleansing the mouth may give rise to Bednar's ulcers.

The diagnosis of thrush rests upon the appearance and growth of the patches, and the fact that they are in the early stage removed with difficulty and at once recur. From aphthæ they are clinically distinguished by their color, which is at first dead white, and by the fact that the growth of thrush has an uneven surface and is elevated above the surface of the epithelium. The diagnosis can be made absolutely certain by a microscopical examination of the membrane, which shows the specific fungus. The picture shown is a network of double threads with interrupting constrictions that form chains of many links. Interposed among the threads are seen clusters of round or oval highly refracting spores.

Treatment consists partly in general care of the patient, fresh air, clean utensils, and the avoidance of starchy foods. Although thrush thrives in an acid medium and renders the mouth acid, many clinicians claim that boric acid holds first place as a local application. In infants this is safely applied by means of the boric acid teat of Esmarch, which consists of a compressed pad of absorbent cotton, impregnated with powdered boric acid. The pad, which should be about  $1\frac{1}{2}$  to 2 centimeters in diameter, is covered with cotton cloth and then dipped into a .01 per cent solution of saccharin. As the infant champs and sucks the teat, the mouth is mechanically cleansed, and the boric acid is well distributed. A more common remedy among the laity is the use of borax, either in the somewhat irrational form of borax and honey or in solution. We prefer a solution of 5 per cent borax and 15 per cent glycerin in water, and have seen this clean off a case in a few hours when the boric acid treatment had completely failed. We believe it wise to make up the teat with equal parts of borax or sodium bicarbonate. If infants will not use the teat, Pfaundler and Schlossmann recommend that they be allowed to suck on a brush dipped in a 2 per cent solution of silver nitrate. Infants fed on condensed milk sometimes present white spots on the tongue that somewhat resemble thrush. When removed, they appear after the next feeding.

**Actinomycesis.**—This is due to an infection with the ray fungus, the same that causes "lumpy jaw" in cattle. The fungus is normally found in grain and probably most frequently finds its way into the mouth from the habit of chewing on straws. From the mouth it most commonly enters the tissues through decayed teeth. The disease first manifests itself in the form of a small nodule, which for a time may give no trouble, but later softens and forms sinuses from which is discharged a thin fluid which usually contains the fungus. It may be extremely painful. The process is rather indolent and tends to form hard swellings situated most commonly near the angle of the jaw. It does not commonly involve bone, but may do so (see p. 316).

Diagnosis is made from the chronic induration and sinuses, and from the finding of the fungus in the discharge. This is sometimes seen macroscopically as small round "sulphur granules," or it may require a microscopical examination. When the fungus cannot be found in cover-glass preparations, it can sometimes be demonstrated in glycerin agar cultures. The treatment consists in curetting away the granuloma and in the internal administration of potassium iodid in large doses, or copper sulphate to the limit of toleration. Potassium iodid is the older treatment, but Bevan, based on observations made at the Wisconsin Experimental Agricultural Station, proposed the copper sulphate treatment in man and reports a number of successes. Formerly the granuloma of actinomycosis was confounded with sarcoma.

**Leptothrix.**—This, a constant inhabitant of the mucus of the pharynx, may grow in masses on the base of the tongue or faucial tonsils, or in the cavities in teeth. It forms white or yellowish points, which are not easily removed. The growth is stubborn and, though it causes few symptoms, is difficult to overcome.

**Sarcina.**—This may grow on the mucous membrane in white patches, which in appearance resemble thrush, and the treatment is the same.

(For the diseases that most commonly manifest themselves on the tongue, see Chapter XXXIV.)

## CHAPTER XXIV.

### INFECTIONS OF THE TEETH, PERIDENTAL TISSUES, AND JAW-BONES.

The bones of the jaw differ in no essential from bones composing other parts of the skeleton, and they are subject to the same diseases; but from environment, and possibly from other causes, are more prone to some, and less so to other, pathological processes.

The body of the lower jaw has an outer thick wall composed of hard, compact bone, and contains cancellous bone and a large open canal which carries the nutrient artery and inferior dental nerve. During the period of growth, the neck is separated from the condyle by an epiphyseal cartilage, so that the mandible is a true long bone with a diaphysis and two epiphyses. The bodies of the maxillæ are of less compact bone, and the dental nerves occupy several small canals. The alveolar processes are composed of bone which is almost cancellous. The jaw-bones are covered with periosteum, which dips into the tooth sockets and here serves both as a lining for their sockets and as a covering of their roots. This part of the periosteum is called the alveolar periosteum, the pericementum, or the peridental or root membrane. It is well supplied with blood vessels and nerves, and at the border of the tooth sockets it is continuous with the mucous membrane of the gum as well as the surface periosteum. It is from vessels running in or piercing the periosteum that most of the blood supply of the bone is derived. The cementum covering the roots very closely resembles bone, and it receives its nutrition through the pericementum.

Over the gums, palate, and floor of the nose, and in the maxillary sinus, the mucous membrane is in almost immediate contact with the periosteum.

Most of the infections of the jaw-bones are extensions of infections from the teeth or pericementum. In a comparatively few cases an infection of the mucous membrane extends directly to the surface periosteum and then to the bone substance, but metastatic infection of the bones themselves is rather rare; and we have seen but one case of acute metastatic septic osteomyelitis of the jaw-bones.

Infections of the mucous membrane were taken up in a separate chapter, but infection of the bones of the jaws is often associated with infection of the peridental membrane, so that it is well to consider them together. There are certain irritants, mostly mineral poisons, that

reach the periosteum through the blood or saliva, which, though not infectious themselves, render the tissues susceptible to the organisms of infection that are constantly present in the mouth. These will be considered with infections of the bones.

### DENTAL CARIES.

The omnipresence of certain bacteria in the mouth and their waste products is responsible for the destruction of the hard substance of the teeth. This disease is known as dental caries. It always starts on the outside of the tooth and manifests itself in two distinct processes, i. e., the dissolution of calcium salts by the acids principally produced by fermentation of adherent food stuffs: lactic acid, and the liquefaction

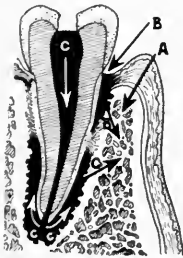


Fig. 279.

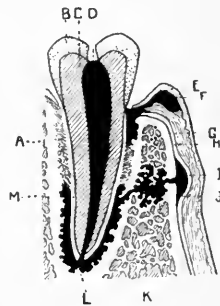


Fig. 280.

Fig. 279. Diagram of a carious tooth, with an infected pulp chamber, root canal, and an infection around the apex of the tooth. (A) is the bone of the alveolar process. The arrow leading from (C) shows the line along which the abscess may perforate the bone. (B) represents a peridental infection from the gingivæ, and the arrow shows the line along which it may penetrate. Between the abscesses (C and B) there still remains some intact pericementum.

Fig. 280. Diagram of carious tooth. Infection of the pulp chamber, root canal, and peridental tissues. B, enamel; C, carious cavity; A, pericementum; E, mucous membrane of the gum; F, an abscess that has formed from an infection from the gingival border; G, compact bone of the alveolar process; H, periosteum; I, periosteum raised by an abscess from a perforation from an apical infection along the tract (J); K, alveolar bone; M, cementum.

of the remaining organic matrix by the action of the ferments. On account of the small amount of organic matter present in the enamel, the latter part of the process is not observed in this tissue. The carious destruction proceeds along the line of least resistance, i. e., toward the pulp. Unless this process is mechanically checked by the dentist in the early stages, the pulp will become exposed in time. Deep-seated caries or exposure of the pulp always means infection. The resulting inflammatory process of the pulp renders the tooth extremely painful. A pulp may become inflamed from other irritants than an infection, but when the pulp chamber is opened and the pulp exposed to the bacteria of the mouth, it is sure to become infected. From here the infection has easy access to the root canals and apical foramen (Figs. 279, 280). Occasionally an apparently perfectly sound tooth with no external evi-

dence of disease is found to contain a dead pulp with an infection at the apical foramen. The death of the pulp can be explained in a number of ways, but the presence of infection in certain teeth cannot be accounted for except by the supposition that the infection was a metastasis. A tooth, the apical foramen of which is in contact with the mucous lining of the nose or antrum, could be infected from these sources, but in other teeth it would appear that the infection must be a metastasis (Fig. 8).

The pain of an inflamed pulp may be referred to some other point on the distribution of the fifth nerve, or, through its connections with the seventh nerve, the pain may be deep in the ear.

### ALVEOLAR ABSCESS.

The infection in the pulp may travel down the root canal and through the apical foramen into the tooth socket, causing an inflammation of the pericementum that may go on to suppuration: this constitutes an alveolar abscess (Fig. 280). If suppuration occurs at the apical part of the pericementum, pus will be formed in a confined space that is well supplied with sensory nerves. This causes intense pain and often a sharp rise in temperature. After the abscess has persisted for some hours, there is swelling of the face and of the lymph nodes which guard the area. If left to itself, the pus will perforate along the line of least resistance, through the alveolar process, through the root canal, along the side of the root to the gingival border (Fig. 280). The natural perforation of live tissue for the liberation of pus does not result directly from pressure, but from the activity of the leucocytes, which will destroy the tissue along some chosen line and tunnel a path through which it can come to the surface.

In the case of the second upper bicuspid and upper molars, rarely of the first bicuspid or cuspid, the pus may perforate into the submucous tissue in the floor of the antrum (Fig. 8). From here it may immediately perforate the mucoperiosteum and discharge into the cavity of the antrum (Fig. 290).

When the pus is liberated from the socket, the pressure will be relieved, the intense pain will cease, at least temporarily, and the temperature will drop. After perforation of the alveolar process has occurred, there may be a small localized abscess known as a "gumboil," or it may point somewhere along the lower border of the mandible, into the tissues of the face or into the antrum or floor of the nose (Fig. 280). The pus may dissect up a considerable area of the periosteum and perhaps cause a necrosis of the subjacent bone. If the virulence of the infection is out of proportion to the resistance of the patient, it may become more or less diffuse, causing suppuration in a neighboring



lymph node or connective tissue space, or a general septicemia or pyemia; any of the latter conditions may have a fatal termination.

In children we have occasionally seen an alveolar abscess accompanied by a marked torticollis with compensatory lateral curve of the spine. This may persist for several weeks.

After the acute inflammation subsides, if there has been little destruction of peridental tissue, the apical abscess and the tract through which it is discharged are soon obliterated by granulations. This constitutes at least a temporary cure. In some cases the infection remains latent, and the inflammation recurs at intervals. After the first, or after a number of flare-ups, there may be established a chronic bone abscess, which spreads by molecular disintegration of its walls. This has been



Fig. 281. Chronic bone abscess around the roots of an infected tooth. This was in a young girl, who had submitted to several external operations for the cure of a discharging fistula below the mandible.

wrongly spoken of as a bone cyst, from which latter it differs by not possessing a definite lining membrane.

### ALVEOLAR FISTULA.

As long as the abscess persists, whether acute, subacute, or chronic, pus or seropus will be constantly excreted. This may be discharged through the root canal or from between the root and the wall of the socket, or through a canal formed in the bone and soft tissues; such a canal is called a fistula. An alveolar fistula will not heal so long as the pus is being formed, unless some easier path of exit is furnished. In an old chronic abscess the amount of fluid excreted may be very small (Fig. 281).

A bone fistula is usually narrow and in the chronic stage has a tendency to become blocked, when, if there is no other exit for the discharge, the acute symptoms will recur and persist until the sinus reopens or drainage is furnished through some other path.

In some apical infections the amount of discharge is so slight as not to be detected when the tooth is opened up, but the relief from pain after drilling and its recurrence on filling the root attest the presence of an inflammation that is causing pressure.

### RETRACTION OF THE GUMS.

Tartar collecting around the necks of the teeth causes an irritation which may eventually result in the retraction of the gingivæ; as a result, a part of the root is exposed, which in turn becomes coated with tartar. This causes a further retraction of the gums and with it an absorption of the alveolar process. It is as a result of this that the teeth appear to grow longer in old people.

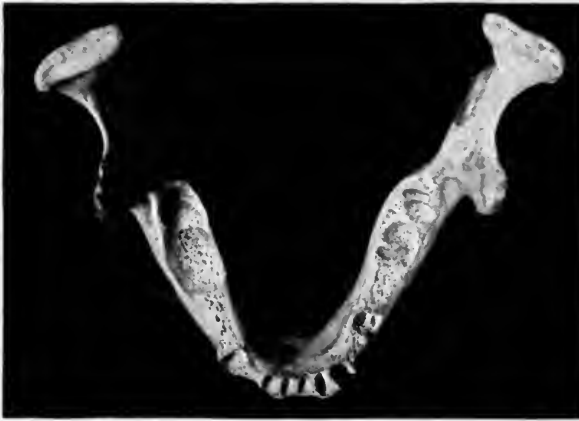

Fig. 282. Jaw-bone showing various degrees of absorption as the result of chronic pyorrhea alveolaris. The site of the second right molar shows but a shallow depression, while that of the third molar of the same side is a little deeper. The site of the second molar on the left side shows separate sockets for the two roots, but the sockets are very wide—especially at their borders. The incisor region shows almost normal sockets, while behind the right first bicuspid is shown the condition that normally results after the removal of a tooth.—From a specimen in the Washington University Medical School.

### INFLAMMATION OF THE PERICEMENTUM (PERICEMENTITIS).

By an extension of an inflammation from the gingivæ or the apical foramen of a tooth, from the irritation of some of the mineral poisons—such as mercury or bismuth—or in certain constitutional disturbances—such as gout—the peridental membrane may become inflamed. As a result, the tooth is somewhat loose and tender, rises slightly out of its socket and above its fellows, and receives the main force of the impact of the jaws.

This inflammation may have been primarily an infection, or an infection may follow an inflammation due to irritation; but in either case suppuration of the pericementum may follow, in which case pus

will be seen exuding from between the neck of the tooth and the gingivæ.

### **PYORRHEA ALVEOLARIS.**

If, as the result of suppuration, any considerable part of the periodontal membrane is destroyed, a space will be left between the cementum of the root and the bone, and both walls of this space will be more or less diseased (Figs. 279, 280).

After the teeth once become loose, the lateral pressure of the roots causes an absorption of the walls of the socket, most marked at its upper part (Fig. 282).

Tartar, food particles, or other débris work their way down into these pockets, still further increasing the irritation. For this reason the disease has a tendency to extend deeper and deeper along the affected roots. Having affected one tooth, it has a tendency to spread to others. The symptoms commonly present are an exudate of pus from around the teeth (it may be necessary to press upon the gums to detect this), the presence of a pocket along the root, and foul, spongy gums, with gradual loosening and finally loss of the affected teeth. If many sockets are affected, there may be mild general sepsis. An increasing tendency for meat shreds to collect between the teeth may be the first symptom noticed by the patient.

### **OSTEITIS OR INFLAMMATION OF THE BONE.**

This may result from injury, mineral irritants, septic infection, or certain other specific infections. When bone becomes inflamed, there is an increase of the blood supply and infiltration of leucocytes, and later on, an increase of the bone corpuscles and an actual loss of bone substance. This bone destruction is caused by the leucocytes and occurs probably for the purpose of furnishing room for the inflammatory increase of the blood supply, leucocytes, and fixed tissue cells. The inflammation may clear up, leaving the bone almost normal, it may go on to suppuration, or it may be followed by a necrosis. It may be followed by rarefying osteitis, in which the bone becomes so porous as to be soft or spongy, or a sclerosis in which the mass of proliferating cells are converted first into fibrous tissue and then into very hard dense bone. Bone is very resistant to the invasion of pus organisms, and when bone suppuration occurs, it is usually confined to a surface. It may be intramedullary, subperiosteal, or in a gradually extending cavity, but the suppurative inflammation will rarely involve the substance of the bone to any depth. If it does do so, necrosis of the involved mass will be more than probable (Fig. 283). As soon as death of this mass of bone occurs, the inflammation will again be limited to a surface at the junction of the living and dead bone, so that the rule that suppuration

of the bone is limited to a surface is subject to few exceptions (Fig. 284).

If, as a result of a suppurative inflammation in a tooth socket, a part of the root becomes denuded by destruction of the pericementum, or if a necrosis has resulted, the denuded root or the sequestrum of bone will act as a mechanical irritant which will prevent healing. Later the lack of proper drainage may help to continue the suppuration. Suppuration always presupposes an inflammatory reparative effort on the part of the tissues, for, if this did not occur, there would be death of the tissues without the formation of pus. The base of a suppurating

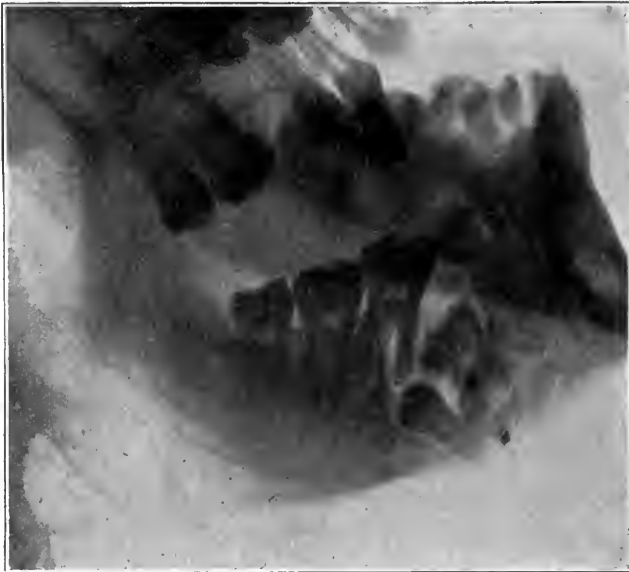

Fig. 283. X-ray showing a chronic bone abscess around an unerupted deciduous second molar, which has in turn prevented the eruption of the second bicuspid. The tooth buds of the bicuspid lie below the deciduous molars.

surface is so crowded with leucocytes and rapidly multiplying fixed tissue cells that they form an extra barrier to the progress of the infection. This inflammatory wall may be continuously modified or destroyed on its exposed surface but at the same time is added to on the surface in contact with the healthy bone, while a concurrent absorption of the bone substance takes place. It is by this process that an infection at the apex of a root may produce a definite cavity in the body of the bone that may in time become quite extensive; yet at no time are any visible bone particles thrown off (Fig. 281). If a progressive destructive process of this kind were to occur on an exposed surface, it might be called an ulcer. In the jaw-bones these are termed

absorption abscesses, sometimes incorrectly, "dental cysts." The process is often referred to as caries of the bone, but this term is better reserved for cases in which destruction is due to the tubercle bacillus.

The bone of the lower jaw is much denser than that of the upper and therefore more resistant.

Absorption abscesses are more common in the upper jaw and attain larger proportions. When an absorption abscess does occur in the lower jaw, it is more apt to enlarge at the expense of the alveolar bone which surrounds the tooth sockets, occupying the center of the body, than to destroy the denser outer walls. In this way a large cavity may form, which embraces the roots of several teeth, but which does not materially lessen the strength of the bone. In many cases the repar-

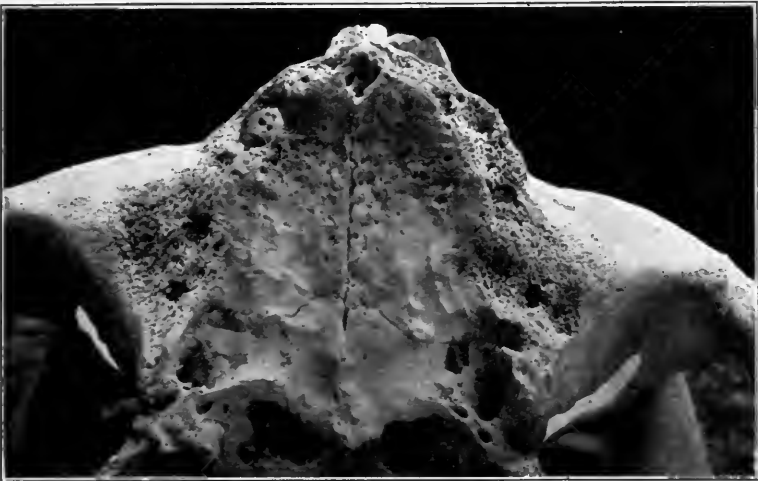

Fig. 284. Inflammatory destruction of the maxillæ, due probably to periodontal infection.—From a specimen in the Washington University Medical School.

ative effort of the bone granulations would be sufficient to overcome the infection, were it not for the presence of a mechanical irritant—such as a piece of dead bone, an exposed denuded root, or an unerupted tooth.

### NECROSIS.

The destruction of bone is not always attained by the slow process just described. If the nutrition of any area of bone is shut off, the part involved at once dies without any immediately apparent change in its structure. It is possible that the death of bone may sometimes result directly from the action of bacterial toxins, but probably it is nearly always due to a shutting off of the blood supply. This may result from direct pressure on the vessels by the swelling in a confined space, from a tearing of the vessels when the periosteum is stripped off

by accident or there is a subperiosteal collection of fluid, or from septic thrombosis of the interosseous veins. As soon as an area of bone dies, the leucocytes begin to separate it from the live bone. If the necrosis has not been caused or followed by a septic infection, the wall of granulations that spring up at the plane of separation will remain free of pus, and the dead bone may remain buried, and gradually be destroyed by the leucocytes in the granulations which surround it. An aseptic necrosis seldom, if ever, occurs in the jaw-bones; the plane of separation between the live and dead bone becomes a suppurating surface, and the dead bone lies in an abscess cavity. If this pus does not find a free exit, there will be fever, pain, etc., just as in any other undrained abscess. It is not the dead bone that causes these symptoms, but the accompanying infection. The infection, however, will persist as long

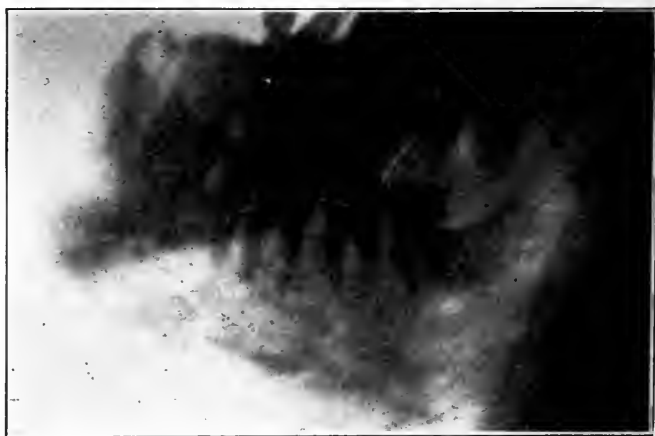

Fig. 285. Necrosis of the body of the lower jaw.

as the dead bone remains in place, and ample drainage must be provided.

The necrosis may involve a part of or the whole bone. If it extends to the surface, the periosteum will almost at once begin to form a shell of new bone, and all exposed surfaces of the live bone will be covered with a wall of granulations. In this way the dead bone will come to lie in a bone cavity lined with granulations, and it is then called a sequestrum. Except when freshly cut or broken, live bone never presents a distinctly hard surface. It is always covered with a thin layer of granulations or periosteum. Dead bone, on the other hand, has no such covering, and its surface is hard and rough like an unpolished stone, when felt with a probe. Dead bone that has become separated may be also detected by the x-ray (Fig. 285).

**Metallic Poisoning.**—Necrosis of the bone can follow any local infection, or even an injury. There are certain mineral poisons that cause an inflammation of the periosteum and bone, and this is very apt to be followed by necrosis. Among these poisons, mercury, phosphorus, and bismuth are the most prominent.

**MERCURY.**—This is carried by the saliva and can cause a destruction and inflammation of the mucous membrane, periosteum, and bone. In mild ptyalism the gingiva and pericementum become sore, but in severe mercury poisoning, which was formerly seen more often than at present, extensive necrosis of the bone and other tissues is of common occurrence.

**PHOSPHORUS.**—Phosphorus fumes gain entrance to the pericementum through carious teeth or from irritation of the gingivæ, and cause at first a painful inflammation and then a very extensive necrosis. In the earlier days of the manufacture of the lucifer match, this was common, but with better care of the workmen's surroundings and of their teeth, it is not so common as formerly.

**BISMUTH.**—This is probably carried by both the blood and the saliva. A case of this kind came into the St. Louis City Hospital in the service of Dr. Walter Baumgarten. In this patient, two months previously, a large quantity of bismuth paste had been injected into the pleural cavity. The pleural sinus had healed with the paste in place, but the man was much emaciated and had an extensive necrosis of the jaws. He died shortly afterward. Other such cases have been reported. Death from sepsis, starvation, and exhaustion is not an uncommon sequel of extensive jaw necrosis from phosphorus or mercury.

**ARSENIC.**—Arsenic when applied locally causes necrosis of the tissue, as does also antimony.

**PEARL WORKERS' DISEASE.**—Persons working at the manufacture of mother-of-pearl articles—such as buttons—are subject to an osteitis arising in the diaphysis next to the epiphysis, or in the periosteum. According to DaCosta, it is more apt to affect the long bones, but may occur in the bones of the face. The attack begins with pain and a moderate elevation of temperature, which lasts several weeks. The condition is apt to recur if the patient returns to his work. It is a condensing osteitis, and undergoes spontaneous cure if the patient gives up this work.

### SPECIFIC INFECTIONS OF BONE.

Besides the ordinary pus infections, there are a number of specific infections which attack the jaw-bones.

**Syphilis.**—This may affect the bones either as a thickening of periosteum, which usually occurs after the secondary lesions have dis-

appeared, or the bone substance may be replaced or killed by gumma, which is a tertiary lesion. As the periosteum and bone become infiltrated with gummatous tissue, the true osseous structures may become absorbed or necrosed. When gumma breaks down, as it is very liable to do, a defect remains corresponding to the size of the deposit, and there may be also a very extensive necrosis, of bone. A most common site of gumma is in the hard palate and bones of the nose. It is usually secondary to or accompanies gumma of the superimposed mucous and submucous tissues, and this accounts for the perforations of the palate that are so often seen in the late syphilis (Fig. 286).

**Actinomycosis.**—Actinomycosis (see page 304) is an infection with the ray fungi, which causes an inflammation, characterized by the formation of dense granulations which have little tendency to break down *en masse*, but they develop fistulæ from which are dis-

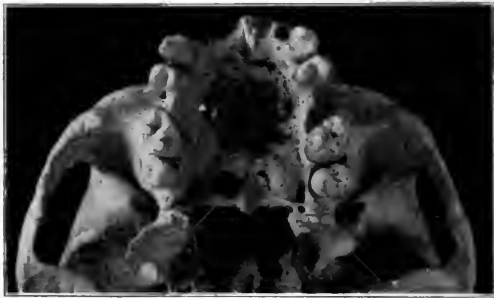

Fig. 286. Syphilitic perforation of the palate, showing partially detached piece of necrotic bone. Photographed for this book by courtesy of the curator of the Hunterian Museum, London.

charged masses of fungi. Actinomycosis has but little tendency to affect the jaw-bones; it usually occurs in the soft tissues of the gums, floor of the mouth, and in the cheek and neck at the angle of the jaw. The infection, entering through carious teeth, sometimes affects the bones; then there may also be extensive necrosis with little reproduction of new bone. There will be the usual fistulæ discharging their seropus and the characteristic yellow granules. The disease seems to have little or no tendency toward spontaneous recovery. It corresponds with "lumpy jaw" in cattle and probably comes most often from putting infected straws in the mouth. It is not improbable that other mycoses than the ray fungi are at times parasitic and cause symptoms and lesions similar to those caused by actinomycosis.

**Tuberculosis of Bone.**—The inflammation that accompanies an infection with the tubercle bacillus is characterized by the formation of granulations that are prone to break down *en masse*, leaving cheese-



like sloughs. The tubercle bacillus does not form pus, but a pus infection may occur secondarily. In comparison with the number of people whose mouths are exposed to infection from the lungs, tuberculosis of the jaw-bones is rather rare, and an infection at the epiphysis of the mandible extremely so.

A bone focus leads to the formation of a cavity which will contain granulations, perhaps a caseous material, or a sequestrum. The sequestra in tuberculous osteomyelitis rarely completely separate.

**Postfebrile Osteitis.**—Following most any of the infectious diseases, particularly typhoid fever, there may result a chronic osteo-

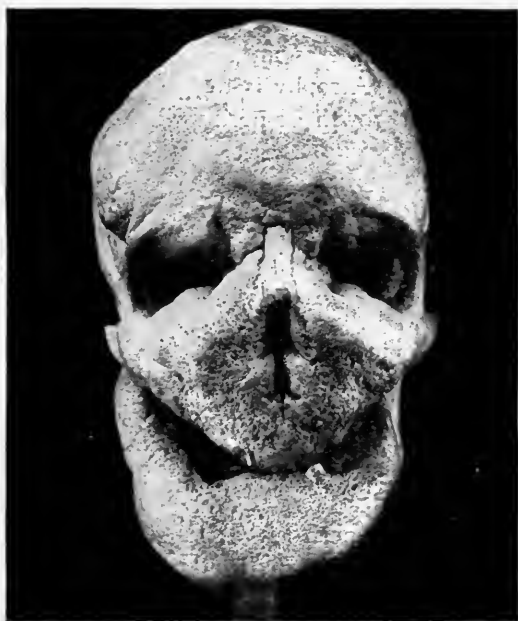


Fig. 287. Leontiasis ossea. Note the slight involvement of the nasal bones. Photographed for this book by courtesy of the curator of the Hunterian Museum, London.

myelitis which may be followed by necrosis. The typhoid bacilli may accumulate in a bone and immediately, or years afterward, on some slight provocation start an active process that ends in necrosis.

There are other rarer specific infections that affect bone, but in all, the general outline of the process is the same as in those that have been described. There is an inflammation which consists in an increased blood supply, infiltration with leucocytes, and an increase of the fixed tissue cells, accompanied by a destruction of the bone tissue by the leucocytes.

### ATROPHY.

Atrophy of the bone is a diminution of the amount of bony matter without change of structure. This comes from lack of use and is nowhere better illustrated than in the absorption of the alveolar process after the loss of teeth, or the absorption from both the body and ramus that occurs in the aged. With the loss of teeth there is a lessening of function and atrophy of muscles. The greatest loss of bone is at the angle where the internal pterygoid and masseter are attached; this causes the apparent increase of the angle seen in old, edentulous mandibles.

### HYPERTROPHY.

Hypertrophy of the bone is an abnormal growth in size and is rarely seen in the jaws. Atrophy is to be distinguished from lack of growth, while any overgrowth of normal tissue may be spoken of as hypertrophy.

### TUMORS OF BONE.

Bone gives rise to tumors, both malignant and benign, but primary tumors of the bone are always of the connective tissue type. Carcinomata may arise in the bone, due to a metastasis, or they may grow into the bone from neighboring epithelium. The latter is a common occurrence in the spread of a carcinoma from the gum to the alveolar process. Endotheliomata may arise within the bone from the contained lymphatics or blood vessels.

### LEONTIASIS OSSEA.

Leontiasis ossea is a hypertrophy, limited to the bones of the face, usually beginning in the maxillæ. The cause is not known. Besides the general deformity, it causes pressure on the nerves and organs of the face. Blindness may result (Fig. 287).

## CHAPTER XXV.

### TREATMENT OF INFECTIONS OF THE TEETH, PERIDENTAL TISSUES, AND JAW-BONES.

Cavities in the teeth should be prepared and filled. If the pulp is involved, the pulp chamber should be emptied and root canals cleaned out. The root canals are filled with gutta-percha or paraffin, and the exposed part of the cavity with some more enduring substance.

#### ALVEOLAR ABSCESS.

When infection extends to the apex of the socket, the patient often seeks relief from the pain, which may be severe and throbbing. This pain is probably made worse by an inflammation of the pericementum, which causes the sore tooth to stand above its neighbors where it is continuously being struck by the teeth above. The indication is to relieve the pressure by draining the inflamed socket. It is rather impractical to achieve this by drilling through the alveolar process, but it can usually be done by opening up the root canal and the apical foramen. The whole trouble can, generally, be relieved by extracting the offending tooth, but in some cases the trauma of an extraction seems only to help disseminate the infection. Another objection to extraction is that in some cases by proper treatment the tooth can be saved and the infection eliminated. If drainage is established, the inflammation will usually at once subside, and after the root canals and crowns are filled, the tooth may remain serviceable without giving any further trouble. Its cementum will be nourished through Sharpey's fibers from the peridental membrane. Sometimes, however, the infection remains latent, lighting up at even long intervals; some day one of these attacks may be a fulminating one. If the drainage cannot be immediately established, suppuration with perforation of the alveolar process or root canal will likely follow. In the earlier stages, we have seen astonishing relief follow a hot mustard foot-bath and a dose of phenacetin, which was ordered by a dentist. With the idea of causing the pus to point in the gum, it is the custom of dentists to apply a poultice made of a piece of dried fig which has been soaked in hot water. These are changed frequently. Hot applications made externally give comfort, but may cause the abscess to point more superficially in the face. Ice applied externally will usually limit the spread of the infection.

Any acute inflammation is best treated by keeping the patient quiet and regulating the vital functions. Small doses of calomel and quinin, given for a day or two, often have an almost specific effect on septic infections of the mouth.

A localized, tender swelling, appearing at the same time with an amelioration of the pain and fever, is a sign that the bone has been perforated, and the swelling on the gum should be incised to the bone, from within the mouth. The incision should be made parallel to the alveolar process, with the knife held obliquely so that the point will cut through the periosteum. The center of the incision should be over the point of greatest tenderness. If the incision is to be made on the lingual surface, posterior to the bicuspid teeth, the point of the knife should be inserted and kept close to the bone on account of the proximity of the lingual nerve. The incision must cut through the periosteum, for the pus is at first subperiosteal and can remain so until great damage is done to the bone (Fig. 280). If the pus is not

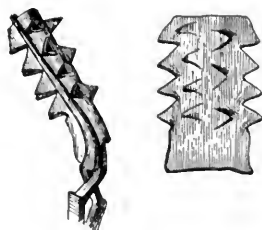


Fig. 288. Showing one method of cutting and inserting a self-retaining rubber dam drainage.

seen to flow after this incision, the knife is to be reinserted at the middle of the wound with the edge toward the bone, and the periosteum incised from the lower to the alveolar border of the jaw. It is not probable that both cuts of this crucial incision will miss a subperiosteal focus, but it does not necessarily follow that visible pus will be liberated. The swelling may be entirely an induration. As sharply outlined, well-marked indurations are often caused by the more virulent staphylococcus and streptococcus infections, it is important that these be freely drained, for any one of them may be an early stage of fulminating infection. The majority will subside without causing serious trouble, but it is a safe rule to incise every such induration, unless seen late when the symptoms are subsiding. Usually a well-executed incision will initiate convalescence, though it may be followed by some reaction, and occasionally the infection will continue to spread in spite of drainage. After the opening is made, a self-retaining rubber dam or tube drain should be carried to the bottom of the wound; and if

pain, induration, or fever persist, hot applications, both in the mouth and externally, should be used frequently (Fig. 288).

The immediate after-treatment consists further in the use of a weak solution of permanganate potassium, or any mildly antiseptic mouth wash. If the rubber dam reaches to the bottom of the wound, other local treatment will be unnecessary. However, if the wound is foul, it may be irrigated, and lightly packed with gauze saturated with compound tincture of benzoin. Whether or not the wound will heal without leaving a fistula will depend entirely upon the condition within the bone and not on local after-treatment of the wound itself.

If there is dead or diseased bone or a piece of root exposed in a bone cavity, it is probable that a sinus will persist. If, after an infection has spread beyond the alveolar process, it is decided to remove the offending tooth or roots, we believe there is sound reason in waiting for the acute symptoms to subside somewhat.

In many cases, where rapid extension of an infection has followed the extraction of a tooth, the dentist has been blamed on the theory that his instruments were not clean. There is no more justice in this than to conclude that because a peritonitis follows an appendectomy it was due to infection introduced at the operation. The infection from a tooth root spreads from near the apex of the socket, a part rarely directly reached by the jaws of the extracting forceps. Both the appendix and the tooth are removed because they are diseased, and the diffuse infection that may result is, in either case, due partly to trauma of the operation and partly to a lack of resistance to the infection. If in the presence of disaster any blame is to be attached to the operation, it must rest either upon the technic or upon the time that it was chosen. In the extraction of teeth there is not much choice in the selection of technic, and in the selection of time, the dentist, like the surgeon, can only exercise his best judgment.

### RETRACTION OF THE GUMS.

Retraction of the gums, being largely dependent upon irritation at the gingivæ, is to be prevented by keeping the necks and roots free from tartar and treating irritations when they appear. If the roots are exposed and pockets have formed between the root and peridental membrane, these are to be cleansed, and the membrane treated. As the gums retract, the alveolar border of the bone is absorbed, and this process may continue until the roots are left without proper support.

As age advances and the cusps of the teeth are worn away, a certain amount of gum retraction is physiological; by this means the roots of the cuspids and bicuspidis may present good, useful chewing surfaces after the crowns have been entirely worn away. If isolated

teeth or the whole set become too loose for function, they may be braced by a continuous bridge or splint into a fairly solid mass.

### PERICEMENTITIS.

As the peridental membrane is not accessible for direct medication, the treatment of an acute pericementitis consists in relieving the cause and protecting the inflamed membrane from violence.

The cause may be a stomatitis, mineral poisoning, apical or marginal infection, or some constitutional disease—such as scurvy or gout, or other autointoxication. When the peridental membrane becomes inflamed, it pushes the tooth slightly out of its socket so that it receives most of the impact of the closing jaws, thus causing a constant irritation with consequent pain. If the inflammation lasts long enough to demand relief from this, it is best accomplished by building up the crowns of several neighboring teeth with oxyphosphate cement or with temporary crowns of some kind, so that the sore tooth will not occlude.

### PYORRHEA ALVEOLARIS.

Pyorrhœa alveolaris is a destruction of the peridental membrane by a suppurative inflammation, which usually proceeds from the gingival margin (Fig. 279). There are two separate considerations in treating pyorrhœa alveolaris: the elimination of the disease, and the preservation of the natural position of the teeth. The roots are to be scraped free of tartar and dead or spongy bone; and all suppurating peridental membrane is to be removed, and the sockets kept clean, in the hope that healthy granulations will spring up and eliminate the space between the bone and the root. In some cases the infection can be eliminated or held in check by the use of specific vaccines, according to the method proposed by Wright (see Chapter II). We have seen good results from this, and there have been a number of confirmatory reports on the subject. Any depression of the general condition should receive attention.

If the teeth once become loose, the lateral pressure of the roots on the inflamed bone hastens absorption of the latter so that the teeth will wobble in their sockets (Fig. 282). If the disease affects only a few teeth, they can be anchored to their firmer neighbors, but if all, or most of them, are involved, they can be banded together in one mass, which will give stability to all of them. The hopelessly diseased teeth, those in which the peridental membrane is almost entirely destroyed, will have to be removed.

The disease, having once been established, is liable to recur. The patient should exercise exceptional care of the mouth and should keep himself under the observation of his dentist.

### ALVEOLAR FISTULA.

With rare exceptions a fistula running toward the jaw-bone is simply an emergency drain, created and maintained for the purpose of carrying off a pathological excretion, and it will persist as long as this abnormal excretion continues; therefore the treatment of an alveolar fistula is the treatment of the pathological condition that causes it. In other parts of the body fistulæ often persist on account of the scar that lines the wall, or on account of disease of its wall. However, with the exception of malignant growths and actinomycosis, we have never seen a fistula about the jaws that was not compensatory for some pathological condition at its deeper end, and no amount of operating on or treatment of the fistula itself will cure it. We have seen cases, in which as many as four operations had been done on the soft tissues of the face without effect, that at once closed on the

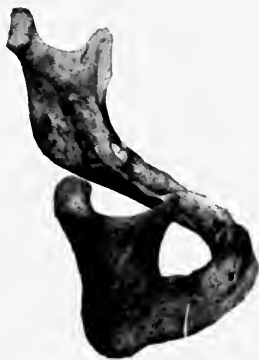

Fig. 289. Jaw of an old person, showing an unerupted third molar tooth.

removal of the diseased root (Fig. 281). The common causes are: a root exposed in an affected bone cavity; an infected cavity surrounded by soft bone, or too large to close by granulations, or prevented from doing so by a piece of dead bone; or an infection around an unerupted tooth. The last condition is a not uncommon cause of persistent fistula in the gum of a person who has apparently lost all of his teeth (Fig. 289). Disease of the maxillary antrum may sometimes drain through a sinus leading into the mouth.

### NECROSIS.

It is not the dead bone that is to be treated, but the tissues that surround it. Sepsis is usually the cause, and it always accompanies necrosis of the jaw-bone. The treatment must cover four points: the elimination or control of the cause, if it is still active; the establishment of free drainage of infected areas; the support of the general condition of the patient; and at the proper time, the removal of the dead bone.

If the necrosis follows an injury—such as the splintering of the lower jaw-bone by a bullet or in a comminuted fracture—it is usually not mechanical violence that causes the necrosis, but the fact that an avenue of infection has been opened which can destroy the remaining source of nutrition of bone spiculæ that might otherwise have survived the original injury. Therefore, in all comminuted fractures and in gunshot injuries, free dependent drainage from the site of the bone injury should be immediately established, but only such pieces of bone as have absolutely no periosteal attachment should be removed at this time.

If the necrosis results from an infection, or an infection preceded by a mineral irritant, this must be dealt with. The fundamental treatment of infection is drainage. Not only the pockets in the diseased tissues should be drained, but the infectious material that collects in the mouth should be rapidly removed. The presence of fever and other signs of sepsis will indicate the necessity of drainage, while local swellings and indurated or soft points of tenderness or pain will indicate the site that is to be drained. The drainage must be free, and as many incisions should be made as are necessary. It may be that there are several distinct pockets, or just one space which can be drained through one well-placed opening. When possible, these incisions should be made from the inside of the mouth. The lingual nerve lies to the inner side of the body of the mandible below the molar teeth, separated from the periosteum only by the mylohyoid muscle. It might be cut by a badly planned incision.

When the infection extends around the lower border of the mandible, intraoral incisions are rarely efficient. External incisions may be made along the lower border of the jaw which will leave no permanent disfigurement, and one or several external incisions should be made here wherever pus tends to collect at this site. The facial artery crosses the body of the lower jaw about 2 centimeters in front of the angle, and a motor branch to the depressor muscles of the mouth crosses obliquely by several filaments over a space of 2 centimeters in front of the artery. If prepared to tie it, there is no objection to cutting the artery, but the whole nerve should not be cut if avoidable. An incision over the nerve may be safely made if only the skin and superficial fascia are cut with a knife, and the other tissues are penetrated with a sharp-nosed artery forceps; and the opening is completed by spreading the blades (Hilton's method). If a depressed scar should result, the scar can be excised later, and all trace practically eliminated by careful suturing. Deep, narrow incisions should be kept patent with a rubber dam or tube drain; wide ones may be lightly packed. Drainage from the mouth cavity is accomplished by the frequent use



of a mouth wash, if the patient can use it properly, or by irrigations from a douche can with a soft catheter passed into the mucous spaces of the fornices and below the tongue. If the excretion is excessive, the patient should be turned on his side so that it will run from the mouth in preference to being swallowed.

Regardless of what incisions are necessary, they should be sufficiently free to gain all that is to be accomplished by drainage. In critical cases, when life seems to be at stake, much of the septic absorption can be prevented by deep, extensive incisions that parallel or enter the inflamed areas, even before any distinct pockets of pus have formed. But in just such cases the drainage should, if possible, be established at one thorough operation; for the repeated hemorrhage and shock of several operations might be the determining factor of fatality.

The source of metallic poisons should be cut off as soon as possible. A deposit of bismuth paste in a cavity should be washed out with olive oil, and the bowels kept freely open. A phosphorus worker should leave his work and begin sulphate of copper internally until the limit of tolerance is established. The sulphate of copper converts the free phosphorus into the insoluble copper sulphid. Whether this would have a beneficial effect on the phosphorus already deposited in the bone and periosteum may be doubtful, but it would render inert any free phosphorus in the circulation.

Mercury necrosis is secondary to the ulceration of the mucous membrane, the saliva being a carrier of mercury. Hydrogen peroxid solution is probably the best local application to limit infection in the presence of mercurial irritation. The use of potassium iodid internally has been recommended to eliminate the drug, but according to Cushney, its efficiency has not yet been established beyond dispute.

In most cases of extensive necrosis of the jaw, there is a profound depression due partly to sepsis, partly to pain, lack of food, and inability to sleep. As already described, sepsis is to be combated chiefly by drainage; one would hesitate to use vaccines in a profound sepsis. Relief of pain and proper feeding are also important. Most of the pain will be relieved by proper incisions; these may be supplemented by an anodyne or a hypnotic, but they are not to be substituted for the incisions. Frequent liquid feeding, a little strychnin, alcohol, or other stimulant, with rest in bed, are to be resorted to in every case of any gravity. These patients sometimes linger for many weeks and then die of exhaustion. When this occurs, one cannot but feel that possibly something else might have been done that would have helped to tide the patient over.

**Removal of the Sequestrum.**—Though a constant mechanical irritant, the necrosed bone is not to be removed until it has been cut loose

from the living bone by the leucocytes, because, until this has occurred, it is practically impossible to determine the line of cleavage between the two. After the sequestrum is cut loose, it has only to be lifted out of its bed. It may be necessary to make an incision through the soft tissues and possibly through some bone before its bed is sufficiently exposed to allow of removal. Usually from three weeks to three months will elapse before a sequestrum is ready to be removed. Tuberculous bone disease is an exception to the rule of waiting until the sequestrum is loose. Here the dead bone is to be removed with a curette, as it is not thrown off cleanly as are other sequestra.

If the necrosis is the result of syphilis, even if loose, the sequestrum should not be disturbed until the patient is fully under the influence of antisyphilitic medication, as a mechanical injury is liable to cause an extension of the infection.

If the full thickness of the jaw becomes necrosed, the sequestrum is not to be removed until enough new bone has been deposited by the surrounding periosteum to form a rigid casing to the gap. Otherwise artificial mechanical support will have to be provided; for the periosteum at this site would crumple up, and a deformity would result proportionate to the extent of the necrosis. The sequestrum should be left in place to serve as a splint to the new-forming bone and should not be removed for three months. It has been observed that where the whole mandible dies it will regenerate, but later the new jaw may atrophy, probably because, containing no teeth, it lacks function.

### CHRONIC BONE ABSCESS.

While an agency of infection is still aggressive, we can do little but provide drainage and care for the patient until sufficient antitoxins are furnished naturally or artificially to modify or overcome it. In most parts of the body this is all that is necessary, for, as soon as the infection is neutralized, healing progresses without interruption. In bone abscesses there are mechanical hindrances that handicap the reparative process to such an extent that surgical intervention is often necessary.

When a defect in the soft tissues, due to actual loss of substance, heals, we often speak of the cavity having been filled with granulations. This is not the case, however, as the granulating surface is ordinarily never more than a few millimeters thick. What happens is that the older and deeper cells are soon converted into scar tissue which forms a contracting layer attached at its edges to the skin or mucous membrane that borders the wound. As this scar layer decreases in size, it draws on the skin or mucous borders like a puckering string, which lessens the circumference of the wound; it also draws the borders down toward the floor of the wound and the tissues of the floor up toward

the surface, which lessens the depth. As a result, when final healing takes place, it will be found that the edges are slightly depressed, and the amount of scar remaining is but a very small fraction of the original size of the defect. What has happened is that the defect is obliterated, not by being filled with granulations, but by the granulations drawing in the neighboring tissues. Shallow bone cavities heal by having the neighboring soft tissues drawn into them, but the natural healing of a deep cavity with a narrow outlet can occur only by being actually filled by the granulations (Fig. 290). This is an extremely slow process, for after a certain time contraction in the deep scar layer of a healing surface interferes with the nutrition of the superficial granulations; they become indolent and easily affected by even mild infections. We may

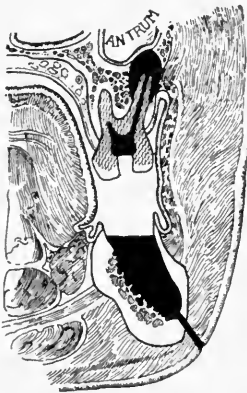


Fig. 290.

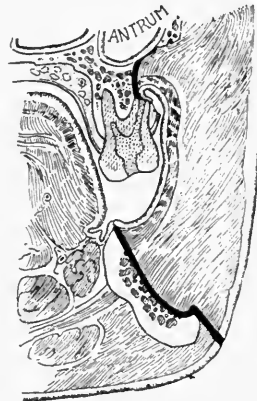


Fig. 291.

Fig. 290. Diagram of an infected bone cavity in the lower jaw with a sinus discharging through the skin in the submaxillary region; also of a bone abscess in the upper jaw under the mucoperiosteal lining of the antrum.

Fig. 291. Diagram of the condition shown in the preceding figure, after the removal of one wall of the abscess in the lower jaw, and after removing one wall of the abscess in the upper jaw and amputation of the tooth root that extended into the cavity.

burn or scrape the indolent and diseased granulations down to healthy tissue, but if the circumstances remain the same, the same condition in the granulations will recur. It is for the reasons cited that abscess cavities in the substance of the bone heal, if at all, very slowly, and for the same reasons the surgical treatment of chronic bone abscesses is their immediate obliteration. The best plan of doing this is to bring one granulating surface in direct contact with another granulating or raw surface, so that healing will occur between them. When this cannot be done, the slight pressure of gauze, wax, or any other non-irritating substance seems both to protect and to stimulate the cells to the extent that they are able to cope with most subacute or chronic infections.

The most powerful antiseptic we have at our disposal, one upon which, consciously or unconsciously, we are almost entirely dependent for overcoming every infection, is the activity of the living tissue cells. Our hope of eliminating infection from such cavities is not the use of chemical antiseptics, but in maintaining the health of the exposed cells.

Before attempting to obliterate a bone cavity, any mechanical irritant—such as a tooth, root, sequestrum, spongy bone, or diseased granulations—should be removed, but this does not necessarily apply to the protective granulations that line the ordinary chronic bone abscess. Cavities in the alveolar process will usually heal after the tooth is removed. There is usually some remaining root membrane which will form new bone to obliterate the deeper part, and as soon as the tooth is removed, there will be an absorption of the upper part of the lateral walls. A light packing of gauze will keep the granulations in a healthy condition. If the cavity extends deeper in the body of the bone, it will have to be obliterated artificially. One method of doing this is to fill it with some substance; another is to remove one lateral wall, thus converting a deep narrow space into a wide shallow one into which the soft tissue can be easily drawn (Fig. 291).

**Obliteration of a Cavity with Bone Plombe.**—Artificial substances made to fill cavities resulting from the destruction of bone are sometimes termed “bone plombe.” There are two kinds of fillings: the absorbable made from an animal tissue or animal wax—to which class belongs the bone wax of Mosestig-Moorhof; and the very slightly absorbable—to which latter belongs Beck’s bismuth paste.

A formula of Mosestig’s filling is:

- Spermaceti, 30 parts.
- Oil of sesame, 15 parts.
- Crystal iodoform, 10 parts.

In the mouth the iodoform is objectionable, and some other mildly antiseptic substance—such as pulverized colloidal silver, insoluble in oil or wax, xeroform, or bismuth subiodid—had best be substituted. This liquid paste is either poured into the prepared bone cavity in a liquid state or is forced in while hot enough to be plastic.

Beck’s paste consists of:

- Bismuth subnitrate (c. p.), 30 parts.
- White wax, 5 parts.
- Paraffin, 5 parts.
- Petrolatum, 60 parts.

This makes a semisolid mass, which should be slightly warmed before being used.

In the parts of the body where the cavity is accessible and can be rendered and maintained aseptic, it is customary to scrape out all gran-

ulations down to healthy bone and then attempt to sterilize the cavity by first pouring in 95 per cent carbolic acid, removing the excess with alcohol. The cavity is then filled with Mosetig's bone wax, or decalcified bone chips, and the soft tissues covering the cavity are then closed without drainage. If by this method infection has been removed, there will be no suppuration, and the filling is eventually absorbed. In chronic suppurating cavities which are less accessible, many remarkable results have been obtained by simply filling them with Beck's bismuth paste. It has been used mostly in fistulæ running to bone cavities, about tuberculous joints, or in chronic empyema. One injection will sometimes cure a sinus that has persisted for years. When used in quantity, there is danger of bismuth poisoning. In one case reported by David and Kaufmann, death, with necrosis of the jaws, resulted after an injection of 6 ounces of the paste.

It is on account of the impossibility of maintaining perfect asepsis in a cavity communicating with the mouth that methods requiring this are not applicable here. When a cavity is cleansed by the method described above, or even simply curetted, a certain amount of injured or dead tissue will remain, which furnishes a culture medium for any remaining bacteria. In the mouth dependence must be placed upon the antiseptic power of the uninjured cells in the granulations, but the cavity must be free from diseased or dead bone or diseased granulations. If it contains any of these, they must be removed, but after doing this, it is better to treat the cavity with light gauze packings until healthy granulations line the walls; then it may be filled with the bone plombe. It is hardly necessary to state that bone plombe is not to be used when the cavity is the seat of any active infection.

If the cavity communicates with the mouth by a very narrow opening or fistula, Beck's paste is applicable; for it is improbable that poisoning will result from the few cubic centimeters that will be required to fill a cavity in a jaw, and it is impossible to dry out such a cavity before inserting the plombe. If the opening is free, then the wax is to be used, since the paste would not stay in place. To use the wax, the cavity must be dry. It may be made so by gentle gauze packing or by a stream of hot air, but the granulations must not be injured. The paste is forced into the cavity in a semiliquid state, from a syringe or a collapsible metal tube which has a tapering nozzle that will fit tightly in the opening of the cavity or sinus. The whole cavity must be filled, leaving no dead space in which fluids can collect and bacteria propagate. The bone wax is put into the cavity in a plastic condition, either with a syringe or tube, or forced in with a wax spoon or some metal instrument. By using the proper fittings to a hypodermic syringe, the bone plombe can be forced through a root canal into an

apical bone cavity. In working with bone plombe in the upper jaw, it must be remembered that the material might be forced into the maxillary antrum or between the bone wall of the antrum and its mucous lining. The quantity of the material entering will somewhat serve as a guide. Whether filling a suppurating antral cavity with Beck's paste is good treatment is another question. If the first attempt to close a cavity with bone plombe is not successful, it may be repeated. When the cavity is in suitable condition, the use of bone plombe has the advantage of requiring no cutting operation and involving no detention from ordinary pursuits. It has the disadvantage of an uncertainty of the result.

**Obliteration of the Cavity with Living Tissue.**—This is done by removing the thinner of the bone walls which bound the cavity, by the use of biting forceps or a bur. This can usually be done through the mouth, but sometimes a supplementary incision along the lower border of the jaw is necessary. After the cavity is cleansed and one wall removed, it may then be lightly packed with gauze for a few days, when no further treatment than a mouth wash should be required. We believe that unless there is some contraindication, this is better surgery than the use of bone plombe (Fig. 291).

Where only the apical third of an incisor, cuspid, bicuspid, or one whole root of an upper molar lies in an abscess cavity or in spongy bone, it is not necessary to extract the tooth, if the root membrane covering the other part of the root or roots is healthy. In such cases the exposed part of the root may be amputated, and the bone cavity treated as previously described (Fig. 291). Under a local anesthetic a semi-lunar incision is made several centimeters long with its center corresponding to the diseased root. The concavity of the incision is toward the fornix. This incision extends through the periosteum, and all of the included tissues are raised from the bone in the form of a flap and held with a small retractor. Sponging is done by an assistant, with small balls of wet cotton, and if the field is obscured by bleeding, this may be controlled by the application of adrenalin chlorid solution. It is probable that a fistula or bone cavity will be exposed. If not, the soft spot or cavity is to be located by the use of a sharp steel probe. The cavity or soft spot is to be cleaned out with a curette or bur, and the exposed root amputated by means of a cross-cut fissure bur or a small plain drill, the latter being Dr. Gilmer's custom. After the operation the cavity is to be lightly packed with antiseptic gauze for a few days, after which no further treatment but a mouth wash is needed. It has been recommended to remove the flap of soft tissue that was raised in exposing the cavity, but we are very certain that this is not a good practice. When the flap is left, its periosteal surface is drawn

into, and helps fill, the bone gap with bone tissue, the whole being covered with normal mucous membrane. If the flap is removed, the bone cavity can be lined only with granulations which result in scar tissue surface; and if a deep depression persists, it is a catch-trap for food particles. If the granulations lining a bone cavity or covering a surface are unhealthy, they should be removed along with any diseased bone, and the cavity treated as already outlined.

### SPECIFIC INFECTIONS.

**Actinomycosis.**—If a necrosis is due to actinomycosis, after treating the local infection, the patient is to be given large doses of potassium iodid or copper sulphate for an extended period. Potassium iodid is the older treatment, but based upon observations made at the experimental agricultural station in Wisconsin, Bevan first treated this disease in man with copper sulphate and reports very good results.<sup>1</sup> After removing the granulations, the cavity might be packed with gauze, wet with weak copper sulphate solution.

**Tuberculosis of the Jaw-Bones.**—Tuberculosis of the upper and of the lower jaws run radically different clinical courses. The virulence of the infection increases in proportion to its distance from the orbit. Metastatic infection of the body of the maxilla runs the same mild course as does a tubercular infection in other bones. Infections of the upper alveolar process and palate are more severe, while in tuberculosis of the body of the lower jaw the disease is aggressive, and unless checked by very radical treatment, usually terminates fatally within two or three years.

The treatment of infections of the maxilla is the same as that of other bones. The cavity is curetted and obliterated, with either living tissue or some bone plombe. Infection of the palate or alveolar process usually takes place within the mouth. It will usually yield to curetting and repeated applications of lactic acid.

In the lower jaw infection from the mouth follows a somewhat similar course as infection of the upper alveolar process and palate, but is more malignant. Unless due to an extension from a tubercular ulcer of the tongue, it is, however, less malignant than a metastatic infection of the body of the lower jaw, which latter usually occurs somewhere along the lower border. In metastatic infection of the mandible, there may be a hard swelling, usually followed by persistent trismus, but with little pain and few constitutional symptoms. Later there will be softening and fistula, with caries and necrosis of the bone. There will be early infection of the lymph nodes and later of the other soft tissues of

<sup>1</sup>For dosage and toxic symptoms of potassium iodid and copper sulphate see textbook on materia medica.

the neck and of the bones of the base of the skull. The disease usually ends fatally in a very few years.

In the early stages only a microscopical examination and possibly the injection of a guinea pig will make the diagnosis certain. In the later stages the diagnosis is less difficult. The early enlargement of the lymph nodes should help to distinguish it from actinomycosis, which rarely causes lymphatic infection. The discharge from an actinomycotic fistula usually shows some form of fungi, while the discharge from a tubercular lesion will, when properly treated, show the presence of the tubercle bacilli. If Much's contention is correct, viz., that the tubercle bacillus is one of the mycoses, then the two diseases are related both in their etiology and in their clinical course. In its earlier stages, it is to be distinguished from sarcomata only by a microscopical examination. Even later this may be necessary.

Carcinoma of the lower jaw is never primary and is due usually to extension from some perfectly evident neighboring focus. Carcinoma may arise in the mucous lining of the antrum, but the age of the patient will usually give a clue to the diagnosis—carcinoma rarely occurring before forty and tuberculosis rarely after thirty years, but there are exceptions to these rules.

The treatment of tubercular infections of the lower jaw should be as radical as of carcinoma or tuberculosis of the tongue. If seen and diagnosed early, a wide local excision in healthy tissues, with or without extirpation of the lymphatic nodes, should be done. The operation upon the lymphatic nodes had best be postponed until time has demonstrated the probable success of the operation on the primary focus. For indications and technic of treatment of tubercular adenitis, see Chapter XXXVII. In all cases the usual hygienic treatment should be carried out.

**Syphilis.**—Syphilitic lesions are to receive no local treatment, except the use of mildly antiseptic washes, until the disease is well under control. Then, and then only, may sequestra be removed.



## CHAPTER XXVI.

### SEPTIC INFECTIONS OF THE FLOOR OF THE MOUTH AND NECK.

Septic infections of the neck are usually secondary to some infection in the mouth, nose, or pharynx, and in many of them the teeth are the portals of entry. From the mouth the infection travels into the neck by one or two routes: (1) by extension along the cellular tissue planes, or (2) through the lymphatics. In many, if not most instances, the infection travels by a combined route, but usually either the lymph nodes or the tissue planes show the greater involvement, and the resulting inflammation is designated accordingly as an adenitis or cellulitis.

#### ACUTE ADENITIS.

This may vary from the enlargement of one or several nodes, which may quickly disappear with the subsidence of the primary focus, to the rapid swelling of a number of nodes in one or several groups, accompanied by pain, fever, suppuration, and diffuse periadenitis. Naturally, one of the upper groups of nodes is most commonly affected. The inflammatory process may remain limited to the neighborhood of the involved nodes, or may be widespread. When a gland capsule ruptures, the pus is liberated between the cellular planes, but it may still remain localized, held in place by a wall of granulations. In a very acute infection, the pus may form more rapidly than it can be walled off, in which case it will travel along the tissue planes under the deep cervical fascia and may enter the mediastinum or the axilla. A localized abscess may, if neglected, rupture spontaneously through the skin or travel along the tissue spaces and cause death before the pus can reach the surface. For this reason, the early drainage of suppurative adenitis in the neck is very important. Owing to the number of protecting lymph nodes in the neck, general infection through the lymphatics is not common. After proper drainage, if not too long delayed, recovery usually takes place. In the non-suppurative forms resolution may be long delayed, and a chronic hyperplasia of the nodes may result.

#### ACUTE CELLULITIS.

The most common instance of this is the swelling of the cheek or floor of the mouth which usually accompanies an "ulcerated tooth."

This usually subsides spontaneously, but it may terminate in an abscess contiguous to the mouth. In the neck it is not so common as adenitis, but some local periadenitis always accompanies a suppurative adenitis.

**Ludwig's Angina.**—In one form, the infection of the cellular planes is so rapid or so extensive as to overshadow the lymphatic involvement. This presents such typical clinical characteristics that it is called Ludwig's angina, after the man who first described it. This is an acute spreading infiltration of the soft tissues, starting in the floor of the mouth and submaxillary region, which binds all the structures into a hard, board-like mass. The swelling is attached to the jaw-bone on one or both sides and presses the tongue upward and backward in the pharynx. The roof and side walls of the mouth are unyielding, and any hard swelling in the floor must crowd the tongue backward. Though not very common, Ludwig's angina is of great interest, because in the past it has been credited with a mortality of about 40 per cent.

Its existence as a definite clinical entity has been the subject of considerable discussion. We have seen a sufficient number of cases to conclude that it is as definite in its pathology and clinical signs as pneumonia or peritonitis, either of which may be caused by any one of a number of infectious agents. The trouble often starts in a sub-acute swelling which may remain indolent for some days or weeks, but when it becomes active, the swelling spreads rapidly until the whole floor of the mouth and front of the neck may be involved. At first the skin is not red but pale and immovable on the subjacent swelling, and does not pit on pressure. There is little constitutional disturbance, and though the patient will usually hold the mouth slightly open and may feel more comfortable sitting up, the respiratory impediment may go almost unnoticed. Within the mouth the induration may be felt in the floor on one or both sides, and the submucosa may be so edematous as to rise above the level of the teeth in a gray roll. In this stage resolution may take place spontaneously, but more commonly, if untreated symptoms of grave sepsis develop and the patient survives long enough, there will be discoloration of the skin with diffuse suppuration, or partial gangrene of the deeper tissues. Pneumonia is not an infrequent complication, and if the swelling extends back into the pharynx, there may be edema of the glottis. Death in from 7 to 20 days is a frequent sequel of the untreated cases. It has been our observation that the most frequent starting-point of the infection of the cellular tissue has been a suppurating submaxillary lymph node or a collection of pus in the floor of the mouth. However, in a series of typical and atypical cases represented before the St. Louis Surgical Club, February, 1909, we reported one in which the infection started in an upper tooth, first involving the tissues of one side of the head and face before reach-

ing the submaxillary region. In another the infection started from a sarcomatous ulcer of the lower jaw, while in a third it started in an abscess under the thyrohyoid membrane. In all of these there was the board-like swelling of the floor of the mouth and grave sepsis with respiratory impediment. It is difficult to obtain pure cultures from abscesses of the mouth, but there is a pretty general opinion that this form of infection is usually due to streptococcus. From the freshly cut tissues in some cases we have obtained a streptococcus in pure culture—less frequently *Staphylococcus aureus*. It has been noticed that the disease may at times be mildly epidemic.

### CHRONIC ADENITIS.

This is usually due to the persistence of some focus within the mouth or pharynx, but at times it would appear as if the infection remained semiactive in the nodes themselves. Usually, after the subsidence of an acute infection, the adenitis disappears, but it may take on a chronic form in which the nodes remain enlarged or may even continue to increase in size. This may occur in one or several groups. On section such enlarged nodes will usually show a simple hyperplasia; and occasionally an abscess may develop. Septic infection of the lymphatic nodes sometimes seems to be the predisposing factor of a tuberculous adenitis, and we have seen endothelioma and Hodgkin's disease start in cervical lymph nodes that were infected from carious teeth. In both instances the nodes were examined microscopically by Dr. Downey Harris while in the inflamed stage, when neither endothelioma nor Hodgkin's disease could be demonstrated.

### CHRONIC CELLULITIS (HOLZPHLEGMON).

This is an indolent hard infiltration of the cellular tissue that may be sharply limited and very resistant to treatment, often lasting for months. Unlike Ludwig's angina, it is not confined to the floor of the mouth and front of the neck, but more often attacks the lateral aspect of the neck. It develops slowly and causes few or no constitutional symptoms and little or no suppuration. Fichter reports five cases in which he found numerous pus organisms. We have found the streptococcus and *Staphylococcus aureus* in pure culture in different cases. After persisting for a period of time, the induration subsides, leaving little or no trace of its former presence.

### TREATMENT OF ACUTE ADENITIS.

This will depend somewhat upon the virulency and extent of the infection. In simple enlargement the nodes themselves need no special attention, even though they be rather tender, but ice may be applied to

the neck; and the intraoral focus, or angina, should be treated. When from the general symptoms and the periadenitis, with increased local tenderness, it is believed that suppuration has occurred in one or several nodes, these should be opened and drained; and at the same time a culture should be made. In case prompt recovery does not occur, an autogenous vaccine can then be made. If the pus is superficial and definite fluctuation can be detected, the drainage incision may be made directly into the abscess, or, after incising the skin, the fascia may be penetrated with a round-nosed artery forceps, after the plan of Hilton. The opening should be large enough to admit the gloved finger. A counter opening is made at the most dependent point, and a strip of rubber dam is drawn through these two openings, to be left in place until all active secretion ceases. The skin incisions should always be made transverse to the long axis of the neck, when they will leave almost no scar.

Very often, in the more virulent infections, there will be clinical evidence of suppuration, while the pus is still too deep or the quantity is too small to be detected by the palpating finger. Small foci of suppuration may be present in a number of nodes buried beneath a thick layer of inflamed periglandular tissue. It is safe in few parts of the neck to make deep stab incisions for drainage. When pus is suspected to be deep in the nodes, it is a better and more expeditious procedure to expose the mass of inflamed glands, which may be done through Kocher's transverse incision or by an incision running along the border of the sternomastoid muscle. The former is a little more difficult, but gives a much less noticeable scar. Most of the deep cervical nodes lie under the sternomastoid, and this muscle will have to be retracted to expose them. Large, softened nodes may be punctured with a round-nosed artery forceps or, very exceptionally, shelled out, and dependent drainage made with a rubber dam. The wound of approach may be packed or sutured at the operator's discretion, but the whole operation should be done quickly and thoroughly. While the very early liberation of pus is conducive to both the safety and the comfort of the patient, still prolonged or repeated operations for sepsis are always to be deplored. If, at the time of the operation, it is suspected that pus has found its way into the mediastina, then the patient should be placed in a bed, the foot of which is very much elevated so that the drain in the neck will be at the most dependent point.

#### **TREATMENT OF ACUTE CELLULITIS.**

The safest treatment of all septic indurations of the floor of the mouth is early free incision. Any particular induration might subside without incision, but one cannot tell which of them is the early stage

of virulent infection. If the induration is entirely above the mylohyoid muscle, the incision may be made within the mouth. If it is around a stone, this may be removed at the same time, but if it arises in connection with an infected tooth, it is not always safe to draw the latter until the inflammation has subsided. For a deep, extensive induration that can be felt from below the jaw, the incision is usually made best from the outside. We do not mean by this that an external wound is to be made for every infection about the lower jaw. We do believe that deep, hard, septic indurations of the floor can be better drained and more safely approached from the outside than from within the mouth, and that, if the incision is made under the body of the jaw, it will not cause a noticeable scar. The mylohyoid muscle is divided with forceps

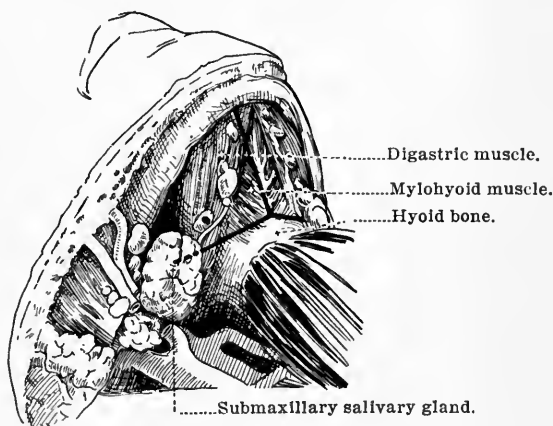


Fig. 292. Location of the submental and submaxillary lymph nodes. Lines of incisions for dividing the digastric and mylohyoid muscles in an indurating cellulitis of the floor of the mouth.

in the direction of its fibers. In Ludwig's angina, as pointed out by Thomas, there is the double indication of free drainage of all of the cellular planes and of freeing the mouth from the upward pressure in the floor. This we believe can be best accomplished by the incisions shown in Fig. 292.

The skin is infiltrated with a  $\frac{1}{4}$  per cent solution of novocain, and an incision is carried from the tip of the chin to the hyoid bone and from the latter point outward under the angle of the jaw as far as the outer margin of the induration. The median incision and the median part of the lateral incision are carried boldly through the deep fascia, but as part of the lateral incision might pass over the fascial vein and carotid arteries, it is made with more precision. The tissues cut as if they were frozen and bleed but little. A flap is drawn upward

exposing the digastric muscle and the lower part of the submaxillary gland. Here a suppurating lymph node is often found. If there is any induration in the floor of the mouth above the mylohyoid, this muscle and the anterior belly of the digastric are cut through on the lines shown in Fig. 292, when search can be made for pus. In the floor it is usually found along the inner surface of the body of the jaw, but in one case we found it deep in the substance of the tongue. If the induration has crossed the midline, the same incisions are made on the other side, but in no instance are the geniohyoid muscles to be cut. These incisions allow the indurated sections to roll outward, which frees the floor of the mouth (Figs. 293, 294). In every instance but

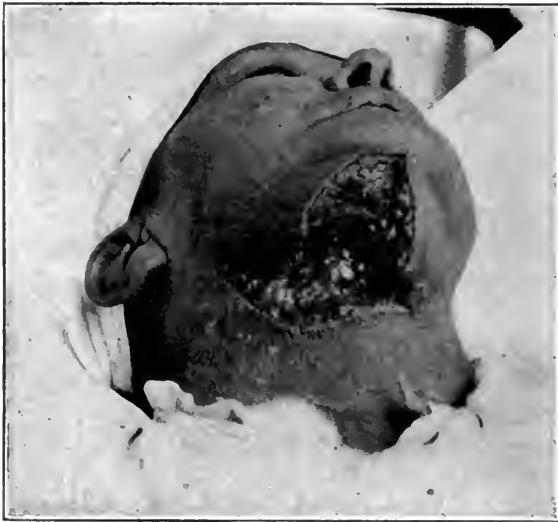

Fig. 293. Showing how the tissues open up after making the incision described for Ludwig's angina.

one, when done early, the operation has in our hands been followed by early recovery. When the induration subsides, the tissues drop back into place, and but a linear scar remains (Fig. 295). If the induration has extended down the neck below the hyoid bone, then a vertical incision is made in the midline, which allows two more triangular flaps to be retracted. In the latter cases careful search for pus should be made among the infrahyoid muscles. In one instance already mentioned, pus was found beneath the thyrohyoid ligament, and recovery took place. The wounds are packed with gauze and are never sutured. Extreme restlessness may result from sepsis, but it is often caused by partial obstruction to respiration. If after proper incisions in the floor of the mouth restlessness persists, which is not relieved by a sedative but is

partially relieved by allowing the patient to sit up, then tracheotomy is to be considered, and if one can be satisfied that the respiratory impediment is not due to pneumonia, the tracheotomy should not be delayed too long.

These patients should have general supporting treatment and sleep.

### TREATMENT OF CHRONIC ADENITIS.

The first indication is a search for some septic focus that can be keeping up the irritation in the lymph nodes; and the general hygiene of the patient is to receive attention. In the rare instances where single groups of nodes continue to enlarge without apparent cause, it is

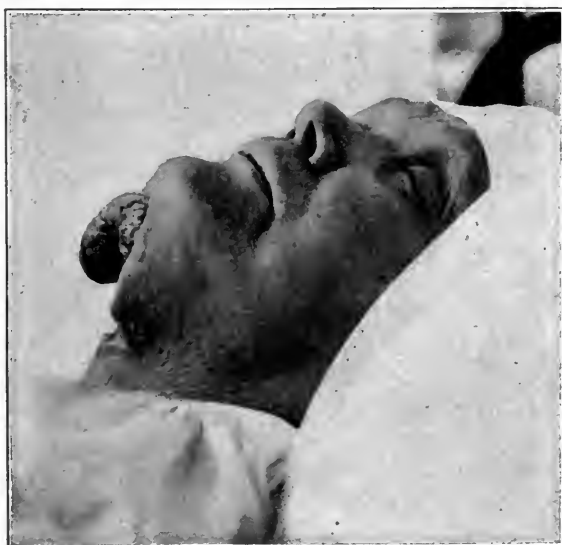

Fig. 294. Lateral view of patient recently operated for Ludwig's angina, further illustrating how the tissues open up.

often well to dissect these out *en masse*. All pathological enlargements are to be regarded with suspicion. If the enlargement is due to an encapsulated septic infection, it is well to have it out, but it is not improbable that on section it will be found that some graver change has occurred—such as tuberculous infection—or even that the growth is due to an actual tumor of the nodes. Before making such an excision, the surgeon must satisfy himself that the enlargement is not simply a part of a generalized disease of the lymphatics, such as Hodgkin's disease, and is not secondary to some other focus.

These dissections are often made very difficult by the scarring that has occurred in the periglandular tissue. After the removal of the mass of chronically diseased nodes, the wound is to be closed with proper

drainage, which latter is to remain in place as long as there is any active secretion. In non-suppurating cases this may be about a week.

### TREATMENT OF CHRONIC CELLULITIS.

This has been found to be remarkably resistant to all ordinary forms of treatment and seems to be little affected by drainage incisions. The usually favorable outcome of the disease hardly warrants extensive deforming incisions, and the latter have, apparently, comparatively little effect. It seems to us that the most promising treatment is to obtain an autogenous vaccine, obtained by incision and culture, and after pro-

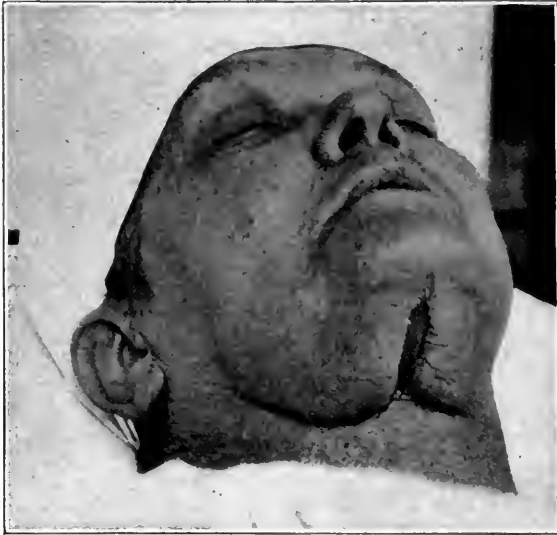

Fig. 295. Patient shown in the preceding figures, eight days after operation. As soon as the induration subsides, the flaps drop back in their normal positions.

tecting the patient by appropriate doses, to encourage the circulation through the inflamed area by cupping (Bier's hyperemia).

### PHLEGMONOUS STOMATITIS.

The term phlegmonous may be applied to any septic infection of a severe type, although the area involved may be very limited. Phlegmonous stomatitis may affect any part of the mucous membrane and subjacent tissues. It is usually dependent upon some local injury or ulceration which forms the portal of entrance of a virulent pus infection. Sometimes a tender, painful, and somewhat sharply outlined induration will appear in the cheek, without apparent cause, and upon inspection the mucous surface shows no cause. In a number of cases, by passing a lunar caustic stick over the surface, an excoriated patch was revealed by the white chlorid stain that resulted. The inflammation rapidly pro-



gresses to the stage of infiltration or suppuration, with sometimes the formation of a fibrous exudate clinging to the mucous surface. The infiltration and swelling are usually somewhat sharply limited, but the remaining mucous membrane shows a lesser type of inflammation. There is considerable pain and immobility of the part affected. The tongue may be so enlarged as to protrude from the mouth, while the swelling around the tonsil may almost close the fauces. If a deep suppuration occurs, especially in the posterior part of the mouth, there may be danger of asphyxia or septic pneumonia, and any septic infection may be followed by general sepsis. There may be no apparent general disturbance, or there may be an increased temperature and pulse rate with other evidences of intoxication.

The treatment will consist in the early use of a cold application, ice in the mouth, an ice bag under the chin, and attention to the bowels, digestion, etc.

If there is a superficial abrasion of the mucosa, it should be repeatedly painted with a 2 per cent solution of silver nitrate. If the disease has progressed to the stage of marked induration, hot applications may be more grateful. All painful, deep indurations should be freely incised, especially any points of increased tenderness. Such incisions may open an abscess, or the resulting drainage prevent its formation. In phlegmonous inflammations of the tongue the dorsum may be incised to its full extent, but deep incision should usually be made near the midline to avoid the chance of serious hemorrhage. (For treatment of peritonsillar abscesses, see Chapter XXXVIII.)

The patient should be given all the rest and comfort possible, and anodynes may be of service, especially aspirin and phenacetin, if the patient is in good condition and can swallow them—otherwise, morphin hypodermatically. But these should not be substituted for early incisions of painful indurations. Supporting treatment should be given where indicated.

### ABSCESS OF THE TONGUE.

Abscess of the tongue is extremely rare, and more often occurs in a subacute form and may be surrounded by considerable induration. It has been mistaken for gumma or a tumor. In a case that came into our service in the City Hospital, an elderly man had a hard swelling in the under surface of the body of the tongue extending into the floor of the mouth. It had given him little pain, but its size caused inconvenience. It was exposed from below the chin through the incision described under Ludwig's angina, and though a considerable quantity of pus was liberated, the surrounding wall was so hard and so sharply defined that, until the microscope and subsequent behavior proved it to be inflammatory, we thought it was a broken-down carcinoma.

## CHAPTER XXVII.

### DISEASES OF THE MAXILLARY SINUS.

The maxillary antrum is an accessory sinus of the nose, occupying the body of the maxilla. At birth it is rudimentary and attains full development at the twelfth year. It is bounded above by the floor of the orbit, internally by the lateral wall of the nose, anteriorly and externally by the anterior and lateral walls of the maxilla; while the floor is at the base of the alveolar process. The cavity occasionally extends into the hard palate for variable distances, even to the midline. It is lined with mucoperiosteum and ordinarily communicates with the nose by an aperture high up in its inner wall, which opens into the middle meatus—sometimes there are accessory openings. The cavity normally contains air and is lined with ciliated epithelium which carries the mucous secretion upward and outward through the nasal opening. The cavity is sometimes divided by incomplete bony septa. The apices of the roots of the molar and second bicuspid teeth are in close relation with, or perforate, the floor. In some cases the apices rise above the floor, covered only by the mucous and the peridental membranes. Occasionally the cuspid and first bicuspid have a similar relationship.

Although the antrum may be the seat of numerous surgical diseases, infection followed by suppuration due primarily to pus organisms, or secondary to some one of the exanthemata or la grippe, is so common as to overshadow in importance all other lesions combined.

#### ANTRAL INFECTION.

The antrum usually becomes infected in one of three ways: infectious material enters, or an infection extends from the nose, through the nasal aperture; or infection extends to the submucous tissue or bones of the floor from a diseased root or peridental membrane. Any part of the wall can be invaded by syphilis or tubercle which may ulcerate into the antrum, but this is of much rarer occurrence. It will be readily understood that the maxillary antrum is a common field which must be invaded by the rhinologist, the general surgeon, and the dentist; but at least its mucous lining is anatomically and physiologically a part of the nasal fossa. The proper treatment of all chronic suppurations of the cavity consists in establishing permanent ventilation from, and drainage into, the nose. It is becoming more and more recognized that the rhinologist, with his special facilities for diagnosis and for

doing intranasal operations, is the one most fitted for the treatment of at least those cases which are secondary to a nasal infection or which require intranasal drainage. If the infection of the cavity is dependent on an intranasal disease, as it is in about one half of the cases, it is perfectly evident that both conditions should be treated. A skilled rhinologist is the only one competent to treat diseases of the upper nasal sinuses. On the other hand, if the disease is an extension from around a tooth, it is just as important that this source of infection be eliminated. In the acute or subacute stage the most logical procedure in cases infected from the teeth is to drain both the cavity and the diseased submucous tissues through the same opening, which can be done at least as well by the dentist or the general surgeon as by the rhinologist.

When the suppuration becomes chronic, permanent drainage from a dependent point, with the removal of hopelessly diseased tissue, is the only treatment which has been found to give permanent relief. Attempts to establish permanent drainage into the mouth have been common, but they require the constant use of a drainage tube or plug to prevent the closure of the opening. They are being discarded for the nasal route, as more nearly approaching the natural physiological and anatomical conditions. An inflamed antrum may contain serum or seropurulent fluid of an acute infection or may contain thick pus. With chronic suppuration there may be partial or complete destruction of the surface epithelium or the whole mucous membrane, or it may be thickened and infiltrated with fibrous tissue. It may be covered with granulations, or the antrum may contain polypi, denuded bone, or mucous cysts.

**Subjective Symptoms.**—As in any acute pus infection, there may be fever, leucocytosis, and an increased percentage of polymorphonuclear cells in the blood. These symptoms are especially likely to occur if the pus is confined by obstruction of the natural opening. With confined pus the most characteristic and constant subjective symptoms are pain and tenderness. The pain may be local, or occur in the guise of a headache or a referred neuralgia. This is to be distinguished from the headache resulting from eyestrain in that it is not relieved by resting the eyes. Headache is a symptom common to suppuration of any of the sinuses, as is an irritation neuralgia of the face, running down the neck and arm and to the back of the head, but pain, tenderness, or a full feeling over the sinus is more apt to indicate a local trouble.

According to Ballenger, giddiness and vertigo, or a momentary sense of blurred or darkened vision and imminent fainting, are frequently present in sinus disease, and these symptoms may be made worse or produced by stooping over.

**Objective Symptoms.**—These are both intranasal and extranasal. The intranasal symptoms may consist of an irregular discharge of fluid or pus coming in gushes, or the presence of pus, or a plug of mucus and pus, under the center of the middle turbinated bone. Suppuration of the nasal mucous membrane is comparatively rare, and local patches of pus near the orifices of the sinuses are an almost certain sign of sinus suppuration.

The middle and posterior ethmoidal cells and the sphenoidal sinus have their openings above the middle turbinate bone. The frontal, anterior, ethmoidal, and maxillary sinuses discharge pus to the same point under the middle turbinate, so that when pus is seen here, other means will have to be used to determine its exact source. The application of a little 10 per cent cocain solution to the site will facilitate the examination. The antrum will hold approximately 5 to 30 cubic centimeters of fluid. A gush from the nose, brought on by having the patient bend forward, is very suggestive of fluid coming from the antrum, but may also be from the sphenoidal sinus. If the opening in the nose is closed, there will be no intranasal discharge, but there may be a bulging into the middle meatus due to pressure over the membranous part of the wall.

In an old suppuration with much pressure, there may be a bulging or rupture into the orbit with exophthalmos, or there may be a thinning or bulging of the anterior antral wall. The anterior wall being the thickest, this latter condition is rare. The pus may perforate and burrow under the face tissues or the soft tissues covering the palate.

Another objective change due to fluid in the antrum is in the transmission of light or the x-ray. If an electric light is placed in the mouth when the patient is in a dark room, the light is transmitted through a normal antrum and shows on the front of the cheek and lower lid. It shows a red crescent of light over the lower lid and causes a red pupillary reflex. The patient also has a sense of light when the eyes are closed, which latter is a subjective phenomenon. When there is fluid in the antrum, there is a lessening of the red pupillary reflex and of the crescent of light over the lower lid, also a lack of sensation of light. The light over the cheek may be misleading, as one antral wall may be thicker than the other. Fluid, or a growth in a sinus, will obstruct the x-ray, causing a shadow and also a blurred outline of the sinus. This latter test is only of value in the hands of a very competent roentgenologist.

The diagnosis may be confirmed or disproved by puncturing the antrum, under local anesthesia, either through the nasal wall under the inferior turbinate bone or through the canine fossa. It was an older custom to puncture the antrum through the root socket of a second

bicuspid or molar tooth. This is a more difficult procedure than puncturing the antrum wall through the canine fossa, and should never be done unless at the site of a hopelessly diseased tooth.

**Treatment of Acute or Subacute Antral Infections of Dental Origin.**—The antrum may be infected directly from a root canal. More often the infection is secondary to an alveolar abscess, but an abscess of the upper alveolus does not necessarily imply an antral infection. In many specimens we have examined in the dissecting room, the condition indicated in Fig. 290 was found, with every evidence that it had persisted for some time without perforating or infecting the antral mucous membrane. When an abscess in this location is acute, it may be difficult to exclude an antral infection without perforating the cavity. This can often be done, by the dentist, through the root canal of a suspected tooth, but this is not, as a rule, satisfactory for either diagnosis or drainage. If the tooth is to be removed, the socket

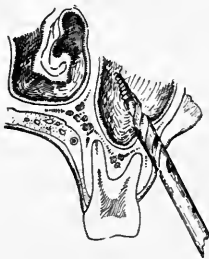


Fig. 296.

Fig. 296. Opening of the antrum with a gimlet. A trephine driven by a dental engine is more commonly used for this purpose.

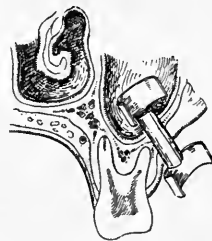

Fig. 297.

Fig. 297. Self-retaining rubber dam drain that will not become lost in the antrum.

can be drilled right up into the antrum, which will drain both the antral cavity and the alveolar abscess. Whether the tooth is to be preserved or not, we think it is often preferable to drill into the antrum just above the apices of the roots. This opening is easier for the general surgeon to make, and the drainage canal does not need to be plugged to prevent food particles from being forced into it. The operation is done as follows:

The tissues are anesthetized with 1 or  $1\frac{1}{2}$  cubic centimeters of a 2 per cent novocain solution with a little adrenalin chlorid—1 Prinz tablet dissolved in  $1\frac{1}{3}$  cubic centimeters of water, injected to the bone. The mucous tissues and the bone are drilled at the same time with some sort of a hand drill or with the electric dental engine, that will make an opening 5 millimeters in diameter. The point of the instrument is applied to the mucous surface at a point just above the prominence of the gum and inserted upward and inward (Fig. 296).

If it is to be opened above the second bicuspid, the drill is pointed upward, backward, and inward; while for the cuspid it is pointed upward and backward. By this means the antrum is entered through the upper part of the alveolar process. We have used an ordinary carpenter's gimlet ever since we first used one in an emergency case. If pus is found in the antrum or under the mucous lining, or even if there is the slightest suspicion of pus being present, a rubber dam or tube drainage is to be left in place (Fig. 297). If the antrum is not already infected, in the presence of an alveolar abscess the pus will easily find its way into the cavity, and if there is not free drainage, antral infection will result. The cavity should be irrigated with normal saline solution, or dilute alkaline antiseptic solution (N. F.), once or twice a day until all signs of suppuration have disappeared, with the possible exception of a slight amount of pus in the drainage tube. The alveolar abscess should be treated as already outlined in Chapter XXV. In an acute infection drainage will have to be provided for a week or two, at least until the alveolar abscess or tooth infection has been attended to. In a subacute infection the discharge may persist for a month or six weeks; but a discharge from the cavity persisting longer than six weeks, after free drainage is furnished, should be considered chronic, and permanent drainage is indicated. Before this is undertaken, it should be ascertained whether any of the upper nasal sinuses are infected, for pus pouring into the middle meatus may constantly reinfect the antrum if the natural aperture is patent.

**Treatment of Chronic Antral Infections.**—Operations for the relief of chronic antral suppuration fall into two general classes: those which provide permanent intranasal drainage, which may be called conservative; and those which furnish free access to the cavity whereby diseased tissue may be removed with a curette. In the great majority of cases permanent relief will be obtained by one of the operations which are collectively styled the Mikulicz, which consist in establishing a large permanent opening between the antrum and the nose through the inferior meatus. Schaeffer was the first to describe the method of puncturing the antrum through the lateral wall of the middle meatus. Various technics have been devised, most of them including the removal of part of the inferior turbinate bone. The most effective of these is the operation described by Sluder. It provides the largest opening, and at the same time is the most conservative, for it preserves the inferior turbinate bone intact. While perfect access for curetting the antrum cannot be obtained by the Mikulicz operation, it is a question whether curetting is often necessary. Free permanent drainage being provided, there rarely remains anything to keep up the irritation; dead bone will be thrown off, polypi, which are inflammatory

growths, will at least cease to grow, and the mucous membrane will have the best chance to regenerate. Discretion is to be exercised in curetting the interior of the antrum. Polypi, dead bone, and heavy, coarse granulations may be removed, but the small granulations are to be left alone in the hope that the deeper epithelium, lining the mucous follicles, may eventually cause a re-epithelization of the surface. If the mucous membrane is entirely destroyed or removed, then, unless a flap is transplanted from the nose, the cavity can be lined only with scar tissue.

**KÜSTER OPERATION.**—The older radical operation of entering the antrum through a large opening made in the canine fossa and, after removing granulations, polypi, or dead bone, packing or treating the cavity for a period will be successful in a number of cases, but not in all; for the opening will eventually close, and the suppuration is liable to recur. It is sometimes called the Küster operation and is performed as follows:

An incision is made down to the bone over the canine fossa in the upper fornix. The soft tissues, including the periosteum, are raised with an elevator, and the anterior wall is removed with a perforator and biting forceps until the opening is  $1\frac{1}{2}$  centimeters in diameter. Then a light is thrown into the cavity; and all diseased tissue is removed, and any septa present are broken down. The cavity is loosely packed with gauze saturated with compound tincture of benzoin, the end of the gauze protruding into the fornix. Subsequently the cavity is irrigated daily, and when suppuration ceases, the wound is allowed to close.

**CAULDWELL-LUC OPERATION.**—The Mikulicz operation has been combined with the Küster under the name of the Cauldwell-Luc operation, which is really a radical procedure giving free access to the cavity and also providing permanent drainage. In this operation the diseased tissue is removed, and the mucous lining of the inferior meatus is turned into the floor of the antrum. Then the opening through the canine fossa is immediately sutured, and all further treatments are carried on through the nasal opening. It is difficult even by this means to remove granulations or diseased bone from the anterior inferior angle of the cavity, and these may cause the infection to persist.

**DENKER OPERATION.**—The Denker operation overcomes this difficulty, gives free access to the sinus, provides permanent intranasal drainage, and for its performance does not require the special technical skill which is needed for an intranasal operation done through the anterior nares. It should, therefore, appeal to the general surgeon as most appropriate for all cases of chronic antral suppuration requiring radical treatment. The technic of the operation is as follows:

The operation is best done under a general anesthetic. The patient

is placed in the Rose position with the head hanging over the end of the table, but supported by an assistant. Postnasal tamponage may be used, but if the head hangs well downward, this is not necessary. The labiogingival incision is made as in the Küster operation, but extends to the median line. The soft tissues, including the periosteum, are elevated, the antrum is opened through the canine fossa, and the lower part of the bridge of bone, between the antrum and the opening of the nose, is removed. This piece of bone is thick and will require strong biting forceps. By this the anterior inferior angle is opened, and the whole cavity is accessible to the curette. Bony partitions should be removed along with such pathological tissue as may seem expedient (Fig. 298). If there is to be a mucous flap turned from the nose to the floor of the antrum, its future site should be freed of all mucous

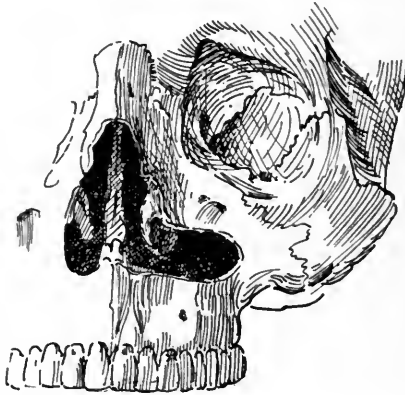

Fig. 298. Denker operation for chronic antral infection.

membrane; otherwise mucous follicles might be buried under it and give rise to cysts.

The next step in the Denker operation is to free the mucoperiosteum from the bony wall of the inferior meatus and from the under surface of the inferior turbinate bone. Having incised the mucoperiosteum, it is elevated and converted into a flap, to be turned outward into the floor of the antrum. Finally, the bony wall of the inferior meatus, with the mucous covering on its antral side, is removed with biting forceps (Fig. 299). The flap of nasal mucoperiosteum is then turned into the floor of the nose and held in place for twenty-four to forty-eight hours with an antiseptic gauze pack, the end of which protrudes from the nostril. The wound in the vestibule of the mouth is immediately closed with sutures.

In doing this operation, it is unnecessary to sacrifice any part of the inferior turbinate bone, which is a functional structure. Ballenger calls



attention to this objection in almost all of the operations that give permanent intranasal drainage. In the few cases upon which we have operated for chronic antral suppuration, we have never found it necessary to remove any part of this bone. By removing the outer wall of the inferior meatus up to the attachment of the inferior turbinate, ample room is obtained. In making the window into the inferior meatus, the lower part of the nasal duct may be injured. It opens at a variable distance below the attachment of the inferior turbinate bone, 30 to 35 millimeters from the posterior boundary of the nostril, which is about at the junction of the anterior with the middle third of this bone.

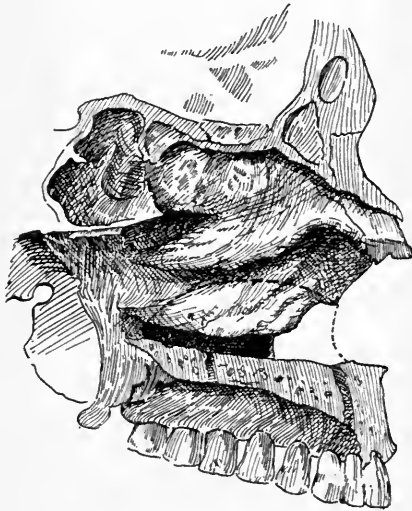


Fig. 299. Denker operation for chronic infection of the antrum, showing the permanent opening between the antrum and the nasal fossa through the inferior meatus. The upper dotted line indicates the height to which the lateral wall is removed, most of the opening being hidden by the inferior turbinate bone.

It was but a step beyond the Denker operation for the rhinologist to abandon the oral route and to open the antrum at the anterior inferior angle, through the anterior nares. This was first done by Canfield, of Ann Arbor; but Ballenger, objecting to the sacrifice of any of the inferior turbinate bone, modified Canfield's operation accordingly. This operation he presents in his work as the Canfield-Ballenger operation, and to the mind of the writer represents the refinement of present-day radical operations for chronic antral suppuration, but will give no better results than the Denker operation.

### CYSTS OF THE ANTRUM.

The antrum may contain free mucus from simple obstruction of its nasal opening, or it may be partially or completely filled by a mucous

cyst, due to the distension of one of its contained mucous follicles. A dental cyst might extend into the antrum. Occasionally the wall of the cyst becomes calcified (Fig. 300). The mucus will obstruct both transmitted light and x-ray, and the pressure of the cyst may cause pain. Later a cyst may thin and distend the walls of the antrum. It is to be differentiated from chronic suppuration by making a puncture.

**Treatment.**—This consists in furnishing a permanent outlet to the mucus. If it is due simply to the closure of the normal outlet, a supplementary one should be made in the inferior meatus. If the dis-



Fig. 300. Calcified wall of a cyst in right antrum, communicating with the socket of two bicuspid teeth.—Hunterian Museum, London. Photographed for this book by courtesy of the curator.

tension is due to a cyst, the antrum should be opened, and the free part of the cyst wall excised.

### TUMORS OF THE ANTRUM.

Fibromata, osteomata, or sarcomata may arise in the cavity from its walls; epitheliomata from its contained or a contiguous mucosa; odontomata, cystic or solid, or a tooth may grow into it. Benign tumors distend or cause absorption of its walls, while malignant tumors infiltrate. (For symptoms of tumors of the antrum see Examination, p. 2.)

**Treatment.**—Benign tumors are to be removed, after opening the antrum, from within the vestibule of the mouth; while malignant growths will demand the total or partial removal of the maxilla, depending upon their size and location.

## CHAPTER XXVIII.

### TUMORS OF THE MOUTH AND JAW-BONES.

Nearly all of the tumors and cysts which can arise in any part of the body may be found in or around the mouth, except those which are peculiar to certain extraneous organs. There are also certain tumors and cysts which are peculiar to this region.

#### HYPERTROPHY OF THE GUMS.

Though probably not a tumor in the strict sense of the term, it is convenient to present hypertrophy of the gums with the tumors of this part.

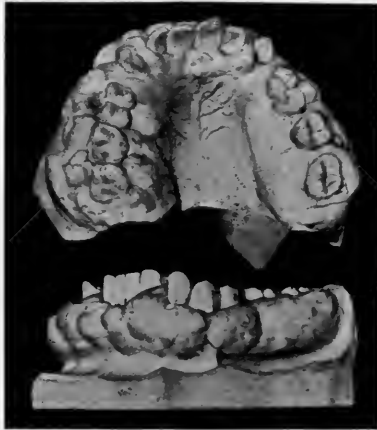

Fig. 301. Hypertrophy of the gums.—By courtesy of Dr. Prinz.

The gum may become infiltrated with fibrous tissue and enlarge until the teeth are buried and the whole mouth is filled. It appears usually in childhood, and all of the cases we have seen or heard of have been in children or young adults.

Cryer illustrates a case in which he removed the gums, alveolar processes, and teeth in both jaws. Fig. 301 presents a less-advanced case from the service of Dr. Herman Prinz. In cases of this severity, or less, we have excised the excess tissue, leaving sufficient of the mucosa to cover the defect. We have advised that the patient be placed on injections of Coley's fluid, as used for sarcoma, in hope that this would prevent a return of the growth. These enlargements are some-

what related to keloid, and one cannot rely upon their not continuing to grow after removal. Radium or the x-ray might be tried.

Special tumors of the lip and tongue will be presented with other affections of these organs.

### MUCOUS CYSTS.

The mucous follicles of the gums may become distended with their secretions, forming small, smooth, elevated nodules. They are to be treated as mucous cysts of the lip.

### EPULIS.

This is a rather poor term, for it means any sort of tumor on the gums (Fig. 302). It may be sessile or pedunculated, and may be of inflammatory origin—fibroma, sarcoma, myeloma, angioma, or carcinoma.

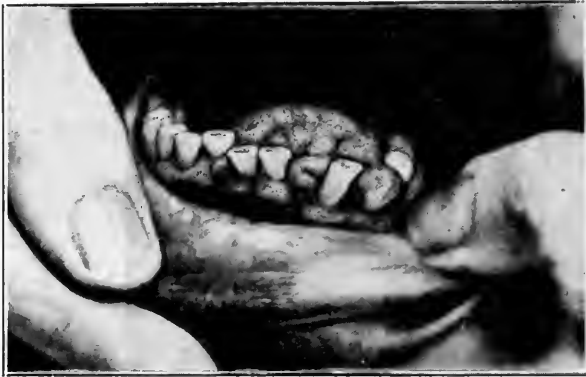

Fig. 302. Giant cell epulis in a negro woman.

In most instances they arise from the edge of the gum at the neck of a tooth, probably most often from the root membrane. They rarely, if ever, occur behind the last molar. As they enlarge, they may remain attached to a narrow stalk or grow along the gum and between the teeth. Ulceration may occur in the benign tumors from irritation.

The myelomata, as they grow downward, cause an expansion of bone. The giant cell epulis is softer, more vascular, bleeds more easily than the fibrous epulis. It is spongy, of irregular contour and consistence, grows more rapidly, and is more common.

**Treatment.**—They should be removed and subjected to a careful microscopical examination. If pedunculated, the portion of the periodontal membrane or bone to which they are attached should also be removed. This will usually necessitate the removal of one or several teeth.

The sessile variety requires a more extensive removal, the incision

extending into healthy mucous membrane, and it is safer to include at least a scale of underlying bone. Pure fibromata, benign tumors composed exclusively of fibrous tissue, are rather rare, but fibrous tissue occurs in various proportions in many of the sarcomata. Many of these tumors, supposed to be simple, show by their subsequent clinical behavior that they are at least locally malignant, and their removal in all cases should be thorough. In a number of immense tumors of the jaw, preserved in the Hunterian Museum of London, the history attached states that they occurred as small nodules upon the gum, were repeatedly removed, and recurred several times in the course of years, growing very slowly, but later taking on rapid uncontrollable growth that eventually destroyed the patient. It is probable that they would not have recurred if, at any time during their period of slow growth, a thorough removal had been made of the tumor with the tissue from which they grew. If the microscopical examination shows a growth to be malignant, the removal should be planned accordingly; but unfortunately the clinical outcome of some of these growths is not always to be determined in this way, and the only safe plan is to remove thoroughly, with a block of the healthy tissue to which they are attached.

#### LIPOMA.

Lipoma, angioma, and cirroid aneurysm are very rarely found in connection with the jaws, and a special presentation of them is not necessary.

#### FIBROMA.

Besides the pedunculated form which comes under the general term of epulis, fibromata may develop either from the periosteum or from fibrous tissue contained within the bone. In the former case it will appear as a slow-growing nodule, attached by a broad base; in the latter it will cause expansion and finally perforation of the bone. They often appear to arise in connection with some trauma and grow very slowly. The diagnosis is made mostly on their slow growth and distinct nodular outline, also on their consistence, which is less hard than bone or cartilage. All new growths should be regarded with suspicion and, wherever possible, subjected to microscopical examination. If the tumor takes on active growth, it should be treated as malignant and removed with a section of the bone to which it is attached, but the full thickness of the lower jaw is seldom to be removed. (There is a special form of fibroma, known as the nasopharyngeal polyp, which will be described with tumors of the pharynx, and under the heading of Retromaxillary Tumors.)

### CHONDROMA.

A chondroma is a tumor composed of hyaline cartilage and, according to Bland-Sutton, grows from pre-existing cartilage; occurring in relation to the upper jaws, they may arise from the cartilaginous septum of the nose. They are encapsulated and non-malignant, and cause distress only by their size and relations. They occur most commonly in children and young persons and are usually small, but may rarely attain a relatively large size. Pathogenically they are to be distinguished from the more rapidly growing, infiltrating chondrosarcomata, which grow to a large size. They should be excised with the cartilage from which they grow.

### OSTEOMA.

These tumors are composed of bone, surrounded by a layer or cap of cartilage—therefore, ossifying chondromata. They occur on any

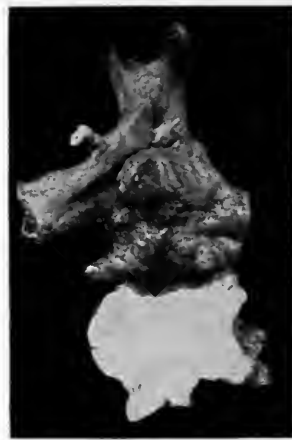


Fig. 303. Osteoma of ivory-like texture, attached to the angle of lower jaw.—Hunterian Museum, London. Photographed for this book by courtesy of the curator.

part of the bones of the face, but probably more commonly on the upper than the lower jaw. They may be of compact or cancellous bone, and may be pedunculated or attached by a broad base. They grow very slowly, but may attain a large size. As they grow, the soft tissues covering them may ulcerate, leaving the bone exposed. They are painless, but pain may be caused by pressure. When pedunculated, they may become detached and be thrown off spontaneously. They are non-malignant (Fig. 303). Detached bony masses have been found in a soft tumor—possibly a sarcoma (Fig. 304). They are to be distinguished from osteo-, or bone-forming, sarcomata, from tumors that expand the bone, and from leontiasis ossea, which latter is a thickening

of, not a growth from, the bone. Treatment consists in their removal, together with a very small area of the bone to which they are attached.

### MYXOMA.

The pure myxoma is rare. Myxosarcoma, which is more common, is a flat, soft tumor of much more rapid growth. The indications are for a complete removal, rather than a partial operation.

### ODONTOMA.

Under this heading are included a number of benign tumors and cysts which arise from the teeth germs during the process of growth, and are composed of dental tissues in varying proportions. These have been classified by Bland-Sutton according to their structural peculiarities as follicular and fibrous odontomata, cementomata, compound folli-

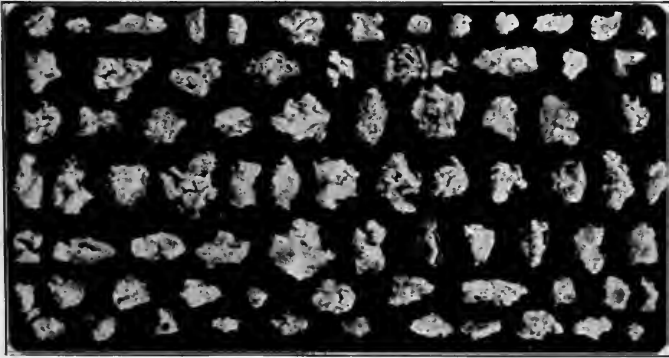


Fig. 304. True osseous fragments removed from a soft tumor in the antrum, from a girl of 11 years. There is nothing to show that this is in any way connected in its origin with the tooth sacs. (Bland-Sutton: Transactions of the Odontological Society of Great Britain, Vol. XXXIV, No. 4, page 96, 2197 E. A.)—Hunterian Museum, London. Photographed for this book by courtesy of the curator.

cular odontomata, radicular odontomata, and composite odontomata. There are some strong reasons for placing cystic adamantinomata among the odontomata, but we have followed Bland-Sutton's classification and presented them with the endotheliomata.

**Follicular Odontoma.**—Ordinarily, at a certain stage of development, the tooth sac in which the tooth has developed is pierced, and the tooth erupts. If for some reason this last stage of dentition fails to occur, the ill-developed tooth will remain in the bone, enveloped by a fibrous capsule, which usually also contains a viscid fluid. The thickness of this capsule varies and it may contain bony spicules. The tooth itself may be absent or represented by a denticle. Follicular odontomata are most common in connection with the permanent molars and may be multiple (Fig. 305).

**Fibrous Odontoma.**—If the tooth sac becomes very much thickened, the unerupted tooth may be found in a mass of fibrous tissue and much deformed.

**Compound Follicular Odontoma.**—Sometimes the thickened capsule ossifies sporadically, in which case it will contain denticles

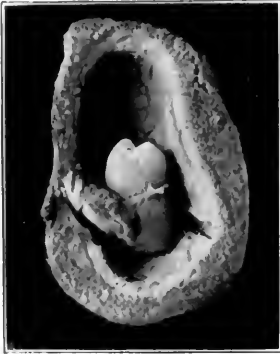


Fig. 305.

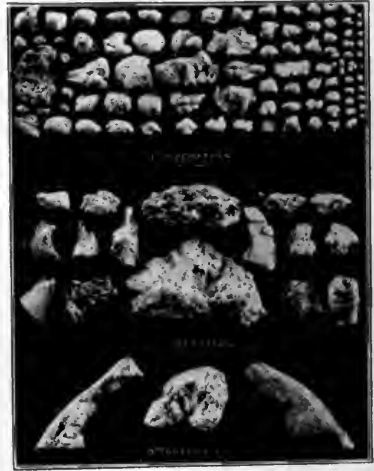

Fig. 306.




Fig. 307.

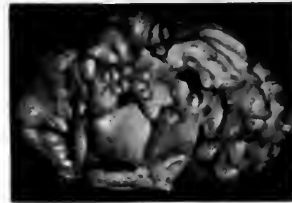

Fig. 308.

Fig. 305. Follicular odontoma. It is possible that this is simply a retained tooth in a sac thickened by inflammation.—Hunterian Museum, London. Photographed for this book by the courtesy of the curator.

Fig. 306. Odontomata composed of cementum traversed by irregular canals resembling the Haversian canals. Removed from the molar region of one side of the mandible. Tumor appeared at 11 years; was operated, on account of the deformity, at 15 years, at 16½ years, and at 19 years. The last operation was followed by cure. (J. Ward Collins, *British Med. Journal*, June 6th, 1908).—Hunterian Museum, London. Photographed for this book by courtesy of the curator.

Fig. 307. Cementoma in a girl, 16 years of age. Had been noticed for four years and gradually enlarging. Probably of inflammatory origin. A provisional diagnosis of odontoma was made, based on the fact that the tooth was not loose.

Fig. 308. Composite odontoma, after Gilmer.

composed of one or all three of the tooth elements; dentin, cementum, and enamel. The follicular and fibrous odontomata are collectively termed dentigerous cysts.

**Cementoma.**—If the thickened capsule described above ossifies, the tooth will be found imbedded in a mass of cementum. Such tumors



are common in horses, but according to Bland-Sutton, do not occur in man (Fig. 306).

**Radicular Odontoma.**—A radicular odontoma is a tumor which arises from the root portion of the tooth and therefore can contain only dentin and cementum. There is reason to believe that some osseous swellings connected with the roots of teeth may be of inflammatory origin; the distinguishing feature of these being that the roots are imbedded in a circumscribed mass of bone, but the tissues of each are distinct and separate and do not merge into each other (Fig. 307).

**Composite Odontoma.**—Under this head are included all hard tooth tumors which present a disorderly conglomeration of cementum, dentin, and enamel in varying proportions. They might be considered

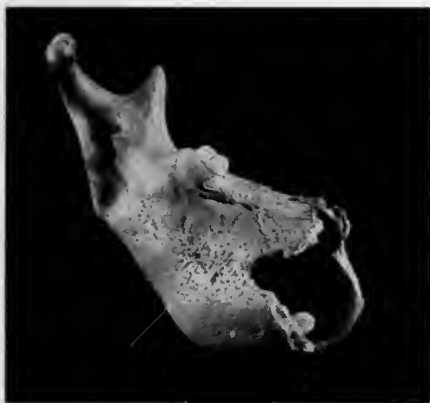

Fig. 309.

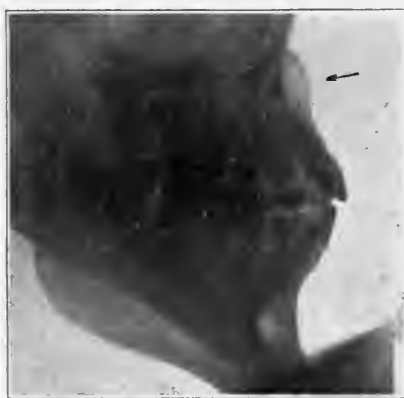

Fig. 310.

Fig. 309. Cystic tumor of the left side of the body of the lower jaw, containing a cuspid tooth. The cyst was lined with granulation. Probably of inflammatory origin. From patient, 13 years of age. One half of the jaw was excised, under the impression that it was a tumor. (See *British Med. Journ.* Vol. 1, 1864, page 241, and *Injuries and Diseases of the Jaw*—Heath, 2d Ed., page 165.)—Hunterian Museum, London. Photographed for this book by courtesy of the curator.

Fig. 310. Bone cyst following infection of upper lateral incisor tooth. The arrow points to the expanded bony wall of the cyst.

as the product of an abnormal growth of all of the elements of a tooth germ and might represent two or more tooth germs fused into one mass in which no normal individual tooth is found. They vary much in shape, are rough in outline, and may attain considerable size. One weighing 885 grains, preserved in the Royal Dental Hospital, is probably the largest on record (Fig. 308).

Gilmer, who has had a large personal observation of cases of odontoma, takes exception to Broca's and Bland-Sutton's classifications, maintaining that they are too broad.

He would include under the head of odontomes only tumors that are composed of nests of aberrant tooth forms, ununited by cement, but

inclosed in a fibrous capsule, similar masses held together by granular calcific matter that resembles, imperfectly, cement, and those classified by Bland-Sutton as composite odontomata. His observations led him to believe that these seldom or never represent or do they replace a normal tooth, but that they are derived from some other source.

He would exclude from the classification of odontomes single teeth that are simply deformed, teeth more or less perfectly developed remaining in a fibrinous capsule (Fig. 305), or imbedded in a mass of cement (Fig. 307), tumors of other tissues, caused by the teeth (Figs. 309, 310), and also cystic adamantinomata (Figs. 312, 313).

Odontomata, dentigerous cysts, etc., are usually observed in young persons and are supposed to occur more frequently in the lower than the upper jaw. When of considerable size, they may cause a thickening that can be felt or seen. It has been observed that some of them have a tendency to erupt like teeth, and this is when they are

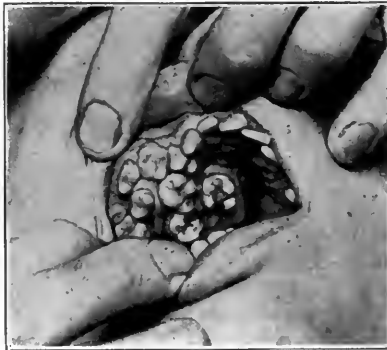

Fig. 311. Supernumerary teeth in a boy, 15 years of age.

most apt to cause symptoms. If the bed of the tumor becomes infected, there will be a purulent discharge, and at this stage the tumor has been frequently mistaken for necrosed bone. The sepsis resulting may be very severe. The x-ray is useful in detecting the mass.

**Treatment of Odontoma.**—The treatment consists in simply removing the tumor; mutilating excisions of a portion of the jaw are in no way indicated. With the follicular variety it is usually sufficient to remove one bony wall, scrape out, and pack the cavity. The solid tumors are to be removed, after removing sufficient bone on one side to permit of their being lifted out with an elevator.

### SUPERNUMERARY TEETH.

The occurrence of supernumerary teeth is not uncommon. In most instances it is probably an atavistic recurrence of some tooth that has been suppressed in the human—such as a central incisor, premolar, or

fourth molar. Such teeth are usually well-formed. Sometimes there is an ill-formed tooth that might have been developed from a "rest." Zukerkandl found enamelless tooth rudiments in the incisor region in twenty out of six hundred crania examined. Black and many others have observed instances in which there were additional buds given off from the dental strand. It is possible that, after giving off the normal number of buds, the dental strand may not always become absorbed, and it might go on producing tooth buds indefinitely. Such might be the explanation of those rare cases where an enormous number of denticles have been repeatedly removed from the same jaw. It is very rare that, where there are a number of supernumerary teeth, they are as well formed as in the case shown in Fig. 311.

### DENTAL CYSTS.

This is a term which is to be always regarded with suspicion, it being often used to indicate an absorption abscess or a dentigerous cyst or follicular odontoma, but there is a pathological condition that can be properly placed under this designation. Occasionally there is found in connection with the root of a dead permanent tooth a fibrous sac, which may vary in size from an apple seed to a small egg. It contains fluid and often cholesterin crystals. These cysts have been regarded as inflammatory, but J. G. Turner has demonstrated an epithelial lining in many of them and believes them to have developed from a peridental epithelial remnant. They may form painless, smooth tumors, which in the upper jaw may invade the antrum. The extent of the cysts is best determined by the x-ray. The smaller cysts require no treatment after the removal of the tooth to which they are attached. Larger ones may require the removal of several teeth. The cavity should be scraped out, and one bony wall may be removed. If the cyst involves only the apices of the teeth, it may be invaded laterally, and the roots within the cavity amputated. (See Treatment of Alveolar Abscess, p. 330.)

### SARCOMA.

Sarcoma is a general term given to non-encapsulated tumors of any of the connective tissues, fibrous tissue, bone, muscle, etc., which tend to infiltrate neighboring tissues and to spread to distant parts of the body through the blood stream. This habit of invading neighboring and distant tissues constitutes malignancy. Benign tumors push neighboring tissues before them or cause their absorption by simple pressure, and they never cause distant infections.

Several varieties of sarcoma occur in connection with the jaws. Including the sarcomatous epulis, sarcoma is the most common variety of tumor of the lower, and next to carcinoma, the most common tumor

of the upper jaw. They may be of the spindle, large, or small round cell, or the somewhat doubtful alveolar variety; or the growth may be mixed in the character of the cells which compose it. Any of them may contain sufficient fibrous tissue to make this a characteristic of the growth, or they may form bone or cartilage. Rarely, melanotic sarcomata of the upper jaw have been observed. The histologic character will often give some clew to their virulency. The large round, the spindle, and the small round varieties vary in malignancy in the order named, the large round cell tumor being least so. The greater the proportion of fibrous tissue, the less the malignancy. The sarcomata that form fibrous, osseous, or cartilaginous tissue are composed of cells which have the power of developing beyond the purely embryonal stage, and it is probable that they are in general less malignant. Melanotic sarcomata are the most malignant of all. The relation of the cells to the blood vessels seems to have some bearing on this subject, those tumors in which the cells are crowded close to the vessels being more malignant than tumors in which the cells are separated from the vessels by some fibrous tissue.

Sarcomata may arise from the gums, the antrum, the surface periosteum, root membrane, or from within the alveoli of the bone. If the sarcoma is in the upper jaw, it most often starts in the antrum. The hard palate and frontal process of the upper jaw are least often involved. Sarcomata arising from the periosteum are usually rather firm in consistency, while those arising from within the bone are often very soft. Scudder states that periosteal sarcoma does not arise in the alveolar border, but from the body of the bone. It is often stated that the periosteal varieties are less malignant than those of endosteal origin. This, however, seems not to take into account myeloma, which is the most frequent of the endosteal tumors, and which is only locally malignant. Scudder claims that the periosteal round and spindle cell sarcomata are very malignant.

A sarcomata arising within a tooth socket causes first a loosening, later a loss of the tooth, and is then inclined to fungate from the cavity. The periosteal varieties cause hard, irregular, usually somewhat fusiform swellings. The myelomata grow within the bone and cause a thinning and often irregular bulging of its walls, but can also cause a thickening of the gum tissue. Certain of the true sarcomata, which grow within the body of the bone, cause a thinning and bulging rather than infiltration of its walls; and from personal observation, we are certain that they are among the more mildly malignant. In the upper jaw periosteal sarcomata may arise within, or endosteal sarcomata may invade the maxillary antrum, causing at first a thinning and bulging of its walls, but later a perforation and involvement of the soft tissues by

direct extension. Sarcomata of the mouth may cause enlargement of the lymph nodes, but with the exception of the lymphosarcomata, more often from septic absorption from the ulcerated surface than from an extension of the disease. Sarcomata seldom cause pain, at least in the earlier stages, though they may do so by pressure on nerve trunks. The diagnosis should always rest upon a microscopical examination, to which it is a safe plan to subject every tumor. The various clinical symptoms which are ascribed to different tumors and different varieties of sarcomata may be misleading in the individual case, and if depended upon for a diagnosis, may cause unnecessary mutilation or a disastrous delay. We have seen an adenocarcinoma in a girl of twenty years which clinically appeared to be a sarcoma, but which had already infected the lymph nodes. In another case, its sarcomatous nature was entirely overlooked because there was little evidence of growth and a very extensive necrosis of one half of the body of the lower jaw. A microscopical examination of some hard granulations which lined the cavity proved its true character. No age is exempt from this disease. Coley attributes acute trauma as a cause in 23 per cent of his 970 cases. Some fungate and ulcerate early, while others attain immense size without ulcerating. In some varieties the growth is rapid from the first; while in others it may be slow or remain in abeyance for years, only to take on a rapid growth.

**Treatment.**—With the exception of the myelomata and certain slow-growing, large round cell varieties, the treatment of all operable tumors is a radical excision *en masse*, of all involved tissues well into the healthy structures. The lymph sarcomata will demand the removal of the lymph-bearing tissue of the regions which drain the infected area. It is not always necessary or advisable to remove a whole or half of the jaw-bone, but the excision should be made from 1 to 1½ centimeters from the tumor all around, regardless of the tissue involved; and where possible, the lower border of the bone should be preserved. After removing the mass, the excised portion of the jaw should be sawed immediately and examined. If the excision has not been made sufficiently far beyond the growth, a further excision can be made. (For Excision Operations on the Gums and Jaws, see Chapter XXIX.)

If too far advanced to attempt radical treatment, the operation should be made as complete as possible, as some of these growths, especially the large round cell variety, return very slowly after an incomplete removal. This may be true even of the mixed small and spindle cell tumors. In large slow-growing tumors of the lower jaw which cause a distinct expansion of bone and can apparently be shelled out of the bone, we believe that this is a better treatment than a very extensive resection. Such tumors are usually composed of large, round

cells and much fibrous tissue, and are slow to return after being removed in this way. The lateral bony walls of the cavity may be excised with their periosteal covering, but at least a thin bridge of bone should remain to preserve the outline of the lower jaw. Gilmer has reported a number of satisfactory results with such tumors treated in this way. In all cases we would recommend the use of Coley's fluid, pushed to the limit of endurance for a long period after every attempted removal of a sarcoma. We have had the satisfaction of seeing several inoperable, or unoperated, sarcoma held in abeyance for a number of years, after the use of the Coley's fluid. (We have found the fluid prepared by Dr. Martha Tracy the most active.) If accessible, radium may be used. The x-ray may be applied in the mouth through a Ferguson vaginal speculum.

In all cases of sarcoma the ultimate prognosis is bad, even if removed early. But recurrence may not take place for a long time, or the patient may die from metastasis of the lungs before there is local recurrence. However, metastasis from jaw sarcomata is rarer than from other sarcomata.

**STARVATION TREATMENT OF INOPERABLE SARCOMATA.**—The idea of treating tumors by limiting their blood supply is an old one. Dawbarn has presented a treatise on the subject of starvation of inoperable tumors of the mouth and neck. Judging from the cases reported in this work, the results in but few can be regarded as positive, but in dealing with inoperable growths, anything that may modify their malignancy must be regarded as worthy of attention. The best results that Dawbarn has had are in sarcomata, and in those that were limited to the area supplied by the external carotid artery. In several of these, the growth of the tumor seems to have been stopped for an indefinite time. The only noticeable result we have observed after the use of this method was the shrinking of the temporal expansion of a nasopharyngeal polyp.

The branches of the external carotid are exposed as described for ligating this vessel. A temporary ligature is thrown loosely around the trunk of the external carotid, or a Crile artery clamp is placed upon the common carotid to provide for accidental tearing of the vessels. The superior thyroid, lingual, facial, occipital, and the ascending pharyngeal, if it can be found, are caught in turn with Halsted artery forceps, doubly ligated, and then cut. The bellies of the stylohyoid and digastric muscles are drawn upward. Into the trunk of the external carotid is injected 6 cubic centimeters of melted wax at low melting point, six parts white wax with four parts olive oil. This fills and blocks the posterior auricular, internal maxillary, and temporal arteries. After this injection one should be able to feel the wax in the temporal artery. Two weeks later the operation should be repeated

on the opposite side. In our experience, several times after primary healing of the neck wound, a fistula has appeared and persisted for several weeks or months, with discharge of pieces of the wax.

### MYELOMA.

These were formerly classed as sarcomata, but are not malignant in that they do not cause metastasis and will not recur after a thorough removal. They arise only in the alveolar tissue of the bone and are composed for the most part of giant cells, with an intermixing of spindle and round cells. The tumor presents the appearance of freshly cut liver. According to Bland-Sutton, they occur in the body of the mandible and the alveolar process of the maxilla. They rarely occur after the age of twenty-five, grow slowly, and expand the bone as they advance. Sometimes they later perforate the bony capsule and invade the soft tissues.

The diagnosis of myeloma rests upon the clinical features cited, and a microscopical examination. For their treatment they do not require mutilating operations; but the bone is to be opened, and the tissues scraped out. If they have perforated the capsule, this portion should be removed by an excision extending into the healthy tissue. A deep bone cavity resulting from the removal of a myeloma had best be treated according to the principles laid down for cavities resulting from bone abscess of the jaw (see p. 330).

### ENDOTHELIOMA.

Endotheliomata are tumors arising from the endothelium of the blood vessels and lymphatics. As endothelial tissue originates from the same germinal layers as does connective tissue, these tumors are related to sarcomata and often behave like them. One form of tumor which has been described as alveolar sarcoma, which may be very malignant, is probably of endothelial origin. In the jaws alveolar sarcomata should be treated as other sarcomata. It is probable that many of the so-called cystomata of the jaw-bones are of endothelial origin.

### MULTILOCULAR CYSTIC TUMORS.

The cysts contain brown mucous fluid, and the septa between them may ossify (Fig. 313). The growing portions of the tumor may somewhat resemble a myeloma. These tumors are most common about the age of twenty years, but they may be met with much later. Eve labeled them multilocular cystic epithelial tumors of the jaw, and they have been supposed to have their origin in the enamel organ. They occur about twice as frequently in females as in males. They are found most generally in the lower jaw near the angle. They are also

known as adamantinoma, and it has been positively asserted that the cells of an enamel organ can be demonstrated. Bland-Sutton states that, though he formally accepted this view, he now considers them as endotheliomata arising from the gums. Between the opinions of such observers as Ève and his followers on the one hand and of Bland-Sutton on the other, we would not presume to judge, but our great respect for the latter's knowledge of tumors, in general, leads us to place them under the heading of endotheliomata. These may attain a large size, are at least locally malignant, and should be completely removed.

### CARCINOMA.

About the throat and nose, where ciliated epithelium is found, this variety is first replaced by squamous epithelium before it shows recog-

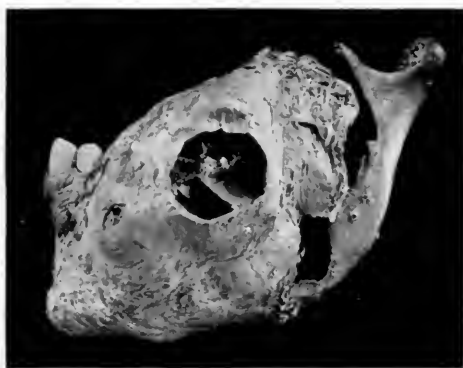


Fig. 312.

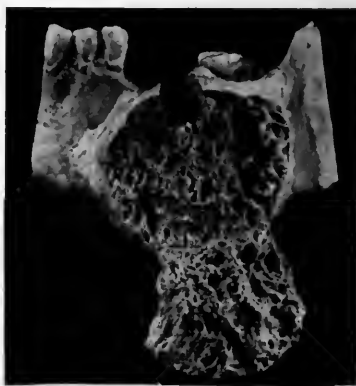

Fig. 313.

Fig. 312. Cystic adamantinoma, from middle-aged man. Tumor had been present several years. (For one of the early descriptions of cystic tumors of the jaws, see *British Med. Journ.*, Vol. 1, 1883, page 1.)—Hunterian Museum, London. Photographed for this book by courtesy of the curator.

Fig. 313. Multilocular cystic tumor, the septa being composed of fibrous tissue and bone. Probably of the same character as the preceding. Bland-Sutton would ascribe this tumor to endothelial origin.—Hunterian Museum, London. Photographed for this book by courtesy of the curator.

nized signs of malignancy. Unless due to an extension from the lips or cheeks, carcinoma of the jaw is almost exclusively a disease of elderly persons. It can arise from epithelium, and in most instances comes primarily from the mucous covering of the gums or the lining of the antrum. Schlatter cites one case in his practice where the tumor arose within the body of the lower jaw, apparently metastatic from a cancer of the breast that had been removed three and a half years previously. The common site of primary cancer of the upper jaw is within the antrum.

Of the tumors which arise within the mouth, most of them seem to be in connection with dental or mechanical irritations. Leucoplakia



is responsible for some, and in this connection smoking must be regarded as a factor. In a number of cases the disease is an extension from the lip or cheek. Broadly, there are two clinical types of carcinoma of the jaws: the hard, ulcerating type, which usually appears on the lower jaw; and the soft, medullary carcinoma, which is found in the antrum and upon the oral surface of the upper jaw. The symptoms of these two differ materially. The hard ulcerating tumor grows more slowly and in the earlier stage causes no pain. The induration and ulceration invade the neighboring surfaces much more rapidly than the deep tissues, but we have seen a thin tongue of carcinoma extending down under the periosteum for 1 centimeter beyond the evident induration. The induration of this type is usually of a hardness that is unmistakable.

When seen upon the oral surface, the medullary carcinoma is usually very soft, and is first noticed as a small papule, which may bleed easily. As it extends, it may take on a cauliflower appearance. It rapidly extends both on the surface and into the antrum, but does not ulcerate early. In tumors arising in the antrum or nasal cavity, pain is an early and almost constant symptom. This may be localized in the form of a toothache, or diffused over the distribution of the fifth cranial nerve. As the tumor enlarges, there are symptoms of obstruction of the nasal fossa and of the nasal duct. The cheek becomes prominent, and when the external bony wall is perforated, the tumor may be felt in the soft tissues of the cheek. The skin may become discolored, but rarely ulcerates. The tumor may fungate into the mouth. These tumors usually invade the orbit, causing exophthalmos, with or without impairment of vision.

Carcinoma of the lower jaw causes earlier evident involvement of the lymph nodes than does carcinoma of the upper jaw. This may be due to the fact that most of the lymphatics leading from the upper jaw empty into the internal maxillary and retropharyngeal nodes, which are not palpable. *Inability to palpate enlarged lymph nodes in the neck should never be taken as evidence that they are not involved.*

The diagnosis of the hard, ulcerating carcinoma is usually not difficult from the clinical picture and its chronicity, but a microscopical examination of the tissue should never be omitted. The medullary carcinoma when situated on the oral surface should be subjected to the same examination.

The malignancy of medullary carcinoma when at all advanced is always evident from the rapidity and impartiality with which it invades all tissues with the exception of the teeth and eyeballs. Any growing intramaxillary tumor should be investigated, and even unaccountable pain over the distribution of the fifth nerve in elderly persons should

lead to careful examination of the whole area of its distribution. If a piece of the new tissue cannot be obtained from within the nasal fossa, it is a simple matter to open the antral cavity through the canine fossa so that a digital examination can be made and a piece of tissue obtained.

The prognosis of carcinoma of the body or surface of the maxilla is bad. The medullary tumor which attacks it rapidly invades the neighboring spaces, and the lymphatics are out of the reach of surgery. With the hard carcinoma of the surface of the lower jaw, the prognosis is very much better. If seen early, it may be rather favorable after a proper operation.

**Treatment.**—The treatment is free excision of the primary growth, and if the growth is on the alveolar surface of the upper, or on the lower jaw, excision of all of the lymph nodes of that side or both sides of the neck. The plan of excision of the primary growth should correspond to its location and extent. Carcinoma invades all tissues, and the excision should be planned to include all tissues to the extent of  $1\frac{1}{2}$  to 2 centimeters beyond the visible margin of the growth. We believe an exception to this rule may be made in the case of an ulcerating carcinoma of the mucous lining of the cheek which apparently does not extend to the buccinator muscle. If the tissues are removed down to the skin, the latter may be allowed to remain, and in this way a much better repair can be done. For ulcerated carcinoma of the lower jaw which has apparently not invaded the tooth sockets, it may be well, all things considered, to retain 5 millimeters of the lower border of the body of the jaw.

### RETROMAXILLARY TUMORS.

A number of tumors growing or originating within the sphenomaxillary fossa may come under this heading. The most common is the fibrous tumor, which arises from the base of the skull in the form of the nasopharyngeal polyp, which, as it grows, fills the nasal fossa and the nasopharynx and extends through the sphenopalatine foramen into the sphenomaxillary fossa, thence along the line of least resistance, filling the posterior part of the orbit and the zygomatic fossa. It may enter the antrum and fill this also. As the tumor grows, it forms adhesions, and it is these new attachments that render the growths very difficult of radical removal. They occur almost exclusively in young males, first appearing about puberty, and continuing to grow until they reach the age of about eighteen or twenty years, when growth usually ceases, or the tumor may recede. Occurring as they do during the period of body growth, it is easily understood how they cause deformity of the bones which bound the cavities they invade. The nose becomes broad, the eyeball protrudes, the cheek bones become

prominent, and the zygoma is bowed outward. The faucial pillars may be pushed downward and inward, and a red, soft, easily bleeding mass protrudes from the nose, while the entire naso- and oropharynx may be filled with the mass to such an extent that tracheotomy is required. According to Schlatter, the alveolar arch and hard palate are not involved in the non-malignant growths. In a case of ours, however, which was subjected to repeated and careful examinations by Dr. Opie, and Drs. Smith and McBain of his staff, and was pronounced by them to be pure fibroma, there was destruction of the hard palate by a mass of the tumor which protruded through the bone. The roots of several molar teeth were loose and painful, and particles of the tumor were adherent when they were removed.

Besides a microscopical examination, the diagnosis between the pure fibromata and malignant tumors is to be made on the history and the behavior of the growth. The nasopharyngeal fibroma, or polyp, begins with a growth in the nasopharynx or the sphenomaxillary fossa, causing partial obstruction. If the growth is higher, near the sphenoidal fissure, there may be ptosis, palsy of the ocular muscles, choked disc, and impairment of vision. As the tumor gradually enlarges, the clinical picture, already described, develops, but it takes some years to do so. The bones become distorted, but usually not thinned. Truly malignant tumors, as a rule, grow rapidly and destroy the bones they encounter; but the dividing line between certain fibromata and the fibrosarcomata is difficult to establish.

The prognosis of the frankly malignant tumor is bad, but in a few sarcomata something might be accomplished by the use of toxins or the ligation of vessels.

The prognosis of the pure fibromata is not always good; as many of them cease to grow or even shrink with the cessation of normal body growth, and as much can be accomplished by carefully planned surgery, the prognosis of these tumors is not nearly so bad as the extent of the involvement might lead one to think.

**Treatment of Retromaxillary Fibromata.**—Von Langenbeck did a temporary resection of the maxilla, and removing the tumor, cauterized the base with the actual cautery. Partly on account of hemorrhage, this is a most dangerous procedure. Considering the tendency of the tumor to spontaneous subsidence at the end of adolescence, it is hardly warranted, but the hemorrhage in all such operations can, to a certain extent, be controlled by a temporary ligation of both external carotids. It is better to remove the tumor piecemeal at different operations, in hope of holding it in control until it ceases to grow. If its pharyngeal attachment can be determined, this part can be removed with a strong snare or old-fashioned uterine ecraseur. Before this is attempted, a

postnasal tampon should be prepared. Its strings should be in place in the nose before the base of the tumor is cut, so that the tampon can be immediately drawn into place. The tampon must be of the proper size, and the strings must be strong, as must be the wire of the snare. An accident to any of these, after the base is partially or wholly cut, might lead to disastrous hemorrhage.

The zygomatic and temporal fossæ can be invaded by a properly placed incision and a temporary resection of the zygoma; the orbit, by a temporary resection of the malar bone. But in operating, the incision should be so planned as not to cut the branch of the seventh nerve that supplies the eyelid. The maxillary sinus can be opened by the Denker operation (see p. 347). The cutting off of the blood supply, after the method of Dawbarn, and the use of Coley's toxins are also to be considered.

A report of the following case will, we believe, be of interest:

A boy, twenty years of age, from whom a nasopharyngeal polypus had been repeatedly removed from the nasopharynx between the ages of sixteen and nineteen years, was finally given up as hopeless, and he came to us for tracheotomy. Examination showed a red, soft growth, protruding 1 centimeter from the right nostril—the nasal fossa was greatly expanded on that side and collapsed on the other. The cheek was prominent, as was the zygoma, and there was a well-marked exophthalmos, without ocular symptoms. The whole of the nasopharynx and oropharynx, as far as the finger could reach, was filled with a rather firm tumor which had its attachment above. In April, 1911, tracheotomy was done. A week later the branches of the right external carotid were exposed, and the superior thyroid, lingual, facial, ascending pharyngeal, and occipital arteries were doubly ligated. The remaining part of the vessel, that giving off the posterior auricular, temporal, and internal maxillary arteries, was injected first with boiling water, but as this did not stop the recurrent flow of blood, the vessels were injected with 6 cubic centimeters of hot wax. After this, the wax could be felt in the temporal artery. One week later, this operation was repeated upon the left side, and after splitting the velum, the pharyngeal portion of the growth was removed, the strings of the postnasal tampon having been previously placed in the nose. After splitting the velum, it was found that both the nasal and pharyngeal parts of the tumor arose from a broad base attached around the neighborhood of the sphenopalatine foramen and to the outer wall of the nasal fossa. With a proper snare the whole mass could have been removed at this time, as the nostril was so distended as to easily admit the index finger for its full length; but there was none at hand, the strength of which we were willing to trust. The free hemorrhage, which occurred after attempting to crush the base with a long clamp, convinced us that the growth obtained some of its blood supply from the branches of the internal carotid. Consequently, after also removing a large part of the mass from the anterior nares, the anterior and postnasal tampons were drawn into place. Two weeks later, it was found that the growth in the temporal fossa had receded so that it could no longer be felt, but of course, the zygomatic arch was still prominent. We believe the recession of this

part of the growth was caused by the shutting off of its blood supply. The part of the tumor in the nasal fossa continued to grow rapidly, and by this time again protruded 1 centimeter from the nostril. The injection of Coley's toxin was begun, giving at first  $\frac{1}{2}$  drop and gradually increasing the dose to 5 drops each day. The injections were given in the arm, and no general reaction was ever noticed. In about two weeks afterward, he noticed he could draw breath through the left nostril, and in the course of a month, he could draw breath through the right nostril. During this time, without any other treatment, the nasal growth had shrunk until the anterior nares appeared almost empty, its lateral attachment being represented by a red scar.

The toxins were continued for four months, at which time they were discontinued because the boy was anemic and depressed. At this time it was found that the whole palpable part of the tumor had turned into a cavernous angioma with thick walls. Several injections with boiling water had little effect, but much of it was later destroyed by puncture with a cautery. At the present time, June, 1912, the tumor is growing slowly.

Tumors of the septum, tongue, floor of the mouth, and pharynx will be presented in separate chapters.

## CHAPTER XXIX.

### EXCISIONS AND TEMPORARY RESECTIONS OF THE JAW-BONES.

In making an excision of any part of the jaw-bones, conservatism is to be strongly recommended. In dealing with a doubtful tumor of the breast or of almost any other part of the body, the surgeon treats it as a malignant disease and makes the widest possible excision. This is not the rule by which he should be guided when confronted with a tumor of the jaw. Partly on account of the deformity resulting from an extensive excision, partly because extensive resections are more apt to be fatal, but chiefly because benign, mildly malignant, and small malignant tumors are best treated by limited excisions, and the very malignant ones can seldom be cured by any reasonable surgical procedure, surgeons are coming to the conclusion that in the jaws the rule should be reversed, and doubtful tumors should be treated by limited excisions.

#### RESECTIONS AND EXCISIONS OF THE MAXILLA.

In the upper jaw, owing to the softness of the bone and its solid attachments, the alveolar process, the hard palate, and in fact the whole bone can be removed with a chisel. In the lower jaw the alveolar process can be removed with biting forceps, but if the excision is to extend into the substance of the body, it is best accomplished with a wire saw.

**Resection of the Superior Alveolar Process.**—To remove an extensive section of the upper alveolus, a tooth is drawn in front of and behind the section to be removed. The mucoperiosteal covering along the line of junction of the palate and alveolar process is cut between these points. A corresponding incision may be made along the outer covering of the bone; but this is not necessary, as here the mucosa will be cut with a sharp chisel. At the extremities of the proposed excision, the alveolar process is cut through by placing the edge of a thin, sharp chisel across its lower border and cutting directly upward. These two vertical cuts having been made, the chisel is placed against the upper part of the outer surface of the block to be excised, and the horizontal cut is made (Fig. 314). As soon as the block is felt to be loose, it is grasped with toothed forceps and twisted out. The operation is very

bloody, but can be completed in a few minutes, when the hemorrhage is controlled first with pressure and later by suturing the mucosa of the buccal fornix to the cut edge of the palate mucosa. If the surgeon prefers, he can resect the upper alveolus with a wire saw, by the same procedure as is described for resection of the lower alveolar process.

**Resection of the Palate and Alveolar Process.**—Removal of one half of the alveolar process and the hard palate of the same side can be done as follows:

The mucous membrane in the upper fornix is to be incised to the bone. If the mucoperiosteal covering of the palate is to be removed with the bone, the velum of that side is detached from the hard palate by a transverse incision which extends from the midline outward between the maxillary tubercle and hamular process. This cut divides the full thickness of the soft palate, and the bleeding is temporarily checked by

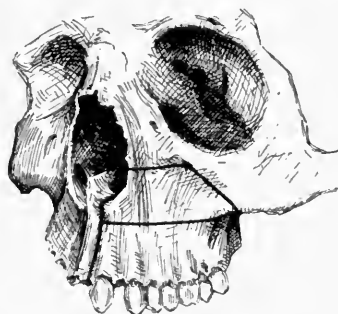

Fig. 314. Showing the line of the bone cuts for excision of one half of the upper alveolar process. Also showing the line of the bone cuts for a suprapalatal excision of the maxilla.

stuffing a wad of gauze into the gap. If the mucoperiosteal covering of the palate can be preserved, it is incised along its outer border and dissected up toward the midline. The velum is detached from the posterior border of the palate process by cutting through the palate aponeurosis and nasal mucous membrane only. In this way the velum remains attached to the soft covering of the hard palate, as in an operation for cleft palate. If the growth extends on the buccal mucosa, the cheek is split, and the growth is dissected free from the cheek but left attached to the alveolar process. The bone excision is made with two cuts, as follows:

(A) The chisel is placed vertically against the anterior surface of the alveolar process in the midline and driven back through the palate to its posterior border. In doing this, it is not necessary to drive the chisel to its full thickness through the alveolar process in order to cut the palate. The instrument may be withdrawn when the alveolus is cut

through, and applied to the palate from within the mouth. If the covering of the palate is to be preserved, it is lifted from the bone with a retractor. If it is to be included in the excision, it is cut by the chisel along with the bone.

(B) The alveolar process and palate having been split, the chisel is placed against the front of the jaw, with its edge and long axis parallel to the palate. The chisel is driven straight back to the level of the maxillary tubercle, and then by depressing the handle the mass is fractured from its posterior attachment. If this cut fails to loosen the bone, the chisel is withdrawn, and its edge placed against the malar process of the maxilla. This can be felt as a narrow buttress above the first molar tooth. This is cut through obliquely upward and inward (Fig. 314).

If the bone has been weakened by the disease, it is better to cut the maxilla from the pterygoid process with a chisel than to attempt to break it at this point; the fracture might occur through the diseased part.

If the excision is to include more than half of the lower part of the maxilla, the nasal septum will have to be cut through. This can be done by placing the chisel against the anterior nasal spine of the maxillæ and cutting straight back for the full length of the septum. This should be done before the body of the maxilla is cut through. By dissecting up the tissues of the face, the whole of the maxilla below the orbital plate can be removed with a chisel. In its upper part the body is so broad that two transverse cuts will be required, one for the outer wall of the nasal fossa, and one for the outer wall of the maxilla. The first of these will be horizontal and includes the anterior maxillary wall as far laterally as the infraorbital canal. The second will be oblique from above downward and outward, and on the anterior wall of the maxilla will extend from the infraorbital foramen to the outer extremity of the malomaxillary suture. In making the first of these transverse cuts, the chisel must enter the sphenomaxillary fossa, which is situated above the maxillary tubercle. In making the second transverse cut, the chisel must enter the zygomatic fossa. The distance the chisel must traverse from the infraorbital foramen to the sphenomaxillary fossa is equal to the distance between the anterior border of the first molar tooth and the hamular process, which is about 3 centimeters. If, before beginning the operation, this distance is measured and a mark is made on the outer border of the chisel, the cut can be made to the proper depth.

The hemorrhage during these operations is very free, and unless the surgeon has made prophylactic constriction of the carotids, bold, quick, accurate cuts and quick removal of the mass are necessary. The



forceps which are used to twist out the bone should be strong and armed with teeth that will take a firm hold, so that no time will be lost. The cutting of the bone and removal of the mass should take but a few minutes.

As soon as the bleeding has somewhat subsided, the temporary packing is removed, and in its place is substituted a permanent pack which is made with a gauze strip, 1 meter long and 5 centimeters wide. This gauze should be impregnated with iodoform, xeroform, or colloidal silver. The permanent packing begins at the posterior part, the gauze being put up into the nasal fossa and also into the antrum, if these have been opened. The packing is done from behind forward; and the end of the pack in the nasal fossa is allowed to protrude from the nostril. The pack must not be so tight as to damage the mucous lining of the cavities, and must be placed in an orderly fashion so that it can be easily withdrawn. This pack having been placed, the edge of the palate mucosa is sutured directly to the buccal mucosa, if they can be approximated; if not, the pack is supported by a hammock of sutures which passes from the edge of the palate mucosa to the cheek. Any persistent bleeding points in the mucosa of the mouth or the cut edge of the velum can be controlled with sutures.

The pack is removed after twenty-four hours by withdrawing it from the nostril, and is ordinarily not replaced. If the edges of the mucous lining of the cheek and of the palate have not been directly coapted, the sutures which support the pack are cut. After this a nasal douche and mouth wash are used frequently. Even when the nasal fossa and antrum are left wide open, during the process of healing the size of the communication with the mouth is greatly reduced and can later be closed by prosthesis.

It has been suggested that the gap between the mouth below and the antrum above be closed with the nasal septum. This is to be done at the time of the excision. The septum is cut high up, in a line parallel with the palate. This cut is joined at its anterior extremity by a vertical one which extends down to the floor of the nose. The flap thus freed is broken at its base and swung laterally until it is horizontal, when the outer extremity can be sutured to the mucosa of the cheek. The velum is sutured to its posterior border after denuding. This is a difficult thing to do.

**Resection of the Upper Part of the Maxilla.**—The maxilla is exposed by the same incision as that for complete removal. If a part of the orbital plate is to be removed, the contents of the orbit are elevated with a spatula. The excision is made with a chisel. After invading the antrum, a wide permanent drainage opening should be made through the inferior meatus of the nose. Otherwise the antrum may be filled

with blood or pus. After completing the excision, a strip of gauze is placed in the antrum, with one end protruding through the inferior meatus and the nostril. The incision in the face is completely sutured. The gauze in the antrum is withdrawn in twenty-four hours, and the cavity is irrigated through the nose with saline, or alkaline antiseptic solution 1 to 3.

**Total Resection of the Maxilla.**—This can be accomplished by raising the tissues of the face from in front of the maxilla through an incision made in the upper fornix, in connection with accessory small incisions over the nasal and malar processes of the maxilla. This does not give sufficient exposure to deal accurately with the floor of the orbit. A number of free cutaneous incisions have been used, but the most effective and least objectionable is a modification of that proposed by Weber. (Kocher's incision is shown in Fig. 315.) This latter does

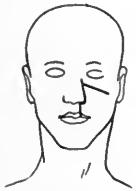

Fig. 315.

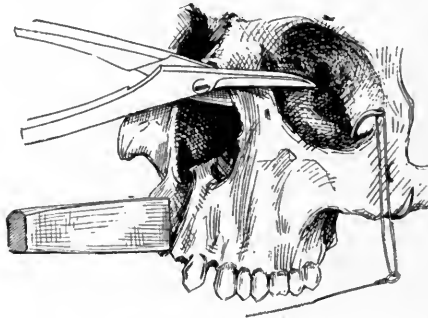


Fig. 316.



Fig. 317.

Fig. 315. Kocher incision in the cheek for total excision of the maxilla.

Fig. 316. Showing methods of dividing the bone in total excision of the maxilla.

Fig. 317. Incision for osteoplastic resection of the upper jaw.

not endanger the nerve supply to the orbicularis palpebrarum. In both of these, there is danger of a slough of the sharp corner of the flap. In Kocher's it is not followed by serious distortion, but in Weber's the lower eyelid may be pulled down.

In cases where the growth is confined within the maxillary bone, the soft tissues may be raised from the periosteum, but if the bone is infiltrated, more tissue must be removed with the bone. Wherever the soft tissues are involved, this area must be included in the excision. The face flaps are dissected back until the pyriform fossa of the nose, and the orbit are opened. The soft tissues covering the palate and the velum are dealt with as in partial resection (see p. 371). If the orbital contents are not to be removed, they are elevated from the floor with a spatula, and the bony walls that separate the orbit from the nasal fossa and from the zygomatic fossa are clearly defined. To cut through the

malar process, a  $\frac{5}{8}$ -circle needle is inserted through the anterior end of the sphenomaxillary fissure so as to protrude from the zygomatic fossa (see Fig. 316). This needle is threaded with a carrier and is followed by a wire saw, by which the malar bone is sawed through. Next the nasal process of the maxilla is cut through with a long-bladed cutting forceps. One blade is placed in the nose, and one in the orbit. This cut should also extend into the sphenomaxillary fissure. Lastly, the alveolar process and palate are cut through with a chisel or wire saw, the jaw is wrenched out with lion forceps, and the cavity immediately packed with antiseptic gauze. In total resection of the maxillæ the operation is repeated on the other side.

As soon as the bleeding is sufficiently controlled, the cavity and specimen should be examined to see if the growth is entirely removed, and further excision can be made.

The cavity is packed with a strip of gauze, one end protruding through the nose, and the intraoral part of the wound is treated (see p. 373). The face flap is sutured in place. If part has been excised, it is replaced by sliding or turning flaps from the forehead or the lower part of the face and neck. In case of a growth that might involve the orbit, before operating, permission should be obtained to remove the eye if it is found advisable to empty the orbit.

**After-treatment.**—After any of these operations, the remaining cavity is kept clean by frequent irrigations. As soon as possible, a prosthetic apparatus should be made. Where the orbital plate of the maxilla has been removed, there is apt to be a luxation of the eyeball. Numerous attempts have been made to prevent this by suturing a piece of neighboring muscle across the orbit below the eye, but these have not been as satisfactory as a prosthetic apparatus which is applied early.

### OSTEOPLASTIC RESECTIONS.

**Osteoplastic Resections.**—This means of reaching tumors originating from the base of the skull was introduced by von Langenbeck. He made the approach from the face by carrying an incision from the inner angle of the eye, along the lower border of the orbit, as far as the middle of the zygoma. From this point it curves downward to the level of the lower border of the nostril and then straight forward to the latter point (Fig. 317). The incision is carried down to the bone, but the flap is not elevated. The origin of the masseter is cut from the lower border of the malar bone, which will allow an elevator to be inserted into the sphenomaxillary fossa. Von Langenbeck passed a narrow-bladed saw into the pharynx through the sphenomaxillary fossa, guiding its inner end with the finger of the left hand passed into the pharynx from the mouth. With this saw the jaw-bone is cut above the alveolar pro-

cess as far forward as the pyriform opening of the nose. A nasal saw with a probe end, run by a surgical engine which has a 5 millimeter stroke, would do this safely and cleanly. A chisel might leave a rough edge, which would prevent the subsequent turning out of the bone flap. Above, the nasal process of the maxilla, the wall of the nasal fossa, and the wall between the orbit and temporal fossa are divided as in making a complete excision. Finally, the zygoma is cut through by means of a wire saw placed under the malar bone, and the whole mass is swung forward with the base of the flap at the nose as a hinge. After completing the removal of the tumor, the jaw is returned to its place, and the soft tissues sutured.

Exposure of the nasopharynx through the mouth is detailed under Tumors of the Pharynx (Chap. XXXIX). Gussenbauer and Nélaton have both described similar operations.

The deep fossæ at the base of the skull can be approached in the midline by turning the maxillary bones to each side. The upper lip is incised in the midline, and the incision is carried around the ala of the nose up to the inner end of the infraorbital ridge on each side. The alveolar process, the palate, and velum are split in the midline. Working through the external incision, both maxillæ are cut across above the alveolar processes with a chisel, without destroying the continuity of the mucous lining of the fornix and the cheeks, from which the blood supply is to be derived. After severing the lower attachment of the septum, the lower portions of the two maxillæ can be turned laterally. If necessary, the external nose can be turned upward, by cutting the attachments of the nasal bones from the septum and the nasal processes of the maxillæ, and fracturing their attachment to the frontal bone.

After removing the tumor, the maxillæ are replaced and wired, and the soft parts are sutured. If packing is used, it should be in the form of long strips which are let out through the nostrils. The operation just described is the operation of Kocher, carried to the limit of surgical possibilities. Such an operation will very seldom be indicated.

**Mortality.**—The immediate mortality of total resection of the maxilla has been variously placed between 2.8 and 30 per cent. As pointed out by C. Schlatter, the difference between high and low mortality is not dependent on the introduction of asepsis, but on the adoption of measures to prevent aspiration of blood during the operation. Heuter, in 1867, suggested that the entire operation should be done without anesthesia. Krönlein used a little morphin and a few whiffs of ether, but operated mainly under suggestive anesthesia. He has had a death rate of 2.8 per cent.

Most operators would hesitate to undertake so formidable an operation without a general anesthesia, but much can be done to lessen the

danger of aspiration even under complete anesthesia. The lateral position will help. Tracheotomy with pharyngeal packing or intratracheal insufflation can be used in some cases, but the Trendelenburg tampon cannula should be discarded. Preliminary constriction of the carotids (see p. 544) has the double advantage of saving blood and limiting the danger of aspiration. Schlatter cites Reyher, v. Lesser, Bryant, Schönborn, Kocher, and Fritz König, as well as himself, as being strongly in favor of this procedure. After controlling the blood supply, the patient can be placed in the lateral position, head somewhat dependent, and in this way aspiration is prevented without the use of complicated time-consuming procedures.

**Prognosis.**—For carcinoma, the ultimate prognosis for cases requiring total resection has been very bad, the majority of series showing the cures amounting to 1 per cent or less. Schlatter states that in the Zurich clinic recurrence took place after an average of 3.9 months in all cases of malignant tumor that involved the entire jaw. With early diagnosis and partial resections the prognosis is much better, 50 per cent remaining well for three years or longer. The prognosis for sarcoma is better than for carcinoma. It has not been considered expedient to remove the cervical lymph nodes in most cases, because the lymphatics first involved are inaccessible.

### RESECTION AND EXCISION OF THE MANDIBLE.

Excision of the condyle was presented under Ankylosis, page 270; of the anterior part of the ramus, under Salivary Fistula, page 425; posterior part of the ramus, under Parotid Excision, page 433, and Resection of the Body for Deformity, page 251.

**Resection of the Inferior Alveolar Process.**—The alveolar bone can be removed with biting forceps. If, however, the excision is to extend into the hard bone, a much more accurate and extensive removal can be made with a wire saw. In front of the third molar tooth this can be done from within the mouth, but behind the second molar an external incision is usually required.

The body of the jaw can be exposed by splitting the cheek from the corner of the mouth to the anterior edge of the masseter, or by an incision running along the under border of the bone on one or both sides. In connection with this inferior incision, the coverings of the chin with the lower lip may be split in the midline, or at the corner of the mouth.

To excise a portion of the alveolus and body but still preserve the bony arch by a narrow bridge of the lower border, the bone is exposed both on its inner and outer surface, and the body is traversed by two drill holes, one at each extremity of the proposed longitudinal bone cut. A needle threaded with a silk carrier is passed into one of these holes

and out of the other. By means of this carrier a wire saw is drawn into position for making the longitudinal cut (Fig. 318). Again passing the saw through each of the drill holes in turn, the alveolar process is cut vertically, liberating the diseased mass. Before making the bone incision, any disease of the soft tissues is to be liberated and included with the bone excision. (Complete resection of the body was described under Correction of Jaw Deformities, Chap. XX.) Before removing the mental part of the body, the tongue should be controlled by transfixing it with a ligature.

**Disarticulation of Half of the Mandible.**—The incision is carried along the lower and posterior borders of the jaw nearly to the lobe of the ear, but the facial nerve and parotid gland must not be cut. The tissues are dissected from the outer and inner surface of the body, and the latter is cut through with a wire saw. The tissues are freed



Fig. 318. Excision of the lower alveolar process. The posterior vertical cut is represented as having been made; the anterior is partially made with the saw still in place. The saw is in position for making the longitudinal cut.

from the outer and inner surfaces of the ramus, and the body is drawn downward and backward; this brings the coronoid process into view. The coronoid process, or the tendon of the temporal muscle attached to it, is cut through. The condyle is then twisted out of the glenoid cavity. In double disarticulation the operation is repeated on the other side.

**Mortality.**—The mortality for simple resection of the jaw for deformity has in our experience been nil. For excisions involving the full thickness of the bone, it is considerably less than for total excision of the upper jaw, but when a piece is excised in conjunction with an excision of the tongue, the mortality may be something between 25 and 40 per cent.

**Prognosis.**—The prognosis after excisions for carcinoma of the lower jaw, which is usually of the hard ulcerating type, is very much better than after excision for carcinoma of the body of the upper jaw.

After excising a carcinoma of the lower jaw, the lymphatics of the neck should be treated as in carcinoma of the tongue.

### PREVENTION OF DEFORMITY.

After removal of one half of the upper jaw, if there are sound teeth in the remaining section, an obturator and a plate carrying teeth can be attached to the teeth in the sound half of the jaw. If there are no teeth in the sound jaw, the plate might be held in place by springs attached to a lower dental plate, or to bands placed on the lower molars.

Not the least important point about an excision of a segment, that includes the full thickness of the body of the lower jaw-bone, is the immediate substitution of an artificial support to take the place of the missing part, or the adoption of some means of preventing the displacement of the remaining portion. This is too frequently neglected. By doing this, the immediate discomfort is lessened, and subsequent deformity is in a large measure prevented. After one half, or a large piece, of the body is excised, the remaining fragment, unless supported, will be drawn backward and toward the median line. The first effect of this is to relax the muscles of the floor of the mouth, allowing the tongue and hyoid bone to fall back. Later, by scar contraction, the displacement is made greater so that the lower teeth no longer articulate with the upper. When the anterior part of the body is removed, there is no support to the muscles taking origin from the symphysis, and the remaining posterior portions of the body are both drawn toward the midline.

To prevent these displacements, several means have been resorted to. After removal of a large part of one side of the body, or a disarticulation of one half of the body, the simplest method of preventing displacement is to wire the teeth of the remaining section of the lower jaw to those in the upper, as in dressing a fractured jaw. This method was proposed by Dr. Gilmer, and we have found that after having the jaws wired together for three weeks there was little subsequent displacement (Fig. 319). It is especially applicable to those cases which include a wide excision in the soft tissues. After wiring the teeth, the opening between the jaws may be found to be limited by a band of scar attached to the cut end of the bone (Fig. 320). This is to be later corrected by freeing this band from its attachment to the lower jaw by surrounding the lower part of the band with a deep V-shaped incision. The mouth is opened to its fullest extent, and the defect remaining after liberating the scar band is eliminated by suturing the edges to the mucous membrane of each side. Sometimes it is necessary to make this V-shaped incision through the full thickness of the cheek (Fig. 321).

The other plans of preventing displacement consist in substituting

bone or some foreign substance for the section of bone removed. The simplest way of doing this is to reproduce the removed portion from dental modeling compound, setting the artificial section down in the trough from which the bone was removed. The modeling compound, having been softened in hot water, can be moulded to the exact size and shape desired, right at the operation. This may be steadied in place by a few sutures passing through its substance, attaching it to the bone

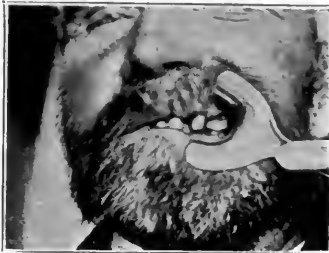

Fig. 319.



Fig. 320.



Fig. 321.

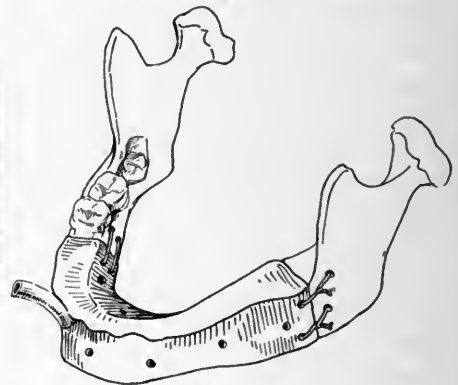


Fig. 322.

Fig. 319. Showing occlusion of the teeth, after excision of one half of the mandible, when the remaining half of the lower jaw was immediately wired to the upper. This photograph was taken some weeks after the wires were removed.

Fig. 320. Showing band of scar tissue that binds the jaws together, after removal of one half of the jaw with part of the adjacent tissue.

Fig. 321. Showing opening obtained in the preceding case, after freeing the lower attachment of the scar band, as described in the text.

Fig. 322. Martin splint for replacing an excised portion of the lower jaw.

or the soft tissues. The jaw can be made more secure by wiring the upper to the lower teeth. As soon as possible, a prosthetic apparatus which carries teeth replaces this temporary splint. It is made to fit the remaining part of the jaw and teeth, and fits snugly into the space which was occupied by the temporary splint. A more elaborate method of doing this same thing is the use of the Martin splint (Fig. 322). In a case of Schlatter's, in which he removed several centimeters of the lower jaw in a girl ten years old, before the girl was eighteen years old



the artificial jaw had to be replaced four times on account of the growth of the bone.

The foregoing methods have the advantage to the general surgeon that he can prepare them himself at the operation, or have them constructed beforehand and adapt them to the conditions resulting from the operation.

C. Martin, of Lyons, was possibly the first to attempt the prevention of deformity by immediate prosthesis. His splint, which is, in general size and form, a reproduction of the segment of bone to be excised, is constructed of gutta-percha. It is hollow and is perforated with small holes on its under, inner, and outer surfaces, and over one of these a short piece of rubber tubing is attached. The gutta-percha splint is made longer than is needed and is cut the proper length at operation. By means of wires, or screws and small silver plates, the splint is at-

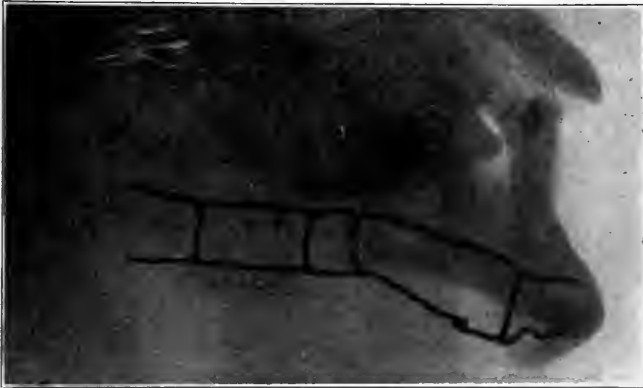

Fig. 323. Showing silver wire bridge in place, replacing one half of the body of the lower jaw.

tached to the ends of the bone, and is allowed to stay in place until it can be replaced with a permanent prosthetic apparatus. During the course of convalescence, the wound is irrigated at frequent intervals with water, or some solution forced into the splint through the rubber tube. According to reports, this splint gives excellent results, but probably no better on the whole than can be obtained with a properly fitted splint of modeling compound. When it is intended to use either of these splints, it is preferable to avoid a long incision at the lower border of the jaw. Failure of primary union would leave the splint without external tissue covering. A small drainage opening should be made at the bottom of the sulcus. Both can be used after a disarticulation. Another plan is to make a bridge of strong wire, No. 10, and insert its ends into holes in the cut surface of the bone. In order to prevent the wires from gradually pressing deeper into the bone and thus lessening the gap, each wire is crooked into a shoulder, near its free

end, which rests against the end of the bone at each of the drill holes. Such a bridge can be prepared beforehand, much longer than will be needed; at the operation the surgeon can cut it to the proper length and bend in the shoulders at the proper places (Fig. 323).

Partsch complicated the arch by attaching a simple band of metal to the outer surface of the remaining ends of the bone, with wire. It is intended that both the wire splint and Partsch's band be allowed to heal in place. For this reason they should be made of some bland metal, such as silver. If a sinus persists that will not heal on the injection of bismuth paste, or if part of the splint remains exposed and it cannot be buried by a flap operation, then all or part of the splint will have to be removed. If the splint can be made to stay in place several months, much good is accomplished. Gilmer is our authority for stating that bridges or splints, which are attached to the teeth only, are never satisfactory as a permanent means of holding the fragments in place after removal of a complete section of the lower jaw.

A number of more elaborate splints have been devised to prevent displacement of the remaining portion of the mandible. One of the earlier was a pair of interlocking flanges, which were constructed so that one half was attached to the teeth of the upper and one half to those of the lower jaw. These are so arranged that the jaws can separate, but the half mandible cannot be drawn toward the midline. These are seldom used except as corrective measures. Where no preventive measures have been used, and displacement of the jaw fragments has occurred, much has been accomplished by the use of the inclined planes. A lug or a metal plane is attached to a lower tooth, set obliquely, and resting against the outer surface of a corresponding upper tooth or a plane attached to the upper tooth. These inclined planes are so arranged that, as the jaws close, the lower jaw fragment is forced to travel outward as it moves upward. In this way some very good results have been accomplished in bad cases.

Small defects have been filled by turning a bone flap from the lower border of the neighboring intact part of the jaw. Ivory splints have been successfully employed. According to Magnuson, ivory heals very rapidly *in situ*, and is replaced by bone. With a careful secondary operation, a piece of rib can be inserted between the cut ends of the bone, through an external incision. Such transplanted bone must retain its periosteum, otherwise it may eventually be absorbed. The space in which it is imbedded must not communicate with the mouth, as the wound should remain aseptic. Therefore, it seems to us that bone transplantation cannot be done at the primary operation with any reasonable hope of success. Dr. Judd, of Rochester, tells us that he has succeeded in retaining a section of rib in a cavity that had

communicated with the mouth, but he considers it necessary to retain the periosteum both of the rib and the jaw. We saw him do one such an operation for a cystic adamantinoma, but there are few conditions in which it is advisable to remove all of the bone and leave the periosteum. We have had a number of successful cases where we have transplanted rib or cartilage into the tissues in clean cavities, and retained the periosteum only on the transplanted bone.

A resected portion of rib has been temporarily enveloped in a skin flap, and after acquiring a source of nutrition, has, with its skin envelope, been transplanted into the jaw. In one instance, in a rapidly growing carcinoma which involved half the jaw, the submaxillary region, and the lower part of the face, the patient elected to take his chances on an operation. The nature of the growth demanded that this be done at a single sitting. Before invading the mouth tumor, we freed the flap of tissue which extended from the level of the mastoid process to 10 centimeters below the clavicle, having its attachment above. This flap included the sternomastoid muscle and the middle 8 centimeters of the clavicle. After removing the gland-bearing tissue of the neck, the borders of the remaining defect were drawn together. Then the tumor, including three fourths of the body of the jaw, the lower half of the cheek, the lower lip, and the tissues of the submaxillary region, was removed in one block.

The infraclavicular portion of the flap was turned upward and around the section of clavicle. The flap was brought forward to replace the defect in the face. The clavicular section being fastened to the cut ends of the jaw-bone, and the infraclavicular portion of the flap being used to replace the deficient buccal mucosa, left a submaxillary defect which was packed with gauze. Mechanically this worked out fairly well, and had the patient survived, we believe the vitality of the bone flap would have been insured, from the fact that it was surrounded by well-nourished tissues which are normally attached to it. Unfortunately, the patient did not long survive the operation.

Some patients with carcinoma are willing to take desperate chances. But it is questionable whether such an operation should ever be performed at a single sitting.

After the removal of one ramus no deformity occurs, but if for any reason both rami are removed, the body of the jaw should be wired to the upper until one or both rami are replaced by bone grafts at an immediate or a secondary operation.

## CHAPTER XXX.

### DISEASES AND TUMORS OF THE LIP.

Congenital clefts of the lips and palate were described in Chapter XIII.

#### INJURIES.

Bruises of the lip may cause great swelling, but as a rule need no special treatment. If seen early, ice may be applied. The lips may be deeply cut, usually from blows which drive the lip against the teeth. The cut may be entirely through the lip, or it may be only on its inner surface. In either case, the coronary artery may be cut. Wide cuts, or cuts that extend entirely through the lip, should be immediately and accurately sutured, but the sutures should not be drawn very tight, as swelling will occur. Usually the sutures will control the bleeding. If there is much sloughing tissue, this may be trimmed with scissors. A slight purulent discharge from the surface of the wound does not preclude immediate suture, but if there is much inflammation of the surrounding tissue, suture is to be postponed until this subsides.

#### SCARS.

The lips may show scars from various causes, the most interesting of which are fine radiating scars observed most commonly about the angles of the mouth, and which extend to the buccal surface. These are due to a former syphilitic infiltration and are to be differentiated from *perlèche*.

Deforming scars are to be excised and repaired according to the principles already given (Fig. 324).

#### LIP CRACKS OR CHAPS.

These are common and often annoying. They occur most commonly either at the corners of the mouth, or in the middle of the mucous surface. Persistent cracks or ulceration in the corners of children's mouths, becoming infected, may lead to lymphatic hypertrophy of the lip. Chronic cracks or ulcers at the corners of the mouth in children are sometimes due to syphilis. Simple cracks or chaps occur usually in winter, and in some persons they are recurrent and annoying; especially a crack that comes in the middle of the lower lip, being slightly indurated, with every movement of the lip tends to become deeper. It

bleeds occasionally and persists throughout the winter. It seems to be dependent upon the anatomical configuration of the lip, and persists on account of the induration of its edges and the mobility of the lip. If the two borders can be strapped together with an adhesive plaster for a week or so, it will heal; but this is difficult to do, and the remaining depression is very liable to open again. In the marked cases it is advisable to excise the fissure with a knife and approximate the borders with deep sutures. This may be followed by permanent relief. Lesser fissures are to be treated by the application of some rather stiff lip salve, to which an antiseptic may be added in appropriate cases.

### SIMPLE HYPERTROPHY.

Either lip may be enlarged from the habit of lip-sucking. Permanent simple enlargement of either lip often persists to an annoying extent after malocclusions have been corrected.

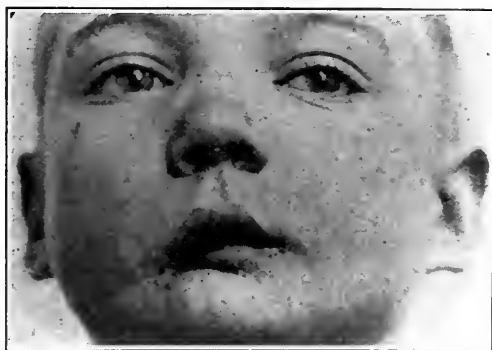

Fig. 324. Deformity of the lower lip, due to scar resulting from noma.

### MACROCHEILIA.

This may be due to a chronic lymphangitis, and is usually dependent upon a chronic inflammation of fissures, eczema, etc. It usually occurs in sickly children. When such a condition is noticed, great care should be taken to cure or prevent fissure, eczema, etc., of the lips. Chronic enlargement of the lip in an adult may be due to syphilis, and in infants, syphilis may cause a diffuse infiltration of the borders. If sufficiently pronounced to demand correction, it can be done by excising a wedge-shaped portion which will resemble a section from an orange. The long axis of the base of this wedge is parallel with the mouth slit. The base of the wedge is to be at the junction of the edge of the lip with its oral surface, and the edge of the wedge is to be taken from deep in the lip, with a razor-edged knife. Before doing this, both ends of the lower coronary artery should be, at least temporarily, controlled. A less

accurate correction can be made by simply removing a wedge from the central part of the lip, that includes an equal amount of the mucous and cutaneous surfaces.

### FURUNCLE.

Furuncle or carbuncle of the lips and face is of special interest because of the relative frequency with which it has been followed by thrombosis of the cavernous sinus of the dura mater. The explanation given for this is that the facial vein communicates freely with the ophthalmic and that neither contains valves.

### PHLEGMON.

Phlegmon may develop in the lips, and this is sometimes seen after the bites or stings of insects. There is always considerable edema. Ice is to be applied in the early stage, and an incision is to be made as soon as pus is located.

### GANGRENE.

Gangrene of the lips is almost always due to cancrum oris (see p. 291).

### HERPES.

Herpes of the lips is common. (See Herpes of the Mouth, p. 286.) On the lips the vesicles rupture and dry, leaving a yellow-brown crust.

### PERLÉCHE.

Perlèche is a superficial ulceration, limited to the angles of the mouth, which appears in children of school age, and is of interest chiefly because it has to be distinguished from syphilis. There is roughness of the skin at the angles, which is marked by numerous radiating grooves. The skin of the area is somewhat brownish in color, and sometimes moist fissures appear at the corners. There is a burning sensation which leads the children to lick the patches, whence the name. By most observers it is believed to be due to an infection. Lemaistre believes it to be due to an aerobic streptococcus. The treatment consists in the application of tincture of iodine, or a drying powder. It is to be distinguished from syphilis by its localization, the fact that the radiating grooves do not extend to the mucous surface of the cheek, and that in healing it leaves no scar.

### TUBERCULOSIS OF THE LIPS.

Lupus may occur on the lip in conjunction with lupus of other parts of the face. Ordinary tubercular ulcer may, but rarely, occur on the lip. (See Tuberculosis of Tongue, p. 446, which it resembles.)

## SYPHILIS.

The lip is a common site for extragenital chancre, which does not, as does the genital chancre, show a characteristic size and appearance, but does always at some stage show an indurated base. It may vary in size from a dime to a dollar and is usually ulcerated. The ulceration may be evident or hidden by thick crusted scabs. It is differentiated from carcinoma by its acute onset, its spontaneous recovery at the end of five or six weeks, the early and marked enlargement of the lymph nodes, its disappearance under antisyphilitic treatment, and the presence of *Spirochæta pallida*. Mucous patches are very common on the inner surface of the lip in the secondary stage of syphilis; deep in the fornix, where subject to little irritation, they are somewhat of the character of the patches under the tongue, but not so elevated. At the corners of the mouth, where they are very common, they are apt to ulcerate. At the edge of the lip a mucous patch may sometimes be seen to be continuous with a cutaneous papule. It is always to be remembered that the moist lesions of the first and second stage of syphilis are fruitful sources of contagion.

A diffuse infiltration of the borders of the lips may occur in syphilitic infants, which is marked by stiffness, a red-brownish color and a peculiar glossiness, and the development of radial fissures.

Gumma may develop in the lip and cause great destruction. (See Syphilis of the Mouth and Syphilis of the Tongue.)

## CYSTS.

Cysts of the muciparous glands of the lip are not uncommon. Usually there are one or several isolated cysts projecting on the mucous surface, but there may be so many as to cause an eversion of the lip. They are small, round bodies, usually freely movable, and may appear bluish.

Single cysts are to be grasped, with their mucous covering, with fine-toothed forceps, and the projecting portion cut away with scissors, the remaining portion being grasped and shelled out. For a general cystic condition of these glands, a mucous flap is to be turned down, and the mass dissected out; after which the remnant of mucous membrane is to be sutured back into place. If the mucous covering is too thin or ragged to give promise of living, flaps can be turned from the lining of both cheeks and sutured in place.

## HEMANGIOMA.

Angioma of the lip is not uncommon. In its early state, it usually shows a small purple spot, perhaps slightly elevated, which is compressible, but which returns to its original size when the pressure is

released. From this it may extend until most of one or both lips and a large part of the face are converted into a purplish tumorous mass. When seen, they are unmistakable. There is a form of superficial angioma known as "wine spots," which may appear on any part of the body. They form a sharply limited reddish-purple stain. In infants an angioma may be pedunculated.

As soon as an angioma shows a disposition to spread, it should be destroyed; in this way the patient may be saved from one of the more extensive type. For the extensive angiomata, Wyeth's method of obliteration with boiling water is often the best treatment. In some part of the tumor 20 cubic centimeters or less of boiling water is injected with a hypodermic syringe. The injection of one part is to cease as soon as the skin turns white, but sloughing does not seem to follow. Some weeks later another part is injected, and so on until the tumor is obliterated. The surgeon wears heavy rubber gloves to protect his hands, and the syringe should rest in a basin of boiling water until immediately before it is to be used. The water in the syringe should be of boiling temperature. For injections of any extent a general anesthetic is needed, but as the injection takes but a few minutes, gas with oxygen is appropriate. The electric needle and also the Paquelin cautery, thrust deep into the tumor, are used for destroying cavernous angiomata, but whenever possible, it is better to dissect out the mass with a sharp knife. For destroying large "wine spots," the repeated action of radium is most effective.

### ENDOTHELIOMA.

We have seen two cases of diffuse endothelioma of the face, which caused considerable deformity, and several smaller ones (Fig. 325). None of these presented any of the characteristics of mixed salivary gland tumors. The tumor was soft, feeling almost like an angioma. The overlying skin was coarse and deeply pitted at the pores. A microscopical section showed masses of endothelial cells and fibrous tissue which had replaced most of the normal tissue.

The treatment of the larger tumors was not very satisfactory, but by turning back as thin a skin flap as seemed compatible with nutrition and then dissecting out masses of the tumor, considerable improvement was obtained (Fig. 326). There was always profuse hemorrhage, and in more severe cases, we had to do several operations before the best result was obtained, because of the fear that sloughing of the skin might follow a too radical operation. The coarseness of the skin persisted, and it was not possible to perfectly restore the contour of the lip and the ala of the nose. Injections of boiling water proved ineffectual in the one case in which they were tried.



## WARTS AND PAPILOMATA.

On the lips these are not uncommon. In two specimens in the Hunterian Museum, in London, papillomata of the lip had developed true horn. Papillomata should be removed, both because they are unsightly, and because they may be an early stage of cancer. The same is true of a chronic scurfy patch, which may appear at the border of the lip in persons who have reached the cancer age. These may persist for years, and yet a microscopical examination may show them to be

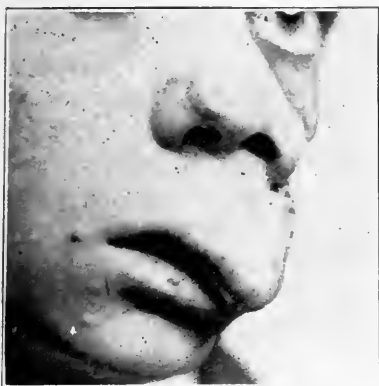

Fig. 325.

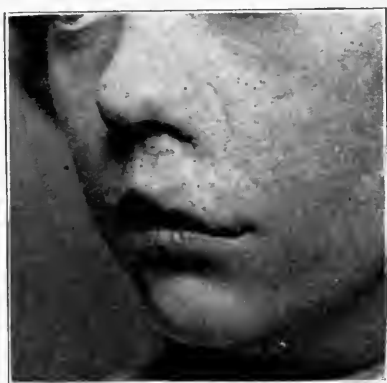

Fig. 326.

Fig. 325. Lymphangioma of the face in a young girl.

Fig. 326. Case shown in preceding figure, after operation. A part of the face tissue was removed up as far as the orbit, including a section from the ala.

squamous cell cancer or rodent ulcer. In some instances they gave a history of having apparently disappeared at times and returning, so this should not mislead one into considering them simple. They may be destroyed with lunar caustic or chromic acid, but a safer plan is to make a fairly wide V-shaped excision of the full thickness of the lip. One can afford to take no chances when dealing with carcinoma, as these indolent patches and warts often take on rapid growth after being irritated by a partial excision or cauterization.

## CHAPTER XXXI.

### CANCER OF THE LIP.

Cancer is more common on the lower than the upper lip, and much less common in women than in men. According to Heimann, out of 509 cases of carcinoma of the lower lip, 473 cases were in males and 36 in females. Smoking has been advanced as a cause of carcinoma. It often occurs at the side at which a pipe is habitually held, but may arise at another site and in persons who do not smoke. It is more common among the inhabitants of the country, which may be due to the greater exposure and consequent changes in the skin. Any chronic change of the skin may be the starting point of carcinoma, as may any chronic irritation. Leucoplakia (see Chapter XXXIV) may appear in one or several patches on the lip, and these may be followed by carcinoma. It is more frequent as age advances, but when it does occur in younger adults, is very malignant.

Carcinoma of the upper lip is usually of the type known as rodent ulcer, a carcinoma of the sebaceous glands, which is not very malignant either locally or in affecting the lymph nodes. Carcinoma of the lower lip is usually of the squamous type and occurs clinically in two forms: (1) The flat ulcer that appears at the mucocutaneous border, advances slowly, remains shallow, is surrounded by little induration, and that in the past has not been supposed to, as a rule, early invade the lymphatics. This form of carcinoma may persist for years and may even scar over only to reappear. (2) The other variety shows more elevation of the borders, much more induration, and deeper ulceration. It has a distinct tendency to run along the mucous surface into the cheek or gum. It early invades the lymph nodes and is very malignant.

### DIAGNOSIS.

The diagnosis of a well-developed carcinoma of the lip is usually simple and rests upon the ulceration, or scaly patch, surrounded by induration, and its chronicity—it having as a rule persisted for several months or years. Later in the disease there is salivation, cachexia, fetor, and enlargement or ulceration of the lymph nodes of the neck. The patient eventually dies of exhaustion or pneumonia, but very rarely from general metastasis. It is difficult to differentiate between a simple papilloma and a carcinoma, but a papilloma of the mucous border should be regarded as a carcinoma until proved otherwise by a very competent microscopist.

Occasionally chancre has been mistaken for carcinoma. The history of the case, the length of time that the sore has persisted, and the early involvement of the lymph nodes should give a hint that would at least call for a microscopic examination. A Wassermann test does not exclude carcinoma. Before carcinomatous glands become palpable, carcinoma of the lip usually presents an unmistakable picture. It is stated that the glands are not involved in 75 per cent of cases, which is probably a great exaggeration. It is often very difficult to feel small lymph nodes even in thin persons. So often have we found enlarged nodes at operation, when none could be felt previously, that we place no value on a negative result from such an examination. The rather general belief in the profession that the flat ulcers invade the lymph nodes late, or not at all, is now hardly acceptable. While there is apparently clinical evidence to support this view, still more recent careful observations tend to refute it. The length of time the carcinoma can lie dormant in the cervical lymphatics probably has much to do with it. We recently saw a case of rapidly growing squamous carcinoma of the submaxillary nodes in a man who had a healed scar on the lip, where a flat ulcer which existed two years had been destroyed with caustic eight years previously. Examples of lymphatic infection appearing two or three years after the destruction of the lip ulcer are not at all uncommon. On the other hand, nodes may be enlarged from absorption of septic material from the ulcer or from accidental causes.

While it is important to make a diagnosis in advanced cases, it is even more important to make a diagnosis of the incipient ones. Every chronic papule, wart, tumor, or abrasion of the lips in persons who have reached the cancer age should be excised and subjected to a microscopic examination. If there is any doubt in younger persons, they should be given the benefit of the same procedure; for, though less frequently, cancer does occur under thirty years, and it is then always very malignant.

### TREATMENT.

As already stated, incipient and early carcinoma of the lip can be destroyed with caustics, x-ray, or radium. But to be safe, the destruction must be deep, and when caustic is used, the resulting defect requires more time to heal and leaves more scar than does a clean excision. In certain instances the prejudice of the patient against "the knife" might force one to adopt such measures. It is probable that both radium and the x-ray are more efficient than caustics. Although they will, when properly applied, destroy the local growth, they can have little or no effect on infected lymph nodes. Although it may be possible that slow-growing carcinomata of the lip infect the lymphatics less early than at most other sites, still it is a safe rule to regard them as infected in

every case of carcinomatous ulceration or induration, and to remove them accordingly. *We have no right to assume that because the lymph nodes are not palpable they are not infected; and the only safe plan is to remove them in every instance where there is a definite carcinomatous ulceration and induration, no matter how small.* The nodes first infected are the submaxillary and the submental, and later the deep cervical. The extent to which the lymphatics are to be removed is to be determined by the clinical character of the growth and the special indications as found at operation. If no, or only slight, enlargement of the submental or submaxillary lymph nodes is found after turning down the skin flap, then one may content himself with removal of the tissue that carries these, and the superior deep and the superficial cervical nodes *en masse*. If, however, the superior cervical are palpably enlarged, then all the cervical nodes should be included on one or both sides. This is a more conservative course than is advocated in print by some surgeons, but it is our present rule. While it is not proper to neglect the lymphatics because, possibly, the majority of these tumors infect them only late in the disease; on the other hand, patients should not be subjected to needless surgery. There is some presumption in the attitude that the only risk the patient runs is in not making the operation sufficiently extensive. There is the possibility that there will be some infection of the wound, and a prolonged operation complicated by an infected deep dissection of the neck, especially in old persons, may be a serious matter. This is not our attitude toward the lymph nodes in the presence of a cancer of the tongue. Then an attempt is made in every instance to remove all of the lymph nodes on at least one side of the neck, but there is abundant clinical evidence to show that in most instances lip carcinomata are much less virulent. Possibly an exception should be made of cases of indurating carcinomata of the lip in young people, persons under forty or forty-five years; here the lymphatic excision should be as radical as for carcinoma of the tongue.

In carcinoma of the face and mouth it is usually not practical to remove all of the lymphatic ducts between the growth and the first group or nodes, but fortunately, secondary infection rarely occurs in these ducts. In the neck the ducts, as well as the glands, should be removed, if for no other reason than that by so doing all glands will be excised.

In the excision of the primary focus, conservatism should have little place. When one is tempted to spare tissue, he has but to think of a few cases he has seen in the end stages of mouth carcinoma to steel him to the safer course (Fig. 327). In dealing with a carcinoma of the lip, the surgeon had best forget he is dealing with a lip and think only of the growth. In the slow-growing flat ulcers of older persons, he may con-

tent himself with an excision that runs 8 or 10 millimeters to each side of the evident disease, prolonging the excision for 3 or more centimeters in the direction of the lymph streams. In the more rapidly growing, indurating variety, the incision had best be made at least 2 centimeters from its borders. If the growth has run on the cheek or upper lip, it should be treated in the same way. If it has encroached upon the gum apparently involving only the superficial tissues, these are to be removed, and the bone sawed or bitten away down to below the bottom of the tooth sockets. If the induration is deep or if the teeth are loose, showing the tooth sockets to be frankly involved, then a section of the whole thickness of the jaw-bone should be removed as part of a block

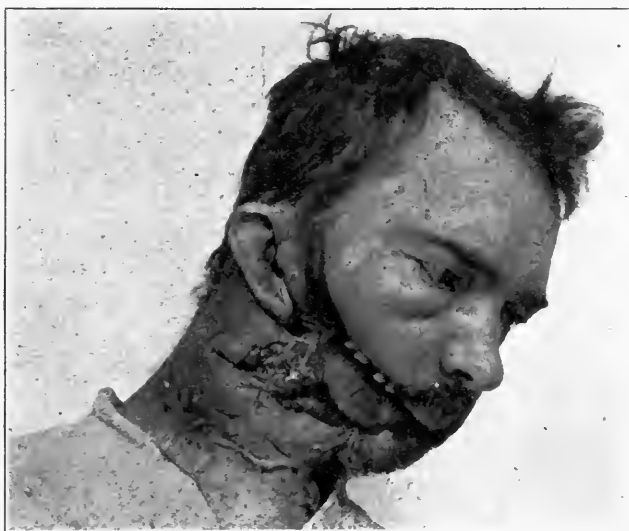

Fig. 327. Showing a patient in whom one half of the lower jaw and cheek was removed to get rid of an inoperable carcinoma of the mouth, resulting from a carcinoma of the lip. Several unsuccessful operations had been done on the lip and mouth. The patient was made much more comfortable by the removal shown, and the growth did not recur in the mouth.

incision. (See Excisions of the Lower Jaw.) If the involvement is of the upper jaw, then, with a sharp chisel, a part of the maxilla is to be removed. (See Excisions of the Maxilla.) *In every instance the whole mass is to be removed in one block. The incisions should be all outlined before the cutting is begun in any part.*

**Excision of Growths and Ulcers of Doubtful Character.**—Warts, persistent papules, or exfoliating patches should be removed by a V-shaped incision, through the thickness of the lip, that extends at least  $\frac{1}{2}$  centimeter to each side of their base. The incision is first outlined, and the sides of the V should be bowed somewhat outward, as this will lessen the subsequent defect, due to scar contraction (Figs. 202, 203). The lip is then injected with a 1 per cent novocain, with adrenalin, so-

lution, and grasped on the outer side of each mark with artery clamps held by an assistant, but not locked. The forceps will control the bleeding and steady the lip. The center of the base of the wedge to be excised is grasped with a vulsellum forceps in the hand of the surgeon; the excision is then made with a sharp knife or with sharp scissors. Hemorrhage is controlled by the sutures, but they are not to be drawn tight. If, after suturing, there is still oozing, an extra through-and-through suture may be drawn tight, the latter to be removed in six or twelve hours. The specimen should be examined microscopically.

**Excision of Indolent Carcinomatous Ulcers.**—This may be done by a V-shaped incision made 1 centimeter on each side of the base of the ulcer. If the ulcer is near the corner of the mouth, the excision shown in Chapter XVIII may be made. At this or a subsequent time, the glands are to be removed according to the plan to be outlined. If the gland operation is to be postponed to a subsequent sitting, the lip excision may be done under a local anesthetic, but the incisions should be outlined with the point of a knife before the lip is infiltrated with the anesthetic solution.

**Excision of Indurating Carcinoma of the Lip.**—Unless of exceedingly slow growth, the greater part of the lower lip with the soft tissues covering the chin should be removed. (Figs. 199-209 show several plans of excision according to the size and location of growth.)

The operation on the primary growth may be done at the same time as the excision of the lymph nodes, or the latter may be done at a subsequent sitting. If both are to be done together, it is our preference to operate on the neck first, stop all hemorrhage, and repair the neck before invading the mouth. In this way less infectious material is carried into the neck wound.

**Typical Operation for an Early Indurated Carcinoma of Lower Lip.**—In the operation about to be described, a part of the platysma myoides muscle and subcutaneous fat is removed with the mass, not because they are necessarily involved, but because certain nodes lie superficial to the muscle. Below the level of the hyoid bone the platysma muscle is to be retained; and in operations that require the raising and transplantation of large flaps from the neck, the platysma muscle is, where possible, to be included with the flap to insure its nourishment. Then care must be exercised to make the plane of cleavage immediately subjacent to the platysma, so as not to include any of the lymphatic nodes which accompany the external jugular vein.

The patient is placed in a recumbent or semisitting position, with the head thrown slightly back, so as to give good access to the upper part of the neck. An incision is outlined with the point of the knife, running along the lower border of the jaw from angle to angle, and  $2\frac{1}{2}$

centimeters downward and backward on the neck on either side (Fig. 328). Next, the sterile cloths are so pinned in place as not to obstruct the view of the neck. The incision, outlined, is made down to the platysma. The flap, including little more than the skin, is dissected downward to the dotted line. This dotted line crosses the middle of the neck at the upper border of the thyroid cartilage. The skin flap is raised, and the platysma and deep cervical fascia are incised along the dotted line. This incision should also cut the external and anterior jugular veins, which are to be caught with forceps. The proximal portions of these veins are to be at once ligated. A flap containing the superficial fascia, the platysma muscle, and superficial layer of the deep cervical fascia is now dissected upward, displaying the fibers of the anterior part of the sternomastoid, omohyoid, and sternohyoid muscles. As there are intermuscular processes of fascia, running from the deep surface of the cervical fascia between all of these muscles, the dissec-

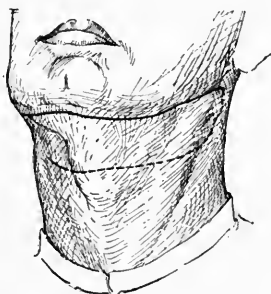


Fig. 328. Submental incision for cleaning out the submental, submaxillary, and superior deep cervical lymphatic-bearing tissue. The dotted lines show the extent to which the flap is freed.

tion must be made with a knife or dissecting scissors. As the dissection proceeds, the mass of tissue that is being removed is drawn somewhat forcibly away from the deep structures of the neck, which puts the tissues on tension. By catching vessels before cutting them and not working into pockets, the inaccessible bleeding is avoided. Beneath the anterior border of the sternomastoid, the carotid sheath is displayed. At the hyoid bone the cervical fascia is attached and will have to be freed; above this the stylohyoid muscle, the tendon of the digastric muscle, and the mylohyoid muscle come into view. As the dissection is continued upward, the submaxillary salivary glands are included in the mass to be removed (Fig. 329).

In removing the submaxillary salivary gland, the facial vein is divided at the lower, external part of the gland; the intraoral part of the gland is cut just where it disappears around the posterior border of the mylohyoid; the facial artery is cut at the lower border of the jaw-bone, and again as it enters the gland from under the posterior belly of the

digastric muscle. Here the artery is cut close to its origin from the external carotid, and had best be tied with silk. In cutting these various vessels and the intraoral part of the gland, they are first doubly caught with forceps, cut, and then ligated. With the submaxillary glands is also removed all of the tissue covering the anterior bellies of the digastric muscles. In this way the removal of the submental and submaxillary nodes is made certain. We have observed that submental

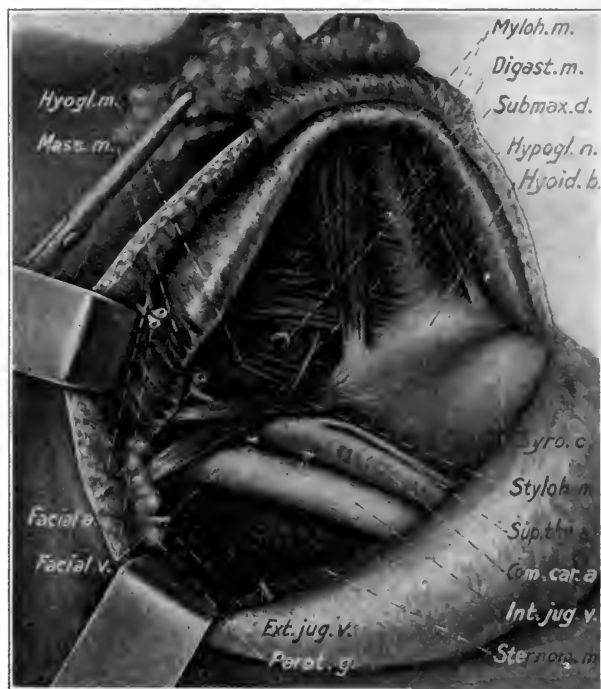

Fig. 329. Showing the dissection of the upper part of the neck after the removal of the lymphatic-bearing tissue of the submental submaxillary and superior deep cervical regions.

nodes may occur on the upper surface of the anterior belly of the digastric near the median border.

The smaller vessels of the neck, which have been caught during the operation, are now tied. Unless the condition of the patient contraindicates, the superior deep cervical glands should be removed on both sides. The sternomastoid muscle is retracted, and the outer ends of the cutaneous incision may, if necessary, be extended downward; but these spaces should not be invaded in a haphazard manner, for the scar which results from opening them will complicate a secondary operation. If the patient is not in the best of condition, and an operation on the



deep cervical glands is indicated, it had best be postponed to a later time. If in any place nodes are adherent to muscle or skin, this should be included in the excision.

The dissection of the neck having been completed, rubber dam drains are inserted through several stab wounds at the lower border of the dissection, and are sutured to the skin. If the deep cervical glands have been removed, these spaces are to be drained at their upper and lower ends by rubber dam strips which are brought out through stab wounds. The upper drains are useful when the patient is in the recumbent position. All bleeding having been secured, the gland mass which has been dissected from the neck is drawn upward, and the skin flap laid in place, and by its facial lining is sutured to the soft tissues at the lower border of the jaw by a continuous catgut suture, which is so placed as not to prevent the cutaneous borders from being properly sutured later. Next, a thickly folded wet bichlorid or alcohol towel is laid between the skin of the neck and the gland mass, and held at the lower border of the jaw by several tenaculum forceps. This, with the suturing of the upper border of the skin flap to the muscles just below the jaw, is to prevent infection of the neck wound from the mouth. Returning to the cancerous mass, the protective cloth covering the face and chin is removed. The primary cancerous area is excised, removing the tissues in front of the chin, down to the periosteum. It is well to include with the excision the fat tissue of the cheek on each side for 2 centimeters above the lower border of the jaw; in this way the buccal nodes which might be infected will be removed. If other structures are involved, they are included (Chapter XVIII), and the whole block with the glands is removed in one mass.

The repair of the lip is to be made as outlined in Chapter XVIII, and a rubber dam, leading to the space in front of the body of the jaw, is to be inserted at several points on each side along the transverse incision, which is to be closed with deep interrupted silkworm-gut sutures.

If the alveolus and gum of the anterior part of the lower jaw has been removed, the mucous lining of the floor of the mouth is to be sutured across the bone to the mucous lining of the new lip. The submucous space is to be drained with a strip of thin rubber dam led out through the transverse incision. If it is a squamous cell cancer of the upper lip, the latter is removed; then the operation on the neck is done as just described. In either case the carcinoma and lip may be removed first, and the glands of the neck removed as a secondary operation. But on theoretical grounds, it does not seem to us good surgery to remove the glands before the primary carcinoma; for in this case cancer cells, or the agency of cancer, might enter the wound through the cut ends of the lymphatic ducts. The sutures should control the

bleeding; and no dressing, other than a dusting powder or a 10 per cent colloidal silver solution, is applied to the face wound, but the neck is well padded with gauze and bandaged fairly firm to obliterate dead spaces. This obliteration of spaces by pressure is extremely important. The patient should sit up within a few hours after the operation and be allowed to get out of bed as soon as practicable.

**Operation for Carcinoma of the Lower Lip Where Repair is to be Made with Flaps from the Neck.**—In extensive carcinoma of the lower lip, where the excision has to extend beyond the angles of the mouth, in order to make proper repair, a different procedure will have to be adopted. The one here presented is somewhat patterned after the operation of Dowd. The incision at the lower limit of the carcinoma field is outlined, and also one from the middle of this to the upper border of the thyroid cartilage. From here the incision sweeps downward and then outward to the outer border of the sternomastoid muscle and then upward for a short distance (Fig. 208). The protective cloths are clamped in place with tenaculum forceps or safety pins, and the incision is made. Beginning above, the midpart of the upper transverse incision is carried to the bone in such a way as not to open the mouth cavity. Next, the vertical and lower transverse incisions are made. Above the hyoid bone the platysma is left in contact with the gland mass to be excised. Below the hyoid bone the platysma is raised with the skin flaps. The subcutaneous tissues below the chin, the lymph-bearing tissue of the front of the neck, and the submaxillary glands are removed as outlined in the previous operation. But it is not practical to remove the deep cervical nodes, as they are not freely accessible in their upper part. If these are to be removed, it should be done at a subsequent sitting, after the flaps that form the new chin and lips have acquired a good blood supply in their new position, so that they will not suffer from an incision made at their base. The operation in the neck having been completed and rubber dam drainage having been inserted at several points along the lower and outer borders of the wound (Fig. 209), the head is tilted slightly forward, and the flaps are rotated upward until there is considerable more tissue than is immediately needed for the construction of the new lip. This lip will be without mucous lining and will later contract considerably. If it is found that there is not sufficient tissue to bring these flaps high enough up on the face, then the sutures of the lower transverse wound will have to be cut, and the defect remaining in this part of the neck will have to be filled, either with the Thiersch grafts or by flaps slid from lower on the neck. The flaps in their new position are sutured at their deep surface by a continuous catgut suture to the muscles just at the lower border of the jaw and chin. The catgut used for this purpose should be a double strand of a

good 20-day variety. Further security may be had by fastening these flaps to the bone with one or two tacks. The neck is now protected with several layers of a wet bichlorid towel. The upper protective cloth is removed, and after excising the primary growth, the repair is made as outlined (Figs. 208, 209). If the alveolar process of the jaw has been removed, the mucous lining of the floor of the mouth is to be sutured to the deep surface of the new lip, and the submucous space is to be drained by strips of rubber dam, let in through cutaneous stab wounds. If sufficient tissue has been obtained, the new lip will be much too long and very loose, but subsequent contraction will correct this. Any fitting of these flaps that is done should in no way shorten the length of the new lip. If by any chance it should eventually prove to be too long, this fault is very easily corrected.

*An important point to bear in mind in these and in all cancer operations is: That the man who undertakes a primary operation on a case fitted for radical treatment assumes a great responsibility; and unless he does his work correctly and thoroughly, he does his patient harm.* In most cases the primary growth and the submental, submaxillary, and deep superficial cervical lymph nodes can all be removed at one or several properly planned primary operations; but to work in the dense scar that remains after the first operation is extremely tedious and difficult, and it is at best guesswork. If the neck has been invaded and the operation for the primary growth is not a success, the condition is still more hopeless; for the lymph, seeking new channels, is very apt to cause infection of nodes which are much less accessible to surgical interference.

Operations for secondary infections in regions which have not been disturbed—for instance, the removal of the deep cervical nodes after there has been a proper cleaning out of the submaxillary and submental regions—may be undertaken with a reasonable amount of confidence, but operations in a region that has been unsuccessfully invaded are most likely to prove unsuccessful.

Before closing this chapter, it is well to say a word in regard to unilateral versus bilateral removal of the lymph nodes in lip carcinoma. In very early cases situated well toward one corner of the mouth, it may be proper to do a unilateral neck operation, but clinical illustrations of early bilateral infection of the lymph nodes from a unilateral focus are so common, that the safer plan is to make a bilateral excision of at least the submaxillary and submental nodes in all cases.

### PROGNOSIS.

Carcinoma of the lip gives the best operative result of any form of carcinoma, and it is probably perfectly fair to state that the cures should be above 75 per cent.

## CHAPTER XXXII.

### TUMORS AND CYSTS OF THE FLOOR OF THE MOUTH.

With the exception of ranula, affections of the salivary glands and their ducts are not included in this chapter.

#### OBSTRUCTION CYSTS OF THE MUCOUS GLANDS.

Retention cysts of the muciparous glands may be found on the inner surface of the lips and on the cheek along the line of occlusion where they may be caught between the teeth. Occasionally they are found along the edge of the upper surface of the tongue. (Their appearance and treatment were discussed in the Chapter on the Lips, p. 387.)

A more striking cyst is sometimes observed under the tip of the tongue, due to the distention of a duct in the glands of Blandin. They may attain considerable size, are of the same bluish-gray color as other mucous cysts, and are to be treated by excision of the gland.

#### RANULA.

This is a rather general term applied to chronic benign cysts of the floor of the mouth, due to obstruction of a duct or of a mucous or salivary gland. There has been much discussion as to the true nature of the cyst. Nevertheless either the anatomical relations or histologic structures of the cysts that occur in the anterior part of the floor of the mouth would, it seems to us, limit the site of origin of a ranula to one of three structures: the incisive glands of Suzanne and Merkel, the sublingual salivary glands, or one of Bochdalek's glands. Probably the most common misstatement made in regard to them is that they are due to obstruction of the submaxillary duct. This is denied by every careful observer, for Wharton's duct has always been found at least partially patent, when examined in the presence of typical ranula. Obstruction of this duct gives entirely different symptoms. It cannot be stated that a complete obstruction of the submaxillary duct could not cause a cyst in the floor of the mouth; but as the obstruction is then in the common excretory duct, the whole submaxillary gland shares in the distention, and cysts arising in the intraoral part of the submaxillary gland bulge downward toward the neck. Whether or not cysts of Blandin's glands are to be included under ranula is rather a matter of individual classification. The term has been commonly taken to mean a cyst in the floor of the mouth; and cysts of these apical glands are usually confined to the under

surface of the tongue, and when the tongue is protruded, the cyst moves with it. If we define ranula as a cyst of the floor of the mouth, then a cyst of an apical gland will seldom come under this heading.

The rarest form of ranula is that which arises in the midline, just behind the incisor teeth, and is credited to the incisive glands. A ranula is much more commonly lateral in its origin, but as it grows, it crosses the midline and may be notched by the frenum. Certain ranulæ are lined with ciliated epithelium, which in the mouth occurs only in the thyroglossal tract or its offshoots—as the glands of Bochdalek. That obstruction of an excretory duct of the sublingual gland is the most common origin of ranula is almost generally admitted. According to Baker, quoted by Butlin, it is accompanied by a secondary atrophy of the remainder of the gland and partial obstruction of the submaxillary duct by pressure. Morestin presents a dissection which shows the lobes of the sublingual gland extending through the mylohyoid muscle and appearing upon its under surface. This appears to be an explanation for certain ranulæ that bulge below the chin in a more marked manner than would result simply from pressure upon the upper surface of the mylohyoid muscle.

A ranula is usually unilocular, but there is no reason why it could not have a double origin.

**Symptoms.**—There is a chronic slow-growing swelling in the anterior part of the floor of the mouth, situated immediately beneath the mucous membrane, which may be median, or more on one side than the other. It is of a bluish-gray color, or may be reddish-gray from the number of small vessels that cover it. It is often covered by veins. It is tense and fluctuates, but does not pit on pressure. It raises the tongue upward and, when large, may cause considerable inconvenience and discomfort, but it is not painful. It rarely causes a prominence below the chin. If ranula develops in childhood, it may cause considerable protrusion and deformity of the lower jaw and displacement of the teeth. Rarely becoming infected, it causes extensive sloughing in the floor of the mouth. They occasionally rupture spontaneously, but the relief is only temporary, as the fistula closes and the sack refills. Rapidly developing cysts of the floor have been termed acute ranulæ. Several have been reported which were due to acute obstruction of Wharton's duct, coming on while eating, in which there was a lateral swelling of considerable size and also swelling of the submaxillary gland; in every instance it was very painful. We have seen one such case which was bilateral. If the sublingual bursa described by Telleux really exists, this might account for some acute ranulæ, in which case it would be a bursitis, but Butlin denies the existence of this bursa. An intermittent ranula may occur, due to a recurrent obstruction of a duct.

**Diagnosis.**—A lipoma in the floor of the mouth might be mistaken for ranula, as might an angioma; but on feeling it, a soft, solid, or readily collapsible, blood-vessel tumor could be distinguished from a cyst. Moreover, the appearance of these is usually different from ranula, but Monod has reported a dermoid in the midline under the tongue, which was of a bluish color, and apparently fluctuated.

Dermoids have a doughy feeling, and pit somewhat on pressure. Cysts of Wharton's duct are fusiform and are accompanied by swelling of the submaxillary gland.

**Treatment.**—Many small ranulae will disappear after opening freely and swabbing them out with carbolic acid or tincture of iodine, but, besides being uncertain of result, this cannot be considered good surgical practice. Though also uncertain of result, the passing of a seton of silk or twisted wire through the cyst and allowing it to stay until it falls out is not open to the more serious objections of the first method. Brophy uses a hollow fenestrated ring.

There are two other ways in which a ranula can be treated: complete excision; and the removal of all of its upper wall with the superimposed mucous membrane, and then suturing the cut mucous edge to the edge of the cyst wall. This latter operation should be done so that the floor of the cyst is completely exposed and there is no overhanging edge. It is best accomplished by making an opening into the cyst wall and getting a good hold upon the wall and mucous membrane with a Halsted artery forceps. Drawing the forceps upward, the wall and mucous covering are cut around with a pair of scissors, curved upon the flat. Care should be taken to wound neither the submaxillary ducts nor their opening. Hemorrhage is controlled partially with artery forceps, and completely by a continuous buttonhole suture of catgut, which fastens the mucous membrane to the edge of the cyst floor. This operation leaves part of the cyst wall to replace the normal mucous floor. We believe that it is good surgery to adopt this method with very large uncomplicated cysts, as excision of a large ranula is a serious operation. If not successful, the extirpation can be done later. Except in nervous people this operation can be done under novocain-adrenalin injections. The cysts can almost always be excised from within the mouth, under either a local or general anesthetic; but it is to be remembered that a cyst of the sublingual gland will not shell out and will have to be cut from the remaining part of the gland. This operation is done by a free transverse, or horseshoe-shaped, incision of the mucous and submucous tissues in front or behind the openings of the submaxillary ducts, according to the location of the cyst. By blunt dissection, after the cyst wall is bared, the mucous and submucous tissue is pushed backward and forward until the upper surface and sides of the cysts are freed.

If, for want of room, there seems to be danger of rupturing its wall, it may now be opened by a free incision, to the edge of which three forceps are attached. With a finger in the sac as a guide, it is freed by blunt dissection or by clipping with a pair of blunt-curved scissors. After removal, the sac should be examined, and if missing in any part, this should be sought and removed.

If the surgeon is doubtful of having removed all of the wall in any particular part, the edge of the mucous membrane should be sutured around the supposed situation of this piece of cyst wall; otherwise the cavity should be lightly packed with mildly antiseptic gauze for a few days, when a mouth wash will be all that is needed. Some large cysts might be more easily removed by an external incision, and if the cyst protrudes through the mylohyoid muscle, this is the only way it can be approached. Küttner recommends that this approach be made submentally, as for removing a dermoid (see p. 404); but if it is necessary to make an external approach, the most satisfactory way is to divide the lip and jaw-bone, as in Kocher's normal approach for excision of the tongue (see p. 501). If, in removing the tumor from below, the mucous membrane of the floor is cut through, this should be immediately sutured, and the submental drainage should not be removed until active suppuration ceases.

### DERMOID CYSTS.

Though dermoids are always congenital, due to an inclusion of the epiderm within the tissues formed from the mesoderm, still they are rarely noticed at birth, and may not be evident until well past middle life. The great majority of them appear between the tenth and twenty-fifth years. They consist of a fibrous capsule lined with stratified epithelium, containing a mass that may vary in consistency from tooth paste to the yellow of a hard-boiled egg. They may contain hair or other skin appendages. Usually, as the result of ill-planned attempts at their destruction, the cavity may be an abscess communicating with the mouth or neck by a fistulous tract. As the suppuration never completely destroys the epithelial lining, the fistula persists and discharges intermittently. Dermoids, in relation to the floor of the mouth, occur in one or two situations: in the midline beneath the skin or between the geniohyoglossi muscles; or laterally below the angle of the jaw. It is Butlin's opinion that laterally situated dermoids, which do not represent the remains of a branchial pouch, were once median and have shifted their position during development. It is possible that a dermoid occurring above the epiglottis may have originally had a more forward position (Fig. 330). Inclusion at the midline could occur only at the time of fusion of the mandibular tubercles.

The dermoid may attain such a size that the site at which it started to grow can no longer be determined. When small, they usually protrude downward below the chin, but may bulge upward into the mouth, in which case they appear as a yellowish mass beneath the mucous membrane. When very large, a dermoid may press the tongue upward and backward, and even cause dyspnea. They are to be distinguished from ranulæ, which have a bluish or reddish-gray color, and when sufficiently large, ranulæ give a distinct sense of fluctuation. On bimanual palpation dermoids yield a doughy sensation. They are of slow growth, usually requiring some years to attain any considerable size. In this they differ from most sarcomata, and they differ from all soft solid growths, including lipomata, in the doughy feeling that can usually be made out, and in the fact that unless very tense they pit on pressure. A dermoid, situated deep in the muscles near the hyoid bone, might be

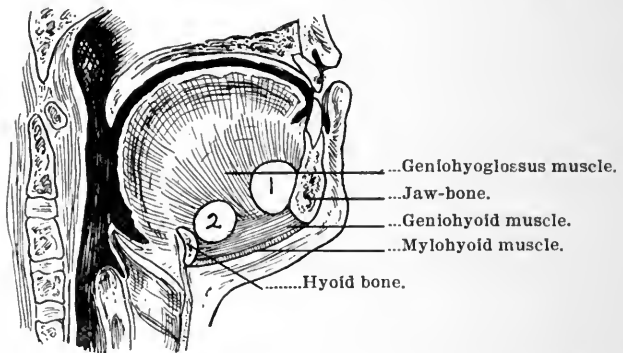


Fig. 330. Diagram showing the locations of median dermoids in the floor of the mouth.—After Butlin.

difficult to distinguish from a thyroid tumor or cyst in this situation (Fig. 330).

The treatment of dermoids is complete excision. If the mass is situated immediately beneath the mucous membrane, it can be removed from within the mouth by a free incision and blunt dissection, but otherwise it is preferable to approach it from below. It is absolutely necessary to remove the whole of the epithelial wall. When approached externally, perfectly free access and a clear view of the tumor can be obtained. Further, the wound can be kept aseptic, the bleeding is easily controlled, and a properly placed skin incision will leave no perceptible scar.

For a medianly placed cyst, a transverse submaxillary incision is made from near the angle of the jaw on each side, and a little in front of the body of the hyoid bone. This incision cuts through the platysma muscle, and the flaps are retracted so that the muscles forming the floor



of the mouth are exposed from the chin to hyoid bone. At the extremities of the incision the submaxillary glands will be uncovered. The median raphe of the mylohyoid muscle is incised, and the two halves of this muscle and the geniohyoid are drawn apart with retractors. It is probable that the cyst will come into view as soon as the mylohyoid is incised, and it is to be freed by blunt dissection. It may be attached to the symphysis of the jaw or to the body of the hyoid by fibrous septa (Fig. 331).

For a large cyst extending up into the anterior part of the floor, one or both sides of the mylohyoid, with the corresponding geniohyoid,

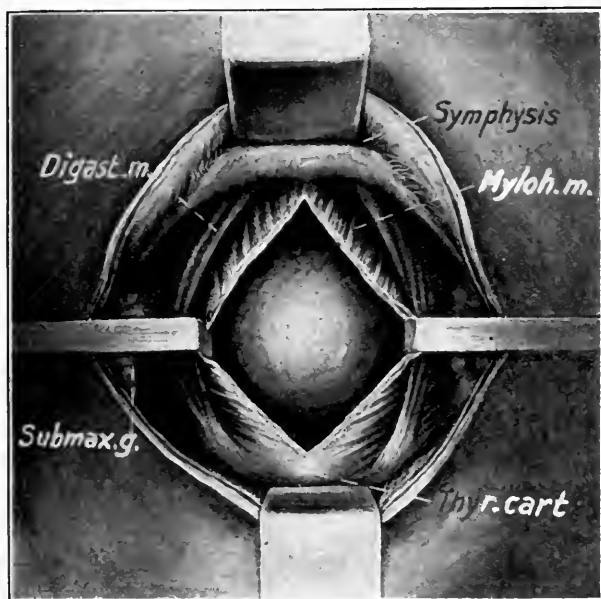


Fig. 331. Sublingual cyst approached through a transverse submaxillary skin incision, and a vertical incision through the mylohyoid muscle. (Error—*thyr. cart.* should be *hyoid bone.*)

may be cut fairly close to the jaw-bone, but not too close to prevent its subsequent suture. Before both geniohyoid are cut, a ligature should be passed through the tongue to prevent dyspnea by backward displacement of the tongue and hyoid.

If the cyst is situated farther back, near the hyoid and bulging toward the foramen cecum, or oral pharynx, the transverse incision of the muscles should be made just above the hyoid bone. The attachments of the mylohyoid, the facial attachments of the digastrics, the attachments of the geniohyoid and geniohyoglossus may all be cut just above the hyoid, after securing the body of the tongue by transfixing it with a ligature within the mouth. Enough muscle should be left at-

tached to the hyoid to admit of subsequent suturing of these muscles, but the hypoglossal nerves must not be injured. If enough room is not to be gained in this way, as may be the case with a suprahyoid thyroglossal duct tumor, the hyoid bone may be split in the midline after making a supplementary median skin incision in front of the larynx. In this way the tongue can be separated into two halves up to its dorsal mucous membrane, giving free access to any median growth. If the operation threatens to involve the mucosa of the tongue, the head should be held low to prevent blood entering the larynx. If the cyst is very large, it may be tapped when it comes into view, which will facilitate its removal (Fig. 339).

After satisfying one's self, by an examination of the specimen, that it has been completely removed, all muscles which have been cut are sutured with a few interrupted tannated gut sutures. If the hyoid bone has been severed, the two halves may be held in apposition by tannated gut sutures passed through its fascial coverings. A rubber dam drain is placed in the midline, and the platysma and skin are re-approximated. (For the manner of outlining the incision and placing protective cloths around a clean neck field, see Operation on Cervical Lymphatics, p. 510.) The rubber drain is to be left in place twenty-four to forty-eight hours. If through-and-through sutures have been used, they are to be removed on the fourth day after operation, and the line of union protected by one layer of gauze and flexible collodion, which does not occlude the drainage opening. In removing the sutures from a recent transverse wound in the upper part of the neck, the head should not be thrown back, for the wound may be pulled open.

For a laterally situated dermoid, the incision, through the platysma and superficial fascia, should extend from the mastoid process along the body of the hyoid. The superficial flap is drawn upward to expose the field. The deep cervical fascia is incised at the lower border of the submaxillary salivary gland, and the gland is also drawn upward, which will expose the mylohyoid muscle, beneath or behind which the cyst can be felt or seen. In incising the mylohyoid, care should be taken not to wound the hypoglossal nerve, which will be seen disappearing beneath the posterior border below the cyst. The cyst is removed, and the wound is treated as described in the previous operation.

**Treatment of a Sinus Leading to a Suppurating Dermoid.**—The sinus and the cyst should be removed. This should not be undertaken during an attack of acute inflammation; but at this time the pus may be liberated, usually by a probe or forceps passed into the blocked sinus, and a drain inserted. When the radical operation is undertaken, the sac should be emptied as nearly as possible by gentle pressure. The sinus and the sac are to be dissected out.

**BENIGN TUMORS.**

Various benign tumors are to be excised. Those situated in, or immediately beneath, the mucous membrane of the floor are to be removed from within the mouth. More deeply situated tumors may be approached from the outside, as are dermoid cysts (pp. 404, 406).

**MALIGNANT TUMORS.**

Sarcoma can occur in either of these situations, but the much more common tumor is carcinoma. In the floor of the mouth carcinoma may arise close to the tongue, in which case it has been supposed to be possibly a primary carcinoma of the sublingual gland, or it may be an extension from the tongue. Carcinoma may occur in the outer part of the floor as an extension from the jaw. In the cheek carcinoma may occur as an extension from the lip or jaw, or may arise independently. The latter, when on the mucous surface, are almost always of the indurating, ulcerating type. (For symptoms and course of carcinomata, see Carcinoma of Lips, Chap. XXXI, Jaws, Chap. XXVIII, and Tongue, Chap. XXXVI.)

## CHAPTER XXXIII.

### AFFECTIONS OF THE SALIVARY GLANDS AND THEIR DUCTS.

The salivary ducts and glands are occasionally the seat of congenital abnormalities; congenital atresia of the duct has caused cystic formation. The glands may be found displaced from their normal site, or the duct openings may be in an abnormal position. Küttner cites a case of Gherini's, of a young girl who had two small openings a little above the sternum and median to the sternomastoid muscles. Saliva exuded from the fistulæ, and injection of a colored fluid into the fistulæ caused the colored fluid to appear at the sublingual caruncle. It is possible in this case that there is a communication between Wharton's duct and a branchial fistula on each side.

#### INFLAMMATION OF THE LARGER DUCTS.

Formerly it was rather generally accepted that most infections of these glands were of a metastatic origin, but now there is considerable evidence to show that most, if not the vast majority, of these occur through their excretory ducts. Even in the so-called secondary infections of the salivary glands, it is probable that the infection is accidental, occurring from the mouth through the duct.

The most common instance of inflammation of a duct is in connection with a stone or a foreign body; but a duct may become inflamed without the presence of a foreign body or a stone. In the early stages of an extensive inflammation, the mouth of the duct will be found open, and the mucous lining everted. If the duct is squeezed, a drop of pus may exude. When the inflammation is dependent on the presence of a stone or other foreign body, recovery usually follows quickly after the removal of the mechanical irritant. When the inflammation develops in the absence of any mechanical irritant, it is often of a chronic, persistent character, and there is a dilatation of the duct and a thickening of its walls. The tube may become so patent that air can enter it. It is supposed that this phenomenon has been observed most commonly in glass-blowers.

Besides those symptoms already noted, there often occurs during eating the ordinary symptom of acute obstruction due to a foreign body in the duct (see p. 413). This is due to a plug of mucus or fibrin. Secondarily, the gland may become permanently enlarged. Usually

the result of treatment in chronic simple inflammation of the ducts is not particularly satisfactory, but in the earlier cases and in those giving obstructive symptoms, help can be afforded. The duct should be sounded to exclude a foreign body; this being absent, the duct can be irrigated once a day with a 5 per cent solution of argyrol or colloidal silver, or a 1 : 2000 solution of potassium permanganate. These injections are best made with a long probe-pointed needle. In older cases the gentle dilatation of the duct with a sound before injection might be helpful. In all cases, however, the injections should be made gently, and it should be seen that the fluid returns freely.

If there is a blocking or stricture of the duct at or near the orifice, this may be relieved by slitting the duct with probed scissors or on a grooved director. The inflammations that follow injuries or accompany stones and foreign bodies may be of any grade, from a subacute mild suppuration to virulent spreading phlegmon, but are usually of the former grade.

### EPIDEMIC PAROTITIS (MUMPS).

Although commonly called parotitis, the disease often affects the other salivary glands and may even affect these without involvement of the parotid. It is an acute, contagious, non-suppurating infection of one or several glands and their ducts, preceded by a stomatitis. It may become epidemic in barracks, etc., but most commonly affects children. At first one gland is involved, usually the left parotid, the other as a rule being infected later. The skin over the swelling becomes edematous. This swelling may be rather extensive, and there is always moderate fever. The disease begins to subside in about a week, and all traces of the swelling are gone in from two to four weeks. Recovery almost always follows, but in a number of cases there is an accompanying swelling of one or, sometimes, both testicles, which may be followed by permanent atrophy. Occasionally it is accompanied by other complications, such as oöphoritis, mastitis, vulvovaginitis, inflammations of the urinary tract or of the eye and ear, or encephalon.

### ACUTE SUPPURATIVE INFLAMMATION OF THE SUB-MAXILLARY AND SUBLINGUAL GLANDS IN YOUNG INFANTS.

In the first few weeks or months of life, infants may be affected by an acute suppurative inflammation which is accompanied by swelling of these glands, discharge of pus from their ducts, and the formation of intraglandular abscesses. In otherwise healthy infants recovery usually takes place, but the glands should be opened as soon as the formation of confined pus is suspected.

### SECONDARY INFECTIONS.

During the acute stage of some infectious fever, toward the period of its subsidence, or a few days after some operation, usually on the ovaries, which may have otherwise been followed by normal convalescence, a swelling may appear in one or both parotids, less commonly in one of the other salivary glands. In the parotids the swelling is first marked in front of the lobe of the ear where the capsule is less tense, but subsequently the swelling shows over the whole gland. The appearance of the swelling is usually accompanied by fever, and there is often severe pain. After a few days the swelling may subside and with it the other symptoms, or suppuration with an increase of all symptoms may follow. The infection is often of a very severe grade, causing diffuse phlegmon of the gland, which may spread to the sur-

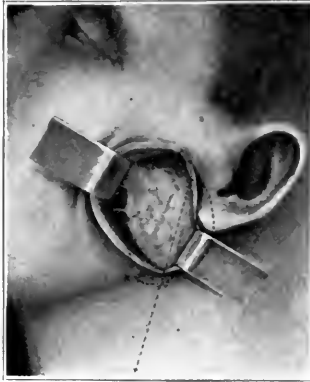

Fig. 332. Exposure of the parotid gland. The oblique dotted line with its upper forward curve shows the line of incision. The oval dotted line shows the posterior and inferior boundary of the gland.

rounding tissues. Death may result in the more severe cases. If the pus is not liberated by incision, it most frequently ruptures into the external auditory canal, but it may make its way into the deep spaces of the neck, into the postpharyngeal space, into the mandibular joint, or through the olivary foramen into the cranial cavity. By thrombosis of the contained veins, the infection may spread to the cranial cavity, or pyemia may result.

**Prophylaxis.**—As the predominance of evidence shows that the infection is usually by way of the excretory ducts and not metastatic, the occurrence of secondary infection of these glands can probably be in a large measure controlled. During fever and even after operations, the secretion of saliva is lessened, and unless the mouth receives particular attention, it often becomes foul. Before any operation the mouth should be cleansed by a repeated mouth wash, which should be

continued until recovery is complete. During the course of a fever or any illness, the mouth should receive constant attention.

**Treatment.**—In the earlier stages, ice should be applied. If supuration occurs, it will usually be on the third or fourth day and is accompanied by an increase of all symptoms. *This is the proper time for radical treatment.* If especially tender or softened spots can be found, these may be opened by an incision down to the capsule. A round-nosed conical artery forceps should then be inserted, but in the presence of severe symptoms the surgeon should not wait for definite fluctuation, which, owing to the tenseness of the capsule, may never be evident. In severe cases, in the absence of any local softening, an incision should be made just in front of the ear from the zygoma to the angle of the jaw down to the capsule, and the flap forcefully drawn forward (Fig. 332). The trunk and branches of the seventh nerve lie deep in the gland at its posterior part and will not be injured by any carefully made incision. In this way nearly the whole gland can be exposed. By incisions carefully made through the capsule, the swollen gland will be permitted to expand, which will increase its blood supply and lessen the danger of gangrene. If pus does not come on opening the capsule, the substance of the gland can be explored at various points by inserting a round-nosed artery forceps. The submaxillary and sublingual glands are to be treated by direct incisions, or, if the inflammation is diffuse, by the incisions given for Ludwig's angina. It is probable that this early radical treatment will be followed by convalescence in most of the cases, and that the very severe consequences already described will seldom be seen.

### CHRONIC INFLAMMATION.

Following any of the chronic intoxications—such as lead, bismuth, opium, uremia, etc.—a subacute swelling may develop in both parotids, or in any of the salivary glands, causing diffuse swelling. They swell slowly with occasional attacks of acute inflammation. The ducts may share in the process. The tendency is toward spontaneous recovery.

Treatment consists in eliminating the source of poison. Oral hygiene should be practiced in all cases. Dry heat from an electric light should be applied, or the counterirritation of iodine. Potassium iodide, internally, has been recommended.

**Inflammatory Tumor.**—This is the name given by Küttner to a progressive chronic inflammation of the submaxillary gland, which may cause it to become as large as an orange. He has seen six such cases and describes them as follows:

“All cases involved the submaxillary gland, though it is probable that the disease also affects others. In marked cases, examination reveals a round or elongated firm tumor in the submaxillary region,

varying in size from a hen's egg to that of an apple. The skin covering it is intact or slightly adherent; upon the deep parts the tumor is only slightly movable on account of the extensive adhesions, which occasionally may involve the mucous membrane of the mouth. Tenderness may be absent entirely. The tumors are a result of a chronic interstitial inflammation of a salivary gland; they sometimes contain in their interior small foci of granulation tissue or occasional minute abscesses. In all the author's cases the tumors showed a tendency to enlarge steadily; they also gave evidence of a decided tendency to implicate more and more the surrounding tissues."

Diagnosis is naturally difficult. Küttner states that they are in no way connected with syphilis and there is nothing about them to distinguish them from a tumor. Even at operation, the involvement of the surrounding tissues is strongly suggestive of a malignant growth. Such a condition is but another strong argument for the microscopical examination of all undiagnosed abnormal masses, either before or at operation.

Treatment is excision of the submaxillary gland. In the case of the parotid gland, multiple drainage might be tried.

#### **PSEUDOHYPERTROPHY (MIKULICZ'S DISEASE).**

Under this head has been described a chronic symmetrical enlargement of the salivary and lacrymal glands. With these, the palate glands, Blandin's glands, the labial and buccal glands, the lymph nodes, and the spleen have been observed to be enlarged in different cases. The disease comes on without other symptoms than the swelling, which is strictly limited to the glands and does not involve extracapsular structures. The glands of both sides are not always involved to the same extent. The tumors are usually, but not always, rather firm. According to Hirsch, the enlargement is due to an infiltration of round cells, which is accompanied by an atrophy of the secreting epithelium and a change of the round cell infiltration into connective tissue. He therefore regarded it as a cirrhosis of these glands. Besides the swelling, there are few symptoms, except those referable to the decrease of secretion—mostly dryness of the mucous membranes. Nothing definite is known of the cause, and the course is uncertain. In some cases the glands enlarge for a time and then remain stationary; in others they recede. Good results have been reported from arsenic and potassium iodid. Total excision may be resorted to in appropriate cases.

#### **SPECIFIC INFECTION OF THE SALIVARY GLANDS.**

**Tuberculosis.**—Tuberculosis of the salivary glands is a very rare occurrence and is to be distinguished from tuberculosis of a contained



lymph node. There have been a very few cases reported of apparently primary infection of the salivary gland, most all occurring in otherwise healthy individuals. It has always been chronic, appearing as a diffuse swelling, a node or cyst, with few subjective symptoms. The diagnosis from tumors is to be made only by the microscope. The treatment is excision. The whole submaxillary gland should be removed, but a local operation may be done on the affected part of the parotid. (For technic, see page 430.) The result of this treatment in the reported cases has been very good.

**Syphilis.**—Syphilis of the salivary glands is also extremely rare and has usually occurred in cases of the more virulent type. It has been observed by Newman that in the earlier stages of the disease the gland presents a diffuse painful swelling, but it is usually a late manifestation of either a gummatous or interstitial fibrous type. Usually there are other marked signs of syphilis, but an immediate absolute diagnosis from malignant tumor, which it may closely resemble, is only to be made by the microscope; though a positive Wassermann would of course be suggestive, and the disappearance of the swelling under antisiphilitic treatment is almost conclusive.

The treatment is the same as for other manifestations of syphilis.

**Actinomycosis.**—This may be part of a neighboring infection, or it may have gained entrance to the gland through the duct. The diagnosis in the later stages, after sinuses have formed, is to be made by the finding of the fungus.

The treatment is the same as that for the same infections at other sites.

## OBSTRUCTION OF THE DUCTS OF THE SALIVARY GLANDS. CYSTS.

The ducts may be partially obstructed from calculi, swelling or neighboring cysts, swellings, or tumors. Plugs of mucus, foreign bodies, or even small calculi plugging the exit of a salivary duct will cause an accumulation of fluid which, if it persists, may cause a dilatation of all of the ducts emptying into the obstructed one, converting all into an epithelial-lined cavity. In the sublingual glands, the terminal ducts of which are small and numerous, the plugging of one of them is more liable to be permanent, which constitutes one of the forms of ranula. In the submaxillary and parotid glands, each of which empty their secretions through a long duct of comparatively large caliber, permanent obstruction rarely occurs.

The symptoms of an acute obstruction of one of the larger ducts are: great pain, made worse by eating or the sight of food; and a fusi-

form swelling corresponding to the duct, with swelling of the whole gland. If the obstruction is not relieved naturally, or by passing a sound or by slitting the duct, suppuration may follow. In partial obstruction there are pain and swelling of both the duct and gland whenever the secretion is stimulated, but this subsides as the accumulation of saliva gradually forces its way out. Partial obstruction of the larger ducts is much more common than complete obstruction, and when caused by the inflammation around a stone or other foreign body, is likely to be recurrent. In the few cases that have been reported of permanent distension of the parotid or submaxillary duct, the obstruction has in most instances been due to a scar stricture or a foreign body. In a few the obstruction was congenital, and in others there was a cystic distention of the duct without any demonstrable obstruction. In the latter cases the secretion could be expressed out of the duct, but would reaccumulate. According to laboratory experiments, absolute occlusion of the main excretory duct causes atrophy of the gland. This does not agree with the accepted idea that most ranulae are due to sublingual duct obstruction.

**Diagnosis.**—The diagnosis is easily made from the location of the swelling and the increase of symptoms, which occurs during eating or even at the sight of food, due to the increased flow of saliva. If convenient, an x-ray picture should be taken to locate a possible stone, but if this is not convenient and a stone or foreign body is suspected, search is to be made with a needle. (See page 416.)

**Treatment.**—An attempt should be made to pass a fine probe into the duct, which may dislodge or locate the obstruction. As large a probe as will easily enter the duct should be selected, but no force should be used, as a false passage might be formed. It may be possible to massage a foreign body out of the mouth of a duct. If the obstruction can be located and is not completely relieved by the passage of the probe, it should be cut down upon and removed as early as possible. A stone, responsible for the inflammation or scar contraction which is causing the obstruction, may have dropped back and may be found lying free in the cavity when the cyst is opened. If no definite cause for the obstruction is found and it cannot be relieved by simply passing a probe and frequently emptying the duct, then the cystic dilation of the duct should be freely incised. Then, if no foreign body is present, further treatment may not be needed, for the frequent discharge of saliva from a large duct will probably maintain a permanent fistula. Should this treatment fail, a piece of the outer wall of the cyst can be removed with its mucous covering. Another plan is to use a silk or twisted silver-wire seton.

## FOREIGN BODIES AND STONES IN THE DUCTS AND GLANDS.

Improbable as it may seem, foreign bodies—such as pieces of grain, apple seeds, bits of tartar, etc.—have occasionally found their way into the submaxillary duct, causing acute obstruction. In other instances the obstruction has not been complete, and no obstructive symptoms were noticed until inflammation occurred around the intruder. Only slender bodies, such as fish bones or bristles, can enter the opening of the parotid duct, on account of its smaller size. With the exception of calculi, which are formed in place, foreign bodies reach the glands only from without. If a body in the duct is not removed, suppuration usually sooner or later supervenes with symptoms of partial or complete obstruction. Foreign bodies which have entered a gland and healed in place are less likely to cause symptoms. A bullet may heal in place. A foreign body in the duct will in time become coated with lime salts, when it is to all purposes a salivary calculus.

The diagnosis of a foreign body, unless it can be seen or the history of its entrance is clear, is only tentative until it can be exposed or felt. (For methods of examining for foreign bodies, see Examination for Stones, page 416.) A soft body will not cast a shadow upon the x-ray plate and can with difficulty be felt with an exploring needle. On the other hand, they are usually situated near the orifice of the duct, where they can be felt with a probe. The treatment is the same as for stones.

**Salivary Calculi.**—Salivary calculi can form in the glands themselves, or in their excretory ducts, the latter being the more common situation. Calculi in Blandin's glands, though not salivary glands, are included under this heading. Calculi form in the salivary glands and ducts less frequently than in the kidneys or liver. Though some of them may have as their matrix some foreign body which has entered the duct, it is probable that, like stones in other situations, they most frequently owe their origin to the presence of bacteria; these, together with a change in the mucous secretion, which they cause, furnish the matrix of the stone. A matrix of a stone having once formed, the same conditions of metabolism which influence the rapidity of the deposit of tartar on the teeth must also influence the rate of stone formation in the ducts.

The most common location of salivary calculi is in the submaxillary duct, being more frequent here than in all other locations combined. They are more common in men, and rarely occur in children, but have been congenital. Usually there is but one stone, the size of a pea or smaller, but they may be of large size—one reported by Puzey having reached the dimensions of  $\frac{1}{2}$  by 1 by  $1\frac{1}{2}$  inches and weighing 7.6

grams. There may be more than one stone, the size of the stones being smaller when there are a number of them. When the stones form in the secondary ducts of a gland, there may be a great number of them, which are apt to be thrown into the common duct, there to collect or to be thrown off through the normal opening.

A stone in a duct may cause no symptoms for a long time and will not do so until there is partial obstruction, or until a pus infection occurs. The symptoms of partial obstruction of a duct are given on page 413. Infection around a stone is accompanied by swelling, usually pain, and possibly suppuration or a diffuse cellulitis. As the result of one or repeated inflammations, the stone may come to lie in a bed of scar tissue, in an abscess, in the bottom of a fistula, or in a mass of fungating granulations and indurated tissue. The last condition has several times been mistaken for a malignant growth, and extensive, mutilating operations have been performed. When the stone lies in an indurated mass, which has attached itself to the bone, it may be mistaken for a periosteitis, and the real cause overlooked. If untreated, a stone may lie in its bed indefinitely, with or without marked symptoms, or may eventually ulcerate its way through into the mouth, less rarely to the external surface.

The diagnosis is to be made partly upon the symptoms referable to the obstruction of the duct (see page 413) and the inflammation of the tissues, and partly by special examinations. The stone is rather impervious to the x-ray, and a good negative is probably the best way of locating or excluding small stones. For the positive diagnosis of small stones in the submaxillary or parotid gland, the x-ray may be absolutely necessary. A probe of soft silver passed into the duct may locate a stone, and while there is no mistaking the definite grating sensation which usually results from the probe sliding over the stone, the lack of this does not exclude stone; for the probe may not have passed as far as the stone, or the stone may be in a pocket. To us the most practical examination is by means of a strong hypodermic, used as an exploring needle. The examination is conducted as follows:

The most marked part of the induration, or its most tender point, is located by a bimanual examination. The surface over this is painted with a 10 per cent cocain solution. A hypodermic syringe with a strong needle is filled with a solution containing  $\frac{1}{2}$  per cent novocain and 1 per cent of the 1:1000 adrenalin chlorid solution. The needle is plunged into the suspected tissue, infiltrating as it progresses, which, if done slowly, lessens the pain. Careful search, by repeated insertions of the needle, is made all along the suspected area, and when the stone is found, a fair idea of its size, or the size of a mass of stones, can be obtained in this way. By the time the examination is completed, the

tissues are well anesthetized, and if it is a suitable case for removal under a local anesthetic, the operation can proceed without further preparation.

**TREATMENT.**—All stones and foreign bodies should be removed. For stones situated in the submaxillary duct or anywhere under the mucous membrane, this is usually not difficult. For a number of stones in the submaxillary gland, the latter may be excised; but a stone situated in the parotid gland, a rare occurrence, would present some serious considerations. A stone situated in Blandin's duct, in the parotid duct, in the sublingual gland, or in the submaxillary duct in front of the molar teeth can be removed with a local anesthetic; but a submaxillary stone situated behind the bicuspid, or in any situation in a nervous patient, had better be removed under a general anesthetic. A submaxillary duct stone having been located, it is pushed upward into the mouth by the fingers of an assistant placed under the jaw. A gag is placed in the mouth, and the cheek is retracted. With the forefinger of the left hand the operator attempts to steady the stone against the body of the jaw. An incision of some length is made down to the stone, and unless there is very profuse bleeding, no attempt is made to control it, since the work has to be done entirely by touch.

If the knife fails to touch the stone, it must be relocated with a needle. The freeing of a single stone is often not an easy matter. These stones frequently present uneven surfaces, and it is difficult to cut through strands of tissue which have gripped the stone in the little space between the nodules. For this purpose a small pointed tenetome is useful, cutting repeatedly with the point of the knife along the same line on the surface of the stone and at the same time attempting to work the tissues from the stone by lateral strokes of the point of the knife. If possible, the stone should be freed in this way until an elevator or small curette can be slipped under it. It is not good practice to undertake to grasp the stone with forceps thrust into the depth of the wound; for one is more liable than not to include some soft tissue in the bite, and it would be possible to do damage. The lingual nerve crosses beneath the duct from the external to the median side at the first or second molar tooth, but if one cuts straight down on the stone and does not make grabs in the depth of the wound, it is in little danger of injury.

After removal of the stone, search should be made for possible neighbors. A nest of small stones is easier to remove than one large one. They can be scooped out of a comparatively small hole with a curette. The wound is packed lightly for a day or two, after which, if all the stones have been removed, no further treatment than a mouth wash is needed.

A stone in the oral part of the parotid duct is treated in the same way. For a stone farther back in this duct, it seems to us that the best procedure would be to go down to it with a clean cut, remove the stone, and after passing a probe into the mouth to be sure that the duct is patent, suture the facial wound in its full depth. The danger here is that a salivary fistula might result.

A single stone, or several of them, could be removed from the parotid in the same manner as are tumor nodules (see page 430), but if it were ever deemed necessary to remove the whole gland, it should be done piecemeal, after locating the trunk of the facial nerve and freeing its branches.

### WOUNDS OF THE SALIVARY GLANDS AND DUCTS.

Wounds of the glands may be followed by an external flow of saliva, but this usually ceases spontaneously in some weeks.

Recent clean injuries should be sutured to their full depth and drained so that the deeper part of the wound cannot be distended. Infected wounds may have to be dressed open until clean enough to be sutured, and when this is done, intraoral drainage should be provided, if an external flow of saliva has persisted.

Lateral injuries of a duct will eventually heal without fistula unless there is considerable loss of substance. If the duct is cut completely through, the ends will retract, and the cut end of the distal part will eventually close. In recent injuries of the duct, an attempt may be made to suture the duct with fine catgut which does not penetrate the mucous lining. This is a difficult procedure. In suturing the duct, the proper approximation of the ends is more of an object than to make a water-tight joint. Whether or not the duct is sutured, free drainage, preferably into the mouth, should be made, and the tissues superficial to the duct should be accurately sutured. (See Treatment of Salivary Fistula, p. 420.)

### SALIVARY FISTULA.

A salivary fistula is an abnormal communication between a surface and a salivary duct or gland, through which saliva is discharged. These fistulæ may be external or internal, but ordinarily internal fistulæ are of no surgical interest, further than that their patency is necessary if there is an occlusion of the distal part of the duct. Rarely an external fistula of the submaxillary gland, or even of the duct, may result from a deep external wound, or an ulceration or abscess due to a stone, but practically all external salivary fistulæ are of the parotid gland or its duct. Gland fistulæ which commonly result from operations on the gland or from the rupture of abscesses are of less importance, both

because they usually heal spontaneously and because the resulting symptoms are not as severe as those of duct fistulæ. Duct fistulæ most commonly come as a result of ill-placed incisions or from accidental wounds, but they may result from any ulcerative process—such as noma, gumma, or carcinoma. In gland fistula only a part of the secretion is lost, but in duct fistula the whole amount is apt to pour out on the cheek. Some general depression may result from the disinclination which the patient has toward eating, but the chief evil is the annoyance and embarrassment due to the presence of the abnormal flow. Between meals this flow is small; while taking food the quantity is considerable. Duphénix collected 70 grams from a patient in fifteen minutes, and Jobert had a patient who voided several cupfuls in twenty-four hours. Usually the mouth of the fistula presents a few granulations which may be surrounded by scar or normal skin, but in the duct fistula there may be a smooth union between the mucous lining and the skin. A recent fistula to a duct, which is still patent at its distal end, is likely to heal spontaneously or with a little help, such as local cauterization and pressure; but a fistula to a duct which is occluded or very much contracted, or a fistula in which the mucous lining of the duct has united directly to the skin, will close only after some successful radical operation. In reference to their repair, the location of the fistula and the amount of destruction in the distal part of the duct are of most importance—those situated in the buccal part of the duct being easily corrected, and those situated farther back having been considered more difficult of repair.

**Diagnosis.**—Except in the early stages of a fistula following an abscess, or of one occurring in a suppurating wound, where the saliva might be disguised by the pus, the diagnosis of the salivary fistula is very simple. The discharge is perfectly clear, is increased during eating, and usually there is some irritation of the skin which is continuously wet with the discharge. In a case observed by Angiéras, cited by Küttner, in which an internal fistula had opened into the maxillary antrum, there was a profuse discharge from the nose. Such a case would be quite perplexing until the recurrence of the discharge while eating might lead to an analysis of the fluid.

While a salivary fistula is usually recognizable at a glance or after a few questions, there are certain points which should be carefully determined. These are: the cause of the fistula; the exact site of the defect, whether of duct or gland; the extent of the injury to the duct; the distance between the skin opening and the duct injury; and the condition of the duct distal to the fistula. All of these bear upon the prognosis and treatment and can only be determined after certain examinations.

Simple fistulæ leading to mucus-lined cavities or ducts in any part of the body have a distinct tendency to heal spontaneously, and unless the wall of the fistula is diseased, as with a tubercular infection, unless the fluids within the duct or cavity can find an easy exit only through the fistula, or unless the mucous lining of the duct is united directly to the skin, the fistula will always close of itself. This is true of salivary fistulæ, and the condition in relation to these points should be determined before treatment is begun. Specific ulcerations will need to be cured before any attempt can be made to close the fistula. A gland fistula can usually be recognized by its location, or, if it opens some distance from the gland, by its direction and the fact that only a small part of the whole secretion is discharged through it. The attachment of the mucous lining of the duct directly to the skin may sometimes be made out by inspection, or can be inferred if the fistula has no depth. The condition of the distal part of the duct and orifice can usually be determined by attempting to pass probes both from the fistula and through the orifice and by injecting methylene-blue solution into the fistula.

**Treatment.**—Most duct fistulæ which have persisted for six months will demand some sort of radical treatment, but a gland fistula is usually cured by simpler methods. Usually repeated applications of silver nitrate or the electric cautery into the depth of a gland fistula and the application of pressure will bring about a cure.

Animal experimentation has shown that the tying of the excretory duct of a gland brings about an atrophy of its secreting cells, and it is possible that the inflammation and scarring, which result from the cautery, block the small ducts that lead into the fistula. If repeated applications of the cautery, followed by pressure and restriction of diet to non-appetizing, unspiced fluids, fails to produce a cure, then the offending part of the gland must be excised, having first located and freed the branches of the facial nerve.

Duct fistulæ are treated in several different ways, the choice depending upon both the location of the defect and the condition of the distal part of the duct. Very recent fistulæ may be treated by cauterization of the outlet, and pressure or the application of impervious adhesive plaster. In cases where a permanent fistula is situated in the buccal part of the duct or near the anterior border of the masseter muscle, the external fistula may be converted into an internal one, or the proximal part of the duct may be implanted directly into the buccal mucous membrane. When the fistula is situated too far back, the duct can sometimes be repaired by suture, or by piecing out with a prologation made from the buccal mucous membrane. After removing a section of the masseter muscle, and if necessary, part of the anterior



border of the ramus, the end of the duct can be planted directly into the mucosa of the mouth.

**Conversion of an External into an Internal Fistula.**—There are two general plans for doing this: (1) the establishment of a new fistula by means of a seton; (2) passing a small drainage tube through the cheek at the site of the duct defect and, gradually withdrawing it from the inner side, allowing the external fistula to heal, while the internal one remains patent. The latter is Kaufmann's method and is carried out as follows:

A trocar, 4 or 5 millimeters in diameter, is pushed through the cheek at the site of the fistula. It is very important, for success, that the trocar penetrate exactly at the site of the hole in the duct and that the deeper part of the external fistula is not separated from the new tract by a thin wall of tissue, which may effectually prevent the saliva finding its way into the mouth. A small spirally cut drainage tube is placed through the cannula, and the latter is withdrawn, leaving the tube in place. The tube may be treated in several different ways, one of which is to withdraw it toward the mouth until the external end disappears beneath the skin. The internal end is cut about 3 millimeters beyond the mucous surface, and then the patient is allowed to chew some food while the finger is pressed gently over the external opening. If the tube is properly placed, saliva should flow into the mouth. When it is determined that the saliva can reach the mouth, the end of the tube is made steady by grasping it and the mucous membrane gently with an artery forceps, and a retention suture is passed through both and tied. The external opening is carefully dried and covered with a piece of adhesive plaster. As the stay suture cuts its way out, the drainage tube will be gradually forced out; but it should remain in place for two weeks, and if the external fistula is still open, it should be replaced if it comes out before that time. If, after a few days, the external orifice has not closed, it may be cauterized or freshened and sutured. If there is a depression at the site of the external opening surrounded by a scar, it will save time and give a better cosmetic result to at once excise this, undermine the skin, and draw it together by immediate suture. This operation can be done under a local anesthetic without detaining the patient from his business. Therefore, if the first attempt is not entirely successful, it should be immediately repeated.

Another way of establishing an internal fistula is to thread a strip of live rubber dam, 3 millimeters wide and 20 centimeters long, on a straight needle which is inserted to the bottom of the fistula and on through the cheek. This end being allowed to remain protruding into the mouth, the other end is threaded upon the needle, which is also in-

serted through the cheek from the bottom of the external fistula, but in such a manner that there will be about 1-centimeter space between the two points at which the dam pierces the buccal mucous membrane. The two ends of the dam strip are tied together with just a little tension, which will eventually cut through the intervening tissue. The dam should not be drawn tight as it is tied, for it would then cut through in a day or two and not stay in place long enough. If, after the fistula is well established, the seton does not cut its way out, it can be tightened by tying a ligature around the two internal ends between the knot and the mucous membrane.

The external opening is treated as in Kaufmann's operation.

**Repair of the Duct.**—Most of the work on repair of the duct has been done by Nicoladoni. If a fair-sized probe can be passed from the mouth to beyond the fistula, this may be taken as evidence that there is only a lateral wound in the duct which is being kept patent by the continuity of the skin and mucosa. The duct should be exposed by an elliptical incision around the fistula, joined by straight incisions over the neighboring parts of the duct.

In exposing the duct, the surrounding tissue should not be stripped off too closely, for this might interfere with its blood supply. Having exposed the duct sufficiently, an attempt should be made to repair the defect with part of the epithelial tissue surrounding the fistula, retaining only a sufficient amount for the purpose, and this must contain no hair. The epithelial surface should be turned toward the lumen so as to form part of the lining of the duct. The sutures should be of the finest tannated gut and so placed that they will not be exposed on the epithelial surface of the lumen. If any part of a suture were left within the duct, that part would not be absorbed and might subsequently form the matrix of a stone. This suturing is to be done, not so much with the idea of making a water-tight joint, as simply assuring the proper relation of the flaps until healing occurs. After closing the defect, an effort should be made to bury the newly repaired duct deeply.

Nicoladoni does a plastic operation upon the skin, by which the newly repaired part of the duct is covered by a flap and not by the skin wound, so that there will be no possibility of the epithelial edges of the defect becoming united to the skin. In cases in which a lateral repair of the duct cannot be made, Nicoladoni has done an end-to-end anastomosis of the duct with a very fine catgut. The suturing would be facilitated if the two ends of the duct were cut cleanly across and a sound passed from the mouth were introduced into the lumen of both ends of the duct. A fistula following these operations does not necessarily mean failure. If the epithelial lining has been properly placed

and the caliber of the duct has been restored at the time of the operation, then, even though subsequent swelling may for a time block the duct and force the saliva out through the wound, later when swelling subsides, the fistula will close, and the saliva will follow the normal route. Where the duct is found too short for an end-to-end anastomosis, Nicoladoni has resorted to the following expedient for approximating the two cut ends:

He exposes the distal portion of the duct for its full length, but leaves around it sufficient tissue to insure its blood supply. The outer surface of the buccinator muscle is exposed for some distance around the entrance of the duct. The natural opening of the duct is surrounded by a horseshoe-shaped incision, which liberates a fair-sized flap of buccinator and mucous membrane, that has its base posteriorly. This flap carries its blood supply. By this means the distal part of the duct can be drawn backward 1 centimeter or more.

**Reconstruction of the Distal Part of the Duct from the Buccal Mucosa.**—The idea of piecing out the duct with buccal mucous membrane was first presented by Nicoladoni and Braun. If the buccal mucosa is unscarred, it is very movable and can be used as follows:

The mucous membrane of the cheek with its submucous tissue is laid bare for some distance through a transverse incision in the external surface of the cheek. Two parallel transverse cuts are made in the buccal mucosa,  $1\frac{1}{2}$  centimeters apart. The central part of the flap thus outlined can be drawn for some distance back on the outer surface of the masseter. If the proximal end of the duct is long enough to be implanted into the end of this double fold, this is done, and the fold is held in its new position by two sutures, placed one at each corner. By a running suture of catgut at the upper and lower borders, this double fold of mucus is converted into a tube. The new duct is buried as deeply as possible. If the duct is too short to be pieced out in this way, a tongue of mucous membrane with its base posterior is turned back and converted into a tube, into which the proximal end of the duct is sutured.

**Transplantation of the End of the Proximal Portion of the Duct into the Buccal Mucosa.**—This is v. Langenbeck's operation, but he confined it to cases in which the proximal part of the duct was sufficiently long to allow of the end being inserted into the mucous membrane in front of the masseter muscle. It is just these cases which are fitted for the much simpler procedure of establishing an internal fistula. Nicoladoni went farther and excised the anterior border of the muscle to allow of a short duct being implanted more posteriorly. Partly on theoretical grounds, partly on experimental operations upon the cadaver and from observation of other operations

on this region which involved the destruction of the masseter muscle and ramus, we concluded that v. Langenbeck's operation might be applied to any duct fistula situated between the anterior border of the masseter and the gland, if the intervening muscle and bone were removed. This operation is more likely to be followed by success than either of those which have been described for fistula in this situation. The direct suturing of the duct or the repair of a lateral defect is very nice surgery, but is more appropriate for the expert who has made a special study of the technic than for one who has not. Even in the expert's hands, it seems to us that there are many opportunities for failure, as also in the grosser operation of Nicoladoni and Braun. An infection might cause the retention sutures to cut through before the new tube had been fixed in its position, and in this way failure could result.<sup>1</sup>

The destruction of one masseter muscle and one ramus causes no serious disturbance in function and can be done with little apparent deformity. If around the transplanted duct sufficient connective tissue is retained to insure its blood supply, no infection, short of a gangrenous process, could materially influence the result, for success is in no way dependent upon the primary union of the tissues.

The operation may be done in this way:

If possible, a probe is passed into the proximal part of the duct to serve as a guide. From a point on the cheek directly over the normal internal opening of Stenson's duct to a point 2 centimeters behind the fistula, a curved incision is outlined, with its convexity downward, that will pass 2 centimeters below the fistula. If the fistula is surrounded by much scar, an incision must be planned to eliminate this and to make the closure by flap-sliding. The duct is exposed but not closely stripped. The branches of the facial nerve are not endangered, as they lie close to the muscular fascia. If the incision extends back on the parotid sheath, this is not to be cut. The buccinator nerve is located at the lower border of the duct, lying directly upon the masseter (Fig. 192). This being avoided, the proximal part of the duct, with a coating of the fascia which surrounds it, is dissected back from the masseter for 1½ centimeters behind the fistula. If the accessory part of the gland which lies in a finger-like process along the upper border of the duct is encountered, this is to be elevated with the duct. Next, the masseter, fascia, and buccal fat are incised in the line of the duct, and retracted until the buccinator and the masseter muscles are exposed. The masseter muscle is defined and incised in the line of the

<sup>1</sup>Transplantation of the cut ends of the ureters has almost universally been followed by infection of the kidneys. There seems to have been no observation of this occurring after transplantation of the duct of the parotid. If this gland is liable to such infections, then the operations that retain the normal duct opening intact have a distinct advantage.

duct, from its anterior border to as far back as the duct has been freed. The two borders of the muscle incision are forcibly retracted until the subjacent buccinator, and possibly the anterior border of the ramus, are exposed. A finger passed into the vestibule of the mouth as far back as the anterior border of the ramus will serve as a guide in identifying the buccinator. If the ramus of the jaw is exposed, it should be freed of muscle upon its inner and outer surface, and then sufficient bone removed (Fig. 333). If, in doing this, the coronoid process is freed from the ramus, the fragment should be removed. The buccinator is now exposed sufficiently far back to receive the end of the duct, even if cut off at the gland. This is done by passing the end of the duct through a small hole in the buccinator and mucous membrane, and attaching the mucous border of the wound to the connective tissue

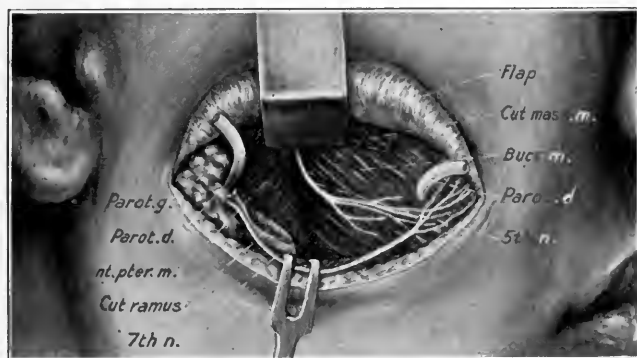


Fig. 333. Exposure of the parotid duct, showing relation of the gland to the buccinator muscle, after division of the masseter and removal of the anterior part of the ramus.

surrounding the end of the duct with a few fine interrupted tannated catgut sutures. The duct should be implanted in the buccinator sufficiently far back to cause no tension. If the fistula is adjacent to the junction of the gland and the duct, it may be necessary to loosen the buccinator, undermining it from the inner surface of the masseter and buccal fat and drawing it up to the gland, after the plan of Nicoladoni and Braun.

The secretion of saliva in a gland can be suppressed by ligating the duct, but this operation has been followed by such serious inflammatory reaction, due to infection, probably from bacteria that have already found their way into the ducts, that it is not to be recommended. As a final means, the parotid gland can be removed, but to do this completely and preserve the seventh nerve is a difficult procedure.

## TUMORS OF THE SALIVARY GLANDS.

Tumors of the salivary glands are of extreme interest, both on account of the peculiar behavior of some and because, in spite of an immense amount of work that has been done on them, the exact nature of the largest group, the so-called "mixed tumor," is still a matter of dispute.

**Benign Tumors.**—Congenital enlargements of the sublingual and of Blandin's glands have been reported.

Lipomata, fibromata, angiomata, and lymphangiomata of the salivary glands have all been observed, but they are of rare occurrence. They present no special symptoms peculiar to this situation and are to be treated as are similar tumors in other situations, the operation being conducted in accord with the plans already outlined.

Obstruction cysts may occur within a salivary gland, due to the blocking of one of the smaller ducts, when the accumulation of secretion and epithelial detritus causes a cyst filled with a glary mucus-like fluid. This is a somewhat common occurrence in the sublingual gland, which constitutes one form of ranula, but is extremely rare in the other two. A cyst of this kind grows slowly. The symptoms and treatment of the sublingual cyst were described under ranula (see page 401). If obstruction occurs in a small duct leading from a lobule in the intra-oral part of the submaxillary gland, this cyst would also constitute a ranula; but if the obstruction were somewhere in the body of the gland, it would bulge beneath the jaw.

For cysts bulging below the jaw or into the cheek, a removal of the whole or part of the gland might be necessary, as the simple opening of the cyst might be followed by a salivary fistula or a recurrence.

An old negro woman entered our service at the city hospital with a tumor connected with the left parotid gland; it was a long, finger-like mass extending down into the neck, and near its lower end was attached to the skin. It was elastic, but distinct fluctuation could not be made out. The history she gave was that two years before a small lump appeared in front of the ear, and five months before operation it began to grow rapidly. We took it for a malignant growth and excised it with the skin covering, together with the neck tissues with which it was in contact. The lower half of the parotid gland was removed. Examination during operation showed it to be a cyst,  $2\frac{1}{2}$  centimeters in diameter and 12 centimeters long. It was filled with a clear, thin, straw-colored fluid, which unfortunately was lost. Examination of the cyst wall by Dr. Harris showed it to be not malignant, of connective tissue averaging about 2 millimeters thick, but nowhere showing an epithelial lining.

**Mixed Tumors.**—The more common and most important of the salivary gland tumors is the so-called "mixed tumor." It was formerly rather generally believed that these tumors were composed of

a number of elements—fibrous and mucous tissue, cartilage, epithelial and endothelial cells—and this view is still held by many. Butlin, Kaufmann, Nasse, and Volkmann are of the opinion that all of the various substances which are found in them are the product of the activity of endothelial cells. Wilms, who has done some of the most important of the recent investigations, with many of the French workers, regards these mixed tumors as containing both epithelial and connective tissue elements. It is usually conceded that they often contain cartilage. Bland-Sutton classifies them with the sarcomata and calls them chondrifying tumors of the parotid. He gives a description of the character of the cartilage cells that compose them, but Butlin describes it as a cartilage-like substance which has surrounded the endothelial cells and states that it differs from true cartilage in several important particulars. Their histological contents may be remarkably diverse. Bland-Sutton refers to this as follows: "It is not unusual, in sections from parotid sarcoma, to meet with spindle cells, cartilage, myxomatous tissue, glandular acini, and fibrous tissue within an area of 2 centimeters square." Some are composed almost entirely of cartilage or a cartilage-like substance arranged in nodules bound together with loose connective tissue, and these represent the more slow-growing. The more rapidly growing tumors consist of masses of spindle cells in which the cartilage or cartilage-like substance may be interspersed. The tumors are liable to undergo mucoid or myxomatous changes, which result in softened spots or definite cysts.

These tumors may be congenital or may appear late in life, but they most often appear between the ages of fifteen and thirty years and have a peculiar preference for the right side. They are most common in the parotid, much less so in the submaxillary gland, and very rare in the sublingual. They occasionally occur in the lacrymal glands and palate. They may arise within the substance of the gland or may be connected with it by a stalk, but they are supposed to always arise within the gland capsule. Parotid tumors may arise in front on the gland in the cheek, in the line of the mouth slit. Until they acquire or show a malignant character, they are encapsulated, and at this time, unless situated very deep in the parotid, are easily removed. The gland may be found compressed and wrapped around a large tumor. When not malignant, they are always sharply defined, but may be very nodular. At first they are usually firm, but later may be cystic. In one case a small encapsulated parotid tumor in a woman of 39 years was so soft as to be almost fluctuating; and on attempting to aspirate it, some tissue was drawn up into the syringe, which under the microscope was identified as being composed of endothelial cells. This diagnosis was confirmed after the removal of the tumor. In the sub-

maxillary gland they usually grow toward the neck, but in the parotid the direction of their growth will depend somewhat upon their original starting point. A deep tumor may grow toward the pharynx. After malignancy once becomes evident, they infiltrate rapidly and may ulcerate through the skin. Death from the malignant mixed tumors, whether malignant from the first or whether the malignancy seems to be acquired later, results usually in a few months. Death results more frequently from the local disturbances—such as dyspnea, starvation, hemorrhage, or pneumonia—than from metastasis of the lungs and other organs.

The most common clinical characteristic is the fact that for a long time after they are noticed they may grow slowly and then remain stationary for years, only to take on rapid and most malignant growth. With this sudden, rapid growth may come metastasis of the lungs and sometimes of the lymph nodes. A few grow slowly, but continuously, without any period of apparent rest. They are often the size of a nut or small orange, but may attain the size of a man's head. When these tumors have persisted for a long time, and especially in older people, they may become cystic. These cysts may reach an immense size. Hayes described one, of the submaxillary gland, that had existed for thirty years in a woman who died at the age of seventy-three, which was fifty inches in circumference, weighed forty-seven pounds, and which could have been easily shelled out. They may be tender in spots or may be painful, but are not necessarily so. When situated in the parotid, they often affect the seventh nerve. Salivation is sometimes a very prominent symptom.

The diagnosis of these tumors in their earlier stage is not easy, except on the supposition that a movable nodule situated within a salivary gland, not a lymph node, is probably a mixed tumor. With both the submaxillary and the parotid, tubercular lymph nodes may for a time simulate a tumor; but these are usually multiple, and the behavior of the nodes will usually serve to distinguish them. Stone, which is much more common in the oral part of the submaxillary gland or its duct than in the parotid, is less easily defined than a tumor nodule and can be diagnosed by an exploring needle or the x-ray. After a tumor in a gland has grown slowly for months or years and then ceases to grow, the diagnosis is rather evident. If, later, this tumor takes on rapid growth, the diagnosis is almost certain. When used as a basis for diagnosis, the history must be taken with the greatest care. Even these tumors may sometimes be present for a long time before they are discovered. Tumors which are malignant from the first behave as do malignant tumors in other situations.

The prognosis of these tumors is good if they are removed while



they are still encapsulated, even if they have already taken on rapid growth. Even the benign tumors may continue to grow after removal, for the reason either that their capsule was not completely excised or that some disconnected nodule may have been overlooked. A malignant recurrence after removal is usually of extreme virulency.

The treatment of all these tumors, unless on account of their extent and evident malignancy they are inoperable, is removal with capsule. If the tumor is surrounded by a capsule, it is not necessary to remove the gland, unless it is so nodular that there is doubt of including all of its prolongations. With tumors of the submaxillary gland, it is probably safest and simplest to remove the whole gland in every instance. (For the technic, see page 431.) With all but malignant tumors of the parotid gland, the seventh nerve must be preserved, which complicates the operation (see page 430). For malignant tumors of any gland, the whole gland with its capsule should be removed. If the structure has infiltrated the capsule, the neighboring structures should be removed *en masse*. If this cannot be done, the tumor is inoperable. If the regional lymph nodes are found to be infected with the tumor, they should also be removed.

**Epithelial Tumors.**—Besides those mixed tumors in which the presence of epithelial proliferation is still a matter of doubt, three varieties of purely epithelial tumors have been observed.

**ADENOMA.**—It is probable that many of the tumors which have been described under this head belong to the mixed tumor variety, but pure adenomata have been seen in all three of the salivary glands. They may be malignant.

**CARCINOMA.**—The pure adenocarcinoma, to which variety the malignant adenomata must belong, appear in two clinical forms in the salivary glands, both very rare. These are the medullary and the scirrhus carcinoma. They are both more common in the parotid than in the other glands, though it is possible that certain carcinomata of the floor of the mouth may have their origin in the sublingual gland.

Histologically a tumor of the salivary gland is to be considered an epithelioma when it is observed that it develops directly from the glandular epithelium, and that other elements of the mixed tumors are not present. The soft variety may originate in young persons and is characterized by the abundance of cell growth, later by ulceration. In the scirrhus variety, which occurs only in elderly persons, there is little tumor formation and marked retraction of the surrounding tissues. In this, it resembles scirrhus of the breast. The skin and tissues covering it may be drawn inward, and the surrounding skin may be thrown into folds. The soft tumors involve the lymph nodes more rapidly than does scirrhus, but with the latter a chain of small, hard nodes

may be found extending to the clavicle. Pain is a rather constant characteristic of all carcinomata, usually more pronounced in the soft than in the hard variety.

In the parotid gland the seventh nerve is usually involved, but with the scirrhus the paralysis may be due simply to pressure. With the more advanced tumors, there is the usual picture of advanced carcinoma of the face or mouth with impairment of the function of all associated organs.

The diagnosis of carcinoma of the salivary glands in the early stages, when the diagnosis is a matter of the greatest importance, is practically impossible. If, after excluding syphilis, tubercle, and acute septic inflammations, all newly forming undiagnosed tumor masses are excised or subjected to a microscopical examination, their diagnosis from clinical symptoms will be a matter of less importance. Many of the developing medullary carcinomata have been mistaken for a chronic or subacute inflammation. Carcinoma of branchial origin may simulate carcinoma of the submaxillary gland, but in the earlier stages this impression would be corrected at operation. Lymphosarcoma, developing within the parotid, might simulate medullary carcinoma.

The prognosis is bad. If, however, in the earlier stages the gland and its capsule are removed with the regional lymph nodes, a cure, or a long interval before recurrence, might be obtained.

The treatment is early excision of the whole gland, capsule, and involved tissue, *en bloc*, for a distance of  $1\frac{1}{2}$  or 2 centimeters, together with the regional lymph nodes. If this cannot be done, the patient should not be subjected to radical operation. When the odor and discharges are offensive, the ulcerating masses may be curetted, when not too close to large arteries, and packed with iodoform gauze saturated with balsam of Peru.

In complete extirpation of the parotid—if such an operation is ever complete—where the skin and fascia covering the gland are also removed, it is remarkable how little distortion of the face results. There is an inability to close the eye, but the scar contraction of the cheek seems to prevent the lateral displacement of the mouth that is typical of Bell's palsy.

**Invasion and Excision of the Parotid Gland.**—In the removal of encapsulated tumors situated in this gland, the most important point is the preservation of the facial nerve. During the whole course of the operation, the same side of the face should be kept in view by a careful observer, and any twitching of the facial muscles should be reported to the operator. To facilitate this, the anesthetic should be administered by means of an apparatus which hides no portion of the face. The incision may be made directly over a small superficial

nodule in the direction of the branches of the seventh nerve (Fig. 192), but it is better in most cases to make a semilunar incision from the center of the zygoma curving backward just to the tragus and behind the border of the jaw. This incision extends down to the capsule of the gland and allows the turning of a flap that exposes it completely. As the anterior border of the gland is approached, care must be exercised not to cut the branches of the facial nerve (Fig. 332). The incision for invading the gland is to be carefully made in the direction of the branches of the nerve, examining each bit of tissue before it is cut by grasping it sharply with an artery forceps. If a nerve is pinched, this causes contraction of the muscles supplied. When the tumor nodule is encountered, it is to be removed by blunt dissection that follows the capsule closely. After finding the plane of cleavage, we have been able to enucleate a tumor very quickly with the finger. On the other hand, freely movable, small nodules, which are deeply situated, may be very difficult to find at operation, even though they can be easily felt. After removal of a large mass, drainage is to be used. This operation may be followed by a temporary discharge of saliva, but unless some larger duct has been cut, this discharge will cease.

Even with very large tumors that are still encapsulated, the seventh nerve should not be sacrificed. Though partly paralyzed for a long time, function will be restored when pressure is removed. With very large tumors, to which the relation of the seventh nerve is not known, it may be advisable to locate the trunk of the nerve, as it emerges from under the upper part of the anterior belly of the digastric muscle, and to follow it and its main branches until their relation to the tumor is evident. After any operation on the parotid, there is liable to be a temporary paralysis of the seventh nerve, most marked in its upper branches. It does not appear for twenty-four hours and disappears in from three to five weeks. Paralysis, due to stretching the nerves, appears at once, but disappears in time. Paralysis, due to cutting the nerve, appears at once and will probably not disappear.

Extirpation of the parotid is a more difficult operation and is followed by complete paralysis of the facial nerve of that side. Both because it is an easier operation and because it gives better results in malignant growths, the gland should be removed with as much of its capsule as is possible. Treves has made the statement that a total extirpation of the parotid is a surgical impossibility, and an examination of its anatomical relations would tend to convince one of the truth of this statement. Much can be gained, however, by a partial resection of the ramus. An incision is made from the middle of the lower border of the zygoma back to the auricle and then down in front of the tragus down to 4 centimeters below the angle of the jaw or farther.

If the skin is adherent to the tumor, this is included with the latter by an elliptical incision. The final removal of an elliptical piece of the skin is advisable in all cases to overcome the retraction of the mouth to the opposite side which might follow cutting of the seventh nerve.

The entire superficial surface of the gland should be exposed, and to do this, it may be necessary to extend the incision forward at the lower border of the zygoma (Fig. 332). At the lower pole the superficial veins are ligated, and by careful dissection carried just external to

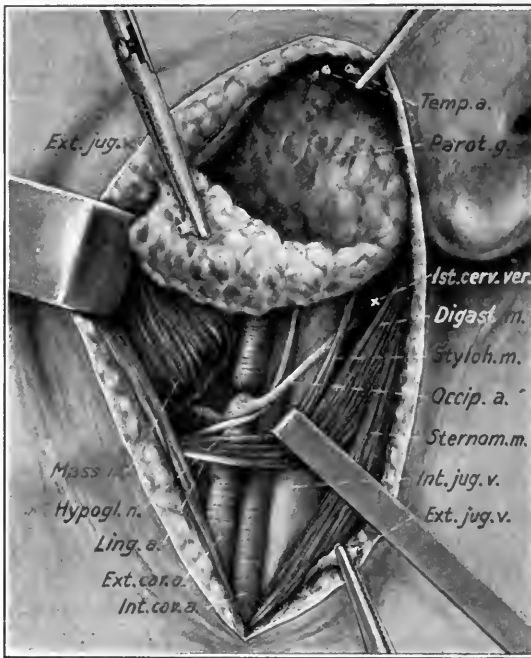


Fig. 334. Freeing the lower part of the parotid gland in total excision. The surrounding and subjacent structures are shown somewhat more plainly than appear at operation. The digastric and stylohyoid muscles may be drawn upward or downward to expose the external carotid artery. (In these several drawings the external ear is represented drawn somewhat backward, but the retractor is not shown.)

the capsule; the posterior bellies of the digastric and stylohyoid muscles are identified running downward and forward just below the angle of the jaw. The posterior portion of the capsule is continuous with the sheath of the sternomastoid, and in order to elevate the gland without opening its capsule, it may be necessary to include a layer of the muscle. Drawing the digastric and stylohyoid muscles either forward or backward, the external carotid can be isolated; and this is to be tied without injury to the hypoglossal nerve, which crosses it super-

ficially at this point (Fig. 334). The external carotid having been secured, the temporal artery and vein are tied just where they cross the zygoma. They lie rather deep just in front of the ear. By surrounding it with an incision above and at the sides and catching every vessel as, or before, it is cut, the gland is made movable and is partially withdrawn from its bed, but it is still held by the fascia that connects it with the pharynx and temporal bone.

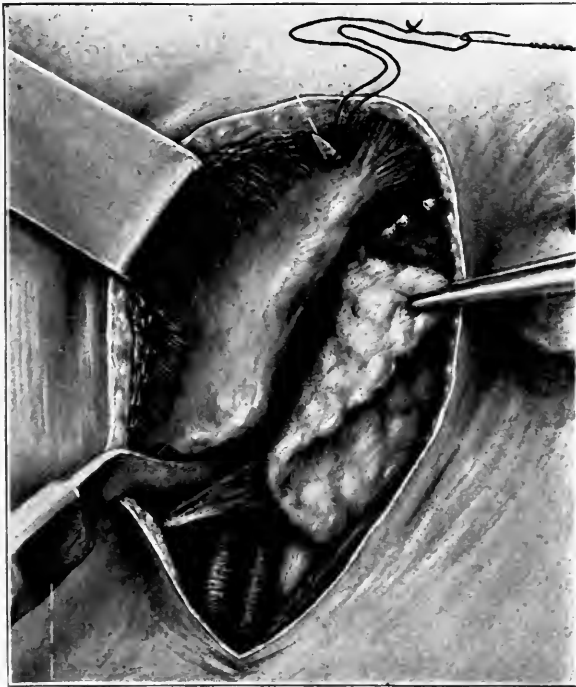


Fig. 335. The ramus of the jaw displayed in total excision of the parotid gland. The needle, shown in Fig. 227, has been passed under the ramus, and the point appears emerging through the sigmoid fossa. It will carry a wire saw into place, which will cut the ramus longitudinally.

To facilitate access to the retromandibular space, Faure, recommends the excision of a piece, 1 centimeter wide, from the posterior border of the ramus below the neck. As simple a procedure, and one that gives better access, is to pass a large, heavy, curved needle under the lower border of the body just in front of the angle and along the inner surface of the ramus and out through the sigmoid fossa immediately in front of the neck (Fig. 335). This is followed by a carrier with a Gigli saw, by which the posterior half of the ramus with the neck is cut free. This piece of bone is to be removed subperiosteally, and

the condyle wrenched out of its socket. The cutting of the bone might be followed by hemorrhage from the inferior dental artery, but this could be controlled as soon as the section of bone is removed. This gives good access to the deep part of the gland and internal maxillary artery, under which latter a ligature can be passed before it is cut. Excision of the condyle does not cause noticeable interference with function.

The internal maxillary artery and vein having been secured, the dissection can be continued backward, drawing upon the gland and

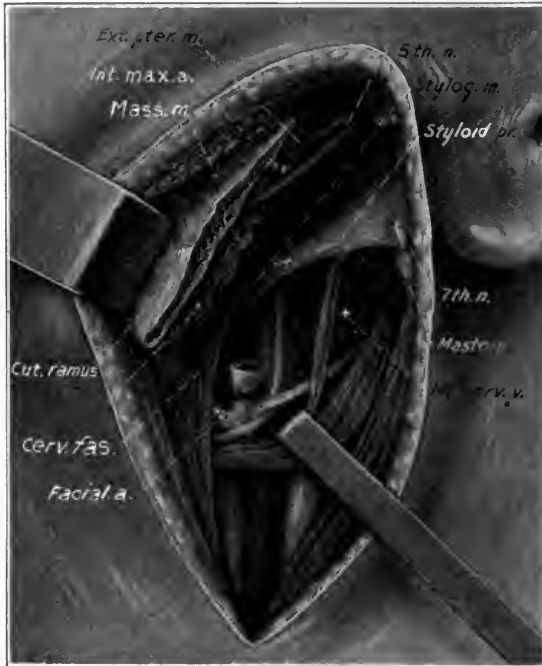


Fig. 336. Structures that are displayed after total excision of the parotid gland, the posterior part of the ramus having been removed.

tearing, rather than cutting, bands which are not in plain view. Posteriorly the capsule of the gland must be followed closely, as it is in close relation with the internal carotid artery (Fig. 336). At the lower part fresh bleeding may be encountered when the external carotid is cut, if it was ligated below the occipital.

If the deep and superficial lymph nodes of the neck are enlarged, these may be removed by prolonging the incision downward, but it is probably better surgery to take one node for microscopical examina-

tion, as this operation is of such severity that a complete removal of the cervical lymph nodes should not be attempted at the same time. If the tumor proves to be carcinoma, or if the node removed is affected with new growth, a complete excision of the lymphatic tissue should be made at a subsequent time. It not infrequently happens that in removing a carcinoma in front of or below the ear, after almost completely freeing the growth, it is found to have deep attachments in front of the mastoid process or tympanic plate, which seems to render it inoperable. In such a case something can be gained, without adding very much to the operative risk, by dissecting back the concha, cutting the cartilaginous part of the external auditory canal, and removing the anterior part of the mastoid, the tympanic plate, and styloid process with a chisel. If, in making this part of the excision, one undercuts the bone in a plane superficial to the jugular bulb, there will be little danger of damaging the great vein or artery.

**Invasion and Excision of the Submaxillary Gland.**—The submaxillary gland is to be exposed by an incision which in a general way passes from near the tip of the mastoid to and past the middle of the body of the hyoid. The incision is curved, with the convexity downward, but its exact location and extent will be modified by the size of the tumor. If the skin is involved, this part is to be included in an elliptical incision. The incision extends through the platysma, and flaps of sufficient size are retracted to give a good exposure. If the platysma is adherent to the tumor, part of this muscle should be included in the excision. The capsule of the gland is freed by an incision at its inferior, anterior, and upper parts. At the posterior part of the lower border of the gland, the facial vein will have to be doubly ligated and cut. The gland is lifted from the anterior belly of the digastric and the mylohyoid muscles, when the intraoral part of the gland will be seen disappearing around the posterior border of the mylohyoid. This border of the muscle is drawn forward with a hooked retractor, when the gland can be severed from the duct after doubly clamping the latter. After the duct is cut, the distal end is ligated. At the posterior border the gland is to be freed down to the upper border of the digastric muscle, from beneath the upper part of which the facial artery enters the gland. The gland is now held by the facial artery and vein at its upper posterior part, if they have not already been cut, and by the facial artery which enters the deep surface from behind the upper part of the digastric muscle. The vessels are caught and cut at the border of the maxilla, and then the deep trunk of the facial artery is cautiously exposed and caught, when the gland can be entirely freed (Fig. 331). The facial artery is tied with fine, strong silk. If the forceps or ligature should slip from this vessel, free hemorrhage

would follow, which could be partially controlled by digital pressure on the common carotid against the sixth transverse cervical process, and then by ligation of the stump of the facial or the external carotid, which are exposed by drawing the posterior belly of the digastric and stylohyoid muscles forward and upward with a blunt hooked retractor.

If the lymph nodes are to be removed, the submaxillary and the submental groups are included with the gland, but the removal of the deep cervicals may, if deemed advisable, be reserved for a subsequent operation. The wound is to be closed with drainage (see Closure of the Submaxillary Wound, page 406).

**Invasion and Excision of the Sublingual Gland.**—Much of this gland lies immediately under the mucous membrane of the floor of the mouth. Nodules and cysts will extend in the direction of the mouth. They are to be removed by an incision made over the most prominent part and by blunt dissection. The tongue is to be held out of the way by a retractor or tenaculum forceps. The remaining wound is to be lightly packed with mildly antiseptic gauze.

Malignant tumors are to be treated as malignant tumors of the tongue and floor of the mouth (see page 493).



## CHAPTER XXXIV.

### CONGENITAL AFFECTIONS AND INFLAMMATIONS OF THE TONGUE.

The tongue may be deformed congenitally or from accident, operation, or disease.

#### CONGENITAL DEFORMITIES.

These are very rare. The commonest is known as tongue-tie, and, popular belief to the contrary, this is unusual. It is due to a short frenum, which prevents the tongue from being protruded beyond the teeth or gums, and the effort to do so may cause the tip of the tongue to be notched. Children are often brought to the surgeon for tongue-tie because they do not talk, but this is rarely the real reason. A genuine tongue-tie may seriously interfere with sucking, and Makuen reports three rather marked cases of improvement in speech after releasing the tongue-tie. When tongue-tie is present, the frenum may be snipped with scissors close to the symphysis of the jaw, the tongue being elevated with the first and second fingers of the left hand.<sup>1</sup> Only the tense part of the mucous band should be divided. Cutting too far back may injure a ranine vein; fatal hemorrhage has occurred from the child sucking on the bleeding vessel. Instances are also reported where a tongue that was made too free by the operation turned back into the pharynx, causing fatal asphyxia. Complete ankyloglossia is a condition where the whole body of the tongue is bound down to the floor of the mouth, with obliteration of the sublingual sulcus. A possible congenital instance of complete ankyloglossia has been reported by Duplong.

In a few instances the tongue has lacked sufficient anchorage so that it could be turned back into the pharynx. Petit reports two cases of fatal asphyxia due to this cause. So rare is complete congenital absence of the tongue, that a case of almost complete absence, reported by Jussieu, has been cited by most writers since. Occasionally the tongue has been congenitally cleft in the midline. This may be accompanied by median cleft of the lower lip and jaw. This could be repaired by simply freshening the edges and suturing the two halves. Thyroglossal duct tumors and fistulæ are presented in the next chapter.

<sup>1</sup>A curious instance of the conservatism of instrument makers is shown in the fact that most grooved dissectors are still made with a slot in the handle, devised by Petit, for straddling the frenum in elevating the tongue for this operation.

### NODULES.

A nodule or an induration in the tongue may be due to a scar or a foreign body. It may be due to a chronic irritation—such as from a sharp tooth—or it may be due to an acute infection. It may be a granuloma—such as tubercle, gumma, actinomycosis, etc.—or it may be the early stage of a tumor.

### INDENTATIONS.

A swollen tongue may be indented by the teeth, and when the tongue remains permanently enlarged, the indentations may persist.

### FISSURES.

Fissures on the surface of the tongue are often of extreme interest. A longitudinal fissure in the midline often suggests that the tongue is wide for its space. Irregular shallow fissures are often seen in tongues that have been the seat of inflammation. Fissures occur in acute infections, chronic superficial glossitis, tubercle, syphilis, and cancer; but according to Butlin, syphilis is the only disease that will produce deep fissures with permanent bosses and nodules between them. These are frequent in tongues that have been the seat of extensive gummatous infiltration and ulceration.

### ULCERS.

“Simple” ulcers arise upon the tongue apparently from various causes. They are seen in all kinds of chronic superficial glossitis and sometimes in a scar. Occasionally they appear to be simply a melting away of the surface epithelium. The real reason why a simple ulcer occurs or why it persists is usually a matter of conjecture. The ulcer may become subacute or chronic, presenting a smooth, red, glazed surface with slightly callous edges. They may be irregular in shape with fissured borders. They may be very painful and sensitive, especially on taking irritating food or drink. The diagnosis of simple ulcer is usually easy from its indolent course and lack of induration. It may persist for many months with little change, but nevertheless all chronic ulcerations should be regarded with suspicion when present in persons who have reached the cancer age, and should not be allowed to persist indefinitely. If the diagnosis cannot be made otherwise, an examination should be made by a competent microscopist.

The response to treatment of these simple ulcers is often more or less disappointing. When due to chronic superficial glossitis, the plan recommended on page 444 should be adopted. The application daily of a 2 per cent solution of chromic acid or silver nitrate may stimulate epithelization. A very painful chronic ulcer could be incised or

scraped in the hope of obtaining healthy active granulations, or, better, excised and the edges of the wound sutured. Any chronic ulcer that becomes the seat of increasing induration in one who has reached the cancer age should be regarded with grave suspicion. In simple, as in traumatic, ulcers the general condition should receive attention.

Dyspeptic ulcers (see page 285).

Herpetic ulcers (see page 286).

Aphthæ (see page 288).

Stomatococce occurs by extension from the gum (see page 296).

Noma may attack the tongue secondarily (see page 291).

**Traumatic Ulcers.**—These may be precipitated by any kind of mechanical irritation, most commonly by a sharp jagged tooth, but traumatic ulcer is rarely entirely dependent upon the mechanical irritation. As pointed out by Paget, it seldom occurs when the patient is in good health, the tongue being normally very resistant to such irritations. At the onset the surface of the sore may be covered by a slough, the edges may be sharply cut, shreddy in places and eaten-out, and the surrounding tissues may be inflamed. In this stage it is really a phlegmon. In the more chronic stage, the swelling in the surrounding tissues is less marked, the edges are not so sharp, and the slough has disappeared from the base; but the induration of its base is more marked.

The diagnosis of simple traumatic ulcer may present difficulty. The presence or history of an irritation will suggest the cause, but it is to be remembered that syphilis or tuberculosis may manifest itself at the site of a mechanical irritation and that cancer may arise in a chronic ulcer.

The phlegmonous stage of a traumatic ulcer will soon pass off under proper local and general treatment, and healing should follow quickly. If in doubt, an examination for the spirochete, and a Wassermann test, should be made. If due to early syphilis, it will usually be followed by other signs of this disease. An ulcerating gumma may show more induration, and the ulceration is usually deeper than in the traumatic ulcer and more resistant to all but antisiphilitic treatment. A tubercular ulcer is shallow; shows little induration, a pale indolent surface, and usually the presence of tubercles near its edge. In a patient over forty years, any chronic ulcer with an indurated part that persists after the apparent cause has been removed should be examined microscopically for carcinoma. If the induration is increasing and other causes including syphilis can be excluded, the excision should be made wide into healthy tissue. Even if carcinoma is not found, one will have done a good service for the patient, as the indurations may persist for a long period before cancer is demonstrable.

In whooping-cough an ulcer may appear on the under surface of the tongue, due to the pressure and friction on the teeth during the act of coughing. Owing to the proximity of large vessels, the ulcer may bleed freely. If such an ulcer threatens to assume serious proportions, a pad consisting of one layer of thick rubber dam fastened over the incisive edges of the lower front teeth has been recommended. A specially constructed silver shield might answer the purpose. Such measures, however, are usually not very practical. In case of serious hemorrhage a deep ligature passed through the base and tied over the bleeding surface would probably be efficient. If the ulcer is indurated, one or two sutures placed in this way could be tied over a small pad of iodoform gauze.

**Dentition Ulcers.**—In infants a small, shallow ulcer sometimes appears where the point of the tongue comes in contact with an erupting tooth. Rarely such an ulcer is caused by an erupting molar. As a rule, these ulcers require no special treatment except the general care of the patient, but may occasionally be touched with a 2 per cent solution of nitrate of silver.

### INFLAMMATIONS.

The mucous membrane may be the site of an acute catarrhal inflammation similar to that in other parts of the mouth. A small, acutely inflamed fissure or ulcer may appear near the tip, that is very painful. Or, possibly, a single filiform papilla will become inflamed and, rising above its fellows, will be subject to considerable irritation. Sometimes a very superficial abrasion or fissure will be surrounded by an extensive area of hard and somewhat tender induration, in which case it is no longer simply a superficial lesion, but a limited phlegmonous inflammation. These are collectively referred to by the patients as "canker sores" and are, we believe, to be distinguished from true aphthæ. In many instances they are partly dependent upon some digestive derangement. The local application of a 2 per cent solution of nitrate of silver, or quickly touching them with a lunar caustic stick, and the use of a permanganate or alkaline antiseptic mouth wash will usually give relief. The bottom of a very painful fissure may be incised after applying a 10 per cent cocain solution, but the habit of cauterizing any mouth lesion deeply is to be condemned on account of the possibility of the scar predisposing to cancer.

(For acute phlegmonous infections and abscess of the tongue, see Septic Infections of the Mouth and Neck, Chapter XXVI.)

### RAW TONGUE (DYSPEPTIC TONGUE).

This is an inflammation which is apt to be recurrent, depending upon the derangement of the digestion. It is characterized by a smooth.

sore, red surface, that seems to be deprived of filiform papillæ. It is not exactly ulcerated; for the excoriation has no depth, but the edge is clearly defined. It usually covers a well-defined and considerable area of the anterior part of the dorsum, while the posterior part is always thickly furred.

It is to be distinguished from acute scalds in that these have a definite history of injury and heal in a few days. The local treatment consists in the use of an alkaline antiseptic mouth wash. The soreness may be lessened by painting with a 2 per cent solution of chromic acid.

The teeth should receive attention, and any digestive disturbance should be treated. When the dyspeptic trouble is relieved, the tongue will return to its normal condition.

### **ERYTHEMA MIGRANS LINGUÆ (GEOGRAPHICAL TONGUE).**

This is a rare disease which appears almost exclusively upon the tongues of children and for the most part in subjects who are in poor condition. It starts as small, red patches, one or several, on the dorsum, usually near the tip. They appear smooth, as if the filiform papillæ were absent, but in which the fungiform papillæ stand out prominently. The patch spreads as a ring or oval with a sharply defined yellow border. When a ring reaches the border of the tongue, it continues around to the under surface. If two rings encounter each other, one may grow at the expense of the other, so that one ends abruptly while the other advances. The rings subside by contracting until they disappear, sometimes leaving the tongue slightly redder and smoother than normal.

Little is known of its cause. Syphilis, of course, has been put forward, but this is only a surmise. We once saw a case in an ill-nourished man, thirty years of age, with a history of acquired syphilis and a typical appearing geographical tongue, but we were unable to keep him under observation long enough to make an absolute diagnosis of erythema migrans. It usually causes so few subjective symptoms that its discovery is a matter of accident, but sometimes it causes an itchy sensation. It is very persistent and does not yield to local remedies. It may persist for months or years. One is at perfect liberty to try any local remedy which he may please, but none seems to have any particular effect. The general condition should be given particular attention, and all means possible used to build up the patient.

### **CHRONIC SUPERFICIAL GLOSSITIS.**

The important characteristic of several forms of chronic superficial glossitis is a change of form and an arrangement of the epithelial cells, which may be collectively termed keratosis. It is this change in the

epithelium that is of greatest interest, because it somewhat resembles the arrangement of the epithelium in the early stages of tongue cancer, and cancer is not an uncommon sequela. Keratosis appears in several clinical forms.

**Leucoplakia or Leucoma.**—This is a somewhat rare and extremely chronic disease that affects most commonly the dorsum of the tongue, but may appear on, or spread to, any part of the oral mucous membrane, or the red borders of the lips. It appears in two forms that differ in appearance, in clinical course, and in pathologic anatomy. In the first of these the affected mucous membrane presents a smooth surface free from papillæ, and is of a bluish color; the border of the patch may fade gradually into the surrounding normal mucous membrane or may be limited by a sharp line of demarcation. The surrounding mucous membrane may be normal or show evidences of irritations, and there may be red raw patches within the bluish-white area. The patch is often seamed with furrows, which may be sore and may later develop indurations of warty excrescences. The patch is usually somewhat pearly or opalescent and cannot be removed without leaving a raw surface. In this form a microscopical examination of the mucosa shows that the papillæ have disappeared, leaving only a layer of corneous epithelium, which is thinner than normal. There is a proliferation of cells in the Malpighian layer, with a collection of leucocytes immediately beneath the epithelium, and the formation of some scar tissue. In other words, the patch appears to be scar tissue covered by a thin layer of epithelium.

The other form of leucoplakia is one that Butlin describes as less common, but we have observed it more frequently than the former. It appears as an opaque, dead white, or slightly bluish or yellowish patch, which is usually raised above the surrounding mucous membrane, from which it is separated by a sharp line. It is thicker toward the middle than at the edges of the patch, and the outline is irregular, and often deeply indented. It may, both objectively and subjectively, feel dryer and harder than the normal mucous membrane. Later it is apt to become indurated and fissured, and the white covering may be cast off in places, leaving patches of red, raw tissue. In this variety of leucoplakia, in common with the one first described, the papillæ have disappeared, and there are leucocytes and scar tissue beneath the epidermis; but here there is an immense thickening of the corneous layer which is the cause of the raised white appearance. This variety was especially described by Sangster.

In both varieties there is a change in the deepest layers of epithelium, which somewhat resembles the first stage of cancer when epithelial cells begin to grow downward through the basement membrane.

Opportunities for the study of the early stages of leucoplakia have been comparatively rare. The disease is then without symptoms and is usually discovered by accident. There is a condition designated by Butlin as smoker's patch, which is possibly one of the early forms of leucoplakia. It is a small, slightly raised oval patch situated upon the dorsum of the tongue, just where the stem of a pipe habitually rests or it is struck by a stream of smoke. The surface may be red and smooth and slightly depressed below the surrounding papillæ. It later becomes covered with a yellowish-white or brownish crust that increases in thickness until it peels off, leaving the original smooth patch. In another form of smoker's patch, the surface is of a pearly bluish-white and perfectly smooth. In either case the disease has a tendency to spread. It may originally appear on the buccal mucous membrane opposite the space exposed between the teeth when the mouth is partially open. Smoker's patch may disappear on the removal of the irritation, may remain stationary for years, or, as is more common, it may spread indefinitely.

In persons who do not smoke, leucoplakia may first appear as a thin, bluish, filmy patch, and this may spread or retract, or even disappear; but after it has once become well-established, it probably seldom if ever is cured. In some cases the disease fluctuates, disappearing in one place, giving rise to the hope that it has been cured, only to break out in another. It may for a long time remain stationary, only to suddenly spread rapidly and involve possibly almost the whole of the oral mucous membrane.

Some patients are especially liable to attacks of inflammation in the patch, or it may die in places and, being cast off, leave a red, raw, sore spot. Most of the real discomfort that these people suffer is in connection with these attacks of inflammation or excoriation.

Besides some special predisposition, the cause may be the local irritation of tobacco, strong spirits, high spices, hot foods, or mechanical irritation. Butlin has observed that it is more prevalent in those who wear red vulcanite dental plates than in those who wear the metal ones, and he also, after observing the disease in several young women who were affected with hereditary gout, assigns that as a cause. The cause most generally assigned is syphilis, and although Gilmer states that he has never seen a case in a person who had not had syphilis, there are numerous other observers who report otherwise. We have seen a number of cases in which there was neither a syphilitic history nor other visible evidence of syphilis. Certain it is that, if syphilis is a cause, the leucoplakia is a post and not an active syphilitic manifestation. The disease is rarely seen in young persons and almost equally rarely in women, but it has been seen in women under twenty, in

persons who do not smoke, in persons who do not use strong spirits, hot spices, or excessively hot foods, and in persons who are not syphilitic, so that no one of these can be looked upon as the specific factor.

The diagnosis of leucoplakia is to be made on the conditions described. It is to be differentiated from syphilitic mucous patches by the acute onset of the latter and the other signs of acute syphilis which may be present. Recent patches of leucoplakia are not so white and are not elevated. It is to be distinguished from postsyphilitic scars—Erb's scars, the thin, slightly depressed opalescent scars that may remain after secondary ulcers—by the history of the attack and by the unchanging size, shape, and character of the scar; from a syphilitic psoriasis by the presence of the same eruption on the skin and other manifestations of syphilis present; from lichen planus by the more pearly appearance and striated arrangement of the lichen and the presence of the eruption on the skin. Lichen yields to arsenic, administered internally, which is not the case with leucoplakia.

Leucoplakia patches may be present with psoriasis. Lissauer found such patches present in ten out of fifty cases of simple psoriasis.

The treatment of smoker's patch, leucoplakia, and smooth tongue is mostly palliative. Care in diet and limitation or abstinence from smoking, with elimination of other irritants, will do much to reduce the intensity and number of inflammatory attacks which cause the discomfort. In the quiescent stage, no treatment other than abstinence from irritants is needed. Butlin allows a limited amount of smoking, but not chewing. In milder cases, a mouth wash of 15 grains of bicarbonate of potash, or 1 or 2 grains of chromic acid to the ounce of water, is recommended. The alkaline antiseptic solution (N. F.), properly diluted, is always soothing to any form of irritation of a mucous membrane. Some tongues are benefited by a daily application of balsam of Peru. Butlin is partial to the application of ointments in all forms of irritation of the mouth and recommends some simple cerate, like cold cream or toilet lanolin. The surface is first dried with a soft cloth, and then a little ointment is applied and thoroughly rubbed in with the finger, or by rubbing the tongue against the roof of the mouth. In some cases one local remedy, and in others another, will be beneficial; but in no case should caustics be used, as the resulting scars might further increase the tendency to carcinoma. We have seen carcinoma develop simultaneously over the whole surface of a leucoplakia after such treatment. Constitutional remedies are of little avail. Even if a leucoplakia is dependent upon syphilis, it is a postsyphilitic lesion and is not influenced for good by mercury. It is the belief of some that it may even be caused by antisyphilitic treatment.

The question of excision will sometimes arise. This is not to be



ordinarily recommended in early cases unless they are very small. However, all persistent ulcers, thick indurations, and warty excrescences should be removed if possible. Small lesions can be excised, together with a wedge-shaped piece of tongue, which will allow the immediate coaptation of the edges by suture. If it were necessary to remove a large surface, the effort might be made to transplant a flap graft from the cheek to cover the defect. The disease is extremely chronic, and a radical cure probably rarely occurs except by excision.

**Smooth Tongue (Moeller's Glossitis).**—There is a form of chronic glossitis characterized by an abnormal smoothness of the whole dorsum, due to a loss of the papillæ. The mucous membrane is redder and not of a uniform tint. The subjective symptoms are more marked than in leucoplakia, which it anatomically very closely resembles, lacking only the white color, though it may be slightly bluish. It is more easily irritated, and there is greater tendency to acute ulceration. The treatment is similar to that of leucoplakia.

**Ichthyosis.**—This is the name applied by Hulke to a certain form of keratosis characterized by patches of a chronic hypertrophy of the papillæ, which may become white and quite horny. Otherwise it is of the same nature as leucoplakia and is very prone to be followed by carcinoma. The term verrucula, which means little wart, has also been applied to this condition. The treatment of ichthyosis is similar to leucoplakia, except that salicylic acid solutions may be beneficial in keeping down the hypertrophied papillæ.

Dr. Mook recently showed us a case of this kind in his service in the Skin and Cancer Hospital, in a syphilitic who had received salvarsan. The patch was becoming thinner, especially at its edges, where it looked more like a typical leucoplakia. In one case in the Skin and Cancer Hospital, the ichthyosis extended to the nasal mucous membrane.

**Black Tongue or Hairy Tongue.**—This is another, less important form of keratosis. It is rather interesting, because usually the back of the tongue becomes dark brown or black, and the papillæ elongated, until it looks as if it were covered with hair. At first the patch is small, but it extends slowly until a large part of the dorsum is involved. It usually lasts several months. It is possibly caused in some cases by a black mould which has been cultivated by Ciaglinski and Hewelke, but the color may be due to accidental staining. It is not believed that this form of keratosis predisposes to cancer; and it is not accompanied by the changes in the corneous and deeper layers, which are found in the other forms of keratosis. Lediard saw a case complicated by cancer, and we once saw another. But in both instances the cancer was under the tongue away from the hairy patch, and in our case the

cancer antedated the patch. The patient may be assured that the disease will pass off. A 2 per cent salicylic acid lotion may be applied daily, if necessary, to keep down the excess of epithelium.

### GLOSSODYNIA EXFOLIATIVA.

This is a form of superficial glossitis closely related to neuralgia of the tongue. It generally appears in poorly nourished anemic or neurotic women. It is characterized by red spots or streaks, that are to be observed by separating the papillæ, and a burning pain, that may be very severe. The pain is usually brought on by eating or continuous speaking. The condition is chronic, but has quiescent periods.

Heretofore, treatment has not been a success. The application of increasing strengths of silver nitrate gives relief by forming a protecting pellicle. The actual cautery has been recommended with the object of destroying the nerve ends. If such a case were to come under our observation now, we would try the injection of alcohol around the lingual nerve.

### TUBERCULOSIS OF THE TONGUE.

Tubercular infections of the tongue may occur secondary to pulmonary tuberculosis, by direct contact from the sputum; it may be an extension of lupus from the face, or due to metastasis; and it is possible that in some cases the infection is primary. Ordinary tubercular infection of the tongue is much more common in men than in women, but in the latter lupus is more prevalent. This is especially true of girls and young women.

Tubercles first appear as small yellowish nodules from 1 to 5 millimeters in diameter, and in this stage are usually discovered by accident. They seldom attain large size without ulcerating, but occasionally they may grow to be 1 centimeter in diameter, or larger, and still be covered with normal mucous membrane. They may be multiple, and most commonly appear near the tip or sides of the tongue. If incised, they may show caseation. In place of frank ulceration, the nodule may become fissured.

**Tubercular Fissures.**—These are usually single, short, and very deep compared with their surface extent. The sides are foul and ragged. The induration may cause an elevation of the edges, which has been described as a tubercular papilloma.

**Tubercular Ulcers.**—Lupus is usually associated with the same disease on the face. It shows more tendency to shrink and atrophy than to break down, and small tubercles can usually be found in and near its edges. It gives rise to a purulent discharge, but shows no tendency to slough *en masse* or to form punched-out ulcers. It gives little pain and is very chronic. Tubercular ulcer is the term applied

to the more aggressive type. A tubercular ulcer may arise in a tubercular nodule, in a traumatic ulceration, or may start without a recognized previous induration or injury. When completely formed and not sloughing too extensively, it usually shows an uneven, pale, flabby surface of rather watery granulations, or covered with a grayish-yellow secretion. The edges may be slightly redder than the surrounding mucous membrane. They are usually sharp cut or beveled, rarely elevated, everted, or undermined, but Butlin states that he has seen tubercular ulcers with as much induration as is found in carcinoma. At first the ulcer may be indolent and neither painful nor tender; but as the disease advances, tenderness and pain become marked, and the patient declines from both exhaustion and lack of food.

The ulcer later advances rapidly with or without actual sloughing, and if unchecked, death usually takes place within a few months. If the ulcer should heal spontaneously, as it may do in the early stages, it usually returns later to the same spot. (For diagnosis and treatment of tubercular lesions of the soft tissues of the mouth, see page 299.)

### SYPHILIS OF THE TONGUE.

Syphilis is one of the most frequent diseases of the tongue and next to cancer the most important; yet this does not warrant the very common assumption that every obscure affection is due to syphilis.

**Chancre.**—The primary sore may occur upon the tongue, but not nearly so frequently as it does upon the lips; it is much more frequent in men than in women. It occurs in two rather distinct clinical forms: the smooth, and the ulcerated. The former appears as a smooth, round or oval excoriation, not elevated, sharply outlined, and covered with a grayish purulent secretion. It is distinctly indurated and not ulcerated. The ulcerated chancre has the same induration, but the surface shows a shallow concave ulceration. Butlin describes a rare fissured chancre which occurs in a fold of the tongue, but in all, the induration which has given it the name of "hard" is the same. In every case there is an early and marked enlargement of the cervical nodes, usually of both sides, but the enlargement is not always greatest on the side corresponding to the sore.

**Mucous Patch.**—These may occur on the dorsum or under surface, but more frequently on the sides and tip. They are not so common on the tongue as on the lip and tonsil. They are usually multiple, are more common in men, and rarely appear without other signs of secondary syphilis. The appearance varies according to the location. On the dorsum they are usually round or oval, almost white, and very slightly elevated. On the under surface, where they are exposed to no irritation, they are still whiter and more elevated. Unless

there is some irritation, there is no redness of the surrounding mucous membrane in either situation. The white layer may be removed, leaving a smooth, elevated red base. On the sides of the tongue when irritated by the teeth, they show more or less ulceration, which has red, sometimes stellate, outlines. They are rarely painful unless ulcerated. After a careful examination of the case and of the history of other lesions, it is improbable that they can be confounded with anything else.

**Syphilitic Fissures.**—These may occur in the secondary or the tertiary stage. The former are almost always on the border of the tongue, due to irritation of the teeth. They may occur in a mucous patch, in which case the fissure may be stellate and will show sloughy borders, or they may develop without a previous mucous patch. These latter will show little evidence of inflammation, but are tender and painful. These fissures may extend and become ulcers. Often there is nothing in their appearance to denote their specific cause. After removal of irritants—such as rough teeth—they heal quickly under antisymphilitic treatment and the daily local application of a 2 per cent solution of chromic acid; but they leave scars, which may be depressed or may be raised and show milk-white lines or patches. The fissures of tertiary syphilis are probably fissures in gummata, although they may show little induration. They are usually situated in the dorsum and may be very deep. The treatment is the same as for gummata, but the depth of the fissures should be kept free from food and filth. They leave deep fissured scars.

**Sclerosing Glossitis—Tertiary Plaques.**—Under this head Butlin describes a condition, to which attention was first pointed by Fournier, and which, according to the latter author, is often responsible for the deep fissures that are seen in old disfigured tongues. Butlin describes a case under his care at St. Bartholomew's Hospital, which, during the course of a severe tertiary syphilis, showed plaques on the tongue on several occasions. One on the middle of the dorsum he describes as being an inch long, made up of two separate oval plaques, which afterward coalesced and, increasing considerably in size, formed a single plaque measuring two inches long and three fourths of an inch across. It rose almost abruptly from the dorsum and in its center reached the height of one eighth of an inch, but was a little less elevated at the sides. It was perfectly smooth and of a deep-red color, but with a decidedly purple tint. Down the center ran a groove formed by the meeting of the two original plaques. The whole plaque was glazed and shiny, and was at no point broken or even cracked. It felt very firm, but the firmness did not extend far into the substance of the tongue. In other somewhat similar plaques which had previously appeared on the same tongue when the patient neglected treatment, there

developed a moderately deep ulceration, but all would disappear under proper treatment.

According to Fournier, there may be a superficial or deep sclerosing glossitis, depending upon the depth of the induration. In the superficial variety there are indurations which develop in the derma, and which feel like discs of parchment. They are of a deeper red than the surrounding mucous membrane and may be of any size and shape. They tend to break down, forming fissures or ulcers which, when healed, leave milk-white patches. The disease is very chronic and very painful in the ulcerated stage. In the deeper variety there may be no induration of the superficial part of the mucous membrane. The surface of the mucous membrane is mammillated or lobulated, and like the surface of the liver in cirrhosis, ulceration is liable to result, especially in the fissures. A rare form is the syphilitic macroglossia, in which the whole tongue is swollen and hardened. There is not, we believe, evidence to show that these various forms are not due to diffuse gummata, and they are often accompanied by ordinary gummata.

The prognosis of the lesion will depend upon its extent and the time at which treatment was begun. After scar is formed, the deformity is permanent, and the resulting fissures may be the source of constant irritation.

**Gumma.**—Gumma of the tongue may be superficial or deep. In either situation they are apt to be multiple, but the deep gummata are often larger and may persist longer without ulceration. (For the characteristics of gummata and gummatous ulcers of the tongue, see under Differential Diagnosis of Carcinoma of the Tongue, page 478.)

Little progress has been made during several decades in the treatment of late syphilis, and there are many conditions which we had come to regard as permanent postsyphilitic lesions. But with the introduction of salvarsan, many of the supposedly postsyphilitic lesions were found to clear up; and therefore they are to be regarded as active and not postsyphilitic lesions. As an example, it would be very appropriate here to cite a case of late syphilitic glossitis, reported by Sir Malcolm Morris, that cleared up perfectly after the administration of salvarsan. We cite this particular case because, in spite of uninterrupted mercurial treatment, the tongue had become deeply fissured, lobulated, and eroded; and because the report is accompanied by four colored lithographs which show the typical lesion before treatment, the apparently normal tongue forty days after the injection of salvarsan, and two intermediate stages. To one who is not familiar with the picture of marked sclerosing syphilitic glossitis, the first illustration is well worth seeing. To one who has struggled to relieve such a condition with the older remedies, such a result seems little short of marvelous.

## CHAPTER XXXV.

### TUMORS OF THE TONGUE.

In this chapter are presented the various tumors that have been found in the tongue, exclusive of carcinoma.

#### **LYMPHANGIOMATOUS MACROGLOSSIA.**

Although not the latest writing on the subject, Butlin's description in his "Diseases of the Tongue" is, we believe, the best clinical presentation of lymphangiomata of the tongue. Lymphangiomata appear in the mouth, as either grouped or scattered vesicles, which usually contain clear fluid, or which may be hemorrhagic from the rupture of a capillary. Between the vesicles are seen bright-red points due to capillary loops. A patch of vesicles may be small or cover a considerable area. The vesicles may be so small as to require a hand-glass for their detection. We have seen them on the under surface of the tongue as several discrete tufts that resembled papillomata in which no vesicles could be seen.

They start as simple dilatations of the lymph spaces beneath the epithelium. But as these extend, the surface epithelium is thinned; by extending downward and by fusion of the spaces, large cysts may be formed. In the tongue the growth of lymphangiomata with their various subsequent changes constitutes lymphangiomatous macroglossia. As the disease progresses, three changes occur around these dilated lymph spaces, and in proportion to the predominance of each will the condition in advanced cases depend.

(A) The blood vessels, both arteries and veins, that surround the lymph spaces increase in size and become thin-walled, and by rupturing into the cystic spaces, fill them with blood. By this means certain lymphangiomata will be found to contain fluid stained with blood or solid blood clots.

(B) An inflammation occurs around the lymph spaces which results in the formation of connective tissue. These attacks of inflammation are recurrent, but each, when it subsides, leaves the tissues more infiltrated than before. The clinical history of a lymphangioma is marked by these repeated inflammatory attacks. The connective tissue infiltration around the cysts gives them a firm tumor-like base which is one of their diagnostic features. An old lymphangioma attains great hardness. As the connective tissue increases, by its pressure it causes

atrophy of the muscle fibers so that the enlarged tongue contains less muscle than normal.

(C) Round cells collect in the deep connective tissue spaces which are not replaced by new connective tissue, but tend to form new growth which may terminate in a small round cell sarcoma or lymphosarcoma.

Lymphangiomas are usually congenital, but may not show active enlargement until puberty or later. They are apparently not always congenital, for they have followed injury or operations upon the tongue or mouth, even so slight as the cutting of the frenum. They have occurred in conjunction with cystic hygroma and true angioma. The enlargement of the tongue, though progressive, is from time to time accentuated by the acute attacks of inflammation. At first the tongue may simply present vesicles on some part of its surface while its substance is soft. When the vesicles rupture, they may leave tender places that cause a disinclination to take food. Later, as the size increases, the tongue can still be retained within the mouth, but it is evidently too large. It causes impairment of speech and difficulty in eating. When it constantly protrudes, the saliva dribbles, the teeth become coated with tartar, and the mouth is foul. The tongue is subject to attacks of superficial glossitis with ulceration, and becomes dry and fissured. The teeth become displaced, and the palate and jaws deformed. When the enlargement occurs during the period of growth of the bones, the deformity of these is much more marked. The whole tongue may be the seat of the angioma, but more commonly it is limited to some part. Aside from the swelling that follows acute inflammatory attacks, the process is slow of development, requiring months or years to reach an advanced form. The diagnosis is made from: the presence of cysts containing serum or blood, which usually have some induration around their base; and the chronic progressive enlargement, which is usually very firm. If a section is removed for microscopic examination, it should be done only after placing a chain of sutures around the site of the proposed excision, as the subsequent bleeding may be very free. Even from the needle holes very free bleeding may occur, but it is mostly capillary and will cease with gentle suture pressure. It is to be distinguished from nevus by the presence of serum in some vesicles and the character of its progress; from muciparous cysts by the induration at the base of the vesicle.

**Treatment.**—This should be excision of the affected area made through healthy tissue. When the disease involves the whole tongue, there is little question that a total excision should be made, for it is progressive and will continue to grow unless removed. If so radical a measure does not seem advisable, a wedge-shaped excision should be made of sufficient tissue to allow the tongue to be retained in the mouth.

The excision should be made as early as practical, because the longer the growth persists the more tissue will have to be sacrificed. If the tumor shows no present inclination to grow, as may be the case in infants and young children, excision can be postponed until after infancy and the child is in good condition, but it might be necessary to do the operation immediately after birth in order to preserve life.

It is to be strongly recommended that the excision be made with a knife or scissors with immediate suture. While this method would appear most reasonable and practical, still the actual cautery has been recommended. Butlin sounded a warning against the use of the actual cautery in the tongue in any condition, on account of the danger of the scar being a predisposition to cancer. Moreover, in lymphangioma the disease has been made worse by its application.

In making an excision with a knife or scissors, hemorrhage is a serious consideration. One lingual artery could be tied for a unilateral growth, but a simultaneous ligation of both linguals might not be safe. One lingual could be tied, and the opposite carotid temporarily compressed. If it were evident that, even after splitting both cheeks in the line of the mouth, the growth could not be surrounded by hemorrhage controlling sutures, the tongue could be removed by Kocher's normal excision (see page 501).

### **SIMPLE MUSCULAR MACROGLOSSIA.**

This occurs congenitally, either by itself or in conjunction with other hypertrophies of muscle and bone. A combination of muscular and lymphangiomatous hypertrophy has been reported by Zeisler. The muscular tissue may be normal in its microscopical appearance, or the fibers may be increased in number and in size. Simple muscular hypertrophy of the tongue is usually associated with defective intellect, and as a rule, no treatment is indicated; but the size of the tongue can be lessened by a V-shaped excision. Besides these usually congenital conditions, the tongue may become temporarily or permanently enlarged as the result of septic infection, syphilis, or mercurialism.

### **TUMORS OF THE BLOOD VESSELS.**

Aneurysm, in its various forms, may occur. Capillary nevi, similar to those seen upon the skin, composed of a mass of dilated capillaries, occur on the tongue, cheeks, and lips. They are usually congenital, but may be acquired. Upon the tongue they appear as small, slightly elevated patches, the size of a pea or smaller; on the buccal surface of the cheek they may be larger—here, or upon the lip, they may be continuous with a wine spot upon the face. They are of a bluish color, darker than their surroundings, and at the periphery an interlacing



of small vessels is visible. They may be single or multiple or may converge into the venous cavernous form of angioma.

**Cavernous Angioma.**—The venous or cavernous angioma is composed of a mass of dilated veins and is either sharply circumscribed or merges into the capillary form. The circumscribed cavernous angioma possesses a distinct efferent artery and afferent veins and does not communicate with the neighboring capillaries. They occur singly or in groups and show lumps or ridges of distended veins, of a dark bluish or greenish-black color, which project slightly above the surface and may extend deeply into the subjacent tissues. They are very compressible, but immediately refill when pressure is released. When the head is held low or pressure is put upon the deep jugular veins, or when anything else occurs that retards the venous return, they become more distended than usual. Butlin states that some of these venous angiomas are not compressible, but feel like tense elastic cysts. We have never observed such a condition nor do we understand the mechanism that can produce this symptom—unless they contain a clot or have been inflamed as the result of injury or infection. They are usually congenital in origin, often growing later from capillary nevi, but they may arise apparently independently of a congenital angioma.

Venous and capillary angiomas are of clinical importance, both because of their liability to hemorrhage and because they may spread indefinitely, converting all tissues of a large area into a swollen, discolored mass of thinly covered blood vessels. In the tongue they are usually not large, though there are a few instances on record in which the whole tongue was converted into a greatly enlarged cavernous mass. One of these, preserved in the Hunterian Museum of London, old catalogue No. 2767, consists of what was the anterior two thirds of the tongue, which was removed from a man by Butlin, because it had been converted into a cavernous angioma. It was of congenital origin. Parts of the lips, cheeks, and floor of the mouth and face may be converted into a soft, compressible tumor of a bluish color on its mucous surface and slightly more reddish on the external. Nowhere are these extensive extending nevi sharply marked off from the surrounding tissue. When situated under the tongue in the floor of the mouth, cavernous angioma has been mistaken for ranula. Besides being the source of occasional copious hemorrhages, started by injury or by simple rupture of the thin-walled vessels, these nevi may become infected and suppurate. In the smaller tumors, especially of the capillary nevi, this may be followed by obliteration, but in the more extensive cavernous ones it constitutes a serious complication. Cavernous nevi are sometimes obliterated by fatty degeneration.

Varicose veins filling the floor of the mouth are to be distinguished from cavernous angioma by their symmetrical bilateral distribution, and by the presence of enlarged normally situated veins on the under surface of the tongue and inner surface of the lip. The varicosity of the veins in the floor of the mouth may be so extensive as to raise the mucous membrane to the level of the ginvivæ. They empty when compressed and immediately refill in the same way as does a cavernous angioma. They might bleed freely if injured, but we have never observed any serious symptoms caused by them.

DIAGNOSIS.—The arterial and aneurysmal tumors are distinguished by their pulsation. With aneurysms the thrill may be felt. A history of a penetrating injury may suggest the presence of an aneurysmal varix. In cirroid aneurysms the enlarged arteries have been felt under a mass of varicose veins. The diagnosis of capillary and venous nevi is usually extremely simple, but if indurated, it is desirable to determine whether the induration is due to some former injury or infection, or to the involvement of the lymphatics. The latter condition would constitute lymphangioma. In pure hemangiomata indurations due to past injury or infection are usually sharply localized, while the inflammation that often accompanies lymphatic dilatation causes a more diffuse hardness. With the lymphatic angiomata, the characteristic blebs are usually present. From varicose veins a cavernous angioma is to be distinguished by the symptoms already mentioned.

TREATMENT.—As a general proposition, all angiomata should be destroyed or removed. While small nevi, as such, really need no treatment; still, when small, their removal is a very simple matter, and their tendency to enlarge at any time must not be ignored. At least, they should be destroyed or removed as soon as they begin to extend. Many blood vessel tumors have been destroyed by the injection of irritating substances into them, but with the exception of boiling water in the large diffuse cavernous angiomata, the injection treatment is to be condemned on account of the danger of both sloughing and embolism. Besides the injection of boiling water into certain selected cavernous tumors, there are three lines of treatment that may come within the domain of good surgical practice: (A) the ligation of vessels; (B) the destruction of the mass by acupuncture; and (C) the excision of the mass, either by dissecting it out or by cutting through the surrounding healthy tissue. Other things being equal, excision is the best practice. Aneurysmal enlargements have been treated by the proximal ligation of one or several arteries—such as the lingual and facial—first on one side of the face and later upon the other. Whenever possible, it is better to excise the mass of vessels, but before this is done, the arterial blood supply is to be controlled. In some situations this can be done

by grasping the base or surrounding tissue with one or several compression forceps, or by temporarily surrounding the growth with interlocking compression sutures. These sutures may include parts of the face, the body of the jaw-bone, or the tongue. These compression sutures are best made of elastic-band rubber and should be drawn only sufficiently tight to control the blood supply, and not crush the tissues. For the anterior two thirds of the tongue and the floor of the mouth, the blood supply may be controlled as follows:

Just anterior and internal to the angle of the jaw, close to the inner surface of the bone, a small submaxillary skin incision is made, and through this a probe-pointed needle or a stiff probe is forced through the posterior part of the floor of the mouth just in front of the anterior faucial pillar, using the finger on the inside as a guide. By means of this probe or needle, two silk carriers, one white and the other black, are drawn through the floor of the mouth, the internal ends being brought out of the mouth and fastened to the submaxillary ends by an artery forceps. This part of the operation is repeated on the other side. By means of the two white carriers, a fine, strong, elastic tube or band is made to surround the pharyngeal surface of the tongue, and skin, just above the hyoid bone. This ligature includes the lingual and the facial arteries. The internal end of each of the black silk carriers is passed through the cheek, and by means of these, constricting bands may be made to surround the remaining tissue of the floor with the body of the jaw on each side. The distal end of the facial arteries can be controlled by grasping the cheeks with flexible-bladed forceps. While tightening the band that surrounds the tongue, the body of the latter should be drawn forward, and the band placed as far back as will be permitted by the faucial pillars. By doing this, the body of the tongue will be in front of the constricting band.

Another plan is to ligate certain arteries of one side—such as the facial, lingual, and distal part of the external carotid—while the external carotid is temporarily compressed upon the other. This will partially control it. After controlling the blood supply, the tumor is cut down upon and dissected out. Both aneurysms and sharply outlined cavernous angiomata can be removed in this manner. With aneurysms, the cut ends of the individual arteries will have to be caught and ligated before completely releasing the control ligatures. With venous tumors, the cut end of the afferent artery can be controlled with sutures. From the lips, sides of the tongue, or tip of the tongue angiomata can be removed by V-shaped excisions (Fig. 341).

Small, and even large, nevi have been destroyed by the electric needle.

### CARTILAGINOUS TUMORS.

Cartilaginous tumors, or cartilage-like tumors, may occasionally arise in the tongue in connection with the median septum, or secondly in the endotheliomata. They are exceedingly rare. The osseous and the true cartilaginous tumors are congenital and can occur only in, or near, the median line, and are of extremely slow growth. Endotheliomata that produce a cartilage-like substance are also of slow growth, but like mixed tumors of the salivary glands they may become active. They should be removed if they cause symptoms or show any activity, but it is more probable that they will be removed to make sure of their character. Amyloid deposits on the tongue have been reported. They occur in persons suffering from amyloid degeneration, and have usually been situated on the base of the tongue in front of the epiglottis.

### LIPOMA.

Besides those that occur in or under the tongue in the midline and which grow into the floor of the mouth, lipomata have been reported as occurring singly at the anterior part of the border of the tongue; and multiple lipomata of the tongue have been observed in old men. Except those that occur in the midline beneath the tongue, the tumors lie immediately under the mucous membrane, which, although thinned and stretched and devoid of papillæ, is movable over the growth. Usually the yellow color has been apparent through the thin mucous membrane. The superficial tumors are movable, can be displaced by finger pressure, and their lobulated structure is palpable. The central lipomata are probably always congenital and derived from the median septum of the tongue. They are likely to contain both fibrous tissue and cartilage. These may grow between the muscles until they appear beneath the chin. These tumors seldom cause ulceration, and even when as large as a small orange, they are remarkably free from subjective symptoms. Excepting those which are congenital, they have usually appeared in middle or later life. They are to be distinguished from soft sarcomata chiefly by their chronicity, requiring as they do many years to attain any considerable size. (The differential diagnosis of median lipomata from ranulæ and dermoids is given on page 402.)

The treatment of lipomata that have attained a sufficient size to attract the patient's attention is removal. The extirpation of submucous lipoma is very simple. Under local anesthetic an incision is made down to or into the tumor. The latter is grasped with forceps and drawn forcefully out of its bed. As this is done, its attachments to the surrounding connective tissue are cut with knife or scissors. If the tumor is distinctly pedunculated, it may be removed by an elliptical incision at its base. The wound may be immediately closed by deep

sutures that include its full depth. (The sublingual lipomata are to be approached as outlined in Tumors of Floor of the Mouth, page 404.)

### FIBROMA.

These occur in two forms: the soft tumors that are especially liable to become pedunculated and are often known as lingual polypi, and the hard tumors that are more apt to remain intramuscular. The former are frequently situated on the dorsum of the tongue and are often multiple. It is stated that they are apt to follow a chronic inflammation as do polypi of the nose. These soft tumors grow slightly more rapidly than do lipomata and do not possess their yellow color, but otherwise resemble them closely. The hard tumors are much rarer than the soft. Neither variety gives subjective symptoms, except those due to their size. The treatment is the same as of lipoma.

### KELOID.

Keloid of the tongue has very rarely been observed. Butlin cites two cases: one, reported by Sedgwich, occurring spontaneously in a little girl, the tongue resembling the site of surgical operation; another, of supposed keloid, following an injury of the tongue, in a young man under the care of Mr. Marrant Baker. The present treatment of keloid is the use of radium or the x-ray.

### TUMORS AND CYSTS OF THE THYROGLOSSAL TRACT. (LINGUAL GOITRE.)

The demonstration by His of a tract of tissue extending from the pyramidal lobe of the thyroid gland to the foramen cecum has made possible the explanation of tumors and cysts occurring near the foramen cecum or the hyoid bone, that contain elements belonging to the thyroid gland.

**Thyroglossal Tract Tumors Near the Foramen Cecum.**—These may be cystic or very soft solid. All of these tumors are of congenital origin, but they may not develop sufficiently to cause symptoms until later in life. Usually they are noticed about puberty, but may not give symptoms until late in life. Those occurring about the foramen cecum are usually somewhat sessile and vary in size from a pea to a hen's egg. When large, they project backward toward the pharynx and forward to a less extent, though another tumor may occur above the hyoid that projects beneath the chin. Such a case has been reported by Bernays. They are almost always soft and not indurated, but the first case reported, which was by R. Wolff before the German Surgical Congress, in 1882, is described as being hard.

They are usually of a dark color, covered with stratified epithelium and large veins. They are enclosed in a distinct capsule, and their

substance shows mature or immature typical thyroid gland tissue. Where cysts occur, they are lined by ciliated epithelium. The tumors are very vascular and may contain hemorrhages. Occasionally they are so vascular as to be described as blood cysts. Besides the disturbances that are dependent upon the size and location of the tumor, the most constant symptom is hemorrhage into the mouth, due to rupture of the veins that almost invariably cover it. It occurs most commonly in girls and women. The diagnosis is to be made on: the location of the tumor; its slow growth, usually having been noticed for several years, or hemorrhages having occurred over this period; and its dark color, as seen with the laryngoscope. The lack of surrounding induration or ulceration serves to distinguish it from a malignant growth. Owing to its vascularity, it is not practicable to obtain a section for microscopical examination. In examining tumors and cysts situated along the line of the thyroglossal tract, the situation of the thyroid gland should always be carefully palpated to determine the presence of the normal gland.

Cases have been described in which the lingual tumor was the only thyroid substance present, and its removal was followed by myxedema.

**Perihyoid Thyroid Tumors and Cysts.**—Besides the thyroid gland substance that occurs along the tract within the substance of the tongue, aberrant thyroids have been found in and about the hyoid bone. Streckeisen described these aberrant thyroid masses, and Spalteholz refers to these as *glandulæ thyroideæ accessoriæ*. Treves is inclined to hold them responsible for certain deep carcinoma developing in the neighborhood of the hyoid bone.

Thyroid tumors and cysts occurring above the hyoid tend to project externally between the chin and hyoid bone, or upward and backward, pushing the base of the tongue before them, or they may separate the muscular layers in the midline and project under the mucous membrane of the dorsum of the tongue. They can usually be observed and felt from without, and if deeply situated, can be felt by bimanual palpation. They may be cystic or solid and may cause symptoms varying from slight difficulty of speech to suffocation. If they come to lie immediately beneath the mucous membrane of the dorsum of the tongue, they may cause hemorrhages, similar to those that occur with thyroid tumors originating near the foramen cecum. Cysts and tumors originating in front of the mylohyoid are apt to become pendulous when they attain considerable size.

Those tumors or cysts that lie below the hyoid are usually attached to its lower border or posterior surface. Cysts often extend up between the bone and the thyrohyoid ligament. The latter ligament is attached near the superior border of the bone, with a rather inaccessible space

between the membrane and the posterior surface of the bone. Cysts attached in this space have often been difficult to cure. They are liable to become infected from such ill-advised treatment as puncture and injection, and sinuses remain that lead up behind the bone. These sinuses intermittently discharge a glary fluid, or, becoming obstructed, bulge with the contained fluid. When the cavity is infected, the accumulation is accompanied by acute inflammatory symptoms. Unless all of the epithelium is removed, recurrence will take place. These cysts and tumors always contain at least remnants of thyroid tissue or ciliated epithelium, which precludes their origin from a thyrohyoid bursa (Fig. 339).

**Treatment of Thyroglossal Tract Tumors and Cysts.**—Tumors situated near the foramen cecum, which have persisted for some time and are not increasing in size, and which cause neither subjective symptoms nor hemorrhage, have been considered to require no treatment,

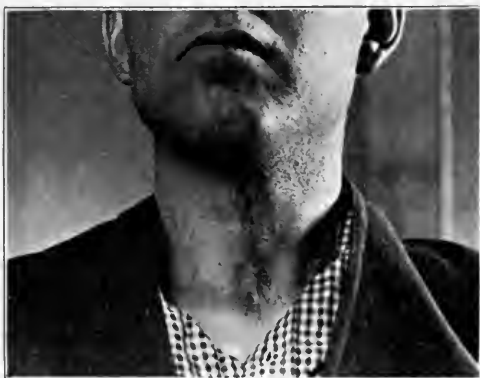

Fig. 337. Scars resulting from repeated inflammation, and incomplete operations on a thyroglossal duct fistula.

as they have never been known to become malignant. When treatment becomes necessary, it should be excision. Owing to the vascularity and inaccessibility of the growths, the galvano-cautery or hot snare is almost universally recommended for the removal of all but very large growths; and when used, the cautery should be at a dull heat to prevent bleeding.

Partial excision of a lingual or suprahyoid tumor might be done, if the size of the tumor causes annoyance and no normal thyroid tumor can be felt. If, after excision of a lingual or suprahyoid goitre, myxedema should develop, thyroid extract would have to be continued indefinitely. The smaller growths may be reached by opening the mouth with a gag, drawing the tongue forward, and working with a laryngoscopic mirror. The hot snare can remove only the projecting part of the mass, but this has been followed by satisfactory results in two cases, cited by Butlin. There was for a time an apparent re-

currence after this method of treatment, which later disappeared. When the growth is too large to be removed in this way, access to the pharyngeal surface of the tongue may be had by a high lateral pharyngotomy. It is our preference, for reasons already stated, to approach all deeply situated tumors of the tongue and the floor by an external incision, and we believe that these very vascular growths can be more safely and completely removed in this manner. (For technic, see under Removal of Dermoid Cysts, page 404.) Perihyoid tumors and cysts are to be treated in the same manner.

The treatment of tumors, cysts, or sinuses is by excision through a median incision, but it is absolutely necessary that the retrohyoid, or even intrahyoid, part be removed. We have seen a number of cases of sinuses in this region that had been repeatedly incompletely removed, or had been cauterized, but not one of them were permanently cured by

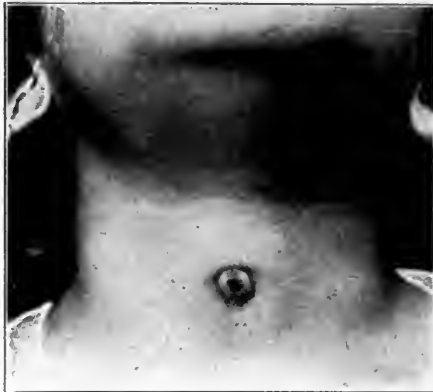

Fig. 338. The external opening of a thyroglossal fistula in a child eleven years old. Removed completely without difficulty, after dividing the hyoid bone.

this treatment (Fig. 337). The simplest way of reaching the retrohyoid attachment is by cutting the bone in two or removing a section of the body. It has not been found that dividing the hyoid causes subsequent trouble, if the halves are sutured by their facial coverings or if a section of the body is removed (Fig. 338). If a section is removed from the body, sufficient bone must be retained to preserve at least part of the attachment of the geniohyoid and geniohyoglossi muscles (Fig. 339).

### PAPILLOMATA, WARTS.

These are local epithelial proliferations that grow toward the surface and remain superficial to the basement membrane. This distinguishes them from malignant epithelioma—cancer—in which the multiplying cells break through the basement membrane and invade the deeper tissues. They are not uncommon in the mouth, occurring upon the



dorsum of the tongue, although they may grow on the under surface of the tongue, on the lips, or on the inner surface of the cheeks. They are usually single, but may be multiple. Butlin cites a case of a boy in St. Bartholomew's Hospital, who had a warty enlargement of all the fungiform papillæ of the tongue. They may occur at any age, but are of much greater surgical interest in persons who have reached what is regarded as the cancer age. This is especially true of warts that develop in a patch of leucoplakia or chronic superficial glossitis, as, according to Butlin, these almost invariably become cancerous, if not so from the first. Papillomata within the mouth resemble warts in

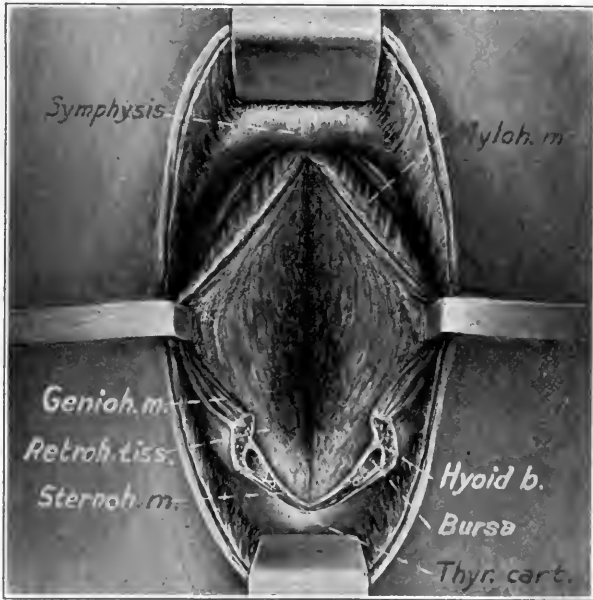


Fig. 339. The region of the foramen cecum of the tongue and the retrohyoid space approached through a transverse submaxillary incision in the skin, and a vertical incision of the mylohyoid muscle and thyroid membrane, and division of the body of the hyoid bone. Such an approach is useful with some tumors and cysts of the thyroglossal duct.

other parts of the body, but on the lip, as already mentioned, they may develop true horn. When developing within a patch of leucoplakia, they at first look like a localized thickening in the patch, but later their watery character becomes apparent. Condylomata and mucous patches in protected areas—such as under the tongue—may resemble a soft wart, but their recent growth and other signs of syphilis will usually give a hint as to their character.

**Treatment.**—Considering the fact that these growths are closely related to cancer and within the mouth in older persons are often but an early manifestation of cancer, we believe that there can be no mis-

take in the position that they should be removed. There are many ways of removing or destroying a wart, but the most certain is the removal of its base by a wedge-shaped excision; and if followed by immediate suture, primary union will occur. In this way the complete removal is assured, and the postoperative discomfort is reduced to a minimum, as is the amount of resulting scar tissue; and the growth is preserved for examination. Ordinarily the incision may be carried within two millimeters of the base of the wart. But those that are at all indurated at the base, are ulcerated, or those that occur in a patch of leucoplakia or chronic inflammation or induration should be regarded as probably cancerous; and the line of incision had better be 1 centimeter from the base, and the wedge of tissue removed correspondingly deep. After removal, the growth should be examined microscopically. We have been struck with the large proportion of inactive, apparently innocent papillomata that in routine examination showed histologic characteristics of carcinoma.

### SARCOMA.

This is one of the rarest of tumors of the tongue. But a few have been reported in literature, and of a number of these, description of the microscopical appearance and the clinical behavior have led to a doubt or a negation of their sarcomatous nature. Of the true sarcomata, most have been of small, round cell type, some with considerable fibrous tissue. Some of these small, round cell growths have been supposed to be lymphosarcomata developing from lymphangiomata. There is nothing characteristic about their location or mode of origin, and among those reported, several have appeared early, but grown intermittently, remaining stationary for years, only to terminate in extreme malignancy. Von Bergmann states that even in the earlier stages they are always very painful. This does not correspond with sarcomata in other regions, where they are usually not painful. Some ulcerate early, while others reach considerable size without involvement of the mucous membrane. When ulceration is excessive, the growth might be taken for gumma or carcinoma. Some have caused enlargement of the regional lymph nodes, while others have not.

In some instances, the lymphatic enlargement has been purely from septic irritation; while, in a case reported by Bloodgood and another by Butlin, an enlargement of the submaxillary gland, which subsided after the removal of the lingual tumor, was due to pressure on the duct.

Those sarcomata that cause a real involvement of the lymph nodes are probably of the lymphatic type. The malignancy of the growths varies excessively, and their histological character seems to furnish little light on the prognosis. Rapidly growing, small, round cell sarco-

mata have been removed from the tongue, with no return for years afterward; yet, in as many reported cases, the growth has returned repeatedly, both locally and in the lymph nodes, after short periods, in spite of extensive operations.

The diagnosis of sarcoma, in order to be of use to the patient, must be made microscopically; the specimen removed for this purpose should include the edge of the growth and a portion of the surrounding tissue. Between hypertrophy of the lingual tonsil and lymphosarcoma the microscope may fail to distinguish. Tumors growing in the neighborhood of the foramen cecum should not be incised with impunity, as the aberrant thyroid growths are extremely vascular and might give rise to troublesome hemorrhage. After removing a piece of any growth for microscopical examination, the raw surface should be immediately cauterized to control hemorrhage and prevent distant transplantation.

**Treatment.**—The diagnosis having been established, the treatment is, of course, removal, with a wide sweep into the healthy tissue. If the lymph nodes are enlarged, these should be removed if, upon microscopical examination, the enlargement proves to be due to infection with the growth. It is questionable if more extensive operating is indicated than is necessary to remove the evident growth with a fair margin of the healthy tissue, for some sarcomata have remained cured for years after being removed with a very meager amount of healthy tissue, while others have returned after repeated extensive operations. The result depends so much upon the degree of malignancy of the tumor that, provided the incision is carried beyond the apparent limits of the growth, the character of the operation seems to have little influence on the outcome. That persistent and repeated removal of the evident growth may be followed by a good result is demonstrated by one presented by Mikulicz in his atlas. The anterior part of the tongue was amputated for a spindle cell sarcoma that occupied both sides of the anterior third and which had been noticed for three months. Six months later, an operation was done for a secondary growth in the lymph nodes, which was followed by a second operation on the lymphatics six months after the first gland operation. Three years after the first operation, there was no return, although there had been an ulceration in the scar, which healed on the removal of some carious teeth.

As with sarcomata of the jaw, we believe that Coley's toxins should be persisted in for several months after each operation.

## CHAPTER XXXVI.

### CANCER OF THE TONGUE.

It is generally accepted that this is always a squamous epithelioma and, unless an extension from the floor of the mouth, is never of the granular type. According to von Bergmann, Steiner reports one that is apparently an exception. We observed one in the author's service at the O'Fallon Dispensary that had apparently originated deeply in the tongue, the tumor occupying most of one half of the body, fixing it to the floor, but not involving the mucous membrane of the dorsum. There was no ulceration until after a section had been removed for microscopical examination. Dr. Tiedemann, pathologist at the Washington University Medical School, reported that it was a columnar epithelioma. It is possible that this originated in the sublingual gland, but the floor of the mouth was little involved compared with the tongue. It had persisted for three months, and at the time pain and distressing salivation were well marked.

#### POSITION.

Cancer may occur on any part of the tongue, but the under surface, tip, and root are much more often exempt than are the dorsum and borders of the body. This corresponds with the more common sites of the supposedly precancerous conditions, including trauma of the borders from rough teeth, and at this site the dorsum is constantly covered with fur, which consists mostly of bacteria clinging to the papillæ.

The age at which carcinoma most commonly develops is between forty and sixty years, but it is probable that the predisposition increases with age—the falling off in frequency after sixty or sixty-five being due to the fact that there are fewer people of the more advanced ages, not that they are less susceptible to the disease. As with carcinoma of the lip, the disease occasionally occurs in young persons, even children, but is then always extremely malignant.

#### ETIOLOGY AND PREDISPOSITION.

A discussion of the specific cause of cancer would be out of place here; although it is possible that the question may be settled before this book is published, at present, and for years past, more study

has been expended upon it than any other one problem in pathology, and it is today apparently little nearer actual solution. The two main theories are: (1) that the uncontrolled growth of the epithelial cells is due to some fault essential to the tissues or acquired through mechanical irritation; (2) that the wild, ungoverned epithelial multiplication and invasion is due to the irritation of some specific fungus or other organism. If one were to review but a fraction of the evidence that is advanced by the exponents of either theory, he would for the time be apt to feel that there could be room for no other conclusion.

The most common predisposing factor is age, and with cancer of the tongue sex has at least an indirect bearing. As stated before, 85 per cent of the cases occur in men. The common explanation for this is that men's mouths are more frequently exposed to the irritants that predispose to cancer—tobacco, strong drink, and syphilis. But that this is the only cause is not proved. Of certain local factors that predispose to cancer we have considerable knowledge; for its accuracy and for an appreciation of the importance of the factors, we are indebted chiefly to Butlin. These have been mentioned in previous chapters and consist of changes in the epithelium, that can be included under chronic irritations, inflammations, and leucoplakia; also deep scars and traumatic ulcers. (The latter are the "Dekubitalgeschwür" of the Germans.) Not by any means that all of these lesions are always or even commonly followed by cancer, but possibly 75 per cent of all carcinomata of the tongue have been associated with some one of them.

Of the scars that may form the starting point of malignant epithelial proliferation, Butlin calls especial attention to those resulting from the use of strong caustics and the cautery, and throughout his writing continually warns against their use in those who have reached the cancer age. Cancer following a scar may be long in showing itself. Among sixteen such cases, in various parts of the body, gathered by Cheatle, the disease appeared between five and thirty-five years after the injury.

Of the mechanical causes, the most frequent is the irritation due to sharp and jagged teeth. Occasionally carcinoma may develop in some trivial acute injury. Cancer of the tongue has apparently been caused by metastasis from some distal site. Butlin cites one such case. By far the most common local antecedent of cancer of the tongue is a chronic superficial glossitis or a leucoplakia. According to von Bergmann, in a series of 159 cases, over 50 per cent were preceded by distinct leucoplakia or chronic white patches. A fair percentage of carcinoma, probably 25 per cent, develops independently of any recognizable precancerous lesion.

**EARLY DIAGNOSIS—RESPONSIBILITY OF MEDICAL PRACTITIONERS AND DENTISTS IN REGARD TO THE RECOGNITION OF THE EARLY MANIFESTATIONS OF CANCER.**

Considering, on the one hand, its invariable outcome, unless successfully operated upon, the sufferings of the victim, and the improbability of successful treatment in the advanced stages; on the other hand, the success, or long periods of immunity, that may follow comparatively simple early operation, the importance of very early diagnosis cannot be overestimated. It, together with the conditions which so frequently antedate its clinical development, should be the subject of study not only by surgeons but by all practitioners who have occasion to examine the buccal cavity. As far as we know, nowhere else—unless it be the stomach—are the majority of clinical carcinomata preceded by recognizable lesions, and nowhere can these precancerous or early cancerous conditions be observed as well as in the mouth, where they often persist for years before becoming malignant or show malignancy, and where developing abnormalities are so quickly recognized by the patient. If there is sound basis for hope that a routine periodic examination of women who have reached the cancer age will very materially reduce the death rate from cervical cancer, much more could reasonably be hoped in reference to the tongue and mouth, if medical practitioners and dentists universally recognized the importance of all chronic lesions and treated and instructed their patients accordingly. The onus of this responsibility rests chiefly upon the dentist. There are few persons in this country who do not consult a dentist, not only once, but repeatedly. It is during what is termed the cancer age that the teeth are disintegrating or artificial teeth are worn. Until the much desired cancer specific is discovered, it is mainly to the educated dentist, grounded in general oral pathology, who makes a complete, though quick, survey of the whole mouth, that the medical profession and the public must look to reduce the now increasing death rate from cancer of the tongue.

In 1909, Mr. Butlin stated that he had operated upon only a little more than two hundred cases of cancer of the tongue in twenty-five years, and he is recognized as the foremost man in connection with the study and treatment of this disease. He states that Whitehead has probably operated upon the same number, that Kocher has operated on possibly one hundred and forty, and few other surgeons have operated upon a hundred cases. Warren states that but 62 cases were operated on in the Massachusetts General Hospital between 1892 and 1906, fifteen years. Struck with the paucity of cases that come to operation, Butlin wrote to the General Registry Office of England requesting

statistics on the occurrence of cancer of the tongue. Dr. Tatham gave the death rate from the disease in England for several years, which showed an average of seven hundred and fifty deaths a year. Butlin estimates that there may be seventy successfully operated cases a year, which would bring the number of cases up to eight hundred and twenty annually. This can only mean that the vast majority of cases are allowed to go unoperated, or are operated on at a time when they have become incurable. Yet, unlike the disease in the stomach, breast or uterus, the patient in almost every instance must have known that he had something wrong with his tongue, either from the time when the cancer first appeared or often for years beforehand; and in most cases either the early cancer or the condition that led to it must have been observed by some medical practitioner or dentist.

Our one present hope for cure of cancer of the tongue is early diagnosis and operation. This is to be more appreciated when we consider not only the late but also the immediate results of operations on early and later cases. The operative death rate of the earlier cases is something between 3 and 5 per cent, while the cures (three-year limit) may on Butlin's statistics be estimated at something between 50 and 60 per cent. With the later operations, those in which the disease may still be considered as possibly curable, the immediate death rate jumps to between 20 and 30 per cent, and the cures may be placed well below 10 per cent. Warren places his cures, in cases in which the disease was confined to the tongue and floor of the mouth, at 31 per cent, but when it has spread to other structures, at 3.4 per cent. Of 172 cases of cancer of the tongue and mouth in the Massachusetts General Hospital, 50, or 29 per cent, were considered inoperable when they entered.

#### EARLY TYPES OF CANCER.

Even more important than knowledge of the conditions that may predispose to cancer is that of the early appearance of the disease itself. These unfortunately are various and not always easily recognized. According to Butlin, these may be in the form of a wart, fissure, superficial abrasion, pimple, superficial tubercle, or deep submucous nodule—the last being the least frequent form of a starting carcinoma. He explained these varied appearances in the initial stage, not by the supposition that various sorts of lesions of independent origin and character are cancer from the first, but that they may become infected with carcinoma. He mentions five conditions, which he considers the most typical and most frequent forms of early cancer of the tongue:

“(1) A little plaque-like, hard sore, smooth and polished, but neither ulcerated nor excoriated. (2) The transformation or replacement of a simple ulcer by a cancerous ulcer, which only differs from the simple

ulcer by feeling a very little stiffer and a very little firmer. (3) The transformation of an entire plaque of leucoplakia into a plaque of cancer. The difference is marked by very slight thickening, a denser white, and furrowing and fissuring in various directions, but without excoriation or ulceration. (4) The transformation of one small area of a leucoplakia tongue into cancer, only marked at first by very slight and superficial hardening. (5) A white, warty growth or compound wart, neither broken nor ulcerated, and feeling at first as if it were fixed to the mucous membrane and quite superficial."

He also states that there are other conditions in which cancer of the tongue may begin, but that these five are the most frequent. Twelve colored plates illustrating these conditions have been published by Butlin, which are worthy of careful study. In his early writings, he classified certain papules, warts, and slightly indurated ulcers that were always followed by the development of clinically typical carcinoma as "precancerous." Later, based upon the discovery that indurated ulcers and papules and warts, developing in a patch of chronic superficial glossitis or leucoplakia, were from their beginning microscopically typical carcinomata, he was led to this statement: "I am now wondering whether there are really any conditions perceptible to touch or sight which are precancerous in the sense which I have been accustomed to employ them." That is to say, he formerly thought that warts and papules turned from non-malignant to malignant lesions. From a rather careful study of his writings, we believe that this implied elimination of the term precancerous refers only to epithelial growths and the ulcers that follow them, which is in accord with the views of many pathologists; that a truly benign epithelial wart or papilloma never undergoes malignant degeneration.

### EARLY CLINICAL CHARACTERISTICS.

When the new cancer has persisted for some indefinite time, there are certain early clinical characteristics, the presence of some of which may make a diagnosis possible.

**Chronicity.**—The first of these is that the disease, having once started, probably rarely recedes. An apparent contradiction to this statement is that, in the history of certain superficial inflammations, an ulcer may appear and disappear spontaneously, to be later followed by an ulcer that is indurated and proves to be cancer. According to our present idea, the most likely explanation of this is that the first ulcer was of a simple nature, and that its successor was an ulceration in a superficial cancerous induration that developed at the site of the first. In the lip a true glandular cancer, the rodent ulcer, may recede and even



scar over, only to break down again, but this is apparently a rare occurrence with squamous epitheliomata. In the earlier stages its progress is not rapid, and it may appear for months as an indolent sore. In this stage, the only suspicious thing about it is that, after removing the source of irritation, it does not yield to such simple remedies as appear to be indicated.

**Continuous Growth.**—The next thing noticed about carcinoma is that it not only does not recede, but is progressive. This extension is occasionally shown in the form of external growth, but much more commonly by induration and ulceration. The base of a wart, the edge of a fissure, or the surface of an abrasion becomes hard, while a deep nodule becomes large. Any slowly extending induration in the tongue of a man, over forty years of age, not due to some evident cause, should always excite grave suspicion. Even when there is an apparent cause for the induration, vigilance should not be relaxed until it has entirely subsided, or until sufficient time has elapsed without farther extension to preclude its being cancer. An induration could be partly due to a developing carcinoma, but mostly to an inflammation, and as the latter subsides, the decrease in the extent of the induration might be misleading.

**Induration.**—The induration is often of a hardness that is difficult to mistake for anything else, although when surrounding an ulcer it may for a time be so limited as to escape notice. It is best detected by pinching up the suspected tissue between the finger and thumb.

**Ulceration.**—Another symptom of carcinoma, which may be the earliest objective sign, is ulceration. This is always surrounded by a wall of new growth in which the ulceration occurs, but it may be so limited in extent as to be not very evident. In other words, the growth may be continuously destroyed almost as rapidly as it forms, leaving only a thin layer of compact cancer substance between the floor of the ulcer and the apparently normal tissue. The ulceration may appear over a large surface before any induration can be felt. This may occur over an area of chronic superficial glossitis that has taken on malignancy. (For further characteristics of ulceration, see page 471.)

**Pain.**—The fourth symptom in the order of diagnostic importance is pain. (For the characteristics of this pain, see page 471.) It is possible that pain is not infrequently a very early symptom and may be the first to attract the patient's attention. It may even occur months before there are recognizable objective signs. A man from the O'Fallon Dispensary, neurological service, was referred to the author as a case of tic douloureux. Although the location of the pain deep in the ear was not characteristic of major tic, still, for want of anything definite except the pain, the third division of the fifth nerve was injected.

giving some relief. The man was asked to return for observation, but was lost sight of. Six months later he returned, complaining of the pain and of hemorrhage from the mouth. Another examination revealed one of those deep-fissured carcinomata, far back under the tongue, which are almost peculiar to this site. That there might have been some slight objective sign of the cancer at the first examination we cannot deny; but if there, it was overlooked by the chiefs and assistants of two out-clinics and of one ward, and at the time of recognition was very difficult to see with the tongue elevated. In a series of seven early carcinomata, reported by Butlin, we notice that in one pain had been present for several months "in the place where the ulcer was," and in another pain preceded the formation of a plaque by eight months.

**Microscopical Appearance.**—When one or several of the above symptoms have aroused the suspicion that a growth is cancerous, the final test is made by a microscopical examination of either the whole specimen or of a section removed for that purpose, which should include a portion of the healthy bordering tissue. This examination should never be omitted when a doubt is raised, but to be of use, it must be made by one specially trained for the work (see page 469).

Salivation and enlargement of the lymphatic nodes, though constant symptoms of the older growths, are rarely related to the earlier stages. Occasionally the lymph nodes will become enlarged, apparently simultaneously with the discovery of the primary growth, or the lymphatic enlargement may be the first symptom that leads to the finding of the primary growth. It is probable that even in these cases the original tumor for some time presented symptoms that, though unobserved, were nevertheless characteristic.

### CLINICAL STAGES OF CARCINOMA OF THE TONGUE.

A cancer is a true cancer from the time the first cell takes on malignancy and throws off the restraint that limits normal reproduction to above the basement membrane. Therefore it is not in exact accord with the pathology to speak of an immature or a fully developed cancer, but it is convenient in presenting the subject to divide the stages of its growth into three periods. The first of these stages has just been discussed. The second period might be considered to start at the time when the objective symptoms render the diagnosis rather obvious. A third and final stage is that during which it is no longer curable by operation. It is impossible in any given case to say just at what time the growth merges from the second to the third stage—that is, at what moment a growth becomes inoperable—but when well advanced the third stage is easily recognizable.

**MID-PERIOD OF CARCINOMA OF THE TONGUE.**

At the beginning of this period some one or more symptoms will assume a more typical form. Later, owing to the progressive growth, ulceration and subsequent enlargement of the lymph nodes, pain, hemorrhage, and distressing salivation are commonly added, while the peculiar general depression or intoxication, known as cachexia, is a thing that no cancer patient escapes unless the growth is removed before this has had time to develop. Besides these, a profuse discharge and a sickening odor are almost certain to hold a prominent place in the later picture. As stated before, active growth, having once started, is progressive—in some cases slowly, in others very rapidly—but it never ceases.

**Growth.**—Sometimes growth continues in the form of an external tumor that may become very evident, even to protruding from the mouth; but this is very rare, and the later extension is usually only in the form of an induration that can be felt better than seen. Often this induration is almost as hard as cartilage, but it may be relatively soft. In a form of cancer that is very rare in the tongue, the scirrhus, growth may be accompanied by an interstitial scar contraction that may lessen the normal size of the tongue without much ulceration being present.

**Ulceration.**—This constant symptom of lingual carcinoma, due to a superficial disintegration of the ill-nourished cancer tissue, may appear before the induration is evident or not until the tumor has attained some size, but it is usually a fairly early symptom. Butlin regards it as an almost necessary symptom and states that though the hard, dry surface of certain warty growths may remain unbroken for some time, even here ulceration is never delayed more than a few weeks. In the case referred to on page 464, we refused to confirm the diagnosis of carcinoma until it had been demonstrated by microscopical examination, because the growth had been present three months without ulceration. This was in spite of the fact that several other typical symptoms were present, but a columnar cell cancer of the tongue is a surgical curiosity. The ulceration may destroy the induration so rapidly as to be the most prominent feature. It may be on a surface or deep in a fissure that makes but little surface showing. It may present a smooth, red surface that joins the mucous membrane in a sharp outline, or it may be covered with ragged sloughs or foul septic granulations. One prominent characteristic of the ulceration of carcinoma on the tongue is that its edges are usually rolled and prominent, seldom "punched out," and almost never undermined. This is an important point in distinguishing between a carcinomatous ulcer and an ulcerating gumma.

**Pain.**—Pain as a rule develops early and is usually of an intense,

persistent character, sometimes with a peculiar tendency to radiate to, or be most pronounced in, the top of the head or deep in the ear. Pain in the ear is usually associated with cancer of the edge or under surface of, or far back on, the tongue. Often the patient will be conscious of little or no pain in the growth, but will suffer torment from pain at one of the sites mentioned.

**Hemorrhage and Salivation.**—These are rarely early symptoms. Pain may be intolerable, the salivation distressing, and hemorrhage of very frequent occurrence, the bleeding being often profuse but rarely directly fatal.

**Lymphatic Infection.**—Infection of the regional lymph nodes occurs sooner or later in every case of cancer. In certain flat ulcers of the lip, the glandular infection may apparently be long delayed; but with carcinoma of the tongue, this is not the case. Just how early the nodes may become involved or how long their infection may be delayed is not known. In spite of the fact that in a few cases the development of the intraoral growth and of the glandular involvement has seemed to have occurred almost simultaneously, it is certain that for a time the growth must be local, and it is probable that it usually remains so for a period after it has assumed an appearance that could be recognized as at least suspicious. In younger persons the lymphatic circulation is supposed to be more active than in the aged, and this is one explanation advanced to partly account for the extreme virulence of carcinoma in young subjects. It is also believed that in very old persons the average interval is longer than in middle life. It is certain that the interval is not always the same, even in persons of similar ages.

Butlin states: "It is probable that in the most rapidly progressive cases the glands may be affected within a few weeks after the disease within the mouth has become actually carcinomatous. On the other hand, there is quite as good reason to believe that carcinoma of the tongue may exist for six, possibly even more, months before the glands are involved." It may be possible that glandular infection occurs much earlier than is supposed. It cannot be taken to mean that infection has not occurred, because the nodes are not palpable and because by microscopical examination cancer cells cannot be demonstrated. It is more than probable that the infection can be held in check in the nodes for some considerable time, the cancer cells reaching the nodes either lying dormant or even being destroyed. In a case reported by Butlin, he had removed some small plaques that he had under enforced observation for three months, in which microscopical examination revealed a very early form of carcinoma. So early was the form of the disease, that one of the pathologists of the Cancer Research Institute was not sure of its character, but another, with Butlin, was satisfied

it was carcinoma. Owing to the unwillingness of the patient, no operation was done on the lymphatics, and three and a half years later, the man returned with a very extensive involvement of all of the nodes on that side of the neck. The intraoral growth had not recurred. As proved by this case and by observations made by many other surgeons, the fact that the infection in the lymph nodes may apparently remain dormant for a long period does not negate its presence, and many cases may have been lost sight of before the glandular infection could be recognized.

The body of the tongue drains its lymph streams into the submental, submaxillary and superior deep cervical, and infrahyoid nodes. There is one lymph duct that drains the area near the frenum, which passes directly to a node that lies near the lower end of the anterior belly of the omohyoid muscle. Some of the lymph streams from the dorsum run through one or two small nodes situated between the geniohyoglossi muscles, while other similar nodes have been described in relation to the upper surface of the mylohyoid muscle.

The root of the tongue, that part situated behind the circumvallate papillæ, is derived from the same structures that form the pharynx, and its lymph streams drain directly into the upper deep cervical nodes of the corresponding side through a duct that pierces the wall of the pharynx behind the tonsil. There is little communication between the two halves of the tongue anteriorly, but in the root the anastomosis is free.

In a general way, disease of the tip of the tongue will cause enlargement of the submental nodes, while disease of the frenum might cause enlargement of the infrahyoid group. From the almost universal lack of evidence to the contrary, one might be led to believe that the intraoral nodes are not liable to become the seat of secondary deposits, but Mikulicz and KümmeI state that the nodes between the geniohyoglossi muscles are frequently involved and can be felt to be enlarged early in the disease.

Disease of the border will affect the submaxillary nodes, but when situated farther back, the superior deep cervicals will be first invaded. These divisions of territory are not absolute in their anatomical arrangement, and when one set of lymphatics becomes diseased, new channels through anastomosis are sought, so that eventually the spread of the disease is by devious routes. For these reasons, it is never safe to remove only a group of nodes, but all on one side of the neck; at least all of the deep and superficial cervicals and those that lie in front of them should be removed in every case. As all of the lymph streams from the tongue, with the exception of the single duct that goes to the subhyoid nodes, go directly or indirectly to the superior deep cervicals,

these latter are usually among the earliest to become palpable. For this reason, it has been customary to speak of the one enlarging at the level of the hyoid bone as the principal node of the tongue (Fig. 340).

When the disease is situated at the tip of the tongue, or on the root—that is, behind the circumvallate papillæ—or when the disease extends to the median line, then the lymphatics of both sides may be easily infected. In the later stages of the disease, the lymphatics of both sides are always infected, and the growth in the neck is often much more rapid than in the tongue. Rarely the nodes opposite to the site of the primary growth are first enlarged.

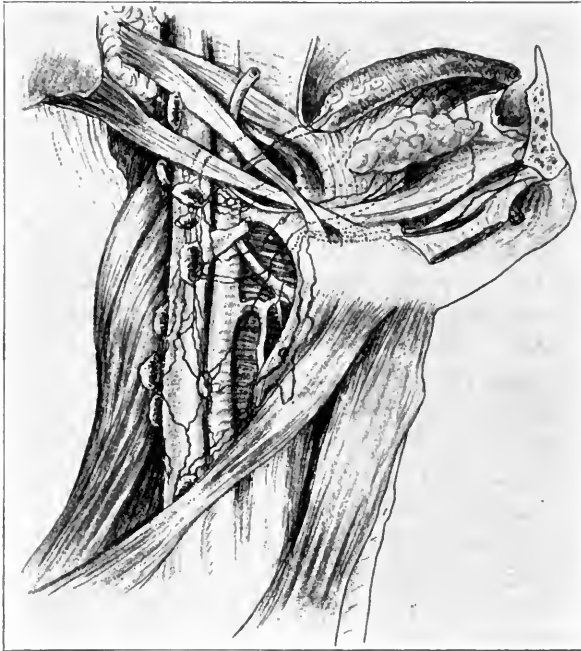


Fig. 340. Lymphatics of the tongue.—After Poirer.

The appearance of infected lymph nodes varies with the stage of infection. In the earliest stages the nodes may be so soft and small as not to be detected until their fascial coverings have been divided. The smaller nodes appear more numerous than ordinary, and the larger ones are soft and vascular. On opening such a gland, there may be seen one or several small, white points, or several small hemorrhages, which latter, according to Butlin, are a suspicious sign if the gland has not been roughly handled. Careful microscopical examination may show the invading epithelial cells or the beginning of epithelial pearls, but Butlin is of the opinion that the microscope may not be able to demon-

strate the epithelial cells in these earlier gland infections, even when the gross appearance is suggestive. We have made investigations that led to the same conclusion. In the more advanced lymphatic infections the typical appearances of cancer will be evident. The nodes will be enlarged and more or less filled with hard, white tissue that may cut like cartilage, and usually the glands will be seen to be adherent to neighboring tissue. Under the microscope the picture at this stage is unmistakable. Later, softening of the nodes or open ulceration will be found. In the neck carcinomatous ulcers are usually punched out or undermined.

**Clinical Types of the Mid-Period.**—In this intermediate stage the objective symptoms described are as a rule unmistakable, but the picture may vary greatly in different cases. These variations are due largely to the extent and direction of the growth, both locally and in the lymph nodes, and the rapidity with which ulceration destroys the new tissue.

Even in the more developed stages of some carcinomata, there may be only a papillomatous growth surrounded by an area of infiltration at the base, or, as occurred in one of our cases, a papilloma covered one fourth of the dorsum, but was indurated only in one small spot. In another form the most prominent feature may be an ulcer of irregular outline, surrounded by an everted edge made of irregular, hard, small tubercles, and with a hard, somewhat limited base and side walls. As in one illustrated by Butlin, the marginal hard border nodules may be replaced by elevated fleshy masses, the floor of the ulceration being occupied by a slough. The ulceration may be in the form of an oval, scooped-out gully with sloping sides, the base and sides being clean, glazed, bright red, free from granulations, and extending over the elevated edges, abruptly meeting the apparently normal mucous membrane in a regular smooth outline. In this stage the disease is apt to be absolutely painless. Instead of being a scooped-out groove, the ulceration may be in the form of a fissure, marked along its surface edges by a few irregular nodules, and extending deeply into the substance of the tongue. When the edges of such a fissure are pulled apart, the anterior is found to be lined by foul, ragged sloughs and to contain decomposing food particles. The depth of the fissure can only be determined with a probe, while the immobility of the tongue may suggest much deeper induration. This form is most frequently seen far back at the junction of the under surface of the body of the tongue with the floor of the mouth, and from the proximity of the trunk of the lingual nerve, may be extremely painful in its earliest stages. In the sclerosing cancer, which is of rare occurrence, the surface may be depressed and but little ulcerated, while the body of the

tongue is lessened in size, but contains a mass of board-like hardness. In these types, as in most all variations of the picture, the essential features of carcinoma are sufficiently evident to be recognized by the careful clinician. The tangible and visible evidence of lymphatic involvement varies greatly in different cases. There may be one or a few hard nodules above the bifurcation of the carotids, or the whole chain of one or both sides, including the submaxillary and submental nodes, may be involved. In the early stages these may not be evident.

**General Symptoms.**—As cancer in the tongue progresses, especially if situated farther back, difficulty of speaking and swallowing will develop. After any malignant growth has persisted for some time, it tells upon the general constitution and is evidenced by a feeling of malaise, loss of weight, and a peculiar yellowish color of the skin with the loss of all natural color. This is more pronounced in the late stages. With any advanced carcinoma of the mouth, the loss of weight and weakness are increased by the difficulty of taking food and the loss due to the salivation. Later in the disease, a foul discharge and worse odor are always present. Anyone who has ever attended a neglected cancer in its late stages is likely to remember the odor as probably the worst that may be associated with any disease.

### FINAL STAGE OF CARCINOMA OF THE TONGUE.

In the last stage of the disease all of the symptoms mentioned as belonging to the mid-period are intensified. The tumor extends more rapidly, and some other local structures—such as the floor of the mouth, jaw, fauces, pharynx, or palate—will have become involved. The tongue may be fixed in the floor of the mouth so that it cannot be protruded. The lymphatic involvement of the neck may be very extensive. Some of the nodes first involved may have broken down, involving the skin and causing induration and discoloration or craterous ulcers. Before the skin is involved, the breaking-down of the nodes themselves may be detected by the softening or fluctuation present. The pain, salivation, cancerous discharge, and stench all unite to make this one of the most terrible of diseases. The patient, exhausted by lack of sleep and food, by sepsis, and by the toxins that seem essential to the disease, loses weight rapidly and before death comes is usually but a poor remnant of his former self. If the growth has involved the glottis, tracheotomy may have to be performed to prevent suffocation.

**Death from Carcinoma of the Tongue.**—Like carcinoma of the lip, carcinoma of the tongue is almost essentially a local disease and, except by direct extension from the infected lymphatics, will seldom invade the tissues below the clavicle. There are comparatively few cases recorded where it has affected either the liver or the lungs.



These are estimated at about 1 per cent of all cases. Death comes usually from poisoning, starvation, and exhaustion, sometimes from a low form of pneumonia. It rarely comes directly as the result of hemorrhage, but repeated losses of blood no doubt often hasten the end.

### DIAGNOSIS.

The diagnosis is to be made from the symptoms enumerated and, at least in the very early and doubtful cases, by a microscopical examination. In the very early stage, chronicity developing induration, ulceration, or possibly pain, may arouse a suspicion of the nature of the disease; or the appearance of the lesion may be sufficiently typical to warrant a tentative diagnosis of cancer. A consideration of the age and sex, and probably the history of some previous chronic lesion that is known to predispose to the disease, may all bring affirmative evidence. Early in the second stage, induration, ulceration, and active growth will be present, as may be pain, salivation, or a discharge. Before the cancer becomes evidently beyond the scope of a radical operation, pain, salivation, discharge, odor, hemorrhage, and pronounced cachexia may one or all have disappeared, but none of them are as marked as they will be later in the disease. Though surgically extremely important, enlargement of the lymph nodes should be a point upon which the surgeon is not dependent for a diagnosis. When present, it is to be accepted, with the rest of the evidence, but the chances of cure by operation are much greater if the growth is recognized and removed before palpable enlargement of the nodes occurs. As a contributory evidence of this, a series of Butlin's cases may be cited:

Fifty-six cases in which the results are known, and in which the glands were removed, were selected for a basis. In one of these cases the submaxillary gland was not removed, and this cannot be counted as a radical gland operation. The series is therefore reduced to fifty-five cases. In thirty-four of these, glands were enlarged, but in the majority of cases not demonstratively cancerous at the time of operation. Seven of these patients died of recurrence in the neck, and eleven were cured. Of twenty-one cases in which the glands were not enlarged at the time of operation, none died of recurrence in the glands, and thirteen were cured on a three-year basis. Reduced to percentages, the results of the two series are as follows: When the glands were enlarged, 20.6 per cent neck recurrences and 32.35 per cent cures on a three-year basis; while in the series where glands were not enlarged, there were no neck recurrences and 61.9 per cent cures. These figures should be a sufficient argument against requiring glandular enlargement as an essential to the diagnosis. Mikulicz and Küm-

mel go so far as to state that the disease is not permanently curable when the nodes become palpable.

**Differential Diagnosis.**—Warty growths, simple ulcers and fissures, tubercular infiltrations or ulcers, primary and tertiary syphilitic lesions, and other granulomata may all bear a close resemblance to carcinoma. From our anxiety to make an early diagnosis, these resemblances may be annoying or misleading. There is never any real excuse for being seriously misled by a chancre. Its rapid growth and the early enlargement of the lymph nodes should excite suspicion. The presence of the spirochætæ is easily demonstrated, and if seen after the first few weeks, the secondary lesions will probably settle the question. Noguchi claims that it is impossible to differentiate microscopically, with either dark stage or stained specimens, between *Spirochæta pallida* and *Spirochæta microdentium*, and that the diagnosis between these two can be made only by culture, microdentium culture giving an odor and pallida none. Unbroken gumma or the ulcer remaining after the breaking-down of a gumma may present more serious difficulties. As described by Butlin, in their early stages an unbroken gumma and a deep carcinoma may have the following points in common: slow development; an ill-defined outline not separable from the tissues of the tongue; both diseases prone to occur in the dorsum of the tongue, and in men over thirty. They may differ in the following points: gummata are often multiple; carcinomata rarely so. Intra-oral tertiary syphilitic lesions rarely occur by themselves, there usually being other marks of the disease in other parts of the body, but there is nothing to preclude a carcinoma from developing in a syphilitic or from an old syphilitic scar. The difficulty in differentiating between the two may be so great as to be settled only by time, or a microscopical examination. Time spent in watching an early carcinoma is valuable time wasted, and if the diagnosis cannot be made, it should be treated as a carcinoma.

Almost the same difficulties may arise in distinguishing between an ulcerating gumma and a carcinoma. Gummatous ulcers are most frequently met with on the dorsum; while deeply ulcerating early carcinomata are most frequent upon the borders. The edges of a gummatous ulcer are usually undermined; while on the tongue the borders of a cancer are never undermined, and are indurated to a much greater extent than those of a gummatous ulcer. The floor of a carcinomatous ulcer is covered by a slough or granulations that bleed when disturbed; while the floor of a gummatous ulcer may contain a tough laminated membrane that can be peeled off in pieces with little bleeding. Carcinoma is always more likely to bleed than is an open gumma, and in the former pain is a more common symptom. Gummatous ulcers are often

multiple; cancer almost never so. After a cancerous ulcer has persisted for some time, the glands will become enlarged, which does not occur with gumma.

The common practice of making a differential diagnosis by means of the therapeutic test is open to two serious objections: the most important is the time lost in the presence of carcinoma; and the other, that after a severe course of mercury and iodid the mucous membrane of the mouth becomes more or less inflamed, and the patient is depressed and less resistant to infection. If in this condition an operation is done, the risks are increased.

The serum tests are not open to the latter objection, and where the means are available, Wassermann, Noguchi, and luetin tests may be applied in doubtful cases. Even if these tests are positive or negative, the information is not so reliable as is that derived from a properly made microscopical examination. These tests may not invariably be positive in the presence of tertiary lesions, and it is possible that the reaction may occur in other disease than lues. Even if positive, they do not preclude cancer, and some late observations suggest that cancer is one of the diseases that may cause a positive Wassermann reaction. With reference to the therapeutic test Butlin states:

“The reason that leads us to speak so strongly of the microscopic examination is that we have seen many cases in which carcinomatous ulcers have been treated as syphilitic ulcers by some of the best clinical surgeons in London, not because they felt sure the disease was syphilitic, but because they could not feel sure whether it was cancerous or syphilitic. Weeks were allowed to elapse in this manner until the ulcer had clearly shown that it was not in the least affected by anti-syphilitic treatment, and perhaps had implicated the lymphatic glands. The period at which it should have been removed was allowed to pass, and the operation was undertaken when the prospect of ultimate success was exceedingly small and when the patient was weakened by large doses of iodid of potassium, and in one case by mercurial salivation.”

Head cites a case, exhibited by H. Burt, in which a young woman, twenty-four years of age, had a cancer of the tongue which shrank materially under the use of iodid, only to later grow rapidly while under the same treatment. He calls attention to the fact that iodids may cause, for a time, a prompt reduction of a malignant growth.

The diagnosis between tubercle and carcinoma is even more difficult. But primary tuberculous ulcers of the tongue are rare; and even when secondary ulcers closely simulate carcinoma, the presence of the primary lesions, usually in the respiratory passage and lungs, should suggest the probability of the same disease in the mouth. Even here,

the conclusion cannot be certain, for tuberculous infection in the lung does not preclude carcinoma of the mouth. Here, again, the microscope can be a most helpful agent, but only when used by one of great experience.

Between a simple papilloma and a carcinoma the diagnosis should be made by the microscope. The papilloma should always be removed. If the wart arises in a patch of leucoplakia or chronic glossitis, it may be regarded as carcinoma. Between simple ulcers and carcinoma the diagnosis is often difficult. This is made more so by the knowledge that carcinoma can develop in a simple ulcer. The persistence or spreading of the ulcer and induration after removal of the apparent cause should be regarded as very suspicious.

Chronic abscess may be mistaken for deep carcinoma. In a case referred to on page 341, it was only after a microscopical examination had been made of the wall of the abscess that we believed that we had not to deal with a broken-down carcinoma. The wall of the abscess was of such hardness that it appeared typical of cancer, though the location was unusual for the latter disease.

Butlin remarks: "Until the last few years it was almost universal in the profession to regard a carcinomatous ulcer as probably and then possibly an ulcer of some other kind until it was clearly proven to be carcinoma by unmistakable signs. Yet even among 'men of experience' there was a fatal tendency to do what is commonly termed 'give the patient a chance' by treating the disease on the assumption that it was syphilitic or simple. Gradually medical men are coming around to the belief that 'to give the patient a chance' means under such circumstances to '*give the carcinoma a chance of obtaining a firm hold and to take all chances of complete recovery from the patient.*'"

**Microscopical Diagnosis.**—If we are to cure a large percentage of cancers, it is to be done, according to our present state of knowledge, only by operations done at a time when from clinical signs alone the diagnosis will in most cases be still a matter of some doubt. To give us the courage to do a sufficiently radical operation, there is no help like microscopical findings. Unfortunately this means of diagnosing early carcinoma of the tongue, which ought to be employed in every doubtful case, has been greatly discredited. While there is no doubt that in many instances the surgeon has been led astray, this does not mean that there are not men whose training and technic make them competent to render an opinion that at least will not be misleading. It has been our good fortune to have had extremely satisfactory results from the men upon whom we have learned to rely.

The most confusing thing about the histologic appearance of some carcinomata is the overwhelming infiltration of round cells that may

partially destroy and completely obscure the invading epithelial cells. On account of this, malignant disease has been mistaken for innocent ulceration, but repeated examinations of several sections from one or several carefully selected specimens that include a part of the apparently healthy neighboring tissue will most likely reveal cell nests or columns of invading epithelial cells, if they are present. There are normally occasional apparent cell nests in the mucous membrane, but these will not mislead an experienced pathological microscopist. When doubt exists as to the microscopical findings, the surgeon has still the clinical data to guide him, which, if carefully studied, will rarely be negative or misleading, except in the very earliest cases; and these being small had best be removed if there is any doubt of their character.

The differentiation between tubercle and epithelioma may be still more difficult, but there are special tests that may confirm and exclude tubercle; the distinction is not of so great importance as with other inflammatory growths, as the treatment of carcinoma and tuberculosis of the mouth is almost essentially the same (see page 300).

#### **DIFFERENTIATION BETWEEN OPERABLE AND NON-OPERABLE CARCINOMATA.**

The diagnosis of cancer in the third stage presents few difficulties unless it be confounded with tubercle, syphilis, or mycosis. To determine whether an advanced carcinoma is operable or inoperable is often quite another matter and must be decided by good judgment and nice observation, rather than by any special rule of thumb. Although it is not uncommon to hear good observers remark upon the fact that carcinoma usually extends farther than the external appearance indicates and that when there is any doubt that the case is operable it is almost certain to be inoperable, still, if there is any reasonable doubt of its not having gone beyond the surgeon's reach, if the patient is willing, and if his general condition warrants it, he should be given the benefit of the doubt, and the operation should be performed.

The virulency of the growth has much to do with the prognosis, and this varies. As evidence that an advanced case may not be hopeless, we may cite a case of Butlin's operated on in 1903, in which at operation he found a mass of glands in the neck that he considered irremovable. Later he "summoned up" his courage and again attacked this mass of glands, which were removed with great difficulty. In 1908, he received word from the family physician that the patient was perfectly well.

There are three factors to be taken into consideration in determining the operability of a case: the extent of the disease; the condition of the patient in reference to the probability of being able to withstand the effects of one or several extensive operations; and the experience

and ability of the surgeon. If the local growth is confined to the tongue, it is always to be considered operable unless the tissues of the neck are involved well outside the lymph nodes. If it has involved the floor of the mouth on one side and even the jaw, or has extended to the wall of the pharynx or palate, the case may still be curable; but the risk from the operation is greatly increased, and the chances of success are small. If in a pharyngeal or faucial involvement the finger can be passed well beyond the posterior limit of a growth that is movable upon the deeper structures, its removal may still be undertaken with a faint hope of ultimate success. In order to make this examination, it may be necessary to paint or spray the velum, fauces, and pharyngeal wall with a 5 per cent solution of novocain. Before deciding that a patient who has suffered from pain, and lack of sleep and food, is too weak for operation, it should be determined what a few days of rest, freedom from pain, and proper treatment will do for him. A patient who has been reduced by repeated hemorrhages may sometimes be greatly helped by a blood transfusion.

While a patient who dies as a result of the operation may be considered better off than he who lingers through the terminal stages of a carcinoma of the mouth, no one may undertake a radical operation on a case that he knows to be hopeless. Besides not having the right to subject a patient to useless danger, there is the important consideration that every death after operation is a discredit to our surgery, and is liable to deter some other patient from the benefits of a necessary operation.

If the attempt at local removal is a failure, and the disease returns *in situ*, in a few weeks or months, then the patient is even worse off, and as Childe remarks, "it's better to let him die once than twice." Even local removals should not be attempted when they offer no hope of local eradication. But if the primary growth can be removed, much is gained by the patient, for the cervical growth is easier to care for and gives less discomfort than the intraoral ulcer. Crile's radical operation on the lymph nodes and their surrounding tissues greatly lessens the number of lymphatic recurrences.

#### PROGNOSIS OF CARCINOMA OF THE TONGUE.

When unoperated upon, the certain result is death, and in a distressing form. The average duration of life with an unoperated carcinoma of the tongue is placed by Butlin and von Bergmann at about one year. DaCosta extends the limit to a possible two years, while very young, or greatly debilitated, subjects may survive but a few months. Even with careful and extremely radical operations, the ultimate prognosis of the majority of cases that show all of the typical symptoms is little better. For cancer operated on in the early stages

—that is, before they assume the classic picture which in the past has been too frequently demanded for a diagnosis—the prognosis is very different.

**Results of Operation.**—The so-called cures are cases that live three years without recurrence. The length of time these patients will survive after three years varies, but it is a noticeable fact that after three years recurrences are comparatively few.

Butlin's final results are based on 200 cases. Of these, 32 are not counted—the operation was abandoned, the patient was lost sight of, the operation was too recent, or the patient had died of some other disease within the three years. Including the operative deaths, but excluding unoperated, recent, and untraceable cases, out of 168 cases, there were 57 recoveries traced for periods varying from three to twenty-two years without recurrence, which is 33.92 per cent cures, with an operative mortality of 10 per cent. Possibly one or two cases supposed to have died of other causes might have been affected by distant metastasis, but this would not greatly affect the general result. In many of the 200 cases the lymph nodes were not removed, and in a number of the earlier cases the lymphatic removal was very limited. In the second half of this series the results are still better. In 99 cases out of the first 197, there were 22 cases not counted, because too recent, the patient was lost sight of, the operation was not completed, or was only palliative. Of the 77 remaining cases, 32 were successful, which gives 41.55 per cent of cures in cases subjected to a radical operation and traced for over three years. Warren places cures at 17.5 per cent. Dollinger, of Buda Pesth, stated before the Second Brussels Congress that of 23 cases of cancer of the tongue 69 per cent died within the first year and not one survived three years; and the result given to Butlin by a prominent Australian surgeon made little better showing. Many more statistics could be quoted, but they would fall between these extremes. The prognosis of cases operated on for recurrence is very bad, but occasionally one has been cured.

### **TREATMENT OF CARCINOMA OF THE TONGUE.**

The treatment of any operable case of cancer is its entire removal locally, and removal of the infected lymph areas. The burning-out of a cancer of the tongue is to be condemned, both on account of the fact that it cannot destroy cells in the deeper tissues and because the resulting scar is of the kind that predisposes to the formation of cancer. Of the use of the x-ray, various reports have been given, but we must not be blinded by the reports made by enthusiasts before sufficient time has elapsed to allow of final judgment. The opinion of most surgeons is that while the x-ray will destroy cancer cells on the surface its penetration is not sufficient. Radium will also destroy surface

growths, but is open to the same objections as is the x-ray. Surface epitheliomata have been destroyed by x-ray, by radium, and by purely local excision, but these successes should not deter us, when we are allowed to choose, from the practice that is known to give the best chance to the greatest number.

The extent to which the operation is to be carried is always a difficult question to decide, and is often complicated by the general condition of the patient. On the one hand, the surgeon knows that he is dealing with a disease that must be entirely removed, and which in many instances is limited to the mouth and certain tissues of the neck that are perfectly accessible to dissections. On the other hand, the patient is often enfeebled by dissipation, age, or cachexia, possibly all three, and is not an ideal subject for a prolonged operation. The mouth is a septic cavity. By making extensive wounds that expose the great vessels and deep facial planes of the neck which communicate with the mouth by operative wound or through the efferent lymph ducts, one adds the risk of sepsis to that of operative shock. Hemorrhage is a serious consideration, not only on account of the direct effects of the loss of blood, but hemorrhage within the mouth obscures the operative field and increases the risk of aspiration into the trachea. Finally, any operative interference with the floor of the mouth and the posterior part of the tongue is apt to be followed by a low form of septic pneumonia, which is the most frequent form of operative death.

The loss of the tongue itself, especially if only two thirds or a lateral half is removed, is not so serious a deformity as one would at first imagine. If the patient survives the first few days, he can swallow liquids. Even where the amputation extended to within 1 centimeter of the epiglottis, we have seen a patient take fluids and make partially intelligible attempts at speech within a day after operation. With a fair-sized stump remaining, speech is surprisingly good.

When a surgeon is confronted with a supposedly operative case of carcinoma of the tongue, he at once meets these very serious questions: how far is it necessary for him to go in his attempt to remove the disease, and how best can he do this with least risk to life? Very often the question reduces itself into not how far he should go, but how far can he go without assuming risks that are unwarranted even in dealing with carcinoma. The answers proposed to these questions by surgeons of large observation and experience in this special line are often somewhat divergent. One of less experience is left with the alternative of studying the methods, teachings, and results of one school, better still of one man, or of attempting to analyze and to profit by the experience of many and steer his course accordingly. The latter is a very large order, and he who attempts it must beware, lest between two stools he



fall, which is most likely to happen if he attempts to follow the more radical teachings of some men without having either their skill or their clinical experience, or if he undertakes to mix technical methods without having thoroughly mastered the motifs and problems of each. The following are some of the questions that will arise with every case:

(a) **WHEN SHOULD THE OPERATION BE DONE?**—This should be as early as possible, but in cases where the mouth is septic and those in which the patient is in a poor physical condition, a few days may be well spent in preparation.

(b) **THE EXTENT OF THE LOCAL EXCISION?**—Heidenhain maintains that a bilateral excision should be made in every case, but Butlin has denounced this practice strongly; and both he and Kocher are content to make the excision 2 centimeters beyond the evident involvement. Warren advocated an inch, and he believes that for want of free removal most recurrences are local. These directions refer to the muscular tissue of the tongue and the muscle sheaths. Carcinoma of the tongue does not spread so rapidly in the mucous membrane and extra muscular cellular tissue as it does in the substance of the muscles, and tends especially to spread along the length of an affected muscle. It tends to spread more rapidly toward the base than toward the tip, and in front of the vallate papillæ does not readily cross the median septum. These points should be considered in planning the excision. It would seldom be practical to make a block excision including all tissues for a distance of 2 centimeters or an inch beyond the growth. Kocher makes his incision in the mucous membrane of the floor, 1 centimeter beyond the growth.

Mr. Lenthal Cheate, who has been carrying on the research for several years, has found in microscopical sections of the muscles, at a considerable distance from the primary disease, columns of cancer cells lying between the fibers of the muscles, that look quite healthy to the naked eye. He therefore recommends that the hyoglossus and geniohyoglossus and the inferior lingualis muscle should be removed in every early case of cancer of one half of the tongue, even if the primary disease is quite small and in an early stage of existence.

Butlin, however, believes that his observations warrant the opinion that, with the possible exception of cases where a preoperative microscopical examination of the tissues shows the growth to be of unusual malignancy, and of those cases where the primary growth is very extensive, a block excision, which includes the whole of one or both geniohyoglossi muscles and extends three quarters of an inch beyond the evident growth, is the proper routine practice.

In 102 out of 200 cases, the patient either died of recurrence at some other site, or was alive and well after three years without re-

currence in the mouth scar. Of 33 cases in which recurrence is known to have taken place in the mouth scar, the growth was extensive in most of them at the time of operation, and in only three did he feel that a more extensive local excision would have given better promise.

(c) THE CHARACTER OF THE LOCAL OPERATION?—Butlin prefers the intraoral operation. This is done through the mouth, with or without splitting the cheek. In all cases in which the jaw-bone is not directly involved, the low operative mortality is a very strong argument in its favor. Kocher considers that, for the intraoral operation to be appropriate, the tumor must be freely movable on the jaws and floor of the mouth, and must be so placed that, after the application of toothed compression forceps to the body of the tongue behind the growth, there will be room enough to make the excision in front of the forceps. If the growth extends back to the faucial pillars, he performs his "normal excision," which includes splitting the jaw-bone and floor of the mouth in the median line (see page 501). For complete excision of the tongue, Kocher uses the operation, which he has described as excision of the tongue at its root (see page 502). Carcinoma of the base of the tongue may be removed through a transverse suprahyoid incision, but when the jaw is directly involved, a section of the bone must be removed as part of the block excision.

An idea of the relative mortality of these various operations may be gained from the following figures: In 101 cases operated on by the oral route, Whitehead had 3 per cent postoperative deaths; but in 38 complicated cases, he had 17 deaths, a death rate of 44.73 per cent. Butlin does not state specifically just how many of his cases were operated on by the intraoral route, but from his teachings it is fair to surmise that the majority were. In the last 102 of his 200 cases, there were 9 deaths resulting from operation, which is 8.82 per cent. In the 200 cases, there were 20 operative deaths, or 10 per cent. While the first mentioned series shows little improvement in the death rate, here the average operation was more extensive than in the earlier cases. The causes of death in the 20 cases are as follows:

Died suddenly during operation.....	1
Sepsis of wound.....	1
Septic pneumonia.....	10
Subsequent hemorrhage.....	3
Shock .....	2
Suffocation (sudden a week after operation).....	1
Heart failure some days after operation, feeble patient, 77 years old.....	1
Acute mania (without sepsis).....	1

20 cases

In a series of 62 cases operated on by Kocher, between 1890 and 1893, 23 were operated on through the mouth, with or without splitting the cheek; of these one died, a mortality of 4.34 per cent. Seven were complete excision from the root; of these one died.

In 29 cases reported by Warren, operated from below the jaw, there were 3 deaths, or 10.3 per cent. Butlin estimates the mortality of this operation, from 62 collected cases, as 20 per cent.

Of 23 cases of Kocher's in which the jaw and floor of the mouth were split in the median line, 4 died, a mortality of 17.39 per cent. While in 4 cases it was split laterally and in 3 a piece of the bone was excised; of these 7 cases 2 died.

In 13 operations, reported by Warren, in which the jaw was divided, there was a mortality of 30.7 per cent. Sachs gives the mortality of this operation in Kocher's clinic as 19 per cent, while Butlin places it at 25 per cent.

Loison places the death rate of simple operations at 10.7 per cent, while of the more complicated ones at 23 per cent.

Of course the choice of method does not always rest with the operator, but it will be seen from these figures that where the operation is performed within the mouth the postoperative death rate is remarkably low in comparison with those cases in which the bone is divided.

(d) SHOULD THE LYMPHATICS OF THE NECK BE REMOVED IN EVERY CASE?—This question will not arise in connection with cases where the lymph nodes are palpably enlarged, unless the disease is apparently hopelessly advanced. With the very early cases, however, believing that for an uncertain time the lymph nodes may be immune, one might hesitate to subject the patient to an extra operation, unless it could be shown that the chances for cure are thereby materially increased. Certain series of published cases might at first lead one to think that this is not a wise routine procedure. In a series of 18 early cases, cited by Butlin, there were 8 cures. In 6 of the 8 cured cases, the glands were not removed. Warren reports a similar series. Out of 19 very early cases, he had 8 cures, and in only one of the 8 cured cases were the glands removed. These cures are figured on a three-year basis. Butlin reports one case, in which infection of the unremoved glands became evident three and one half years after a successful mouth operation. In neither of these series is the number of cases stated in which the glands were removed, nor the condition of the glands at the time of operation. Therefore the only conclusion that can be drawn from them is that certain early cases will remain free of glandular recurrence, for three years, even when the glands are not removed.

In the following data, worked out from Butlin's full reports, an attempt had been made to get some basis for comparing the per-

centage of glandular recurrences, with and without their removal. In a series of 44 cases in which the glands were not removed, in 5 the glands were enlarged at the time of operation, 6 died of operation, 8 died of recurrence in the mouth, and 3 other cases were not tabulated, making a total of 22 cases not appropriate for our present purpose. In the 22 remaining cases in which the glands were not removed, they were not palpable at time of operation; the patients survived operation, were traced afterward, and had no mouth recurrence. Of these 22 patients, 10 died of glandular recurrence, which is 45.45 per cent.

In a series of 70 cases, in each of which the contents of the anterior triangle were removed, 6 died of operation, 1 was lost sight of, 10 died of recurrence in the mouth, 7 died of recurrence, site unknown, and 12 others were not tabulated—a total of 36 cases not to be included. Of the remaining 34 cases which survived operation without mouth recurrence and which were traceable, but 8 died of glandular recurrence of the same side and 2 of the opposite side. This gives neck recurrences after glandular removal as 27.77 per cent against 45.45 per cent recurrences where the lymph nodes were not removed and were apparently not enlarged. While the number of cases available is small, the figures are at least suggestive, and an extremely significant fact is the following: Out of the 34 cases selected from the series of 70 in which the glands of the anterior triangle of one side were removed, 8 are known to have died of glandular recurrence of the same side, but 7 of these 8 cases had enlarged glands at the time of operation; and in the remaining case the operation was incomplete, inasmuch as the submaxillary salivary gland was not removed and the recurrence was at this site. Subtracting the 7 cases in which the glands are stated to have been enlarged at time of operation, and the one in which the operation was incomplete, we have remaining 26 cases where the anterior triangle was cleaned out, in whom the results are definitely known, and in whom there was no mouth recurrence. Of these 26 cases, 24 remained well, and 2 died of recurrence in the nodes of the opposite side. Not one of the 26 cases died of recurrence in the side of the neck from which the nodes were removed. Compare this with the 22 selected cases, previously cited, in which the glands were not removed, but in none of which were they palpable at the time of the operation on the tongue. In this series 10 died of recurrence in the neck. Although to say that glands are not palpable when the neck is not opened does not say they were not enlarged, still we think this can be taken as fair argument for the removal of the glands in every early case. Butlin wrote, in a very recent personal communication: "It seems as if it were hard lines on those people to induce them to undergo operation which may not be necessary, because

half of them, or more, would suffer from glandular disease without the operation. But the trend of surgical opinion has been for many years in favor of doing too much rather than too little and of removing those parts and structures which are very liable to become diseased, although there is no certainty that they will become diseased. Certainly, I would have my glands removed if I had cancer of the tongue." Mikulicz and Kümmel believe that the nodes of one or both sides should be removed in every instance, except when the growth is located upon the extreme tip of the tongue. Just why the exception is made in the latter situation, we are not able to determine.

(e) IS IT NECESSARY TO REMOVE PRIMARY GROWTH AND THE LYMPHATIC AREAS IN ONE MASS, AS IS DONE WITH CARCINOMA OF THE BREAST?—Butlin answers this question in the negative. He states that he has rarely removed the primary growth and the lymphatics in one continuous mass; yet in only two of his cases could it be reasonably concluded that recurrence was due to affection of the tissues that were left behind between the primary disease and the glands. The excision of the tumor, the floor, and the glands in one mass precludes doing a two-step operation, which latter greatly lessens the operative mortality. It is only in his "excision at the root" that Kocher attacks the glands and primary tumor at the same operation.

(f) TO WHAT EXTENT SHOULD THE LYMPH NODES BE REMOVED?—Whatever operation is done on the neck, the lymph nodes, lymphatic vessels, and the tissues that carried them should be removed in one mass, from the floor of the mouth down. Although there are a few instances where recoveries have occurred after the removal of single or several enlarged nodes, it is possible that in these instances the enlargement was due to other causes than infection with cancer. There is reason to believe that the lymphatics in their normal condition can, to a limited extent, destroy cancer cells, as they do other infections, but it is well known that tissues that are injured by trauma are less resistant to infections than are those that are healthy. Even if all of the diseased glands could be removed by dissecting them out individually, which is practically a surgical impossibility, still this would not deal with the cells that might be yet within the lymph ducts. It is conceded that, if the lymph nodes are to be removed for any disease, they should be taken out *en masse* with the lymphatic ducts and the tissue that supports them. If the removal is for carcinoma, even more radical removals seem to be productive of better ultimate results. Butlin is content in most cases, at least those supposedly early cases in which palpable enlargement of the lymph nodes has not occurred, to remove the contents of the anterior triangle, which include the superficial and deep, submental and submaxillary nodes, the submaxillary

salivary gland, the lower facial nodes, the lower parotid nodes, the deep and superficial cervical nodes, and the infrahyoid nodes that lie near the omohyoid muscle. This he does very thoroughly. This is also the procedure recommended by Kocher. Of late, more radical measures have been advocated.

Maitland advocates the removal of the sternomastoid and the clearing out of both the anterior and posterior triangles, with or without the removal of the internal jugular vein, as circumstances indicate.

Crile has applied the methods now sanctioned in regard to carcinoma of the breast and removes all of the lymph nodes, the internal jugular vein, and the sternomastoid in one block. In fact, he has shown that all structures in one side of the neck, including the vagus and hypoglossal nerves, with the exception of the carotid artery, can be removed with comparative safety.

(g) SHOULD THE LYMPH NODES OF BOTH SIDES OF THE NECK BE REMOVED?—If the carcinoma is bilateral, or situated on the base, there is no doubt that the lymphatics of both sides should be removed. Although it occasionally happens that early infection of the opposite lymphatics results from a laterally situated growth of the body, Butlin's statistics show that this happens so seldom as to hardly warrant the bilateral excision as a routine procedure, but if not counterbalanced by the increased operative risk, it would save some patients. In 200 cases of Butlin's the lymph nodes were palpably affected on both sides in 9 instances. In 6 of these the cancer occupied both sides of the tongue. In 3 of the 200 cases, the nodes of the opposite side were involved. In 2 of the 3 cases, the nodes were removed from the neck on the opposite side of the primary growth only, and both of these cases were well a number of years after the operation. In 2 cases the nodes on the opposite side became enlarged after an otherwise successful operation on the tongue and one side of the neck. If the lymphatic involvement on one side is sufficiently advanced to warrant one of the more radical operations that includes the removal of the internal jugular vein, it seems to us that under these circumstances it would be wise to do a simpler operation on the other side within a few days. Daugel removed both internal jugular veins in one patient, at one operation, with recovery; but this is a result that cannot be expected to be repeated often.

(h) SHOULD THE PRIMARY TUMOR AND THE LYMPH NODES BE REMOVED AT THE SAME OR AT A SEPARATE OPERATION?—In 22 of Butlin's cases in which the lymph nodes and the primary tumor were removed at a single sitting, there were 4 operative deaths. In 47 cases in which the lymph nodes were removed a few days previous to, or a few days after, the operation on the tongue, there was 1 death

due to operation, which gives a death rate of 18.18 per cent for the single operation, and 2.12 per cent for cases that were operated in two stages.

Butlin gives the series of two-stage operations as consisting of 48 cases with 2 deaths, but explains in a note that in one case the tongue was reoperated on at the time the glands were removed, for fear, the primary operation not being sufficiently extensive, the entire neck wound might become septic. This cannot be considered a two-step operation in the sense that we here take it, and we therefore exclude this case.

Warren suggests that the two-step operation may represent but a stage in the development of the surgery of carcinoma of the mouth, and that later, by improved methods, a continuous operation may be performed with comparative safety.

If we grant the present advisability of a two- or three-step operation, we are brought to the question:

(i) SHALL THE REMOVAL OF THE PRIMARY GROWTH OR THE LYMPHATICS BE DONE FIRST?—We have always been impressed with the idea that even if cancer-producing cells do not lodge in the lymph ducts they must require some time for their passage from the primary growth to the nodes. Therefore, on these theoretical grounds, we believe that, if the glands, intermediate tissue, and primary growth are not removed in one mass, the removal of the primary growth should precede the lymphatic removal by some days, and that the lymphatic operation should not precede the removal of the primary growth. This view does not seem to be shared by men of large experience, but we have lately seen one case where the neck wound became extensively infected with carcinoma, where a block gland dissection was made without removal of a cancer in the mouth. In certain instances, there are strong reasons for doing the neck operation first. After active growth has once started within the lymph nodes, it proceeds at a much more rapid rate than the cancer of the tongue or lip, and it is believed under these conditions to be good surgery to do the glands first, if the whole operation cannot be carried out at one sitting. If the operation upon the tongue includes the removal of the lower part of the hyoglossus muscle, then the mouth cavity will be opened at the neck operation, which increases the chance of infection and necessitates leaving the upper part of the neck open to avoid filling the wound with food and mouth secretions. Another argument that has been advanced for a primary neck operation is that, if the mouth operation is performed first, the neck wound is liable to become infected through the lymph ducts. If the mouth wound is properly cared for, this will be avoided, and it seems to us that this is somewhat of an acknowledg-

ment of our first contention. If the neck can become infected with sepsis from the mouth wound, why not from carcinoma, if the latter is still in place? Under ordinary circumstances it is the custom of most surgeons who advocate a two-step operation to do the intraoral one first. Butlin usually operates upon the glands as soon as the patient begins to take food well and has somewhat recovered from the first operation—about ten days.

The primary removal of the lymphatics has been advocated for two other reasons: (1) that at the time of the first operation the lingual and facial arteries can be conveniently tied, as a preliminary to the tongue operation; (2) that, if the neck is operated on first, the patient is less likely to back out of the second operation. Although a preliminary ligation of the lingual artery gives an almost bloodless operation, was advocated by Billroth and Treves, and is still utilized by Kocher and other surgeons when for any reason the first operation is done upon the neck, still it is not generally considered a necessary routine procedure; and in the operations to be described, hemorrhage is always controllable. The second point is of some value, as it not infrequently happens that a patient who has no evident disease in the neck becomes unwilling to undergo a second operation after having experienced the first. Butlin meets this difficulty by not stating that there will be two operations, but informs the friends that he will begin the operation on such a day and finish it nine or ten days later.

(j) SHOULD EXCISION OF THE TONGUE BE PRECEDED BY LARYNGOTOMY?—At present most operators seem to prefer depending on the position of the patient to prevent the aspiration of blood during the operation—Kocher is among these. Crile uses his nasal anesthesia tubes with packing of the pharynx, but this procedure is hardly applicable if the excision is to extend behind the attachment of the anterior faucial pillar. Whitehead advocated preliminary laryngotomy as a routine procedure, and Butlin, since 1900, has made it his routine practice. The Trendelenburg expanding cannula is not popular. It is one of the things that is not apt to be on hand when desired, and apt to be out of order if on hand. Besides, it may cause reflex nerve irritation when in place, or be followed by local injury of the tracheal mucous membrane. A simple laryngeal tube can be quickly inserted, and after spraying with a 5 per cent novocain solution, the pharynx can be packed with gauze. If the tracheal tube is arranged so that a rubber tube can be attached to its external opening, a gas-oxygen anesthesia may be given, which is here a great advantage. Final judgment has not been passed upon tracheal insufflation, but it is possible that it may supplant all other methods.



## OPERATION FOR THE REMOVAL OF THE TONGUE.

While in the presence of malignant disease, time is precious, and the operation should be done as soon as possible; still some local or general preparation may be indicated, the carrying out of which will materially lessen the operative risk.

**Local Preparation.**—It is not always possible to get the mouth in very good condition, because the local tenderness may preclude extensive manipulations and it is not desirable to give a general anesthetic for this purpose. The teeth should be cleansed thoroughly several times a day—if possible, with a brush. If in bad condition, the tartar might be scraped off, loose and carious teeth removed, and pus-pockets treated with tincture of iodine.

Butlin recommends that when possible the mouth should be repeatedly wiped out, especially the pockets, with soft pledgets of cotton wool or bits of marine sponge soaked in a bichlorid or bichlorid of mercury solution, 1:1000. Also, over the vascular granulations, the same solution may be painted with a camel's hair brush, but if the growth is covered with hard nodular epithelium, it will do no harm to rub it with a soft sponge and clear all the fur and débris out of the sulci. In doing this, no free fluid should be allowed to run into the mouth, and the patient should rinse the mouth immediately afterward. The mouth should be rinsed frequently with a  $\frac{1}{2}$  per cent solution of potassium permanganate, especially after eating. Very foul sloughy surfaces may be cocaineized and then painted with a 10 per cent solution of formalin or rubbed with lunar caustic. The nasal passages and nasopharynx may be douched with alkaline antiseptic solution (N. F.), one to three of water, and Kocher recommends that suppurating crypts in the tonsils should be cleaned out. These local preparations certainly lessen the liability to sepsis and should be carried out as completely as practicable. The oozing of blood from the growth may be controlled by some chemical styptic, the cautery at a very dull-red heat, or by ligating the lingual artery.

Some operators precede a lingual amputation, and in fact any serious mouth operation, by a preliminary injection of polyvalent streptococcus antitoxin. We do not believe that anyone can as yet show a series of cases sufficiently large to serve as a basis for conclusions.

**General Preparation.**—Many patients with very early growths need no special general preparation. Those who are weak from pain, loss of sleep, lack of food, and from hemorrhage may be improved by a few days of special treatment, possibly a blood transfusion in extreme cases of debility.

**Position on the Table.**—The semisitting position, recommended by Whitehead, gives the best view, and if the patient is not too deeply anesthetized, this will not be accompanied by the aspiration of blood. The Trendelenburg position is supposed to guard against aspiration, but it has not always served us well in mouth operations. Butlin states that formerly he used the Whitehead position, but now always places the patient on his side. "The patient is placed upon his side with his head a little forward and downward, so that the blood runs naturally into the cheek and out of the mouth." If the table is made to slope a little downward, toward the head-end, the advantages of the Trendelenburg and lateral positions are combined. This we have found very serviceable.

**Anesthetic.**—A general anesthetic should be used, and we almost invariably use ether, unless it be oxygen and nitrous oxid, which may be conveniently administered through the laryngotomy tube or Crile's nasal tubes. The latter are only of service when the operation is confined to the anterior part of the tongue.

### INTRAORAL OPERATION.

In the more extensive of the intraoral lingual operations, especially those that extend to or through the faucial pillars, the work is much facilitated by splitting the cheek straight back from the corner of the mouth to the anterior border of the masseter muscle. This incision passes below the parotid duct and above the mandibular division of the seventh nerve, and when properly repaired, gives a scarcely noticeable deformity. This was first advocated by Roser, is sometimes used by Butlin, and strongly recommended by Kocher.

### V-SHAPED OPERATION.

Small tumors situated on the anterior fourth or third, or on the lateral border, of the tongue may be removed by a V-shaped excision. Unless these tumors are seen very early and confined to near the tip, this is not applicable to carcinoma, in which the excision should be at least  $1\frac{1}{2}$  centimeters from the border of the growth. Even in very early carcinomata, it should not be employed when the microscopical examination shows it to be very malignant. The V-shaped excision is made as follows:

The tongue is drawn forward with vulsellum forceps, one pair on each side of the growth. For a lateral growth the cheek is retracted or split. The proposed incision is first outlined on the dorsum. Two or three through-and-through silkworm gut sutures are placed by perforating the tongue on each side 5 millimeters beyond the line of the proposed incision, in such a way that when the incision is made the

remaining raw surfaces can be immediately approximated by tying these sutures. Each suture is entered at the dorsum, to one side of the proposed excision, and passes directly through the substance of the tongue without deviating toward the plane of excision. The same needle next penetrates from the sublingual to the dorsal surface at a corresponding point on the other side of the growth. After the through-and-through sutures are placed in this way, the free ends will protrude from the dorsum, and at least 5 centimeters of each loop from the under surface. The tongue still being held by the vulsellum

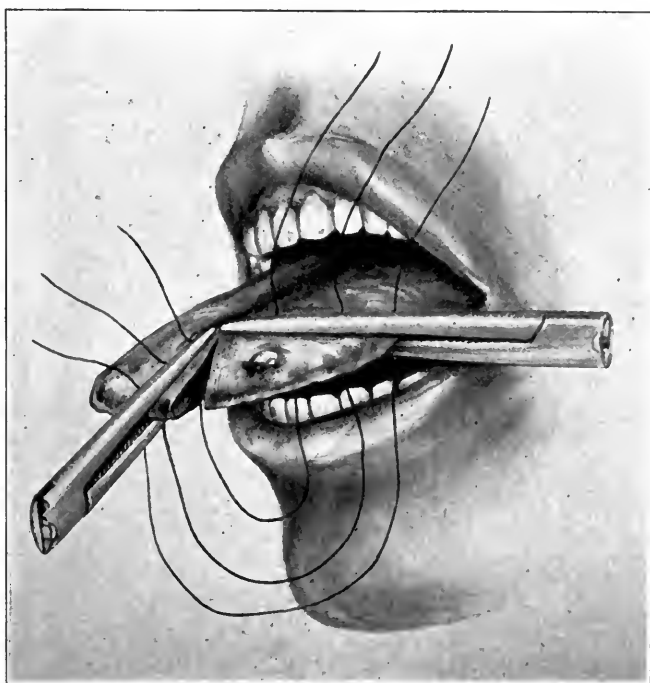


Fig. 341. V-shaped excision from the tongue. The sutures are placed previous to making the excision, and hemorrhage is controlled by immediately approximating the borders.

forceps, its substance is grasped on each side, external to the line of the incision, with a long narrow-bladed forceps. These should be placed over the sutures so as not to come quite up to the line of incision; otherwise the tongue, as it is cut, will slip from between the forceps blades. The forceps are not locked, but are held tight by an assistant. The teeth on the points of Kocher's straight forceps prevent slipping just where the blades will be most separated. These preparations having been made, the surgeon takes the two vulsellum forceps in one hand and with a very sharp knife or sharp, strong scissors makes the two

incisions. The forceps are released, and the silkworm gut sutures tied to control the bleeding. Some supplementary sutures may be added where needed (Fig. 341).

### EXCISION OF ONE HALF OF THE BODY.

The tongue is grasped on each side near the tip with vulsellum forceps or retention sutures, the patient being turned to the side opposite the growth. One retention suture or forceps is held by the operator, and the other by an assistant. The tongue is drawn out, and the dorsal mucous membrane split exactly in the midline from well behind

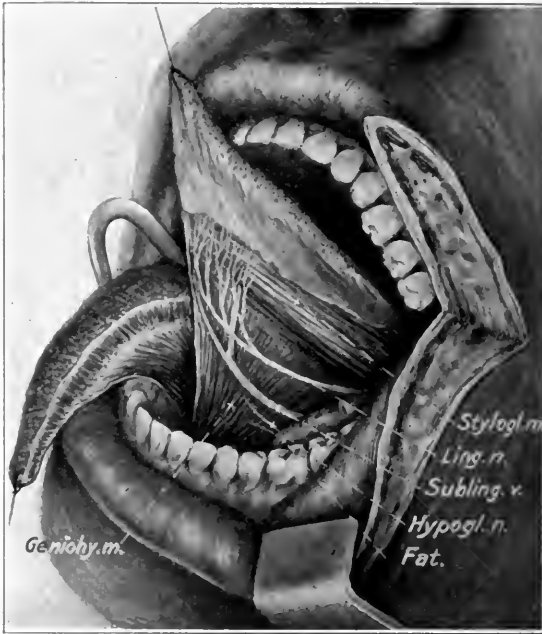

Fig. 342. Removal of one half of the tongue, anterior pillar, and tonsil from within the mouth, after splitting the cheek and also dividing the tongue in the midline, and the mucous membrane of the floor. Tongue in position for cutting the geniohyoglossus muscle from the jaw.

the disease to near the tip; then, elevating the tip somewhat, the body is divided exactly in the midline as far back as the attachment of the frenum with one clip of a pair of strong, sharp scissors. The remaining part of the body is best split by Butlin's plan of using the fingers of both hands, making the division exactly in the midline. If the plane of the tear deviates from median, the lingual artery might be injured. The halves of the tongue are to be separated as far back as the proposed excision, forward to the mandible and downward to the inferior borders of the geniohyoglossi muscles. After separating the two geniohyoglossi muscles, all facial tissues should be removed

from the surface of the healthy muscle. In this way the lymph nodes will be included in the excision. If the growth approaches near the midline, it is safer to make the division just to the other side of the midplane, so as to include the median septum with the part to be excised. This is not quite so easy as splitting the tongue in the median plane, and to avoid the possibility of troublesome hemorrhage, it would be safer to have a provisional ligature around the lingual artery of the unaffected side in the digastric triangle. This ligature should be placed distal to the dorsal branch. After splitting the tongue lateral of the midline, some fibers of the geniohyoglossus muscle of that

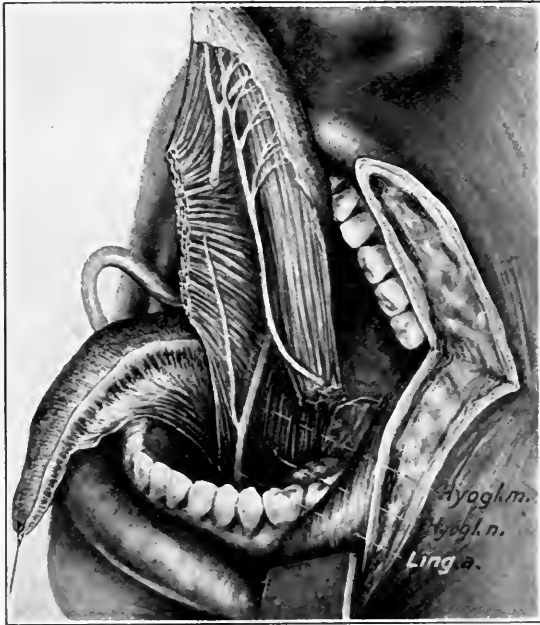

Fig. 343. Tongue in position for cutting it across at its base. In order to illustrate its position, the lingual artery is shown very much more plainly than it can be made to appear at operation.

side will have to be cut. The tongue having been split, the mucous membrane is incised in the floor at the side of the tongue. If the carcinoma involves the floor, it may have to be treated as will be presently described. If not, the incision in the mucosa should be at least 1 centimeter from the edge of the growth. The lateral incision extends as far back as is needed and forward to the frenum. If possible, the anterior part of the lateral incision should be behind the opening of the submaxillary duct. With the finger the mucosa is pushed from the subjacent tissues toward the tongue, and the latter is freed from the adjoining structures of the floor until the outer surface of the geno-

hyoglossus is freed as far forward as its origin from the genial tubercles at the symphysis. In doing this, the lingual vein may be cut or torn, and the lingual nerve will be divided. If the cancer extends to the floor of the mouth, but does not involve the bone or the mylohyoid muscle, then the structures in the floor should be included with the excised part of the tongue. To do this, the incision through the mucous membrane is made close to the inner border of the jaw. The structures in the floor, the intraoral part of the submaxillary gland and its duct, the sublingual gland, and the lingual vein and nerve are elevated from the mylohyoid muscle with the finger, until the outer border of the geniohyoid muscle is exposed.

This having been accomplished, the excision of the tongue proceeds. The diseased half of the tongue is drawn upward, making the geniohyoglossus tense, which muscle is cut with scissors close to the genial tubercle (Fig. 342). If the entire half is to be removed, the

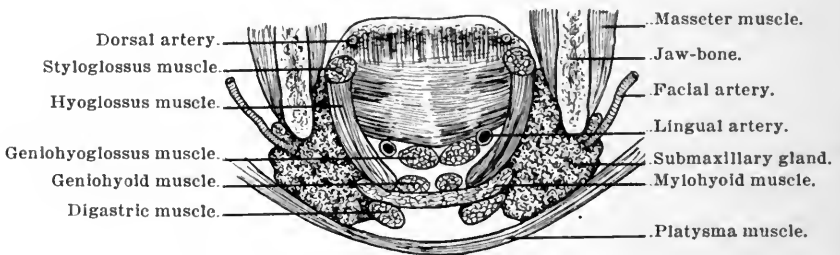


Fig. 344. Diagrammatic coronal section of the tongue.—After Butlin.

anterior pillar of the fauces must be cut through. Before beginning the transverse incision, the affected half of the tongue should have been so freed from the floor of the mouth and fauces that it can be drawn well out into view beyond the line of the teeth, and this should take place without any blood vessels of importance having been injured (Fig. 343). The transverse cut is made with short cuts with the scissors through the muscles attached to the base, at least 2 centimeters beyond the growth. The cutting is done from the lower toward the dorsal surface. The lingual artery can usually be secured before it is cut. It lies near the midline and appears as a white cord in the midst of the muscles. The exact position of the artery is to the outer side of the insertion of the geniohyoglossus muscle. Near the hyoid bone it is covered by the hyoglossus muscle, but anteriorly it lies deep in the sulcus between the geniohyoglossus and the inner border of the inferior lingualis muscle. It should be approached with shallow cuts, feeling carefully for its pulsations. As soon as these

are recognized, a pair of sharp-pointed artery forceps, with blades partly spread, are thrust into the muscle, and the vessel clamped; while doing this, the tongue is steadied by placing the index finger of the left hand upon the pharyngeal surface. The artery should be immediately tied.

After the lingual artery is controlled, the tongue can be then cut away quickly, the dorsal artery being caught after being cut at the outer border (Fig. 344). If the structures in the floor of the mouth have been included in the excision, these must be cut across posteriorly,

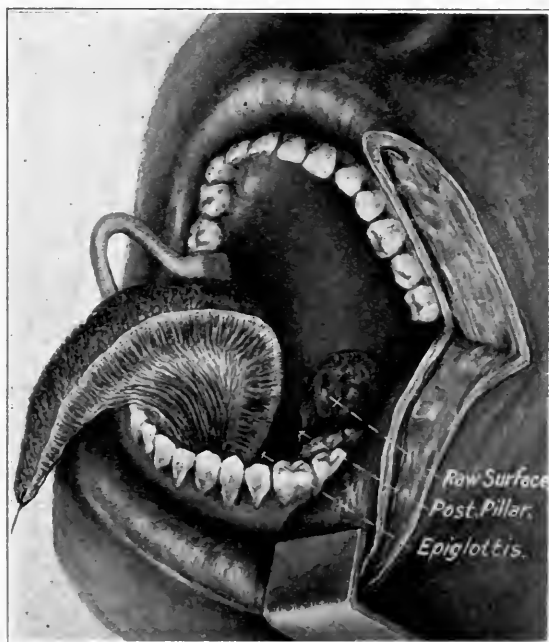


Fig. 345. Removal of one half of the tongue, the anterior pillar, and tonsil, completed. In order to display the posterior part of the space, the remaining part of the tongue is represented too far to the side.

and the bleeding points caught individually with pointed forceps. The cut end of the intraglandular excretory duct of the submaxillary must not be ligated (Fig. 345). Another plan of controlling hemorrhage is to place a row of through-and-through, interlocking, mattress sutures across the base of the tongue. This line of sutures must be well behind the transverse cut, otherwise one of them might be clipped during the excision. This takes time, and sometimes forceps and sutures slip.

If the cancer has involved the faucial pillar or tonsil, the pillars, tonsil, and half of the velum can be removed with the tongue through the mouth after splitting the cheek (see Excision of Tonsil, page 537).

After completing a unilateral excision, some surgeons prefer to double the half tongue back on itself, placing the tip posteriorly and suturing the apposed raw surfaces. This makes a short, broad stump.

### BILATERAL EXCISION.

The tongue is secured by the two stout ligatures or vulsellum forceps, as in the excision of one half of the body. The mucous membrane of the floor of the mouth is treated in the same manner, but on both sides. The anterior pillars are divided if the disease extends far back. The tongue is raised up so that the geniohyoid muscles are made tense, and they are cut across with scissors close to the genial tubercles. The entire tongue is then separated as far back as the epiglottis, or if the disease is not very far back, to a point 2 centimeters behind the evident disease. In this operation both geniohyoglossi muscles are divided at the genial tubercles, but the geniohyoid should not be injured if they are not apt to be included.

The transverse cut is made as in excision of one half of the body, but both arteries being controlled. Just before the tongue is separated, a ligature is passed through the tissues of the stump, through the glossoepiglottic fold, if the entire tongue is removed—so that it can be drawn forward in case of hemorrhage. This ligature serves not only in cases of hemorrhage, but also to draw the stump forward in case of dyspnea. It may generally be removed with safety on the day following the operation.

The operation as described is the operation of Whitehead, which Butlin prefers to any other for the removal of the tongue within the mouth. Instead of removing the tongue in one piece, however, he generally splits it, and removes it in two halves.

If the vessels are cut before being caught, hemorrhage is free. The stream from the larger vessels is out of the mouth, and they can be secured in a moment. The vessels should be tied as soon as caught. Clamps are apt to become loosened and fall off, or tear away from the soft tissues. And it must be borne in mind that it is by no means uncommon for a patient to come partly out of the anesthesia during the operation.

If in a complete amputation the tongue should be separated before the larger vessels are ligated—an awkward accident, which ought not to occur—Mr. Butlin suggests that Mr. Christopher Heath's recommendation must be borne in mind: The stump is drawn forcibly forward by the forefinger hooked around it, and the bleeding is thus temporarily arrested. When the blood has been sponged out of the mouth, the vessels can be taken up and tied.

In his "normal excision" of the tongue by splitting the lower jaw



and floor of the mouth, Kocher calls attention to the value of drainage placed through the floor of the mouth just in front of the stump. This can be placed after an intraoral excision through a stab wound through the skin and mylohyoid muscle in front of the hyoid bone, the rubber drain entering the mouth between or to the side of the geniohyoid muscles. This drain removes a quantity of saliva and wound secretion, and we believe adds greatly to the comfort and safety of the patient. With such a drainage in place, it is proper and expedient, where possible, to suture the mucous membrane over most of the raw surface left in the floor of the mouth.

Kocher uses the actual cautery to divide the mucous membrane in the posterior part of the mouth and also to divide the muscles. This is done both to limit hemorrhage and to limit infection of the freshly cut surface.

**Kocher's "Normal Excision."**—This consists in dividing the jaw in the middle line in all cases where the cancer extends as far back as the isthmus of the fauces, and where it has involved the arch of the palate, the walls of the pharynx, and the soft palate. This is a modification of Roux and Sédillot's method. It causes little bleeding and gives sufficient room for removal of pharyngeal cancer in the region of the isthmus of the fauces. An incision is made down to the bone in the middle line through the lower lip, and extending as far as the hyoid bone. The submental lymph nodes are removed. The jaw-bone is sawed through just to one side of the symphysis—to the side on which the tumor is situated. The cut is made between the central and lateral incisor, and does not disturb the attachment of the muscles to the genial tubercles. Previous to sawing the bone, without removing the periosteum, holes are drilled on each side of the line of the proposed saw-cut. These are for the wire that will hold the sawed ends in apposition after the operation, and should at once be marked by placing a tack or a piece of wire in each of them. The two halves of the jaw are forcefully separated with hooks. The mylohyoid muscle is split near the midline, the digastrics are separated, and the outer surface of the geniohyoid and geniohyoglossus is exposed. The excision is then carried out in a manner similar to that already described. The nerves and muscles are preserved as much as possible, in order not to interfere with the mechanism of swallowing more than is necessary.

Kocher rubs xeroform into the cut surfaces, but only in a thin layer so as not to produce toxic symptoms if swallowed. The two halves of the jaws are then approximated with strong silver wire, and the edges of the jaw firmly united. An opening is left a little above the hyoid bone at the posterior end of the incision, into which a strip

of xeroform gauze is inserted. We prefer rubber dam for drainage when it is not expected to control bleeding. Kocher believes that this operation gives the best access and causes the minimum of injury. For reasons already given, we prefer the intraoral excision wherever applicable.

The after-treatment consists in the free application of iodoform, colloidal silver, or xeroform, while the wound is kept open and packed; if necessary, the packing is removed to feed the patient through a tube.

Cancer situated between the faucial isthmus and the hyoid bone may be attacked by a suprahyoid pharyngotomy, preceded by a laryngotomy, by a Mikulicz high lateral pharyngotomy, or by Kocher's normal excision just described. In this case, not only is the jaw split in the middle line, but also the hyoid bone to the thyrohyoid membrane, preserving the mucous membrane of the floor of the mouth as far as the condition of the growth will allow; and then, after slitting the tongue and holding the two halves apart, one can decide how far the operation must extend in order to remove the disease completely.

### RESECTION OF THE TONGUE AT THE ROOT. KOCHER'S OPERATION.

For a complete removal of the tongue, Kocher recommends this operation for the following reasons: "(1) because it gives the best access; (2) because it permits of the simultaneous removal of the glands as well as of all the tissue which intervenes between them and the primary seat of the disease; (3) because it admits of preliminary ligation of the lingual or external carotid arteries; and (4) because it allows at least the anterior attachments of the muscles of the floor of the mouth to be preserved."

It seems to us that from the figures already quoted there is no advantage from the simultaneous removal of the lymph nodes and the primary tumor, but rather the reverse. The advantage of primary ligation of the lingual artery is not great.

The incision begins below the mastoid process and extends along the anterior border of the sternomastoid, and then forward along the crease between the floor of the mouth and the neck to the middle line, and lastly, upward to the lower border of the jaw. In cases where the extent of the carcinoma is limited, it need only correspond to the middle two thirds of this incision—i. e., from the sternomastoid as far as the hyoid bone. After the subcutaneous vessels have been ligated, the flap is dissected up and fixed with a suture to the cheek. Next, the submaxillary, submental, and upper deep cervical lymphatics, with the submaxillary salivary gland, are dissected free from the great vessels and the digastric and mylohyoid muscles, and freed from their connec-

tions on the outer surface of the jaw, during which procedure the facial artery and vein again must be ligated.

The lingual artery is easily exposed and ligated by dividing the fibers of the hyoglossus muscle a little above the posterior part of the greater cornu of the hyoid bone. The hypoglossal nerve and lingual vein, which lie upon the outer surface of the muscle, are to be preserved.

The outer surface of the mylohyoid muscle is now exposed with its nerve lying on it. This muscle is divided parallel with the jaw when the mucous membrane is felt. After the limits of the new growth have been investigated, the mucous membrane is incised from the mouth, guided by the finger. From this opening the mucous membrane is further divided beyond the tumor, artery forceps being applied to the more important bleeding vessels of the mucous membrane. Further hemorrhage is readily arrested by dragging forward the soft parts by means of the finger introduced through the wound in the mouth.

The anterior and posterior limits of the tumor are defined, as well as the extent to which the jaw is involved. If the jaw is involved, a section of the bone is removed.

The tongue is detached from the hyoid bone, and the excision completed as indicated by the extent of the disease, any hemorrhage being readily and securely arrested. The tongue can be well drawn out through the floor of the mouth as soon as the mucous membrane has been divided.

If, in order to facilitate the administration of the anesthetic, a preliminary tracheotomy has been performed, the entrance to the larynx is at once plugged with sterilized gauze introduced through the pharynx.

#### AFTER-TREATMENT.

Kocher recommends, where laryngotomy has been done, leaving the wound open so that the entrance to the larynx may be plugged with sterilized moist (salt solution) gauze, which is to frequently be changed—a carbolic or sublimate gauze dressing being applied over the wound, and the patient fed with a tube each time the wound is dressed.

We have not been successful in attempts to plug the opening of the larynx under the circumstances referred to above, either with gauze or plugs of cork especially formed for the purpose. The slimy mucus, which seems always to be present as a result of the irritations incident to the operation, acts as a lubricant, and the plug has always been coughed out.

As long as swallowing is much interfered with, the patient must remain in the sloped position, with head and neck dependent.

After drying the surface of the wound, Whitehead swabs it over with a varnish, made by substituting for the alcohol ordinarily used in the preparation of Friar's balsam a saturated solution of iodoform, dissolved in nine parts of ether and one of turpentine. Butlin uses powdered iodoform, or packs the surface of the wound with strips of the softest iodoform gauze, which, like the iodoform varnish, has the effect of rapidly stilling the oozing of blood. Kocher uses xeroform, while we not infrequently have used a 15 per cent solution of colloidal silver, both as a paint and on the strips. For the later dressings, we soak iodoform gauze in Friar's balsam.

For troublesome oozing, where there is no vessel which can be tied with advantage, the oozing surface is covered with a pad of gauze, which is fixed in place by means of one or more silk sutures. If no drain has been led out from the floor of the mouth through the sub-maxillary region, the patient is put to bed, lying on one side, with the head low, so that all the mucus escapes by the angle of the mouth on to a piece of wool and gauze or a folded rough towel. If the patient lies in this position, there is little difficulty in keeping the mouth free from the collection of discharge, mucus, and saliva. If the discharges cling to the interior of the mouth, and the patient is not able to get rid of them, the nurse wipes them out, or irrigates the mouth frequently with a weak antiseptic solution. If a good, free, external drain has been placed through the floor of the mouth, the patient may sit up as soon as he comes out from under the anesthetic. It is good practice to allow the patient to keep small pieces of ice in the mouth during the first day or two, and if the pain is severe, morphin should be given hypodermatically. During the first twenty-four hours, food, if necessary, is administered by means of nutrient enemata or a carefully passed stomach tube.

As a rule, the patient can swallow on the second day, taking food from a feeder with a piece of India-rubber tubing on the spout. He sits up or lies on the sound side, and if only half of the tongue has been removed, places the tubing on the sound side of the tongue. In cases in which the operation has been very extensive, it may be necessary to feed through a fube and funnel. A soft catheter, about No. 6 or 7 English, may be used for the purpose. It is fastened to a long piece of India-rubber tubing, to the other end of which is fixed a glass funnel. The catheter is smeared with oil or glycerin and is introduced through the mouth or nose. The catheter need not be passed more than half way down the esophagus. This feeding may be performed twice or three times in twenty-four hours, a pint or a pint and a half being administered on each occasion. After nutriment enters the esophagus, Butlin recommends letting a little water run in to clear

the tube and catheter. The tube is raised and straightened in order to completely empty it. It is then tightly pinched between the finger and thumb, and the catheter is withdrawn. By this means not a drop of the liquid will find its way into air passages.

Tube feeding may be preceded by a little cocaine sprayed on the back of the throat, and the patient is propped up, or in the sitting posture. In our experience, unless a part of the jaw-bone has been removed, the patient can swallow liquids, while sitting up, on the second or third day after operation.

Packing within the mouth should be removed piecemeal as it loosens, the free ends being clipped off with sharp scissors. After the whole packing has been removed, it may or may not be replaced. If there is a drain in the floor of the mouth, it is seldom necessary to replace it, but a mildly antiseptic wash—weak permanganate of potassium solution—should be used frequently. The antiseptic packing should be continued as long as it will be retained, if the wound in the floor is not clean.

## CHAPTER XXXVII.

### TUBERCULAR AND MALIGNANT DISEASES OF THE CERVICAL LYMPHATICS.

Certain localized infections of the lymphatics are best treated by radical excision of the diseased tissues.

In malignant disease, whether primary or secondary, this is with rare exception the only treatment that gives any chance of cure. In tubercular infections of the lymphatics, the age, resistance, and hygienic surroundings of the patient and the activity of the disease must be considered in deciding between conservative and radical treatment of an individual case.

#### TUBERCULAR ADENITIS.

Tubercular diseases of the lymph nodes on one or both sides of the neck usually result from infection through the teeth, tonsil, or nasopharynx, less commonly from the middle ear or mastoid antrum, or from the nodes of the opposite side. It is seldom that the exact portal of infection is recognized. Tubercular lesions of the mouth, throat, and ears are much less common than is tubercular adenitis, although in systematic examinations the bacilli may occasionally be demonstrated in the cavity of a tooth, in the crypt of the tonsil, or lodged in some other place. It is an accepted fact that the bacilli may enter the lymphatics without causing a recognizable inflammation at the portal of entry.

**Symptoms and Course.**—The course of a tubercular adenitis is usually rather chronic, but it is occasionally very acute. The ordinary history is that a single nodule appears, commonly in the upper cervical or submaxillary group, slowly enlarges, and later other such kernels follow. At first these remain discrete, but later there is a tendency to fuse into a somewhat lobulated mass. In the meantime, chains of hard, small nodules may be developed in several other groups, so that the palpable enlargement may be confined to one chain or group of nodes, or may be felt all over one or both sides of the neck. The isolated nodules are hard, rounded, and movable; while the conglomerate masses become somewhat fixed, and a softening can sometimes be detected in some of the larger nodules. Even after the nodes have become quite large, resolution may take place. This is more likely to occur if the original atrium of infection is removed and the patient

is placed under good hygienic conditions. Usually, after one or more nodes become markedly enlarged, they caseate, and a cold abscess may result. Before the age of seven years cold abscess is extremely common. If the mass is not extirpated at this time, sinuses may result. These are persistent, and their external opening is usually surrounded by an area of bluish discoloration. They heal slowly, often only to recur, and when healed, leave unsightly scars. In some cases there is less tendency to form abscesses or sinuses, and the mass enlarges until its presence causes considerable disfigurement.

In the acute cases the nodes rapidly enlarge; there are fever, loss of weight, and the ordinary general symptoms of an active tubercular infection.

In the chronic cases there is little or no fever and no pain, and the patient suffers remarkably little in general health. In these chronic cases there is a very distinct tendency to ultimate recovery. If a secondary pus infection occurs, there will be all of the signs of acute septic inflammation. Tubercular adenitis is almost essentially a disease of children and early adult life, seldom being seen after thirty years.

**Diagnosis.**—The majority of children between the ages of four and twelve years have palpable lymph nodes, and chronic enlargement of the lymph nodes from simple hyperplasia is not uncommon in early adolescence. Moderate enlargement of the nodes cannot be taken as the basis of a diagnosis of tubercular infection. When a tubercular infection advances to the stage of causing excessive enlargement of certain nodes or a group of nodes, then the diagnosis is usually, but not always, simple. There is little danger of confounding the disease with enlargement due to acute septic infection. In the more chronic forms of simple irritation, the nodes have not the tendency to fuse together in masses, and when periadenitis is present, the outline of the glands is not so distinct as in tubercular adenitis. Syphilis, lymphosarcoma, Hodgkin's disease, endothelioma, and secondary carcinoma, all cause an increasing enlargement of the nodes; but if one will confine operative interference to cases in which there is a persistent and an increasing localized enlargement of the nodes, will always remove all of the lymph-bearing tissue, and will seek the atrium of infection, except in the case of syphilis or of Hodgkin's disease, the mistakes in diagnosis will not be detrimental to the patient. On section, a tubercular node may show an apparently simple hyperplasia or it may be caseated. Even microscopically the diagnosis may be difficult, and the safest plan for making a diagnosis in uncertain cases is the injection of fresh material into a guinea pig.

**Treatment.**—It was the observation of many of the older clinicians that a chronic tubercular adenitis gave an immunity against the more

active types of the disease. The value of such observations is not to be lightly treated, and in this instance it corresponds to our more newly acquired knowledge of antitoxins. In spite of this, modern aseptic surgery has placed at our disposal therapeutic measures that can be advantageously employed in many of the more active processes.

In the earlier stages and in cases in which there is not deformity from the enlargement of the nodes, in which the nodes are not enlarging, are not breaking down, and in which the patient's general health is not affected, radical surgical treatment is not indicated. Possible sources of infection should be sought and eradicated. In children enlarging cervical lymphatics is sufficient indication for removing ragged or enlarged tonsils and adenoids, and the teeth should receive attention when decayed. Of course, any other gross lesions should also be corrected. The patient should be placed under proper hygienic conditions. In this regard, the choice of treatment might be determined by the circumstances of the patient. A patient that can be sent to the country or to some proper climate might very properly be spared an operation that would be positively indicated in an inhabitant of a tenement house. For children, cod-liver oil has been considered a great help in treating tubercular infections and the anemia that accompanies them.

In a tubercular adenitis the infection is inclosed within a wall of granulations and the gland capsule. The local circulation is meager, and it is not reasonable to expect any very great effect from specific agents, such as tuberculin; but this might be helpful in preventing the spread of the disease to other nodes or from becoming diffused. In this respect, tuberculin injections might be very properly made just before and after a radical operation to prevent general diffusion of the bacilli. The injection of vaccines and toxins should be done only by one who has made some study of this subject, for they may produce more harm than good if improperly used. Cases in which, in spite of the best obtainable conditions, the glands are enlarging or the infection is spreading and cases in which the glands are breaking down or in which there are persistent general symptoms due to the local lymphatic infection are proper ones for surgical interference. Except in young children and in the presence of open sinuses, the operation should be radical and should remove all of the infected lymphatic tissue. A limited apical infection of the lung is not a contraindication to an operation for a rapidly advancing cervical adenitis. Cases with advanced pulmonary or peribronchial tuberculosis, with pharyngeal infection dependent upon pulmonary disease, or with extensive involvement of groups of glands that cannot be reached should be excluded from radical operation. The radical operation for tubercular adenitis is



based upon the fact that for a time, possibly for a very long time, the infection is confined within one or a group of nodes and that during this period the infected areas can be removed by a properly planned and executed operation. The two essentials of a radical operation are: (1) the elimination of the original source of infection, so that tubercle bacilli will not be poured into the neck wound through the cut ends of the lymphatic ducts; and (2) that the infected mass is removed entirely, and preferably in one piece. In this way there is no danger of leaving infected foci or of disturbing the infection during the operation.

There is a feeling on the part of most surgeons, which we share, that, except for diagnostic purposes or for obtaining material for making an autogenous vaccine, single nodes should seldom be removed, but the infected group, the impalpable as well as the palpable ones, should be removed *en masse* with the fascia that carries them. Of late there is a tendency on the part of some to revert to the older plan of removing only the larger nodes and to depend upon hygienic measures to overcome the less seriously affected in the same group. Just how far the pendulum will swing in this direction is impossible to say. While we are satisfied to do the least possible surgery on babies and young children on account of their peculiar ability to overcome the infection, in older children and young adults we prefer to remove the whole group if we invade the neck at all. In children and babies it seems wise to repeatedly aspirate cold abscesses until the cavity becomes filled with granulations. In aspirating, strict asepsis is preserved, and the needle enters the neck well away from the abscess and travels through at least 1 centimeter of the subcutaneous tissue before it enters the cavity. Some surgeons inject emulsions containing iodoform crystals.

Before a radical operation is undertaken, certain preparatory steps may be advisable. The patient should be placed in the best possible physical condition. If unruptured pure tubercular abscesses are present, these need not deter the surgeon from operating, but it may be advisable to withdraw the fluid and to inject a very small quantity of a 2 per cent solution of methylene blue into the cavity, which will serve to outline it during the operation. In this way the sac is more easily removed without rupture.

Open sinuses that have a mixed infection may be lightly curetted at a preliminary operation and packed with gauze, soaked in a weak formaldehyde solution. If the nature of the septic infection can be determined, an autogenous vaccine can be prepared, and a course of treatment given before the major operation is undertaken. It is a source of danger, of prolonged postoperative discomfort to the patient, and of embarrassment to the surgeon to have an extensive suppura-

tion occur in the immense wound that remains after a complete removal of the lymphatic-bearing fasciæ of the neck. It is far preferable to allow all sinuses to heal before operating. If it is deemed advisable to operate in the presence of a sinus, it can be plugged lightly with gauze, saturated with tincture of iodine. At operation the discolored skin at the mouth of the sinus should be excised.

When the infection seems limited to the submental and submaxillary regions, the operation may be planned to meet this limited infection, but it is always safer to remove all of the lymphatic-bearing fasciæ and nodes below the site of the infection. In about 80 per cent of cases the enlargement first appears beneath the upper end of the sternomastoid muscle. In a very few cases it will be found to have started in the lower part of the neck. In any case, all of the lymphatic tissue should be removed cleanly from any area that is invaded by the surgeon. Reoperation is more difficult and less likely to be effective than is a well-executed primary operation. It is perfectly proper in selected cases to divide the operation into several stages—such as, for instance, to operate upon both submaxillary and submental groups and then take the lateral cervical nodes at two subsequent operations. But it is never proper to enter any area without removing all of its lymph-bearing tissue. In spite of our best judgment and efforts, recurrence will sometimes happen, and we shall have to occasionally reoperate on our own as well as on other cases.

**Radical Operation for Tubercular Infection of the Cervical Lymphatics.**—Many plans have been devised for exposing the lymphatic-bearing fasciæ of the neck, but there is one that, while giving perfect access to the operative field, does so with very little disfigurement to the patient; and this we will describe. As far as we know, it was first used by Dr. White, of Chicago, and is probably at present the most popular among those doing truly radical operations.

The hair should be shaved for 2 centimeters above and posterior to the normal hair-line on that side. The skin is prepared down to the middle of the sternum and well past the midline on the opposite side. The patient lies on the table on his back with a low pillow under his shoulders. The incision is to run from the tip of the mastoid process to a point 3 centimeters above the middle of the clavicle, and then, turning abruptly, crosses the sternoclavicular joint to a point 2 centimeters beyond. This incision is to be outlined before the protective cloths are clamped into place. If the infection does not extend forward of the submaxillary group, all diseased tissue can be removed through the incision just outlined.

If enlarged nodes are situated in front of the submaxillary salivary gland, a supplementary incision will have to be made if this tissue

is to be removed at the same operation, and this must be borne in mind in placing the protective cloths. We prefer in all operations to have the protective cloths fastened securely to the skin. This takes but a few minutes and relieves the operator's mind of all further anxiety on this point. The upper cloth is fastened with safety pins or tenaculum forceps along the border of the jaw and hair-line and is turned upward over the hair and the ether mask. Ether is subsequently poured directly on this cloth, while the anesthetist observes the pulse and controls the position of the head with one hand under the cloth. The fastenings of the cloth that skirts the posterior border of the wound should be placed at short spaces, for there is a tendency for this cloth to sag away from the skin and to allow the handles of artery forceps to slip under it. Only several centimeters of the skin incision should be made at a time, and the bleeding should be controlled with Halsted forceps or heavier clamps, as the operator prefers; but the whole superficial incision should be completed before the deeper tissues are disturbed. The skin should be cut squarely through and not beveled, as this renders a good closure difficult. This incision should go down to the deep fascia covering the sternomastoid muscle. In its middle and lower parts it cuts through the platysma muscle. The external jugular vein is exposed and doubly ligated. Schroeder recommends that the proximal part of the vein be left somewhat long on the left side, as it might be useful in forming anastomosis with the thoracic duct, should the latter be injured subsequently. We have found it simpler, after resecting the duct, to implant it into the internal jugular vein. The flap is dissected forward until the whole posterior border of the sternomastoid is defined. The lymphatic-bearing fascia of the posterior triangle is now exposed and should be removed *en masse*. Before this is begun, the spinal accessory nerve which enters the gland mass from beneath the posterior border of the sternomastoid muscle should be found and dissected free. It emerges from under the sternomastoid just below and slightly behind the angle of the jaw, and runs downward and backward, to disappear under the trapezius muscle. It should be freed from the surrounding tissue throughout this course through the posterior triangle. It should not be crushed with the forceps, but may be lifted with a loop of tape or catgut. In weak, growing children cutting this nerve has been the starting of a scoliosis due to partial paralysis of the trapezius muscle. The nerve may be identified by grasping it lightly with artery forceps, which will cause a contraction of the trapezius muscle. This nerve secured, the cutaneous branches of the superficial cervical plexus may be cut as they are encountered, for their preservation in the dissected area is apt to be followed by a somewhat persistent neuralgia. The posterior

border of the sternomastoid muscle is dissected forward until the internal jugular vein is exposed. Surgically this is one of the most important structures in the neck, and the enlarged nodes may be adherent to the posterior part of its sheath. About the middle of its course there are usually two nodes just anterior to it in the angle between the vein and the omohyoid muscle. From the level of the

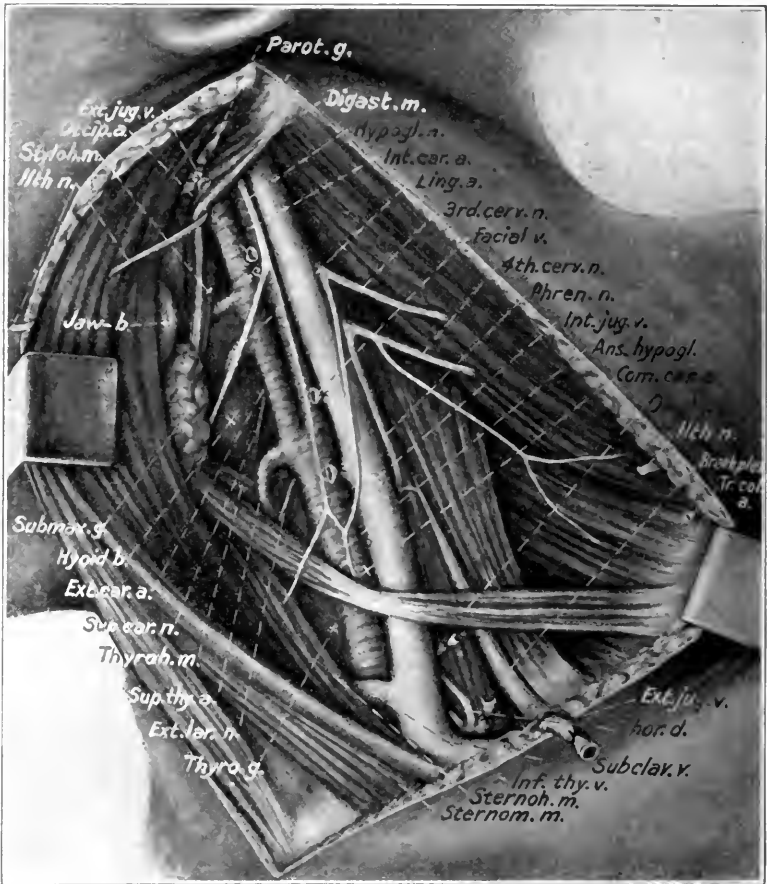


Fig. 346. Structures displayed in a radical excision of the deep cervical nodes. In order to retract the wound in both directions at once, the spinal accessory nerve has been cut. It should be preserved in a resection for tubercular adenitis.

hyoid bone downward, the sheath and the attached glands are dissected from the vein. In doing this, it is safest to use a dissecting scissors or a pointed artery forceps, thrusting the point into the mass of fascia and, by spreading the blades, investigating each mass of tissue before it is cut. When the mass attached to the vein is pulled forcibly, the vein, from which the blood will be pressed out, is easily drawn with it

and may be caught upon the end of the scissors and cut. When working close to the vein, the outline of the wall should be in constant view. When recognized, small veins should be caught before being cut, and all bleeding controlled. Blood in the tissues obscures the view and is productive of accidents. A lateral wound in the jugular vein should be immediately sutured with fine catgut; a transverse cut can also be sutured. Ligation of one internal jugular will rarely cause trouble. As soon as the lower part of the internal jugular vein is well exposed, it will be seen to collapse with each inspiration. If wounded, this negative pressure may suck in air (see Air Embolism, page 61). To avoid this possibility, the vein may be blocked and kept permanently distended by stuffing a folded strip of gauze between the vein and the sternomastoid muscle at the root of the neck. A part of this strip is left protruding from the wound. The mass having been dissected free from the lower half of the jugular, it may have to be freed from the subclavian in the same way. Special care must be used to get a node that may be found close in the angle of junction of these two veins. On the left side this part of the dissection is complicated by the thoracic duct that enters the subclavian vein at this point. By carefully separating the tissues, it may usually be found without difficulty, as it turns downward, emerging from behind the internal jugular vein (Fig. 346). Except at its lower end, it is well behind the lymph nodes. It is usually well distended with a clear fluid, and is thus easily distinguished from a vein. If it is accidentally cut in two, an attempt may be made to anastomose it with the proximal end of the external jugular vein or to implant it into the internal jugular. (Contrary to what might be expected from the supposed anatomy and physiology of this duct, section and non-repair have not proved to be a necessarily fatal accident, but may be followed by a very pronounced loss of weight.) The posterior belly of the omohyoid muscle is seen crossing the lower part of the space. Its nerve supply comes from the ansa hypoglossi, which lies on the carotid sheath, and this should not be injured. At the posterior part of the triangle the mass may extend far under the trapezius muscle, which latter, if necessary, may be cut close to the clavicle. In this way the dissection can be extended to the upper limit of the axilla. If palpable nodes can be felt in the axillary space, they should be removed at a subsequent axillary operation. When the glandular mass is freed anteriorly, inferiorly, and posteriorly, it is dissected upward from the muscles forming the floor of the triangle. In doing this, the muscular branches from the superficial cervical nerve plexus should be preserved, but if the mass is adherent to the muscular sheaths, this may be difficult. Most important is the phrenic nerve, which arises from the third,

fourth, and fifth cervical nerves and is seen to lie upon the surface of the scalenus anticus muscle and runs downward to disappear under the subclavian vein. Its injury would be a very serious accident. When this part of the dissection is completed, the cervical portion of the brachial plexus is plainly in view. The transversalis colli artery and vein lying beneath the deep layer of the cervical fascia may have been cut. In the upper part of the neck the lymph nodes will be found to lie superficial to and under the sternomastoid muscle. The skin and superficial fascia are to be dissected free from the superficial lymph nodes and external jugular vein, which lie upon the upper third of the sternomastoid muscle. Next, the muscle itself is freed from the mass of enlarged glands that may completely surround its upper end. In raising the upper part of this muscle from the subjacent mass, the spinal accessory nerve that here enters its under surface is to be freed without injury. If the spinal accessory and the muscular branches from the third and fourth cervical nerves were both cut, there would be complete paralysis of the trapezius muscle. The freeing of the diseased mass from the structures beneath it is now continued. The superior deep nodes that lie around the bifurcation of the carotid are dissected free. In doing this, the hypoglossal and communicans hypoglossi nerves may be exposed. These must not be injured. The dissection is continued up to the mastoid process, freeing the mass from the internal jugular vein. Above, the gland-bearing fascia is attached to the styloid process, the base of the skull, and also to the transverse process of the atlas, from which it must be cut. At the lower border of the parotid gland, it may be found impossible to establish a natural line of cleavage, and very free hemorrhage from numerous small vessels results from cutting into the substance of this gland. The whole mass is now removed, leaving a clean dissection of the posterior triangle of the neck and the carotid sheath, but the submaxillary and submental nodes still remain. Nodes situated around the submaxillary salivary gland can be reached by retracting the sternomastoid muscle and drawing the skin forward, or by drawing both the skin flap and muscle forward (Fig. 346). The submaxillary nodes lie imbedded in the fascial sheath of the salivary gland, which sheath must be removed with the nodes. If the anterior submaxillary and submental nodes are involved, a supplementary skin incision is required. An incision is made from the middle of the body of the hyoid bone in the direction of the mastoid process. It follows the skin fold and runs about 2 centimeters below the angle of the jaw. The skin, superficial fascia, and platysma muscle are cut through, and with a pair of sharp-pointed rake retractors these flaps are drawn upward and downward until the lymphatic mass is entirely uncovered. In drawing back the

upper flap, the inframaxillary branch of the facial nerve (Fig. 347) should be sought and preserved. It is probable, but not necessary, that the branch to the platysma will be cut. Beginning at the lower margin of the mass, the deep fascia is incised. The facial vein is either avoided or doubly ligated. The mass is lifted from the subjacent tendon and bellies of the digastric, stylohyoid, and mylohyoid muscles, and dissected free from the submaxillary gland, taking with the mass the facial sheath of the gland. The submental nodes lie near the midline on and between the anterior bellies of the digastric muscles. At the lower border of the jaw the fascia containing the mass is cut across. All bleeding vessels that have been caught must be tied, with the possible exception of the skin vessels. This may be tedious, but it is the safer plan, as a large blood clot greatly interferes with the healing of this wound. In spite of the best technic, this wound cannot be considered clean, for the reason that the lymphatic vessels from the

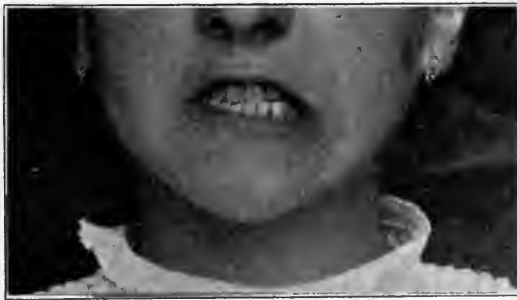

Fig. 347. Inability to depress the angle of the mouth, due to damage of the infra-mandibular nerve at a submaxillary operation on the right side.

mouth have been cut across and empty their secretions into it. For this reason drainage of every part should be carefully provided. Through a stab wound made posterior to the lower angle of the incision, a thin folded strip of rubber dam or a spirally split tube is passed under the sternomastoid muscle and well into the submaxillary space. If preferred, the submaxillary space may be drained directly through a stab wound made at its lower part, but it will not drain past the sternomastoid muscle into the lateral neck wound unless drainage is provided as above outlined. No matter in what way the wound is sutured, the platysma should be well approximated. The drain that passes under the sternomastoid should be left in place from three to six days, as, all lymphatic vessels having been cut, serum is at first continually poured into the wound.

**Results of Radical Operation.**—It is our observation that in the majority of cases operations are followed by very good results. About

10 per cent of all patients will die of tuberculosis, either generalized or localized, most commonly pulmonary, and in about 10 per cent of all cases the disease will recur locally after carefully executed operations.

### SECONDARY CARCINOMA OF THE CERVICAL LYMPHATICS.

The cervical lymphatics will sooner or later become infected in every case of carcinoma or lymphosarcoma of the mouth or face, rarely from sarcoma. (For the order in which various groups may become involved and a description of the clinical appearance of carcinomatous nodes, see page 470 and page 472.)

**Treatment.**—It is our belief that, with the possible exception of the flat carcinomata of the lip (page 390), for malignant disease, not only should all of the nodes in one or both sides of the neck be removed, but always as far as possible the nodes, lymph ducts, and the periglandular tissue should be removed in one block. It was Crile, we believe, who first emphasized this procedure, and his operation includes the removal of the sternomastoid muscle and internal jugular vein. Maitland advocates a less radical procedure in that he does not remove the vein as a routine procedure. We agree with Maitland who removes the internal jugular only when the nodes are plainly adherent to the vein itself, and believe that there are strong reasons for this practice. Kocher and Butlin both advocate a less radical operation. This cannot be done as quickly as the block excision, and there is good reason to believe it is not so effective; but theirs is a less serious operation and may be indicated in earlier cases. The operation we perform in nearly all cases of carcinoma of the mouth, with the exception of flat ulcers of the lips and carcinoma of the maxilla, is essentially as follows:

The submental and the submaxillary nodes, including the platysma muscle, are removed as outlined under Carcinoma of the Lip, page 394, but the incision is made as follows:

On the side of the neck it is outlined as for a radical operation for a tubercular infection. A second incision is outlined from the symphysis of the jaw to the middle of the hyoid bone, and then straight backward to the incision on the side of the neck. The upper part of the lateral incision and the submaxillary incision are made through the skin, and the flap is reflected upward to 2 centimeters above the lower border of the jaw. The least possible amount of the subcutaneous tissue is included. The submaxillary and submental excisions are then made as stated. The incision on the side of the neck is next completed. Above the level of the hyoid bone the platysma muscle is raised with the flap.



The lower anterior flap is turned forward as far as the anterior border of the sternomastoid muscle. The clavicular and sternal origins of this muscle are cut, and the mass of lymphatic tissue is dissected up from the muscular floor behind the internal jugular vein. At the angle of junction of the subclavian and internal jugular on the left side, care should be taken not to injure the thoracic duct (Fig. 346). If the tissues can be freed from the internal jugular vein, it is left in place; if not, the vein is doubly ligated just above its junction with the subclavian and cut through, and the vein included with the block excision. The anterior belly of the omohyoid muscle with the tissue over the thyrohyoid muscle is removed, as the latter contains a node that receives lymph from the neighborhood of the frenum linguæ. Usually there are two nodes situated just above the omohyoid in the angle between it and the jugular vein. As the dissection proceeds upward, the mass is raised from the muscles forming the floor of the posterior triangle, and from the contents of the carotid sheath. All nerves of the superficial cervical plexus are cut as they are encountered, but the phrenic must not be injured. With the exception of the common and internal carotid arteries and the phrenic nerve, any or all structures can be removed from one side of the neck, but such excisions are accompanied by largely increased risks. The various tissues encountered were enumerated in the description of the dissection for tubercular adenitis. At the upper angle of the wound the sternomastoid muscle is cut across close to the mastoid process. If the jugular vein is included in the excision, it must be ligated close to the base of the skull. The lymphatic-bearing fascia is cut across close to its attachments to the mastoid process, the transverse process of the atlas, and the base of the skull. It sometimes happens that the upper part of the jugular vein is surrounded by a dense mass of hard nodes. At first these look rather hopeless, but with patience we have usually found that the vein could be freed, and that between the cancerous masses and the base of the skull there was almost a centimeter of soft tissue through which the excision could be made. The flaps are approximated with sutures and clips, using free drainage of rubber dam. In making this dissection, Crile applies a temporary clamp to the common carotid artery. We do not do this, because the trunk of the vessel is in plain view and can be easily compressed with the finger at any time. We do think it advisable, however, to inject a drop of 1 per cent novocain solution into the proximal part of every nerve large enough to recognize before it is cut. This lessens the shock. This is a very extensive dissection; and before it is undertaken, the operator should plan and prepare for every step, and during the course of the work, the exposed tissue should as much as possible be protected, with either the flaps or hot saline towels. After

the dressing is applied, the head and neck and shoulders should be firmly bandaged to insure the approximation of the flaps to the deep tissues. This is a very important thing, and this pressure should be maintained until the flaps become firmly united to the deep tissues.

**Results.**—Operations done before the nodes become much enlarged are frequently curative, but operations done when the nodes have become adherent to the surrounding tissues are rarely more than palliative.

## CHAPTER XXXVIII.

### CONGENITAL MALFORMATIONS, INJURIES, AND DISEASES OF THE PHARYNX.

While, strictly speaking, the pharynx is not a part of the mouth, still their close anatomical and physiological relationship and the fact that in many diseases the lesion may occupy both cavities lead us to believe that they should be considered together.

#### ANATOMICAL CONSIDERATIONS.

The pharynx is a musculomembranous bag lined with mucous membrane. It is attached to the base of the skull behind the nasal fossæ in front of the vertebral column. Below, it is continuous with the esophagus at the lower level of the cricoid cartilage, and is larger above than below. The muscular wall is complete behind and laterally, where it is in close relation with the bodies of the six upper cervical vertebræ and great vessels, separated only by layers of the deep cervical fascia, and in places by a few muscles. The wall is lacking in front, the deficiency being partly filled by the pharyngeal surface of the tongue and the body of the larynx. It has three anterior openings, one each for the nasal fossa, the mouth, and larynx. The muscles are mostly constrictors, which are active in deglutition, phonation, and respiration. The anatomical and physiological relationship of the pharynx to the three cavities opening into it is maintained, not only by a continuity of their mucous lining, but also by the attachment of one of the three pharyngeal constrictors at the lateral border of each of the three openings. In front, the pharynx has a muscular attachment to the pterygoid process, the pterygomaxillary ligament, the hyoid bone, and the thyroid cartilage. Posteriorly it has no direct attachment to the surrounding structures, being separated from them by a layer of cellular tissue. With respect to the three anterior openings, the pharynx is anatomically divided into three parts: the naso- or epipharynx, the oro- mesopharynx, and the laryngo- or hypopharynx.

The nasopharynx is situated above the level of the hard palate, and normally, during the act of swallowing or of oral respiration, is completely shut off from the oral part of the tube, partly by elevation of the velum and partly by contraction of the superior constrictor. Anteriorly it communicates with the nasal fossæ through the posterior nares, while on each of its lateral walls at the level of the middle turbi-

nated bone is found the Eustachian cushion and the opening of the Eustachian canals. From the posterior part of the Eustachian cushion, a fold passes downward on the side of the pharynx, known as the tubopharyngeal fold. Behind the Eustachian cushion is a deep lateral depression, known as the fossa of Rosenmüller, or the pharyngeal recess. In the mucous membrane of the roof is a collection of lymphoid tissue, known as the pharyngeal tonsil. The oral portion of the pharynx extends from the level of the hard palate to the hyoid bone, and communicates with the mouth through the isthmus of the fauces, which is bounded above by the velum, below by the root of the tongue, and laterally by the anterior and posterior faucial pillars. Between the latter is a space known as the tonsillar sinus, in which lies the faucial tonsil, another collection of lymphoid tissue which is considered as belonging to the pharynx. The faucial and pharyngeal tonsils, together with a collection of similar tissue on the root of the tongue, form a ring known as Waldeyer's lymphoid ring, which surrounds the nasal and oral openings of the pharynx. Lymphoid tissue may be found in less amount in Rosenmüller's fossa and on the posterior pharyngeal wall. These lesser collections are called lymphoid follicles. The base of the tongue is connected with the upper surface of the epiglottis by a median line of mucous membrane, on each side of which is a shallow pouch known as the vallecula.

The laryngopharynx extends from the hyoid bone to the lower border of the cricoid cartilage where it merges into the esophagus. The anterior wall of the laryngopharynx is formed by the larynx, with which it communicates through the glottis. This part is demarcated from the oropharynx by the epiglottis, and there are two mucous folds extending from the lateral border of the root of the tongue to the epiglottis, known as pharyngoepiglottic folds. On either side of the opening of the glottis, which is bounded by the aryepiglottic folds, is a pocket called the recessus piriformis which leads downward. These structures and spaces, as well as those in the nasopharynx, can be felt with the finger and seen with a laryngoscopic or posterior rhinoscopic mirror.

### CONGENITAL MALFORMATIONS OF THE PHARYNX.

Congenital malformations of the pharynx, other than cleft of the velum, are very rare. Atresia of the posterior nares may be congenital, due to lack of complete obliteration of the oral plate, that at one time separated the pharynx from the primitive mouth and nose cavity. The condition causes complete nasal obstruction. (For its treatment, see page 238.) Occasionally the nasal septum extends back into the nasopharynx. Sometimes unilateral or bilateral clefts occur

at the side of the velum, which, when congenital, probably represent a failure of union at this site of the first branchial arch—to which belongs the tensor palati muscle—and the second arch—from which the anterior faucial pillar is derived. It is Bruck's opinion that such lateral clefts are sometimes acquired, due to syphilis or diphtheria.

**Branchial Fistula.**—Congenital branchial fistulæ, sinuses, or cysts are sometimes present, which represent a failure of complete closure of the openings that may occur during development at the site of the gill slits. In the mammalian embryo there are four blind clefts on each side. The entoderm of the pharynx protrudes in a succession of parallel out-pocketings which meet corresponding ectodermal depressions. Entoderm and ectoderm fuse where they meet, and in

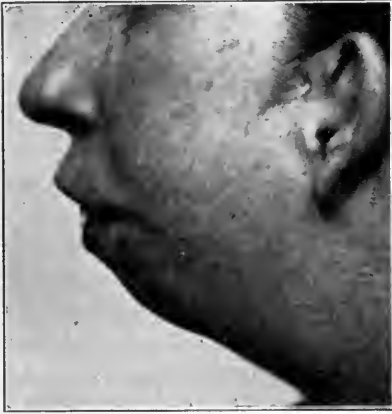

Fig. 348.

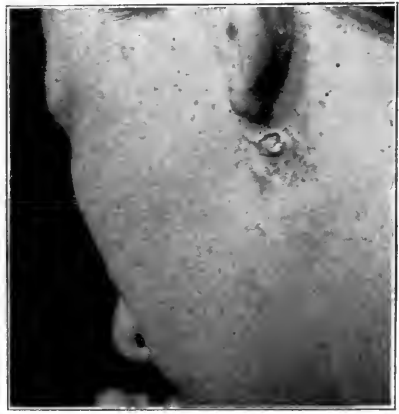

Fig. 349.

Fig. 348. Branchial fistula of the first cleft, bilateral. The pit can be seen in front of the upper part of the ear.

Fig. 349. Branchial fistula of second cleft. A blind pouch was connected internally with the cartilage of the external auditory canal. Fistulæ representing the first or second cleft are of rare occurrence.

fishes they rupture at these sites, making the gill slits or branchial clefts. According to Stöhr, in mammals the clefts are represented by ectodermal depressions, and if they ever rupture through, the defect is usually soon obliterated, so that permanent openings on the side of the pharynx are rarely found. The first gill slit is represented by the external auditory canal and the Eustachian tube. Sinuses or cysts that represent imperfect closure of this cleft are usually found close to the ear (Fig. 348). The second cleft normally closes entirely, but is represented upon the pharyngeal surface by Rosenmüller's fossa and the tonsillar recess (Fig. 349). Internally, the inner openings of the third and fourth clefts, which also close, are represented on the side of the pharynx by an ill-defined fold in front of the laryngeal nerve and by the sinus piriformis respectively. According to Stöhr, the third

and fourth clefts form a single deep recess on the side of the neck, known as the cervical sinus, which persists only in pathological cases, and is the source of branchial fistulæ.

These fetal remains may be represented in the developed human in several ways. There may be a complete epithelial-lined sinus leading from the skin of the neck to the wall of the pharynx. The defect may be represented by an epithelial-lined fistula that opens only on the skin surface—an external fistula—or it may be connected only with the pharynx—an internal fistula. The epithelial remains may communicate neither with the skin nor mucous membrane, in which case they form branchial cysts or dermoids, depending upon the character of epithelium with which they are lined. Though they are necessarily congenital, they may not become evident until some years after birth, though the site of the external opening may be marked by a nodule. These nodules are supposed to represent supernumerary cervical auricles, may sometimes contain cartilage, or may be represented by pigmented spots. The presence of such a nodule does not always indicate the presence of a sinus or cyst.

**DIAGNOSIS.**—When there is an external opening, it may be permanent, or there may be an intermittent rupture with a discharge of fluid. If they become infected, they are distended with pus and may be surrounded by a considerable area of inflammation. If the sinus communicates with the pharynx, the pus is usually very offensive. As a rule, little is to be learned by an attempt to pass a probe. In some instances it has been found that, after freeing the external opening from the surrounding skin, a probe could be passed into the pharynx. Of the several we have dissected out, none consisted of a straight tube that could be followed by a probe, for the external part of the fistula consisted of a series of irregularly shaped epithelial pouches. We have been able to inject methylene-blue solution directly into the pharynx so as to stain a gauze pad, but in one instance the sinus burst, diffusing the blue throughout the neighboring neck tissues, which was embarrassing at a subsequent operation.

The diagnosis is usually based on: the location of the external opening, near the anterior border of the sternomastoid muscle; its persistency, recurring intermittently; the findings at operation; and the microscopic appearance of the tissue. It is most likely to be confounded with a persistent sinus leading to a tubercular lymph node. If there is no internal or external opening, there will be simply a tumor in the side of the neck.

**TREATMENT.**—Owing to the difficulty that may attend the excision of a complete fistula, it has been deemed best by some to simply provide drainage at the external opening. Under this treatment the canal

may shrink to its smallest capacity and give little trouble. The injection of escharotic fluids is not apt to be attended with success, as it is practically impossible to destroy all of the epithelial lining.

The only radical treatment is excision. If it is a blind pocket connected only with the skin, this is a simple matter; but if it is a complete fistula, it is often very difficult, as the inner part of the tube may be very delicate and uncertain of identification. If one were fortunate enough to be able to pass a probe through the full length of the fistula, this would form a guide that could be easily followed. If the incision in the skin can be made transversely, no objectionable scar will result.

According to the embryology of the arches, a fistula representing the second cleft would run between the stylohyoid muscle and ligament in front, and the internal carotid artery and stylopharyngeus muscle behind. One of the third cleft would run between the stylopharyngeus and superior constrictor muscles and internal carotid artery above, and the middle constrictor below; while one of the fourth cleft would run below the middle constrictor. When working in the neck in following such a tract, it is well to bear in mind that under the stress of necessity any structure that is likely to be encountered, except the common and internal carotid arteries, the superior laryngeal, vagus, glossopharyngeal, and hypoglossal nerves, may be divided. The vagus or the glossopharyngeal is not likely to present serious difficulties, and the stylohyoid and digastric muscles can be repaired. In spite of this, the following of a fistula between these structures is always a difficult and tedious procedure.

In operating upon a fistula, the external incision should be made large so that, after freeing the outer part, the sternomastoid can be retracted and the region of the stylohyoid ligament and muscle can be freely exposed. The fistula must be followed right to the pharynx. For a sinus representing the second cleft, better access may be had to the inner end of the tract by excising the ramus of the jaw as in the original Mikulicz pharyngotomy (see page 538). Unless the inner end of the tract is removed, leakage from the pharynx will cause a recurrence of the fistula. If the fistulous tract has been preserved intact as it is dissected toward the pharynx, and it is found impracticable to follow it to its natural inner opening, the following suggestion which we noticed in some medical journal may be followed:

At some convenient point of the neck the pharynx is opened, and the distal end of the fistulous tract is implanted into the pharyngeal mucosa. This may not absolutely prevent accumulation within the fistula; but accumulation is less likely to occur here than in a long-necked fistula, and both ends of the fistula will now discharge into the pharynx.

**Pharyngeal Pouches.**—The mucous membrane of the pharynx sometimes bulges laterally between the muscles. These may represent incomplete fistulæ that communicate only with the pharynx. According to Bruck, the lateral diverticula, seen in elderly persons, occur in connection with the upper part of the esophagus and are usually acquired.

### INJURIES OF THE PHARYNX.

The pharynx is sometimes severely burned from the swallowing of scalding liquids or caustics. Such injuries may, if the patient survives, be followed by severe scar contraction. The pharynx may be wounded by any sort of penetrating object, most commonly by sticks thrust in the mouth or by falling with a pipe in the mouth. If the wound is in the velum or posterior wall, little real damage is usually done, but if the velum is torn through its posterior border, it should be immediately sutured. A simple puncture needs no specific treatment. Wounds in the faucial pillars or tonsil are sometimes much more serious, as a large blood vessel may be injured, possibly with fatal hemorrhage. A stick or a pipe stem has been broken off in a lateral pharyngeal wound and for the time overlooked. Such a foreign body might give rise to an abscess or to subsequent fatal hemorrhage. Marrant Baker reports such a cause.

### ACUTE INFECTIONS.

**Acute Pharyngitis.**—This is most commonly associated with an acute infection of the nasal passages or may be a part of a general inflammation of the air passages, including the bronchi.

**Acute Tonsillitis.**—This may be of a simple catarrhal variety in which the mucous covering is red and swollen. In the follicular variety yellowish-white dots will be seen over the surface of the inflamed tonsil, which are evidence of suppuration and accumulations of epithelium in the mouths of the tonsillar follicles.

**Phlegmonous Pharyngitis.**—A phlegmonous inflammation may attack any part of the pharynx, due to a penetrating infection with pyogenic bacteria. The favorite site is in the retropharyngeal connective tissue or in the connective tissue around the tonsil. Suppuration within the tonsil, not confined to the crypts, is rather rare. The pharynx may be attacked by a true erysipelas, either primarily or as an extension from the skin. Phlegmonous inflammation of the pharynx may cause considerable swelling, and if this is in the neighborhood of the glottis, respiration may be so impeded as to necessitate tracheotomy.

**Tonsillar Abscess.**—This is usually unilateral, the tonsil becoming large and painful with general symptoms of suppuration; later, softening may be detected.



**Peritonsillar Abscess.**—In peritonsillar abscess the pillars and the neighboring parts of the velum and pharynx all become red and swollen, but the tonsil itself often shows little evidence of inflammation. Inspection is difficult; but if seen, the anterior pillar, half of the velum, and the uvula will be swollen and edematous, the tonsil being still little changed, but almost hidden. Half of the faucial isthmus will be blocked by the swelling. As the swelling increases, there is pain, increased by motion—such as moving the head, opening the mouth, and swallowing. There are the usual general symptoms of suppuration, and palpation will at first reveal a spot of greatest tenderness which corresponds to the focus of suppuration. Later a localized softening will be felt, which means that a distinct abscess has formed. If it is not opened artificially, the abscess usually bursts in a few days, when the symptoms will subside; rarely the abscess burrows into the retropharyngeal space. In one case that came to autopsy shortly after entering the City Hospital, the pus had burrowed along the prevertebral space down into the posterior mediastinum. A very large abscess may cause considerable dyspnea, and when it bursts or is opened, the pus may be aspirated into the larynx. A peritonsillar abscess has been known to ulcerate into the internal carotid artery, causing fatal hemorrhage. Tonsillar and peritonsillar abscess have a distinct tendency to recur in some persons.

**Treatment of Tonsillar and Peritonsillar Abscess.**—In the very early stages ice may be applied externally to the space under the jaw, and bits of ice may be dissolved in the mouth. As soon as a distinct spot of increased tenderness has been identified by palpating with the end of the finger, or if seen later and a softened spot can be detected, it should be opened. This can be done with little extra pain, after painting the surface with 10 per cent cocain. The site of election for opening a peritonsillar abscess is 1 centimeter above the anterior faucial pillar, which will be depressed and run rather horizontal. The knife should be guarded by wrapping the blade with cotton to within 1 centimeter of the point, so that it will cut but 1 centimeter deep. The incision is carried toward the midline. If pus is not formed, the patient will for a time be somewhat relieved, but the incision may have to be repeated. It is for this reason that many operators prefer not to open a peritonsillar abscess until it is well defined. A pair of round-nosed, narrow-bladed artery forceps, thrust into the wound and spread, will usually liberate the pus, if the original incision was anywhere near the abscess.

Persistent and severe hemorrhage might follow the opening of a peritonsillar abscess, but this is not liable to occur unless the incision was made very deep and far external. Bleeding may follow the spon-

taneous rupture of the abscesses, or, rather, the rupture may be due to hemorrhage, which results from necrosis of the wall of an artery. Arterial bleeding is most apt to be from the ascending pharyngeal or the internal carotid artery. If the bleeding cannot be controlled by packing, by the pressure of a Proebstring or Mikulicz-Störk tonsillar clamp, or by digital pressure—all of which are extremely painful in an inflamed area—resort should be had to ligating the external carotid low down, so as to control the ascending pharyngeal artery, and at the same time placing another ligature loosely around the part of the common artery. If the bleeding comes from the internal carotid, it will not be arrested by the first ligature, and the second will have to be drawn tight. Even the recurrent circulation from the upper end of the internal carotid might continue bleeding with a fatal termination. Ligation of the common carotid in young persons is not apt to be followed by serious consequences.

**Retropharyngeal Abscess.**—Retropharyngeal abscess causes the posterior wall of the pharynx to bulge forward. It may be caused by extension from a peritonsillar or a parotid abscess, suppuration in the temporomandibular joint, or by suppuration originating in the pharyngeal tissue. In children under five years there are some lymph nodes in the prevertebral connective tissue in front of the second and third cervical vertebræ, which later atrophy. When present, these are important etiological factors in the development of retropharyngeal abscess.

Retropharyngeal septic abscesses are usually preceded by a pharyngitis or tonsillitis, but the onset of the retropharyngeal inflammation may be very acute, or somewhat insidious, with symptoms, particularly in children, that are not very characteristic. There may be mild fever, malaise, disinclination to take food, and some swelling of the cervical nodes and throat, but a difficulty of swallowing and breathing and a tendency to cough after taking fluids may be the first symptoms that point to serious trouble. The difficulty of swallowing may be so great that fluids regurgitate through the nose. Later there will always be the general symptoms that accompany acute septic infection.

Examination will show a dusky redness of the pharyngeal wall, which is covered by a viscid mucus, and if palpated, it will be found to be bulging forward in some part, usually unilateral. The abscess may be low down, so that it can be detected only by palpation. In older children and adults the swelling may be seen with a laryngoscopic mirror, if the mouth can be opened sufficiently, but palpation is always the most efficient mode of examination. The swelling is felt to be circumscribed and, when pressed upon the pharyngeal wall, yields in front of the finger. The posterior pharyngeal wall normally rests

firmly against the border of the vertebra. True fluctuation cannot be elicited with one finger.

Secondary tubercular abscess usually follows after caries of the bodies of the spinal vertebræ. It rarely follows tubercular infection of the retropharyngeal lymph nodes. It is always subacute in onset and manifests itself mainly by pressure symptoms. If due to spinal caries, the characteristic stiffness of the cervical spine will be found. Unless there is a secondary pyogenic infection, the symptoms of an acute pus infection will be absent.

**Treatment.**—The secondary tubercular abscess is but an accident of the spinal disease, and is to be treated as part of the latter; incidentally it might be stated that a tubercular abscess should never be opened through the pharyngeal wall. A septic abscess not of tubercular origin should be opened through the pharyngeal wall if it has not begun to point in the neck, but if the latter circumstance has occurred, it might in some cases be opened from the outside.

The incision in the pharyngeal wall should be sufficiently free to insure free drainage and should be carried to the lower part of the abscess cavity. If the abscess is situated high up in older children, the incision may be made after painting the surface with 10 per cent cocain, or 20 per cent novocain; but in young children and in all cases where the abscess is low down, the incision had best be made under a general anesthetic. The blade of the bistoury is wrapped with cotton to within 1 centimeter of the point, and the abscess is localized with the index finger of one hand, as this serves as a guide to the knife. After puncturing the abscess, the incision is carried from above downward, or the reverse. The opening should be at least large enough to admit the finger. In one case of a large abscess that extended from the third to the sixth cervical body, in a child two years of age, we opened it at the upper end and, inserting the finger to the bottom of the cavity, pressed laterally into the neck. With the other hand and the help of an assistant, we dissected down to the finger from the outside and carried a drainage tube from the external incision well up into the abscess. It was held in place by a skin suture. This gave dependent external drainage.

If the abscess is large and there have been considerable dyspnea and coughing after attempts to take fluid, we believe it wise to precede the opening of the abscess by a laryngotomy for two reasons: (1) The sudden opening of a large abscess is apt to be followed by aspiration, if the child is struggling for breath. (2) The swelling and stiffness of the tissues around the entrance of the glottis allow fluids to enter the larynx, which accounts for the coughing that accompanies attempts to take fluids. It is safer to have the tube left in the larynx until the

child can swallow normally, and until this occurs, fluids should be given only with the child in inverted position.

### ADHESIONS OF THE VELUM AND FAUCES AND PHARYNGEAL WALL—STRICTURE OF THE PHARYNX.<sup>1</sup>

Adhesions and contractures of the pharynx may, according to their location, be divided into three kinds: (1) those in the neighborhood of the velum, which lessen or occlude the communication between the oro- and the nasopharynx; (2) those which form in the fauces, which lessen the size of the communication between the mouth and the pharynx; and (3) those which constrict the hypopharynx.

Adhesions and contractures may be in more than one part of the pharynx. Palate adhesions can be the result of simple inflammatory conditions of the mucous membrane, of deep ulcerations from syphilis, lupus, etc., of destruction by caustics, or of wounds, either accidental or the result of ill-devised operative measures. Some few cases have been congenital. The condition may be anything from a simple adhesion of one mucous surface to another, or adhesion of two bare muscular surfaces without the deposit of much fibrous tissue, to the union of broad masses of scar with deep destruction, infiltration, and distortion of the tissues.

Owing to the constant motility of the parts, simple adhesions of the mucous membranes are not liable to occur. When, however, there is deep ulceration, especially as the result of gumma, the subsequent contraction will distort the tissues, which in healing are apt to acquire abnormal attachments. Such attachments are especially liable to occur if the ulceration occupies apposing surfaces, such as the wall of the nasopharynx and the upper surface of the velum. Complete shutting-off of the nasopharynx may follow rather slight inflammation when there is a perforation of the palate, through which the patient breathes, which allows the inflamed fauces and velum to remain at rest.

Contractures at the junction of the nasopharynx and oropharynx may cause few symptoms, even when very extensive, but if the destructive ulceration and subsequent scarring approaches the Eustachian cushions, deafness may result.

If the stenosis is complete, unless there is palate perforation, there will be mouth-breathing, inability to blow mucus from the nose, and possibly insufficient aeration of the middle ear cavity. Usually there

---

<sup>1</sup>An exhaustive paper on the subject of adhesions in the upper part of the pharynx, including a history of attempts at correction, and the bibliographical references was presented by John A. Roe (Journal of the A. M. A., Vol. LIV, No. 3, page 185, Jan. 1, 1910) before the section on laryngology and otology of the American Medical Association.

is some modification of the voice. Contractures in the faucial isthmus and hypopharynx are never complete, for death would result from lack of food or air. There have been cases in which the faucial isthmus was the size of a lead pencil, or smaller, and in these the patient could take only liquid food. In stricture of the isthmus the tongue is usually drawn somewhat upward and backward. Stricture of the hypopharynx, due to swallowing caustic fluids, usually extends into the esophagus.

The practical points of interest in any case are: the extent and location of the adhesions upon which will depend the advisability of operative interference; and the amount of ulceration and scar infiltration that caused the adhesions. Upon the latter will largely depend the quality of the operative results. If they are the result of a simple adhesive inflammation, breaking-up of the adhesions and preventing their return will restore the normal condition. If there have been extensive loss of tissue and wide infiltration with hard scar, the operative results can at best be a poor compromise.

**Treatment.**—If the adhesions are due to agglutination of the mucous surfaces, simply freeing them with the finger or a blunt instrument and the repeated application of some unguent or silver leaf will be all that is needed. We have an analogous condition in an adherent prepuce. For the more serious conditions, due to loss of epithelium, to scar contraction, and malunion of the tissues, almost every conceivable scheme has been tried in the past, for their relief. In many of them the operator had apparently lost complete sight of the fact that where scar tissue is removed or cut, unless the raw surface be covered with epithelial tissue, contraction tends again to occur; and that where a raw, newly scarred area is continuous over two apposed surfaces, union of these surfaces is almost certain to result. The latter phenomenon is well illustrated in the difficulty in maintaining the cleft after separating webbed fingers.

Dilators have held a prominent place in these operations, but except in a very limited class, dilatation can be of very little good. If the scar tissue remains, the dilator would have to be used for an indefinite period.

If, by some mechanical means, small isolated or narrow linear raw surfaces can be prevented from coming in contact with other raw surfaces until after the neighboring epithelium has been drawn, or grown over them, then some good will have been accomplished. Packing, dilators, and the pressure of bands passing around the velum from the nasal to the oral cavity have all been used for this purpose. For incomplete shutting-off of the nasopharynx, by adhesions at the posterior border of the velum, Nichols proposed the application of the old

plan that has been used in operating on webbed fingers. It consists in introducing a silk strand through the outer part of the adhesion, the strand transfixing the tissues that separate the nasal from the oral pharynx. The nasal end of the suture is drawn down through the still patented opening, and the silk is tied loosely in the form of a ring. This procedure is a counterpart of the plan of placing a silk ligature in the lobe of the ear after piercing it. It is allowed to stay in place until an epithelization of the tract has occurred, and then, without wounding the outer wall of this tract, the palate is cut loose from the pharynx. It seems to us that the best plan to protect this new epithelial tract and to make certain that the incision opens it accurately would be to pass a probe through the tract and cut down upon the latter. Roe used silver wire for the same purpose in three cases.

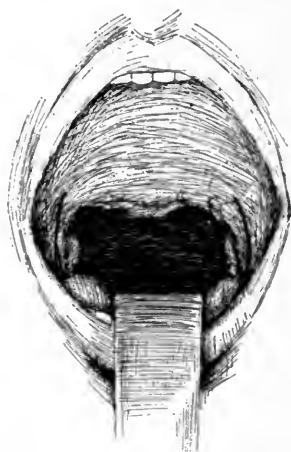

Fig. 350. Line of incision for using the anterior faucial pillar for covering raw surface on the nasopharynx or velum.

This plan is applicable only when the adhesion is small or the line of adhesion is narrow and not infiltrated. A quicker result under such circumstances might be obtained by exposing the nasopharynx by splitting the velum in the midline and freeing the adhesions. Then obliterate the raw surfaces on the velum by suturing the edges of the mucous membrane over the defect with fine tannated catgut, and repair the split velum (Fig. 350).

Where the ulceration has been deep and extensive, as much of the constriction will be due to contraction and distortion as to adhesion. These are most difficult cases to relieve by operative measures. As a rule, if there is a fair breathing space, an operation is not indicated, unless perhaps it be to enable the aurist to use the Eustachian catheter. If the tongue is bound up so as to interfere with function, the scars

may be dissected out and replaced with flaps turned from the cheeks. If it is deemed advisable or essential to separate the velum from the pharyngeal wall, it may be done with an angular knife, or scissors, after splitting the velum.

With a stricture limited to the faucial isthmus, it is a comparatively simple thing to excise sufficient scar tissue to give a free opening and to cover the resulting raw surface with a flap of mucosa from the cheek, or even a flap of skin and subcutaneous tissue turned from the neck through a high lateral pharyngotomy wound. In the lower part of the oropharynx, or in the hypopharynx, strictures are best treated by the use of dilators that will maintain the patency of the canal. These, however, must be so constructed as to permit breathing while they are in use. When the contractures are thick and firm, it may be necessary to precede dilatation by cutting the bands, either through the mouth or by a lateral pharyngotomy wound. After cutting the bands, or excising the scar from the hypopharynx, it would be a safe plan to pass a dilator at regular intervals. But from the reported cases, it would appear that there is not the same tendency for the stricture to return in the lower pharynx as there is near the velum, and in most cases simple cutting of the bands has been sufficient.

**Prognosis.**—In cases where inconvenience is caused by contraction and distortion of the fauces or the hypopharynx, operative interference and dilatation may be undertaken with the hope of relieving the condition.

The same is true of all palate adhesions where there has been little loss of tissue and but slight deposit of fibrous tissue. But where the velum and pharynx are incorporated in a thick mass of scar tissue, all that can be accomplished is to establish a breathing and feeding space. If these are already present, the case had best be let alone. The operation is not free from danger, and is liable to be followed by a post-operative discomfort out of proportion to the good accomplished.

## CHAPTER XXXIX.

### TUMORS OF THE VELUM, TONSILS, AND PHARYNX.

A number of varieties of tumors occur in the pharynx and in the velum. The inaccessibility of the pharynx and its close proximity to essential nerves and vessels and to the spinal column are apt to render malignant growths inoperable in a comparatively early stage of their growth.

#### TERATOMATA.

Teratomata occurring in the soft palate or pharynx have the following peculiarities: They usually take the form of pedunculated skin-covered tumors, the central part consisting of a solid core of connective tissue, bone, cartilage, and a variable amount of striped muscle tissue. The skin is usually beset with hairs, and sometimes the tumor contains teeth. The tumors are usually small and pedunculated; it may be difficult to tell if a certain one originates from the base of the skull or the palate. Sometimes they are sessile below, but may project through the floor of the pituitary fossa, causing local intracranial pressure.

It is noteworthy that pedunculated skin-covered and pilose tumors are found only at the two extremities of the notochord, in the nasopharynx, and near the rectum. In describing these, Bland-Sutton points out their probable relation to dichotomy, which may be limited to the bones of the face, in which case the supernumerary maxillæ may fuse together, impacted in the nasopharynx and fixed to the base of the sphenoid bone. He has described specimens, mostly in the Royal College of Surgeons' Museum, showing various degrees of this condition, from a well-formed maxilla with unerupted teeth to a conglomerate mass of bone teeth and cartilage impacted in the palate and firmly fixed to the base of the sphenoid bone. In one case in which two pigs were attached to each other by the lateral aspect of their heads, every part was complete in duplicate, except the mandibles. After a careful search, the missing pair of mandibles were found hanging in the pharynx as a teratoma.

The treatment of these tumors is removal; the ease or difficulty of this will depend very much upon their size and attachment. Some are attached by stalks or pedicles that are easily severed. Sometimes they apparently take their origin from the palate, but really arise in the



nasopharynx. The nasopharynx can be exposed by splitting the velum, with or without removing part of the bony palate (page 238).

### BENIGN TUMORS.

Papilloma, fibroma, angioma, lipoma, osteoma, and enchondroma occur and give few symptoms except those due to their size. Papillomata may be single or multiple about the oral part of the pharynx, may have smooth or cauliflower-like surfaces, and may be from the size of a pinhead to a pea. On the tonsil they may be in the form of a pedunculated growth that shows tonsil structure. Retention cysts may occur, arising in the roof of the pharynx, due to blocking the median recess. If by their size any of these tumors cause annoyance, all but the angiomata and the retention cysts may be excised.

**Vascular Tumors.**—Vascular tumors are not uncommon in this region and are more commonly composed of blood vessels than lymphatics. Of the blood-vessel tumors, the cavernous angiomata are the most common and are more frequently situated upon the edge of the velum and palate arches. They may become very large, extending beyond the limits of the pharynx, and are then a menace to life on account of hemorrhage.

The treatment of these is probably best done by the use of the electric or actual cautery punctures, with a needle at a dull-red heat. It usually requires a number of treatments to obliterate the tumor. The lymphatic angiomata may occur here as well as on the tongue, and are subject to recurrent attacks of inflammation. If they cannot be excised, they might be treated with the electric cautery, and at a time when the tumor is not acutely inflamed. Excision is preferable.

Racemose and true aneurysm may occur. The former rarely causes severe trouble. The latter may arise from the internal maxillary or other branches of the external carotid. Probably the best treatment of true aneurysm in this situation is ligation of the vessels that supply it. Varicose veins are more common on the pharyngeal surface of the tongue, but may occur on the pharyngeal wall. As a rule, they give rise to few symptoms, but when indicated, they can be treated as cavernous angiomata.

Kümmel calls attention to certain lipomata and fibromata originating near the laryngeal opening, and tending to grow in finger-like processes that may hang down into the larynx or the esophagus. They may cause asphyxia, or other less serious symptoms. Becoming spontaneously detached, they may be coughed up or swallowed. If their point of origin be made out, they can be grasped with forceps at the base and torn loose.

There are three other recognized groups of tumors relative to the

pharynx that are usually benign, are rare, and for one reason or another are of particular interest: the palate adenoma, the nasopharyngeal polypus, and the retropharyngeal tumor, most commonly called goitre.

### PALATE ADENOMA.

Palate adenoma, so designated by Bland-Sutton, but is described by Bruck simply as intramural tumor. They are very rare and occur either at the posterior part of the hard palate or in the velum. They may vary in size to several centimeters across, and usually possess perfect capsules, from which they are easily enucleated. The benign non-ulcerated cases are to be distinguished from gummata by the fact that the tumors are freely movable under the mucous membrane. But this may rupture, in which case the tumor resembles a gumma or malignant growth. From their exposed position, they are somewhat prone to ulceration, forming deep crater-like ulcers and causing a marked odor. Their structure is complex and variable, and they are difficult of classification. They have been placed among the dermoids, teratomata, and salivary gland tumors. According to Bland-Sutton, they may show glandular tissue with ducts buried in the struma that resembles sarcomatous tissue. Epithelial pearls may be present, some being keratinous. Myxomatous tissue may be present, and also lymphoid follicles.

No doubt, encapsulated tumors of various kinds have been included under the head of palate adenoma, but there seems to be good reason for the belief that the majority of them bear a somewhat close relation to mixed salivary gland tumors. They occasionally, after a prolonged benign course, show very marked malignancy, which is a distinct characteristic of the mixed salivary gland tumors. Kümmel states that the palate tumor may have its origin in the parotid, extending into the velum through the wall of the pharynx. The tumors may appear at puberty, but usually between the thirtieth and fiftieth year.

**Treatment.**—They are almost always benign, and their treatment consists simply in enucleation. Those that have taken on or show malignancy will have to be treated accordingly.

### NASOPHARYNGEAL POLYPUS OR NASOPHARYNGEAL FIBROMA.

This is a non-malignant fibroma that usually arises in the roof of the nasopharynx from the cartilage of the occipital bone, and follows a peculiar clinical course. They occur almost exclusively in males at about the age of puberty. They grow at first within the nasopharynx, the nasal fossa, and pharynx, but later perforate through the sphenopalatine foramen, and invade the sphenomaxillary fossa, the orbit, maxillary antrum, and zygomatic and temporal fossæ, and ac-

quire new attachments as they grow. In this form they have been described by Langenbeck as retromaxillary tumors (page 366). The tumor can cause absorption of the bone and in this way may penetrate the skull and invade the cranial cavity or the palate. We have seen pieces of the tumor attached to teeth that were extracted because the wall of their sockets had become invaded. At the age of twenty or twenty-five years they tend to stop growing and even retrograde. In some cases they are said to have become sarcomatous. Although from the fact that they do not cause metastasis they must be regarded as benign, still from their location and their peculiar habit of forming new attachments they are, when extensive, extremely difficult to eradicate.

Histologically the polypus consists of dense fibrous tissue, but the vessels may be very numerous; and when the growth protrudes from the nostril, it presents a soft, red, easily bleeding mass. If the tumor perforates into the skull, there may be signs of intracranial pressure.

**Treatment.**—Treatment of the intrapharyngeal growths should be their complete removal and the destruction of the base with the electric or actual cautery. This procedure would be facilitated by splitting the velum and even removing the palate processes. The treatment of the more extensive growths was discussed under retromaxillary tumors (page 367).

### RETROPHARYNGEAL GOITRE.

This is described by Bruck as a tumor behind the lower part of the pharynx, arising from a lateral lobe or an aberrant part of the thyroid gland. Hajek saw one and Braun two supernumerary thyroid glands in this region. It is a slow-growing tumor that does not cause trouble until it reaches a certain size and bulges forward the posterior wall of the pharynx. The tumor is very vascular, and if it perforates the pharyngeal wall, may cause hemorrhage, or become inflamed. In a case of Wölfler's, the tumor did not develop until an enlarged thyroid lobe had been removed. If examined through the pharyngoscope, it is seen to move up and down in swallowing. Unless it arises from an aberrant thyroid, it can be moved laterally only in one direction, owing to its attachment to the lateral lobe of the thyroid gland. It can be made to produce a bulging at the side of the neck, at the level of the thyroid cartilage. It might at first be mistaken for a retropharyngeal abscess, but the latter is not movable.

The treatment is removal by an operation, the tumor to be approached as in a low lateral pharyngotomy. If there is any suspicion that there is a deficiency of thyroid in the normal position, the tumor should not be removed, but displaced with an intact blood supply in a part of the neck where it will not cause obstruction.

Busch has called attention to other benign retropharyngeal tumors, fibromata, enchondromata, and mixed tumors. They belong to the connective tissue group, are well encapsulated, easily enucleated, and bear some resemblance to the adenomata of the velum and palate. Unless ulcerated, they cause symptoms only from their size. If very freely movable and their mucous covering is thin, they can be removed through the mouth, but otherwise they should be approached from the outside. Extrapharyngeal malignant tumors can press upon or involve the pharynx, and we have seen swallowing almost precluded from enlargement of the lymph nodes in Hodgkin's disease.

### MALIGNANT TUMORS OF THE PHARYNX.

The nasal and oral portions of the pharynx are much more commonly the seats of malignant disease than is the hypopharynx. The most common tumor of the pharynx is carcinoma, and except when due to extension from the tongue, it is usually of the medullary variety. It originates most commonly in the neighborhood of the tonsil, but may spread rapidly. Here, as well as elsewhere, carcinoma tends to ulcerate early, does not attain the size to which sarcoma grows, and early affects the lymph nodes. In this way they may often be differentiated clinically. When seen early, they may be removed, and a radical operation done upon the regional lymph nodes.

Lymphosarcomata may develop from either the faucial or pharyngeal tonsil, or from any of the collections of lymphoid tissue of the pharynx. Störk describes their appearance as an enlargement that at first cannot be distinguished from ordinary hypertrophy, unless perhaps it is somewhat whiter and more nodular. With this there may be a pale, somewhat hard, and edematous thickening of the neighboring mucous membrane. The tumor may attain considerable size, but before it does so, neighboring and distant lymphatic infections become evident. The general picture assumes that of pseudoleucemia. Death from this type of tumor, like that from carcinoma, is very painful. Unless seen very early, treatment is of little avail. When seen early, a free excision of the tumor and of the neighboring lymphatics should be made.

Sarcomata, round and spindle cell, are of more frequent occurrence than lymphosarcomata. They present the usual characteristics of sarcoma, especially considerable growth without ulceration. They rarely affect the lymph nodes, but it is very common to find the latter enlarged from inflammatory irritation.

The treatment is excision, if the tumor is still accessible, and possibly the use of Coley's toxins. Some brilliant results have been claimed for both radium and the x-ray, but we are not ready to express an opinion in regard to their value.

In the hypopharynx both carcinoma and sarcoma occur, but they are rare and when they arise low down are usually difficult of diagnosis. If, in making the inspection with a laryngoscopic mirror, the larynx is drawn forward, the tumor may become evident. A pharyngoscopic examination would reveal such a growth when present. Kümmel warns against the passage of a bougie, and claims that there is no circumstance under which the pharynx is more easily perforated.

Malignant tumors in this situation, unless seen very early, promise little with operation. X-ray, radium, and toxins may be tried. Laryngotomy and gastrotomy may be done when the occasion arises, but as Kümmel states, the best treatment is the continuous use of morphin.

### PHARYNGOTOMY.

Operative invasion of the pharynx may be necessitated by cicatricial contraction, imbedded foreign bodies, and new growths—the last being the most common reason. Pharyngeal constrictions have been considered previously. Except in operations in the nasopharynx, it is safer to do a preliminary tracheotomy or laryngotomy and to pack the lower part of the pharynx. When the pharynx is to be laid widely open, it may be advisable to put the packing in the opening of the larynx after painting the entrance with cocain. In choosing the position on the operating table, the same considerations hold as in operating on the tongue (see page 494).

In carcinoma, lymphosarcoma, and some of the sarcomata the regional lymphatics should be removed (see page 516). Kümmel gives the location of the lymphatics primarily related to various parts of the pharynx, as follows:

Tumors arising above the velum affect the retropharyngeal nodes. In case of tumor originating in the piriform sinuses, the aryepiglottic fold, and the posterior wall of the larynx, and consequently the anterior wall of the hypopharynx, the glands situated between the superior border of the thyroid cartilage and the hyoid bone are first affected. Later, all of the deep glands of the neck are affected.

As with carcinoma of the tongue, however, it is better to remove all of the lymphatics *en masse*, including the whole of the deep cervical chain. When possible, it is preferable to do the operation in two stages, as in operating on the tongue, but in external operations through the neck, the removal of the growth and of the lymph nodes is usually done at one operation.

**Intraoral Removal of a Malignant Growth of the Tonsil and Velum—Operation Through the Mouth.**—The following operation is taken from Jacobson:

This method can only be made use of: (a) in a very early stage of tonsillar new growths, when there is no evidence of glandular enlargement; or

(b) when epithelioma of the tonsil coexists with a similar condition of the tongue.

If the following operation seems somewhat severe, the infiltrating tendency of growths here must be remembered.

In most cases the surgeon will do well to avail himself of the help given by the following preliminary steps: (1) laryngotomy and plugging the fauces with a sponge, placing a temporary loop around the common carotid; (2) slitting the cheek.

The patient's head being suitably raised and supported in a good light, the cheek on the affected side is divided from the angle of the mouth to the masseter, and the two ends of the facial artery tied and twisted. The mouth is now kept widely open by a gag inserted on the opposite side, the tongue drawn out of the mouth, and the masseter pulled backward by a retractor. As much room and light as possible being thus obtained, the surgeon divides the soft palate first in the middle line, and then from within outward with scissors; he next, either with the same instrument or with a blunt dissector and his nail, dissects around and carefully enucleates the tonsil with the pillars. The whole operation should be deliberately carried out, the surgeon cutting wide of the growth and encroaching on the tongue, etc., if needful. Bleeding will be best arrested by temporary forceps pressure and firm sponge pressure.

Where the growth is at all cauliflower in its prominence, the chief part may be first removed with a heated wire or with the Paquelin cautery, so as to get more room in dealing with the base. And if the surgeon so prefer, he may do the whole operation with cautery instead of scissors. In any case the cautery must be used at a dull-red heat only, for fear of hemorrhage. The surgeon must be prepared for its leaving indurated tissues which may simulate deposits of growth, and for the tendency of the instrument, as it is quickly cooled down by its contact with succulent tissue, to stick to them. A little additional heat frees it at once, far more satisfactorily than pulling it away. I prefer to limit the cautery, if used, to searing thoroughly the surface of the wound.

Mr. Butlin points out that some of the new growths met with here are so easily separable, so circumscribed, if not encapsuled, that there is not the least difficulty in shelling them out.

**High Lateral Pharyngotomy.**—This and the low lateral pharyngotomy should be preceded by laryngotomy. If the growth is not movable on the pharyngeal wall, or if situated too low down to be reached from within the mouth, then the operation of von Mikulicz may be resorted to. It consists in gaining access by the excision of one ramus of the jaw. This operation is susceptible to many modifications, but the general principle is the same. No deformity or impairment of function results from the excision of the ramus, and the field is better displayed than by simply dividing the bone. One plan of doing this is as follows:

The cheek is split from the corner of the mouth straight back to the masseter muscle. If this does not give sufficient room, the posterior end of the cheek cut is continued downward and backward to

the lower end of the posterior border of the jaw. The posterior end of this cut severs all of the tissues down to the bone. This latter cut divides the branches of the cervicofacial division of the seventh nerve, which leaves the lower lip and platysma muscle paralyzed on that side. This is not a very evident deformity. With a periosteal elevator the masseter muscle is raised from the outer surface of the ramus until the neck of the condyle is exposed. With a wire saw the jaw is cut through at the junction of the body and ramus, the line of the cut running downward and backward. The ramus is tilted outward, freed subperiosteally from the structures on its inner surface, and finally twisted out of the socket. The inferior dental artery and nerve will be cut or torn, and the former may have to be caught and twisted. It is easier to cut the coronoid process with forceps than to separate the tendon of the temporal muscle.

The removal of the ramus leaves the outer surface of the internal pterygoid muscle exposed, upon which lie the lingual and mylohyoid nerves. The tonsil lies upon the mesial surface of the lower part of this muscle, separated from it by the muscular wall of the pharynx and the styloglossus muscle. The internal pterygoid may be drawn forward or backward, or it may be cut transversely, or excised with a growth. In making a block excision, it is to be remembered that the hypoglossal nerve skirts the pharynx at the level of the lower border of the jaw, when the latter is in its normal position. Moreover, the internal carotid artery lies  $1\frac{1}{2}$  centimeters behind the tonsil. If the excision is to be extensive, especially in the posterior and upper part of the pharynx, it is a safe plan to put a provisional ligature around the common carotid that can be drawn tight if needed.

In the original Mikulicz operation, the incision extends from the mastoid process downward and forward to the greater cornu of the hyoid. The ramus of the jaw is exposed on its inner and outer surfaces without cutting the facial nerve. After excising the ramus, the jaw is drawn aside, the masseter and internal pterygoid muscles are drawn forward, and the digastric and stylohyoid are drawn downward and backward. Then the surface of the wound corresponds very closely with the region of the tonsil. When the lateral wall of the pharynx is divided, access is obtained to the palate tonsil, base of the tongue, and pharyngeal wall. By dividing the stylohyoid and digastric muscles and hypoglossal nerve, entrance to the larynx is made accessible. The splitting of the cheeks gives the operator a more forward view. If the procedure first described does not give a sufficiently low exposure, the incision can be carried below the angle of the jaw to the middle of the upper border of the hyoid bone.

In opening the pharynx in this region, the following structures from

above downward will be encountered: the stylohyoid and digastric muscles, the hypoglossal nerve, hyoglossus muscle, and lingual artery. In repairing the wound, the divided structures are sutured wherever possible. If the defect in the pharyngeal wall is not too great, it is closed with chromic gut, but the wound in the neck is either left open and packed, or it is closed with very free drainage. For a low exposure of the pharynx von Langenbeck's lateral pharyngotomy is more appropriate.

**Low Lateral Pharyngotomy.**—The incision is made along the anterior border of the sternomastoid from the mastoid process to below the cricoid. The platysma muscle and deep fascia are cut through. After separating the tissues and drawing the carotid sheath backward, the lingual and superior thyroid arteries and the several veins are doubly ligated and divided. By means of a curved steel sound passed into the pharynx through the mouth, the lateral pharyngeal wall is pushed into the wound and incised. It is not practical to pack the pharynx until it has been opened and explored. The edges of the wound are caught with clamps, and the finger is passed into the pharynx, the wall of which can then be divided as far as necessary. Just below the jaw the visual field is small. It can be enlarged by extending the incision transversely forward above the hyoid bone, which renders the area of the piriform sinuses very accessible.

In low lateral pharyngotomy both the external and internal branches of the superior laryngeal nerve will probably be divided. The internal branch passes forward deep to the external carotid artery, crossing the outer surface of the posterior part of the greater cornu of the hyoid from behind downward and outward. Cutting this nerve may cause severe shock, and it has been advised to block it with cocain before dividing. The nerve is small, and it might be painted with a 20 per cent solution of novocain.

In approaching a cancerous growth by a lateral pharyngotomy, the regional lymphatics should be removed before the pharynx is opened. If the condition of the patient did not warrant a continuance of the operation after the pharynx was exposed, the edges of the skin wound might be sutured to the pharynx along the line of the proposed pharyngeal incision, or the lateral spaces left after removing the nodes might be obliterated with buried catgut sutures, the wound over the pharynx being dressed open. At a subsequent date the pharynx could be opened, and the operation completed.

In making repair, if possible, the pharyngeal wound should be closed, but it is advised to pack the external wound. V. Bergmann has suggested suturing the pharyngeal wall to the skin. This has two immediate advantages: (a) it allows free escape of the secretions, and



(b) the patient can be conveniently fed by a catheter passed through the wound. Later an operation might have to be done to close the pharyngeal fistula. If the pharyngeal wound is to be sutured, Kümmel suggests the passing of a soft catheter through the nose down to a point below the pharyngeal wound, holding it there with absorbable catgut suture. Through this tube the patient can be fed. Preliminary gastrostomy may be done, but it is an extra and we believe unnecessary operation. In a case of ours, an infection at the gastrostomy wound so long delayed the real operation as to render it evidently useless.

The tracheal tube should be left in place until all active inflammation has subsided. Kümmel cites a case of his, in which tracheotomy was not performed, the patient dying of edema of the glottis fourteen days after operation, before tracheotomy could be done.

The operations of approaching the pharynx from the front by a transverse suprahyoid or infrahyoid pharyngotomy have fallen somewhat in disrepute for two reasons: (1) they do not furnish free access; and (2) they are more apt to be followed by phlegmonous inflammation of the neck. The infrahyoid pharyngotomy has the further disadvantage that on one side the incision must not extend closer than 1.5 centimeters to the extremity of the hyoid bone. Otherwise both internal laryngeal nerves might be cut, causing anesthesia of the larynx, and predisposing to pneumonia.

Kocher recommends transverse pharyngotomy for reaching the neighborhood of the epiglottis and the base of the tongue. If a transverse pharyngotomy is performed, either primarily or in conjunction with a lateral approach, all but the deepest part of the wound should be left opened and packed. (For exposure of the nasopharynx by splitting the velum, see page 238.)

## CHAPTER XL.

### LIGATION AND TEMPORARY CONSTRICTION OF THE ARTERIES.

In all extensive operations about the mouth the prophylactic control of hemorrhage is important, both on account of the saving of blood and because it lessens the danger of aspiration pneumonia.

The permanent ligation of the common carotid artery is an operation that should never be done without necessity. In young subjects with soft arteries it is supposed to be free from danger, but we have seen very severe, though not permanent, brain disturbance result from the ligation of the common carotid artery in a boy nineteen years old. In older persons it is a procedure fraught with the gravest dangers both to brain function and to life, and as Kocher expresses it: "ligature of the common carotid artery in an old man with arterial sclerosis is equivalent to a death sentence."

In the days when every wound was expected to become infected, it was customary to ligate arteries only at a distance from a large branch or trunk. This was done with the idea that when a long clot could form in the vessel there was less likelihood of secondary hemorrhage occurring from ulceration at the site of ligature. This was a common cause of death in those days after the ligation of large vessels. The fact that the external carotid gives off many large vessels within a centimeter or two of its origin deterred the earlier surgeons from ligating it. With clean wounds the danger of secondary hemorrhage is eliminated. The death rate from the ligation of the common carotid is between 10 and 20 per cent, while brain disturbances occur in about 25 per cent. For prophylactic purposes the choice lies chiefly between ligation of the external carotid and temporary compression of the common artery, but in certain limited operations on the face or tongue the facial or the lingual artery may be separately controlled. Even the control of one external or one common carotid may not sufficiently limit the peripheral bleeding, on account of the free anastomosis between the vessels. This is especially liable to be the case when the arteries are dilated from sclerosis. In these cases we have introduced the procedure of ligating the external carotid on one side and temporarily compressing the common carotid on the other. This, as a rule, gives an almost bloodless field. In tying or compressing an artery, the

ligature should be applied with just sufficient pressure to occlude the vessel, but none of its coats should be damaged.

### CORONARY ARTERIES.

These are never tied except at a wound, but may be conveniently temporarily compressed by forceps that grasp the full thickness of the lip. The forceps are not to be locked, but may be held in position by winding a silk ligature around the handles.

### TEMPORAL ARTERY.

This artery is practically never tied except in an open wound, but it may be compressed by surrounding it with a silk ligature, without making an incision, by passing a full-curved or half-circle needle around it down to the zygoma immediately in front of the ear.

### FACIAL ARTERY.

This artery may be temporarily compressed by passing a ligature around it in the same manner as the temporal. The ligature must be strong, as it includes a quantity of tissue besides the artery, and must be tied tightly. The artery crosses and lies close to the lower border of the body of the lower jaw at the anterior border of the masseter muscle. It may be ligated at this site by making an incision 2 centimeters long, parallel to the lower border of the bone. The skin, platysma, and fascia are divided, and the artery is exposed by drawing back these structures with sharp hooked retractors. The inframaxillary branch of the facial nerve lies below the border of the jaw. The artery is accompanied by the facial vein. (For ligation of the facial artery at its origin, see External Carotid Artery.)

### LINGUAL ARTERY.

In the first and second parts of its course this artery bears a close relationship to the upper border of the greater cornu of the hyoid bone. As a prophylactic measure before operation on the tongue, or to control bleeding from the tongue, such as from carcinomatous ulceration, it is usually tied in the second part of its course. An incision is made along the upper border of the greater cornu from just behind the angle of the jaw to the body of the hyoid bone. This incision extends through the skin, platysma, and fascia; then these structures are forcibly retracted.

The facial vein often passes downward and backward across the exposed field, and it may be convenient to doubly catch and cut and ligate it. The lower border of the submaxillary salivary gland appears beneath the upper border of the wound. This is to be freed and drawn

upward with a broad-curved retractor. By this means the triangle, formed by the midtendon of the digastric muscle below and the hypoglossal nerve above, will be exposed just above the hyoid bone. It is through this triangle that the lingual artery is to be usually exposed. To render this field more accessible, Kocher recommends that first the hyoid bone is pressed up from the opposite side, and after exposing the greater cornu, it is seized with a sharp hook and drawn forward. In this way the field is made more superficial. From the upper border of the posterior end of the greater cornu, the fibers of the hyoglossus muscle are seen to ascend vertically. The hypoglossal nerve lies on the superficial surface of this muscle, but anteriorly disappears under the posterior border of the mylohyoid muscle. The lingual artery lies deep to the hyoglossus muscle in this triangle. It is usually exposed by carefully cutting through this muscle in the triangle and retracting the fibers as they are cut. The artery rests upon the middle constrictor muscle of the pharynx. Kocher exposes the artery by incising the hyoglossus muscle just above the thickened posterior extremity of the cornu, behind the tendon of the digastric and the stylohyoid muscle, and below the hypoglossal nerve. By so doing, he also controls the dorsal branch. (For ligation of the lingual artery at its origin, see External Carotid Artery.)

### EXTERNAL CAROTID ARTERY.

To expose this, we use Kocher's normal incision, which runs from the anterior part of the apex of the mastoid process to the body of the hyoid bone, passing a finger breadth below and behind the angle of the jaw. By making this incision pass two finger breadths below the angle, a better exposure is obtained. The origin of the artery lies under the anterior border of the sternomastoid muscle at the level of the upper border of the thyroid cartilage. It is much more common practice to run the incision from the mastoid process to the cricoid cartilage along the anterior border of the mastoid muscle, but this gives little better exposure and leaves an unsightly scar. The skin and platysma muscle are incised, and these tissues are forcibly retracted with sharp hooked retractors. By this means 5 centimeters of the anterior border of the sternomastoid muscle should be exposed. In the posterior part of the wound the external jugular vein and the great auricular nerve lie upon the sternomastoid. The deep layer of the cervical fascia is incised along the anterior border of the sternomastoid, the latter being freed and retracted. The common facial vein is seen passing downward and backward over the posterior belly of the digastric and stylohyoid muscles to join the deep jugular. It lies superficial to the arteries and may be retracted downward, but more room is

gained by doubly catching it with forceps, cutting and ligating it. The origins of both the external and internal carotid arteries are now exposed (Fig. 346). The internal carotid lies posterior and slightly superficial to the external carotid, and can usually be further identified by the fact that it rarely gives off branches. The internal carotid artery occasionally springs from the arch of the aorta, or one or more branches, usually derived from the external carotid artery, may arise from it. The external carotid artery gives off in its exposed portion: the superior thyroid artery, which runs forward and downward below the level of the cornu of the hyoid bone; the lingual, which runs above the cornu; and the facial and the occipital arteries, which run forward and backward respectively at the level at which the hypoglossal nerve crosses superficial to the external carotid. There is a small sterno-mastoid branch which bends downward over the hypoglossal nerve, while the ascending pharyngeal lies deep to the main trunk of the external carotid. In passing a ligature around the trunk, the artery must be first carefully freed and then raised with the aneurysm needle or blunt elevator; otherwise the descendens hypoglossi nerve, which lies posterior and superficial to it, or the superior laryngeal nerve, which crosses beneath the artery at this level, might be included in the ligature. In order to avoid the danger of wounding the artery just at the bifurcation, we prefer, where possible, to pass the ligature between the superior thyroid and the lingual arteries, which has the further advantage of shutting off one source of recurrent circulation.

It is not easy to place a Crile clamp on the external carotid artery, but it may be temporarily constricted as follows: A very fine piece of elastic rubber tubing or a thin strip of dam is passed under the artery as a ligature. A silk ligature is laid lengthwise on the artery, and the two ends of the dam strip are crossed over the artery and the ligature with just the proper tension. The silk ligature is then tied around, and holds the two ends of the dam where they cross each other. To release the constriction, the silk ligature can be cut without endangering the artery. Usually, however, for prophylactic control, one external carotid is ligated, and a Crile clamp is applied to the opposite common carotid.

All of the four larger branches, the superior thyroid, the lingual, the facial, and the occipital arteries, can be ligated separately, and the continuation of the trunk can be exposed by drawing up the muscular mass composed of the stylohyoid and the posterior belly of the digastric. This is done in Dawbarn's operation for the starvation of malignant growths. The upper end of the common carotid artery is exposed by this same incision. A provisional ligature can be placed around it, and it can be ligated here in case of accident to the origin of the external

carotid, or when hemorrhage is due to damage to the internal carotid. In one case where we were attempting to ligate the external carotid in a mass of scar resulting from a previous operation, the trunk tore close to its origin, and we were forced to ligate the common artery.

### COMMON CAROTID ARTERY.

The artery may be conveniently compressed against the transverse process of the sixth cervical vertebra at the level of the cricoid cartilage. For this reason, this process is called the carotid tubercle. Pressure is applied by placing the thumb against the side of the cricoid cartilage and pressing straight backward. It may be ligated in its upper part through the incision just described, but it is much more easily exposed lower down in its course. Opposite the cricoid cartilage is the site of election. As with the external artery, it is usually exposed by an incision along the anterior border of the sternomastoid, but here, as in exposing the external carotid, the transverse incision is preferable. The common carotid artery ascends in the neck in a line that passes from the sternoclavicular articulation to the angle of the jaw. A transverse incision at least 7 centimeters long is made at the level of the cricoid cartilage, with its center corresponding to the anterior border of the sternomastoid muscle. The skin and platysma are cut through and drawn upward and downward with sharp hooked retractors, which exposes the sternomastoid and sternohyoid muscles. If the superficial cervical nerve is seen crossing the sternomastoid transversely, it is to be drawn upward. The fascia is to be divided along the anterior border of the sternomastoid, and the latter is retracted, exposing the long slender belly of the omohyoid muscle, which here runs downward and slightly backward. The artery still remains hidden by a second layer of fascia, the carotid sheath, and is to be found by splitting this sheath in the angle between the omohyoid and the sternomastoid. In doing this, the descendens hypoglossi which lies on the sheath is to be drawn forward. On splitting the sheath, the artery is exposed. Posterior to it and slightly overlapping it is the internal jugular vein; between these lies the vagus nerve, while the trunk of the sympathetic nerve lies deep to the artery. The aneurysm needle is passed from behind forward, avoiding these structures. In applying a Crile clamp for temporary compression, it is well to raise the artery with an aneurysm needle.

## CHAPTER XLI.

### MOTOR DERANGEMENT.

Motor abnormalities are of two general kinds: paralytic, and spasmodic.

#### PARALYTIC AFFECTIONS.

If the cortical cells in the motor area of the brain, or any of the conducting paths between these cells and the muscle they innervate, are interfered with, there will be a partial or complete paralysis of that muscle. This may be due to a destruction of or pressure upon the motor cells. It may be due to destruction of or pressure upon the conducting paths within the brain; or it may be due to section of or pressure upon a peripheral nerve. In any case the result will be the same. Motor impulses can no longer reach the muscle; therefore voluntary contractions are no longer possible. At first such a muscle can be made to contract by some local stimulus. Later, however, if the lesion is situated below the motor nerve nucleus, the muscle will degenerate. After complete division or blocking of a motor nerve, atrophy of the muscles follows quickly, and deformities are not uncommon. The latter may be due either to the unopposed action of other muscles, or to shortening of the paralyzed muscle during atrophy. The condition of the motor nerve of a muscle is best determined by electrical tests.

**Electrical Tests.**—The faradic current stimulates the nerves directly, and the muscles only indirectly. Therefore, if the nerve has degenerated, there will be no response from the faradic current. The galvanic current stimulates both the nerve and muscle, causing a contraction as the current is turned on, and another as it is cut off. Only a very strong galvanic current will cause a continuous contraction during the passage of the current. In using the galvanic current, begin with the weakest current that will cause a response. A large electrode is applied to the back of the patient, and a small one is used for obtaining muscle contractions.<sup>1</sup> In health, using the galvanic current, the cathodal closing is first to appear—that is, when the negative pole, the pole attached to the zinc plate of the battery, is applied over the muscle. A decidedly stronger current is required to elicit anodal

<sup>1</sup>If a wall plate is not available, about thirty ordinary dry cells are required for making galvanic tests. These are connected in series with a current controller. One or two cells are sufficient to drive the induction coil for the faradic current.

closing or opening contractions with the positive or carbon pole applied over the muscle. The cathodal opening contraction requires the strongest current of all. The contractions in health are sharp and abrupt. In disease the reactions may be altered quantitatively or qualitatively. In quantitative alterations a given current produces greater or less contractions than it would if the nerves and muscles were normal. In qualitative alterations the given current may produce sluggish contractions, or the anodal contractions may be more readily elicited than the cathodal closing contraction.

These changes depend upon the separation of the motor nerve from its nutritive center. Within a short time after this separation has occurred, degeneration takes place. The nerve first fails to respond to electrical stimulation, and after a longer period the muscle will no longer respond. It is during the period that occurs between the degeneration of the nerve and that of the muscle that the characteristic reaction, known as the reaction of degeneration, occurs. This includes a series of changes that may be summarized as follows: (1) with the faradic current no response can be elicited; (2) with the galvanic current occur both quantitative and qualitative changes. Quantitative changes: The muscles will respond to a weaker current than is required in health; this is called the irritability of weakness. Qualitative changes: The contraction becomes sluggish, and in most cases the anodal closing contraction is obtained with a weaker current than is cathodal closing contraction. This is less constant than is the sluggishness of the contraction. The reaction of degeneration is not fully established until about a week after the nerve has been severed, but the nerves begin to lose their sensitiveness about three days after injury. If the nerve cannot be repaired, the muscles will cease to respond to the current after two or three years have elapsed. When the nerve connection is effectively re-established, the reaction of nerve and muscle progressively returns to the normal. These changes, the reaction of degeneration, will be present only when the interruption in the motor conducting path has occurred below the lower motor nucleus, thus separating the muscle endings from the center that exercises trophic influences. When the lesion is situated more centrally, there may be no change in the electrical reaction. In partial section or incomplete nerve block, the trophic changes are absent, and paralysis is not complete.

**Treatment.**—If possible, the cause of pressure or of damage to the nerve should be remedied. If it is found that the normal conducting path will not be re-established spontaneously, or by such perineurial operations as may be indicated, then, in the case of certain important nerves, resort to direct nerve suture, or nerve transplantation, is



indicated. In complete section of a nerve, direct nerve suture, grafting, or transplantation should be done as soon as possible. It is only when the nature and extent of the lesion is in doubt that the operation is postponed until time has demonstrated that the lesion will not be remedied spontaneously. When a peripheral motor nerve is cut some place below its motor nucleus, the fibers distal to the lesion degenerate. When connection is established between the distal part of the motor nerve and its own, or some other, motor nucleus, the nerve fibers grow downward into the distal part of the nerve, and function is re-established.

**Trifacial Nerve.**—Besides carrying sensations to one half of the face, each fifth cranial nerve carries motor fibers to the muscles of mastication. These will be paralyzed after section of the posterior root of the Gasserian ganglion, and after removal of the ganglion, if the motor root is included. There is usually a transient paralysis, more or less complete, after injection of the third division of the fifth nerve with alcohol.

Paralysis of the muscles of mastication of one side causes little inconvenience and is not very noticeable. On palpation it will be found that the masseter or the temporal muscles either do not contract or contract less vigorously than those of the uninjured side. In unilateral paralysis the chin deviates toward the paralyzed side when the mouth is widely open, owing to the unopposed action of one external pterygoid muscle. If there were a complete bilateral paralysis, the lower jaw would hang down.

**Facial Nerve.**—The facial, or seventh cranial, nerve transmits motor impulse to one half the face and scalp, exclusive of the muscle that elevates the eyelid, the ocular muscles, the muscles of the tongue, and the muscles of mastication. It also supplies impulse to one of the muscles of the middle ear, to the stylohyoid, and to the posterior belly of the digastric muscle. The chorda tympani, which carries the sensation of taste, is, for a part of its course, incorporated in the seventh nerve. The facial nerve runs along a tortuous course through the temporal bone, and is not infrequently injured in fractures of the skull.

Paralysis of the face may also be caused by accidental injuries to the nerve, or infections or growths along its course. It may result from an intracranial lesion, either in the cortical motor area, in the nucleus of the seventh nerve, or along one of the conducting paths to or from the nucleus.

Bell's palsy is a facial paralysis due to injury or disease of the facial nerve. It may be due to traumatism or tumor, but most cases develop suddenly without injury, as a result of exposure to cold, or to some infection. Rheumatism and gout are supposed to be etiological fac-

tors. In a few cases in which the nerve has been examined shortly after paralysis of the latter kind, a degenerative neuritis has been found. This comes on quickly and may be fully developed in a few hours or days. Paralysis, due to tumors or middle ear disease, comes on more slowly and is usually not so well defined.

**SYMPTOMS.**—The symptoms will vary with the location and extent of the lesion. A lesion situated in the face area of the cortex, the nucleus of the facial nerve, or the conducting path between them will cause a paralysis of the opposite side of the face. Shortly after the nerve leaves its nucleus in the midbrain, the fibers cross the median plane to be distributed to the face on the opposite side. Lesions below the point where the nerve tracts cross will cause paralysis of the face on the same side. If a gross lesion is situated along the path in which the facial and auditory nerves lie in close contact, it is likely that both nerves will be affected. If the lesion is situated between the junction of the pars intermedia and the giving off of the chorda tympani, it is probable there will be loss of taste on one half of the body of the tongue. The face shows characteristic changes, varying with the extent of the paralysis. In a complete one-sided paralysis there will be a smoothing out of the natural creases of the forehead, with an inability to raise or wrinkle the brow, and there will also be a slight drop of the eyebrow of that side, and an inability to close the eye. When an attempt is made to close the eye, the globe turns upward, and there is a slight movement of the lower lid. This latter movement is probably due to certain muscle fibers innervated through the sympathetic. In a paralysis of long standing, there may be considerable irritation of the eye, due to the inability to close it. The buccinator muscle will remain flaccid, and food will collect in the buccal pouch on that side. The mouth will be drawn to the opposite side by the unopposed action of the opposite buccinator. It will be impossible to pucker up the mouth. There are other evidences of the paralysis present, but these are the most noticeable.

Complete double facial paralysis is, at first sight, not so noticeable as is paralysis of one side, owing to the fact that the mouth is not distorted. However, there is a peculiar mask-like appearance of the face, which is due to the immobility of the muscles of expression. We have seen one such case, in the service of Dr. Schwab, at the City Hospital, which was part of the symptom complex of a general paralysis.

**PROGNOSIS.**—The prognosis of the non-traumatic form, not due to a growth, is good, but recovery is not always complete. Mild cases may recover in a month, and the usual duration is three to five months. In the traumatic form the prognosis will depend upon the extent and

character of the injury. A partial section of the trunk of the nerve usually recovers spontaneously, because the ends of the divided fibers are still held in close proximity. Complete recovery is still more apt to occur after contusions. If, immediately after an injury of the nerve or one of its branches, the paralysis is not complete in the part supplied by the injured branch, then there is good reason to believe that there will be considerable spontaneous recovery.

The prognosis of a paralysis due to perineurial tumors, or inflammatory growths, will depend upon their nature and accessibility. The prognosis of a paralysis due to a malignant growth is necessarily bad. Where the paralysis is due to simple pressure, recovery will usually take place on removal of the pressure.

TREATMENT.—When there is a complete transverse destruction of the nerve sheath, surgical repair may be undertaken immediately, but even the history of an injury does not always preclude spontaneous recovery. In non-traumatic Bell's paralysis, as long as the electric excitability remains unchanged, no local treatment is necessary, but it is safer to use massage or electricity to prevent atrophy or degeneration of the muscles. When the paralysis remains unchanged, the question of nerve repair or of an anastomosis of the facial to some other motor nerve arises; but the latter should not be considered until after six months, and it is better to wait a year. Hackenbruch reports a favorable result by operation after  $7\frac{3}{4}$  years, Taylor after 12 years, Elsberg after  $29\frac{1}{2}$  years.

Ballance, of London, first did facial-accessory anastomosis on the human in 1895. When a nerve is cut in two, or is subjected to considerable pressure in any part of its course, the axis cylinders degenerate in the distal part of the nerve. If the open end of the distal part of the nerve sheath is properly united directly, or even closely, to an opened sheath of a motor nerve that still retains its physiologic and anatomic central connections, then the axis cylinders will grow downward into the distal previously functionless part of the sheath. This re-establishes physiological connection between the end organs and the central nervous system. The object of anastomosing the distal part of a paralyzed facial nerve with the trunk of a neighboring functional motor nerve is that the intact nerve can be made to take over the function of the facial, and that a more or less satisfactory innervation of facial muscles will result. The spinal accessory or the hypoglossal is the nerve chosen. Even when the technic and healing are satisfactory, the results of the operation cannot be ideal. It is necessary to educate the cortical centers to take on a new function for which they were not intended. After a successful operation of this kind the tone and grosser movements of the facial muscles will be restored, but not the finer

movements of expression. Further, after uniting the facial to either the accessory or hypoglossal nerves, there are usually persistent, objectionable, associated movements—such as grimaces of the face when the patient shrugs his shoulders or moves his tongue. The younger the patient, the better chance he has of overcoming or lessening these association movements. Almost perfect results are to be hoped for after uniting the cut ends of the trunk of the facial nerve, but unfortunately the lesion is often situated in an inaccessible part of the nerve. On the whole, the results of a satisfactory anastomosis are so much better than the facial paralysis that this operation is well worth doing.

Faulty technic, or sepsis in the wound, greatly lessens the chances of good result. In about two thirds of the collected cases results have been rather satisfactory.

**Operation of Facial-Accessory or of Facial-Hypoglossal Anastomosis.**—**EXPOSURE OF THE TRUNK OF THE FACIAL NERVE.**—An incision is made along the anterior border of the sternomastoid muscle from 2 centimeters above the tip of the mastoid process to the upper level of the thyroid cartilage, cutting through the skin and superficial and deep cervical fasciæ. To expose the trunk of the facial nerve, the parotid gland is drawn forward, and the sternomastoid is drawn backward until the stylohyoid and posterior belly of the digastric muscles come into view. If the trunk of the nerve is not easily found, the posterior surface of the parotid gland is carefully incised. The lobes are separated, and a branch or division of the nerve is sought within the gland substance near the posterior border. As the nerve is approached, each piece of tissue is pinched with a Halsted forceps before it is cut. When the nerve trunk or a branch is pinched, there is a contraction of the muscles supplied. In this way, the nerve can be safely approached. When the nerve is located, it is followed back to a point as close to its foramen of exit as possible, without injuring it.

**EXPOSURE OF THE SPINAL ACCESSORY NERVE.**—This nerve enters the deep surface of the sternomastoid muscle 3 to 5 centimeters below the mastoid process. The trunk lies directly below or on the transverse process of the atlas and deep to the posterior belly of the digastric. It is found by turning back the anterior part of the sternomastoid and seeking it where it enters the deep surface of this muscle.

**EXPOSURE OF THE HYPOGLOSSAL NERVE.**—The nerve is sought where it crosses superficially to the external carotid artery at the origin of the occipital artery (Fig. 351).

**ANASTOMOSIS.**—Sufficient of the facial and the other nerve selected should be exposed to make the union without tension. As high up

as is practical on the facial nerve, a fine, curved, eye needle, carrying a very fine silk suture, is passed under the sheath, transverse to the long axis of the nerve. The suture should engage the sheath for one fourth of the circumference of the nerve, but should not penetrate deeply into the substance of the nerve. On the opposite side of the nerve, at exactly the same level as the first, a similar suture is placed. These are fastened to the upper protective cloth with two artery forceps. At the proposed site of section of the hypoglossal or accessory nerve, two more sutures are placed in a similar manner. With a pair of sharp scissors

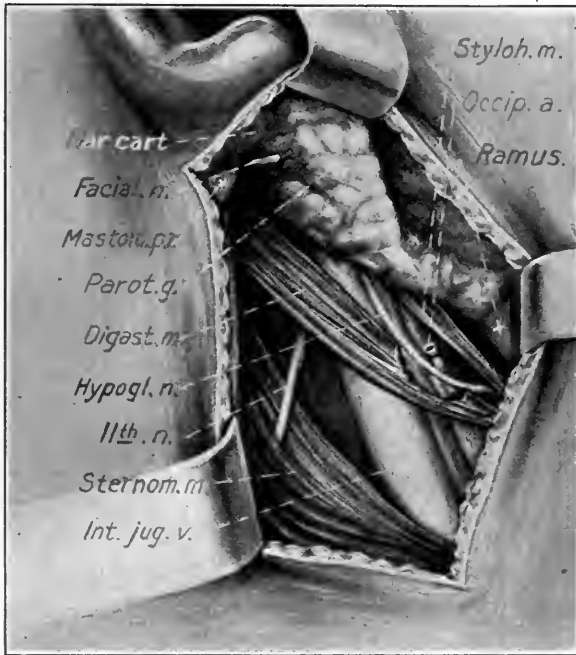

Fig. 351. Structures in relation to the facial, hypoglossal, and spinal accessory nerves. The digastric and stylohyoid muscles have been separated to show the hypoglossal nerve, and the parotid gland is turned forward to display the facial nerve. In this case the spinal accessory enters the sternomastoid at a lower level than usual.

the facial nerve is cut just proximal to the sutures, while the accessory or hypoglossal is cut just distal to them. The nerves should be cut within a millimeter of the sutures. In doing this, the trunk may be steadied by grasping the facial nerve proximal to the sutures and the hypoglossal or accessory distal to them. As soon as the nerves are cut, the two ends are approximated by tying appropriate sutures. The ends of these sutures are not immediately cut short, but are used to hold up the anastomosis, while it is carefully examined. If at any point the sheath is turned in, or the nerve not accurately abutted, re-

inforcing sutures of fine split silk are placed. By this method of suturing, the ends can be immediately approximated as soon as the nerves are cut, which is probably a safeguard against intraneural infection. In making the anastomosis between the facial and the accessory, the latter nerve may be brought superficial to, deep to, or through the digastric and stylohyoid muscles. The wound is closed, leaving in a small strip of rubber dam drain, that does not touch the nerves, and which is to be removed in twenty-four hours. The two most important points about the operation are asepsis and providing a sufficient length of each nerve to allow of anastomosis without any tension.

The choice of the nerve to be used, the hypoglossal or the accessory, requires some consideration. The centers which send impulses through the hypoglossal nerve, normally, give rise to finer movements than those supplying the accessory. It might, therefore, be surmised that the hypoglossal is better adapted for taking over the functions of the facial. On the other hand, the loss of one hypoglossal is a much more serious matter than the loss of the accessory. If the functional result of the operation proved a failure, after using the hypoglossal, the patient would be much worse off than before the operation.

**Hypoglossal Nerve.**—If motor impulses are shut off from one half of the tongue, it will deviate to the paralyzed side when protruded. If the paralysis persists, that side of the tongue will later shrink. The motor supply of the tongue is through the hypoglossal nerve, which comes from the hypoglossal nucleus in the floor of the fourth ventricle. A section of the nerve is not infrequently removed in excising an infiltrating growth in the submaxillary region. It might also be cut accidentally in operations about the upper part of the carotid sheath. Paralysis of half of the tongue has resulted from pressure upon the nerve in the anterior condyloid foramen, due to caries of the occipital bone. The nucleus of the hypoglossal nerve may be involved with others in a lesion of the bulb. Functional motor disturbances of the tongue are not infrequent.

### SPASMODIC AFFECTIONS.

These may, in a general way, be divided into two kinds: (1) those that are directly dependent upon some physical irritation; and (2) those that are more or less under the control of the volition. An example of the former is tetanic closure of the jaws, due to some lesion along the distribution of the fifth nerve (page 72). A common example of the latter is facial tic, but this may start with, or even be dependent on, some definite pathologic or other irritation.

**Facial Tic.**—This is a motor disturbance affecting, chiefly, muscles supplied by the seventh nerve, and characterized by a set of spas-

modic contractions of certain muscles, recurring at more or less regular intervals. There are one or more sharp contractions of the affected muscle, followed by a period of relaxation. When the spasm involves a number of groups of muscles, the spasm may start in one set and travel in a more or less regular sequence through the various groups involved. The interval between spasms varies in different patients, and at different times in the same patient. This interval is somewhat under the control of the patient, but after holding it in abeyance for some time, the spasms recur in quick succession.

It most commonly appears in the zygomatic and orbicularis palpebrarum muscles of one side, but may spread to other groups; and the

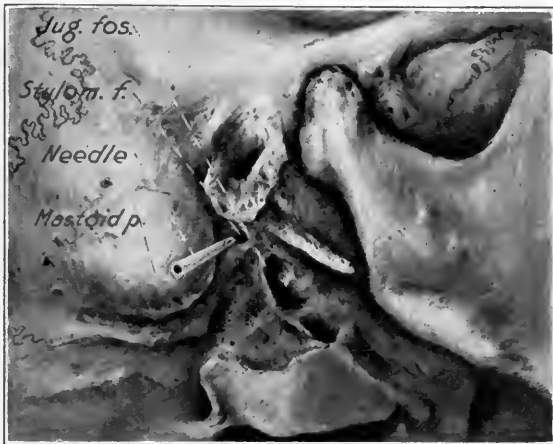

Fig. 352. Showing stylomastoid foramen from which the facial nerve emerges. Also represents a needle penetrating to the foramen. The needle enters in front of the middle of the mastoid process. The internal jugular vein in the jugular fossa is to be avoided.

tongue, neck, shoulder, and arm muscles may all become involved. Occasionally the spasms are painful, but this is rarely the case.

Facial tic seems frequently to have its origin in some local irritation, either pathological, or external—such as an uncomfortable collar—but it is looked upon as essentially a habit spasm. According to Head, it develops only in persons of a certain neurotic taint of mental habit—such as persons who make it a practice of touching every other post that they pass, etc. In a few cases it is evident that it is mainly a subconscious voluntary action. Such, for instance, was the case of a young woman in whom the tic had followed the moving of a molar tooth for a dental operation. She thought that the new position of the tooth was responsible for the trouble, and when questioned on the sub-

ject, she immediately had a series of spasms of extreme degree, which, also, involved the jaw muscles. When her attention was diverted from her trouble, there was only an occasional twitching of the buccinator. As a rule, the mental element is exhibited by the power to hold the spasms in abeyance for a certain time. Regardless of the nature of the original irritant, after the spasms have persisted for a length of time, the psychic element is the all-important factor.

**PROGNOSIS.**—In the earlier cases great good, even cure, may result from proper treatment. The old long-established cases are liable to persist.

**TREATMENT.**—A physical cause should be sought and, if possible, removed, but the treatment is a problem for a neurologist, rather than for a surgeon. In some cases good has resulted from temporarily blocking the facial nerve, in the hope that a few months respite will break the habit, but after such an operation, the surgeon must not be surprised if the tic recurs, or appears in some other set of muscles.

There are several ways of blocking the nerve. One is to cut downward and stretch it. Another is to inject a weak alcohol solution, 40 or 50 per cent. around the trunk with a hypodermic needle (Fig. 352). After these operations, the nerve is more or less paralyzed, but will recover in nine months, or even less time. Before doing such an operation, the patient and friends should be given to understand the results in an indisputable manner. Lawsuits have arisen for lack of a clear understanding on this point.



## CHAPTER XLII.

### TIC DOULOUREUX AND SPHENOPALATINE NEURALGIA.

The term neuralgia is one that is somewhat loosely applied. It is generally used to designate a recurrent localized pain, that cannot be accounted for by any recognizable lesion. According to our limited knowledge of the subject, neuralgia seems to be due to pressure, toxemia, or malnutrition, the last including the lack of an accustomed stimulation.

As the fifth cranial nerve carries all common sensations from the mouth, teeth, and face, neuralgias of the head and face are very common, and clinically present several varieties. The pain may radiate over the distribution of several nerves—as one that involves the fifth cranial and several cervical nerves—or it may be confined to one nerve.

#### FIFTH CRANIAL NERVE.

This nerve carries both motor and sensory fibers. It supplies motor impulses to muscles of mastication, the mylohyoid muscle, the anterior belly of the digastric muscle, and the tensor palati and tensor tympani muscles. It carries sensory impulses from the whole face and its contained cavities, the mouth, nose, and orbits.

The sensory part of the nerve has on its root, situated on the inner end of the petrous bone within the skull, the Gasserian ganglion, which is analogous to a posterior root ganglion of a spinal nerve. The motor part has no connection with the ganglion, but joins with the sensory fibers of the third or mandibular division.

The sensory fibers are arranged in three groups. The first or ophthalmic division arises from the innermost part of the ganglion, emerges from the skull through the sphenoidal fissure, and traverses the roof of the orbit. The second or maxillary division arises from the midpart of the ganglion, emerges through the foramen rotundum, crosses the sphenomaxillary fossa, and traverses the floor of the orbit. The third or mandibular division arises from the outermost part of the ganglion, and leaves the skull through the foramen ovale. Before any of these divisions leave the skull, they send off dural branches.

There are many conditions occurring in the mouth, and especially in connection with the teeth, that demand surgical or dental treatment on account of the pain accompanying them; and in these the pain is

often of a referred neuralgic character. Many attacks of neuralgia will yield to medical treatment.

### TIC DOULOUREUX: MAJOR NEURALGIA OF THE FIFTH CRANIAL NERVE.

A convulsive chronic neuralgia limited to the fifth nerve is designated as a major tic, or tic douloureux, and this can only be relieved by some surgical procedure that blocks the conducting power of the affected nerves. Possibly a practical way of putting it would be to say that every persistent incurable neuralgia of the fifth nerve is clinically a major tic and should be so treated. While no patient should be allowed to suffer unnecessarily, because his ailment does not fall in with our preconceived ideas of what constitutes a major tic, nevertheless it is important that the surgeon, the consultant, and the dentist be able to recognize the disease when present and to differentiate it from other neuralgias and extraneural conditions that simulate it. Otherwise the patient may be subjected to an unnecessary operation, or the surgeon may find himself embarrassed by a faulty prognosis. If the nerve-blocking operation is successfully done to relieve the referred pain of an unrecognized malignant growth, valuable time may be lost before some gross symptom calls attention to the tumor. When the dentist fails to recognize a true major tic, he is likely to persist in useless operations and extractions, which give his patient no relief and which may cause his skill to be questioned.

A very slight acquaintance with the symptoms of the disease will exclude the possibility of not recognizing it when present. The recognition of its counterfeits is, in most cases, quite as simple, but may be so difficult as to baffle the most skillful and most painstaking neurologist.

**Symptoms.**—In a carefully observed series of cases of true major tic, there were some features common to all. Within certain limits, the clinical picture in the individual cases varied considerably, but by excluding from operation cases that varied beyond these limits, we have done very few inappropriate operations. The clinical features that were common to all of the true cases that we have observed are:

1. The neuralgia is confined to the distribution of one or more branches of the fifth nerve on the affected side. There are cases which appear to be exceptions to this rule, but from the anesthesia resulting from injections, it was learned that the distribution of this nerve varies considerably, the most striking departure from the average being that the first division, through the supraorbital, may supply the area behind the ear. This purely local distribution of the pain is in striking contrast to the pain, which Sluder has described as neuralgia due to an irritation of the sphenopalatine, Meckel's, ganglion. In this the

pain radiates over the distribution of the first and second divisions of the fifth nerve, over the occiput, side of the neck, and down the arm, forearm, and hand (Figs. 353, 354). We have very occasionally seen a true tic douloureux associated with pain of some other part. In one

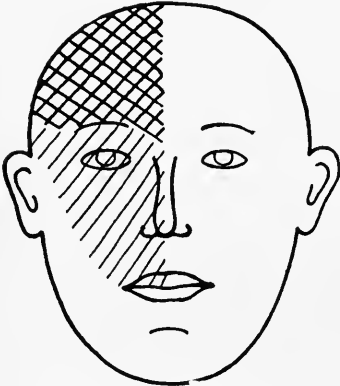


Fig. 353.

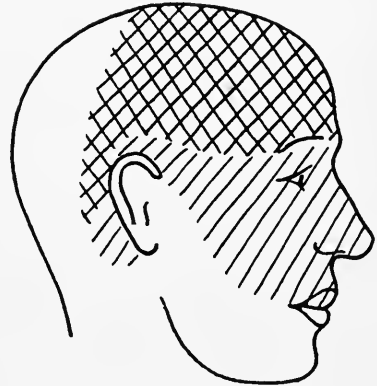


Fig. 354.

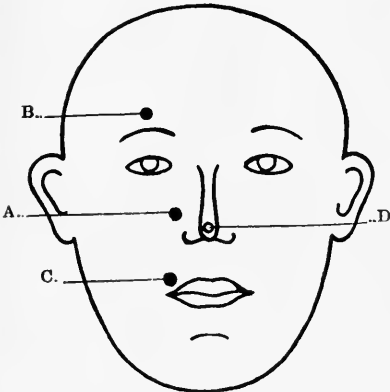


Fig. 355.

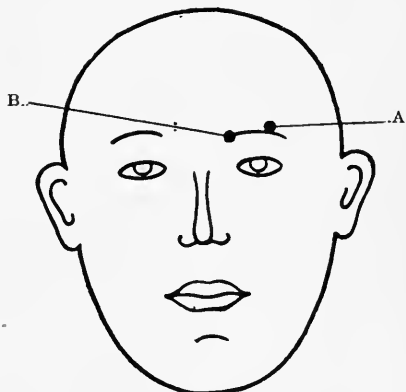


Fig. 356.

Figs. 353 and 354 show the anesthesia resulting from a deep injection into the first and second division of the fifth nerve. From the anesthesia it will be seen that the area behind the ear is supplied, in this case, by the first division of the fifth nerve, which accounts for the fact that the pain radiated behind the ear. This is not the average distribution.

Fig. 355. Case of woman 65 years of age. (A) pain came on at this point in 1905; (B) pain came on at this point in March, 1908; (C) pain came on in 1905 sometime after the appearance at (A); (D) touching the spot (D) would start pain in (A and B).

Fig. 356. Man 53 years of age. (A) pain came on in this spot in 1884, and was somewhat relieved by cutting the supraorbital nerve in May, 1908; (B) pain came on in this spot after cutting supraorbital nerve.

case there was a pain in the back of the thigh that came on and passed off with the facial pain.

2. The pain in every case came on in a rather definite spot, from which it might radiate in various directions over areas belonging to the fifth nerve of the same side (Figs. 355, 356).

3. Whether the first intimation was a severe pain or a paresthesia so slight as to be compared with the touch of a feather, and whether in the later stages the patient had but occasional twinges or the pains followed each other so closely as to destroy all rest and drive the sufferer almost to desperation, the pain was always, in all stages of the disease, paroxysmal.

If the first pain was severe, the patient might have thought that he had been struck or stung; but severe, or almost imperceptible, the first pain, with but very few exceptions, lasted but a second or a few minutes. Later the pain returned—that day or the next, or in a week, month, or year, but it returned. And the subsequent history is that the intervals between the pains shortened, and that the length and intensity

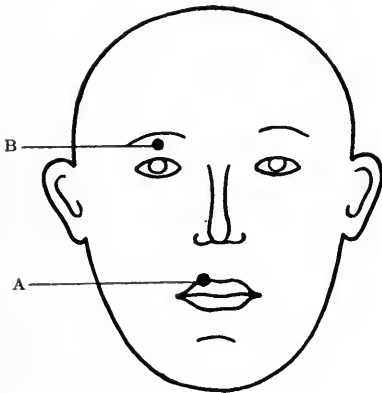


Fig. 357.

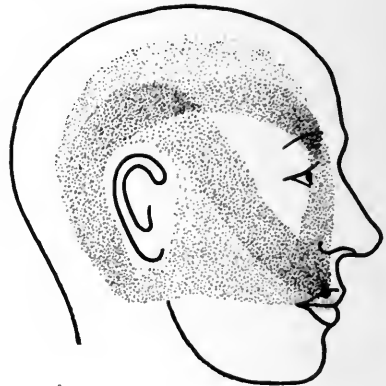

Fig. 358.

Fig. 357. Man 68 years of age. (A) pain came on in this spot December, 1906; (B) from May, 1909, touching this spot caused exquisite pain.

Fig. 358 is intended to show the direction and distance that the pain radiated from the pain spots. The fact that the pain radiated behind the ear tended to cast some doubt upon the diagnosis before the injection was made. Result of two injections is shown in Figs. 353 and 354.

of the individual twinges increased as time went on. In one of the exceptional cases referred to, the first paroxysm lasted four hours.

To the paroxysmal character is later added an irregular periodicity, which may be evidenced by the pain being present on alternate days—more frequent or more intense on alternate days—or present for indefinite stretches of time that last for weeks or months, alternating with periods of comparative or complete freedom. A very marked, regular periodicity, especially in a recent case, is strong evidence against but does not absolutely exclude the possibility of its being a true major tic. Such neuralgias are usually of the variety known as sun pains, which seem to be due to some malarial or climatic influence or sinus infection. In a very few cases there has been a continuous dull

ache over some part of the nerve, with recurring paroxysms of a sharper character.

4. When the pain returns, it is in the same spot in which it first appeared, and although it may radiate, the pain is always most sharp in one certain place that can often be covered by the end of a lead pencil. Later other such pain areas may develop, but they are in turn equally definite (Figs. 355-357). After some months or years the primary pain area may be less severe. The pain may come in several of these spots at once, in one or the other by turns, or play from one to the other. The pain may remain confined to the distribution of the branch over which it first appeared, or it may involve other branches or divisions of the nerve successively. The second and third divisions are the ones supposed to be most commonly affected, and some observers maintain that involvement of the first alone is never a true major tic.

5. The neuralgia is usually confined to one side, but involvement of both sides is not uncommon.

6. The trunks and branches of the affected nerve may or may not be tender, but in almost all cases there are spots over the distribution of the nerve, stimulation of which causes a twinge in the pain area. The touch of a finger, a breath of cold air, in some cases heat, in others the taking of food or liquids in the mouth or the act of swallowing, or a sudden movement or jarring—any or all of these may bring the pain. One old lady could not let a bright light fall on the eye on the affected side without a sharp pain in a spot to the outer side of the ala of the nose (Fig. 355). A number could not take sweet or sour things, and one suffered a supraorbital pain whenever food touched the velum. It is pitiful to observe the extremes to which sufferers will resort to avoid the stimuli that they know will produce pain. Some of them will talk from, or will take food or drink into, only one side of the mouth. One patient would go for days without swallowing even water, and others will not enter a room until they are sure all windows are closed. Some, for months at a time, will not wash one side of the face or brush the teeth.

8. In the older cases, though there is evidence of extreme pain during the attack, the patient seems to have become accustomed to it and seldom makes an outcry or demonstrative complaint.

9. Contrary to the repeated statement that it is essentially a disease of middle or later life, it appears in all decades from the second on. The earliest case of ours was nineteen years, but in most instances it first appeared between forty-five and sixty years.

10. This form of neuralgia is extremely stubborn to treatment. For a time most of them were influenced by medicinal treatment, but.

sooner or later, this seems to lose its effect. In most cases of long standing, one or a number of teeth had been extracted, usually with little or no benefit. Removal of pulp stones, abnormal roots, misformed teeth, impacted or unerupted teeth, or necrosed bone had in many cases given temporary relief, possibly for months; but in all cases the pain returned. Excision of the accessible parts of the affected nerve trunks had given temporary relief, as had injections into the peripheral portions of the nerves. But even where the relief obtained lasted some years, the pain eventually returned. It is not impossible, however, that cases, giving typical symptoms of major neuralgia, have been cured by some other than surgical means. Naturally, such cases are not likely to come under our direct observation.

The time the neuralgia had persisted before coming under observation varied from two months to thirty years, so that in these cases there had been ample opportunity for trying various measures.

The duration of the disease is one of the strongest points in the diagnosis; it is the recent cases that require most careful differentiation. Pains due to pulpitis, neuralgias due to malaria or pus infections, pain due to malignant growths, or any other acute cause, will, if observed long enough, show some change or characteristic that will differentiate it from a true tic, or the general health or condition of the patient will give some clew to the cause. Except indirectly, through loss of sleep or lack of food during an acute exacerbation, this disease affects the general health to a remarkably small degree.

In very few cases have we observed trophic or functional changes, such as anesthesia, reddening of the skin, or lacrymation from the affected eye during the attack. In those cases where there was a motor convulsion of the face or neck muscles, we were inclined to believe that the twitching was voluntary though subconscious.

**Diagnosis.**—From these observations, it seems logical to conclude that a paroxysmal pain, coming on suddenly in one or several spots over the distribution of the fifth nerve, returning persistently at the same spot, whether or not other similar pain spots later appear, and not yielding to medicinal or surgical treatment of any associated lesions, is a true major tic. The conclusion that no neuralgia except that which exactly corresponds to all of these conditions can be a major tic is probably not warranted.

### SPHENOPALATINE NEURALGIA.

Sluder has called attention to a pain syndrome, which seems to be due to an irritation of the sphenopalatine ganglion. This form of neuralgia is fairly common and should be differentiated from tic douloureux. His description of the syndrome is concise and clear, and we, therefore, quote him, as follows:

"When seen from the beginning, the pains of postethmoidal or sphenoidal diseases have usually preceded the development of the characteristic neuralgia picture. I have also remarked that after the neuralgic manifestations have continued for some time (approximately four weeks) they begin to run irregularly, assuming the form of migraine, which may persist even for years, after all local inflammatory conditions have disappeared.

"One of the most striking manifestations of disturbance in the sphenopalatine ganglion is the wide and characteristic distribution of pain along definite lines. These neuralgic manifestations can be evoked by mechanical irritation of the ganglion, by the faradic current, and by therapeutic injections of alcohol. The neuralgia is described as a pain at the root of the nose, sometimes also in and about the eye, taking in the upper jaw and teeth; sometimes also the lower jaw and teeth, and extending beneath the zygoma to the ear to take on the form of earache. It is emphasized at the mastoid, but is nearly always severest at a point about two inches posterior to the mastoid, thence reaching backward by way of the occiput and neck; and it may extend to the shoulder blade and shoulder, and in severe attacks to the axilla, arm, forearm, hand, and fingers. This is the most frequent picture, as I have observed it. Sometimes the patient complains also of a 'stiff' or 'aching' throat, without inflammation; of pain, or oftener of itching, in the roof of the mouth; or of pain inside the nose.

"Along with the pain there is, also, on the affected side, slight anesthesia of the soft palate, and of the pharynx as far down as the lower part of the tonsil, and also in the anterior lower part of the nose.

"In a large percentage of cases, the neuralgia is accompanied by motor disturbance, affecting the configuration of the soft palate. The palatine arch on the affected side is often higher than on the well side, and during movement, the median raphe is deflected from the affected side. Taste is usually less acute on the dorsum of the affected side."

**Pathology and Etiology.**—Little is known of the pathology of this disease. It has been supposed to be an ascending neuritis; but the symptoms do not correspond with those of an ordinary neuritis, and little has been observed by microscopical examination of sections.

The etiology is but little less obscure. The history of certain cases of tic douloureux suggests very strongly the origin in some tooth lesion, but a characteristic of both forms of neuralgia is that relieving the supposed exciting cause does not relieve the pain. It is not improbable that many may be the sequelæ of sinus disease.

### TREATMENT.

Once the diagnosis is established, resort should be had to some measure that will block the sensory conduction of the affected nerves. In tic douloureux, at first superficial injections may give relief for many months; but later these lose their effect, and some operation on the proximal portion of the nerve is usually indicated. This will consist either of cutting the nerve, and possibly removing a portion, or of injecting some fluid around the trunk that will influence its power of conducting these abnormal painful sensations.

We know little of the cause or of the pathology of this disease. But in spite of the fact that it is often called a central neuralgia, some part of the irritation must be peripheral; for, if it were otherwise, no amount of blocking of the peripheral paths would influence the pain. Not knowing what the irritation is, or where it is operative, it is reasonable to conceive that the closer to the brain the block is made the more likely is it to be successful in curing. This is borne out by clinical observation. The peripheral operations are the simpler, safer, and least efficient. The deeper operations require more skill and give more lasting relief.

Injections, according to our observations, give relief for as long if not for a longer time than do peripheral nerve sections or avulsions. They cause less immediate disability and discomfort than cutting operations, and as a rule, are regarded more kindly by the patient. Therefore, with the exception of the nerves of the orbit, no description will be given of the mode of making these nerve sections. Descriptions of these operations will be found in any textbook of surgery, most concise in Kocher's Operative Surgery.

In a historical review of the subject of nerve injections, Otto Weiner states that about 1840, Ryud used morphin and creosote, and in 1857, Wood injected morphin, while Bell used atropin. From this time on, almost everything from air to chloroform has been advocated. The use of ether and chloroform, and other irritating substances in mixed sensory and motor nerves had to be abandoned on account of the paralysis produced; chloroform, on account of the shock; and air, on account of the danger of air embolism.

It is difficult to say just what is the rationale of the injection treatment, but clinically it is shown to be very successful. There are two distinct classes of fluids that are used today for injections into the branches of the fifth nerve. The most popular of these is alcohol in various strengths, with or without other substances in solution. The formula that we have generally used closely resembles that proposed by Patrick, and is as follows:

Novocain, 2%.  
Chloroform, 5%.  
Alcohol, 70%.  
Water, 23%.

For injections made in the deep orbit, the quantity of chloroform is reduced to 2 per cent.

In 1869, Potain ascribed benefit to the parenchymatous injection of water, and later, aqueous solutions of cocain became popular. On account of the toxicity of cocain, Schleich advocated weaker solutions. Bock used tropacocain, and Kurzwelly beta-eucain.



In 1904, Lang made intraneural injections of physiological saline solution, and beta-eucain, 1:1000. Weiner observed chills and fever following the use of physiological salt solution, and uses this solution:

Sodium chlorid,	6.
Calcium chlorid,	.75
Water,	1000.

He gives as his results: in sciatica, 51 cases were cured, 8 improved; in trifacial neuralgia, 22 cases cured, 2 improved, and 2 not improved. If the experience of other operators supports Weiner in these results, there can be no question that this milder fluid will supersede the alcohol and all of its relatives. While it is exceedingly gratifying to be able to relieve instantly and apparently permanently the most intense pain by a deep alcohol injection, every thinking man appreciates that it cannot be done without risk, and that it is only the gravity of the situation that warrants the means.

Patrick has abandoned the injection of the first division. While we personally have not had any mishap of permanent nature, we have known two cases of blindness and one of dementia to follow this operation. It is possible that these unfortunate results were due to avoidable errors in technic, but in any larger series of cases of deep injections of the fifth nerve with any corrosive fluid, there will be a certain number of accidents. An efficacious fluid, the use of which is free from danger, will go a long way toward increasing the popularity of this method of treatment.

Before any injection is made, the skin should be cleansed. Before an irritating solution is injected, it is better to anesthetize at least the skin by the injection of a small quantity of  $\frac{1}{4}$  to 1 per cent solution of novocain, the strength depending upon the quantity that is injected (Chapter 43). Before making a deep nerve injection, we have made it a practice with ordinarily strong patients to inject  $\frac{1}{150}$  grain of scopolamin and  $\frac{1}{6}$  grain of morphin into the arm four hours before the operation, and repeating the dose a half hour before operation. This usually has the effect of very much reducing the pain of the injection. In very old persons one such dose has had the desired effect. Ordinarily this is a very painful operation, and only the knowledge that it gives almost instantaneous relief in the great majority of cases gives the operator the heart to persist in the careful, painstaking way that is usually followed by success. We occasionally do it under a general anesthetic, but this is much less likely to be successful.

The needle used for anesthetizing the skin may be very fine, but that used for the nerve injection must be coarse and rather blunt, and strong in proportion to the depth at which the injections are made

(Fig. 359). The blunt needle is less apt to open a vein and liberates the fluid close to the point. The injections may be made into the nerves, as they emerge from the superficial foramina of exit—which might be termed peripheral injections; or they may be made with the idea of attacking the nerve trunks, just as they emerge from the foramina that furnish their exit from the cranial cavity—which might be termed deep injections. The former could be considered minor, and the latter major operations. There are certain nerves that may be attacked at intermediate points.

**Injection of the Peripheral Branches of the Fifth Nerve.**—For the peripheral injections a coarse hypodermic needle may be ground on a whetstone till the end is cut at an angle of  $45^\circ$ , or such needles may be obtained from the dental supply houses. The needle is made to penetrate deeply into the tissues before the fluid is liberated. For these peripheral injections a small quantity ( $\frac{1}{2}$  to 1 cubic centimeter) of fluid is sufficient.

Besides the knowledge of the exact or relative position of the foramina of exit, two other things are helpful in locating the nerve trunks: (1) the nerve trunks are sometimes tender to touch; and

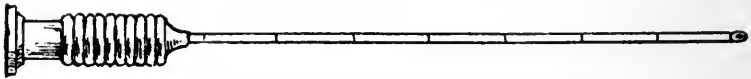


Fig. 359. Needle used for deep nerve injections.

(2) an exquisite pain, which radiates over the distribution of the nerve, tells when it is touched by the needle or irritating fluid. When the injection fluid is of an anesthetizing character, this severe pain lasts but a few minutes after the first few drops are liberated. During the progress of the injection, the skin, or mucous membrane over the distribution of the nerve, should be repeatedly tested for anesthesia, which, when obtained, assures the anatomical success of the operation. The point of the needle is shifted in the tissues during the injection so as to distribute the fluid over a sufficient area to insure its coming in contact with the nerve and to avoid the risk of placing the whole injection in a vein.

*The nasal nerve* can be reached, before it leaves the orbit by the anterior ethmoidal foramen, by inserting the needle at the middle of the inner wall of the orbit above the inner canthus. The bony wall must be followed closely to avoid the lacrymal sac. The bone itself is very thin, and care must be taken not to puncture it. The nerve will be encountered at a depth of from 18 to 22 millimeters from the bony ridge that can be felt in the inner border of the orbit. These intraorbital injections cause considerable swelling of the orbital tissues

(see Deep Injections of the Ophthalmic or First Division of the Fifth Nerve, page 575).

*The supraorbital nerve* is to be attacked at the supraorbital notch, rarely a foramen, which can be felt at the junction of the inner with the outer two thirds of the upper border of the orbit.

*The supratrochlear nerve* emerges from the orbit just under the inner end of the supraorbital ridge. Just before it emerges, it is in close relation with the periosteum and the tendon of the superior oblique muscle.

*The infraorbital nerve* emerges from the infraorbital foramen, which is situated 6 millimeters below the middle of the lower border of the orbit. The foramen may possibly be felt with the finger, and can always be located with the needle point.

*The orbital branch of the superior maxillary nerve* is given off in the floor of the orbit or in the sphenomaxillary fissure, and finds its exit by one or two foramina situated near the junction of the floor with the lateral wall of the orbit, 4 to 8 millimeters from the border. It divides into a temporal branch which enters the temporal fossa and a malar branch which appears on the facial expansion of the malar bone. The nerve trunk might be reached by inserting the needle just where the relatively vertical outer wall emerges into the curved infra-lateral boundary of the orbit. The needle follows the bony wall in a downward, backward, and inward direction to a depth of  $1\frac{1}{2}$  centimeters. The injection should begin when the needle has penetrated 5 millimeters, and the fluid is distributed from this point to a depth of 15 millimeters, or until an anesthesia or a paresthesia over the distribution proclaims that the fluid has reached its destination. The nerve is inconstant in its size, mode of exit, and area of distribution. It may be replaced by a branch from the ophthalmic division.

*The auriculotemporal nerve* may be injected as it crosses the root of the zygoma. It lies just behind the temporal artery, the pulsation of which will serve as a guide. This nerve lies in such close relation to the rather large temporal vein that there might be danger of the fluid entering the latter. The excision of this nerve would be safer than injection with alcohol.

*The mental branch of the inferior dental nerve* emerges through the mental foramen, which opens on the external surface of the mandible below the second bicuspid tooth. If the lower teeth have not been lost, the opening of the foramen lies nearer the lower than the alveolar border of the bone. If the alveolar process has been absorbed, the opening will be found at the upper border of the bone.

*The inferior dental nerve*, of which the mental is a branch, can be reached just before it enters the inferior dental canal. This injection

is more satisfactorily made with a strong needle 5 centimeters long or longer. If the month is opened fully, a triangular mucus-covered space is visible behind and above the last lower molar. This space covers the anterior border of the internal pterygoid muscle, and the outer border of the space is formed by the anterior border of the ramus of the jaw. These structures should be identified with the finger. To inject the inferior dental nerve, the needle pierces the mucous membrane of this triangular space near its median border and 5 millimeters above the level of the occlusal surface of the inferior molars. It at once enters the substance of the internal pterygoid muscle. The syringe is held at such an angle that the barrel rests on the second lower bicuspid of the opposite side (Fig. 360). The needle penetrates to the bone and follows it horizontally backward to a depth of  $1\frac{1}{2}$  centimeters; and while it is in contact with the bone, the injection is made, at the same time shifting the point to distribute the fluid. The opening of the inferior dental canal is in the middle of the inner sur-




Fig. 360. Injection of the mandibular nerve.

face of the ramus at the level of the occlusal surface of the last molar. Above this opening the inferior dental nerve is in contact with the bone.

*The lingual nerve* lies in contact with the ramus of the mandible a little in front of the inferior dental nerve. It may be injected at the same time as the inferior dental, or it may be reached by entering the needle just behind the last lower molar at the level of its neck, the barrel of the syringe resting on the first molar tooth of the opposite side. The needle penetrates about 1 centimeter. The point should be in contact with the bone when the injection is made.

*The descending palatine nerve* enters the soft tissues of the hard palate by emerging from the posterior palatine canal in the sulcus between the palate and the alveolar process opposite the last molar tooth. The nerve runs forward close to the alveolus and can be injected just as it enters the palate. The lesser nerves, that supply sensation to the mucous membrane of the soft palate, emerge close to the opening of the posterior palatine canal.

The *palatine branch of the nasopalatine nerve* enters the soft tissues of the hard palate from the incisive foramen, that lies behind the incisive papilla just behind the incisor teeth. It can be injected by entering the needle just behind the interdental space in the midline and passing the point upward and backward to the foramen. The needle penetrates about 1 centimeter.

The *long buccal nerve* lies to the inner side of the coronoid process. It may be injected here with certainty only when the nerve trunk is sufficiently tender to reveal its exact location. The injection is made by holding the mouth open with a gag, locating first the coronoid process and then the nerve trunk with the finger. The nerve

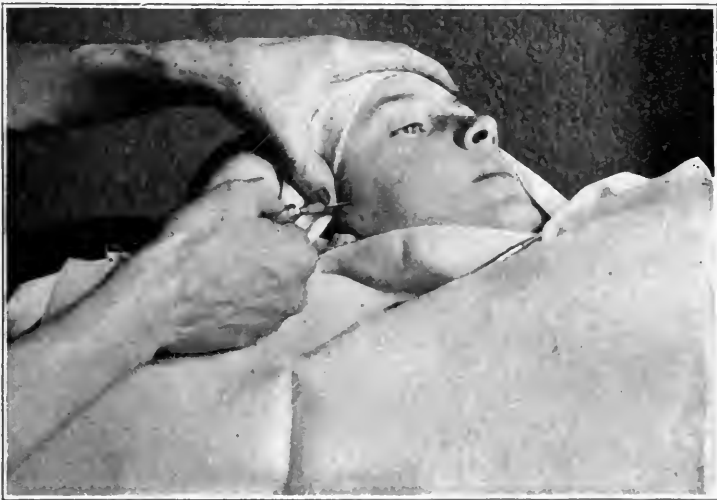

Fig. 361. Position of patient and operator in injecting the second or third division of the fifth nerve.

lies between the buccinator muscle and the insertion of the temporal muscle.

The effect of these superficial injections is more or less satisfactory. Very often the first successful injection will give relief for months, but it is our observation, from the histories of a number of cases that had repeated superficial injections, that, while the first injection may have given relief for a considerable period of time, later, the time of relief given shortens until at last they are practically ineffective. The longest period of relief that we have known, following a superficial injection, is a year. When it is demonstrated that superficial injections no longer give relief, then the deeper nerve trunks must be attacked. It is our custom, when the diagnosis is established, to at once make the deep injections which give a much longer period

of immunity. According to our observations, the relief from apparently successful deep injections varies from one year to indefinitely. Therefore we feel justified in the statement that, with the possible exception of the first division, deep injections should be tried in all cases before the more radical intracranial operation is advised.

**Deep Injections of the Trunks of the Fifth Nerve.**—**INJECTION OF THIRD, OR MANDIBULAR, DIVISION.**—The needle enters 5 or 10 millimeters below the middle of the zygoma and half way between the posterior border of the condyle of the jaw and the angle formed by the temporal and zygomatic border of the malar bone (Fig. 361). It penetrates to a depth of 40 to 50 millimeters and then comes in con-

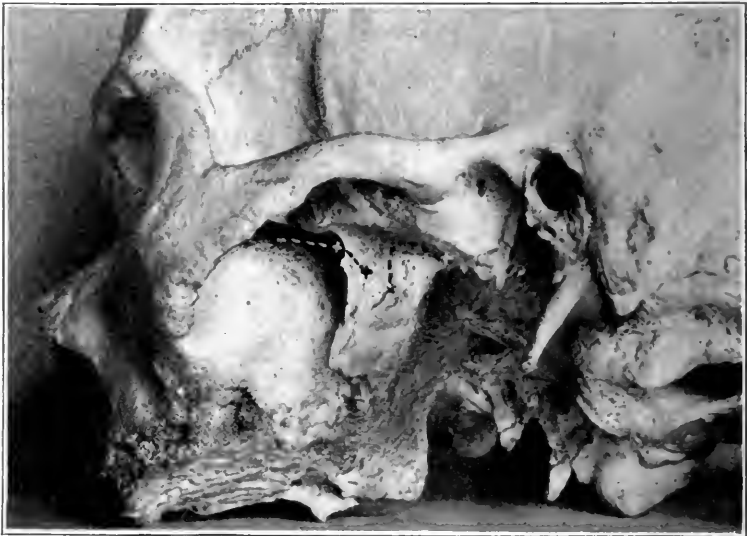

Fig. 362. The posterior dotted line on the pterygoid process shows the path followed by the point of the needle in the injection of the third division, after it has encountered the pterygoid process. The anterior line shows one course taken in reaching the second division.

tact with the external plate of the pterygoid process. This depth varies in proportion to the width of the skull and the prominence of the cheek bones. The average depth at which the process will be encountered is about 43 millimeters, and it is not commonly over 45 or under 40 millimeters, although in a few cases it may vary considerably beyond these limits. If the needle penetrates deeper than would be expected from the size and contour of the skull without striking the process, it should be withdrawn somewhat and thrust slightly upward and forward, for it may have passed behind the process. When the bone of the process is felt, the point of the needle is worked upward repeatedly, withdrawing slightly, and then reinserting it, the

point each time coming in contact with the bony plate, until the under surface of the great wing of the sphenoid is felt. This surface is rather perpendicular to the pterygoid process, and the needle is felt to slide obliquely along the bone. In this way the sulcus between the pterygoid process and the under surface of the sphenoid wing is located. When this sulcus is recognized, the point of the needle is, by the same process of withdrawing and reinserting, made to step backward until it is felt to slip off into the space at the posterior border of the process, when it will be right at the foramen ovale, which gives exit to the whole of the third division of the fifth nerve. In working

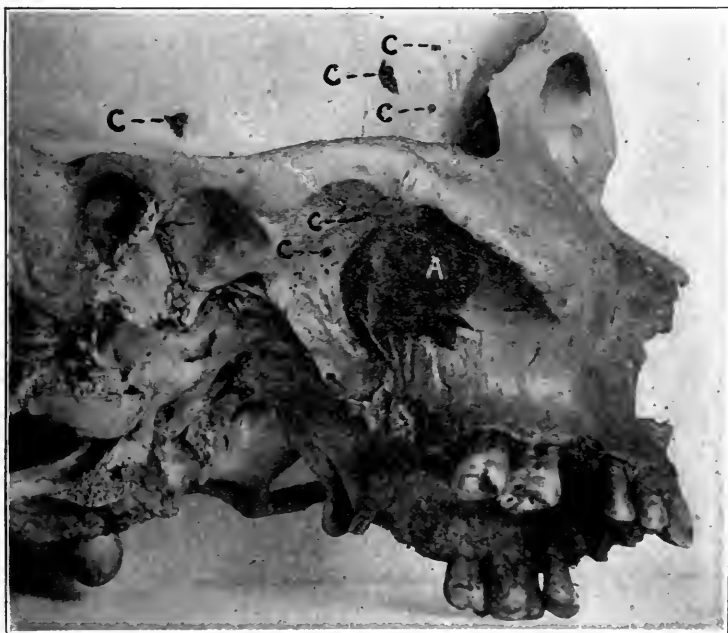


Fig. 363. Skull showing osteoporosis. A, defect in outer wall of antrum. C, openings into the cranial cavity.

the point of the needle backward, it is kept more in contact with the under surface of the sphenoid wing than with the external plate of the process. The sulcus between these two is rounded, and the needle must work along the upper part of the groove. Otherwise, when the posterior border of the process is reached, the point will be below the foramen ovale, and a backward projection of the external pterygoid plate might separate it from the nerve (Fig. 362).

When from the feel of the needle or the sensation of the patient it is thought that the needle is in contact with the nerve, the fluid is liberated a few drops at a time, the point of the needle being shifted

slightly, until an anesthesia and a paresthesia proclaim the success of the injection, or until 4 cubic centimeters of the alcohol mixture or 25 cubic centimeters of Weiner's fluid are liberated. Special effort should be made to obtain an anesthesia at the site of the pain spot.

At the time the injection is made, the depth of the needle point should not be more than 5 millimeters greater than it was when the external pterygoid plate was first struck. If driven deeper than this, the Eustachian tube, which lies just internal to the foramen ovale, might be injured.

In a skull that is affected by osteoporosis (Fig. 363), there may be small perforations at the base of the pterygoid process that lead direct into the middle cranial fossa. Even if the needle were to engage in one of these openings, it would not penetrate to the dura without being pushed to an unwarranted depth. There is another method of reaching the third division of the nerve, which consists in inserting the needle intraorally just above the position of the third molar tooth. The point is directed upward and backward and follows the external pterygoid plate until the under surface of the sphenoid bone is encountered. The needle is then made to step backward until it drops in the foramen ovale. It is much more difficult to locate the foramen by this technic, and it cannot be done aseptically.

Sometimes the needle can be inserted through the foramen directly into the Gasserian ganglion, but the advantage of this is somewhat doubtful when compared with the extra hazard. In one case where, on account of certain circumstances, we deliberately injected the ganglion through the olivary foramen, the operation was followed by an almost complete paralysis of the seventh and eighth nerves of that side. The facial paralysis was most marked in the upper part. Within six months the facial paralysis cleared off, but the hearing of that side had not been restored. It is a little difficult to explain this accident. The centers of the involved nerves cannot be reached directly by a needle entering the cranial fossa through the foramen ovale when the injection is made from the external surface of the face. It would also be impossible to directly injure the trunks of the seventh and eighth nerve in this way. If the alcohol had leaked back into the posterior fossa along the root of the fifth nerve, then it seems that the sixth nerve should have been involved with the seventh and eighth. The least improbable explanation would be that the alcohol had followed the great superficial petrosal nerve to the aquæductus Fallopii.

Dr. W. T. Coughlin carried on a series of experiments in the anatomical laboratory at Washington University, in which he injected a solution of methylene blue at the foramen ovale from the outer surface of the cheek, as described above. In the majority of instances the



blue fluid entered the foramen ovale and stained the dura around the entire Gasserian ganglion. On patients we have seen an anesthesia of the second or first division follow an injection of the third.

**INJECTION OF SECOND OR SUPERIOR MAXILLARY DIVISION.**—This is injected by inserting the needle below the zygoma at the junction of the anterior with its posterior two thirds. It may be that the coronoid process of the jaw will be encountered, and if this is the case, the mouth must be held open with a gag or by placing a folded napkin or a cork between the anterior teeth or gums.

The external pterygoid plate is encountered at an average depth of 43 millimeters, depending on the size of the skull and the prominence of the zygoma. In twenty-two dried skulls the depth varied from 33 to 50 millimeters. When the external pterygoid plate is found, the point of the needle is made to step upward and forward until it is felt to drop into the sphenomaxillary fossa, when it will be in close proximity to the nerve sought, and also to the sphenopalatine (Meckel's) ganglion. In quite a large number of skulls there is a sharp outward flare of the anterior border of the external pterygoid plate just where it is crossed by the needle. If this is encountered, the needle must be drawn sufficiently to step over this obstruction. The needle, when in the fossa, should not have penetrated more than 5 millimeters deeper than it was when it first struck the surface of the pterygoid plate. On entering the fossa, the needle is directly in line with the sphenopalatine foramen of the palate bone and could penetrate into the cavity of the nose without encountering any bony obstruction. In this regard the rule that has been suggested, to insert the needle in a direction upward and forward and make the injection at a depth of 50 millimeters, might in some skulls lead one to make the whole injection directly into the nasal fossa. This injection of the second division is more difficult than that of the third. If for some reason the nerve is not located by the directions given, the needle may be made to travel still farther forward until the posterior surface of the superior maxillary bone is encountered, and then to travel upward as far as possible where the nerve is encountered, lying in a shallow groove on the upper posterior part of the maxillary bone (Fig. 362). If, in doing this, the needle is inserted too deeply, the injection may be made into the orbit through the sphenomaxillary fissure. In attempting this in a skull that is affected with osteoporosis, the injection might be landed in the antrum (Fig. 363). With Weiner's fluid this would be of small consequence, but alcohol is irritating. We have had this accident happen once.

**INJECTION OF THE SPHENOPALATINE GANGLION.**—In view of Sluder's work on neuralgia associated with irritations near the sphen-

palatine (Meckel's) ganglion, it is desirable to have a definite technic for reaching this ganglion. Sluder has been in the habit of injecting this ganglion through the nose by piercing the vertical plate of the palate bone, but with an operator less skilled, this would be a very uncertain mode of approach. Dr. Sluder and the writer have made a study of the practicability of an external approach. When the needle is inserted, as advised above for reaching the second division, the point of the needle usually stops in front of, or external to, the ganglion. It may be inserted just below the malar bone at a point directly below the angle between the temporal border of the malar bone and the upper border of the zygoma. The needle is pushed slightly upward and a very little backward until the pterygoid process is encountered. The needle is then slipped forward until it enters the sphenomaxillary fossa. The injection is made while moving the point

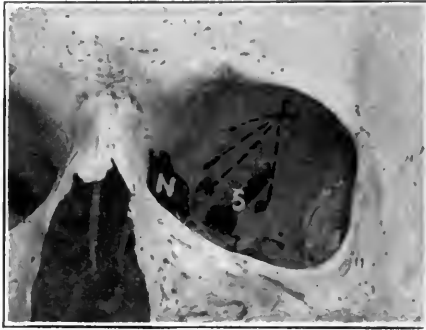


Fig. 364. Skull with osteoporosis. C, openings into the anterior fossa. N, opening into the nasal fossa. It will be seen that along the line of the frontosphenoidal suture there are no perforations, nor have we observed them in any skull examined.

of the needle up and down in the fossa, at a depth of 5 millimeters greater than that at which the point was when it encountered the pterygoid process. The mouth should be widely open. The success of this injection is determined by the anesthesia developed over the hard palate and within the nose over the turbinate bones and septum.

In many skulls a more direct approach could be made by entering the needle just within the angle between the temporal border of the malar bone and the upper border of the zygoma, and passing it inward and very slightly upward. The needle would encounter the external surface of the greater wing of the sphenoid bone, and then, by depressing the point, it would enter the sphenomaxillary fossa. The injection is to be made at a depth of 2 centimeters greater than at the outer surface of the great wing of the sphenoid. In skulls of some muscular persons, the prominence of the zygomatic crest might render this approach impracticable.

INJECTION OF THE FIRST OR OPHTHALMIC DIVISION.—This must be injected deep in the orbit just as it emerges from the sphenoidal fissure. The frontal and lacrymal branches enter the orbit through the outer part of the fissure, but the nasal branch lies rather toward its inner extremity. In making this injection, it is not permissible to insert the needle beyond the outer extremity of the sphenoidal fissure. The injection is made by inserting the needle under the external angular process of the frontal bone (Fig. 365), and following the outer wall of the orbit closely, backward, inward, and very slightly downward to a depth of 30 to 35 millimeters, depending on the size of the skull. In a number of skulls the distance of the outer end of the sphenoidal fissures from the external angular process of the frontal bone varied

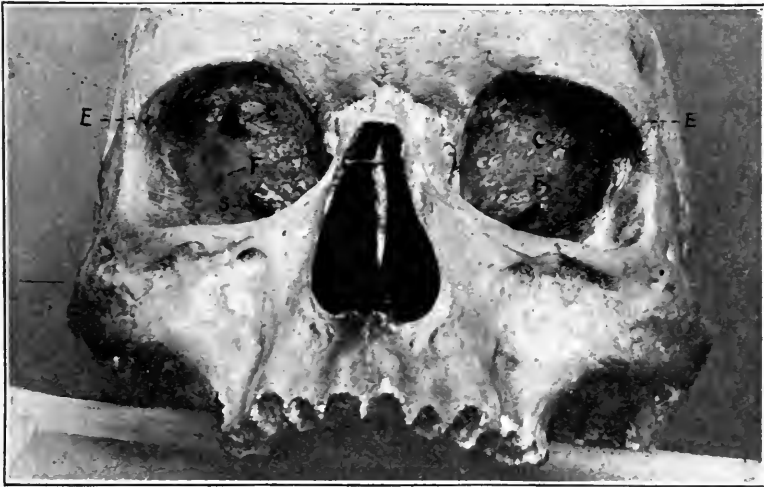


Fig. 365. Injection of the first frontal and lacrymal branches of the first division. E, point of entrance of the needle. S, sphenoidal fissure. C, perforation into the anterior cranial fossa. F, foramina leading to the sphenoparietal sinus.

from 33 to 45 millimeters. In some skulls the needle could have been pushed 10 millimeters beyond the outer end of the fissure without entering the anterior cranial fossa, while in others it would have entered immediately. In none of the skulls examined would the needle have touched the optic nerve at a depth of less than 43 millimeters. The fluid easily disseminates in the loose tissue in the back of the orbit, and in most instances a number of nerves are affected by the injection. We have seen dimness of vision follow, which passed off in ten days or two weeks, while the diplopia due to partial paralysis of the ocular muscles has lasted three weeks or more. In one case, a very sharp orbital hemorrhage, that caused closure of the lids and a pronounced exophthalmos that appeared in two minutes, caused no visual or other

subjective symptom and was apparently disseminated by the next day. That there is much greater danger in making this injection than in either of the other two, there can be no doubt. Patrick states that he has abandoned it on account of the extra hazard. The experience quoted above tends to show that this danger is not due to the possibility of hemorrhages. To what the blindness was due, in the case elsewhere cited, we do not know; possibly an excessive inflammatory reaction of the optic nerve due to the irritating fluid, for the nerve itself would probably not be touched.

In many skulls of older persons there are perforations in the orbital palate of the frontal bone, which forms the roof of the orbit (Fig. 364);

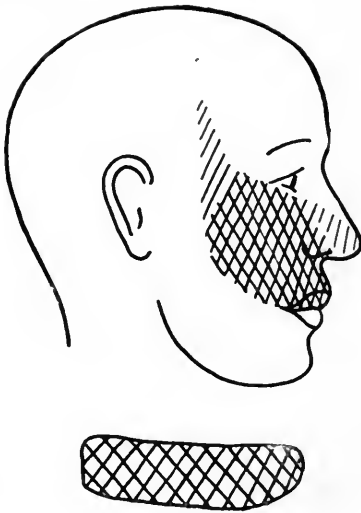


Fig. 366.

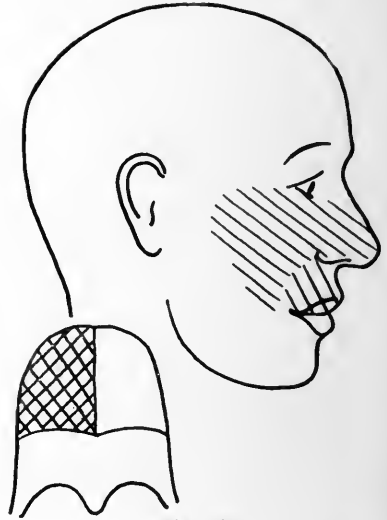


Fig. 367.

Fig. 366 shows the anesthesia that resulted from a deep injection of the second division of the fifth nerve in the case shown in Fig. 355. The palate is shown and also the right half of the upper gum.

Fig. 367 shows the relative amount of anesthesia that existed one month after the injection. Six months after the injection, the anesthesia had entirely disappeared. Some paresthesia still persisted ten months after the injection. Pain returned two years later.

but if the direction given, to keep the point of the needle applied to the outer wall of the orbit, is observed, there will be no danger of entering one of these. In some skulls (Fig. 365) there is a foramen in the suture between the orbital plate of the frontal bone and the lesser wing of the sphenoid that transmits a vein from the orbit to the sphenoparietal sinus. This lies directly in the path of the needle and may be of large size. It is not inconceivable that the point, becoming engaged in such a foramen, might cause a part of the injection to be shot into the sinus. With Weiner's solution this would have no serious consequence, but the injection of alcohol might result in embolism. On the whole, avul-

sion of the frontal nerve is a safer operation than the injection of any corrosive or hardening fluid deep into the orbit. At least, after proper explanation, the choice should be left with the patient.

The immediate effect of a successful injection with the alcohol formula (page 564) is a very severe pain radiating over the distribution of the nerve, which is usually quickly followed by an anesthesia and a subjective numbness, or possibly only the latter, but in either case the neuralgic pain is at once completely relieved (Figs. 366, 368, 370). There will be paresthesia, in the form of crawling sensations over the

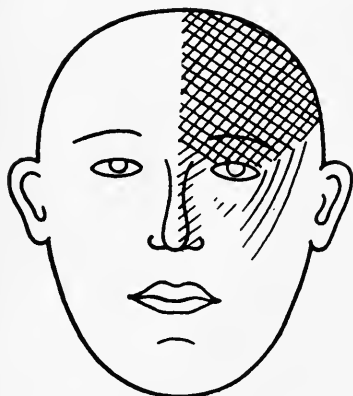


Fig. 368.

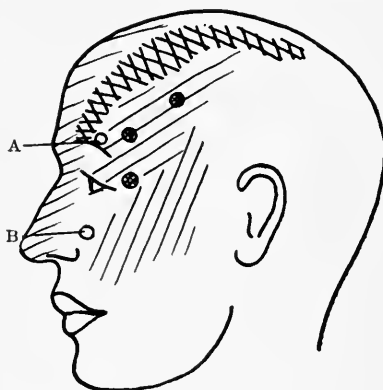


Fig. 369.

Fig. 368 shows the anesthesia that resulted from the injection of the first and second division of the left fifth on April 26, 1909. The chart was made on April 27. It will be seen that a much more complete anesthesia was obtained over the first than the second division. Note that partial anesthesia extended into the area of the nasal branch of the first division. There was some diplopia and dimness of vision after the operation, but it cleared up in a week.

Fig. 369 shows the condition of anesthesia on May 1, 1909, four days after the injection. In October, 1908, the whole of the frontal nerve had been removed back to the sphenoidal fissure, which probably accounts for the streak of absolute anesthesia that has persisted. The other anesthesia spots are probably due to some damage to the nerve fibers during the injection. Spots A and B were tender, due probably to the beginning of the return of protopathic sensibility. The pain in this case returned in one month, but not so severely as before operation. The anesthesia had not entirely disappeared six months after the injection. Ganglion operation refused. The obtaining of the definitely limited anesthesia by injecting the orbit after the avulsion of the frontal nerve brings up some interesting questions.

distribution of the affected nerve, and a sensation of stiffness over that side of the face. Complete and rather persistent loss of taste and also a weakness of the muscle of mastication on that side often follow the injection of the third division. With the alcoholic injections of the first and sometimes of the second divisions, there is a great swelling of the lids which subsides in forty-eight hours, and in all cases a slight swelling of the face that may last several days. There is often a little fever that may at first go to  $102^{\circ}$  or  $103^{\circ}$ , but we have never seen any serious inflammatory condition result. In a few days most of the anesthesia will have disappeared (Figs. 366 to 371), but traces of it will remain for six months to a year. The paresthesia may last longer.

In 75 per cent of the cases the pain had not returned, when last heard from at periods varying from several months to five years, and all had experienced some benefit from the operation. If the operation proves unsuccessful, the injection may be repeated as soon as the reaction subsides. The patient can be assured that the second injection will not be as painful as the first, at least not until the nerve is actually struck; and then the pain may be over in a few minutes. Sometimes it is more persistent. A number of patients have returned for reinjection at periods mostly between fifteen months and two and one half years. So far, these have experienced relief from the second injection, but it

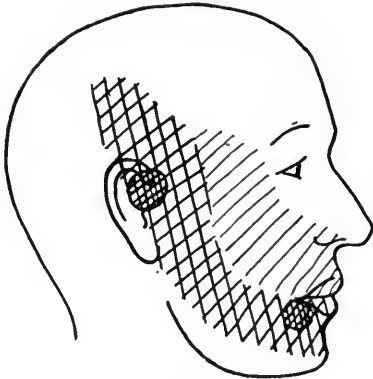


Fig. 370.

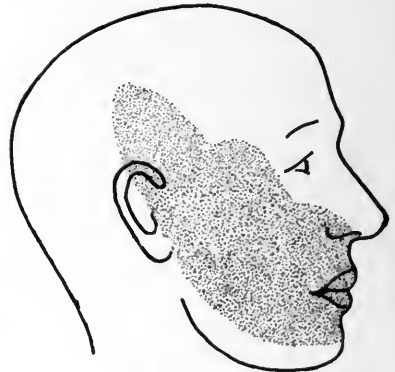

Fig. 371.

Fig. 370 shows the anesthesia after injection for neuralgia of the second and third division. The second division was injected on March 2, 1909, with almost total anesthesia resulting. The third division was injected March 24, 1909. It was charted on March 25, 1909. It will be seen that the anesthesia to pain and touch over the second division has considerably lessened between the time of injection and the time of charting. At the time of charting it was found that on the right side, the lingual and labial surfaces of the lower gum, the superior, inferior, and lateral surfaces of the anterior two thirds of the tongue, and the internal surface of the cheek below the occlusal line were completely anesthetic to touch, pain, and temperature; and sense of taste was lost in the anterior two thirds of the right half of the tongue.

Fig. 371 shows the area on the surface that was completely anesthetic to heat and cold. The anesthesia had not entirely disappeared nine months after the injection. Pain had persisted for fifteen years before injection, and had not returned one year after injection.

is possible that a time may come in many cases when the injection will no longer be efficient and that a ganglion operation may eventually be necessary.

It is always well to start with the understanding that it may require more than one injection to cure the pain. When the two divisions are involved, they may be injected at the same sitting if the patient stands it well; but the most painful branch should be treated first. Sometimes the injection of one division will be followed by relief of a pain spot that was situated over the distribution of another division, but often the neuralgia in the least affected nerve will become apparently worse after

its more severely affected neighbor has been relieved. The second and third can often be injected with one insertion of the needle, entering it as for the injection of the third division, and when that injection is made, shifting it forward to the second.

**Nerve Resection.**—**AVULSION OF THE FRONTAL NERVE.**—While apparently a simpler operation, resection of the supraorbital nerve is hardly a justifiable operation on account of the slight likelihood of its being of any great benefit. Normally there is a branch of the nerve that leaves the orbit to the inner side of the notch; both this and the supratrochlear, which is also likely to be involved, are difficult to find in the orbicularis palpebrarum muscle.

To avulse the trunk of the frontal nerve, the eyebrow is cleaned, but not necessarily shaved. The eyelid is held down with a sponge, and an incision made that starts near the outer end, follows the eyebrow, and curves downward at the root of the nose. The incision is made down to the periosteum, and all superficial tissues are turned downward, the supraorbital nerve being identified in the notch before the relations are greatly disturbed. The orbital contents are gently depressed with a spatula, and the supraorbital nerve is followed backward into the orbit until the supratrochlear branch is found passing to the trochlea of the superior oblique tendon. As far back as can be seen, the whole nerve trunk is grasped with a pointed artery forceps and twisted out. The skin and muscles are sutured *en masse* with deeper interrupted sutures without drainage.

**AVULSION OF THE NASAL NERVE.**—The nasal nerve is exposed by an incision extending from the supraorbital notch along the inner border of the orbit. The tissues, including the lacrymal sac, are drawn outward, the bone being followed closely to a depth of from 2 to 2½ centimeters. The tendon of the superior oblique muscle, which is attached to the bone internal to and behind the supraorbital notch, is to be avoided. The nerve leaves the orbit through the anterior ethmoidal foramen, where it can be caught with a hook and avulsed. If possible, the anterior ethmoidal artery that accompanies it should not be cut. If bleeding from the little artery should be persistent, a strip of gauze may be left in contact with the bleeding point and protruding through the wound. In closing the wound, use interrupted sutures and avoid puncturing the lacrymal sac with the needle.

**Intracranial Operations.**—If the attack upon the peripheral nerves proves primarily or ultimately a failure, then, to obtain relief, the interruption in the sensory conduction tract must be made at or proximal to the Gasserian ganglion.

In 1884, W. J. E. Mears first proposed the removal of the ganglion for tic douloureux, and in 1890, Rose performed the first successful

operation. In 1891, Horsley, failing to remove the ganglion, avulsed the sensory root. The complete extirpation of the ganglion is an extremely difficult operation, and one attended by very profuse and unavoidable hemorrhage.

The difficulty and danger encountered in separating the ophthalmic division from the wall of the cavernous sinus are such that Hutchinson has been led to abandon this part of the ganglion and to content himself with the removal of the parts related to the second and third division. In many cases, however, the first division is affected or becomes so later, and in a number of failures after supposed complete removal, it is in the distribution of the ophthalmic that the pain has returned.

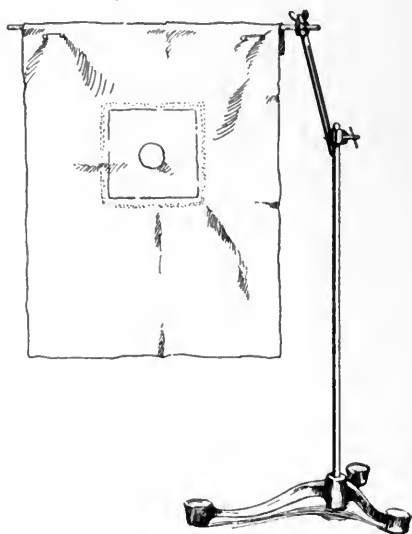


Fig. 372. Head apron on standard. Outer part is of double-faced rubber sheeting. The inner part is rubber dam.

The section or avulsion of the posterior root of the ganglion is a simpler operation, and is freer from hemorrhage. It is productive of less shock, and in doing it, one may be certain that all connection with the higher perceptive centers has been destroyed. It is probable that the ganglion has some trophic functions that are not interfered with by the posterior root section; therefore the operation of extirpation of the ganglion is being replaced by some operators for that of the posterior root section. Spiller first urged this as the operation of election, and Frazier has performed it probably more often than any one else. The only objection that can be urged against the latter operation in favor of the former is that in a certain percentage of cases the skillful operator can preserve the motor root intact while extirpating the ganglion,



which is almost impossible to do while simply cutting the posterior root.

OPERATION OF CUTTING THE POSTERIOR ROOT OF THE GASSERIAN GANGLION.—The danger of accidental meningeal infection is lessened by following the suggestion of Crow and Cushing, which is to administer hexamethylene tetramin in large doses before and after any operation in which the dura is opened. One-half gram of urotropin each six hours will liberate a demonstrable quantity of formaldehyde in the

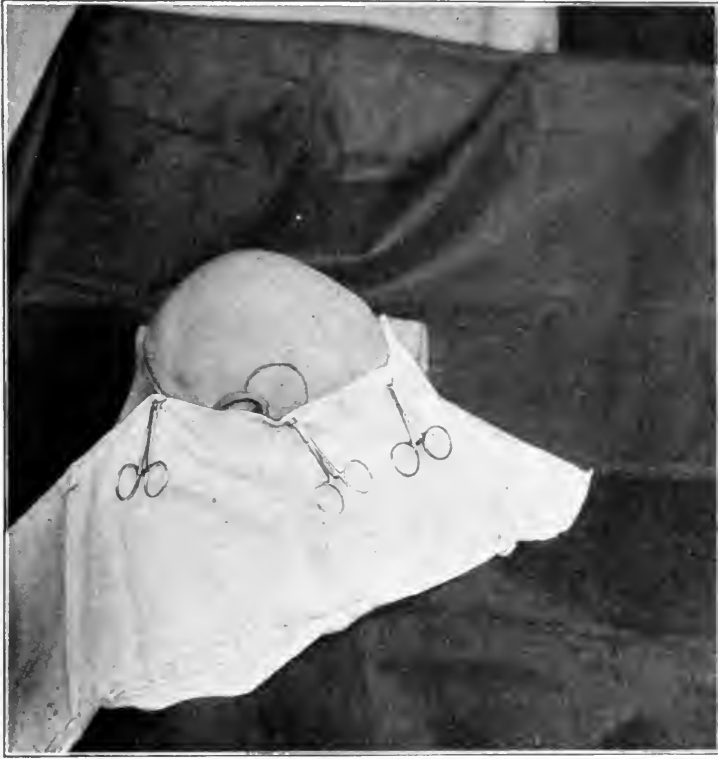

Fig. 373. Head apron in position. This completely separates the operative field from the anesthetic by an impervious wall.

cerebrospinal fluid. We usually give four grams a day in all intracranial operations.

The whole head, or at least the affected side, is shaved. In women the shaving of the whole head is often seriously objected to, and with care a clean field can be obtained as follows:

Shave on the affected side for a distance of 3 centimeters beyond the line of the proposed incision. Wash the scalp and hair thoroughly and rub the hair dry. Some women are apt to take cold after a hair-

washing. Plait the hair on the opposite pole of the head, so as to draw it away from the shaved field. To avoid the risk of contaminating the field while seeking for landmarks, after the area is cleaned, before the protective towels are in place, the line of incision is outlined with the point of a knife after the skin is prepared. The skin is disinfected, and if the whole scalp has not been shaved, the hair margin next to the field is plastered down with sterile adhesive plaster, which will prevent the hair from straying over into the field. This adhesive plaster is removed with gasolin after the wound has healed.

The operation is ordinarily done under morphin, atropin, gas, or ether anesthesia, but has been performed with a local anesthetic.

Before starting the operation, it has been our custom to withdraw 30 cubic centimeters of spinal fluid by lumbar puncture. By this

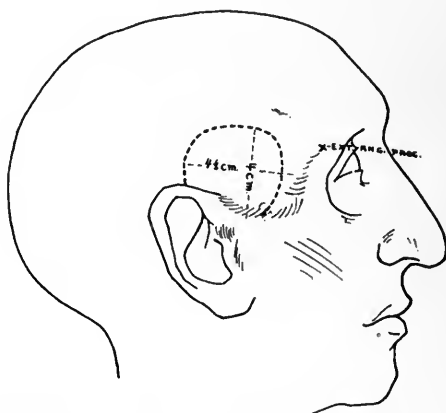


Fig. 374. Line of incision for resection of the posterior root of the Gasserian ganglion.

means more room is gained in the subdural space, and there is less compression of the intracranial contents. The patient sits almost erect in an operating chair or on a table with a back-rest that supports the head. The sterilized head apron (Fig. 372) or sheet is adjusted. The immediate operation field is surrounded by towels, that are pinned to the scalp or fastened with small tenaculum forceps (Fig. 373). A horseshoe incision is made, beginning at the middle of the zygoma and carried at first upward and slightly forward, the highest point being 4 centimeters above the zygoma or on the level of the external angular process of the frontal bone. It terminates just below and behind the upper part of the attachment of the ear. The incision (Fig. 374) is made straight down to the bone, and the flap, which includes the periosteum, is turned down. The scalp flap is 4 by 4½ centimeters, and should not extend anteriorly beyond the average hair-line. The in-

cision is somewhat larger than that used by Frazier. In doing this, the branches of the temporal artery and vein are cut and must be caught. When the bleeding of the flap and scalp is controlled, the flap is held down by a tenaculum forceps (Fig. 375), and is covered by a towel which is pinned in place. The squamous part of the temporal bone is opened in the middle of the bare area and rongeured away until an opening 3 by 4 centimeters is made, that extends as far forward as the vertical part of the middle meningeal artery and as far

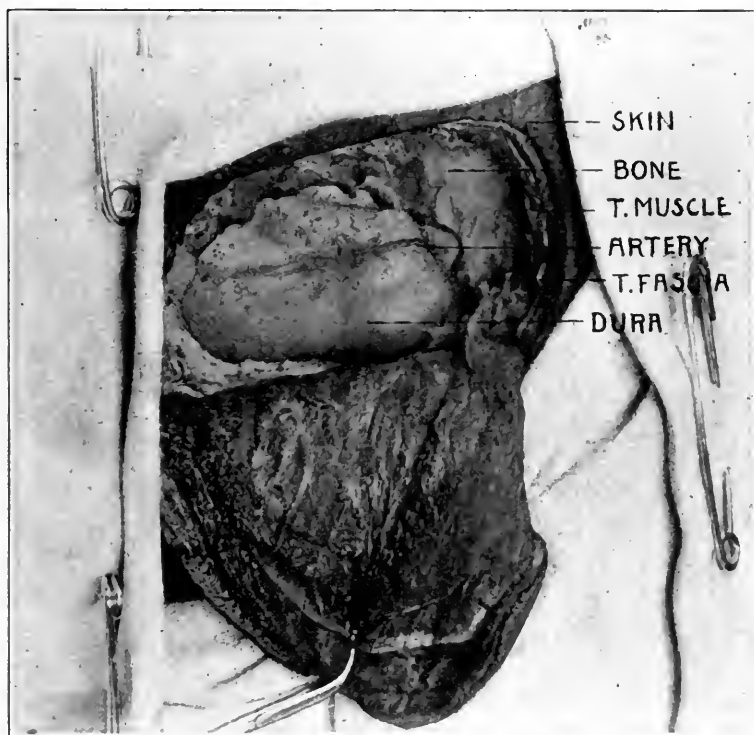


Fig. 375. Section of the posterior root of the fifth nerve. Flap turned down, skull opened, and dura exposed.

below the upper border of the zygoma as can be conveniently done. The squamous part is of compact bone, and does not usually bleed from diploë.

In this operation the nerve root is reached by raising the dura, with the enclosed brain,  $1\frac{1}{2}$  centimeters from the cranial floor; this must cause some compression, and for this reason we resort to preliminary spinal puncture. In Krause's operation for the extirpation of the ganglion, the contusion that occurs while elevating the brain has been the cause of fatal brain injury. Krause suggests making a

minute incision in the dura to allow the escape of the cerebrospinal fluid. This or a spinal puncture will lessen the danger of brain injury, if the end of the retractor is not pressed sharply against the cerebrum. If this opening is made, it should not be larger than 2 millimeters, as the brain substance might protrude through a larger one. A possible objection to this puncture is that in case of infection it might more easily permit of intradural extension. The dura and the brain are elevated by inserting a spatula or elevator along the cranial floor. There will be found some attachment of the dura along the petrosquamosal suture (Fig. 376), into which small branches of the meningeal artery may enter. Hemorrhage from these is controlled by apply-

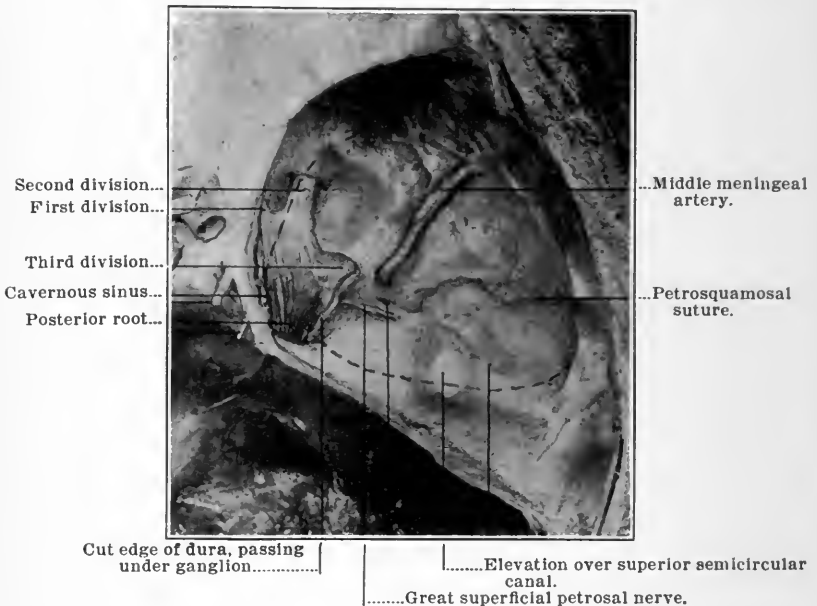


Fig. 376. Area on the floor of the middle cranial fossa, from which the dura is elevated (as indicated by the dotted line), and the structures exposed.

ing a small flat gauze sponge and holding in place with a retractor. The retractor should be of thin metal that can, if desired, be rebent during the operation. The blade should be  $1\frac{1}{2}$  to 2 centimeters wide and 4 centimeters long. Frazier uses the handle of a spoon bent to the desired shape. At a depth of about 2 centimeters the trunk of the middle meningeal artery will be seen emerging from the foramen spinosum. The artery has a free course of about 5 millimeters before it enters the dura (Fig. 377). This part of the trunk is to be carefully freed all around. It is at once surrounded by a ligature or grasped close to the dura with small pointed artery forceps. In the latter

case the artery is cut between the dura and the forceps, and a linen or silk ligature is thrown around the trunk and tied before the forceps are released (Fig. 378). This method of ligating the artery precludes the possibility of cutting the ligature with the artery, or cutting the artery too close to the ligature. Immediately beyond the artery lies the Gasserian ganglion inclosed in an envelope formed by the splitting of the dura into two layers. At the outer edge of the ganglion the process of the dura that passes under the ganglion is incised with a knife or sharp elevator. This exposes the outer border of the ganglion, and dissection is continued until the posterior root is found entering its posterior part and until the outer wall of the cavernous sinus is encountered (Fig. 379). The posterior root is not anywhere adherent




Fig. 377. Free part of middle meningeal artery, passing from the foramen spinosum to the dura.

to its dural coverings, and it can be lifted from its bed with ease. It is not a solid nerve trunk, but is composed of a number of detached threads; all of which must be cut in order to ensure the success of the operation. This is best done by passing a small blunt hook across to the wall of the cavernous sinus and drawing the root outward until it can be caught with forceps and avulsed. The hook used for this purpose should not only be blunt but smoothly rounded, and even probe-pointed, so that there can be no danger of injury to the wall of the sinus. It is not practical to attempt to recognize and preserve the motor root.

The operative field traversed along the base of the skull, the various structures encountered, and the relative size of the posterior

root are shown in Fig. 376. The operator must not work too far backward before opening the envelope of the ganglion, lest the superior petrosal sinus, which lies just behind the elevation of the superior semicircular canal, be endangered, bleeding from which would be embarrassing. As the operation progresses, hemorrhage is controlled by the pressure of folded strips of gauze held in place by the retractor or narrow spatula. Frazier recommends that, after the posterior root is cut, the patient should be allowed to come from under the anesthetic in order that the cutaneous sensations can be tested to be sure the whole

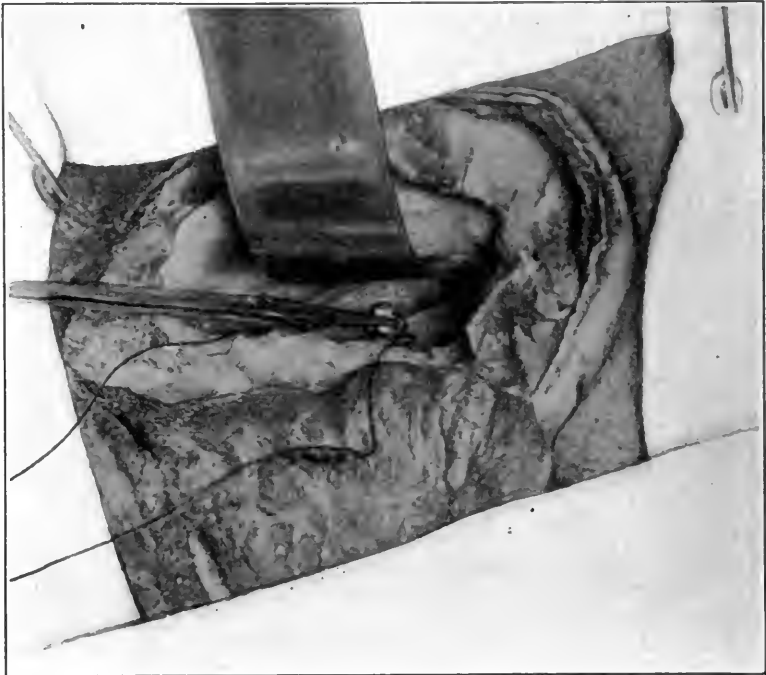


Fig. 378. Tying the middle meningeal artery.

trunk is severed. A rubber tissue drain is inserted, and the wound is closed by suturing the flap in place with interrupted silkworm gut sutures, that embrace the full thickness of the scalp. The drain is removed in twenty-four hours. The sutures which have not drawn tight are cut in twenty-four hours and are removed in two days. If the motor root were preserved, the temporal muscle would have to be sutured separately.

The mortality from the more recent ganglion operations in the hands of experienced operators is less than 4 per cent. Frazier had one death ten days after operation, out of 28 operations of posterior

root section. In ganglion extirpation most of the deaths have occurred within the first twenty-four hours after the operation from shock or hemorrhage, both of which are less in the root operation than in the extirpation.

The effects of the operation are paralysis of the muscles of mastication in the affected side when the motor root is cut, and an absolute anesthesia over the areas that are supplied wholly by the fifth nerve. There should be no risk of injury to the third, fourth, and sixth nerves

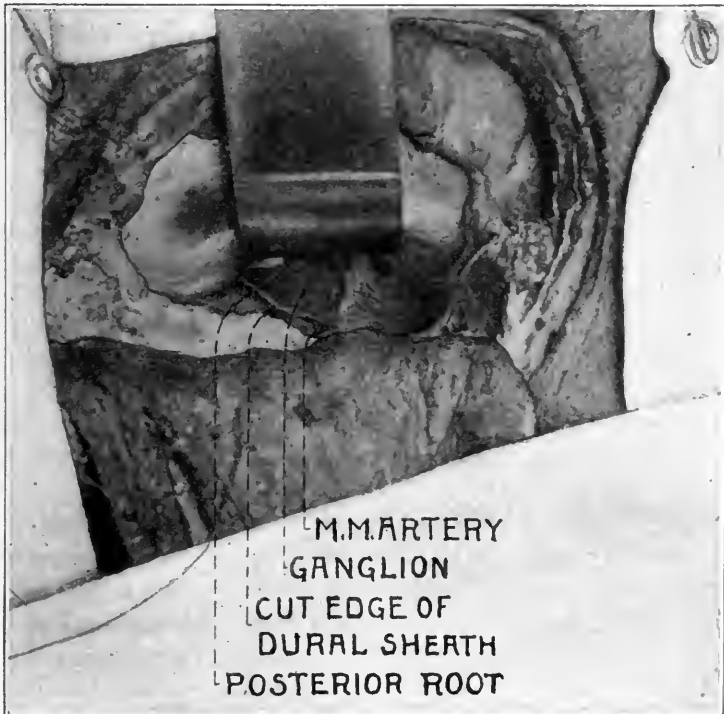


Fig. 379. Display of the posterior part of the ganglion and of the posterior root.

in this operation, and if the brain is elevated evenly and carefully, no cerebral damage will result.

Ulceration of the cornea is a common postoperative complication of the removal of the ganglion, but according to Spiller, it is not so frequent after posterior root section. The eye should be protected by a transparent shield for several weeks after the operation, and the possibility of corneal ulceration should not be dismissed till after three months have elapsed. It is very probable, but not absolutely certain, that posterior root section will cure every case of tic douloureux.

## CHAPTER XLIII.

### LOCAL ANESTHESIA.<sup>1</sup>

When, in 1853, Alexander Wood popularized a method of general medication by means of hypodermic injections, he gave the impetus toward a method which is now used universally—namely, to inject some drug for producing local anesthesia. At that time, however, morphin or tincture of opium was the drug used, and it was not until cocain was tried that the full value of the hypodermic injection was realized.

Cocain was discovered by Niemann in 1859, but it required twenty-five years to make known the remarkable anesthetic properties which this alkaloid possessed when applied in the readily soluble form of its hydrochloric salt. It was on September 15, 1884, that Carl Koller, of Vienna, presented his epoch-making communication at the Ophthalmologic Congress at Heidelberg, in which he demonstrated the effects of cocain as a local anesthetic. With the introduction of this drug into therapeutics, local anesthesia achieved results which were beyond expectation, and its final adoption created a new area in local anesthesia.

#### MEANS OF PRODUCING LOCAL ANESTHESIA.

We produce local anesthesia by inhibiting the sensory nerve fibers in their course or at their peripheral end-organs. This is done: (a) by inhibiting the function of the peripheral nerves in a small area of tissue—terminal anesthesia; or (b) by blocking the conductivity of a sensory nerve trunk somewhere between the brain and the periphery—conductive anesthesia. There are two methods of producing local anesthesia: (1) the production of local anemia; (2) the action of certain drugs that directly obtund the conducting power of sensory nerves.

**Means of Producing Anemia.**—Local anemia can be produced (1) by the Esmarch elastic bandage. In surgery of the head, however, this obviously cannot be used. (2) A second means of producing anemia is by reducing the temperature of the body by the application of cold. This is best accomplished by the use of pure ethyl chlorid (boiling point 55° F., 13° C.) in an ether spray. Mixtures of the ethyl chlorid and methyl chlorid in various proportions—known as

---

<sup>1</sup>The history of local anesthesia and its applications to dental operations are largely gathered from the article by Dr. Hermann Prinz, "Modern Methods of Producing Local Anesthesia," in the Dental Summary, February, March, and April, 1912.



anestol, anestile, coryl, methethyl, etc.—are extensively used in oral and general surgery. These mixtures produce a deeper anesthesia, but they may cut off the circulation so completely as to produce necrosis. Carbonic acid snow, liquid air, and liquid nitrous oxid gas all have a boiling point far below zero and have been recommended, but they are not so easy to administer and are dangerous.

Ethyl chlorid is the most satisfactory agent for producing refrigeration of the tissues. For the extraction of teeth and any minor operation about the head and oral cavity, the capillary end of the tube should be held about six to ten inches from the part to be sprayed. The Gebauer tube is fitted with a spray nozzle, which shortens the distance to one or two inches, and is especially well adapted for dental purposes. The part should be sprayed until the tissues are covered with ice crystals and have turned white. The tissues to be anesthetized should be dried well, and the adjacent tissues should be rubbed with vaselin or glycerin. If the stream is to be directed to some part within the mouth, cotton rolls and gauze should be packed around, to prevent the liquid from running down the throat. For the extraction of teeth the liquid should be projected directly upon the surface of the gum, as near the apex of the root as possible, but care should be taken to protect the crown of the tooth on account of the painful action of the cold on this part. On account of the difficulty of directing the stream of ethyl chlorid upon the tissues in the posterior part of the mouth, it is not successfully applied in these regions. The intense pain produced by the extreme cold prohibits its use in pulpitis and acute pericementitis. To anesthetize the second and third branch of the fifth nerve, it is recommended to direct the stream of ethyl chlorid upon the cheek in front of the tragus of the ear, but we have not seen good results from such a procedure.

The injection of adrenalin is a third means of producing local anemia. It acts as a powerful vasoconstrictor and stimulates the smooth muscular coat of the blood vessels. While adrenalin does not possess local anesthetic action, it increases very markedly the effect of certain anesthetics when combined with them. A very weak solution gives the desired local result and has no effect upon the tissues or on the healing of the wound.

A synthetic suprarenin has recently been introduced which, with hydrochloric acid, forms a stable and readily soluble salt. Its advantages over the organo-preparations has led us to adopt it as a component in the preparation of local anesthetic solutions. For dental purposes—that is, for injecting into the gum tissue—the dose may be limited to one drop of the adrenalin solution (1:1000), or the synthetic suprarenin solution (1:1000), added to each cubic centimeter of the

anesthetic solution. The injection of plain normal saline solution into the tissues, under pressure, especially into the skin, will obtund the terminal nerves. This method is frequently used, but is less efficient and has no advantage over a very weak cocain or novocain solution.

**Cocain and Substitute Drugs.**—Ever since the introduction of cocain into materia medica for the purpose of producing local anesthesia, quite a number of substitutes have been placed before the profession, for which superiority in one respect or another is claimed over the original cocain. The more prominent members of this group are tropacocain, the eucains, acoïn, nirvanin, alypin, stovain, novocain, and very recently, quinin and urea hydrochlorid. None of these compounds, with the exception of novocain, has proved satisfactory for the purpose in view. The classical researches of Braun have established certain factors which are imperative to the value of a local anesthetic. These factors concern their relationship to the tissues, in regard to their toxicity, irritation, solubility, and penetration, and to the toleration of adrenalin.

Although the novocain has the same anesthetizing power as cocain when injected into the tissues, it is not so easily absorbed on a mucous surface, and therefore, for anesthetizing by local application, cocain is preferable to novocain. Not the least of its good points is that it will combine with adrenalin in any proportion, without lessening the effect of the latter. When adrenalin is added to the novocain solution, it prolongs its action, lessens the danger of general intoxication, and enables the operator to use a much smaller dose than he could use when he uses either one separately. At the same time, however, it increases the length of time required for the drug to act. Sometimes fifteen minutes must elapse before anesthesia is accomplished, when adrenalin has been added to the solution.

The dose of novocain is about one third of a grain in a  $1\frac{1}{2}$  or 2 per cent solution. A  $\frac{1}{5}$  to  $\frac{1}{2}$  per cent solution of novocain combined with adrenalin chlorid in physiological salt solution has been frequently injected by us in quantities of 2 grains of the drug for a single anesthesia. The addition of the adrenalin, with its powerful vasoconstrictor action, confines the injected novocain to a given area. It is *the* important factor which prevents the ready absorption of both drugs, and consequently largely nullifies poisonous results.

**ABSORPTION OF POISONOUS DRUGS.**—There are some persons, usually those who might be described as "nervous," upon whom it is very difficult to establish a satisfactory local anesthesia; and it is difficult to state when a patient may collapse under a local anesthetic. It is merely a matter of using common sense to decide whether a patient shall receive a local anesthetic or not. If, for instance, a patient ap-

pears to be in a condition that indicates general derangement of the system, cocain, novocain, or any other anesthetic is not indicated. It is important to note that novocain is much safer than other drugs of this nature. The danger of injecting in a pus-pocket must always be borne in mind, for the infection can easily be pressed on ahead into sound tissue. The injection should be made into the sound tissues and in such a way as to encircle the diseased area, or the nerve to be blocked.

Danger from the injection of cocain or its substitutes is lessened by limiting the general absorption of the injected fluid, which may contain very poisonous drugs. We have, however, a good working principle to go by: that local anemia or ischemia prevents the rapid absorption of fluids that are injected into a circumscribed area. Moreover, if the absorption of the fluid is retarded, there results an increase in the local action of the poisonous drugs; and increased local action means increased local consumption of the poisonous drugs, and consequently less danger from general absorption.

**PREPARATION OF THE ANESTHETIC SOLUTION.**—In order to get the best results from the injection of anesthetizing drugs, the solution should be isotonic with the body fluids.

Osmotic pressure is a physical phenomenon which is dependent on the number of molecules of salt present in a solution, and on their power of dissociation. Equal osmotic pressure becomes established when the salt solution is of the same concentration on each side of a permeable animal membrane. The membrane of a living cell readily absorbs distilled water, but if, on the other hand, the surrounding fluid is a highly concentrated salt solution, the solution absorbs water from the cell; and the cell shrinks and finally dies. This process is called necrobiosis.

The pain, or tissue necrosis that frequently follows an injection, is usually due to using a solution that is not isotonic with the tissue fluids.

By means of still another physical law the proper concentration of fluids for intracellular injection may be determined. All aqueous solutions possessing an equal freezing point have equal osmotic pressure. A physiological salt solution which at body temperature has the same osmotic pressure as the tissue fluids can be injected into the loose connective tissues under the skin in moderate quantity, and neither swelling nor shrinking of the cell will occur. A simple wheal will form, which causes no irritation, and consequently no pain is felt.

A solution of novocain for dental purposes may be prepared as follows:

Novocain,	.648
Sodium chlorid,	.259
Distilled water,	29.573

To each syringeful (2 cubic centimeters) add 2 drops adrenalin chlorid solution when used.

A sterile solution may be made extemporaneously by dissolving the necessary amount of novocain-adrenalin in tablet form in a given quantity of boiled distilled water. A suitable tablet may be prepared as follows:

Novocain,	.022
Synthetic superarenin hydrochlorid,	.000054
Sodium chlorid,	.022

One tablet in  $1\frac{1}{5}$  cubic centimeters of sterile water makes a 2 per cent solution of novocain ready for immediate use.

For cutaneous operations we seldom use a solution of greater strength than  $\frac{1}{2}$  per cent novocain. Usually  $\frac{1}{5}$  per cent solution properly injected is sufficient. For cutaneous anesthesia a less amount of the adrenalin chlorid solution is used, one drop of the 1:1000 adrenalin chlorid solution to ten cubic centimeters of anesthetic solution being sufficient. If a too concentrated solution of adrenalin chlorid is used, it will produce gangrene of the skin.

Solutions for hypodermic purposes should preferably be made fresh when needed. A small glass dish and a dropping bottle constitute the simple outfit for dental purposes.

The novocain and sodium chlorid may be boiled indefinitely, but the amount evaporated should be replaced with sterile water before the solution is used. The adrenalin will not stand boiling, neither will it keep after it has been added to the aqueous solution.

### HYPODERMIC ARMAMENTARIUM.

In order to successfully inject a local anesthesia, it is important that one should have the right kind of a hypodermic syringe. The injection into the dense gum tissue requires from 15 to 50, or more, pounds of pressure, as registered by an interposed dynamometer, while in pressure anesthesia 100, or more, pounds are frequently applied. After making a thorough test of most of the dental hypodermic syringes offered at the dental depots within the last five years, by means of the pressure and in clinical work, we recommend the all-metal syringe of the "Imperial" type. They are usually made of nickel-plated brass, which, however, is a disadvantage, as the nickel readily wears from the piston and exposes the brass. The "Manhattan" all-metal platinoid syringe gives the best general service for dental work. It holds 40 minims (2.4 cubic centimeters), and is provided with a strong finger

cross-bar. The space between the cross-bar and the piston-tip is of importance, as it allows the last drop of the fluid to be expelled under heavy pressure without tiring the fingers. The syringe described is designed for injecting under considerable pressure. This is needed in working in the mucoperiosteum of the gums and palate. For the ordinary soft tissues such great pressure is not needed. But the connections should be tight, and they should be able to withstand considerable pressure. Some syringes with slipjoints are not adapted to infiltrating even the skin, because the force necessary will dislodge the needle from the barrel. For injecting a small amount of fluid, the ordinary hypodermic will suffice, but for using a diluted infiltrating solution, it is more convenient to use a syringe that will hold 10 or 20 cubic centimeters of the solution. Regardless of the type of syringe used, it should be so constructed as to stand boiling. In using a dental syringe with leather packing, the latter is to be removed before boiling.

For infiltrating the skin, a very fine needle is preferable; its insertion causes less pain, and it causes less laceration. For infiltrating deep tissues, a coarse needle will do the work more quickly and effectually. The length of the needle should be adequate to the work in hand.

### TECHNIC OF INJECTION.

The anesthetic may be forced into the tissues in or about the teeth in the following ways:

- Subperiosteal injection.
- Peridental injection.
- Intraosseous injection.
- Perineurial injection.
- Injection into the pulp.

For operating on the soft tissues, the solution is injected directly into the tissues to be cut, or around the sensory nerves supplying the area. For operations confined to a small area of mucous membrane, local application of a strong novocain or cocain solution is permissible.

Before any further steps have been taken, the field of operation should be thoroughly cleansed with an antiseptic solution. A thin coat of the official tincture of iodine painted over the surface is very good for this purpose. After the diagnosis has been made, the method of injection is determined. The anesthetic solution should now be prepared, and the syringe and needle made ready for use. To facilitate the ready penetration of the needle into the tissues, its point may be coated with sterile vaselin.

The hand holding the syringe is governed by the wrist so as to allow delicate and steady wrist movements, and the fingers must be trained to a highly developed sense of touch. The syringe is filled by drawing

the solution into it; it is held perpendicularly, point up, and the piston is pushed in until the first drop appears at the needle point, which precaution prevents the injection of air into the tissues.

**Subperiosteal Injection.**—The success of this depends upon the penetration of the fluid into the bone and thus reaching the contained nerves. The subperiosteal injection about the root of an anterior tooth is best started by inserting the needle midway between the gingival margin and approximate location of the apex. The pain of the first puncture may be lessened by a very fine needle, by the compression of the gum with the finger tip, by holding a bit of cotton saturated

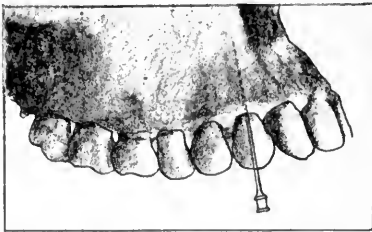


Fig. 380.

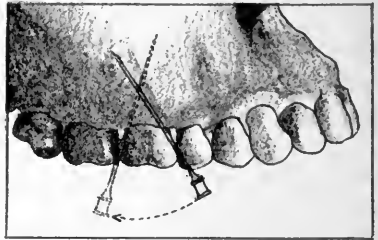


Fig. 381.

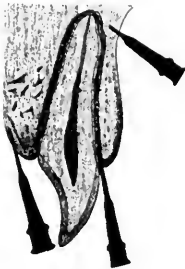

Fig. 382.

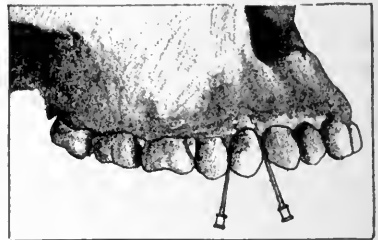


Fig. 383.

- Fig. 380. Subperiosteal injection of a cuspid tooth.—After Prinz.  
 Fig. 381. Subperiosteal injection of a molar tooth.—After Prinz.  
 Fig. 382. Subperiosteal, periodental, and intraosseus injection of a cuspid tooth.—After Prinz.  
 Fig. 383. Periodental injection of a bicuspid tooth.—After Prinz.

with the prepared anesthetic solution on the gum for a few moments, or by applying a small drop of liquid phenol on the point of puncture. The needle opening faces the bone, and the syringe is held at an acute angle with the long axis of the tooth. After puncturing the mucosa, a drop of the liquid is immediately deposited, rendering further injection painless. As the needle is forced along the alveolar bone toward the apex of the tooth, the liquid is deposited under pressure close to the bone on its upward and return trip. The continuous slow moving of the needle prevents injecting into a vein. A second injection may be made by partially withdrawing the needle from the puncture and

swinging the syringe anteriorly or posteriorly from the first route (Figs. 380, 381). After removing the needle, place the finger tip over the puncture and gently massage the injected area. No wheal should be raised by the fluid, as that would indicate superficial infiltration and failure of the anesthetic. Five to ten minutes should be allowed before the extraction is started.

The upper eight anterior teeth usually require a labial injection only, while the molars require both a buccal and a palatine injection, using a slightly covered needle for this purpose.

The lower molars require a buccal and lingual injection. The curved needle is inserted midway between the roots, the gum margin, and the apices. The external and internal oblique lines materially hinder the ready penetration of the injected fluid, and therefore ample time should be allowed for its absorption.

The injection into inflamed tissue, into an abscess, and into phlegmonous infiltration about the teeth is to be avoided. The injection into engorged tissues is very painful. The dilated vessels quickly absorb the anesthetic without producing a complete anesthesia, and poisoning may result. In purulent conditions the injection is decidedly dangerous, as it may force the infection beyond the line of demarcation. If the abscess presents a definite outline, the injection has to be made into the sound tissue surrounding the focus of infiltration. If a tooth is affected with acute, diffuse, or purulent pericementitis, a distal and a mesial injection usually produces successful anesthesia by blocking the sensory nerve fibers in all directions.

**Peridental Injection.**—This simple method, which consists in injecting the anesthetic by means of a fine, short needle into the peridental membrane between the tooth and the alveolar wall, is a most satisfactory method of anesthetizing teeth standing singly, or teeth affected by some chronic peridental disturbance. To accomplish this, separation of the teeth is often necessary. The injection is usually repeated two or three times. A higher pressure is used than in the former method, but the amount of fluid used is much less. The results are extremely satisfactory, and this method should be used whenever conditions justify it (Figs. 382, 383).

**Intraosseous Injection.**—In 1896, Otté recommended this method, by which he forces the anesthetic solution directly into the spongy cancellous bone. This is more direct and more certain of result than subperiosteal injection. To do this, the gum tissue must be anesthetized above the neck of the tooth, in the same manner as outlined under subperiosteal injection. Then an opening is made into the bone on the buccal side with a fine spear drill or a Gates-Glidden drill. The opening should be made more or less at a right angle with the long axis

of the tooth, a little below the apical foramen in single-rooted teeth, or between the bifurcation in the molars. The right-angled hand piece is preferably employed for this purpose. The drill should be of the same diameter as the hypodermic needle. The gum fold is tightly stretched to avoid laceration from the rapidly revolving drill. As soon as the alveolar process is penetrated, a peculiar sensation conveyed to the guiding hand indicates that the alveolus proper is reached, and the sensation felt by the hand is about the same as that experienced when a bur enters into the pulp chamber. In this artificial canal the close-fitting curved needle of the hypodermic syringe is now inserted, and the injection is made in the ordinary way. The quantity of fluid used is much less than is usually needed for a subperiosteal injection. The roots of the teeth are imbedded in a sieve-like mass of bone tissue

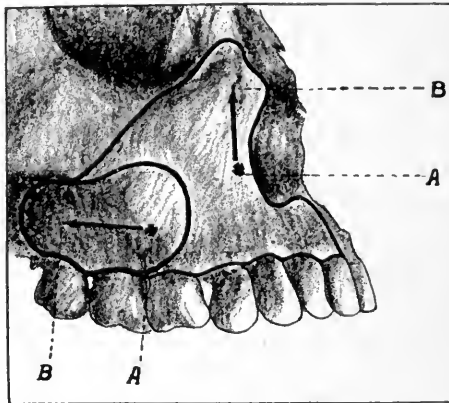


Fig. 384. Subperiosteal and perineurial injection for the control of the dental branches of the maxillary nerve.—After Priuz. A, point of insertion of the needle in the gum. B, point at which the injection is made.

(diploë), which allows a ready penetration of fluid when injected under pressure. Very recently, Masselink advocated this method for the anesthetization of any tooth in the mouth, either for the purpose of extraction or the removal of its pulp. He employs a No.  $\frac{1}{2}$  round bur for penetrating the alveolar plate and a very short needle (one sixteenth of an inch) with a dull point for injection (Fig. 382).

**Perineurial Injection.**—When a number of teeth or a large area is to be anesthetized, this method is preferable. It consists in injecting the fluid about the nerve trunks at some convenient point to block afferent impulses. All the teeth of one half of the upper jaw can be anesthetized by four injections—two buccally, and two on the palatine side of the bone. A one-inch needle is required for this work (Fig. 384).



(1) To reach the many small branches of the posterior dental nerves at the alveolar foramina, the injection is made buccally above the region of the tuberosity, about one-half inch above the gingival line, the needle entering between the first and second molar tooth, and being pushed upward and backward close to the bone.

(2) The second injection is made below the infraorbital foramen, so as to reach the middle and anterior dental nerves. With the index finger of the left hand, the foramen is approximately located by exerting pressure upon the nerve-exit. The lip is lifted up with the middle finger of the same hand, and the needle is now inserted between the apices of the cuspid and the first bicuspid teeth. The needle is slowly pushed upward until its point is felt beneath the finger tip.

(3) The nerves of the palate are blocked. Clinical observation has taught that the teeth are sensitized, not only through their proper maxillary nerves, but also through branches of the fifth nerve distributed to the neighboring soft tissue. In the upper jaw the posterior palatine and nasopalatine nerves must be controlled.

(4) To anesthetize one half of the mandible, three injections are necessary: the first near the mandibular foramen, the second near the mental foramen, and the third into the incisive fossa. The injection of the lingual nerve with the inferior dental will obviate the latter injection.

The technic for injecting the various nerves about the jaw was given under the Treatment of Neuralgia.

**Anesthetization of the Pulp.**—By pressure anesthesia, pressure cataphoresis, or contact anesthesia, as the process is variously termed, we understand the introduction of a local anesthetizing agent in solution by mechanical means through the dentin into the pulp for the purpose of rendering this latter organ insensible to pain. Simple hand-pressure with a suitable instrument, the hypodermic syringe or the so-called "high pressure" syringe, is recommended for such purposes. A liquid cannot be forced through healthy dentin by a mechanical device without injury to the tooth itself. If a cocain solution is held in close contact with the protoplasmic fibers of the dentin, the absorption of cocain takes place in accordance with the law of osmosis. By drying out the dentin and then confining the anesthetic solution under a water-tight cover, the pressure applied by the finger is sufficient to obtain results. In teeth not fully calcified and in so-called "soft" teeth, pressure anesthesia is more readily obtained, while, according to Zederbaum, the process fails in teeth of old persons, teeth of inveterate tobacco chewers, worn, abraded, and eroded teeth, teeth with extensive secondary calcific deposits, teeth whose pulp canals are obstructed by pulp nodules, teeth with metallic oxids in tubules, teeth

with leaky fillings, mainly all from one and the same cause—namely, clogged tubules. In most of these cases no amount of persistent pressure will prove successful.

From the foregoing, it will be observed that the so-called "high pressure" syringes possess no special merit relative to pressure anesthesia. A good all-metal syringe can be made to produce from 250 to 300 pounds pressure; this is much greater than is needed in the ordinary forms of pressure anesthesia.

**METHODS.**—(1) The pulp is wholly or partially exposed. Excavate the cavity as much as possible, and if the pulp is not plainly exposed, dehydrate with alcohol and hot air. Saturate a pledget of cotton with a concentrated cocain or novocain solution, place it in the cavity, cover it with vulcanizable rubber, and with a suitable burnisher apply slowly increasing, continuous pressure from one to three minutes. Now expose the pulp and test it. If it is still sensitive, repeat the process.

(2) The pulp is covered with a thick layer of healthy dentin. With a very small spade drill bore through the enamel or directly into the dentin at a most convenient place, guiding the drill in the direction of the pulp chamber. Blow out the chips, dehydrate with alcohol and hot air, and apply the syringe, provided with a special needle, making as nearly as possible a water-tight joint. Apply slow, continuous pressure from two to three minutes. With a round bur the pulp should now be exposed, and if still found sensitive, the process is to be repeated. The intraosseus or peridental injection is the most practical method of anesthetization of the pulps.

The anesthetizing of the peridental membrane for the treatment of pyorrhea alveolaris is a comparatively simple matter, if carried out according to the methods as outlined under the heading of Peridental Anesthesia. Sometimes a topical application of a fairly concentrated novocain-adrenalin solution (about 10 per cent), applied to the pockets by means of cotton ropes, accomplishes the desired purposes. The careful application of 10 per cent cocain on small cotton wisps left in place for ten minutes is more efficacious. This solution should not be allowed to drip into the mouth. The surgical treatment of pyorrhea is materially simplified, if the tissues under consideration are relieved of sensation.

### LOCAL ANESTHESIA FOR OPERATIONS ABOUT THE MOUTH.

For opening the antrum, a submucous and subperiosteal injection is made with a 2 per cent novocain solution over an appropriate area in the canine fossa, and sufficient time is allowed for the solution to diffuse through the bone before the operation is begun.

For very small incisions a 1 or 2 per cent solution may be used, but if a large area is to be anesthetized by direct infiltration, a much weaker solution must be used. Schleich popularized the use of weak cocain solutions in large quantity, put in under pressure. We have modified his solution by the substitution of novocain and the addition of adrenalin. The following solution will be found effective in most people, and can be used in a relatively unlimited quantity:

Sodium chlorid,	0.25
Novocain,	0.06
Water, q. s. ad.,	32.0
<b>Boil.</b>	

If any water is lost by boiling, it is made up by the addition of sterile water. To each 10 cubic centimeters of the anesthetizing solution, when cooled, is added .06 cubic centimeters of a 1:1000 solution of adrenalin chlorid. The latter salt will not stand boiling, and the solution spoils soon after it is added.

It is most important that the skin is perfectly anesthetized. Few of the subcutaneous tissues are sensitive to cutting, although they are sensitive to crushing, pulling, or tearing. It is practical, for instance, after anesthetizing the skin, to do such an extensive operation as removing a goitre with but little pain.

To anesthetize the skin, a fine needle is inserted obliquely into the substance of the skin, the injection being made with great pressure. The needle should not penetrate the skin, but the point should remain in its substance. When the injection is made, the skin turns white and rises up in an elevated circular papule, which has an uneven pitted surface. If the needle has completely penetrated the skin, the fluid is deposited beneath it, and its appearance remains unchanged. When the white papule is the size of a dime or a nickel, the needle is withdrawn and inserted in one edge of the papule, and the injection is repeated; or if the needle is of sufficient length, it is simply pushed in intracutaneously to a new area. This is known as Schleich's method. The mucous membrane can be anesthetized in the same way or by simply painting the surface with a 5 to 20 per cent cocain or novocain solution, depending upon the size of the area. The deeper tissues are infiltrated with a coarser needle that penetrates to various depths.

After injecting the line of the superficial incision, the tissues to be invaded should be entirely surrounded by the solution.

To open an abscess that is covered by a layer of non-infiltrated tissue, the latter is injected with the anesthetizing solution, but the injection should not be made into the abscess or indurated tissue. Besides being a source of danger, the injection is more painful than an

incision with a sharp knife. Spraying the surface with ethyl chlorid is here more satisfactory.

The most satisfactory application for perineurial injections is in operating on the body of the tongue, or on the body of the lower jaw. Theoretically one should be able to inject either the second or third division of the fifth nerve where they emerge from foramina of exit, and thus completely anesthetize the whole area of the face. We have not been able to do this with any certainty in practice. (For the technic of making perineurial injection in the face and mouth, see Injection of the Trunks and Branches of the Fifth Nerve, Chapter XLII.) Usually from 1 to 2 cubic centimeters of a 2 per cent novocain solution are used about the nerve, and when successful, 10 to 15 minutes elapse before the anesthesia appears over the area guarded by the nerve.

## CHAPTER XLIV.

### GENERAL ANESTHESIA.

BY DR. WILLIAM KRÄNNING.

The anesthetic agent and the method of administration should always be a matter of selection for the individual patient in hand. Nitrous oxid with oxygen presents the slightest element of danger; chloroform the greatest.

The anesthesia should be conducted by a trained anesthetist, and there is a distinct advantage in reciprocal confidence between anesthetist and operator. The preliminary and immediately subsequent care of the patient, so far as concerns the anesthesia, should be in the hands of the anesthetist.

Forty-five minutes before the induction of anesthesia, the patient should be given  $\frac{1}{4}$  grain of morphin sulphate with  $\frac{1}{150}$  grain of atropin sulphate, hypodermatically. In young children and infants this is omitted, and the dose is modified in elderly people. The induction should occur under every possible consideration of the mental attitude of the patient.

The careful selection of the anesthetic agent does not release the anesthetist from continued attention to that feature of his work. In occasional instances danger signals present themselves; and a correct interpretation makes it obligatory upon the anesthetist to change to the drug more closely adapted to that particular patient. It is an essential part of the anesthetist's duty to see that the patient is properly protected by clothing, that the position will not cause danger, and that the larynx is kept free from blood and mucus.

### CHLOROFORM.

The use of chloroform should probably be restricted to patients presenting pulmonary lesions that would be aggravated by ether. This drug should be given by the drop method with a widely open mask. The sudden deaths that occasionally occur under chloroform might in some cases have been avoided by starting the anesthetic more gradually. The parenchymatous degeneration that may follow chloroform anesthesia, especially in septic patients, can be prevented only by abstaining from its administration.

### ETHER.

Ether is ordinarily given by the drop method on the usual wire mask covered with eight or ten layers of gauze. The mask is surrounded with a wet towel.

The method of delivering vapor of ether is gaining favor. The usual apparatus required provides for setting the ether container in a vessel containing warm water, maintained at a temperature of 110° F. Air, driven by hand bulb or foot bellows through the container, either through the ether or above it, becomes charged with ether vapor, and is so delivered to the patient.

The administration of ether by the rectum also necessitates setting the container in a vessel of warm water—at 110° F. The rectal attachment, usually of glass tubing, has a limb joining the main tube at an acute angle an inch or two distal of the anal enlargement. This limb, with its rubber tubing, enables the anesthetist to empty the rectum of accumulated gases by turning a stop-cock. Anesthesia is induced in the usual manner by the mask method, the rectal attachment is then introduced, and the process is continued by delivering air through or over the ether in the container. The rectum should be emptied of accumulated gases by turning the stop-cock every three or four minutes.

Crile presented a method well adapted to operative attack upon the face. Ether is dropped upon gauze, secured over a glass funnel with a Y-tube with two rubber tubes of medium firmness about the size of a No. 18 catheter. One tube is introduced through each nostril down the pharynx to a point just above the larynx. Gauze is packed highly around the tubes in the nostrils and in the pharynx. Anesthesia is first induced in the customary manner.

The method of anesthesia by insufflation is finding wider application. Anesthesia is induced in the usual manner by mask. A rubber tube, smaller in caliber than the trachea, is then introduced through the larynx well into the trachea. The free end of the tube is connected with the insufflation apparatus, which contains a gauge for reading the pressure in millimeters of mercury. Air is driven by bellows over the ether in a container and finds ready exit by the side of the tracheal tube. As the air and ether pass out along the side of the tube, they drive the mucus and blood out of the larynx. The apparatus is so constructed that the proportion of ether in the air can be regulated.

### NITROUS OXID.


The administration of nitrous oxid with oxygen requires a special apparatus. A close-fitting mask is necessary. The details for holding

and mixing the gases and for adding ether or chloroform at will may vary and still permit successful work.

The induction of nitrous oxid anesthesia is preceded by the hypodermic administration of morphin and atropin. The proper use of rebreathing is of distinct advantage. Should the surgeon call for deeper anesthesia or greater relaxation, the requisite percentage of ether is added until sufficient relaxation is secured; then nitrous oxid-oxygen alone is resumed.

A detail requiring emphasis is the utmost gentleness of manipulation by the operator and his assistants.

Spinal analgesia should be limited in its application to work below the navel. The technic properly belongs to the surgeon.





## BIBLIOGRAPHY.

---

This does not pretend to be a full bibliography, but only comprises a few titles of the works used in the preparation of this volume. The best bibliography on this subject is to be found in Perthes, *D. Verletz. und Krankh. d. Kiefer*; while those in von Mikulicz, *Krankheiten des Mundes*, and Butlin, *Diseases of the Tongue*, are carefully selected, but less complete.

---

### CHAPTER I.

#### Examination.

GOULD, PIERCE, *Essentials of Surgical Diagnosis.*

#### Floor of the Mouth.

MOULLIN, *Treatise on Surgery.*

TREVES, *Surgical Applied Anatomy.*

PIERSOL, *Human Anatomy.*

#### Palate.

CUNNINGHAM, *Human Anatomy.*

KOCHER, *Operative Surgery.*

BLAND-SUTTON, in *Keen's System of Surgery.*

#### Teeth.

PRINZ, *Dental Materia Medica.*

#### Checks.

BLAND-SUTTON, in *Piersol's Human Anatomy.*

#### Salivary Glands.

GRAY, *Anatomy*, p. 782.

### CHAPTER II.

#### Infections.

EMERY, *Immunity and Specific Therapy.*

RICKEYS, *Infection, Immunity, and Serum Therapy.*

MUIR AND RITCHIE, *Manual of Bacteriology.*

PFEIFFER AND MARX, *Deutsche medizinische Wochenschrift*, 1898.  
*Centralblatt für Bakteriologie.*

## CHAPTER IV.

## Hemorrhage.

- DAWBARN, *Journal A. M. A.*, vol. xxxvi, p. 357; *Annals of Surgery*, Feb., 1907.
- WIRTH, *Centralblatt für die Grenzgebiete der Medizin und Chirurgie*, 1909, xii, No. 7, pp. 241-288.
- LEARY, *Boston Medical and Surgical Journal*, 1908, vol. clix, p. 73.
- BAUM, *Mitteilungen aus den Grenzgebieten der Medizin und Chirurgie*, 1909, vol. xx, No. 1, pp. 1-194.
- MORAWITZ, *Müchener medizinische Wochenschrift*, 1907.
- HOLT, *Diseases of Infancy and Childhood*.

## Blood Transfusion.

- CRILE, *Journal A. M. A.*, 1906, vol. xlvii; *Annals of Surgery*, 1907, p. 329; *Journal A. M. A.*, 1909, p. 320.
- DORRANCE AND GINSBURG, *International Clinics*, vol. iv, 20th series.
- HARTWELL, *Journal A. M. A.*, 1909, p. 297.
- PEPPER, *Journal A. M. A.*, 1907, p. 382.
- REHLING AND WEIL, *American Journal of Surgery*, March, 1909.

## Shock.

- MOULLIN, *Treatise on Surgery*, Hamilton, 1893, p. 150.

## Air Embolism.

- SENN, Reports of Laboratory Experiments, *Transactions of the American Surgical Association*, vol. fii, p. 197.
- HARE, *Therapeutic Gazette*, 1889, vol. v, p. 606.
- BLAIR AND MCGUIGAN, A Suggestion for the Treatment of Air Embolism, *Annals of Surgery*, Oct., 1910.

## CHAPTER V.

## Wounds.

- KOCHER, *Operative Surgery*.

## Burns.

- WOOD, F. C., *Keen's Surgery*, vol. i, p. 379.

## CHAPTER VI.

## Fracture of the Teeth.

- WUNSCHHEIM, Frakturen, Infraktionen, und Knickungen in Zähnen, *Österreich-ungarische Vierteljahrsschrift für Zahnheilkunde*, 1904, p. 45.
- OWEN, *Odontography*, 1840-45, p. 569.

WEDL, *Atlas zur Pathologie der Zähne*, 1893.

TOMES, J. A., *System of Dental Surgery*, 1887, p. 431.

WILLIAMSON, An Interesting Case of Fracture, *Journal British Dental Association*, 1888, p. 123.

## CHAPTER VII.

### Fractures of the Upper Jaw.

CRYER, *Internal Anatomy of the Face*.

#### Treatment.

LEDENTU, A., ET DELBET, P., *Nouveau Traite de Chirurgie*.

OMBREDANNE, LOUIS, *Maladies des Machoires*.

MARSHALL, *Injuries and Surgical Diseases of the Face, Mouth, and Jaws*.

## CHAPTER VIII.

### Treatment of Fractures of the Lower Jaw.

GILMER, *Archives of Dentistry*, Sept., 1887; *Oral Surgery*, 1907, p. 105, p. 109.

BOND, THOS. E., *A Practical Treatise on Dental Medicine*, 1852.

## CHAPTER IX.

### Kinds of Dislocation of the Lower Jaw.

LEFÈVRE, *Journal Hebdomadaire*, 1834, vol. iii, p. 333.

ROBERT, *Archives Générales de Médecine*, 1845, vol. vii, p. 44.

NEIS, *Luxation du Maxillaire inf. en haut on dans la fosse Temporale*, *Thèse de Paris*, 1879, No. 252.

STIMSON, *Fractures and Dislocations*.

MALGAIGNE, *Atlas*, plate xvii, Fig. 1.

#### Treatment.

GILMER, *Oral Surgery*.

### Chronic Dislocation.

ANNANDALE, *Lancet*, 1887, vol. i, p. 6411.

## CHAPTER X.

### Morphology of Congenital Facial Clefts.

LEXER, in von Bergmann's *System of Practical Surgery*, vol. i.

OWEN, *Harelip and Cleft Palate*.

### Relation of the Alveolar Cleft to the Teeth.

- Untersuchen über des Zwischenkiefer in den Menschen in seiner Normalen und Abnormalen Metamorphose, Stuttgart, 1840.
- WARZYNSKI, Contribution a L'etude du bec de lievre, simple et complex, *Virchow's Archiv*, 1888.
- TURNER, SIR WILLIAM, *Journal of Anatomy and Physiology*, vol. xix.
- KÖLLIKER, Zur Odontologie der Gaumen-spalte, *Centralblatt für Chirurgie*, 1890, vol. xv.

### Theories of Failure of Cleft Closure.

- FEIN, Über die Ursachen des Wolfsrachen, *Wiener klinische Wochenschrift*, 1899, vol. x.
- TANDLER, Zur Entwicklungs Geschichte, *Wiener klinische Wochenschrift*, 1899, vol. x.
- FRIEDRICH, *Archiv für klinische Chirurgie*, Bd. 68, heft 2, p. 199.
- FRONHÖFER, H., Die Entstehung der Lippen-kiefer und Gaumen-spalten in folge Amniotischen Adhesionen.
- ZIEGLER, Allgemeine Pathologie, 1895.
- DRUITT, *Modern Surgery*.
- VANDER, A., *Rebman's Handbook of Medical Sciences*, p. 179.
- CZAPSKI, Binokulares Korneal Mikroskop, *Archiv für Ophthalmologie*, vol. xlv, pp. 222-235.
- LUEDE, Improved Illumination for the Ziess Binocular Corneal Microscope—Used in the Study of the Episcleral Vessels and their Circulation, *Archives of Ophthalmology*, vol. xl, No. 4, p. 19.
- GRAVES, The Scaphoid Scapula, *Medical Record*, May, 1910; The Clinical Recognition of the Scaphoid Type of Scapula and Some of Its Correlations, *Journal A. M. A.*, July 2, 1910.

## CHAPTER XI.

### Anatomical Considerations of Congenital Palate Clefts.

- SALTEHOLZ, *Hand Atlas of Anatomy*.
- MERKEL, *Handbuch der Topographischen Anatomie*, vol. i, p. 401.

### Flaps made from other than Palate Tissues.

- MARSHALL, *Injuries and Surgical Diseases of the Face, Mouth, and Jaws*.

## CHAPTER XIII.

### CONGENITAL PALATE AND LIP CLEFTS.

#### Brophy Operation.

- HEITMULLER, *Correspondenzblatt für Zahnartze*, vol. xxxiii, No. 1.
- OWEN, EDMUND, *Burghard's Operative Surgery*, vol. ii.

## Lane Operation.

LANE, Cleft Palate and Harelip.

## Mortality.

ROBERTS, Surgery of Deformities of the Face.

## CHAPTER XIV.

## CONGENITAL PALATE CLEFTS.

## Flap Sliding Operation.

OWEN, Keen's Surgery, vol. iii, p. 627.

## CHAPTER XVII.

## OBTURATORS AND SPEECH TRAINING.

## Physiological Action of the Muscle Concerned.

KINGSLEY, Oral Deformities.

WARNIKROS, *Ashe's Quarterly*, April, 1909.

## Obturators and Artificial Vela.

WARNIKROS, Verhandlungen der Deutschen Odontologeschen Gesellschaft, vol. vii, Schaff's Handbuch.

## Speech Training.

BIGELOW, Voice Training after Operation for Cleft Palate.

## CHAPTER XVIII.

## Restoration of the Lower Lip.

STEWART, CLARK, The Radical Treatment of Epithelioma of the Lip, *Journal A. M. A.*, vol. liv, No. 3.

ESMARCH AND KOWALZIG, Surgical Technic.

## CHAPTER XIX.

## Occlusion and Malocclusion.

LISCHEE, Orthodontics.

## CHAPTER XX.

## Protrusion of the Lower Jaw.

BABCOCK, W. WAYNE, *Items of Interest*, June, 1910.

## CHAPTER XXIII.

## Infections and Inflammations of the Mouth.

BUTLIN, Diseases of the Tongue.

BRUCK, Diseases of the Nose, Mouth, Throat, and Larynx.

PFAUNDLER AND SCHLOSSMANN, Diseases of Children.

## Specific Infections.

CARR, Practice of Medicine, p. 762.

BRISTOW, A. T., *Annals of Surgery*, Oct., 1911.

SIEGEL, *Deutsche medizinische Wochenschrift*, 1891, vol. xvii, p. 1328; 1894, vol. xx, pp. 420-426.

EICHMEYER, W., *Ergebnisse der Allgemeinen Pathologie Lehrbuch*.

## CHAPTER XXIV.

## Necrosis.

DETURK, *Archives Générales de Chirurgie*, Nov., 1908.

## CHAPTER XXV.

## Treatment of Necrosis.

CUSHNEY, *Pharmacology and Therapeutics (potassium iodid)*.

## Chronic Bone Abscess.

MOSETIG-MOORHOF, *Wiener klinische Wochenschrift*, 1906, No. 44.

BECK, Bismuth Paste in Chronic Suppuration.

DAVID AND KAUFMANN, *Journal A. M. A.*, 1909, vol. lii, p. 1055.

MAYOHOFER, *Österreich-ungarische Vierteljahrsschrift für Zahnheilkunde*, 1905, No. 2; 1906, No. 3; 1907, No. 1.

## CHAPTER XXVI.

## Chronic Cellulitis.

FICHTER, *Münchener medizinische Wochenschrift*, 1904, p. 35.

## CHAPTER XXVII.

## Antral Infection.

BALLENGER, Ear, Nose, and Throat.

MIKULICZ, *Langenbeck's Archiv für klinische Chirurgie*, vol. xxxiv.

SLUDER, *Laryngoscope*, December, 1909.

## CHAPTER XXVIII.

## Hypertrophy of the Gums.

CRYER, Internal Anatomy of the Face.

## Odontoma.

GILMER, Oral Surgery.

## Sarcoma of the Jaws.

SCUDDER, Tumors of the Jaws.

COLEY, Injury as a Causative Factor in Carcinoma.

## Multilocular Cystic Tumors of the Jaws.

BLAND-SUTTON, Keen's Surgery, vol. i, p. 784.

## Carcinoma of the Jaws.

SCHLATTER, Von Bergmann's System of Practical Surgery, vol. i, p. 708.

## CHAPTER XXIX.

## Mortality of Total Resection of the Maxilla.

SCHLATTER, Von Bergmann's System of Practical Surgery, vol. i, p. 726.

## Prevention of Deformity.

GILMER, Conservative Surgery for the Treatment of Diseases of the Mandible,  
*Journal A. M. A.*, Aug. 7, 1909.

MAGNUSON, *University of Pennsylvania Medical Bulletin*, 1908, vol. xxi, p. 103.

## CHAPTER XXXI.

## Cancer of the Lip.

LEXER, Von Bergmann's System of Practical Surgery, vol. i.

## CHAPTER XXXII.

## Ranula.

BAKER, *St. Bartholomew's Hospital Report*, 1871, vol. vii, p. 134.

MORESTIN, *Gazette d'Hôpitaux*, 1897, vol. lxx, p. 529.

MONOD, *Bulletins et mémoires de la Société de Chirurgie de Paris*, 1881, vol. vii, p. 365.

## CHAPTER XXXIII.

## Secondary Affections of the Salivary Glands.

KÜTTNER, Von Bergmann's System of Practical Surgery, vol. i.

## Foreign Bodies in the Ducts and Glands.

PUZEY, *Lancet*, 1884, vol. i, p. 424.

## Benign Tumors.

BLAND-SUTTON, Keen's Surgery, vol. i, p. 752.

HAYES, *Medical News*, Philadelphia, 1893, vol. lxii, p. 60.

BUTLIN, Diseases of the Tongue.

## CHAPTER XXXIV.

## Congenital Deformities of the Tongue.

MAKUEN, *International Clinics*, 1897, 7th series, vol. i, p. 319.

DUPLONG, *Bulletins et mémoires de la Sociéte de Chirurgie de Paris*, 1883, n. s., T. ix, p. 457.

PETIT, *Mémoires Acad. Roy. des Sciences*, 1742, p. 247.

JUSSIEU, *Hist. de L'Acad. des Sciences*, 1718.

## Dyspeptic Tongue.

BUTLIN, Diseases of the Tongue.

## Chronic Superficial Glossitis.

BUTLIN, *Trans. Path. Med. Chir. Soc.*, 1878, vol. lxi, p. 51.

SANGSTER, *Trans. Path. Soc.*, 1882, vol. xxxlii, p. 103.

LISSAUER, *Deutsche medizinische Wochenschrift*, 1899, vol. xxv, p. 12.

HULKE, *Transactions Clinical Society*, London, 1869, vol. ii, p. 1.

CIAGLINSKI AND HEWELKE, *Zeitschrift für klinische Medizin*, 1893, vol. xxii, p. 626.

LEDIARD, *Transactions Pathological Society*, 1886, vol. xxxvii, p. 222.

## Syphilis of the Tongue.

FOURNIER, *Des Glossites Tertiares*, Paris, 1877.

MORRIS, SIR MALCOLM, *British Medical Journal*, March 30, 1912, p. 712.

## CHAPTER XXXV.

## Lymphangiomatous Macroglossia.

BUTLIN, Diseases of the Tongue.

## Simple Muscular Macroglossia.

ZEISLER, *New York Medical Record*, 1885, vol. xli, p. 253.



## Keloid.

SEDGWICK, *Transactions Pathological Society*, 1861, vol. xii, p. 234.

## Thyroglossal Cysts and Tumors.

BERNAYS, *St. Louis Medical and Surgical Journal*, 1888, vol. iv, p. 201.

VON CHAMISSO DE BONCOURT, *Beitrage zur klinischen Chirurgie*, 1897, vol. xix, p. 281.

SELDOWITSCH, *New York Medical Journal*, 1897, vol. lxxv, p. 281.

REINTJES, *Internationales Centralblatt für Laryngologie*, 1899, xv, 174.

STRECKHEISEN, *Archiv für pathologische Anatomie*, 1886, ciii, 131-215.

## CHAPTER XXXVI.

## CANCER OF THE TONGUE.

## Etiology and Predisposition.

CHEATLE, *British Medical Journal*, Feb. 22, 1908.

## Early Types of Cancer.

BUTLIN, *British Medical Journal*, 1909, p. 462; Jan. 2, 1909; Feb. 14, 1903; May 26, 1906.

## Mid-Period of Cancer of the Tongue.

BUTLIN, *British Medical Journal*, Feb. 11, 1905; May 26, 1906.

MIKULICZ UND KÜMMEL, *Krankheiten des Mundes*.

## Diagnosis.

HEAD, *Eye, Ear, Nose, and Throat, Practical Medicine Series of Year Books*, 1903.

BURT, H., *Journal of Laryngology, Rhinology and Otology*, Jan., 1903.

## Prognosis.

BUTLIN, *British Medical Journal*, Jan. 2, 1909; Feb. 20, 1909.

DOLLINGER, *British Medical Journal*, May 30, 1903.

## Treatment.

LOISON, *Von Bergmann's System of Practical Surgery*, vol. 1, p. 874.

BUTLIN, *British Medical Journal*, Jan. 2, 1909.

KOCHER, *Operative Surgery*.

MAITLAND, *Australian Medical Gazette*, Oct. 20, 1906.

ANDREWS, *Keen's Surgery*, vol. iii, p. 332.

## CHAPTER XXXVII.

## Secondary Carcinoma of the Cervical Lymphatics.

MAITLAND, *Australian Medical Gazette*, Oct. 20, 1906.

## Injuries of the Oral Pharynx.

JACOBSON, *Operation of Surgery*.

## Acute Infections of the Pharynx.

PITT, *St. Thomas Hospital Reports*, vol. xii, p. 131.

## Adhesions of the Velum.

ROE, JOHN A., *Journal A. M. A.*, vol. liv, No. 3, p. 185.

KÜMMEL, *Von Bergmann's System of Practical Surgery*, vol. i.

NICHOLS, A., *Method of Correcting Adhesions Between the Soft Palate and the Pharyngeal Wall*, *New York Medical Journal*, 1890, vol. xi, p. 219.

## CHAPTER XXXIX.

## Palate Adenoma.

KÜMMEL, *Von Bergmann's System of Practical Surgery*, vol. i.

## Pharyngotomy.

JACOBSON, *Operations of Surgery*, p. 378.

## CHAPTER XL.

## Ligation and Temporary Construction of the Arteries.

KOCHER, *Operative Surgery*.

## External Carotid Artery.

CUNNINGHAM, *Textbook of Anatomy*.

## CHAPTER XLII.

## Fifth Cranial Nerve.

PIERSOL, *Human Anatomy*.

## Sphenopalatine Neuralgia.


SLUDER, *The Rôle of the Sphenopalatine or Meckel's Ganglion in Nasal Headaches*, *New York Medical Journal*, May 23, 1908; *The Anatomical and Clinical Relations of the Sphenopalatine or Meckel's Ganglion to the Nose*

- and Its Accessory Sinuses, *New York Medical Journal*, Aug. 14, 1909; Further Clinical Observations on the Sphenopalatine Ganglion-Motor, Sensory, and Gustatory, *New York Medical Journal*, April 23, 1910; A Phenol (Carbolic Acid) Injection Treatment for Sphenopalatine Ganglion Neuralgia, *Journal A. M. A.*, Dec. 30, 1911, p. 2137.
- WEINER, OTTO, *Berliner klinische Wochenschrift*, vol. xlv, No. 10, p. 429, March 7, 1910.
- PATRICK, *Journal A. M. A.*, vol. xlix, pp. 1567, 1987.
- KEEN, *Surgery*, vol. v.
- CROW AND CUSHING, *Johns Hopkins Bulletins*, 1909, p. 102.

## CHAPTER XLIII.

## Local Anesthesia.

- PRINZ, Modern Methods of Producing Local Anesthesia, *Dental Summary*, 1912, Feb., March, and April.



## INDEX.

### A

- Abrasion of the teeth, mechanical, 80  
 symptoms of, 80  
 treatment of, 80
- Abscess, absorption, 313  
 alveolar, 308  
 treatment of, 319  
 chronic bone, treatment of, 326  
 by obliteration of cavity with  
 bone plombe, 328  
 by obliteration of cavity with  
 living tissue, 330  
 with Beck's bismuth paste, 328  
 definition of, 34  
 of gums, 18  
 of tongue, 341  
 peritonsillar, 524  
 treatment of, 525  
 retropharyngeal, 526  
 treatment of, 527  
 tonsillar, 524  
 treatment of, 525
- Absorption abscess, 313
- Acetone, Legal's test for, 66
- Acetonuria, 66
- Actinomycosis of bone, 316  
 of the mouth, 304  
 of the salivary glands, 413
- Acute adenitis, 333  
 treatment of, 335  
 cellulitis, 333  
 treatment of, 335  
 infections of the pharynx, 524  
 pharyngitis, 524  
 tonsillitis, 524
- Adenoma of the salivary glands, 429  
 palate, 534  
 treatment of, 534
- Adenitis, acute, 333  
 treatment of, 335  
 chronic, 335  
 treatment of, 339  
 tubercular, 506  
 diagnosis of, 507  
 radical operation for, 510  
 results of, 515  
 symptoms and course of, 506  
 treatment of, 507
- Adhesions of the velum, fauces, and  
 pharyngeal wall, 528  
 prognosis of, 530  
 treatment of, 529
- Adrenalin in local anesthesia, 589
- After-treatment of clefts of lips and  
 alveolar process, 209  
 of congenital palate clefts, 164, 184  
 of operations on deformities of the  
 jaws, 262  
 of operations on impacted teeth,  
 283  
 of operations on the tongue, 503  
 of resections of the maxilla, 375  
 of transplantation of skin- or mu-  
 cus-covered flaps, 222
- Air embolism, 61  
 experiments in, 62-64
- Albrecht, theory of relation of alveo-  
 lar cleft to the teeth, 131
- Alveolar abscess, 308  
 treatment of, 319  
 cleft, relation to the teeth, 129  
 Albrecht's theory, 131  
 Ferguson's theory, 130  
 Kölliker's theory, 131  
 Warnikros' theory, 130
- clefts, correction of, in infants, 197  
 double, corrections of at later pe-  
 riods, 198  
 single, corrections of at later pe-  
 riods, 198
- fistula, 309  
 treatment of, 323
- process and lip, congenital clefts  
 of, after-treatment of, 207  
 operative correction for, 196-  
 210  
 results of, 210  
 fracture of the, 82  
 treatment of, 82  
 resection of the inferior, 377  
 of the palate and, 371  
 of the superior, 377
- Analgesia, spinal, 603
- Anastomosis, facial-accessory nerve,  
 552  
 facial-hypoglossal nerve, 552
- Anaphylaxis, 72
- Anatomical considerations of con-  
 genital palate clefts, 139
- Anatomy, 2-27  
 of Bochdalek's glands, 6  
 of fauces, 14  
 of floor of the mouth, 4  
 of glands of Nuhn and Blandin, 5  
 of gums, 17  
 of incisive glands, 5  
 of jaws, 22

- Anatomy—*cont'd*  
of lips, 20  
of lymph nodes, 26  
of maxillary antrum, 23, 342  
of mouth cavity, 2  
of muscles of mastication, 24  
of palate, 12  
of parotid gland, 24  
of pharynx, 14, 519  
of salivary glands, 24  
of sublingual glands, 24  
of submaxillary glands, 25  
of teeth, 15  
of temporomandibular joint, 21  
of tongue, 12  
of vestibule of mouth, 19  
Anemia, means of producing, 588  
Anesthesia in operation for removal  
of the tongue, 49  
general, 601-603  
by insufflation, 602  
chloroform in, 601  
ether in, 602  
nitrous oxid in, 602  
local, 588-600  
absorption of poisonous drugs in,  
590  
adrenalin in, 589  
anesthetization of the pulp in, 597  
cocain in, 590  
ethyl chlorid in, 589  
for anesthetizing the skin, 599  
for operations about the mouth,  
598  
hypodermic armamentarium in,  
592  
intraosseous injection in, 595  
means of producing, 588  
novocain in, 590, 592  
peridental injection in, 595  
perineurial injection in, 596  
preparation of solution in, 591  
subperiosteal injection in, 594  
technic of injection in, 593  
Aneurysm of the tongue, 452  
Angina, Ludwig's, 334  
of Plaut, 297  
Vincent's, 297  
Angioma of the lips, 387  
of the tongue, cavernous, 453  
diagnosis of, 454  
treatment of, 454  
Angle fracture bands, 96  
splint, 105  
Brown's modification of, 258  
Ankyloglossia, 437  
Ankylosis, limitation of jaws due to  
scar bands or, 265  
of the jaw, operations for, 270  
Anthrax, 294  
Antitoxin, 37  
tetanus, 72  
Antral infection, 342  
objective symptoms of, 344  
Antral infection—*cont'd*  
subjective symptoms of, 343  
treatment of acute, 345  
treatment of chronic, 346  
Canfield-Ballenger operation  
in, 349  
Cauldwell-Luc operation in, 347  
Denker operation in, 347  
Küster operation in, 347  
x-ray in, 344  
Antrum, cysts of the, 349  
treatment of, 350  
maxillary, anatomy of, 23, 342  
tumors of the, 350  
treatment of, 350  
Aphthæ, 288  
Bednar's, 289  
Aphthous stomatitis, 288  
Approximation of the maxillæ in con-  
genital palate clefts, 190  
Arsenic poisoning, 315  
Arterial bleeding, 48  
Horsley's formula for, 48  
Arteries, constriction of the, 542  
common carotid, 546  
coronary, 543  
external carotid, 544  
facial, 543  
lingual, 543  
temporal, 543  
ligation of the, 52, 542  
common carotid, 546  
coronary, 543  
external carotid, 544  
facial, 543  
lingual, 543  
temporal, 543  
Atresia of the posterior nares, 520  
Atrophy of bone, 318  
Atropin, use of, after proctoclysis, 54  
Atypical deformities of the jaws, 261  
Autogenous vaccines, method of pre-  
paring and administering, 37  
Avulsion of the frontal nerve, 579  
of the nasal nerve, 579  
of the teeth, 81  
treatment of, 81
- B
- Babcock, operation for protrusion of  
the lower jaw, 259  
Baby's mouth, method of washing,  
285  
Bacillus fusiformis, 291, 297, 298  
Klebs-Löffler, 294.  
lepræ, 295  
mallei, 294  
of Frisch, 296  
of Siegel, 295  
Bacteria, cultures of, 38  
dead, method of using, 38  
reaction from injection of, 39

- Bacteria—cont'd**  
of suppuration, 33  
Wright's method of determining number of, 38
- Bartlett elevator**, 172
- Beck's bismuth paste in chronic bone abscess**, 328
- Bednar's aphthæ**, 289
- Bell's palsy**, 549
- Benign tumors**, 40  
of the pharynx, 533
- Bier's hyperemia for inflammations**, 36
- Bigelow, speech training**, 215
- Bismuth paste, Beck's, in chronic bone abscess**, 328  
poisoning, 315
- Bite, open**, 236  
correction by traction of, 260  
by surgical operation, 260  
operation for, 260  
fixation in, 260
- Black tongue**, 445
- Bleeding, arterial**, 48  
Horsley's formula for, 48  
in extraction of teeth, control of, 50  
veins, 49
- Blood pressure, lowering of**, 51  
sequestration of, for prevention of hemorrhage, 46  
transfusion, 55  
for prevention of hemorrhage, 48
- Bochdalek's glands, anatomy of**, 6
- Bone abscess, chronic treatment of**, 326  
by obliteration of cavity with bone plombe, 328  
by obliteration of cavity with living tissue, 330  
with Beck's bismuth paste, 328
- actinomycosis of**, 316  
atrophy of, 318  
fistula, 309  
hypertrophy of, 318  
inflammation of the, 311  
or cartilage, transplantation of, for obliquity of the chin, 248  
plombe in chronic bone abscess, 328  
specific infections of, 315  
treatment of, 331  
syphilis of, 315  
treatment of, 332  
tuberculosis of, 316  
treatment of, 331
- Branchial fistula**, 521  
diagnosis of, 522  
treatment of, 522
- Brophy elevator**, 172  
operation for cleft palate, 153  
oral speculum, 170
- Brown's modification of Hammond splint**, 258
- Burns**, 75  
from chemical caustics, 76
- Burns—cont'd**  
shock in, 76  
treatment of, 76  
x-ray, 76
- Burow-Stewart operation for restoring the lower lip**, 226
- Butlin, ointment for herpes**, 287
- C**
- Calcium lactate for prevention of hemorrhage**, 47
- Calculi in glands of Nuhn and Blandin**, 415  
salivary, 415  
treatment of, 417
- Cancer of the lip**, 390-399  
of the tongue, 464-505
- Cancerum oris**, 291  
treatment of, 292
- Canfield-Ballenger operation for chronic antral infection**, 349
- Cannula, Sweet's**, 56
- Capillary nevi of the tongue**, 452
- Carbuncle of the lips**, 386
- Carcinoma**, 41, 364  
classification of, 41  
of the cervical lymphatics, 516  
results of operation on, 518  
treatment of, 516  
of the floor of the mouth, 407  
of the jaws, medullary, 365  
prognosis of, 366  
treatment of, 366  
of the lip, 380-399  
diagnosis of, 390  
excision of growths and ulcers of doubtful character for, 393  
of indolent, 394  
of indurating, 394  
operation for early indurated, 394  
where repair is to be made with flaps from the neck, 398  
prognosis of, 399  
treatment of, 391  
of the lower jaw, 364, 365  
of the pharynx, 537  
of the salivary glands, 429  
of the tongue, 464-505  
age in, 465  
chronicity of, 468  
continuous growth of, 469  
death from, 476  
diagnosis of, 477  
differential, 478  
microscopical, 480  
differentiation between operable and inoperable, 481  
early clinical characteristics of, 468  
early diagnosis of, 466  
early types of, 467  
etiology of, 464

- Carcinoma of the tongue—*cont'd*  
 final stage of, 476  
 induration of, 469  
 microscopical appearance of, 470  
 mid-period of, 471  
   clinical types of, 475  
   general symptoms of, 476  
   growth of, 471  
   hemorrhage of, 472  
   lymphatic infection in, 472  
   pain of, 471  
   salivation in, 472  
   ulceration of, 471  
 operation on, 484  
   character of, 485  
   extent of, 484  
   excision of tongue or laryngotomy first in, 492  
   questions concerning, 484  
   removal of lymphatics in, 487  
   removal of lymph nodes in, 487  
   time of, 484  
   pain of, 469  
   position of, 464  
   predisposition to, 464  
   prognosis of, 482  
   results of operation on, 482  
   treatment of, 483  
   ulceration in, 469  
   of the upper jaw, 364, 365  
 Caries, dental, 307  
   of teeth, 17, 307  
 Carotid artery, common, constriction of, 547  
   ligation of, 546  
   external, constriction of, 544  
   ligation of, 544  
 Cartilaginous tumors of the tongue, 456  
 Cauldwell-Luc operation for chronic antral infection, 347  
 Caustics, chemical, burns from, 76  
 Cavernous angioma of the tongue, 453  
   diagnosis of, 454  
   treatment of, 454  
 Cellulitis, 30  
   acute, 333  
   treatment of, 336  
   chronic, 335  
   treatment of, 340  
 Cementoma, 356  
 Cervical lymphatics, malignant diseases of the, 506  
   radical operation for tubercular infection of the, 510  
   results of, 515  
   secondary carcinoma of the, 516  
   results of operation, 518  
   treatment of, 516  
   tuberculosis of the, 506  
 Chancre of the mouth, 302  
   of the tongue, 447  
 Cheek and the mouth, closure of defects at the angle of the, 222  
 Cheeks, lips and palate, repair of acquired defects in, 217-229  
 Chicken-pox, 293  
 Children, examination of, 1  
 Chin, obliquity of the, 246  
   paraffin injection for, 247  
   transplantation of bone or tissue for, 248  
 Chloroform in general anesthesia, 601  
 Chondroma, 354  
 Chronic adenitis, 335  
   treatment of, 339  
   bone abscess, treatment of, 326  
   by obliteration of cavity with bone plombe, 328  
   by obliteration of cavity with living tissue, 330  
   with Beck's bismuth paste, 328  
 cellulitis, 335  
   treatment of, 340  
 inflammation of the salivary glands, 411  
 stomatitis, 286  
 superficial glossitis, 441  
 ulcerative stomatitis, 296  
 Cleft closure, theories of failure of, 133  
   heredity, 133  
   infection, 137  
   injury, 137  
   malnutrition, 136  
   maternal impressions, 136  
   mechanical cause, 134  
   supernumerary teeth, 135  
   tumors, 135  
   palate speech, 214  
 Clefts, alveolar, correction of, in infants, 197  
 congenital facial, 122-138  
   clinical types of, 124  
   Merkel's plan of, 123  
   morphology of, 122  
   theories of, 133  
   types of, 124  
   lip and alveolar process, after-treatment of, 209  
   correction of, 196-210  
   results of, 210  
 palate, 139-195  
   advantages of very early operation for, 149  
   after-treatment of, 164, 184  
   anatomical considerations of, 139  
   approximation of the maxillæ in, 190  
   Brophy operation for, 153  
   choice of operation for, 164  
   consideration of various ages for operation for, 148  
   Davies-Colley operation for, 162  
   double, 141  
   flap sliding operation for, 174  
   instruments and materials for, 169



Clefts, congenital palate—*cont'd*

- Küster operation for, 186
- Lane operation for, 161
- Langenbeck operation for, 176
- mortality in, 185
- mortality in operations for, 166
- non-union in, 184
- operations in early infancy for, 151-166
- operation for extraordinary cases of, 186-195
- plastic operations in ordinary cases after early infancy, 167-185
- position and light in operation on, 168
- postoperative hemorrhage in, 184
- preferable age at which to operate, 148-150
- preparation for operation, 151, 168
- principles of repair by plastic flaps, 139-147
- reoperation in, 185
- repair by flaps from other than palate tissues, 145, 192
- repair by flaps from palate tissues, 142
- results in, 185
- retention devices for, 182
- single, 141
- two-step operation for, 186
- double alveolar, correction of, 198
- single alveolar, correction of, 198
- Closure of the jaws, hysterical, 264
- Clotting, delayed, treatment of, 50
- Cold, application of, for hemorrhage, 50
- Coley's fluid for retromaxillary fibroma, 368
- for sarcoma, 362
- Composite odontoma, 357
- Compound follicular odontoma, 356
- Congenital clefts of the lip and alveolar process, 196-210
  - after-treatment of, 209
  - results of, 210
- deformities of the tongue, 437
- facial clefts, 122-138
  - clinical types of, 132
  - Merkel's plan of, 123
  - morphology of, 122
  - theories of, 133
  - types of, 124
- lip pits, 138
- malformations of the pharynx, 520
- palate clefts, 139-195
  - advantages of very early operation for, 149
  - after-treatment of, 164-184
  - anatomical considerations of, 139

Congenital palate clefts—*cont'd*

- approximation of the maxillæ in, 190
- Brophy operation for, 153
- choice of operation for, 164
- consideration of various ages for operation for, 148
- Davies-Colley operation for, 162
- double, 141
- flap-sliding operation for, 174
- instruments and materials for, 169
- Küster operation for, 186
- Lane operation for, 161
- Langenbeck operation for, 176
- mortality in, 185
- mortality in operation for, 166
- non-union in, 184
- operations in early infancy for, 151-166
- operations for extraordinary cases of, 186-195
- plastic operations in ordinary cases after early infancy, 167-185
- position and light in operation on, 168
- postoperative hemorrhage in, 184
- preferable age at which to operate, 148-150
- preparation for operation, 151, 168
- principles of repair by plastic flaps, 139-147
- reoperations in, 185
- repair by flaps from other than palate tissues, 145, 192
- repair by flaps from palate tissues, 142
- results in, 185
- retention devices for, 182
- single, 141
- two-step operation for, 186
- Constriction of the arteries, 542
  - common carotid, 546
  - coronary, 543
  - external carotid, 544
  - facial, 543
  - lingual, 543
  - temporal, 543
- Contused wounds, 67
- Coronary artery, constriction of, 543
- Correction of alveolar clefts in infants, 197
  - of deformity of the nose, 205
  - of double alveolar clefts, 198
  - of harelip, 200
  - of open bite by surgical operation, 260
  - by traction, 260
  - of protrusion of the lower jaw by surgical operation, 251

Correction—*cont'd*  
 of retraction of the lower jaw by surgical operation, 239  
 by traction, 239  
 of single alveolar clefts, 198  
 Cracking of the jaw, 263  
 Cysts, 40  
 dental, 359  
 dermoid, 403  
 of the antrum, 349  
 treatment of, 350  
 of the floor of the mouth, 400  
 of the gums, 352  
 of the lips, 387  
 of the thyroglossal tract, 457  
 near the foramen cecum, 457  
 perihyoid, 458  
 treatment of, 459  
 of Wharton's duct, 402

D

Dawbarn, plan of sequestration of blood, 46  
 Defects at the angle of the mouth and of the cheek, 222  
 in the lips, cheeks, and palate, repair of acquired, 217-229  
 Deformities of the jaws, after-treatment of operation on, 262  
 atypical, 261  
 preoperative considerations of, 261  
 of the maxillæ, 238  
 of the nose, correction of, 205  
 of the tongue, congenital, 437  
 Deformity, prevention of, in excisions of the jaw-bones, 379  
 Denker operation for chronic antral infection, 347  
 Dental arches and the jaws, malrelation of, 232  
 caries, 307  
 cysts, 359  
 splints, 102  
 Derangement, motor, 547-556  
 Dermoid cysts, 403  
 treatment of sinuses leading to suppurating, 406  
 Desquamation, 298  
 Diacetic acid, von Jaksch's test for, 66  
 Diagnosis of branchial fistula, 522  
 of carcinoma of the lip, 390  
 of the tongue, 477  
 differential, 478  
 early, 466  
 microscopical, 480  
 of cavernous angioma of the tongue, 454  
 of condition of pulp, as developed by Prinz, 17  
 of condition of teeth, 16

Diagnosis—*cont'd*  
 of fractures of the lower jaw, 94  
 x-ray in, 94  
 of the upper jaw, 84  
 of obstruction of the ducts of the salivary gland, 414  
 of ranula, 402  
 of salivary fistula, 419  
 of shock, 60  
 of tic douloureux, 562  
 of tubercular adenitis, 506  
 Diphtheria, 294  
 Dislocation of lower jaw, 115-121  
 backward, 115  
 chronic, 121  
 forward, 116  
 kinds of, 115  
 outward, 116  
 reduction by manipulation, 120  
 by traction, 119  
 retention of, 120  
 Stimson on, 118  
 subluxation of, 121  
 symptoms of anterior, 119  
 treatment of, 119  
 unreduced, 121  
 upward, 115  
 Displacement in fractures of the lower jaw, 89  
 of the upper jaw, 83  
 Dorrance and Ginsburg, vein-to-vein transfusion, 55  
 Dowd, operation for carcinoma of lower lip, 398  
 Drainage of wounds, 71  
 rubber dam, for alveolar abscess, 320  
 Dressings, 78  
 sterilization of, 44  
 Dyspeptic tongue, 440

E

Edema of the lungs, 63  
 Electrical tests for paralytic affections, 547  
 Elevator, Bartlett, 72  
 Brophy, 172  
 Lecluse, 278  
 Elevators for extraction of teeth, 278  
 Embolism, air, 61  
 experiments in, 62-64  
 Empyema, 34  
 Endothelioma, 41, 363, 388  
 Epulis, 352  
 treatment of, 352  
 Erb's scars, 444  
 Erythema migrans linguæ, 441  
 multiforme, 289  
 Ether in general anesthesia, 602  
 Ethyl chlorid in local anesthesia, 589  
 Etiology of carcinoma of the tongue, 464

- Eustachian canal, 520  
 cushion, 520
- Examination of adults, 1  
 of children, 1  
 of infants, 1  
 of tumors, 2  
 of ulcers, 2  
 physical, 1
- Excision of growths and ulcers of doubtful character on the lip, 393  
 of indolent carcinoma of the lip, 394  
 of indurating carcinoma of the lip, 394  
 of jaw-bones, 370  
 prevention of deformity in, 379  
 of the mandible, 377  
 of the maxilla, 370  
 of the parotid gland, 430  
 of the sublingual gland, 436  
 of the submaxillary gland, 435  
 of the tongue, bilateral, 500  
 Kocher's normal, 501  
 V-shaped, 494
- Extraction of teeth, 276-283  
 bleeding in, control of, 50  
 elevators in, 278  
 forceps in, 277  
 impacted, 282  
 instruments in, 276  
 reasons for, 276  
 temporary, 279
- Exudative stomatitis, 286

## F

- Facial-accessory nerve anastomosis, 552  
 artery, constriction of the, 543  
 ligation of the, 543  
 clefts, congenital, 122-138  
 clinical types of, 132  
 Merkel's plan of, 123  
 morphology of, 122  
 theories of, 133  
 types of, 124  
 -hypoglossal anastomosis, 552  
 nerve, affections of the, 549  
 prognosis of, 550  
 symptoms of, 550  
 treatment of, 551  
 tic, 554  
 prognosis of, 556  
 treatment of, 556
- Farcy, 294
- Fauces, anatomy of the, 14  
 pharyngeal wall and velum, adhesions of, 528  
 prognosis of, 530  
 treatment of, 529
- Faure, excision of the parotid gland, 433
- Feeding during treatment of fracture of the lower jaw, 114
- Ferguson, theory of relation of alveolar cleft to teeth, 130
- Fibroma, 353  
 nasopharyngeal, 524  
 treatment of, 525  
 of the tongue, 457  
 retromaxillary, treatment of, 367
- Fibrous odontoma, 356
- Field, operative, preparation of, 43
- Fifth cranial nerve, 557  
 injection of the peripheral branches of the, 566  
 of the trunks of the, 570  
 major neuralgia of the, 558  
 diagnosis of, 562  
 symptoms of, 558
- Fissures of the tongue, 438  
 syphilitic, 448  
 tubercular, 446
- Fistula, alveolar, 309  
 treatment of, 323  
 bone, 309  
 branchial, 521  
 diagnosis of, 522  
 treatment of, 522  
 salivary, 418  
 conversion of an external into an internal, 421  
 diagnosis of, 419  
 reconstruction of the distal part of the duct from buccal mucosa in, 423  
 repair of the duct in a, 422  
 transplantation of the end of the proximal part of the duct into the buccal mucosa in, 423  
 treatment of, 420
- Fixation, direct, in fractures of the lower jaw, 95  
 indirect, in fractures of the lower jaw, 95
- Flap sliding operation for congenital facial clefts, 174  
 transplantation for oral scar bands, 267
- Flaps, repair by, from other than palate tissues, 145, 192  
 from palate tissues, 142  
 principles of, in congenital palate clefts, 139-147  
 transplantation of skin- or mucus-covered, 217  
 after-treatment of, 222  
 blood supply of, 221  
 cheek flaps in, 219  
 neck flaps in, 219  
 preparation of margins of the defect in, 218  
 preservation of the epithelial lining in the mouth in, 218  
 preservation of the motor nerves in, 218  
 shoulder and chest flaps in, 221

- Follicular odontoma, 355  
 compound, 356
- Foot and mouth disease, 295
- Forceps in extraction of teeth, 277
- Fordyce's disease, 289
- Foreign body, possible presence of, 68
- Fossa of Rosenmüller, 520
- Fracture bands, Angle, 96  
 of the teeth, 82  
 treatment of, 82
- Fractures of the lower jaw, 89-114  
 at angle, operation for wiring the  
 bones, 99  
 care of the tissues in, 108  
 character of the injury, 89  
 delayed union in, 113  
 dental splints in, 102  
 diagnosis of, 94  
 direct fixation in, 95  
 displacement in, 89  
 feeding during treatment in, 114  
 indirect fixation in, 95  
 Lane's plate in, 101  
 malunion in, 114  
 operation of wiring the jaw at  
 or in front of the second  
 molar, 101  
 time required for union, 113  
 treatment of, 95  
 complicated by loss of bone, 112  
 individual fractures in, 109  
 wiring lower to the upper in, 96  
 x-ray in diagnosis of, 94
- of the mandible, 89-114  
 of the ramus, 93, 108, 111  
 of the upper jaw, 83-88  
 care of the tissues in, 85  
 character of the injury in, 83  
 diagnosis of, 84  
 displacement in, 83  
 Kingsley splint in, 87  
 Marshall's method in, 86  
 treatment of, 84  
 mechanical, 85
- Frisch, bacillus of, 296
- Furuncle of the lips, 386
- G
- Gag, Lane, 170  
 Owen-Smith, 170  
 Whitehead, 170
- Gangrene, 290  
 definition of, 32  
 of the lips, 386  
 treatment of, 291
- Gasserian ganglion, operation of cut-  
 ting the posterior root of  
 the, 581
- Gelatin for prevention of hemorrhage,  
 47
- Geographical tongue, 441
- German measles, 293
- Gigli saw, 242, 257
- Gilmer, method of reconstructing den-  
 tal arches, 103  
 of wiring lower to upper jaw,  
 96  
 modification of Garretson's use of  
 lead plates, 205  
 posterior band splint, 106
- Gland, parotid, anatomy of, 24  
 invasion and excision of, 430  
 submaxillary, anatomy of, 24  
 invasion and excision of, 435
- Glanders, 294
- Glands, Bochdalek's, anatomy of, 6  
 of Nuhn and Blandin, anatomy of, 5  
 calculi in, 415  
 salivary, actinomycosis of, 413  
 acute suppurative inflammation  
 of the, 409  
 adenoma of the, 429  
 affections of the, 408-436  
 anatomy of the, 24  
 carcinoma of the, 429  
 chronic inflammation of the, 411  
 cysts of the, 413  
 foreign bodies and stones in the,  
 415  
 inflammation of the larger ducts  
 of the, 408  
 inflammatory tumors of the, 411  
 obstruction of the ducts of the,  
 413  
 diagnosis of, 414  
 treatment of, 414
- secondary infections of the, 410  
 prophylaxis of, 410  
 treatment of, 411
- specific infections of the, 412
- syphilis of the, 413
- tuberculosis of the, 412
- tumors of the, 426  
 benign, 426  
 epithelial, 429  
 inflammatory, 411  
 mixed, 426  
 wounds in the, 418
- Glossitis, chronic superficial, 441  
 Moeller's, 445  
 sclerosing, 448
- Glossodynia exfoliativa, 446
- Gloves, rubber, sterilization of, 44
- Goitre, lingual, 458  
 retropharyngeal, 535
- Gonorrhoea, 294
- Grafts, Thiersch, 217
- Granulations in wounds, 73
- Graves, scaphoid scapula, 137
- Gumma of the mouth, 301  
 of the tongue, 449
- Gums, abscess of, 18  
 anatomy of, 17  
 hypertrophy of the, 351  
 mucous cysts of the, 352  
 retraction of the, 310  
 treatment of, 321

Gunning splint, 105  
Gun-shot wounds, 68

## H

Hairy tongue, 445  
Hammond splint, 102  
Hammond-Robert's palate clamp, 166  
Hands, surgeon's, preparation of, 42  
Harelip, 124  
  correction of, 200  
  double, operation for, 203  
  Owen operation for, 203  
  Rose operation for, 201  
Hartwell, method of transfusion, 57  
Heat as symptom of inflammation, 29  
Hemangioma of the lips, 387  
Hemorrhage, 46  
  application of cold for, 50  
  control of, 48  
  of carcinoma of the tongue, 472  
  postoperative, 51  
  in palate cleft operations, 184  
  prevention of, 46  
  animal serum for, 48  
  calcium lactate for, 47  
  defibrinated blood transfusions  
  for, 48  
  gelatin for, 47  
  sequestration of blood for, 46  
  secondary, 52  
  treatment of effects of, 52  
  vasoconstrictor drugs in, 51  
Heredity, influence of, on failure of  
  cleft closure, 133  
Herpes, 286  
  Butlin's ointment for, 287  
  of the lips, 386  
Hilton, method of intraoral incision,  
  324  
Horsley, formula for arterial bleed-  
  ing, 48  
Holzphlegmon, 335  
Hullihan splints, 105, 258  
Hutchinson teeth, 16  
Hyperemia, Bier's, for inflammations,  
  36  
Hypertrophy of bone, 318  
  of the gums, 351  
  of the lips, simple, 385  
  pseudo, 412  
Hypodermic armamentarium in local  
  anesthesia, 592  
Hypoglossal nerve, affections of the,  
  554  
Hysterical closure of the jaws, 264

## I

Ichthyosis of the tongue, 445  
Immunity, acquired, 28, 29  
  inherited, 28, 29

Impacted teeth, 281  
  after-treatment of, 283  
  removal of, 282  
  treatment of, 282  
  indications for, 281  
Implantation of teeth, 81  
Incised wounds, 67  
Incisive glands, anatomy of, 5  
Indentations of the tongue, 438  
Induration of carcinoma of the  
  tongue, 469  
Infants, correction of alveolar cleft  
  in, 197  
  examination of, 1  
Infection, agencies of, 32  
  antral, 342  
  as a cause of cleft closure, 137  
  definition of, 32  
  in carcinoma of the tongue, lym-  
  phatic, 472  
  inflammation accompanying, 28  
  of a wound, 69  
  spread of, 32  
Infections, 32  
  of bone, specific, 315  
  treatment of, 331  
  of floor of the mouth, 333  
  of the jaw-bones, 306  
  treatment of, 319  
  of the mouth, 284  
  of the neck, 333  
  of the peridental tissues, 306  
  treatment of, 319  
  of the pharynx, acute, 524  
  of the salivary glands, prophylaxis  
  of, 410  
  secondary, 410  
  specific, 412  
  treatment of, 411  
  of the teeth, 306  
  treatment of, 319  
  specific, 293  
  treatment of, 35  
  by antitoxins, 37  
  by cold, 36  
  by heat, 36  
  by hyperemia, 36  
  by surgery, 35  
Inflammation, 28  
  accompanying an infection, 28  
  from irritation, 28  
  good or harm from, 31  
  of the bone, 311  
  of the pericementum, 310  
  of the salivary glands, chronic,  
  411  
  of the larger ducts of, 408  
  results of, 30  
  symptoms of, 30  
Inflammations of the mouth, 284  
  of the tongue, 440  
  treatment of, 35  
Inflammatory tumor of the salivary  
  glands, 411

- Injection in local anesthesia, intra-  
 osseous, 595  
 periodental, 595  
 perineurial, 596  
 subperiosteal, 594  
 technic of, 593  
 of paraffin, for obliquity of the  
 chin, 247  
 postpharyngeal, 216  
 of the auriculotemporal nerve, 567  
 of the descending palatine nerve,  
 568  
 of the fifth nerve, mandibular di-  
 vision, 570  
 ophthalmic division, 575  
 peripheral branches, 566  
 superior maxillary division, 573  
 trunks, 570  
 of the inferior dental nerve, 567  
 mental branch, 567  
 of the infraorbital nerve, 567  
 of the lingual nerve, 568  
 of the long buccal nerve, 569  
 of the nasal nerve, 566  
 of the orbital branch of the supe-  
 rior maxillary nerve, 567  
 of the palatine branch of the naso-  
 palatine nerve, 569  
 of the sphenopalatine ganglion, 573  
 of the supraorbital nerve, 567  
 of the supratrochlear nerve, 567  
 Injuries of the lips, 384  
 of the pharynx, 524  
 of the soft parts, 67  
 Injury as cause of failure of cleft  
 closure, 137  
 Instruments in extraction of teeth,  
 276  
 sterilization of, 44  
 Insufflation, general anesthesia by, 602  
 Intracranial operations, 579  
 Intraoral operation for removal of  
 the tongue, 494  
 Intravenous transfusion, 53  
 Irregular setting of the teeth, causes  
 for, 231
- J
- Jacobson, pharyngotomy, 537  
 Jaksch, v., test for diacetic acid, 66  
 Jaw, ankylosis of, operations for, 270  
 lower, carcinoma of the, 364, 365  
 disarticulation of half of the, 378  
 dislocation of, 115-121  
 backward, 115  
 chronic, 121  
 forward, 116  
 kinds of, 115  
 outward, 116  
 reduction by manipulation, 120  
 reduction by traction, 119  
 retention of, 120  
 Stimson on, 118
- Jaw, lower, dislocation of—*cont'd*  
 subluxation of, 121  
 symptoms of anterior, 119  
 treatment of, 119  
 unreduced, 121  
 upward, 115  
 excision of the, 377  
 fractures of, 89-114  
 at angle, operation for wiring  
 the bone, 99  
 care of the tissues in, 108  
 character of the injury, 89  
 delayed union in, 113  
 dental splints in, 102  
 diagnosis of, 94  
 direct fixation in, 95  
 Lane plates in, 101  
 malunion in, 114  
 operation of wiring the jaw at  
 or in front of the second  
 molar, 101  
 time required for union, 113  
 treatment of, 95  
 treatment of, complicated by  
 loss of bone, 112  
 treatment of individual frac-  
 tures in, 109  
 wiring lower to the upper in,  
 96  
 x-ray in diagnosis of, 94  
 protrusion of the, 235, 250  
 Babcock's operation for, 259  
 correction by surgical opera-  
 tion, 251  
 correction by traction, 250  
 submucoperiosteal operation  
 for, 256  
 transmucoperiosteal operation  
 for, 255  
 retraction of the, 235, 238  
 correction by surgical opera-  
 tion, 239  
 correction by traction, 239  
 operation for, 242  
 undeveloped, x-ray of, 230  
 upper, carcinoma of, 364, 365  
 fractures of, 83-88  
 care of the tissues in, 85  
 character of the injury in, 83  
 diagnosis of, 84  
 displacement in, 83  
 Kingsley splint in, 87  
 Marshall's method of, 85  
 treatment of, 84
- Jaw-bones, excisions of the, 370  
 prevention of deformity in, 379  
 infections of the, 306  
 treatment of, 319  
 resections of the, 370  
 tumors of the, 351
- Jaws, anatomy of, 22  
 closure of the hysterical, 264  
 deformities of the, after-treatment  
 of operations on, 262

- Jaws, deformities of the—*cont'd*  
 atypical, 261  
 preoperative considerations of, 261  
 limitation of, due to reflex irritation, 264  
 due to scar bands or ankylosis, 265  
 malrelation of the, and the dental arches, 262  
 indications for surgical operations for, 237  
 orthodonture in the treatment of, 237  
 Junker apparatus for anesthesia, 152

## K

- Kaufmann, method of conversion of an external into an internal salivary fistula, 421  
 Keloid of the tongue, 457  
 Keratosis, 441  
 Kingsley splint, 87, 105  
 Klebs-Löffler bacillus, 294  
 Koch's serum reaction, 300  
 Kocher normal excision of the tongue, 501  
 operation for resection of the tongue at the root, 502  
 Kölliker, theory of relation of alveolar cleft to teeth, 131  
 Koplik's spots, 293  
 Krause, operation for extirpation of Gasserian ganglion, 583  
 Küster, operation for chronic antral infection, 347  
 operation for congenital palate clefts, 186

## L

- Lane gag, 170  
 operation for palate and lip clefts, 161  
 plates, 101  
 Langenbeck low lateral pharyngotomy, 540  
 operation for congenital palate clefts, 176  
 operation for salivary fistula, 423  
 Lecluse elevator, 278  
 Legal's test for acetone, 66  
 Leontiasis ossea, 318  
 Leprosy, 295  
 Leptothrix, 305  
 Leucoma, 442  
 Leucoplakia, 286, 442  
 Ligation of arteries, 52, 542  
 common carotid, 546  
 coronary, 543  
 external carotid, 544  
 facial, 543

- Ligation of arteries—*cont'd*  
 lingual, 543  
 temporal, 543  
 Limitation of jaws, due to reflex irritation, 264  
 due to scar bands or ankylosis, 265  
 Lingual artery, constriction of, 543  
 ligation of, 543  
 goitre, 458  
 Lip operation, difficult respiration after a, 208  
 pits, congenital, 138  
 restoration of the lower, 226  
 Burow-Stewart operation for, 226  
 of the upper, 228  
 Lipoma, 353  
 of the tongue, 456  
 Lips, anatomy of, 20  
 angioma of the, 387  
 blood supply of the, 21  
 cancer of the, 390-399  
 carbuncle of the, 386  
 carcinoma of the, 390-399  
 diagnosis of, 310  
 excision of growths and ulcers of doubtful character, 393  
 of indolent, 394  
 of indurating, 394  
 operation for early indurated, 394  
 where repair is to be made with flaps from the neck, 398  
 prognosis of, 399  
 treatment of, 391  
 chaps of the, 384  
 cheeks, and palate, repair of acquired defects in, 217-229  
 congenital clefts of the, after-treatment of, 209  
 operative correction of, 196-210  
 results of, 210  
 cracks of the, 384  
 cysts of the, 387  
 diseases of the, 384  
 furuncle of the, 386  
 gangrene of the, 386  
 hemangioma of the, 387  
 herpes of the, 386  
 injuries of the, 384  
 papillomata on the, 389  
 phlegmon of the, 386  
 scars on the, 384  
 syphilis of the, 387  
 tuberculosis of the, 386  
 tumors of the, 384  
 warts on the, 389  
 Local anesthesia, 588-600  
 absorption of poisonous drugs in, 590  
 adrenalin in, 589  
 anesthetization of the pulp in, 597  
 cocain in, 590

- Local anesthesia—*cont'd*  
 ethyl chlorid in, 539  
 for anesthetizing the skin, 599  
 for operations about the mouth, 598  
 hypodermic armamentarium in, 592  
 intraosseous injection in, 595  
 means of producing, 588  
 novocain in, 590, 592  
 peridental injection in, 595  
 perineurial injection in, 596  
 preparation of solution in, 591  
 subperiosteal injection in, 594  
 technic of injection in, 593
- Lockjaw, 72
- Loosening of the teeth, 81  
 treatment of, 81
- Ludwig's angina, 334
- Lungs, edema of, 63
- Lupus of the mouth, 299
- Lymph nodes, anatomy of, 26
- Lymphangiomatous macroglossia, 450  
 treatment of, 451
- Lymphatic infection in carcinoma of the tongue, 472
- Lymphatics, cervical, malignant diseases of the, 506  
 radical operation for tubercular infection of the, 510  
 results of, 515  
 secondary carcinoma of the, 516  
 results of operation on, 518  
 treatment of, 516  
 tuberculosis of the, 506
- Lymphosarcoma of the pharynx, 536

## M

- Macrochelia, 385
- Macroglossia, lymphangiomatous, 450  
 treatment of, 451  
 simple muscular, 452
- Macrostomia, 125
- Malformations of the pharynx, congenital, 520
- Malignant tumors, 40  
 of the pharynx, 536
- Malleus, 294
- Malnutrition as cause of failure of cleft closure, 136
- Malocclusion, 231
- Malrelations of the jaws, and of the dental arches, 232  
 indications for surgical operation for, 237  
 orthodonture in the treatment of, 237
- Malunion in fractures of the lower jaw, 114
- Mandible, carcinoma of the, 364, 365  
 disarticulation of half the, 378  
 dislocation of the, 115-121  
 excision of the, 377

- Mandible—*cont'd*  
 fractures of the, 89-114  
 protrusion of the, 235, 250  
 retraction of the, 235, 238
- Marshall, method in fractures of the upper jaw, 86
- Martin splint, 380
- Maternal impressions as cause of failure of cleft closure, 136
- Maxilla, excisions of the, 370  
 resection of the, 370  
 total, 374  
 upper part of, 373
- Maxillæ, approximation of the, in congenital palate clefts, 190  
 deformities of the, 238
- Maxillary antrum, 342  
 anatomy of, 23, 342  
 sinus, diseases of the, 342-350
- Measles, 293  
 German, 293
- Mechanical cause in failure of cleft closure, 134
- Mercurial stomatitis, 289
- Mercury poisoning, 315
- Metallic poisoning, 289, 315
- Microorganisms of suppuration, 33
- Mikulicz's disease, 412  
 high lateral pharyngotomy, 538
- Mineral poisons, 289, 315
- Mixed tumors of the salivary glands, 426
- Moeller's glossitis, 445
- Morawitz, defibrinated blood transfusion as a styptic, 48
- Morphology of congenital facial clefts, 122
- Mortality of operations on congenital palate clefts, 166, 185
- Motor derangement, 547-556
- Moullin, description of shock, 59
- Mouth, actinomycosis of the, 304  
 anatomy of, 2  
 and the cheek, closure of defects at the angle of the, 222  
 chancre of the, 302  
 floor of the, anatomy of, 4  
 carcinoma of the, 407  
 cysts of the, 400  
 infections of the, 400  
 tumors of the, 400  
 benign, 407  
 malignant, 407  
 gumma of the, 301  
 infections of the, 284  
 inflammation of the, 284  
 local anesthesia for operations about the, 598  
 lupus of the, 299  
 method of washing a baby's, 285  
 parasites of the, 303  
 Serre operation for restoring the angle of the, 225  
 syphilis of the, 300



**Mouth—cont'd**  
 tuberculosis of the, 299  
 tumors of the, 351  
 vestibule of the, anatomy of, 19  
 Mucolofibrinous stomatitis, 288  
 Mucous cysts of the gums, 352  
 patch of the tongue, 447  
 Mucus-covered flaps, transplantation  
 of skin- or, 217  
 Multilocular cystic tumors, 363  
 Mumps, 409  
 Murphy method of proctoclysis, 54  
 Muscles of mastication, anatomy of,  
 24  
 speech, physiological action of, 24  
 Mush bite, 105  
 Myeloma, 363  
 Myxoma, 355  
 Myxosarcoma, 355

## N

Nares, atresia of the posterior, 520  
 osseous obstruction of the, 238  
 Nasopharyngeal fibroma, 524  
 treatment of, 525  
 polypus, 524  
 treatment of, 525  
 Neck, infections of the, 333  
 Necrosis, 311, 313  
 definition of, 32  
 treatment of, 323  
 by removal of the sequestrum,  
 325  
 Nerve anastomosis, facial-accessory,  
 552  
 facial-hypoglossal, 552  
 facial, affections of, 549  
 prognosis of, 550  
 symptoms of, 550  
 treatment of, 551  
 fifth cranial, 557  
 injections of the mandibular di-  
 vision of the, 570  
 of the ophthalmic division of  
 the, 575  
 of the peripheral branches of  
 the, 566  
 of the superior maxillary di-  
 vision of the, 573  
 of the trunks of the, 570  
 major neuralgia of the, 558  
 diagnosis of, 562  
 symptoms of, 558  
 frontal, avulsion of the, 579  
 hypoglossal, affections of the, 554  
 nasal, avulsion of the, 579  
 resection, 579  
 trifacial, affections of the, 549  
 Neuralgia, sphenopalatine, 562  
 Nevi of the tongue, capillary, 452  
 Nicoladoni, operation for repair of  
 duct in salivary fistula, 422

Nicoladoni and Braun, reconstruction  
 of distal part of duct from  
 the buccal mucosa for sali-  
 vary fistula, 423  
 Nitrous oxid in general anesthesia,  
 502  
 Nodes, lymph, anatomy of, 26  
 Nodules of the tongue, 438  
 Noguchi reaction, 302  
 Noma, 291  
 treatment of, 292  
 Nose, correction of deformity of the,  
 205  
 deviated, Senseny's plan of replac-  
 ing a, 207  
 Novocain in local anesthesia, 590, 592  
 Nuhn and Blandin, glands of, anat-  
 omy of, 5  
 calculi in, 415

## O

Obliquity of the chin, 246  
 paraffin injection for, 247  
 transplantation of bone or carti-  
 lage for, 248  
 Obstruction of the nares, osseous, 238  
 Obturator, Warnikros, 213  
 Obturators, 213  
 versus operation, 216  
 Occlusion, ideal, 230  
 Odontoma, 355  
 composite, 357  
 fibrous, 356  
 follicular, 355  
 compound, 356  
 radicular, 357  
 treatment of, 358  
 Oidium albicans, 303  
 Open bite, 236  
 correction by surgical operation,  
 260  
 by traction, 260  
 operation for, 260  
 fixation in, 260  
 Operation about the mouth, local an-  
 esthesia for, 598  
 for ankylosis of the jaw, 270  
 for carcinoma of the lip, early in-  
 dicated, 394  
 where repair is to be made  
 with neck flaps, 398  
 of the tongue, results of, 483  
 for chronic antral infection, Can-  
 field-Ballenger, 349  
 Cauldwell-Luc, 347  
 Denker, 347  
 Küster, 347  
 for congenital palate clefts, advan-  
 tages of very early, 149  
 Brophy, 153  
 choice of, 164  
 Davies-Colley, 162  
 flap sliding, 174

Operation for congenital palate clefts  
 —*cont'd*  
 in early infancy, 151-166  
   preparation for, 151  
 in extraordinary cases, 186-195  
 in ordinary cases after early infancy, plastic, 167-185  
   preparation for, 168  
 Küster, 186  
 Lane, 161  
 Langenbeck, 176  
 mortality of, 166  
 preferable age for, 148  
 two-step, 186  
 for double harelip, 203  
 for fracture of the lower jaw, wiring the bone, 99  
 for harelip, Owen, 203  
   Rose, 201  
 for malrelation of the jaws, indications for, 237  
 for open bite, 260  
   fixation in, 260  
 for oral scar bands by flap transplantation, 267  
 for protrusion of the lower jaw, Babcock's, 259  
   submucoperiosteal, 256  
     adjusting the bone, 257  
     cutting the bone, 256  
     intraoral fixation, 258  
   transmucoperiosteal, 255  
     cutting the bone, 255  
     fixing the jaw, 255  
 for removal of the tongue, 493  
   anesthesia in, 494  
   excision of one half of body, 496  
   general preparation for, 493  
   intraoral, 494  
   local preparation for, 493  
   position on the table in, 494  
   V-shaped, 494  
 for restoring the angle of the mouth, 225  
   the lower lip, Burow-Stewart, 226  
 for retraction of the lower jaw, 242  
   adjusting the bone in, 294  
   cutting the bone in, 242  
   intraoral fixation in, 245  
 for tubercular adenitis, 510  
   results of, 515  
 in infection of the cervical lymphatics, 515  
   results, 515  
 intracranial, 579  
 lip, difficult respiration after a, 208  
 obturators versus, 216  
 of cutting the posterior root of the Gasserian ganglion, 581  
 of wiring the jaw at or in front of second molar, 101  
 Operative correction of congenital clefts of the lip and alveolar process, 196-210

Operative—*cont'd*  
 field, preparation of, 43  
 treatment of oral scar bands, 267  
 Orbicularis oris, 20  
 Orthodonture in the treatment of malrelations of the jaws, 237  
 Osseous obstruction of the nares, 237  
 Osteitis, 311  
   postfebrile, 317  
 Osteoplastic resections, 375  
   mortality of, 376  
   prognosis of, 377  
 Owen operation for harelip, 203  
 Owen-Smith gag, 170

## P

Pain, 2  
 as symptom of inflammation, 29  
 of carcinoma of the tongue, 469, 471  
 referred, 2  
 Palate adenoma, 534  
   treatment of, 534  
 and alveolar process, resection of the, 371  
 anatomy of the, 12  
 clamp, Hammond-Roberts, 166  
 clefts, congenital, 139-195  
   advantages of very early operation for, 149  
   after-treatment of, 164, 184  
   anatomical considerations of, 139  
   approximation of the maxilla in, 190  
   Brophy operation for, 153  
   choice of operation for, 164  
   consideration of various ages for operation for, 148  
   Davies-Colley operation for, 162  
   double, 141  
   flap sliding operation for, 174  
   instruments and materials for, 169  
   Küster operation for, 186  
   Lane operation for, 161  
   Langenbeck operation for, 176  
   mortality in, 185  
   mortality in operations for, 166  
   non-union in, 184  
   operations for extraordinary cases of, 186-195  
   operations in early infancy for, 151-166  
   plastic operations in ordinary cases after early infancy, 167-185  
   position and light in operation on, 168  
   postoperative hemorrhage in, 184

## Palate

- clefts, congenital—*cont'd*
  - preferable age at which to operate, 148-150
  - preparation for operation, 151, 168
  - principles of repair by plastic flaps, 139-147
  - reoperation in, 185
  - repair by flaps from other than palate tissues, 145, 192
  - repair by flaps from palate tissues, 142
  - results in, 185
  - retention devices for, 182
  - single, 141
  - two-step operation for, 186
- lips, and cheeks, repair of acquired defects in, 217-229
- perforations of the, 228
- speech, cleft, 214
- Palsy, Bell's, 549
- Papillomata of the lips, 389
  - of the tongue, 460
  - treatment of, 461
- Paraffin injection for obliquity of the chin, 247
  - postpharyngeal injection of, 216
- Paralysis, Bell's, 549
- Paralytic affections, 547
  - electrical tests for, 547
  - treatment of, 548
- Parasites of the mouth, 303
- Parotid gland, anatomy of, 24
  - invasion and excision of, 430
- Parotitis, 409
- Partsch band, 382
- Passavant's cushion, 205
- Pearl worker's disease, 315
- Pellagra, 288
- Pemphigus, 287
- Perforations of the palate, 228
- Pericementitis, 310
  - treatment of, 525
- Pericementum, inflammation of the, 310
- Perihyoid thyroid tumors and glands, 458
- Peritonsillar abscess, 525
  - treatment of, 525
- Perlèche, 386
- Pharyngeal pouches, 524
  - wall, velum, and fauces, adhesions of, 528
    - prognosis of, 530
    - treatment of, 529
- Pharyngitis, acute, 524
  - phlegmonous, 524
- Pharyngotomy, 537
  - high lateral, 538
  - intraoral removal in, 537
  - low lateral, 540
- Pharynx, acute infections of the, 524
  - anatomy of the, 14, 519

Pharynx—*cont'd*

- carcinoma of the, 537
- congenital malformations of the, 520
  - diseases of the, 519
  - injuries of the, 524
  - lymphosarcoma of the, 536
  - sarcoma of the, 536
  - stricture of the, 528
  - teratomata of the, 532
  - tumors of the, 532
    - benign, 533
    - malignant, 536
    - vascular, 533
- Phlegmon of the lips, 386
- Phlegmonous pharyngitis, 524
  - stomatitis, 340
- Phosphorus poisoning, 315
- Physiological action of speech muscles, 211
- Pits, congenital lip, 138
- Plastic flaps, made from other than palate tissue, 145
  - made from palate tissue, 142
  - principles of repair by, in congenital palate clefts, 139-147
  - operations in ordinary cases of palate cleft, after early infancy, 167-185
    - in wounds, 75
- Plates, Lane, 101
- Plaut, angina of, 297
- Pneumonia postoperative, 63
- Poisoning, arsenic, 315
  - bismuth, 315
  - mercury, 315
  - phosphorus, 315
- Poisons, metallic, 315
  - mineral, 289, 315
- Polypus, nasopharyngeal, 524
  - treatment of, 525
- Postfebrile osteitis, 317
- Postoperative hemorrhage, 51
  - in operations on palate cleft, 184
  - pneumonia, 63
- Postpharyngeal injection of paraffin, 216
- Pouches, pharyngeal, 524
- Preparation of dressings, 44
  - of instruments, 44
  - of operative field, 42
  - of rubber gloves, 44
  - of surgeon's hands, 42
  - of sutures, 45
- Prevention of deformity, in excisions of the jaw-bones, 379
  - of hemorrhage, 46
  - sequestration of blood for, 46
- Prinz, diagnosis of condition of pulp, 17
  - extraction of teeth, 276
  - local anesthesia, 276
- Probe, use of, 69
- Proctoclysis, 54

Proctoclysis—*cont'd*  
 method of J. B. Murphy, 54  
 use of atropin after, 54  
 Prognosis of carcinoma of the  
 tongue, 482  
 Protrusion of the lower jaw, 235, 250  
 Babcock's operation for, 259  
 correction by surgical operation  
 of, 251  
 by traction of, 250  
 submucoperiosteal operation for,  
 256  
 adjusting the bone, 257  
 cutting the bone, 256  
 intraoral fixation, 258  
 transmucoperiosteal operation  
 for, 255  
 cutting the bone, 255  
 fixing the jaw, 255  
 Psoriasis of the tongue, 444  
 Puncture wounds, 67  
 Pus formation, 30, 33  
 Pus-forming organisms, 33  
 Pyemia, 32  
 Pyorrhoea alveolaris, 17, 311  
 treatment of, 322

## R

Radicular odontoma, 357  
 Ramus, fracture of the, 93, 108, 111  
 Ranula, 400  
 diagnosis of, 402  
 symptoms of, 401  
 treatment of, 402  
 Raw tongue, 440  
 Redness as symptom of inflamma-  
 tion, 29  
 Reduction of dislocation of lower  
 jaw, by manipulation, 120  
 by traction, 119  
 retention after, 120  
 Rehn's spots, 293  
 Reoperation in congenital palate  
 clefts, 185  
 Repair of acquired defects in the  
 lips, cheeks, and palate, 217-  
 229  
 Replantation of teeth, 81  
 Resection, nerve, 579  
 of the alveolar process, inferior,  
 377  
 superior, 370  
 of the jaw-bones, 370  
 of the mandible, 377  
 of the maxilla, 370  
 after-treatment of, 375  
 total, 374  
 upper part, 373  
 of the palate and alveolar process,  
 371  
 of the tongue at the root, Kocher's  
 operation, 502

Resection—*cont'd*  
 osteoplastic, 375  
 mortality of, 376  
 prognosis of, 377  
 Respiration, difficult, after a lip oper-  
 ation, 208  
 Restoration of the lower lip, 226  
 Burow-Stewart operation for, 226  
 of the upper lip, 228  
 Retraction of the gums, 310  
 treatment of, 319  
 of the lower jaw, 235, 238  
 correction by surgical operation  
 for, 239  
 by traction for, 239  
 operation for, 242  
 adjusting the bone in, 244  
 cutting the bone in, 242  
 intraoral fixation in, 245  
 Retromaxillary fibromata, treatment  
 of, 367  
 tumors, 366  
 Retropharyngeal abscess, 526  
 treatment of, 527  
 goitre, 535  
 Rima oris, 20  
 Rose operation for harelip, 201  
 Rosenmüller, fossa of, 520  
 Rubber gloves, sterilization of, 44  
 Rubeola, 293

## S

Saline transfusion, 53  
 Salivary calculi, 415  
 treatment of, 417  
 fistula, 418  
 conversion of an external into an  
 internal, 421  
 diagnosis of, 419  
 reconstruction of the distal part  
 of the duct from the buccal  
 mucosa in, 423  
 repair of the duct in, 422  
 transplantation of the end of the  
 proximal part of the duct  
 into the buccal mucosa in,  
 424  
 treatment of, 420  
 glands, actinomycosis of the, 413  
 acute suppurative inflammation  
 of the, 409  
 adenoma of the, 429  
 affections of the, 408-436  
 anatomy of the, 24  
 carcinoma of the, 429  
 chronic inflammation of the, 411  
 cysts of the, 413  
 foreign bodies and stones in the,  
 415  
 inflammation of the larger ducts  
 of the, 408  
 inflammatory tumors of the, 411

- Salivary glands—*cont'd*  
 obstruction of the ducts of the, 413  
   diagnosis of, 414  
   treatment of, 414  
 secondary infections of the, 410  
   prophylaxis of, 410  
   treatment of, 411  
 specific infections of the, 412  
 syphilis of the, 413  
 tuberculosis of the, 412  
 tumors of the, 426  
   benign, 426  
   epithelial, 429  
   inflammatory, 411  
   mixed, 426  
   wounds in the, 418  
 Salivation in carcinoma of the mouth, 472  
 Salvarsan in syphilis, 302  
 Sarcina, 305  
 Sarcoma, 41, 359  
   Coley's fluid for, 362  
   of the pharynx, 536  
   of the tongue, 462  
   treatment of, 463  
   treatment of, 361  
   starvation, 362  
 Saw, Gigli, 242, 257  
 Scaphoid scapula, Graves, 137  
 Scar bands, operation by flap transplantation on, 267  
   operative treatment of oral, 267  
   or ankylosis, limitation of jaws due to, 265  
 Scars after wounds, 74  
   of the floor of the mouth, 407  
   on the lips, 384  
 Scleroma, 296  
 Sclerosing glossitis, 448  
 Scurvy, 293  
 Secondary hemorrhage, 52  
 Senseny, plan of replacing a deviated nose, 207  
 Sepsis, probability of, in wounds, 69  
 Septicemia, 32  
 Sequestration of blood for prevention of hemorrhage, 46  
 Sequestrum, removal of, in treatment of necrosis, 325  
 Serre, operation for restoring the angle of the mouth, 225  
 Serum, animal, for prevention of hemorrhage, 48  
 Shock, 58  
   depression in, 59  
   diagnosis of, 60  
   excitement in, 59  
   fatality of, 59  
   in burns, 76  
   Moullin's description of, 53  
   treatment of, 60  
 Siegel, bacillus of, 295  
 Simple muscular macroglossia, 452  
 Sinus leading to a dermoid, treatment of, 406  
 Skin, local anesthesia for anesthetizing the, 599  
   or mucus-covered flaps, transplantation of, 217  
 Slough, 290  
   treatment of, 291  
 Sluder on sphenopalatine neuralgia, 562  
 Smallpox, 293  
 Smoker's patch, 443  
 Smooth tongue, 445  
 Spasmodic affections, 554  
 Specific infections, 393  
   of bone, 315  
   treatment of, 321  
 Speculum, oral, Brophy, 170  
 Speech, cleft palate, 214  
   muscles, physiological action of, 211  
   training, 215  
 Sphenopalatine ganglion, injection of the, 573  
   neuralgia, 562  
 Spinal analgesia, 603  
 Spirochæta pallida, 300, 387  
 Splint, Angle, 105  
   Brown's modification of, 258  
   Gilmer posterior band, 106  
   Gunning, 105  
   Hammond, 102  
   Hullihan, 105, 258  
   Kingsley, 87, 105  
   Martin, 380  
 Splints, dental, 102  
   varieties of, 107  
 Sponges, 174  
 Stab wounds, 76  
 Staphylococcus albus in wounds, 70  
 Stenson's duct, 25  
 Sterilization of dressings, 44  
   of instruments, 44  
   of rubber gloves, 44  
   of sutures, 45  
 Stimson on dislocation of the lower jaw, 118  
 Stomatocacc, 296  
 Stomatitis, 285  
   acute catarrhal, 285  
   aphthous, 288  
   chronic, 286  
   ulcerative, 296  
   exudative, 286  
   gonorrhæal, 294  
   mercurial, 289  
   mucolofibrinous, 288  
   phlegmonous, 340  
 Stricture of the pharynx, 528  
 Styptic, blood transfusion as a, 48  
 Sublingual gland, anatomy of the, 24  
   invasion and excision of the, 436  
 Subluxation in dislocations of the lower jaw, 121

- Submaxillary gland, anatomy of the, 25  
 invasion and excision of the, 435
- Supernumerary teeth, 358  
 as cause of failure of cleft closure, 135
- Suppression of urine, 65
- Suppuration, 33  
 bacteria of, 33  
 microorganisms in, 33  
 tissue changes in, 34
- Surgical operation for malrelations of the jaws, indications for, 237
- Sutures, 77, 172  
 sterilization of, 45
- Suturing of wounds, 71, 75
- Sweet's cannula, 56
- Swelling as symptom of inflammation, 29
- Symptoms of anterior dislocation of lower jaw, 119  
 of antral infection, objective, 344  
 subjective, 343  
 of inflammation, 29  
 of mechanical abrasion of the teeth, 80  
 of ranula, 401
- Syphilis of bone, 315  
 treatment of, 332
- of the lips, 387  
 of the mouth, 300  
 of the salivary glands, 413  
 of the tongue, 447  
 salvarsan in, 302
- Syphilitic fissures of the tongue, 448

## T

- Teeth, anatomy of the, 15  
 avulsion of, 81  
 treatment of, 81  
 causes of irregular setting of the, 231  
 diagnosis of conditions of the, 21  
 extraction of, 276-283  
 elevators in, 278  
 forceps in, 277  
 individual, 279  
 instruments in, 276  
 reasons for, 276  
 temporary, 279
- fracture of the, 82  
 treatment of, 82
- Hutchinson, 16
- impacted, 281  
 after-treatment of, 283  
 removal of, 282  
 treatment of, 282  
 indications for, 281
- implantation of, 81
- infections of the, 306
- loosening of, 81  
 treatment of, 81
- Teeth—*cont'd*  
 mechanical abrasion of the, 80  
 symptoms of, 80  
 treatment of, 80  
 relation of alveolar cleft to, 129  
 Albrecht's theory of, 131  
 Ferguson's theory of, 130  
 Kölliker's theory of, 131  
 Warnikros' theory of, 130
- supernumerary, 358  
 as cause of failure of cleft closure, 135
- transplantation of, 81
- Temporal artery, constriction of, 543  
 ligation of, 543
- Temporomandibular joint, anatomy of, 21  
 diseases of the, 263  
 treatment of, 263
- Tenaculum, 171
- Teratomata of the pharynx, 532
- Tertiary placques of the tongue, 448
- Tetanus, 72  
 antitoxin, 72
- Thrush, 303
- Thyroglossal tract, cysts of the, 457  
 near the foramen cecum, 457  
 perihyoid, 458  
 treatment of, 459
- tumors of the, 457  
 near the foramen cecum, 457  
 perihyoid, 458  
 treatment of, 459
- Thyroid tumors and cysts, perihyoid, 458
- Tic douloureux, 558  
 diagnosis of, 562  
 etiology of, 563  
 pathology of, 563  
 symptoms of, 558  
 treatment of, 563
- facial, 554  
 prognosis of, 556  
 treatment of, 556
- Tissue changes in suppuration, 34
- Tongue, abscess of the, 341  
 after-treatment of operations on the, 503  
 anatomy of the, 7  
 aneurysm of the, 452  
 black, 445  
 cancer of the, 464-505  
 capillary nevi of the, 452  
 carcinoma of the, 464-505  
 age in, 465  
 chronicity of, 468  
 continuous growth of, 469  
 death from, 476  
 diagnosis of, 477  
 differential, 478  
 microscopical, 480  
 differentiation between operable and inoperable, 481

- Tongue, carcinoma of the—*cont'd*  
 early clinical characteristics of, 468  
 early diagnosis of, 466  
 early types of, 467  
 etiology of, 464  
 final stage of, 476  
 induration of, 469  
 microscopical appearance of, 470  
 mid-period of, 471  
   clinical types of, 475  
   general symptoms of, 476  
   growth of, 471  
   hemorrhage of, 472  
   lymphatic infection in, 472  
   pain of, 471  
   salivation in, 472  
   ulceration of, 471  
 operation on, 484  
   character of, 485  
   extent of, 484  
   excision of tongue or laryngotomy first in, 492  
   questions concerning, 484  
   removal of lymphatics in, 487  
   removal of lymph nodes in, 487  
   time of, 484  
   pain of, 469  
   position of, 464  
   predisposition to, 464  
   prognosis of, 482  
   results of operation on, 482  
   treatment of, 483  
   ulceration in, 469  
 cavernous angioma of the, 453  
   diagnosis of, 454  
   treatment of, 454  
 chancre of the, 447  
 deformities of the, 437  
 dyspeptic, 440  
 excision of the, bilateral, 500  
   Kocher's normal, 501  
   one half of the body, 496  
   V-shaped, 494  
 fibroma of the, 457  
 fissures of the, 438  
 geographical, 441  
 gumma of the, 449  
 hairy, 445  
 ichthyosis of the, 445  
 indentations of the, 438  
 inflammation of the, 440  
 keloid of the, 457  
 leucoma of the, 442  
 leucoplakia of the, 442  
 lipoma of the, 456  
 mucous patch of the, 447  
 nodules of the, 438  
 operation for removal of the, 493  
   anesthetic in, 494  
   excision of one half of the body in, 496  
   general preparation for, 493  
   local preparation for, 493
- Tongue, operation for removal of the—*cont'd*  
 intraoral, 494  
   position of the table in, 494  
   V-shaped, 494  
 papillomata of the, 460  
   treatment of, 461  
 psoriasis of the, 444  
 raw, 440  
 resection of the, at the root, Kocher's operation, 502  
 sarcoma of the, 462  
   treatment of, 463  
 smoker's patch of the, 443  
 smooth, 445  
 syphilis of the, 447  
 syphilitic fissures of the, 448  
 tertiary plaques of the, 448  
 -tie, 437  
 tubercular fissures of the, 446  
 ulcers of the, 446  
 tuberculosis of the, 446  
 tumors of the, 450-463  
   blood-vessels of the, 452  
   cartilaginous, 456  
 ulcers of the, 438  
   dentition, 440  
   traumatic, 439  
 warts of the, 460  
   treatment of, 461  
 Tonsil scissors, 171  
 Tonsillar abscess, 524  
   treatment of, 525  
 Tonsillitis, acute, 524  
 Tonsils, tumors of the, 532  
 Transfusion, blood, 55  
   for prevention of hemorrhage, 48  
   Hartwell's method of, 57  
   intravenous, 53  
   saline, 53  
   vein-to-vein, of Dorrance and Ginsburg, 55  
   selection of donor in, 55  
   technic of, 56  
 Transplantation, flap, operation on  
   oral scar bands by, 267  
   of bone or cartilage for obliquity of the chin, 248  
   of skin- or mucus-covered flaps, 217  
   after-treatment of, 222  
   blood supply of, 221  
   cheek flaps in, 219  
   neck flaps in, 219  
   preparation of margins of the defect in, 218  
   preservation of the epithelial lining of the mouth in, 218  
   preservation of the motor nerve in, 218  
   shoulder and chest flaps in, 221  
   of teeth, 81  
 Treatment of acute adenitis, 335  
 antral infection, 345  
 cellulitis, 336

Treatment—*cont'd*

- of adhesions of the velum, fauces, and pharyngeal wall, 528
- of affections of the facial nerve, 551
- of alveolar abscess, 319
- of avulsion of the teeth, 81
- of branchial fistula, 522
- of burns, 76
- of cancrum oris, 292
- of carcinoma, 366
  - of the servical lymphatics, secondary, 516
  - of the lip, 398
  - of the tongue, 483
- of cavernous angioma of the tongue, 454
- of chronic adenitis, 339
- antral infection, 346
- bone abscess, 326
  - by obliteration of cavity with bone plombe, 328
  - by obliteration of cavity with living tissue, 330
  - with Beck's bismuth paste, 328
- cellulitis, 340
- of cysts of the antrum, 350
  - of the thyroglossal tract, 459
- of diseases of the temporomandibular joint, 263
- of dislocation of the lower jaw, 119
- of effects of hemorrhage, 52
- of epulis, 352
- of facial tic, 556
- of fracture of the alveolar process, 82
  - of the lower jaw, 95
    - complicated by loss of bone, 112
    - feeding during, 114
    - individual, 109
    - of the teeth, 82
    - of the upper jaw, 84
- of gangrene, 291
- of impacted teeth, 282
  - indications for, 281
- of infections, 35
  - by antitoxins, 37
  - by cold, 36
  - by heat, 36
  - by hyperemia, 36
  - by surgery, 35
  - of bone, specific, 331
  - of the jaw-bones, 319
  - of the peridental tissues, 319
  - of the salivary glands, secondary, 411
  - of the teeth, 319
- of inflammations, 35
- of loosening of the teeth, 81
- of lymphangiomatous macroglossia, 451
- of malrelations of the jaws, orthodonture in, 236
- of mechanical abrasion of the teeth, 80

Treatment—*cont'd*

- of nasopharyngeal fibroma, 525
    - polypus, 525
  - of necrosis, 323
    - by removal of the sequestrum, 325
  - of noma, 292
  - of obstruction of the ducts of the salivary glands, 414
  - of odontoma, 358
  - of oral scar bands, operative, 267
  - of palate adenoma, 524
  - of papillomata of the tongue, 461
  - of paralytic affections, 548
  - of pericementitis, 322
  - of pyorrhea alveolaris, 323
  - of ranula, 402
  - of retraction of the gums, 321
  - of retromaxillary fibromata, 367
  - of retropharyngeal abscess, 527
  - of salivary calculi, 417
    - fistula, 420
  - of sarcoma, 361
    - of the tongue, 463
    - starvation, 362
  - of shock, 291
  - of sinus leading to a dermoid, 406
  - of slough, 291
  - of syphilis of bone, 332
  - of tic douloureux, 563
  - of tonsillar abscess, 525
  - of tubercular adenitis, 507
  - of tuberculosis of bone, 331
  - of tumors of the antrum, 350
    - of the thyroglossal tract, 459
  - of warts of the tongue, 461
  - of wounds, 74
- Trifacial nerve, affections of the, 549
- Tubercular adenitis, 506
  - diagnosis of, 507
  - radical operation for, 510
  - results of, 515
  - symptoms and course of, 506
  - treatment of, 507
- diseases of the cervical lymphatics, 506
  - fissures of the tongue, 446
  - ulcers of the tongue, 446
- Tuberculosis of bone, 316
  - treatment of, 331
  - of the lips, 386
  - of the mouth, 299
  - of the salivary glands, 412
  - of the tongue, 446
- Tumors, 40
  - as cause of failure of cleft closure, 135
  - benign, 40
  - classification of, 40
  - examination of, 2
  - malignant, 40
  - multilocular cystic, 363
  - of bone, 318



**Tumors—cont'd**

- of the antrum, 350
  - treatment of, 350
- of the jaw-bones, 351
- of the lip, 384
- of the mouth, 351
  - of the floor, 400
    - benign, 407
    - malignant, 407
- of the pharynx, 532
  - benign, 533
  - malignant, 536
  - vascular, 533
- of the salivary glands, 426
  - benign, 426
  - epithelial, 429
  - inflammatory, 411
  - mixed, 426
- of the thyroglossal tract, 457
  - near the foramen cecum, 457
  - perihyoid, 458
  - treatment of, 459
- of the tongue, 450-463
  - cartilaginous, 456
  - of blood vessels, 452
- of the tonsils, 532
- of the velum, 532
- retromaxillary, 366

**U**

- Ulceration of carcinoma of the tongue, 469, 471
- Ulcers, definition of, 32
  - examination of, 32
  - of the tongue, 438
    - dentition, 440
    - traumatic, 439
    - tubercular, 446
- Union, delayed, in fractures of the lower jaw, 113
  - time required for, in fractures of the lower jaw, 113
- Urine, suppression of, 65

**V**

- V-shaped operation for removal of the tongue, 494
- Vaccines, autogenous, method of preparing and administering, 37
  - combined, 38
  - standardized, 39
  - stock, 37
  - unstandardized, 39
- Vallecula, 520
- Varicella, 293
- Variola, 293
- Vascular tumors of the pharynx, 533
- Vasoconstrictor drugs in hemorrhage, 51
- Veins, bleeding, 49

- Vein-to-vein transfusion of Dorrance and Ginsburg, 55
  - selection of donor in, 55
  - technic of, 56
- Vela, artificial, 213
- Velum, fauces, and pharyngeal wall, adhesions of, 528
  - prognosis of, 530
  - treatment of, 529
  - tumors of the, 532
- Venous angioma, 435
- Verrucula, 445
- Vestibule of the mouth, anatomy of, 19
- Vincent's angina, 297
- Von Pirquet reaction, 300

**W**

- Warnikros obturator, 213
  - theory of relation of alveolar cleft to teeth, 130
- Warts of the lips, 389
  - of the tongue, 460
  - treatment of, 461
- Wharton's duct, cysts of, 402
- White operation for tubercular infection of the cervical lymphatics, 510
- Whitehead gag, 170
  - operation for excision of the tongue, 500
- Wine spots, 388
- Wiring bone for fracture of lower jaw, 99
  - jaw at or in front of second molar, 101
  - of the lower to the upper jaw, 96
- Wounds, 67
  - bacteria in, 70
  - contused, 76
  - drainage of, 71
  - extent and character of, 76
  - granulations in, 73
  - gun-shot, 68
  - healing of, 72
    - by first intention, 73
  - in salivary glands, 418
  - incised, 67
  - infection of, 69
  - location of foreign body in, by x-ray, 69
  - plastic operations in, 75
  - possible presence of foreign body in, 68
  - probability of sepsis in, 69
  - puncture, 67
  - scars after, 74
  - stab, 76
  - Staphylococcus albus in, 70
  - suturing of, 71, 75
  - tetanus in, 72
  - treatment of, 74


Wright, method of determining number of bacteria, 38  
Wyeth, method of obliterating angiomas, 388


## X


X-ray burns, 76


X-ray—*cont'd*

for locating foreign bodies in wounds, 69  
in antral infection, 344  
in diagnosis of fracture of the lower jaw, 94  
in treatment of carcinoma of the tongue, 483  
of keloid, 457









263888

MS  
B

Author Blair, Vilray Papin

Title Surgery and diseases of the mouth and jaws. Ed. 2

DATE.

NAME OF BORROWER.

**University of Toronto  
Library**

**DO NOT  
REMOVE  
THE  
CARD  
FROM  
THIS  
POCKET**

Acme Library Card Pocket  
Under Pat. "Ref. Index File"  
Made by LIBRARY BUREAU

