

EX LIBRIS

BIOLOGY
LIBRARY

6

THE
STATE
OF
NEW YORK
IN SENATE
JANUARY 18
1880
REPORT
OF THE
COMMISSIONERS
OF THE LAND OFFICE
IN ANSWER
TO A RESOLUTION
PASSED BY THE SENATE
MAY 18 1879
AND BY THE ASSEMBLY
MAY 18 1879
ALBANY: J. B. WHITTAKER, STATE PRINTER.
1880.

OXFORD MEDICAL PUBLICATIONS

THE MICROSCOPIC
ANATOMY OF THE TEETH

PUBLISHED BY THE JOINT COMMITTEE OF
HENRY FROWDE, HODDER & STOUGHTON
17, WARWICK SQUARE
LONDON, E.C. 4

OXFORD MEDICAL PUBLICATIONS

THE MICROSCOPIC
ANATOMY OF THE TEETH

BY

J. HOWARD MUMMERY

D.Sc. (PENN.), M.R.C.S., L.D.S. ENG.



LONDON

HENRY FROWDE

HODDER & STOUGHTON

OXFORD UNIVERSITY PRESS

WARWICK SQUARE, E.C.

1919

QL858

M9
BIOLOGY
LIBRARY
G

TO THE
LIBRARY

TO
SIR EDWARD SHARPEY SCHAFER, F.R.S.
IN ACKNOWLEDGEMENT OF MANY KIND SUGGESTIONS
AND IN REMEMBRANCE OF PAST ASSOCIATION
UNDER THE GENIAL INFLUENCE OF THAT
GREAT TEACHER OF PHYSIOLOGY
PROFESSOR WILLIAM SHARPEY

462588

‘ Science may appear to lose influence when the fallacy of a prevailing hypothesis is demonstrated ; but it holds a treasured reputation for honesty of purpose by frankly acknowledging and registering its mistakes.’—J. W. MELLOR.

‘ If a man will begin with certainties, he shall end in doubts ; but if he will be content to begin with doubts, he shall end in certainties.’—FRANCIS BACON.

PREFACE

IN the following pages I have endeavoured to bring up to date, as far as possible, our knowledge of the microscopic anatomy or histology of the teeth.

No doubt much remains obscure, and there are very many points which are still matters of controversy, but modern methods of research have done much to clear up a great deal of this obscurity, which must, however, always attend the study of such difficult tissues to investigate as the dentine and enamel of the teeth.

Sir Charles Tomes's *Dental Anatomy* is still the acknowledged and authoritative text-book for the wide field which it covers, and the present work is confined to dental histology, in which there are many points which have not been fully considered in recent English text-books on the subject.

In presenting the results of my own investigations, which have occupied me for many years, I hope I have adequately acknowledged the work of others on the same subject. It has been difficult during the last four strenuous years to obtain papers and communications from abroad, and if I have overlooked any important research I can only express my regret for any such omission.

It may perhaps be considered that I have hardly given sufficient space to the historical aspect of histological research, but I have avoided referring at great length to obsolete views and those now not generally received, in order that the student may obtain a clearer understanding of the present state of knowledge and of the different theories that chiefly hold their ground at the present day.

To the pioneers in dental histology, and in England especially to Sir John Tomes and Mr. James Salter, we owe a great debt of gratitude. These early investigators obtained

the most important results with the comparatively imperfect methods of research then at their disposal, and stimulated and guided the work of those who followed them, whose facilities with perfected modern methods have been very much greater; results which might never have been obtained had the way not been pointed out by their predecessors in the same field of knowledge.

I desire to most gratefully acknowledge my indebtedness to friends who have given me assistance in carrying out this work; especially to my friend Mr. Montagu Hopson, to whom I owe many valuable suggestions, and whose kind help in reading the proof-sheets and assisting in the compilation of the index has been of the greatest value.

I also wish to acknowledge my indebtedness to Professor Symington, F.R.S., for his kindness in supplying me with valuable material and permission to reproduce a photograph from the *Atlas of Skiagrams*; to Sir E. Sharpey Schafer, F.R.S., for the use of an illustration from the *Microscopic Anatomy*; to Sir E. Ray Lankester, F.R.S., for permission to reproduce a figure from the *Quarterly Journal of Microscopical Science*; to Professor Osborn for the use of two figures from his work on *The Evolution of the Mammalian Molar Teeth*; and to the publishers of Leduc's *Mechanism of Life* for permission to reproduce an illustration from that work.

To Mr. John Humphreys of Birmingham I am indebted for the loan of several important preparations from his valuable collection.

The illustrations, when not otherwise stated, are from my own photographs and preparations.

J. HOWARD MUMMERY.

TABLE OF CONTENTS

CHAPTER	PAGE
PREFACE	vii
INTRODUCTION	3
I. DEVELOPMENT OF THE TEETH IN MAMMALIA	13
Evolution of the Human Molar	32
II. ENAMEL	46
Tubular Enamel	84
The Enamel of Rodents	106
III. DEVELOPMENT AND CALCIFICATION OF THE ENAMEL	119
IV. THE DENTAL PULP	197
V. DENTINE	236
Development	262
Calcification	278
VI. CEMENT	287
Development	294
Calcification	298
Absorption	299
VII. THE PERIODONTAL MEMBRANE	305
The Gum	309
VIII. THE TOOTH FOLLICLE AND ITS CONNEXIONS	311
IX. NASMYTH'S MEMBRANE	333
Eruption of the Teeth	346
X. THE ATTACHMENT OF TEETH	352
XI. HORNY TEETH	366
INDEX	371

0

INTRODUCTION

IN a work on the microscopic anatomy of the teeth it may perhaps be considered necessary to define exactly what is meant by a tooth. This might seem at first sight an easy matter, but in formulating any exact definition we meet with many difficulties.

It may be said that if we except the bill of the bird, all horny or calcified organs which occupy the commencement of the alimentary canal may be looked upon as teeth, and that their primary function is prehension. But such a definition does not cover the whole ground, for some teeth never erupt, as the incisors of the female Narwhal; teeth are found in ovarian cysts, while the placoid scales of the Sharks are identical in structure with true teeth.

Although the bill of the bird does not appear to fall under the category of teeth, birds may be looked upon as modified reptiles, and there is little doubt that they are descended from forms which possessed true teeth, but these were lost before Tertiary times.

The fossil birds described by Marsh were furnished with teeth, and the Archæopteryx was a toothed animal with strong affinities to both birds and reptiles. Among recent birds Carl Röse has described the formation of a tooth-band in a tern (*Sterna Wilsoni*), although it is quite rudimentary, and no teeth are derived from it (6).

Although the primary function of teeth is prehension, they are also used in many instances as weapons of offence and defence, as the tusks of the Boar; and those that are developed exclusively in the male serve as sexual weapons. The enormous canines of the Walrus assist in locomotion and grasping, as well as in combat, and the greatly developed incisors forming the tusks of the Elephant are used in uprooting trees and carrying heavy weights, while the Beaver employs its sharp incisors in felling timber to form its dams. In the human being teeth serve as aids to speech.

These organs are variously adapted by their form and

structure to their several purposes ; the pointed, more or less conical teeth being employed for the seizure of prey, both the sharp pointed teeth of many fishes and the more powerful canines of Carnivora. The incisors are modified for dividing and tearing, and the molars both for this purpose, and also, in many animals, for the grinding and trituration of the food.

In all these modifications they are most perfectly adapted to their chief purpose, the seizure and preparation of the food.

As resisting power and a certain degree of hardness are essential to the functions performed by the teeth, they are usually calcified, that is, permeated by, or impregnated with, inorganic salts. Some teeth, however, persist throughout life as horny structures, produced from the stratum corneum of the oral epithelium, as the teeth of the Cyclostomata (*Petromyzon*, *Myxine*, and *Bdellostoma*) in fishes, and the adult structures in *Ornithorhynchus* which take the place of teeth, although more correctly described as horny plates.

While confined in the higher forms to the maxillary, premaxillary, and mandibular bones, teeth are found, especially in fish, in many other positions, as on the pre-mandibular, vomer, pterygoid, and pharyngeal bones, and upon the branchial arches. In many fish the whole mouth bristles with teeth, and they are even found upon the tongue in the parasitic *Myxine*. Horny structures are also present on the tongue of *Ornithorhynchus*.

Three chief tissues constitute the structure of the completed tooth : dentine, enamel, and cement.

The bulk of the tooth is made up of dentine, a hard calcified substance penetrated in different degrees by channels ; an exceedingly hard external layer, the enamel, is present in most teeth and covers the exposed surface of the crown and the roots, and in some instances the crowns of the tooth are coated with cement, which, as its name indicates, serves in many teeth to bind together the other two tissues, as shown in the Ungulates, where the cement in some forms in early stages a complete investment of the crown, and when subjected to wear, occupies the intervals

between the layers of enamel and dentine, and wearing down more rapidly than either of these, maintains a sharp cutting edge or surface to the tooth, as is most conspicuously seen in the Rodents.

The calcified portion of the tooth surrounds a cavity occupied by the pulp, which in a foundation of connective-tissue fibres supports the blood-vessels and nerves and the formative cells of the dentine, and persists during the life of the tooth.

The mammalian tooth is implanted in a socket within that portion of the bone of the jaw which is especially developed to receive it, named the alveolus. The tooth is attached within the socket by a fibrous membrane, the periodontal membrane or ligament, which is continuous with the periosteum of the alveolar bone on its outer aspect. All teeth are not, however, implanted in sockets, being in many animals attached by ankylosis, the tissue of the tooth merging into that of the bone; but, as shown by C. S. Tomes, this attachment in most cases is not direct to the bone of the jaw, but to a separate process of bone, the bone of attachment, which is analogous to the alveolar process of human teeth.

Various modifications of these modes of attachment are found in the animal kingdom, which will be considered in another place, and show a remarkable adaptation to the habits and mode of life of the different species. Especially with the class of fishes is this very noticeable, the varieties of adaptive modification being so numerous that a large number have probably not yet been described.

Teeth are called dermal appendages, and both in structure and development are closely related to the skin. This is especially well seen in the Sharks, where it is very evident that the teeth and the dermal spines are similar structures, the teeth passing by almost imperceptible gradations into the dermal spines and appendages of the skin. The close relation of the teeth and hair is another evidence of their dermal nature. In many instances this interdependence of the teeth and hair has been manifested; a great excess of hair being accompanied by abnormalities, diminution of number, or absence of teeth.

Teeth are developed from the mucous membrane of the mouth, and as stated by Beddard (2): 'Developmentally and histologically there are (in Mammalia) no fundamental divergencies from the teeth of Vertebrates lower in the scale. The teeth originate quite independently of the jaws with which they are, later, so intimately connected, the independence of origin being one of the facts upon which the current theory of the nature of teeth is founded. The scales of the Elasmobranch fishes consist of a cap of enamel upon a base of dentine, the former being derived from the epidermis and modelled upon a papilla of the dermis, whose cells secrete the dentine. The fact that similar structures arise within the mouth (i. e. the teeth) is explicable when it is remembered that the mouth itself is a late invagination from the outside of the body, and therefore the retention by its tissues of the capacity to produce such structures is not remarkable.'

To the comparative anatomist and anthropologist, teeth are of the greatest importance, as from their indestructible nature they have survived the vicissitudes of time and destructive agencies in the most remarkable manner. When found either alone or in association with remains of a more perishable nature, they have indicated by their form and structure the nature of the food and the habits and affinities of long extinct forms, and have served to forge the links of the evolutionary chain, from the remotest appearance of vertebrate life on the earth to the present time.

The varieties of combinations of the different tissues, the intricate patterns assumed in different teeth, and the differences in the intimate structure of the dentine and enamel, render the study of these organs throughout the animal kingdom a source of unflinching interest and of the greatest importance in all endeavours to obtain a better comprehension of the evolutionary development of organized beings.

They render it still more evident that, so far as the organic world is concerned, the doctrine of evolution as stated by Darwin rests upon a sure foundation. The survival of the fittest is a demonstrable fact, and the principal,

although, as Darwin himself said, not the sole agency by which this is brought about, is natural selection.

It should not, however, be forgotten that the great principle enunciated by Darwin which laid the foundation of the modern science of evolution was *descent with modification*. Darwin's theory is too often spoken of as the theory of natural selection, but this was only an explanation of the method by which he considered the change of one species into another was chiefly brought about. As stated by De Vries, 'The theory of descent remains unshaken even if our conception concerning the mode of descent prove to be in need of revision' (8).

The law of natural selection is founded on the fact that variations arise among groups of organisms, and those variations which are of advantage to the organism in the struggle for existence are perpetuated by heredity. Darwin states in the *Origin of Species* (3a), 'natural selection acts solely by accumulating slight, successive, favourable variations, it can produce no great and sudden modifications,' but Darwin considered that natural selection, while it has been the principal agent, has not been the sole influence in the evolution of species; he considered it was aided in an important manner by the inherited effect of the use and disuse of parts.

The discoveries of Mendel (5) have, however, of late years considerably modified several of Darwin's conclusions. These important discoveries were for a long time passed over in silence, but have lately obtained great prominence among evolutionists, and they explain much in the doctrine of heredity which has hitherto been obscure. Mendel's researches were repeated and confirmed by De Vries, Torrens, and Tschermak, and published by them in 1900.

Mendel's first series of experiments were made on the edible pea. A variety of this pea with tall stems was crossed with a short-stemmed variety. The next generation, F_1 , showed all long-stemmed plants, and this tallness he described as the 'Dominant' character. These tall plants, when self-fertilized, gave in the next generation, F_2 , both tall and short plants in a definite numerical relation to one another, this being in the ratio of, approximately, three tall to one short.

These short plants he called the *Recessives*.

The *recessives* when self-fertilized gave pure short plants, the short variety remaining pure in succeeding generations.

The *dominants*, however, continued to yield both pure tall plants and also mixed plants, showing in successive generations the same proportion of three tall to one short.

As stated by Bateson (1), 'the whole F_2 generation, therefore, formed by self-fertilization of the original hybrid, consists of three kinds of plants :

25 per cent.	50 per cent.	25 per cent.
pure dominants	impure dominants	pure recessives
}		
or	three dominants	to one recessive.'

It is thus seen that a permanent pure variety arises from the mixed variety, and in this instance a fixed law of variation is established.

Many experiments demonstrate that these laws are applicable to all living organisms, both vegetable and animal. As Bateson says: 'The fact of *segregation* was the great discovery which Mendel made—segregation being the dissociation of characters from each other in the course of the formation of the germ.'

Natural selection acts on variations, but how these variations occurred had always previously been an obscure and undetermined problem.

Mendel's researches have, to a great extent, contributed to the solution of this problem, and although much yet remains obscure, this discovery has given an impulse to the study of heredity which cannot fail to have the most far-reaching and important results.

As the author above referred to says: 'There is nothing in Mendelian discovery which runs counter to the cardinal doctrine that species have arisen by means of Natural Selection,' or 'the preservation of favoured races in the struggle for life', but, as he points out, the scope of natural selection is closely limited by the laws of variation, and Darwin would have welcomed the work of Mendel with delight, as explaining much which he himself felt to be obscure.

The bearing of these laws on the phenomena of colour variation has been studied in many plants and animals, and there is little doubt they will be of great value in the study of the heredity of disease as well. As to what influence these laws may have had on the evolution of the forms of teeth, we are quite without evidence.

Other factors have also to be considered, as sexual selection and concomitant variation.

Sexual selection is illustrated by the fact that those individuals among the males which possess certain physical advantages over their fellows, will be able to obtain the mastery in their fights for the possession of the females, as by the provision of stronger and better-developed horns or tusks ; and their superior physical development would be inherited.

Concomitant variation or correlation of growth is shown in the development of one organ at the expense of another—an animal with very large horns having suppressed canines, and one with greatly developed tusks showing absence or diminution of horns.

One illustration of the truth of the doctrine of evolution is the existence, in the course of development of the higher forms, of vestigial remains of organs constantly present in the adult forms of early progenitors, as instanced by Darwin in the teeth of Ungulates (3 *b*) :

‘The calf has inherited teeth, which never cut through the gums of the upper jaw, from an early progenitor having well-developed teeth ; and we may believe that the teeth in the mature animal were formerly reduced by disuse, owing to the tongue and palate, or lips, having become excellently fitted through natural selection to browse without their aid ; whereas in the calf the teeth have been left unaffected, and on the principle of inheritance at corresponding ages have been inherited from a remote period to the present day.

‘Disuse, aided sometimes by natural selection, will often have reduced organs when rendered useless under changed habits or conditions of life ; and we can understand on this view the existence of rudimentary organs.’

Darwin established the great principle of continuity

throughout the organic world, and as Professor Huxley says : 'The primordial germs of a man, a dog, a bird, a fish, a beetle, a snail, and a polype, are in no essential structural respects distinguishable. In this broad sense it may with truth be said that all living animals, and all those dead faunæ which geology reveals, are bound together by an all-pervading unity of organization.'

Especially since Darwin's time, the study of the cell and its relations to heredity has greatly occupied the attention of naturalists, and 'microscopic anatomy has shown us the nature of the material on which organic evolution has operated'.

We have to distinguish between the 'somatic' or body cells and the 'germ' cells.

The somatic cells build up the body of the individual, the germ cells are the racial cells, and the phenomena of heredity depend on their continuance from one generation to another. The germ cell, according to Weismann, is immortal; the somatic cell perishes with the individual body.

As Wilson says (9): 'The cell theory must be placed beside the evolution theory as one of the foundation stones of modern biology—these two great generalizations have been developed along widely different lines of research, and have only within a very recent period met upon a common ground.' The cell nucleus is shown to be the vehicle of inheritance, and, as this author further states, 'thus the wonderful truth became manifest that a single cell may contain within its microscopic compass the sum total of the heritage of the species. The death of the individual involves no breach of continuity in the series of cell divisions by which the life of the race flows onwards—the individual body dies, it is true, but the germ cells live on, carrying with them, as it were, the traditions of the race from which they have sprung, and handing them on to their descendants;—the body is merely the carrier of the germ cells which are held in trust for coming generations.'

Another question which has led to much controversy is whether characters acquired during the lifetime of the individual are capable of being transmitted to the offspring. This much-debated theory was formulated by Lamarck in

the early part of the nineteenth century, and Darwin, in order to account for the transmission of acquired characters, founded his theory of ' pangenesis ', by which he considered the germ cells were compounded of minute germs from every part of the body, and he thus accounted for the transmission of acquired as well as congenital variations ; but this theory has been abandoned by subsequent authorities.

The theory that characters acquired during the life of the individual are transmitted by heredity has met with very little acceptance in Great Britain or in Germany, but has many supporters in France and especially in America, where the school of neo-Lamarekians, supported by such eminent naturalists as Cope, Ryder, and Osborn, still maintains a prominent position.

Weismann, who was one of the chief opponents of this theory, considers that ' not one of the asserted cases of transmission of acquired characters will stand the test of rigid scientific scrutiny '.

' It is impossible ', he says, ' that acquired characters should be transmitted, for it is inconceivable that definite changes in the body or " soma " should so affect the protoplasm of the germ cells as to cause corresponding changes to appear in the offspring.'

But all these researches, which have so much occupied the attention of a host of investigators for the past fifty years, have not brought us any nearer to an understanding of the origin of life.

If we admit the possibility of spontaneous generation in the earliest conditions of the globe, we cannot form any conception of such a process—we fail to comprehend the energizing force which originated such beginning. If we study the production of the remarkable osmotic growths produced by Leduc and others from inorganic salts in a colloid, we cannot be sure that these curious forms, similar as they are to the products of living organisms, show anything but an analogy to, and are not identical with them.

If we accept Lord Kelvin's hypothesis, ' that life may be, and may have been, disseminated across the bounds of space throughout the solar system and the whole universe ' (7), this brings us no nearer to the origin of life, and we can

only say with Hutton, we find 'no vestige of a beginning, no prospect of an end'.¹

¹ For an interesting description of Arrhenius' view of the mode by which minute organic particles might be supposed to be disseminated into space from our atmosphere, see *Growth and Form*, by D'Arcy W. Thompson, pp. 48 and 49. It has, however, been suggested that the nature and intensity of the light outside our atmosphere would be rapidly destructive to all forms of life, and as Sir Ray Lankester says in a recent work (4): 'Hence Sir James Dewar argues that, whilst it would appear that the extreme cold of space would not kill a minute living germ and prevent it passing from planet to planet or from remotest space to our earth, yet one thing which is more abundant in space than within the shell of our atmosphere is absolutely destructive to such minute particles of living matter, even when hard frozen, and that is intense light, the ultra-visible vibrations of smallest wave length.'

REFERENCES

1. Bateson. *Mendel's Principles of Heredity*. Camb., 1909.
2. Beddard, F. E. *Camb. Nat. Hist.*, x, 43-4.
3. Darwin, C. (a) *Origin of Species*, p. 282; (b) *ibid.*, p. 292.
4. Lankester, E. R. *Diversions of a Naturalist*, p. 159.
5. Mendel, Gregor Johann. *Versuche über Pflanzen-Hybriden: Verh. Naturf. Ver. in Brünn*, Bd. 10, 1865. Translation in *Journal Roy. Horticult. Soc.*, 1901, xxv, xxvi.
6. Röse, C. 'Über die Zahnleiste und die Eischwiele der Sauropsiden.' *Anat. Anzeig.*, 1892, Nos. 23 and 24, p. 749.
7. Thompson, D'Arcy W. *Growth and Form*. Camb., 1917.
8. De Vries, Hugo. *Plant Breeding*, London, 1907, p. 3.
9. Wilson, E. B. *The Cell in Development and Inheritance*. London and New York, 1896.

CHAPTER I

DEVELOPMENT OF THE TEETH IN MAMMALIA

THE two principal tissues of the teeth are enamel and dentine, enamel being derived from the ectodermic epithelium of the mouth and dentine from the mesodermic submucous tissue.

The enamel organ is the first part of the tooth germ to appear, the dentine papilla arising later, although it is the first to show commencing calcification.

While, however, the appearance of an epithelial inflection is the most constant indication of tooth formation, it does not necessarily point to the future formation of enamel.

Epithelial
inflection

Tooth germs are developed, not upon the surface, but always at some little distance within the tissues, and in their simplest form consist of dentine and enamel only, but the future tooth is determined by the epithelial inflection rather than by the dentine germ, which is a subsequent production of the mesodermic tissue.

It is only in comparatively recent times that a clear understanding of the mode of development of the teeth has been arrived at.

The views held by Goodsir (7) were for long accepted as giving a true explanation of the process of tooth development, and were adopted by Professor Owen and many other eminent authorities.

Goodsir considered that the first indication of tooth formation was the appearance of a groove which he called 'the primitive dental groove', and that this was followed by a papillary stage, a follicular, and an eruptive stage. This primitive dental groove we now know was not a groove but a band. The epithelial band is formed from the cells of the deeper layer of the epithelium of the mouth, and is, by the proliferation of these cells, prolonged downwards into the mesodermic tissue as a continuous band, passing horizontally along the line of the future jawbones. The

Views of
Goodsir

separation of the cells of the mesoderm by the intrusion of the epithelial band forms a groove (the primitive dental groove of Goodsir), but it is not hollow, but filled with the cells of this epithelial band.

Goodsir's views were correct up to a certain point, but the methods of preparation then available did not enable him to appreciate the all-important part taken by the epithelial cells in this process, as these cells were washed out of the depression in the mesodermic tissue produced by the ingrowth of the epithelium, which then appeared as a hollow groove. As pointed out by Schafer (24), Kölliker showed the importance of the cells of the deeper layer of the epithelium of the mouth in the production of the primitive dental lamina from which the enamel organs of the teeth are developed, as although attention had already been drawn to this by Huxley (10) and Marcusen (17), it had not been generally accepted. In fact Huxley accepted the views of Goodsir, except with regard to the development of the teeth in fishes and reptiles, which he did not consider could be explained by this view.

The explanation of the mode of development of the teeth in the Mammalia, now generally accepted as the true one, is founded upon the researches of Kölliker (12), Leche (14), Röse, and many others, and has been demonstrated by Röse (19) in the series of illustrative models which he prepared.

There are certain differences in the development of the teeth in reptiles and fishes which will be considered elsewhere.

At about the thirty-fourth to the fortieth day of intra-uterine life, when the embryo is from 12 to 15 mm. long, before the commencement of ossification, the lower jaw being represented by Meckel's cartilage only, the first indication of tooth formation occurs.

This consists of an ingrowth of the deeper layers of the epithelium of the mouth, forming a band which follows the line of the future alveolar margin of the jaw. While it is usual to speak of an ingrowth of the epithelium, it is necessary to remember that in the embryonic jaw we are not looking at a completed tissue in which the only active

growth is that of the epithelial cells, but at a structure which is rapidly enlarging in every direction; upgrowth and downgrowth are proceeding at the same time, and the tissues of the embryonic jaw are increasing in thickness as well, so that the tissue near the surface becomes more deeply situated, owing to the increase of growth in all directions around it.

It is thus seen that the usual description of an ingrowth or downgrowth of the cells is not strictly correct, and it would be more accurate to speak of it as a proliferation of the deeper cells of the epithelium, which become deeply situated on account of the growth of the neighbouring mesodermic cells.

Really the whole surface of the epithelium is raised, and the general proliferation of cells being associated with the growth of the jaw tissues on every side, the parts are increased in size and not diminished, as might be suggested by the usual description. To avoid confusion, however, this proliferation of cells will be spoken of as an ingrowth or downgrowth.

In some mammalian germs, more especially in Ungulates, there is a more or less marked heaping up of the epithelium over the situation of the ingrowth. This ingrowth, the 'primitive dental lamina', divides (according to Röse on the forty-eighth day) into two separate bands lying rectangularly to one another, the one passing perpendicularly into the jaw (the labio-dental lamina), the other more or less horizontally backwards, constituting the true tooth-band or 'dental lamina'.

The labio-dental lamina is an ingrowth of the epithelium between the lip and the jaw, the cells of which atrophy and form an open groove extending along the developing jaw, between the tooth-band and the opening of the mouth in front, and the tooth-band and the buccal wall farther back. There is some difference of opinion with regard to the time and mode of differentiation of the labio-dental lamina and the dental lamina. These divisions of the primitive dental lamina arise, according to Röse, simultaneously. Baume (2) is of opinion that the dental lamina (or tooth-band) is differentiated from the previously formed labio-dental lamina,

while Leche (14) considers that the two laminae are formed simultaneously and independently.¹

Tooth-
band.

The dental lamina or tooth-band with which we are more immediately concerned does not pass quite horizontally into the jaw, but is curved, in the maxilla backwards and upwards, in the mandible backwards and downwards. Little thickenings or buds soon appear upon the dental lamina where teeth are to be formed; these thickenings, however, do not arise upon the free lower margin of the lamina, but on its labial aspect just short of that margin. The thickened portions grow down into the submucous tissue beneath, forming a cap over the mesodermic dental papilla, and form the enamel organs of the milk teeth (fig. 1).

In this figure the relations of the mesodermic dentine papilla with the epithelium are shown diagrammatically.

As the enamel organs are not given off from the free edge of the lamina, there is left a free growing edge above and behind the milk-tooth germs in the upper jaw, below and behind them in the lower jaw, and from this produced portion of the tooth-band the successional permanent teeth are developed.

These latter then are not produced from the neck of the enamel organ, as was formerly taught, but from the further growing margin of the parent tooth lamina. As the developing jaws continue to grow backwards, the portion of the dental lamina beyond the limits of the forming deciduous teeth is prolonged also in the same direction, and gives rise to the permanent molars. When further developed, the enamel organs become separated from the dental lamina, and are only attached to it by means of connecting bridges which undergo perforation and absorption, the further development of the tooth proceeding independently of the dental lamina. At birth the connecting bands between the milk incisors have nearly disappeared, while those between the first and second temporary molars are still uninterrupted.

¹ For the sake of clearness of description the nomenclature given by Professor Schafer (*Microscopic Anatomy*) is adopted. The primitive *Zahnleiste* is called the primitive dental lamina. The *Lippenfurche* of Röse is called the labio-dental lamina, and the *Zahnleiste* of Röse the dental lamina or tooth-band.

The breaking up of the dental lamina and the connecting bridges gives rise to little separated portions or islands of epithelium, the so-called 'glands of Serres' (20). As will be shown, however, in discussing the structure of the follicle (p. 311), the remains of the epithelial bridges or necks of the

Connect-
ing
bridges.

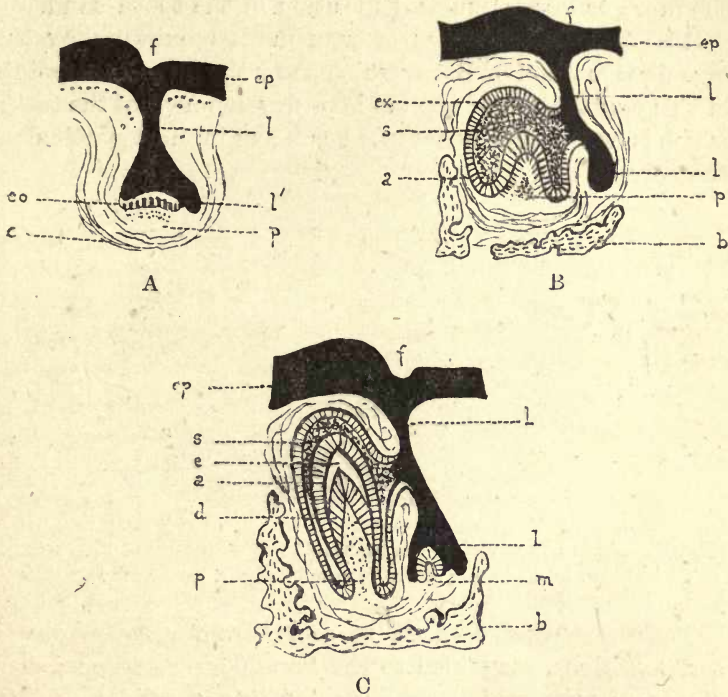


FIG. 1. Diagrams illustrating development of mammalian teeth (adapted from Gegenbaur). *ep.* Epithelium of mouth; *f.* furrow (not always present); *l.* dental lamina or tooth-band; *l'* its continuation to form the permanent tooth; *eo.* enamel organ cells; *ex.* epithelium; *s.* stellate reticulum; *e.* enamel; *a.* ameloblasts; *d.* dentine; *p.* papilla; *b.* bone; *m.* germ of permanent tooth; *c.* capsule.

enamel organ do not all atrophy—there is also a proliferation and further development of these cells which takes place within the connective tissue of the follicle.

On the surface of the epithelium of the jaw is a shallow groove, the 'tooth furrow', which marks the connexion of the tooth-band with the oral epithelium; this furrow runs

Tooth
furrow.

chiefly on the outer side of the wall of the jaw, but in the incisor region, on the top of the jaw wall. As Röse says : ' This tooth furrow (which, as already mentioned, indicates the line of demarcation of the tooth-band from the epithelium of the jaw) is in some places fairly deep, in others scarcely indicated, in places even, obviously double, according to the more or less irregular disposition of the tooth-band.'

Röse's
models.

Röse prepared a series of wax models built up by the ingenious method of Born, which show the important points in this explanation of the mode of development of the teeth, which is now generally accepted as being in most particulars the correct one.

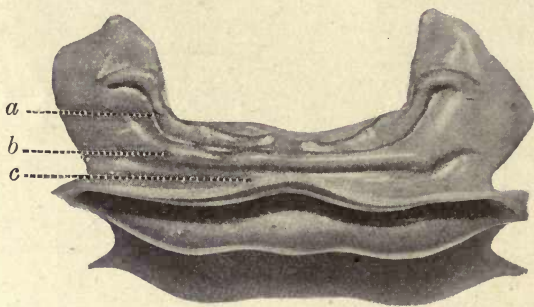


FIG. 2. From the model of the mandible of an embryo of nine weeks.
a. tooth-band ; *b.* lip furrow band ; *c.* lip furrow.

These models are made to scale, from photographs of serial sections, magnified to the same degree and copied on sheets of wax, which are moulded into a solid model by melting their edges.

Three of these models are figured in the accompanying illustrations, and a description of them may assist in obtaining a clear understanding of the most important points in mammalian tooth development.

Fig. 2 shows a photograph of the model of the epithelial surface of the mandible of an embryo of nine weeks, 2.5 cm. in length. The opening of the mouth is represented with part of the epithelium of the lip and of the mucous membrane of the mouth. The tooth-band is seen as a curved band directed backwards ; in the mandible at this stage it shows an undulating margin and enlargements at intervals,

the enlargements being the first indication of the separation }
of the original enamel organs.¹

Fig. 3 is a photograph of the model of the maxilla of an embryo, fourteen weeks old, $11\frac{1}{2}$ cm. in length. The epithelial structures only are seen, looking down upon the upper or cranial aspect of the epithelium of the mouth and into the hollow caps of the epithelial enamel organs, which are advancing in a vertical direction towards the observer,

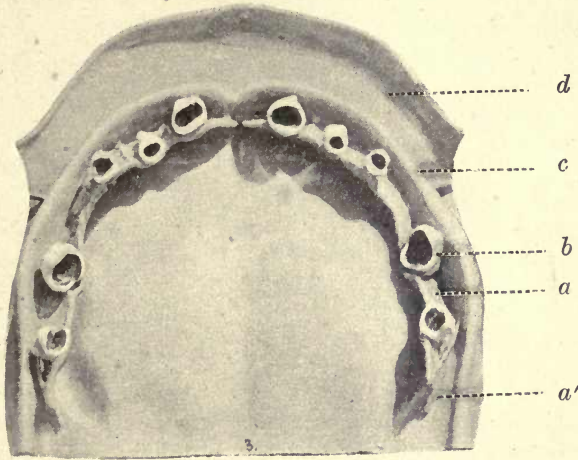


FIG. 3. From the model of the maxilla of an embryo of fourteen weeks. The epithelial structures viewed from above. The germs of the ten deciduous teeth are seen. *d*. lip furrow; *c*. lip furrow band; *b*. tooth germ; *a*. tooth-band; *a'*. prolongation of tooth-band to form permanent teeth.

the free margin of the tooth-band also advancing upwards behind and beyond the enamel organs.

These enamel germs have been aptly compared to swallows' nests attached to the flat surface of a board; they are seen to be attached to the labial surface of the tooth-band and not to its free growing margin. The mesodermic tissues are not represented in the model, being supposed to be stripped off from the epithelial structures.

¹ A set of these models is to be seen in the Odontological section of the Hunterian Museum of the Royal College of Surgeons. Details of the mode of production of the models are given in Röse's original paper (19) and in the author's communication to the Odontological Society's *Trans.*, May 1893.

Fig. 4 shows the left half of the mandible of a seventeen-weeks' embryo, 18 cm. long. The enamel organs of the five temporary teeth of that side are seen growing from the tooth-band, which shows indications of absorption between the germs. The prolongation of the tooth-band backwards, which gives origin to the first permanent molar, is very clearly seen. It is evidently not produced from the neck of the enamel organ of the temporary tooth, as formerly taught, but from a further backward growth of the original tooth-band.¹

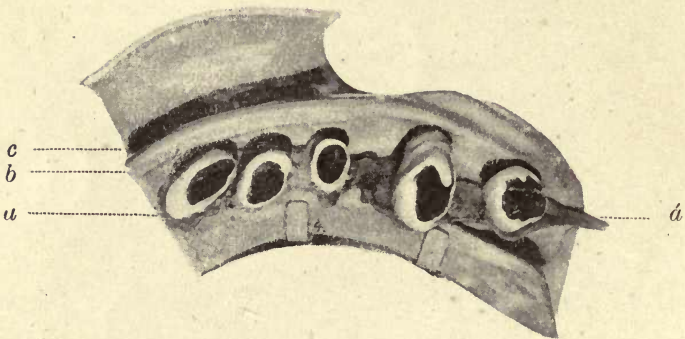


FIG. 4. Model of left half of mandible of a seventeen weeks' old foetus. *c.* lip furrow; *b.* lip furrow band; *a.* tooth-band; *a'.* prolongation of tooth-band to form first permanent molar.

From these models and the foregoing description, it can be easily understood that in the process of breaking up and absorption of the tooth-band between the forming enamel germs, remnants of this epithelial lamina may persist, and give rise to such irregularities as supernumerary teeth, odontomes, &c., other portions becoming degenerated and not absorbed, giving rise to such abnormal structures as cysts and epithelial pearls.

The question of the existence of pre-milk and post-permanent teeth is closely connected with this mode of development of the teeth.

Pre-milk teeth would be produced by buds given off from

¹ To understand clearly the relations of the parts in this model the page containing the illustration should be held above the head (the lower margin of the page forward), and viewed from below and from the front.

the tooth-band in front of the buds for the milk teeth. These have often been described in developing teeth, but are probably never calcified. Post-permanent teeth are considered to be due to the downgrowth of the persisting remains of the dental lamina or tooth-band, at the back of the jaw.

C. S. Tomes (27 *a*) says: 'A post-permanent set is represented in some animals by bands beyond the permanent tooth germs, but these never calcify,' and he further says that he 'regards both pre-milk and post-permanent rudiments as at best hypothetical, and the evidence insufficient to establish their existence'; but Marett Tims says: 'There is now less reason for hesitation in accepting the evidence of the pre-milk vestiges than was formerly the case. Doubt may still exist as to the value of the post-permanent downgrowths of the dental lamina.'

Post-permanent and pre-lactical germs.

In the further course of development, the successional permanent teeth grow more deeply into the jaw, ingrowing septa of bone separate them from the milk teeth, and they come to have an alveolus of their own.

Immediately following the formation of an enamel organ from the epithelial dental lamina, the dentine germ arises and is seen in the form of a papilla filling up the concavity of the enamel organ.

Dentine papilla.

As previously stated, the production of the dentine papilla seems to be determined by the formation of an enamel organ, and the dentine germ is not a true papilla, but a condensation and proliferation of the cells of the mesoderm in this situation, first appearing as an opacity in the sub-mucous tissue.

Leche holds that this may be due to the crowding of the cells by the surrounding growth of the epithelial cells of the enamel organ. Dursy (6) considers that this opacity forms a band extending all around the jaws, the prominences only arising where teeth are to be formed, and the intermediate portions of the opaque band becoming absorbed in the same manner as are the connecting bridges of the epithelial dental lamina.

The lower and lateral margins of the dentine germ are later prolonged upwards, surrounding the enamel organ and

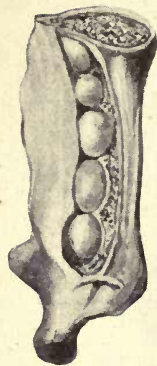


FIG. 5. Tooth-sacs at birth. Left side of mandible viewed from within. Drawn from a preparation by Professor Symington.

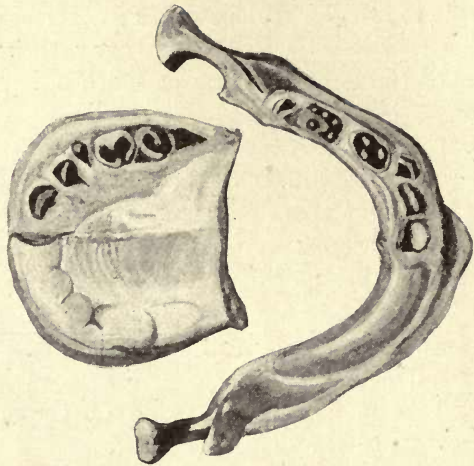


FIG. 7. The jaws at birth. Left side dissected to show stages of calcification of the temporary teeth. In this specimen the calcified point of the first permanent molar had not appeared. Drawn from a dissection by Professor Symington. Formol-preserved specimen.

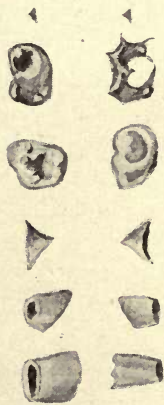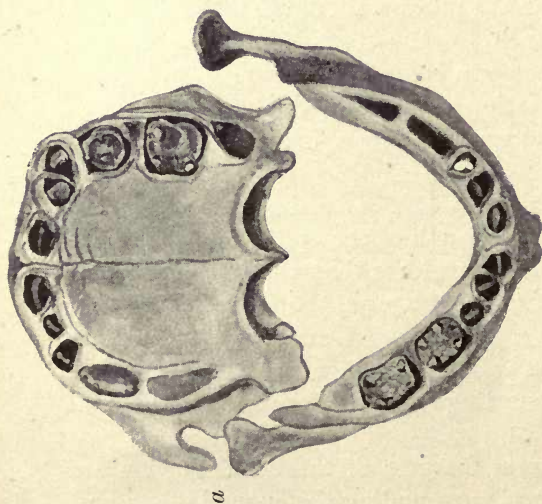


FIG. 6. *a*. Jaws at birth. Dry preparation by Professor Symington. The calcified band of the first permanent molar is seen in the crypt. *b*. Stages of calcification of the teeth at birth.

meeting over its upper surface. It thus becomes closed in by the mesodermic tissue, which forms the sac of the developing tooth.

The tooth-sac of the developing permanent tooth is closed in by a bony shell, except at its uppermost point, where it is pierced by a foramen which opens upon the gum behind the corresponding milk tooth. From the sac a fibrous band passes through this foramen and becomes blended with the gum behind the milk tooth. This band or cord is called the 'gubernaculum' or rudder, as it was supposed to guide or direct the course of the erupting tooth. There is, however, no distinct canal, but bands of connective-tissue fibres enclosing strands of epithelium.

Tooth-sac.

Gubernaculum.

Its position is marked by the foramina, which are seen in the bone immediately behind each of the temporary teeth. Malassez (16), in a paper 'On the Structure of the Gubernaculum dentis', says: 'The teeth of replacement are contained in a bony cavity which is prolonged in the form of a canal to the alveolar border, where it opens at the inner side of the milk tooth. The dental follicle prolongs into the canal a kind of cord which continues until lost in the fibrous tissue of the gingival margin.' It was considered by Delabarre (5) and Serres (20) to be hollow and to guide the tooth in eruption. Sappey (21) said it contained 'the last remnants of the epithelial proliferations'. Malassez considers there is no part of the gubernaculum in which a canal exists, but it is made up of connective-tissue fibres, mostly arranged longitudinally, but the point to which he would draw particular attention is that the connective tissue encloses numerous epithelial strands. In the deep part the epithelial elements are more abundant and form a 'rich network' and 'lateral buds in the form of clubs' are to be seen. 'In the most superficial part of the gubernaculum they are, on the contrary, less numerous, less rectilinear, and more rarely anastomosed.' He also says that these tracts of epithelium can be seen to proceed from the 'corresponding enamel cord of the enamel organ', which he considers not only persists, but 'even proliferates with great activity in the neighbourhood of the tooth of replacement', and his conclusion is that 'this fact leads us to surmise

that the epithelial masses play a certain rôle in the eruption of the corresponding tooth'.

These observations will be further considered in treating of the dental follicle (see p. 317), but Warwick James (11) has lately expounded a similar view in connexion with the eruption of the temporary teeth. He considers that the epithelium 'directs the tooth to its position in the gum', and that the 'path of eruption is prepared by the epithelium'. The principal agents in providing this path are the 'epithelial coils' or 'globes épidermiques', which, by opening out and disrupting, form spaces in the connective tissue of the follicle in the course of the erupting tooth. The epithelial coils will be further considered in another place (p. 312).

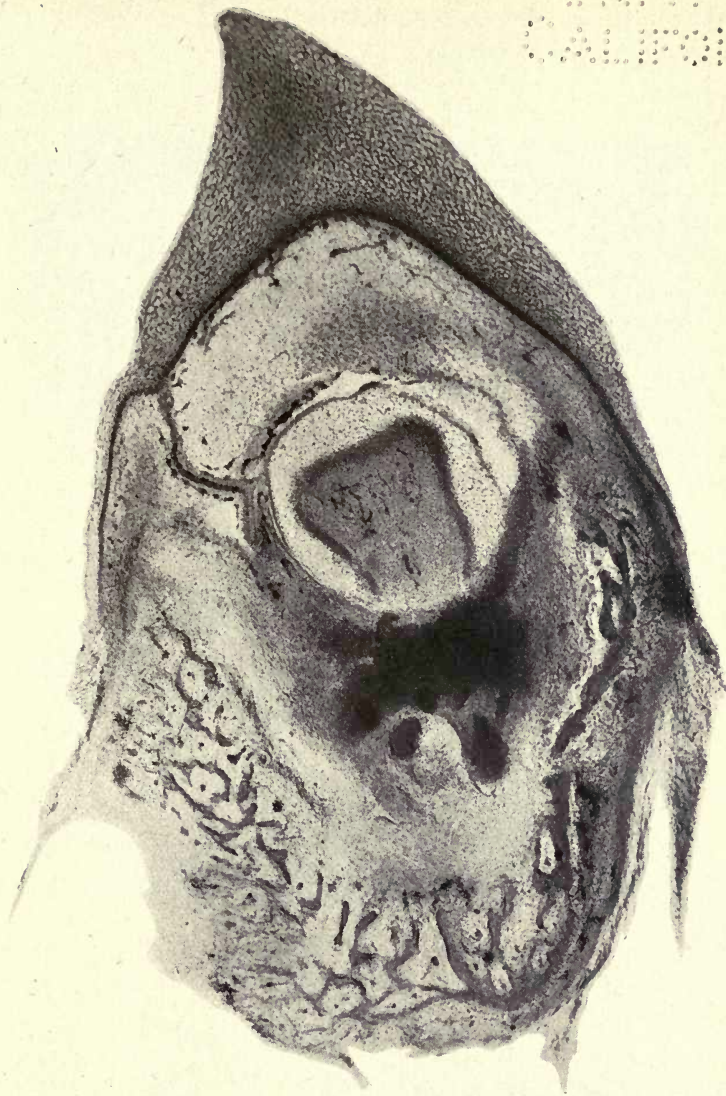
Epithelial
coils.

The tooth-sacs, shown in fig. 5 as they appear at birth, consist of an outer and an inner coat, the outer connected with the periosteum, and the inner coat richly supplied with blood-vessels and separated from the outer by a thin layer of jelly-like connective tissue. The extreme vascularity of the inner coat 'doubtless has relation to the nutrition of the enamel organ' (Schafer).

From the tooth-sac, which is seen to take its origin from the tissue of the mesoderm, the cement and periodontal membrane are formed, and in those animals which possess coronal cement, an investing cap of cement also.

Fig. 5, drawn by the author from a preparation by Professor Symington, shows the tooth-sacs in the left half of the mandible at birth, and in figs. 6 and 7 are shown the stages of calcification of the milk teeth at birth. It is seen that the calcified cusps of the molars have become fused together, and the calcification of the first permanent molar appears as a tiny triangle in its crypt.

Fig. 8, a skiagram from Professor Symington's atlas (23), shows very distinctly the stages of calcification at the period of birth. The crypts of the teeth are seen and the fusion of the calcifying cusps of the temporary molars is well shown, also the single calcified point of one cusp of the first permanent molar. As pointed out by Professor Symington, there is no important difference between this specimen (one month old) and that of the newly-born



Germ of Human Temporary Molar in the crypt. The extension of the tooth band for the formation of the permanent tooth is seen on the left. $\times 50$.

1880
1881
1882
1883
1884
1885
1886
1887
1888
1889
1890
1891
1892
1893
1894
1895
1896
1897
1898
1899
1900

THE UNIVERSITY OF CHICAGO
LIBRARY

infant, but the calcification, being slightly further advanced, gives a better image on the photographic plate, and has therefore been chosen as an illustration.

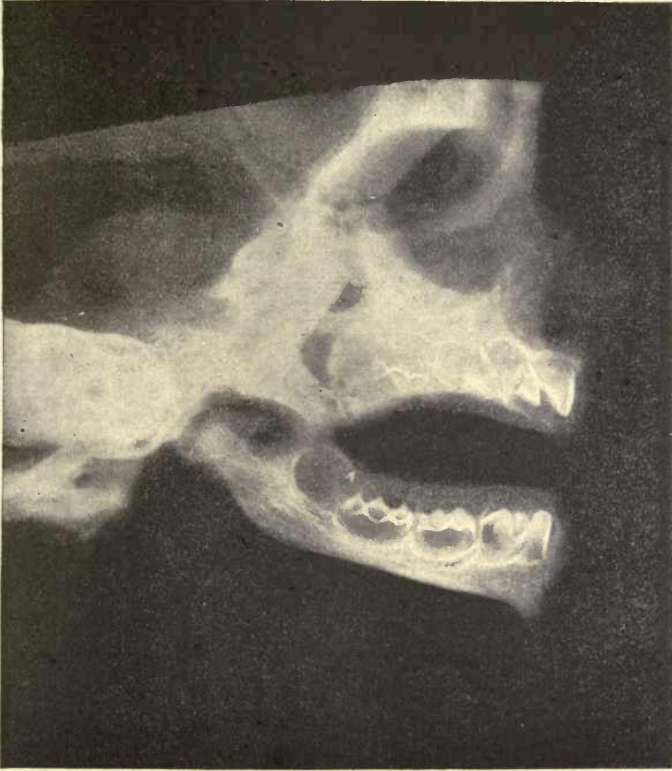

FIG. 8. Right side of jaws of male infant one month old. First molar more calcified than second molar. Independent deposits on the second molar are well shown; they become gradually united by extension of the calcification. A single calcified tip of one cusp of the first permanent molar only is seen. There is no important difference between this stage and the condition at birth. From Symington and Rankin's *Atlas of Skiagrams*.

The first indication of tooth formation is the differentiation of a band of epithelial tissue just beneath the surface of the forming jaw: this is the *primitive dental lamina*. Summary.

The primitive dental lamina separates at an early stage into two laminae at right angles, or nearly so, to one another

—the vertically directed *labio-dental lamina* and the horizontally placed *dental lamina or tooth-band*.

Prominences arise on the tooth-band, near to, but not at the margin of the lamina, on its labial aspect. These prominences become the enamel organs of the milk teeth. The free margin of the lamina behind these germs gives rise to the successional permanent teeth, the permanent molars being formed from that portion of the lamina which grows backwards beyond the limits of the milk dentition.

The germs of the teeth become separated and detached from the lamina by the absorption of the connecting bridges.

Each dentine germ or papilla is formed beneath the cap of the enamel organ, and is produced in the mesodermic tissue, which, according to Dursy, is differentiated as a continuous opaque band round the jaws, corresponding to the epithelial dental lamina from which the enamel is formed.

These papillæ appear in the band in the positions corresponding to those of the future teeth, while the intermediate portions become atrophied and disappear like the bridges of the epithelial lamina.

The margins of the dentine germ are described as growing up and around the epithelial enamel organ, forming the tooth-sac from which the cement and periodontal membrane are produced. It is doubtful if this is a correct description, and this enclosure of the enamel germ may with more probability be considered to be due to the condensation and proliferation of the surrounding connective tissue.

The histology of the enamel and dentine organs and the tooth follicle will be described in another chapter.

The accompanying table carries the development of the teeth up to the time of birth. The eruption of the permanent teeth will be better considered in works on dental anatomy; no work on the histology of the teeth would, however, be complete without some account of the development of these organs.

In fig. 9 is shown the tooth germs in their crypts in the upper jaw of a foetal pig, and in fig. 10 a more advanced germ from the pig in which the calcification of the dentine and enamel is further advanced.

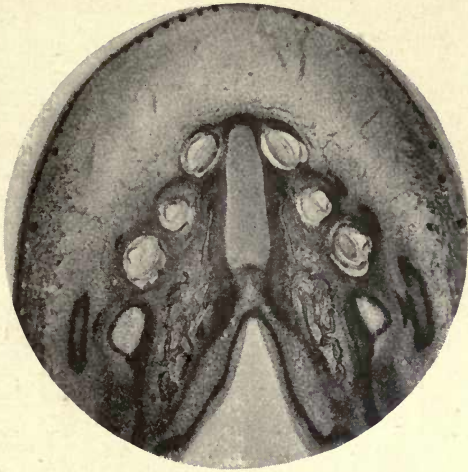

FIG. 9. Upper jaw of pig. The developing teeth *in situ*.

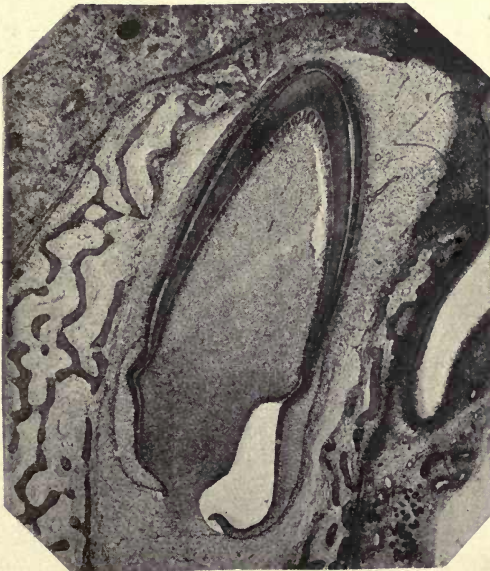

FIG. 10. Tooth germ of pig within the crypt.

TABLE OF THE DATES OF APPEARANCE OF THE SEVERAL STRUCTURES IN HUMAN EMBRYOS (ADAPTED FROM ROSE AND C. S. TOMES).

<i>Length of Embryo.</i>	<i>Age.</i>	<i>From the first appearance of the primitive dental lamina to the time of birth.</i>
12 15 mm.	30 to 40 days.	First appearance of the epithelial inflection forming the primitive dental lamina. First traces of Meckel's cartilage, but no bone formed.
17 mm.	48 days.	The primitive dental lamina has divided according to Rösse into the lip furrow band and the dental lamina or tooth-band. The deepest layer of the epithelium has become columnar and the first traces of bone appear.
2.5 cm. 3.2 cm.	9 weeks. 10 weeks.	Tooth-band shows alternate enlargements and depressions (fig. 2). Club-like enlargements beginning to surround dentine papilla.
4 cm.	11½ weeks.	Eight papillae are present. Ten papillae in each jaw. Lip furrow deepened from disappearance of epithelial cells which filled it.
11½ cm.	14 weeks.	Milk-tooth germs seen like swallows' nests against tooth-band, from which they are partly pinched off. First appearance of stellate reticulum. Tooth-band prolonged backwards into the mesoderm behind the last milk molar having yet no vertical connexion with the surface epithelium (fig. 3).

Fœtus.	Age.		Deciduous Teeth.				Permanent Teeth.								
	Length.	Weeks.	I_1	I_2	C	M_1	M_2	I_1	I_2	C	Pm_1	Pm_2	M_1	M_2	M_3
18 cm.	17	The necks of the enamel organs are reduced in size. Tooth-band fenestrated. Dental furrow found in front of mouth (fig. 4).	First traces of calcification.	Trace of calcification.	Trace of calcification.	Necks of the enamel organ still broad.									
24 cm.	20					Dental furrow extends to back of mouth.							Trace of tooth-sac.		
30 cm.	24					Trace of calcification.				First trace of papilla.			Enamel germ fully developed.		
36 cm.	29					Calcification on each cusp, but they are not united.				Trace of tooth-sacs.					
40 cm.	33					Cusps are united.								Trace of enamel germ.	No calcification yet.

At birth the sacs of the first permanent molars and those of all the temporary teeth are fully formed (fig. 5), the crowns of the temporary incisors are calcified, and the tip of the canine and the separately formed cusps of the two temporary molars are united. One cusp of the first permanent molar is calcified and seen as a minute triangle (figs. 6 and 7).

Tooth Development in Reptiles and Fish

In Reptiles the new tooth germs are, without doubt, developed from the tooth-band as in Mammalia, the successional teeth being given off from the continued ingrowth of this band. In the osseous fish, where it is difficult to trace the connexion of the germs with the tooth-band, it has been considered that these germs may arise independently, and Heincke has stated that new enamel organs may be derived from older ones; but this hardly seems consistent with the received views of tooth development in the Vertebrata, new teeth being derived, not from the enamel organ of a previously formed tooth, but from the extension beyond the tooth of the tooth-band or dental lamina. In Elasmobranch fishes the connexion of the newly-formed teeth with a common tooth-band is very evident. As C. S. Tomes says (27), in the osseous fish 'no obvious connexion between the germs of teeth of different ages is seen', and it appears much more probable that his explanation is the correct one where he says 'it is likely that the germs so soon become detached that their origin from a common tooth-band is masked'.

Röse considers that in all the lower Vertebrates up to the Urodelaë (frogs, newts, &c.), the earliest tooth germ appears as an upstanding papilla of the mucous membrane of the mouth (beneath the epithelium), raised above the surface of the surrounding mesodermic tissue.

Leche denies the existence of an upstanding papilla in the tooth germs of the osseous fish, but Röse considers that it is easily overlooked in the very minute enamel organs of fish embryos, as he has found it in all the osseous fish which he has examined, as well as in reptiles. This author considers that this indicates the origin of the jaw teeth from

calcified skin scales—the placoid scales of Elasmobranch fish described by Hertwig (see p. 177).

By the placoid stage of tooth development, Röse understands the condition in which the earliest tooth germs in the region of the mucous membrane of the jaws develop and proliferate over the deeper lying cells, as do the placoid scales of the Sharks or the papillæ of the skin in Mammalia.

Placoid
stage.

The epithelium of the jaw is somewhat thickened in places, and beneath these thickenings the round cells of the connective tissue have accumulated.

In distinct circumscribed areas the growth of the epithelium is more pronounced, and the papillæ of the placoid germs are seen as lenticular epithelial growths. As in Mammalia, the epithelial tissue is the true form-determining element of the tooth germ.

He affirms that in *Lepidosteus* and the Salmonidæ the earliest placoid germs by further growth sink deeper and deeper into the connective tissue of the jaw, and exhibit an intermediate stage between the placoid and the mammalian form of tooth development.

In this, which he calls the conical stage, the whole mucous membrane of the jaw is concerned, and its epithelial layer contributes for each tooth germ a definite epithelial process, which in the later-formed teeth dips deeply into the mucous membrane, as do the epithelial sheaths of the hair follicles. Röse (19 c, d) would thus describe three stages in tooth development :

Conical
stage.

1. The placoid stage. In this, the germs are seen as upstanding papillæ of the mucous membrane beneath definite thickenings of the epithelial cells which invest them.

2. A second or conical stage in which the germs sink deeply into the mucous membrane enclosed by a distinct epithelial sheath, as seen in the human hair follicle, and the whole surface of the mucous membrane of the jaw is concerned in tooth formation.

3. The tooth-band stage, as seen in Mammalia, where the epithelial germs are given off from a definite tooth-band, and it is this differentiated portion of the epithelium only which is concerned in tooth formation.

The Evolution of the Human Molar

Teeth, being often the only perfectly preserved remains of early ancestors of the Mammalia, are of very great importance in the study of the evolution of the various existing forms, and many different views have been held as to the mode in which the highly complicated molars of existing mammals have been evolved from simpler types.

Although this is a subject which comes more appropriately under the heading of Dental Anatomy, recent researches on certain structures in the enamel organ of Mammalia, which have a strong bearing on the development and evolution of the different forms of teeth, render it necessary to review, however briefly, the principal theories which have been brought forward to account for the origin of these different forms.

Heterodont
and *homodont*.

When teeth are similar in form and size throughout the series, as in the Dolphin, the dentition is spoken of as *homodont*; when, on the other hand, they vary in different parts of the mouth it is described as *heterodont*.

Mono-phyodont
and *diphyodont*.

It was stated by Owen that homodont animals usually have but one set of teeth, or are *monophyodont*. Heterodonts possess two sets of teeth, constituting a permanent and a milk dentition, and are spoken of as *diphyodont*.

There are exceptions to this rule, however, and it was shown by C. S. Tomes (27 *b*) that in the Armadillo (*Tatusia peba*), with a homodont dentition, there are both milk and permanent teeth; it is truly diphyodont, and in many homodont animals traces of a milk dentition have been found, and, as stated by Marett Tims, there are very few animals which can be considered to be truly monophyodont, modern methods of research having shown that in most cases hitherto regarded as monophyodont, functionless representatives of other dentitions are to be found, and the term can only be consistently retained to describe a single *functional* dentition as in the toothed whales.

Fish and reptiles are *polyphyodont*, having a continuous succession of teeth, but in mammals never more than two sets of teeth are developed, although in them also vestiges of additional series have been described by Leche and others.

FIG. A.

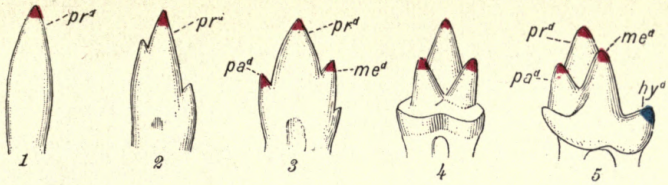


FIG. B.

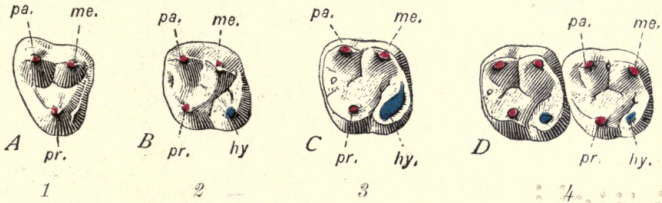
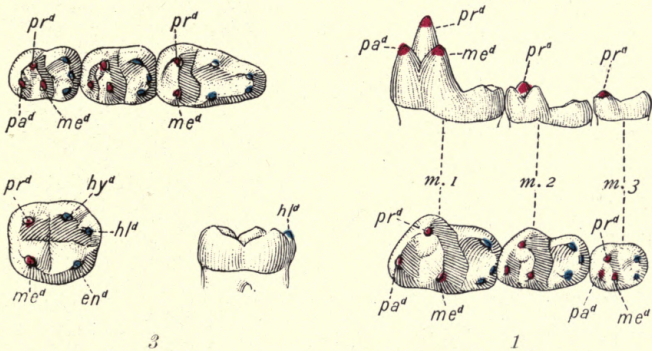


FIG. C.



EVOLUTION OF THE CUSPS OF THE HUMAN MOLARS. (From Osborn.)

FIG. A.—Evolution of lower molar cusps. 1. Simple conical reptilian tooth. 2. Dromotherium. 3. Microconodon. 4. Spalacotherium. 5. Amphitherium.

FIG. B.—Evolution of upper molar cusps. 1. Anaptomorphus. 2. An upper Eocene Monkey. 3. Esquimo. 4. Negro. (See addition of "talon" hy , to "trigon," composed of pa , pr , me .)

FIG. C.—Lower molar cusps. 1. In Miacis. 2. Anaptomorphus. 3. Homo. (The cusps of the trigon and trigonid are coloured red, those of the talon and talonid are coloured blue.)

State of
California

Reptiles have usually teeth of a simple conical form, while the Mammalia have multicuspidate teeth, and different views have been held as to the manner in which the cusps of the higher forms have been evolved.

According to one view, first formulated by Ameghino (1) and strongly supported by Kükenthal (13) and Röse (9), the multiple cusped teeth of Mammalia have been produced by the union or *concrecence* of single conical teeth united to form a single tooth, made up of these separate elements, each cusp of a compound tooth corresponding to the single conical reptilian tooth. Con-
crecence
theory.

This union of the conical teeth might take place either in the antero-posterior (mesio-distal) direction by the union of teeth of the same series, thus shortening the jaw, or in the transverse or bucco-lingual direction, as suggested by Kükenthal, by the union of the teeth of different series. This has been called the *concrecence theory*.

The basal ridge or *cingulum* is a ridge which surrounds the tooth at the neck, and is considered by many to play a very important part in the production of cusps. Speaking of this structure, Osborn (8) says: 'By its disappearance in some regions and by its elevation into prominences in others, the form of a tooth may be profoundly modified, and it thus comes to be regarded as a sort of mother of cusps.' As shown by C. S. Tomes (27), the cingulum is well developed in most of the Insectivora, where the crowns 'often bristle with sharp points', which are produced by the elevation of the cingulum, and these points often exceed in length the principal cusps of the tooth. Marett Tims considers that the development of cusps from the cingulum explains to a great extent the evolution of complex tooth forms. It would certainly appear that accessory cusps arise from the cingulum. *Cingulum.*

The Tritubercular Theory

Professor Cope (4) in 1879 discovered a large series of fossil mammals in deposits of the Tertiary Age at Puerco Cañon in New Mexico. These small animals showed a general similarity of form in the molar teeth, even in those of apparently different habits. These teeth are made up of 'three main tubercles on the crowns of both upper and

lower molars, disposed in triangles'. He concluded that 'this tritubercular type was ancestral to many if not all of the higher types of molar teeth', and considered that it arose from a single conical type or reptilian form of tooth by the addition of added denticles.

It is seen that the concrescence theory also derives the molar teeth from a single reptilian cone, but in a different manner, the supporters of this theory considering that by a shortening of the jaw the multiple conical teeth of the reptiles underwent a clustering or concrescence, forming multicuspidate teeth, and that tritubercular teeth were not the earliest type derived from the single reptilian cone. They thus consider that a molar tooth with numerous tubercles was the more primitive form.

According to the tritubercular theory, the primitive form from which the mammalian molar arose was a single cusp, and additional cusps have been successively added to this.

The tooth with a single conical crown has not hitherto been found in any known ancestor of the Mammalia, but is described as the *haplodont* type (Plate II, fig. A₁).

A single main cone, however, furnished with two small accessory cusps, occurs in the fossil *Dromotherium* (fig. A₂), and is described as the *protodont* type. A central cone with two well-developed accessory cusps gives the *triconodont* type.

Cusps of
the tritu-
bercular
tooth.

This form is represented in the extinct *Triconodon* (fig. A₃), and from this we pass to the tritubercular type (fig. A₄), in which there is a triangular crown with three main cusps, called respectively the *protocone*, *paracone*, and *metacone*, the protocone being internal in upper molars, external in lower molars. The corresponding cusps in the lower jaw are distinguished by the affix -id, being called protoconid, paraconid, and metaconid respectively.

Trigon
and talon.

According to Cope and Osborn (18) the molar is made up of the primitive triangle or *trigon* and the added 'heel' or *talon* (fig. A₅).

The trigon or primitive triangle is the sectorial or tearing element of the mammalian tooth; the talon, the crushing or masticating element.

Upper Molars. According to Osborn, in the early lemurs

and monkeys the upper teeth were, almost without exception, triangular. In the late Eocene or early Miocene Age, the spur or talon was developed, and the triangular became a quadricuspidate tooth.

In Plate II, fig. B, which is also adapted from Osborn, the cusps of the trigon are coloured red, and those of the talon blue. In *Anaptomorphus* (fig. B₁), a lower Eocene form allied to *Tarsius*, a lemurine animal, the trigon only is present, the protocone being internal and the paracone and metacone, forming the base of the triangle, external.

In fig. B₂, a molar of an upper Eocene monkey, in addition to the trigon a cusp has appeared, the *hypocone*, from an upgrowth of the cingulum, and forms the talon of the upper molars.

In fig. B₃, the molar of an Eskimo, the hypocone is very fully developed, as, owing to the nature of the food of these people, the teeth are very little used in mastication.

Fig. B₄, from a negro, shows the cusps of the trigon and talon as seen in the normal human upper molar tooth.

It is thus seen that the four upper molar cusps represent the three cusps of the original tritubercular tooth (the trigon) and one cusp of the added talon, the hypocone.

Upper Molars.

Anterior palatal	Protocone	} Primitive triangle or Trigon.
Anterior buccal	Paracone	
Posterior buccal	Metacone	
Posterior palatal	Hypocone	Primitive heel or Talon.

Lower Molars. Although in the early ancestors of man the three elements of the trigon were represented (fig. 10), in the lower molars of human teeth the paraconid is suppressed, and only the protoconid and metaconid of the original triangle remain, the three other cusps of the quinquecuspidate lower molar being formed by the talonid. The suppression of the paraconid is considered to be due to the antagonism of the upper and lower molars not allowing of its persistence in man. In *Miacis*, a form from the lower Eocene (Plate II, fig. C₁), the trigonid is seen in all the three molars, and, according to Osborn, shows 'how the primitive anterior portion (trigonid) of the crown was reduced to the

level of the posterior portion (talonid) while retaining all of its (three) cusps'. Fig. C₂ shows the arrangement of the cusps in *Anaptomorphus*, the oldest lemur known, the cusps coloured red representing the fully developed trigonid in the first and second molars, but in the third molar the paraconid has disappeared. In this animal we have a six-cusped tooth representing, in the first and second molars, the three cusps of the trigonid and the three of the talonid. In the third molar the six cusps are made up of two of the trigonid and four of the talonid.

In man the trigonid is represented by the protoconid and metaconid only, the paraconid being suppressed, and the five cusps are made up of these and three cusps of the talonid—the *hypoconid*, *entoconid*, and *hypoconulid* (fig. C₃).

Lower Molars.

Anterior buccal	Protoconid	}	Primitive triangle or Trigonid.
Anterior lingual	Metaconid		
Posterior buccal	Hypoconid	}	Primitive heel or Talonid.
Posterior lingual	Entoconid		
Posterior mesial	Hypoconulid		

Origin of
premolars.

Scott (22) claims that the premolars have arisen by a different process from the molars, and considers that the internal cusps of these have arisen from the cingulum. Cope considers that this may show 'the origin of two identical structures by different evolutionary routes'.

Polybunary.

Among the many critics of the tritubercular theory, Forsyth Major (15) considers that the advocates of trituberculism have failed to show that the mammalian molar can be traced back to a more and more simple form, and is of opinion that it can be traced to a *polybunous* or multituberculate form, and that the real tritubercular pattern is a more specialized secondary stage. He states that in the lower Eocene strata, multitubercular teeth are found side by side with the simpler forms. He would, therefore, consider that the tritubercular teeth are reduced and modified forms of earlier multitubercular molars.

Ameghino considers the tritubercular form to be 'the result of the simplification of molars which were formerly more complicated'.

Osborn, in reply to this criticism, says: 'The further we go back among the ancestors of the Multituberculates and Rodents, the less polybucic and more tritubercular they appear.' He holds that the multituberculate tooth is of tritubercular origin.

Leche (14), Taeker (25), and Röse, from the study of development in the embryo, agree in stating that in marsupials, ungulates, and man the first cusp to develop is the paracone and not the protocone. M. F. Woodward (28) also confirms this observation, and says that the paracone is identical with the primitive dental germ, and the protocone is an internal ledge growing out from its base, and concludes that the paracone in *upper molars* corresponds to the primitive reptilian cone. In the lower teeth, however, the successional development corresponds with the order of the cusps in the trigonid of the lower molar.

Marett Tims (26), working on the embryology of the dog, comes to similar conclusions—considering its molar to consist of a primary cone, the paracone, a secondary cone, the metacone, and three cusps derived from the cingulum, which he considers plays a very important part in the development of the mammalian molar.

Smith Woodward (29), speaking of primitive trituberculy, says 'this—at first sight—brilliant generalization can only be accepted as a convenient working hypothesis which remains on its trial', and Gidley (8) concludes that 'no theory involving an absolute uniformity of succession in the development of complex molars will hold true for all groups of animals'. He considers, however, that the nomenclature proposed by Osborn is very convenient for description, and saves much confusion which would be brought about by any change in the descriptive terms used. While there have been a great many criticisms of the tritubercular theory, it has been very ably and impartially stated by Osborn, who acknowledges many difficulties in the acceptance of the theory in its entirety.

The most recent investigation of the evolution of the mammalian molar is that by Professor Bolk of Amsterdam (3). In discussing the views of this author we have to distinguish between the fusion of teeth in an antero-

Bolk's
researches.

posterior (mesio-distal) direction, which would be a fusion of teeth of the same series, and fusion in a transverse or bucco-lingual direction, which would mean the fusion of teeth of different series. Professor Bolk, in his first paper (3 a) on the relationship of the mammalian dentition to that of the reptiles, considers that there is an intimate relation between the diminution of mammalian tooth generations and the complication of their crown surfaces. He says that the so-called single tooth row of the reptiles is really double, consisting of an outer and an inner row, and that their dentition only secondarily becomes what he terms 'monostichic', consisting of an apparently single row. He even describes a third row, but this is resorbed before eruption. He considers that the diphyodont dentition of the Mammalia represents the two rows of the reptilian ancestor, thus concluding that each tooth in the primates has arisen from the *concrecence* of two tooth generations. 'The complication of the teeth in longitudinal (mesio-distal) direction was initiated among the reptiles and inherited by the Mammalia. The complication of the crowns in a transverse (bucco-lingual) direction is the result of the *concrecence* of two tooth generations, whereby the origin of the mammalian tooth from the reptilian was completed, and 'by this *concrecence* the multiplicity of the tooth generations was suppressed'. In other words, the polyphyodont dentition of the reptiles is represented by the complication of the crowns of the mammalian tooth in a transverse direction.

In his second paper (3 b), Bolk describes the results of the microscopic examination of early tooth germs in man and other primates. He also made use of the Born system of modelling employed by Röse in his work on tooth development (see p. 16). In this paper he describes, in the germs of both deciduous and permanent teeth, the following structures in connexion with the enamel organ: (1) a lateral enamel ledge, (2) an enamel crypt, (3) an enamel septum, (4) the enamel navel.¹

The lateral enamel ledge is a buttress or outgrowth arising from each tooth on the lateral margin of the enamel organ.

¹ A good summary of Professor Bolk's views is given in a review in the *Dental Cosmos* for 1913, vol. 55, pp. 103 and 1058.

The enamel crypt is a niche enclosed laterally by the lateral ledge, and its floor is formed by the top of the enamel organ.

The enamel septum. Two centres are described for the differentiation of the enamel pulp (or stellate reticulum)—a mesial or lingual and a lateral or buccal. An area of undifferentiated cells forms a septum between these two centres, and stretches from the external epithelium of the enamel organ to the stratum intermedium, dividing the body

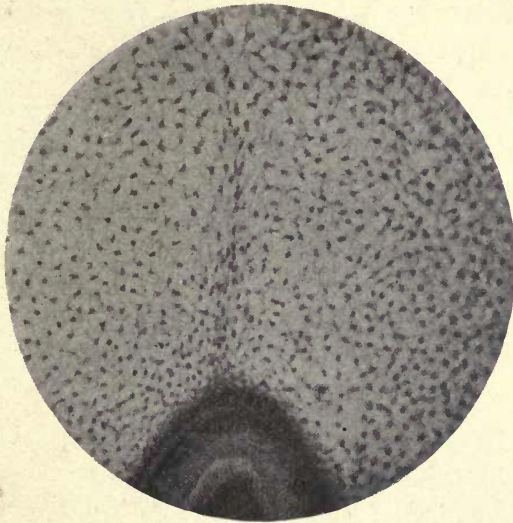


FIG. 11. Enamel organ of *Macropus*, showing division of stellate reticulum into two portions. The enamel septum of Bolk. ($\times 225$.)

of the enamel organ into a mesial and a lateral portion (see figs 11, 12).

The enamel navel, as this author calls it, is a groove or depression in the external epithelium of the enamel organ at the point where the septum touches this layer 'This groove', he considers, 'further accentuates the division of the enamel organ into a mesial and a lateral half, suggested by the septum.'

Marett Tims and Hopewell Smith describe and figure in the enamel organ of a Wallaby a division into two parts, but are uncertain whether to interpret it as the fusion of

two enamel organs or the subdivision of one. If considered to represent the latter, this photograph (p. 369, Tomes's *Dental Anatomy*, 7th ed.) shows Bolk's enamel septum and the enamel groove or navel in the external epithelium.

In a preparation of the author's of the enamel germ of *Macropus* the enamel septum is very evident, as shown in figs. 11 and 12. The stellate reticulum is seen to be divided into two parts, and the cells in the septum are not fully differentiated. Under higher magnification (fig. 12) the junction of

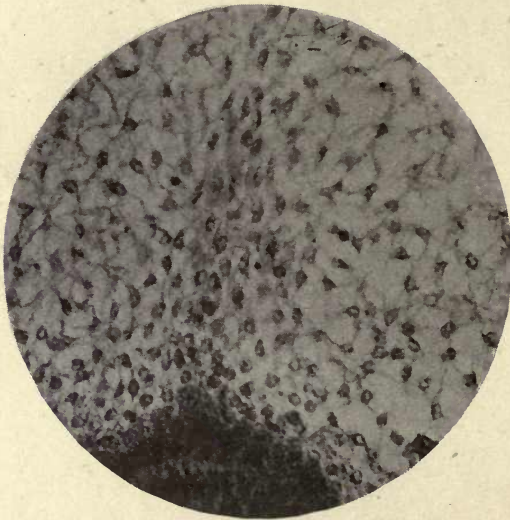


Fig. 12. Under higher magnification, showing blending of cells of the enamel septum with those of the stratum intermedium. ($\times 350$.)

the cells of the septum with those of the stratum intermedium is well seen. In this preparation, however, the septum cannot be traced to its junction with the external epithelium, and the groove on the surface of the latter is not visible. It does not appear that in this case the line of cells can be looked upon as indicating the fusion of two enamel organs, but actually represents the subdivision of one, and tends to lend confirmation to Bolk's description. As he finds these structures in the enamel organ of the primates, Bolk considers that they indicate that each primate tooth arises from the fusion of two separate germs ;

that each primate tooth is a double structure equivalent to two reptilian teeth. This view is a compromise between the concrescence and the differentiation theories.

‘In the reptilian ancestor of the Mammalia a triconodont differentiation had arisen, and two such triconodont teeth, one buccal and one lingual, had become fused. The fusion of these two triconodont teeth, the lingual side of one, to the labial side of the other, yielding a six-cusped element as the typical mammalian tooth, the varieties arising by a secondary reduction of this six-cusped tooth.’

It is seen that Bolk disposes of the assumption that each cusp of the mammalian tooth represents a single reptilian cone-tooth.

Summary

To account for the evolution of the human molar tooth, several theories have been formulated, the most important of these being:

Trituberculism.

The Polybunary or Multicuspidate theory.

Concrescence.

Bolk's triconodont concrescence theory, as it might perhaps be called.

The Tritubercular theory is a very important generalization, and although not generally accepted in its entirety, throws great light upon the relations of the cusps and the functional evolution of the human molar.

This theory, founded by Cope on the discoveries of early mammalian remains in New Mexico, considers that the principal cusps of both upper and lower molars are produced by the *addition* of cusps to the first-formed protocone, which represents the original haplodont or single cone of the reptiles. These added cusps take the shape of a triangle in early forms of the Mammalia, in the upper jaw the base of the triangle being outwards, the protocone forming the inner cusp; in the lower molars the base of the triangle is inwards, the protocone forming the outer apex of the triangle. This primitive triangle is called the trigon in the upper teeth, the trigonid in the lower. To this trigon another element is added, the heel or talon, the trigon

Trigon
and
Trigonid.

representing the cutting or sectorial type, the talon the crushing or masticating type.

Primitive Triangle .	$\left\{ \begin{array}{l} \text{Trigon (upper)} \\ \text{Trigonid (lower)} \end{array} \right.$	Protocone.
		Paracone.
Heel	$\left\{ \begin{array}{l} \text{Talon (upper)} \\ \text{Talonid (lower)} \end{array} \right.$	Metacone.
		Protoconid.
		Paraconid.
		Metaconid.
		Hypocone.
		Hypoconid.
		Metaconid.
		Hypoconulid.

Talon and Talonid.

The talonid is more developed in the lower molars forming three of the five cusps, the talon only possessing one, the hypocone. In the trigonid of the lower molars the paraconid is suppressed.

It has been shown, however, by several embryologists that the paracone is the first to appear in the *upper* molars, although the order of the appearance of the cusps of the lower molars corresponds to the Cope-Osborn theory. The other principal criticism brought against this theory is that multitubercular molars are found in association with tritubercular forms in the same geological strata, and it is considered quite as probable that the cusps of higher forms are produced by the suppression of cusps, and not by addition to a single cone. This is called the Polybuny or Multitubercular theory. The theory of Concrecence, supported by Ameghino (1), Röse, and Kükenthal (13), supposes the cusps of human molars to have arisen by the union or concrecence of simple cones.

Multitubercular theory.

According to Bolk, the multicuspitate teeth of the primates have arisen from the fusion of ancestral reptilian teeth, both antero-posteriorly and laterally, the antero-posterior fusion being of teeth of the same series, the lateral fusion, of teeth of separate series. In each case a triconodont tooth has arisen, and these becoming laterally fused, form the six-cusped molar, which he considers the typical mammalian molar tooth, further modification arising by the addition or suppression of cusps.

As it is generally allowed that subsidiary cusps arise from the cingulum, Bolk's views would appear to combine to some degree three principal views of cusp development—concrecence, trituberculy, and the cingulum theory.

The structures described by this author in the enamel organ are of great interest in their bearing on tooth development, and the confirmation of their constant presence in early tooth germs would be of great value in the explanation of the evolution of the teeth of primates.

The subject is such a complicated one, especially in determining the homologies of the ungulate molar, and there are so many side issues connected with it, that it is impossible to give anything but the merest outline in a work of this scope, but the author has endeavoured to state as simply as possible the principal views with regard to the evolution of the human molar.

The reader who wishes to pursue this interesting subject further is referred to the works mentioned in the short bibliography attached to this chapter, and especially to Osborn's *Evolution of Mammalian Molar Teeth*. An interesting paper on the evolution of human dentition by Mr. John Humphreys was contributed to the Sixth International Dental Congress (9).

REFERENCES

1. Ameghino, F. (a) *Filogenia*, 1884.
(b) 'On the Primitive Type of the Plexodont Molars of Mammals.' *Proc. Zool. Soc. Lond.*, 1899.
(c) 'Sur l'évolution des dents des mammifères.' *Bol. Acad. Nac. Ciencias en Cordoba*, t. xiv, 1896, pp. 381-517.
2. Baume. 'Versuch einer Entwicklungsgeschichte des Gebisses.' *Odontologische Forschungen*, 1882.
3. Bolk, L. (a) 'The Structure of the Reptilian Dentition and its Relationship to the Mammalian Dentition.' *Anat. Anzeig.*, vol. xli, Supplement, Berlin, 1912.
(b) *Die Ontogenie der Primatenzähne (Odontolog. Studien, I): Versuch einer Lösung der Gebissprobleme*, 122 pp., Jena, 1913.
4. Cope, E. D. (a) 'Systematic Catalogue of the Vertebrata of the Eocene of New Mexico.' *Rept. Geog. Explor. and Surveys, &c.*, Wheeler, 1875, pp. 5-7.
(b) 'On the Trituberculate Type of Molar Tooth in the Mammalia.' *Pall. Bull.*, No. 37, *Proc. Amer. Phil. Soc.*, xxi, December 1883, pp. 324-6.

- (c) 'On the Tritubercular Molar in Human Dentition.' *Jour. Morphol.*, July 1888, p. 7.
5. Delabarre. (a) *Thèse doct.*, Paris, Dec. 31, 1806.
(b) *Traité de la seconde dentition*, Paris, 1819.
6. Dursy, E. *Entwicklungsgeschichte des Kopfes*, 1869.
7. Goodsir. *Edinburgh Medical and Surgical Journal*, 1838.
8. Gidley, J. W. 'Evidence bearing on Tooth-Cusp Development.' *Proc. Washington Acad. Sci.*, vol. viii, 1906, pp. 91-110.
9. Humphreys, J. 'Report on the Evolution of the Human Dentition.' *Trans. Sixth Int. Dental Congress*, 1914, pp. 23-30.
10. Huxley, T. H. 'Development of the Teeth and on the Nature and Import of Nasmyth's Persistent Capsule.' *Quar. Journ. Micr. Sci.*, London, 1853, vol. i, pp. 149, 164.
11. James, W. W. 'A Preliminary Note on the Eruption of the Teeth.' *Proc. Roy. Soc. of Medicine*, June 1909.
12. Kölliker. *Gewebelehre*.
13. Kükenthal, W. 'Ueber den Ursprung und die Entwicklung der Säugethierzähne.' *Jenaische Zeitsch. für Naturwissenschaft*, Bd. xxviii, 1893.
14. Leche. 'Studien über die Entwicklung des Zahnsystems bei den Säugethieren.' *Morphol. Jahrb.*, Bd. xix, 1892, p. 502; Bd. xx, p. 113.
15. Major, C. J. Forsyth. 'Nagerüberreste aus Bohnerzen Süddeutschlands und der Schweiz, nebst Beiträgen zu einer vergleichenden Odontographie von Ungulaten und Unguiculaten.' *Palaontographica*, 1873, xxii.
16. Malassez, E. 'On the Structure of the Gubernaculum dentis and the Paradentaire Theory.' *Séances et mémoires de la Société de Biologie*, 8th ser., t. iv, No. 25, 1887, pp. 446-8.
17. Marcusen. *Bull. de l'Acad. de Pétersbourg*, 1849.
18. Osborn, H. F. *Evolution of Mammalian Molar Teeth*. London, 1907.
19. Röse, C. (a) 'Über die Entstehung und Formabänderungen der menschlichen Molaren.' *Anat. Anzeiger*, 1892, Nos. 13 and 14.
(b) 'Über die Zahnentwicklung des Menschen.' *Schweiz. Vierteljahrsschrift für Zahnheilkunde*, Bd. ii, 1892.
(c) 'Ueber die Zahnentwicklung der Fische.' *Anat. Anzeig.*, Bd. ix, No. 21.
(d) 'Ueber die Zahnentwicklung der Reptilien.' *Deutsche Monatschrift für Zahnheilkunde*, April 1892.
20. Serres. *Essai sur l'anatomie et la physiol. des dents*. Paris, 1817.
21. Sappey. *Traité d'anatomie descriptive*, t. iv, p. 119.
22. Scott, W. B. 'The Evolution of the Premolar Teeth in the Mammals.' *Proc. Acad. Nat. Sci. Philad.*, 1892, pp. 405-44.
23. Symington, J., and Rankin, J. C. *An Atlas of Skiagrams illustrating the Development of the Teeth*, 1908.
24. Schafer, E. A. *Microscopic Anatomy*.
25. Taeker, J. *Zur Kenntnis der Odontogenese bei Ungulaten*. Inaugural Dissertation, Dorpat, 1892.

26. Tims, H. W. Marett. 'On the Tooth Genesis in the Canidæ.' *Journ. (Zool.) Linnean Soc. Lond.*, xxv, 1896, pp. 445-80; xxviii, 1901, pp. 261-90.
27. Tomes, C. S. (a) *A Manual of Dental Anatomy, Human and Comparative.*
(b) 'On the Development of the Teeth of the Newt, Glow-worm, and Green Lizard.' *Phil. Trans. Roy. Soc.*, 1876, vol. clxv, part 1, pp. 285-96.
28. Woodward, M. F. *Proc. Zool. Soc. Lond.*, 1896, pp. 588-9.
29. Woodward, A. Smith. *Outlines of Vertebrate Palæontology for Students of Zoology*, Univ. Press, Camb., 1898, p. 269.

CHAPTER II

ENAMEL

ENAMEL, the hardest of animal substances, containing less organic matter than any other tissue of the body, enters into the composition of most teeth.

It either forms the external calcified layer of the crowns of teeth, as in man and many of the Mammalia, or in those teeth which are covered with cement, as in the Herbivora, plays a most important part in maintaining an effective grinding surface.

This is especially well seen in such compound teeth as those of the Elephant, Wart-hog, and Capybara. The molars of these animals are at first covered with an investing cap of cement, which, when the tooth comes into use, is rapidly worn away, exposing the dentine; this being more easily abraded than the enamel, the latter is raised into prominent ridges, and serves to maintain a most effectual grinding surface to the tooth. The cutting edges of the incisors of Rodents are maintained in the same manner by the position and unequal wear of the three tissues.

Enamel may be confined to the tip of the tooth, as in the eel, or invest the whole of the exposed surface, as in man; it is absent in some fish and in the teeth of the order Edentata (Sloths, Armadillos, &c.), and is not found in many reptiles and cetaceans.

It is sometimes difficult to determine whether the outer layer of many teeth of fish and reptiles is really enamel. It is translucent, and shows no visible structure, and might be either a thin layer of dentine or of cement, for both dentine and cement in very thin layers often appear structureless and transparent. It has been stated, however, that in all teeth which have been examined an enamel organ is present, as well in those teeth which are provided with enamel as in those in which it is totally absent. It is considered that the presence of the enamel organ, which is produced from the primary inflection of the

oral epithelium, is the most constant indication of tooth formation whether followed or not by calcification, and even in man the epithelial cells are said to extend at the sides and base of the dentine germ beyond the point at which enamel ceases to be formed, as the epithelial sheath of Hertwig. The author has shown, however, that there is every evidence that this extension of epithelial cells is not an extension of the layers of the enamel organ, but that it is derived from other epithelial elements of the follicle. He has shown that, in man as well as in Rodents, the enamel organ ceases at the neck of the tooth where the enamel terminates. This question will be further considered in describing the structure and functions of the epithelial sheath of Hertwig (p. 320).

In a tissue of such extreme hardness as enamel we should naturally expect to find a great preponderance of inorganic salts, and some authorities have even asserted that there is no animal matter in the fully calcified enamel. Von Bibra's (2) analysis of enamel is as follows :

Chemical
constitu-
tion of
enamel.

Calcium phosphate and fluoride	89.82
Calcium carbonate	4.37
Magnesium phosphate	1.34
Other salts	0.88
Cartilage	3.39
Fat	0.20

This analysis is seen to give :

Organic substances	3.59
Inorganic substances	96.41

In the adult female Von Bibra estimates the amount of animal matter as 5.97 per cent.

The two principal lime salts present in enamel are seen to be calcium phosphate and calcium carbonate, but in the completed tissue the calcium phosphate largely predominates, Von Bibra giving 89.82 of calcium phosphate and fluoride to 4.37 of calcium carbonate (the fluoride only contributing about 2 per cent.), magnesium phosphate being present in the proportion of about 1.3 per cent.

Hoppe-Seyler (9) considers that in human teeth the phosphate and carbonate of lime exist in combination

($\text{Ca}_{10}\text{Co}_3(\text{Po}_4)_6$), and that this salt forms in the finished tissue 95.35 per cent. combined with magnesium phosphate 1.5 per cent., leaving an organic residue of 3.60 per cent.

Hoppe-Seyler also considered that the enamel in the infant contains a much larger amount of organic matter, and this has been given by some authors as high as 14 per cent. C. S. Tomes (18 c), however, justly points out that such an analysis must be of a very uncertain nature, as the difficulties to be met with in obtaining a sufficient amount of the incomplete enamel at birth without contamination with other substances would be almost insuperable.

An analysis of the enamel of erupted or erupting young growing teeth would be of the greatest value in deciding the much-vexed question as to whether enamel undergoes any changes after eruption resulting in further consolidation. No such examination has, however, been recorded, although there are very strong evidences that some such change does take place in growing teeth.

There have been considerable discrepancies in the analysis of enamel given by different authors. Tomes accounts for these discrepancies by the fact that the organic matter in enamel had been estimated by the loss on ignition, but that the water in intimate combination with the enamel had not been accounted for, and he showed that in the case of elephant's enamel as much as 4 per cent. of water remained after the enamel had been dried for a long time at a temperature of 300° F. He concludes that 'the total loss on ignition is very nearly accounted for by the water given off', and what has hitherto been considered organic matter is simply water in intimate combination with the lime salts, and probably with the tribasic calcium phosphate, as this substance retains in combination one or more equivalents of water which it will not part with below a red heat. Tomes's conclusions from these experiments were that enamel contains *no* organic matter.

The most recent analysis of enamel is that given by Dr. Lovatt Evans (10), who in a paper contributed to the International Medical Congress in 1913 showed that the organic matter in human enamel was between 1 and 2 per cent.

Ground enamel, carefully separated from every other

C. S.
Tomes's
analysis.

Dr.
Lovatt
Evans's
analysis.

tissue, was weighed and treated with dilute hydrochloric acid on a water bath and evaporated to dryness. To ensure the complete decomposition of the carbonates this process was repeated with concentrated hydrochloric acid. Frankland's method of detecting the presence of organic matter in the residue was adopted. 'The residue is strongly heated *in vacuo* with copper oxide, and the resulting gas, consisting of carbon dioxide and nitrogen, is collected and analysed. From the amount of gas formed, the amount of carbon in the organic matter can be deduced, and some idea of the relative quantity of organic matter can also be obtained by comparison of the amounts of carbon and nitrogen.' This method, Dr. Lovatt Evans states, is sufficiently delicate 'to detect 0.0003 gramme of carbon in 3 grammes of the enamel, i. e. 0.01 per cent. of carbon, or say 0.02 per cent. of organic matter, if we assume that the organic matter contains 50 per cent. of carbon'. The results gave an organic content of 1 to 2 per cent.

Frankland's method.

We see that the two methods employed by these investigators gave different results, although both agree in showing that there is less organic matter present than the older analyses yielded.

It seems very difficult, however, for other reasons, to imagine with C. S. Tomes that enamel is a totally inorganic tissue, but the 1 to 2 per cent. of organic matter found by Dr. Lovatt Evans may be quite sufficient to account for the histological evidences of the presence of organic matter in enamel.

Owing to its great density and the serious interference with the images it presents, caused by refraction, enamel is one of the most difficult substances for microscopical examination. The actual structure is so veiled by the dense calcification, and the course of the constituent prisms is so varied and complicated, that without studying the process of its development it would be impossible to arrive at any certain knowledge of its true histological nature. These difficulties of investigation have been the cause of the many contradictory statements concerning its actual structure that have appeared in the various publications on the histology of enamel.

Structure of human enamel.

To the unaided eye enamel has a smooth, glistening, almost crystalline appearance. It is seen under the microscope to be built up of prisms or columns united by a densely calcified intermediate substance, which in perfectly formed enamel cannot easily be distinguished from the prisms.

Course
of the
prisms.

The prisms pass from the outer surface of the dentine to the free margin of the enamel, but they do not follow a straight or even course, being in many places spiral in arrangement and disposed at various angles. Prisms in




FIG. 13. Longitudinal section of enamel. ($\times 400$.)

transverse section can often be seen passing more or less at right angles to the others (fig. 15). Their usual arrangement, however, is in radiating and undulating lines or groups of prisms, maintaining a principal direction throughout their course (figs. 13, 14). The prisms or columns, each of which extends from the dentine to the surface in a more or less undulating course, show a marked cross-striation at regular intervals, and are separated from one another by the intercolumnar or interprismatic substance, which, like the prisms, is highly refractive and very fully calcified.

In transverse section the prisms show oval, hexagonal, or polygonal outlines (figs. 15, 16, 24), and in many places




FIG. 14. Longitudinal section of enamel (cross-striation very marked). ($\times 800$.)

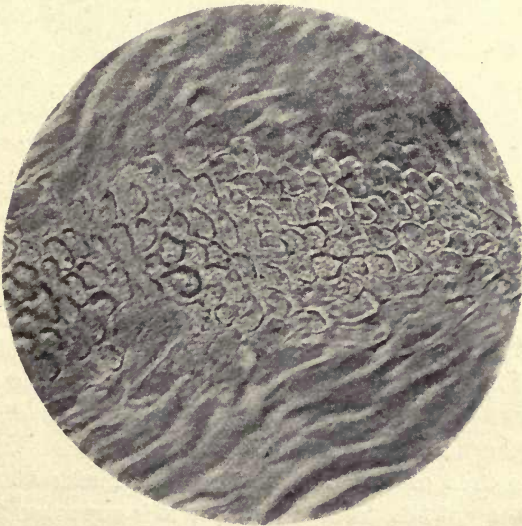


FIG. 15. Transverse section of enamel showing arcade form of prisms. ($\times 750$.)

have an arched appearance, being rounded on one aspect and more or less concave on the opposite side (fig. 24), as will be more fully explained later. Prisms of hexagonal form are not very frequently met with in human teeth, and Leon Williams describes them as usually oval or rounded (see fig. 16). In marsupial enamel they appear, however, to be more constantly of an hexagonal form.

Bödeker holds that there is a living protoplasmic network between the enamel columns continuous with the contents

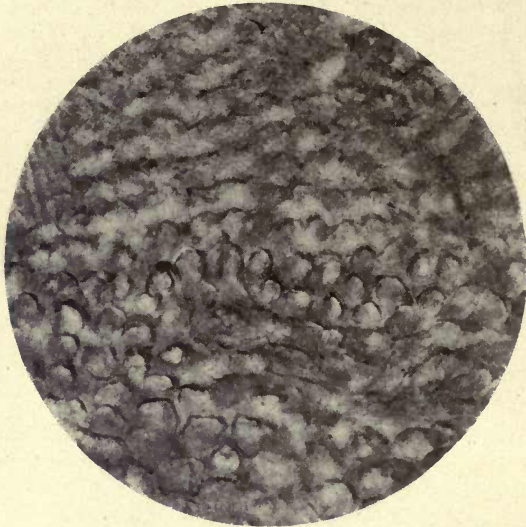


FIG. 16. Transverse section of enamel showing oval and rounded sections of prisms. ($\times 800$.)

of the dentinal tubes, but such a view is at variance with all our knowledge of the structure and composition of enamel, and is certainly due to a misinterpretation of appearances.

The course of the enamel prisms is more regular in some orders of Mammalia ; in the Manatee they are in many places arranged in straight parallel lines, and the Rodents especially show curiously regular patterns which will be further explained when treating of rodent enamel.

As the area of the enamel is much greater at the outer surface than at the dentine junction it is supposed that there must be supplemental prisms interposed, but these, owing to the complicated pattern of the enamel, are difficult to

trace, and although both C. S. Tomes (18 c) and Hopewell Smith (8) speak of them as being present in human enamel, no record of their existence has been made by either photograph or drawing so far as can be ascertained.

It can, however, be shown that both branching and the interposition of supplementary prisms are to be seen in other mammalian enamels, and the probabilities are greatly in favour of a similar condition being present in human teeth.

It would appear that if there is any evidence of branching and the occurrence of supplemental prisms, we should be most likely to see it in teeth in which the spreading out of the enamel is greater than in human teeth.

In the enamel of the Wart-hog (*Phacochærus*) where these conditions prevail it has been shown by the author in a recent communication (11 a) that the columns of prisms divide dichotomously, and supplementary prisms are introduced between them.

Supple-
mentary
and
branching
prisms in
*Phaco-
chærus*.

The large third molar of *Phacochærus* is a compound tooth made up of from twenty-four to thirty denticles, arranged in three rows, each denticle consisting of dentine surrounded by an investing sheath of enamel and enclosed in cement. The denticles, which form columns passing deeply into the jaw, are united by the cement, and the whole forms a compound tooth having many points of similarity with the molar tooth of the Elephant. As the tooth becomes worn down by mastication, the surface shows oval rings of dentine surrounded by enamel, the intervals between the denticles being filled up with cement. This disposition of the enamel gives a much wider area at the circumference than at the dentine junction, so that in the comparatively short course of the enamel columns they would come to be very wide apart at the surface if they maintained the same diameter throughout. A thin section of one of these denticles, where the enamel columns are seen radiating from the dentine to the cement, shows that there is no apparent increase in the diameter of the prisms or of the interprismatic substance (which is very abundant in *Phacochærus*) as they approach the surface, but it also shows very distinctly that the columns of prisms divide and branch and that the

spaces between the branches are filled with supplementary prisms (fig. 17). We thus see that, at all events in one order of the Mammalia, the branching and interposition of prisms is at least one of the methods adopted by nature to overcome this difficulty.

Pickerill (14) has given another explanation of the mode by which he considers this difficulty of the widening of the enamel at the periphery is overcome. He denies the existence of supplemental prisms, but says that the

Variation
in dia-
meter of
enamel
prisms.



FIG. 17. Enamel of *Phacochoerus* (Wart-hog) showing branching of enamel columns.

enamel prisms taper somewhat from the surface to the dentine margin. He has measured a large number of prisms across their diameter, both at the dentine margin and at the enamel surface, and describes a marked increase in their diameter both in native and in European races.

According to this view each enamel prism would be a cone with its base at the surface of the enamel, and he compares the arrangement with that of the prisms in the outer layer of the *Pinna* shell. From a series of measurements he gives the following average diameter of the prisms: On the buccal curve of the teeth, at the amelo-dentinal

junction 0.0031 mm., at the enamel surface 0.0057 mm., giving a proportion of 1 to 1.83. At the cusps the average measurement at the amelo-dentinal junction was 0.0025 mm., at the enamel surface 0.0065 mm. Kölliker gives the diameters of enamel prisms as from 0.0064 to 0.0051 mm., but does not indicate from what part of the enamel his measurements were taken, and there appears to be little doubt that there is a distinct variation in the diameter of the prisms within the substance of the enamel.

One of the most complete researches hitherto published on the structure of human enamel is that of Leon Williams (21), and his paper, accompanied by excellent original photographs, demonstrates very completely the main points of his observations.

Leon Williams' on enamel structure.

He holds that the enamel consists of two distinct portions, the prisms, or rods as he prefers to call them, and the substance between the rods, and that these are developed in different manners. The calcific matter which builds up the rods is a product of the ameloblast cell. The rods are built up of little blocks of coalesced granules, and are arranged like piles of bricks; they show a cross-marking where they meet one another, which is the cause of the minute cross-striations of the enamel prisms. He describes the connexion of the rods with one another laterally by calcified processes. Strings or threads in the calcified material are also seen in many places passing along the length of the rods: these are well shown in fig. 14, and must not be confused with other darker strongly marked vertical lines which are due to refraction. In fig. 18 the granular nature of the calcific deposit can be seen in the formed enamel prism. The cross-striation is confined to the rods and does not traverse the interprismatic or cement substance. The blocks of the enamel rods do not alternate in neighbouring rods, but are opposite one another all across the enamel (figs. 14, 19). The cement substance between them is calcified, according to Leon Williams, independently of the rods, cementing them together and forming a compact tissue which in normal enamel is completely calcified and contains no trace of organic matter. Fig. 20, a photograph from a ground preparation, shows at *a* a detached

segment of the enamel column which strongly suggests that the enamel is built up in this manner.

Summary
of Leon
Williams's
views.

Perfect enamel then consists, according to this author, of the prisms, for which he has substituted the term 'rods', made up of vertical rows of calcified disks in close apposition but sufficiently separated to show the cross-striation which marks their line of junction, and of a densely calcified cementing or interprismatic substance. Delicate plasmic strings are to be seen running vertically within the substance of

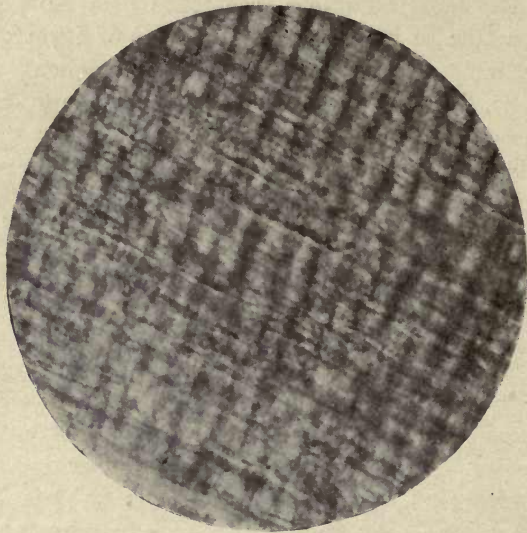


FIG. 18. Enamel (longitudinal) showing granular structure of prisms. ($\times 800$.)

the calcified rod, and calcified connecting bridges pass horizontally between them (fig. 14).

The vertical rows of calcified disks forming the rods are built up of minute coalesced granules.

There is little doubt that this is a true description of the structure of enamel of perfect quality, but Leon Williams's statement that enamel is an entirely inorganic tissue requires some modification, for the reason that enamel in human teeth is seldom, if ever, a perfect tissue. Imperfections in structure, especially at the dentine margin, and minute channels from the dentine are so frequent as scarcely to be looked upon as abnormalities.




FIG. 19. Enamel (human); longitudinal striæ very pronounced. ($\times 800$.)

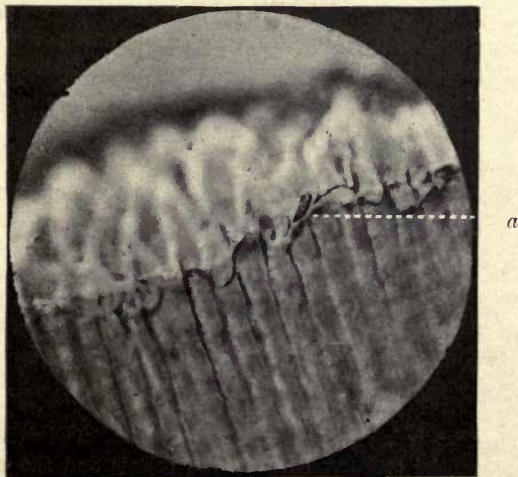


FIG. 20. Enamel, longitudinal (Weil process). Shows small block detached in grinding (*a*). ($\times 800$.)

Mr. Douglas Caush (5) long ago described staining of normal enamel by several methods, and Dr. von Beust (3) and others have succeeded in staining portions of the enamel by the alcoholic fuchsin method, and in fig. 21 both the prisms and the interprismatic substance were stained with anilin violet.

Leon Williams says: 'In no instance have I ever been able to demonstrate the presence of stainable matter, other than bacteria, in human enamel.' The author has, however,

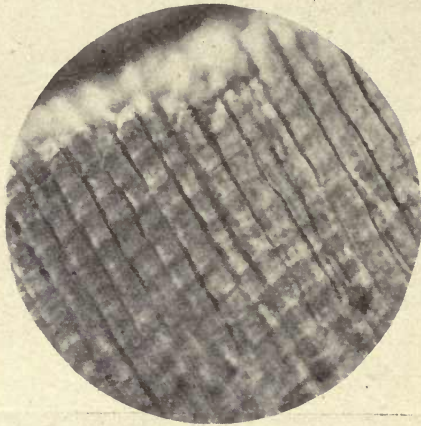


FIG. 21. Young enamel (longitudinal) stained with anilin violet (Weil process). Both prisms and interprismatic substance are stained. ($\times 800$.)

many preparations showing the penetration of the stain into the tubes in the enamel which are prolonged from the dentine, into the spindle-like bodies at the margin of the dentine, and also in some places into the interprismatic substance.¹

Professor Walkhoff (20), in a recent paper, concludes from an examination of many specimens of enamel that there is scarcely a single case among civilized man in which he cannot find considerable faults of structure in the growth

¹ Von Ebner succeeded in staining young enamel, but he did not notice any true differential staining between the prisms and the cement substance; sometimes one, sometimes the other, was more fully stained. He made use in these experiments of unbleached shellac, the erythrolaccine staining the prisms and interprismatic substance. The method is described on p. 28 of his paper (6 a).

of the tissue elements and in their calcification, and he found that the teeth of the anthropoid apes showed defects in the structure of the enamel exactly similar to those in man.

Other explanations have been given of the cause of the cross-striation of the enamel prisms from that given above. Von Ebner (6 *b*) holds that it is the result of the action of acids, but these striæ can be seen in prisms which have not been treated with acids. Fragments scraped from the forming enamel of a dry human tooth still in its crypt and teased out in glycerine on a slide show these markings very distinctly. That this cannot be due to any acid that may be present in the glycerine is shown by the fact that they are quite as evident when examined in alkaline Ferrant solution.

Striation
of prisms.

Hertz described the striæ as due to the intermittent calcification of the enamel rods. The generally accepted view is that they are due to varicosities in the prisms, but this seems to be describing the condition without any reference to its cause. There seems little doubt that the appearance is due to varicosities, but the cause of these is the mode of deposition of the lime salts in the prisms of the enamel. These are made up, as Harting (7) originally said, of little piles of calcospherites, and are due, as Leon Williams has pointed out, to the succession of these regularly deposited calcified bodies within the cytoplasmic strings which form the foundation of the enamel rods, as will be more fully explained when describing the calcification of enamel. Fig. 22, from a preparation of the author's of developing marsupial enamel teased out in glycerine, shows in several places the beaded prisms made up of a regular deposit of small calcified bodies and helps to confirm this view of the nature of these striæ.

The suggested analogy with the varicosities of voluntary muscle fibres can scarcely merit serious attention, as the varicosities in enamel are due to its mode of calcification and are dependent upon enamel being a calcified tissue. The opinion of Hannover and Hertz that they are due to the intermittent calcification of the enamel rods was therefore very close to the real explanation, although these authors did not describe the actual mode of deposition of these uniform calcified elements of the prism.

Form and
arrange-
ment
of the
Prisms.

Within recent years some researches on the form and arrangement of the enamel prisms in human and some other mammalian enamels have been published by E. Smreker (16) and Professor von Ebner (6 a). Smreker, who was the first to point out this form of modification of the enamel prism, asserted that the majority of the prisms in human enamel are not rounded or polygonal in transverse section, but have an arched form, owing to the prisms being longitu-

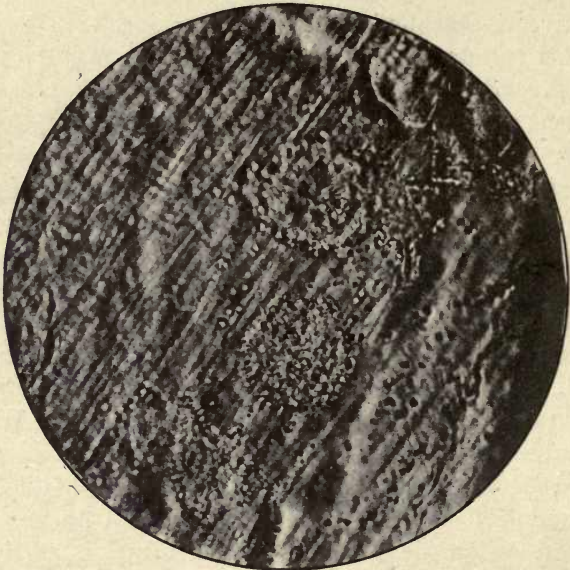


FIG. 22. Marsupial enamel. Teased preparation showing calcospherites in the laminae. ($\times 1,000$.)

dinally grooved and fitting into one another. Von Ebner confirms these observations in his paper published in the same year (1905). Smreker compares the arrangement of the prisms to that of the cells of the prickle cell layer of a pavement epithelium. In the epithelium the cells are seen to present convex and concave margins, the concavity being dependent upon the convexity of the cell beneath (fig. 23). Where one cell comes into contact with a single neighbouring cell there is a single concavity, but if two or more cells are in contact with a single cell the single cell will show two or more concavities. Comparing the transverse section of the

enamel prisms with such cells it will be seen that this arched or concavo-convex shape of the prism renders it necessary to conclude that in longitudinal section it should show a convex margin, and a single, double, or compound groove on the reverse side (figs. 15 and 24). As in the epithelium

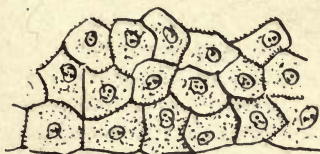

FIG. 23. Drawing to show the arrangement of the epithelial cells in a pavement epithelium.

the interval between the cells is crossed by the prickle processes, so in enamel the prisms are connected by bridges which traverse the interprismatic substance which cements together the interlocking prisms.

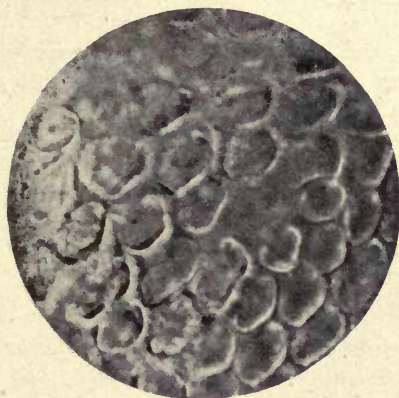

FIG. 24. Human enamel. Transverse prisms. ($\times 1,500$.)

Such an arrangement would necessarily give a very perfect adaptation and tend greatly to increase the resistance of the enamel to any disrupting force. These observations have received very little attention and are not even referred to in recent text-books. They were considered by Walkhoff to be false appearances and not to be evidence of any real structure in the enamel. A careful examination of suitably prepared sections, however, and the evidence

DESCRIPTION OF PLATE III

Drawings from teased preparations of enamel, except figs. 5, 6, 7, and 8, which are from sections.

FIG. 1. Double-grooved prisms (Elephant). *r.* Ridges; *g.* grooves. The ridges are often seen projecting beyond the extremities of fragments.

FIG. 2. Single-grooved prisms (Elephant). *r.* Ridge; *g.* grooves.

FIG. 3. Two double-grooved prisms, transverse above (Elephant).

FIG. 4. Fragments of prisms in transverse fracture (Elephant).

FIG. 5. Four prisms from a section (Elephant) showing surface marking and prominence of the ridge at *r.* Compare with photograph, fig. 26.

FIG. 6. From Elephant: bridges in transverse section. The inter-prismatic substance appeared dark and the bridges are very conspicuous as white lines.

FIG. 7. Elephant. From a section showing a wing process in the enamel. Compare with photograph, fig. 27.

FIG. 8. Elephant. From a section showing ridges and grooves. *r.* Ridges; *g.* grooves. Compare with photograph, fig. 27.

FIG. 9. Two prisms from Elephant, showing needle-splitting (*n*) and inter-columnar bridges (*b*).

FIG. 10. Fragment of Elephant enamel in transverse section. Two entire double concave prisms are seen projecting, with feather edges and intercolumnar bridges (*b*).

FIG. 11. Fragments of prisms seen obliquely (Elephant). Compare with photograph, fig. 28.

FIG. 12. *a, b, c.* Wing processes and membranous layers in Macropus, showing needle-splitting, wings, and bridging.

FIG. 13. Fragment of Macropus enamel. Membranous laminae at right angles to direction of prisms.

FIG. 14. Wing process, human enamel.

The drawings of the teased preparations were made by direct observation under the microscope, and are magnified about 400 diameters; figs. 6 and 7, from sections, are $\times 800$.

Fig.4.



Fig.1.

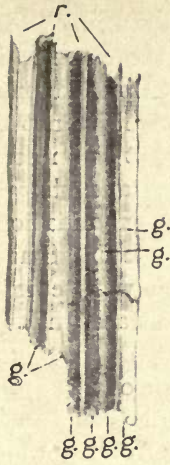


Fig.2.



Fig.3.



Fig.5.

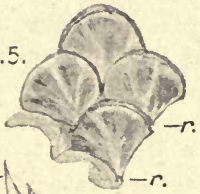


Fig.6.



Fig.7




Fig.8.




Fig.9.

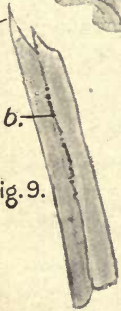


Fig.10.

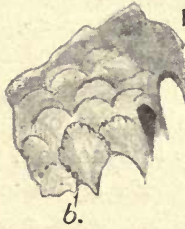

Fig.11.

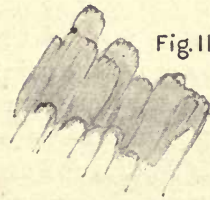


Fig.14.



Fig.12.

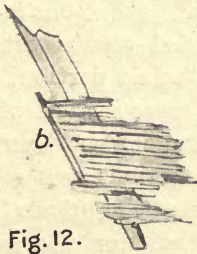
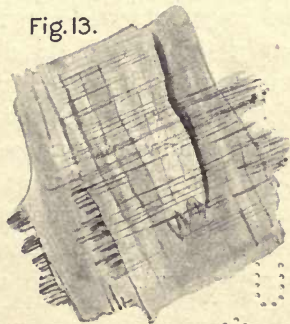

Fig.13.



a.



c.



afforded by teased preparations will, we think, leave little doubt that, at all events in many areas of the enamel, such an arrangement of the prisms exists. Von Ebner expresses his surprise that the observations of Smreker have not been more generally recognized, and concludes that the necessity of preparing very thin sections by grinding and the great difficulties encountered in the microscopic examination of enamel have been the cause of this neglect. Smreker prepared very thin ground sections which were carefully polished, some being treated with silver nitrate and some not.

It will be said that the obvious explanation of this appearance in transverse section is that the prisms are viewed obliquely, one prism appearing to slightly overlap another of the same form, for if a circular disk is overlapped by another it would cause an appearance of concavity in the underlying disk, and, similarly, if one disk is overlapped by two the lower one would have a double concave margin. It would be very difficult to prove that this was not the explanation by the examination of sections alone, but teased preparations, in which the enamel prisms are separated and isolated, would indicate if there were really any such structure as that which these authors describe.

Von Ebner, who was at first inclined to think that the appearances were due to the obliquity of the sections, endeavoured to prove the point by this method. Fragments of enamel were scraped from a tooth and allowed to fall into water or glycerine, where they were separated and broken up with needles and examined under the microscope. Such preparations showed separated prisms with grooves running the whole length of the detached portion, and other separated fragments were seen in cross-section with a concavo-convex figure. These observers also describe other appearances in both teased preparations and sections, as the *Flügelfortsätze* or wing processes of the prisms (Plate III, fig. 14) and connecting processes between the columns of prisms, called by Von Ebner the intercolumnar bridges.

The wing processes of the prisms may often be observed in teased preparations of mammalian enamel. These are lateral projections from the prisms, appearing sometimes

Wing
processes.

as projecting obliquely directed fibres, sometimes showing a zigzag splitting like an edge of fractured glass. These processes are seen to pass all across the prism as well as project from its edges, and Von Ebner has figured them in human enamel as enveloping the concavo-convex prisms like a sheath and projecting on either side. These wing processes are visible not only in forming enamel but also in the completed tissue, and can be seen in thin sections as well as in teased preparations. In some ground preparations made by the author to investigate these observations of Smreker the wing processes of the prisms are distinctly visible in some parts of the sections, and, as will be explained farther on, they are still more conspicuous in the enamel of the elephant. Here and there in teased preparations, portions of membrane-like expansions are seen attached to the prisms, but Von Ebner does not consider, for the reasons given in his paper, that these are identical with the wing processes (Plate III, fig. 12).

The connecting processes between the prisms have been described by Leon Williams, and are no doubt the processes which form the intercolumnar bridges of Von Ebner. They can be seen in thin sections of enamel, but are said by Von Ebner not to be visible in transverse sections. A preparation of the author's, however, shows them quite clearly in transverse section, and they are still more evident in Elephant enamel (Plate III, fig. 6, and fig. 29).

In all teased preparations of human and other mammalian enamels the broken prisms are seen to terminate in needle-like oblique points at one end and sometimes at both ends of the fractured prism (Plate III, fig. 9, &c.). This appearance can be seen over the whole field of the microscope, and it is seldom that a direct transverse fracture can be detected. This needle-like splitting was considered by Von Ebner to be due to the obliquely directed wing processes, but, as it is seen in marsupial enamel where the wing processes are very distinct and have a direction almost at right angles to them, it is a little difficult to understand that this can be the correct explanation of their origin.

The direction of the splitting would appear to suggest that it takes place along the lines of the Tomes' processes

Needle-like
splitting.

of the ameloblasts, which are prolonged into the enamel and constitute the longitudinal system of organic fibres which form the foundation of enamel.

In studying the wing processes the author also made use of marsupial enamel, which in many respects appears to give us the key to the mode of formation of higher mammalian enamels; it is less perfectly calcified, at all events in early stages, and the structure is more easily made out than in a tissue which is very rapidly calcified and in which the early stages of development are soon obscured by the densely deposited lime salts. Teased preparations of the forming enamel of *Macropus rufus* were examined. The wing processes were very much more evident than in any other enamel investigated; they have a more feathery appearance and often pass right across groups of prisms, and appear to show a transition into membrane-like expansions (Plate III, figs. 12 and 13). This would appear to indicate that wing processes and these calcified membranes are one and the same thing, and, as before stated, the wing processes and transverse fibres of the membrane-like expansions are seen to pass almost at right angles to the columns of prisms and their pointed needle-like fractured terminations. The author was, however, unable to detect in marsupial enamel, either in early or completed stages, the curious interlocking of the prisms described by Smreker in human enamel. The prisms in all marsupials examined show the usual polygonal forms in transverse section, and no longitudinal grooving could be detected in teased preparations.

It may be that the interlocked prisms indicate a more highly developed and specialized structure of the enamel.

Inter-
columnar
bridges.

The intercolumnar bridges are somewhat difficult to detect in human enamel; they are shown in fig. 14 and in several of Leon Williams's photographs. In the Elephant they can be seen with great distinctness both in longitudinal and transverse sections (11 a). A study of the microscopic anatomy of the enamel of the Elephant which curiously seems to have escaped the attention of histologists, convinced the author that this remarkable form and arrangement of the prisms is an actual fact and not a false appearance due to the prisms being viewed obliquely, for in the Elephant

the prisms are very much larger than those of human enamel and their structure is more easily made out both in sections and in teased preparations. The average diameter of the prisms of Elephant enamel is 10 to 12 μ , while that of human enamel is 4 to 5 μ .

The interlocking of the prisms is more general in the Elephant; in fact, over the surface of a large section it is difficult to find a single prism that shows the usual rounded or polygonal form. On examining a transverse section of

Elephant
enamel.

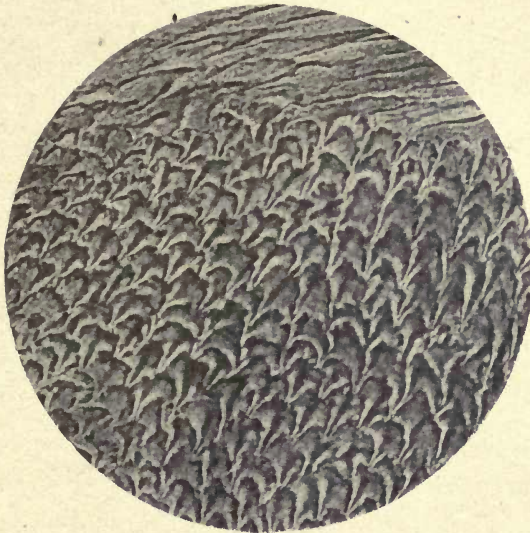


FIG. 25. Enamel of molar of Asiatic Elephant. ($\times 800$.)

the enamel of the Elephant's molar, which includes the neighbouring areas of dentine and cement, the prisms are seen both in transverse and longitudinal section, the former predominating, and the transversely cut prisms appear at first sight to overlap one another like tiles on a roof, or the scales of a fish (figs. 25 and 26). Teased preparations of the enamel show, however, very clearly that these prisms have a concavo-convex cross-section and are deeply grooved posteriorly (Plate III, figs. 1, 2, 3).

The groove may be single, when there is a prominent ridge to be seen on each side of it, or they may be double, as is usually the case, when there is, in addition, a pronounced

Grooving
of prisms.

ridge separating the two grooves. In these teased preparations small detached fragments are seen which show the concavo-convex form in cross-section (Plate III, fig. 4), and occasionally, longitudinally broken-up prisms which give still more certain evidence of the structure, as they show that the broken end of the prism has the above-described concavo-convex form (Plate III, fig. 3). Detached fragments, in which the prisms have broken up in a transverse or oblique direction, also give very instructive views




FIG. 26. Enamel of molar of Asiatic Elephant. ($\times 800$.)

of this structure. In Plate III, fig. 10, the whole of one of the arched prisms is seen *in situ*, with its concave margins projecting free from the surrounding prisms.

In many parts of the sections not only have the prisms the tile-like appearance above described, but they show a serrated margin and appear as if grooved or ridged on the surface, many of them bearing a curious resemblance to the frond of a maiden-hair fern (fig. 25).

In these transverse sections of the Elephant's molar, where there are alternate areas of cement enamel and dentine, the convexity of the prism is invariably directed towards the dentine and never towards the cement on

the opposite side, in any sections examined. In longitudinal section the prisms appear wavy, and in many parts show grooves and feathered margins (fig. 27).

Fig. 28 shows very distinctly the actual arrangement of these double concave prisms in the Elephant. It was photographed at a crack in the enamel, and the prisms are seen at the same time in both longitudinal and transverse section: the fringed margins and little shining points, apparently due to the broken connecting bridges, are also

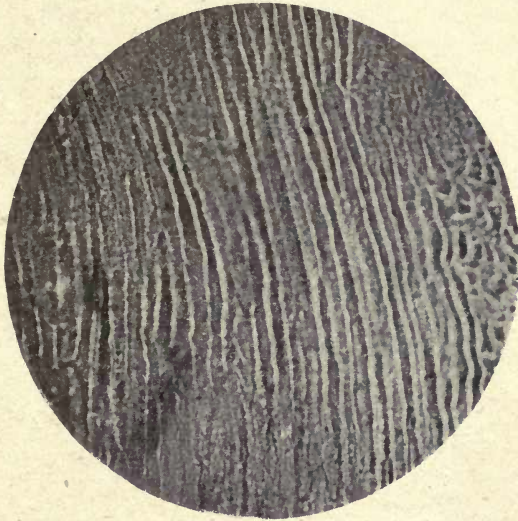


FIG. 27. Enamel of molar of Indian Elephant. Longitudinal section showing grooves, &c. ($\times 500$.)

visible. From this photograph and from many preparations it would appear that the prisms of the enamel are arranged, not in direct lines from the dentine, but that independently of all their curves and intercrossing they maintain a slope towards the dentine which it is very difficult to follow out or define.

The connecting bridges in the Elephant are well shown in fig. 29 in longitudinal section, and in transverse section in Plate III, fig. 6. These processes are seen to pass across the interprismatic substance and form connexions between neighbouring columns. In the longitudinal view it is seen that the connecting processes are somewhat irregular in

form and direction, as are the connecting or wing processes of the prisms. That the membranous expansions and wing processes are calcified, is shown both in man and the elephant by examination with polarized light, and the very irregular zigzag splitting of the wing processes, sometimes seen, may be due to their fracture in teased preparations,

While the needle-like splitting of the enamel in the teased preparations may be due to the longitudinal fibrillation, as before suggested, the membrane-like fibrillar expan-

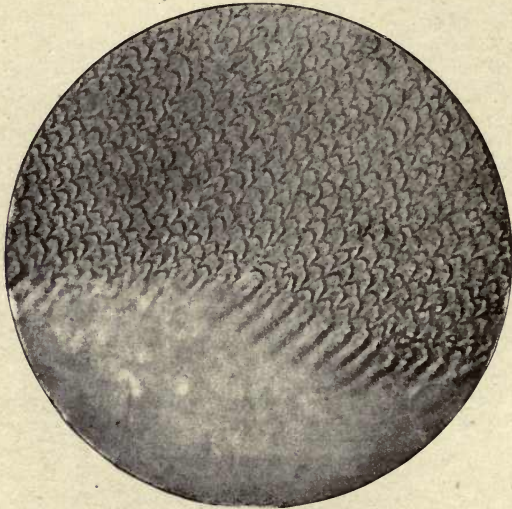


FIG. 28. Enamel of Elephant photographed at a crack, showing prisms in both longitudinal and transverse section. ($\times 400$.)

sions, the wing processes, and the bridges one would be inclined to consider as due to the transverse fibrillation of the matrix so apparent in the forming enamel of marsupials where the teased preparations break up into laminæ (Plate III, figs. 12 and 13).

These transverse fibrillar layers must also be incorporated in the substance of the calcified prism. These grooved prisms are not in direct contact with one another, being separated by the interprismatic substance which is, as it were, flowed around them, cementing together and compacting the whole tissue. As Leon Williams pointed out, the prisms being in many places round rather than hexagonal

there must of necessity be interspaces between them. Professor Walkhoff (20) considers that the cement substance of the enamel, described by Von Ebner, Leon Williams, and other observers as the interprismatic substance, does not exist, and is in reality the outer or cortical layer of the prisms, or, as he calls them, the *Zentralkörper*. C. S. Tomes also says: 'no thoroughly distinct interstitial substance exists in enamel.' The evidences, however, afforded by the development of enamel and the marked staining of a substance between the

The inter-
prismatic
substance.

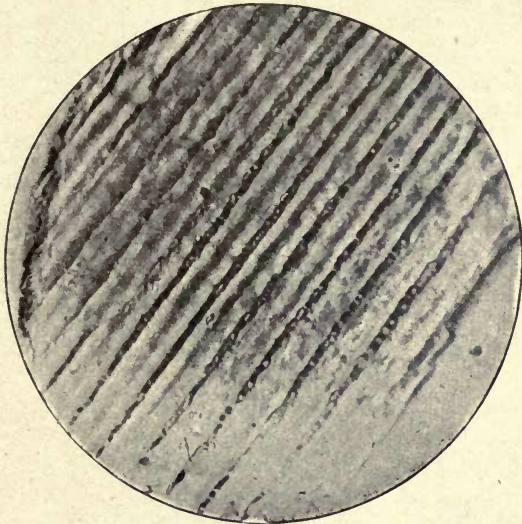


FIG. 29. The intercolumnar bridges (from a teased preparation of Elephant enamel). ($\times 600$.)

prisms in marsupials, point to the actual presence of such a substance altogether independent of the prisms. Leon Williams considers the interprismatic substance to be a separate material, formed separately from the prisms, and the author's own investigations on the enamel of marsupials appear to confirm this view.

Another confirmation of the separate formation and distinct nature of the interprismatic substance is given in a recently published paper by the late Dr. G. V. Black and Dr. F. S. McKay (1), in which they describe an endemic pathological condition of the teeth occurring in certain districts of the Rocky Mountains. This condition they call mottled

Mottled
teeth.

teeth, from the alternate bleaching and pigmentation of the enamel seen in this affection. This pathological condition affects only the interprismatic substance and not the prisms. The work of calcification appears to be reversed, and the last-formed part of the enamel, the interprismatic substance, is removed by the action of some as yet unknown agent which has no effect upon the prisms. This remarkable complaint, investigated by such an accurate




FIG. 30. Striæ of Retzius. ($\times 150$.)

observer as Dr. Black on the spot, and by means of a very carefully prepared series of microscopical sections, lends the greatest confirmation to the view that the prisms and the interprismatic substance are separate structures. The question then arises, how are they distinct from one another? Is the cement substance only a persistently less completely calcified element of the enamel or is it in some way of a different composition?

The so-called 'brown striæ of Retzius' (figs. 30, 31, 32) are brown lines which conform to the position of the enamel cusps at different stages of growth and are probably marks of their stratification, an opinion held by Kölliker, Walkhoff, and others.

Brown
striæ of
Retzius.

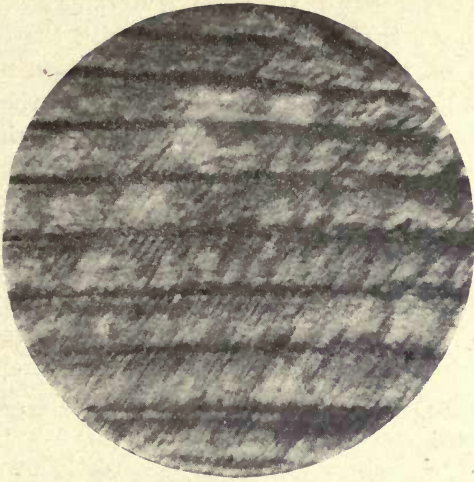


FIG. 31. Striæ of Retzius. ($\times 300$.)

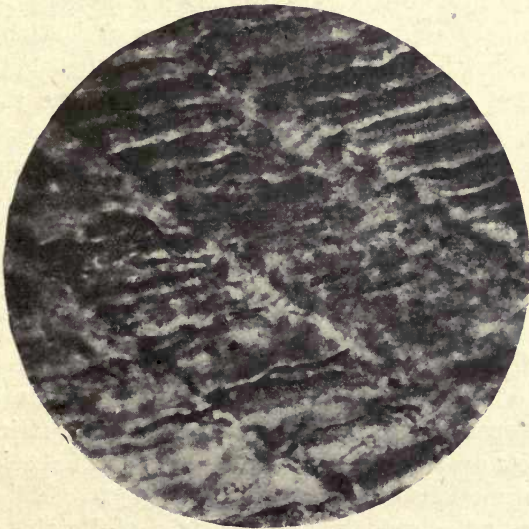


FIG. 32. Striæ of Retzius (human enamel). ($\times 750$.)

They would seem to be an indication of intermittent or interrupted calcific deposit.

Pickerill (14) speaks of the striæ of Retzius or incremental lines, and shows that they correspond with the outcrop on the surface of the enamel of the imbrication lines which he describes as giving rise to the furrows on the proximal surfaces. Underwood (19) considers that the striæ 'are due to an excessive granularity of the prisms; this granularity in each prism corresponding with that of its neighbour, the effect of a line is produced'.

Von Ebner considers they are due to the entrance of air between the rows of prisms, but they are evident in Weil preparations and in others of teeth which have not been allowed to dry. In his latest paper on enamel (6a) Von Ebner says, however, 'the typical Retzius lines, found only in permanent teeth, the contour lines, are dependent, as are also the contour bands in milk teeth, on the arrest of an early stage of development during enamel formation'. He describes the sharp brown lines as well as the brownish band-like striæ in dry sections as due to the entrance of air between the prisms, as first stated by Baume, but he speaks also of two kinds of Retzius's striæ, one in which the prisms are seen to be broken across and others which lie deeper in the enamel. He considers that both kinds of striæ are different appearances of the same structural condition, and in dry sections contain clefts or fissures enclosing air. Leon Williams says that the appearances in his photographs show that these striæ must be due to a pigmentary deposit, but he scarcely conveys this idea in the context, where he would appear to agree with Pickerill and others that they are due to incremental deposit. An appearance of pigmentation would appear to be only a characteristic of these incremental lines in the finished enamel. Pickerill considers that 'the only rational solution of such appearances is, that imbrications and striations of all varieties are to be regarded as evidence of checks in the secretive functions of the ameloblasts' (14).

He does not consider that the striæ of Retzius are due to pigmentation, as they have a different appearance by reflected and transmitted light: by reflected light appear-

ing as white bands and the intermediate substance dark.

These outcrops of the prisms in any case conform to the imbrication lines above described, and are in all probability evidences of a stratified deposition of the enamel.

As stated by Pickerill, the incremental lines are well marked in the teeth of native races, and he considers it inconceivable, owing to their practically universal presence, that they are due to any hypoplastic cause and that they must be physiologically developed structures. He shows very clearly the correspondence of the striæ of Retzius with the imbrication lines on the outer side of the enamel. He says: 'In the cervical portion, the angle of incidence' (of these lines with the surface) 'becomes progressively less and less and the ridges longer and fewer until the striæ become parallel with the surface and the ridge ceases to be distinguishable as such, but forms part of the general contour of the tooth. When the ridges cease to be apparent the striæ of Retzius also cease to be marked, although remaining distinctly visible.' In those animals where the striæ of Retzius are absent, he points out that the imbrication lines are also absent, and considers them absolutely dependent on one another. Kölliker and Walkhoff believe that all striation in enamel is due to the deposition of lime salts in strata. Certainly intermittent deposit appears to be indicated as the rule in the deposition of the hard tissues, as bone cement, &c. (see Chapter III).

Strong evidence that the striæ of Retzius are due to the outcrop of lines of prisms is afforded in floated specimens of Nasmyth's membrane. The impressions of the prisms on the clear layer of the membrane which is in immediate contact with the enamel are seen to be arranged in parallel lines (fig. 33), and these impressions show distinctly that the prisms which made them were raised above the surface of the rest of the enamel. There can be no question here of any appearances produced by grinding, such as are referred to by Von Ebner and Zsigmondy (22), as the specimen from which this photograph was taken was floated off the enamel in acid and must necessarily give an accurate view of the undisturbed surface. Pickerill was the first

to describe these impressions on Nasmyth's membrane in specimens floated off the tooth in acid after previous treatment with silver nitrate. He speaks of the dark striations visible in these preparations as corresponding 'to the furrows between each imbrication' and taking 'the stain more deeply because the pellicle is there a little thicker'. In the author's preparation, as shown in fig. 33, the ridges are impressed upon the membrane from beneath and the lines of the impressions of the prisms are seen to follow these ridges, so that both methods of preparation show the im-

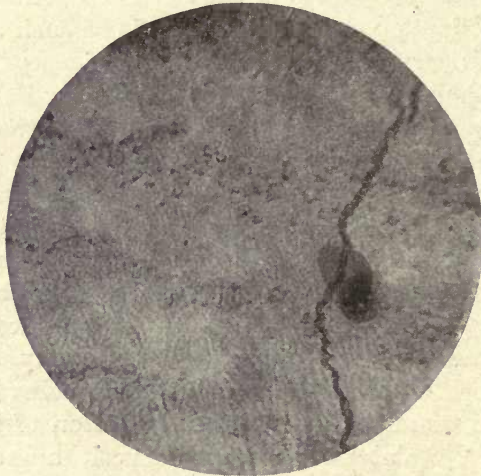


FIG. 33. Floated preparation of Nasmyth's membrane showing impressions of enamel prisms in parallel lines. ($\times 250$.)

press of the imbrication lines on the membrane. Both Von Ebner and Zsigmondy in their study of the striæ of Retzius dwell chiefly on the different appearances in ground sections of enamel. Many of these appearances are produced by grinding the sections across the incremental lines at different angles, and do not seem materially to affect the question of the actual *cause* of the striæ, which, there can be little doubt, is the deposit of the enamel in these alternating lines of growth. In hypoplastic teeth the interruption of the deposit of the enamel is very clearly shown. It can be seen in fig. 34 that the incremental line at *a* is followed by one at *b* that stops short of the normal

surface of healthy enamel indicating that the portion behind *a* was incompletely formed.

Other markings in the enamel are known as Schreger's lines. These lines, which appear white by reflected light, are said by Von Ebner to be quite invisible by transmitted light; in thin sections this would appear to be the case, but in thick sections they are seen as dark cloudy bands. Von Ebner considers that they depend upon the different directions of contiguous groups of prisms, and Pickerill speaks of them as due to the different optical densities of

Schreger's lines.

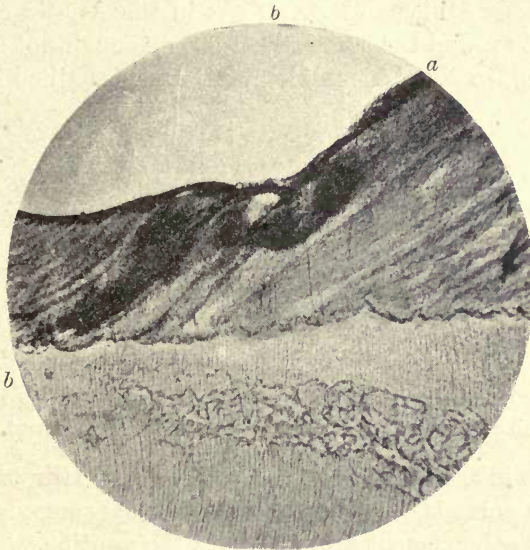


FIG. 34. Hypoplastic enamel showing incremental lines.
a, b. Incremental lines. ($\times 45$.)

contiguous groups of prisms. They are evidently due to optical phenomena and have little histological significance.

The line of junction of the enamel and dentine (fig. 34), or the amelo-dentinal junction as it is usually called, shows a festooned margin, the enamel terminating in rounded contours, the convexities of which are directed towards the dentine.

Amelo-dentinal junction.

These contours are formed by the calcified substance of the enamel and have a very strong resemblance to those at the margin of the dentine, where the coalesced calcospherites which form the calcified dentinal matrix are

advancing upon the odontogenic zone. The union of the enamel and dentine does not, however, appear to be a very intimate one, but in some mammalian teeth which have to bear great strain a much more perfect union between the two tissues is seen.

In a transverse section of the molar of the elephant, which is made up of plates of enamel, dentine, and cement, little thorn-like processes are seen projecting into the enamel from both the dentine and the cement, forming a complete interlocking of the tissues (fig. 35). This was first recorded by Professor Miller and Dr. Dieck in the Asiatic elephant. Miller also found the same structure, although not so highly developed, in the African elephant, and described a similar




FIG. 35. Transverse section of molar of Elephant showing the thorn-like processes. | *E*. Enamel; *D*. dentine; *C*. cement.

condition in the enamel of the Wart-hog and Hippopotamus, in which animals, however, the thorn-like processes proceed only from the cement and not from the dentine.

Certain spaces, the so-called 'spindles', are found within the enamel especially at, and around, the summits of the dentine cusps (figs. 36 and 37).

These are irregular areas of a more or less tubular form and are found, often in great abundance, in most human teeth. They mostly project at right angles to the dentine surface.

Waldeyer and Hertz denied the existence of these spindles on the ground that the appearances were produced by the obliquity of the sections or by fissures in the enamel, but it is difficult to understand how these observers can have arrived at such a conclusion after the examination of even a few good ground sections of human enamel. There appears

Enamel
spindles.




FIG. 36. Spindles in the enamel. From a ground section of a tooth of the neolithic age. ($\times 350$.)

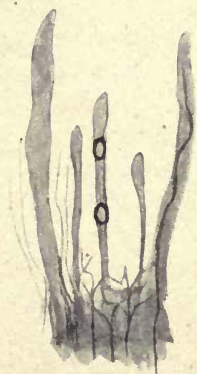

FIG. 37. Spindles in human enamel (treated with fuchsin). Dentinal tube passing into spindle. One spindle contains two air-bubbles. ($\times 500$.)

to be no reason for considering them to be pathological, for they are seen in well-formed teeth, sound in other respects, and are conspicuous in the densely calcified enamel of the teeth of prehistoric races. In several sections of human teeth prepared by the author by the Weil process these spindles are not confined to the immediate margin of the dentine, but pass very deeply into the substance of the enamel. The contents of these spaces are difficult to interpret; they usually appear to consist of amorphous granular matter, appearing quite dark, almost black, in sections. Some, however, are quite clear and transparent, and when stained from the dentine by the fuchsin method show a clear uniform coloration. Their communication with the dentine is evidenced by the passage of the stain from the tubes into their interior and by bubbles of air carried by the stain to their farther extremities (fig. 37). Römer (15) describes and figures fine corpuscles in these spindles which he considers to be nerve-end bodies forming the termination of nerve fibres in the dentinal tubes. As nerve fibres traverse the dentinal tubes it does not seem improbable that they should also penetrate any spaces in the enamel with which the tubes communicate, but although rounded bodies are certainly occasionally to be seen in these spindles they are hardly sufficiently definite to be convincing. The author found appearances very suggestive of these fine corpuscles connected by fine thread-like processes in one of the spindles of a tooth from the Stone Age (fig. 36), and it seems highly probable that such round bodies and their connecting strands may be caused by the arrangement of the granular contents of the spindles. Certainly in the majority of instances they have no appearance of being filled by any organic material.

Walkhoff holds that there is an absorption of the first-formed dentine, and some of the tubes, escaping absorption, persist as these spindles and their connecting dentinal tubes. This would not appear to account for the size and shape of these spaces, and it is a little difficult to understand by what agencies such an absorption occurs.

As described in a paper on the tubular enamel of marsupials (11 b) the author found apparently identical spaces

or spindles in marsupial teeth. In the incisor tooth of one of the Kangaroo-rats many similar spaces filled with granular matter were found half-way across the enamel and a few near the free margin (fig. 38). These spaces communicate with dentinal tubes, and it is significant that in those marsupials in which the tube system is much reduced, bodies exactly like the spindles in human enamel are found at the amelo-dentinal junction and also deeper within its substance, and dentinal tubes are often seen

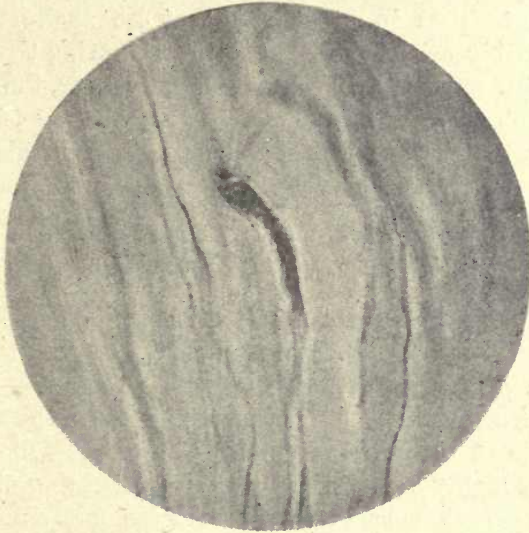


FIG. 38. One of the terminal bulbs in the enamel from the same specimen shown in fig. 56. ($\times 250$.)

passing into these spaces, crossing them and terminating more deeply in the enamel. For this and other reasons dealt with more fully in the section on tubular enamels one would look upon these spindles as due to imperfections in the calcification of the interprismatic substance. The dentinal tubes certainly enter them in many places, but they are not dilatations of these tubes but spaces into which they enter. Von Ebner, writing in 1890, says that the fissure formations in human enamel are the result of a drying up or shrinking of the interprismatic cement substance (6*b*). Pickerill (14) also describes them as 'interprismatic spaces

combined with the poor formation of the cement substance and of the outer portion of the prisms, due to the enamel organ at the time not having acquired a perfect function'.

That dentinal tubes pass into human enamel in places there can be no doubt; they are seen to do so in a great number of preparations, both stained and unstained. This is, however, doubted by Pickerill, who considers the appearance of tubes crossing the boundary line is due to the overlapping of the dentine and enamel.

In properly stained preparations, however, these tubes are seen to pass in so deeply that no such confusion could possibly arise, good thin sections showing the enamel and dentine quite clearly separated. Moreover, the fuchsin method also shows, as referred to above, that the laminae between the horizontal layers of prisms also stain. Pickerill was quite unable to convince himself when using the Von Beust method of staining with alcoholic fuchsin, taken up from the pulp cavity by capillary attraction, that stained tubes passed into the enamel from the dentine. It is a little difficult to understand why he failed to see them, as by this method the spindles and the tubes are often deeply stained and in many places air-bubbles have preceded the staining fluid to the ends of the spindles. He also is of opinion that 'it by no means follows that because a highly volatile and deeply penetrating stain like alcoholic carbol fuchsin¹ may pass occasionally across the amelo-dentinal junction that serum or lymph would do the same'. It surely is inconceivable that a staining solution, which after all is not so highly volatile, should pass into a dead tissue more perfectly than the fluids of the living body in a living tissue.

It seems much more probable that the permeation by serum or lymph from the circulating blood would be more thorough than that obtained by any artificial stain.

If this contention were true it would nullify the value of any stains, alcoholic or other, in demonstrating the existence of channels or spaces in a tissue. What is usually required in histological investigation, especially on the teeth, is

¹ Carbol fuchsin is not employed, but a simple solution of fuchsin in alcohol.

a stain which shall be capable of penetrating as perfectly as possible.

In accordance with the author's views on the nature of tubular enamel, the fact that the tubes of the dentine occasionally penetrate the enamel in human teeth can be well understood.

We find penetration of the enamel by dentinal tubes the main characteristic of the tissue in the marsupials, and we also see a similar penetration in other orders of the higher Mammalia, as Hyracoidea, Rodentia, and Insectivora,

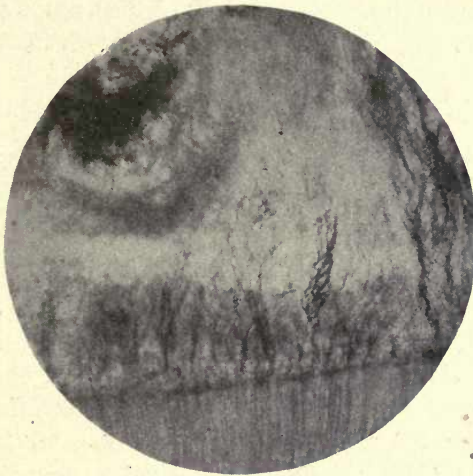


FIG. 39. Fibrous bundles at amelo-dental junction.
Hypoplastic enamel. ($\times 50$.)

which show a reversion to the condition in the marsupials, and in human teeth we have an indication of survival of, or reversion to, the tubular enamel of these other orders of the Mammalia.

Imperfections of structure at the dentine margin are frequently met with in human enamel, areas in which both prisms and interprismatic substance have a coarsely granular appearance.

Radiating bundles of fine fibres are also very frequently seen which appear to be connected with dentinal tubes entering the enamel (fig. 39). These defects of structure are much more apparent at the amelo-dental junction

than elsewhere, the probable reason for which will be considered in treating of the development of enamel.

Tubular Enamel

Tubular enamel may be described as an enamel which is normally penetrated by tubes either from the dentine or from its outer surface.

The penetration of the enamel by tubes from the dentine is seen in many fishes, in marsupials in its most complete form, and also in the Hyracoidea (in *Hyrax*), among Rodentia in the Jerboa (*Dipus*), and in the Insectivora in the Shrews (*Sorex*).

Penetration by tubes from the *outer* surface of the enamel is often found in fish.

In the Plagiostomi it is seen in *Cestracion*, *Lamna*, and in many sharks both recent and fossil, and among osseous fish, in the Gadidæ, Labridæ, and Sparidæ or sea-brems, being especially well marked in the genus *Sargina*, and the enamel of a member of this group, the *Sargus ovis* or Sheep's Head fish, has long been taken as the typical example of this penetration from the outer surface of the enamel. The outer layer of the teeth of Plagiostome fish differs in some respects from the enamel of higher forms, for besides the penetration by tubes it shows a marked transverse striation and contains lacuna-like spaces, and in some examples, as *Lamna*, there is a differentiated outer layer. From a study of the mode of development of this structure in Elasmobranch fishes, C. S. Tomes (18 *d*) concludes that the outer hard layer in the teeth of Selachia and Ganoid fish corresponds neither to the dentine nor the enamel of Mammalia. Having no collagen matrix it cannot be looked upon as dentine, 'while', he says, 'its organic matrix is beyond question furnished by the mesoblastic dentine papilla, the epiblastic ameloblasts over it are in a state of development which implies that they take an active part, and that the tissue is a joint production'. He considers that the part played by the ameloblasts is probably the elaboration of the calcifying salts in this enamel-like substance. In his classification of enamels,

Tubular
Enamel
in Fish.

he places it under the heading of 'Enamels which are not wholly epiblastic', 'a tissue which is laid down by the operation of epiblastic ameloblasts in a matrix which is derived from a modification of the surface of the mesoblastic dentine papilla. Röse is, however, inclined to look upon these tissues as dentine, but on the whole of the evidence afforded by the structure and development of this tissue in Elasmobranchs, Tomes considers it may be appropriately called 'enamel'.

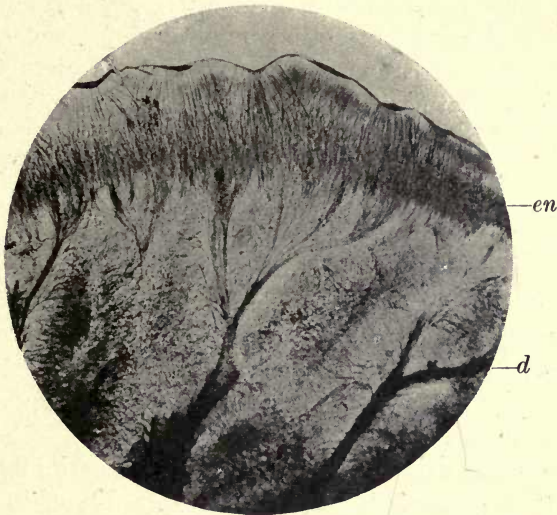

FIG. 40. Enamel and osteodentine of *Heterodontus* (*Cestracion*). Fuchsin stain by capillary attraction. ($\times 50$.)

In *Cestracion Philippi* (*Heterodontus*), the Port Jackson shark, tubes are seen to penetrate the outer layer from without, as well as from the dentine. This fish is of especial interest, as the family to which it belongs, represented by four species, are the sole living representatives of a family of fishes which were the most characteristic and abundant sharks of the Mesozoic Period.

Heterodontus
(*Cestracion*).

Their rounded teeth are eminently adapted for crushing the hard-shelled animals which form their food. The surface of these teeth is marked by rows of little pits or depressions, and a longitudinal section shows radiating lines passing from the bottom of these pits into the enamel. When

treated with alcoholic fuchsin, these radiating lines are strongly coloured by the stain, and a broad band of more diffuse staining passes a little way into the enamel at the base of the depressions (fig. 40).

The large tubes of osteodentine which form the bulk of the tooth give out tree-like branches that divide and subdivide, their ultimate fine ramifications passing outwards and crossing and mingling with the tubes from the outer surface. Fine tubes also pass into the enamel from all parts of the outer surface, although larger and more deeply penetrating in the radiating bundles which start from the base of the depressions. The two systems of tubes appear to communicate with one another at the inner margin of the enamel by their finest subdivisions. The line of junction between enamel and dentine is very imperfectly defined, but in most sharks the boundary line is much more distinct.

In many sharks the tubes from the osteodentine enter the enamel more or less in bundles and branch and anastomose within it, forming a network. Many of the dentinal tubes enter lacuna-like spaces in the enamel. The tubes from the outside enter in more or less parallel straight lines, and appear to communicate with the dentinal system in the deeper part of the enamel.

In *Lamna cornubica* (the Porbeagle shark, fig. 41) the typical osteodentine core sends large branches into the enamel, which also shows traces of lamination and short transverse markings. The delicate striæ from the outside take the stain faintly and the blending of the dentine and enamel at their junction is imperfectly defined as in *Cestracion*. These markings or striæ from the outside have not been hitherto shown conclusively to be of a tubular nature. Tomes speaks of them as striæ and considers it doubtful whether they are of a tubular nature or merely distinctly shown prisms, and says he has never been successful in getting coloured fluids to enter them (18 e).

The author has shown, however, that, in the sharks, in the *Sargus*, and in all the other fishes examined for this purpose, the markings are most certainly tubes, and are quite independent of the columns of prisms which are also seen at the margin of the enamel following a course parallel

to that of the tubes, but quite unstained. The fuchsin method before referred to was adopted in this investigation, and the stain was found to enter the striæ from the outer surface of the enamel and penetrate them to their terminations. The prisms of the enamel are easily distinguished from the tubes, showing that the enamel columns and the striæ are not identical, as has been suggested.

In *Sargus ovis*, the Sheep's-head fish of the United States, *Sargus*. the tubes, which are very strongly marked, pass into the

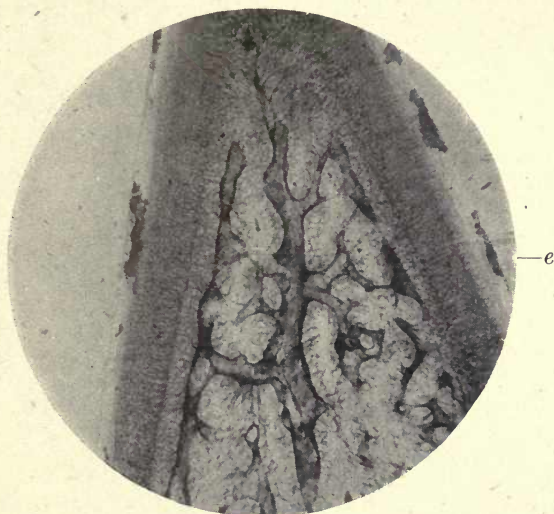

FIG. 41. Osteodentine tooth of *Lamna cornubica* (Porbeagle Shark). Osteodentine centre; tubes radiating from medullary channels. *e*. Enamel. Fuchsin stain by capillary attraction. ($\times 50$.)

enamel at right angles to its surface, and about half-way across its width bend right and left, crossing one another on its inner third, and terminating at a line of dense calcification which forms a dark band following the contour of the dentine surface, and separated from it by a narrow clearer space. The tubes do not reach the dentine in any part (fig. 42). The very complicated pattern in drawings and photographs of *Sargus* enamel is only due in part to the ramifications of the tubes, which can be easily followed in the stained preparations, for the densely calcified band of enamel near the dentine is formed by the exceedingly intricate and complicated course of the prisms.

This is clearly shown in ground preparations, the red-stained tubes being sharply relieved against the unstained yellowish enamel. In his work on dental histology Mr. Hope-well Smith says 'the tubes are found in the longitudinal axes of the enamel rods'; that this is not the case is very evident in the preparations here referred to—the tubular system is completely independent of the enamel rods as shown both in the completed tissue and in teeth in the course of development. This band near the dentine appears

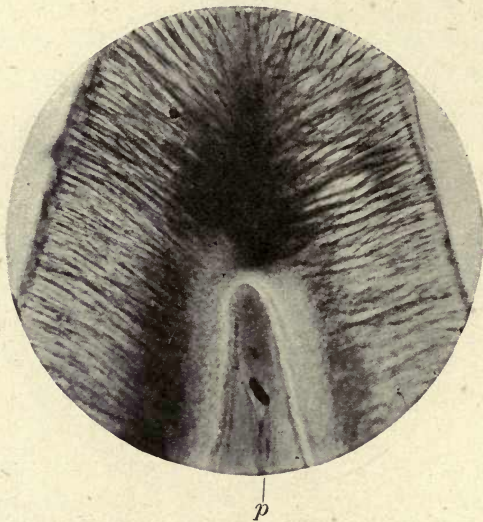


FIG. 42. *Sargus ovis*. Incisor tooth (stained with alcoholic fuchsin by capillary attraction). Within the pulp (*p*) are seen the vascular channels shown in fig. 160 (here cut across). ($\times 50$.)

to be made up of prisms very intricately arranged, and it is quite impossible to trace the course of individual prisms. This pattern can be seen in the abundant organic matrix of the enamel which is laid down in the early stages of its development before any calcification has commenced. In many preparations in which the enamel cap was quite soft and easily cut with a knife the same pattern of twisted and spirally arranged prisms was seen, and such preparations took stains deeply. In the fully-formed tooth a clear area is always to be seen between this layer and the dentine (fig. 43). The first preparations of *Sargus* enamel examined by the

fuchsin staining method were from a dry preparation of the upper and lower jaws of a Mediterranean species of *Sargus*, *S. noct*. In this fish, unlike *S. ovis*, there is a very free penetration of tubes from the dentine as well as from without. In fig. 43 it is seen that the dentinal tubes enter the enamel in radiating bundles and pass right across it, interlacing with the tubes from the outside. At the dentine margin they spread out a little from the close bundles and bend slightly towards one another before spreading out into the enamel.

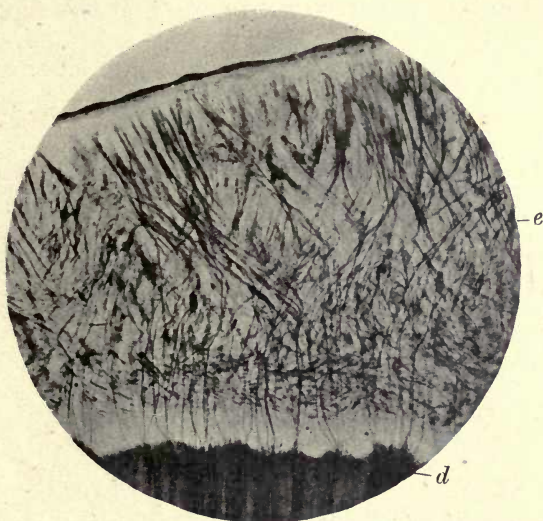

FIG. 43. *Sargus noct*. Completed enamel.
d. Dentine; e. enamel. ($\times 50$.)

These dentinal tubes are very abundant and deeply stained; many can be followed to their terminations close to the free margin, while others are lost in small oblong bundles of tubes formed by those of the outer tube system. These two separate systems of tubes crossing one another in many directions form, with the twisted and spirally arranged prisms, a more intricate and complicated pattern even than in *Sargus ovis*. Many of the tubes from the dentine divide and branch, as do also those from the outside, but the majority of the tubes of both systems pass in more or less even curves across the enamel, interlacing with one another. This penetration by both sets of tubes does not appear to

have been hitherto described in the Sparidæ, as the species examined had always been *S. ovis*, in which there is no penetration by tubes from the dentine. Another species of *Sargus*, *S. vulgaris*, also shows penetration by dentinal tubes, but they only penetrate for a short distance, terminating at the densely calcified layer of prisms above described.

We see, therefore, that in the same genus (*Sargina*) there is a very complete penetration by both systems of tubes in *Sargus noct*, a partial penetration from the dentine and

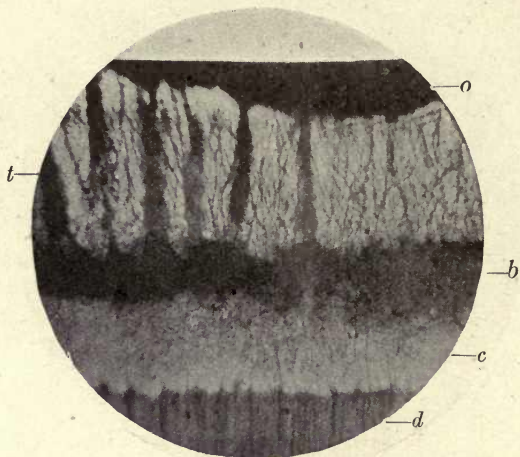


FIG. 44. *Sargus noct*. Unerupted molar. *o*. Remains of enamel organ; *t*, open deeply stained channels in the enamel; *b*, stained horizontal band; *c*, unstained enamel; *d*, dentine. ($\times 50$.)

a full one from the outside in *Sargus vulgaris*, and a complete suppression of the dentinal tubes in the enamel of *Sargus ovis*, only the tubes from without being present. It is not usual to find such a marked difference of structure in the enamel in species belonging to the same genus.

In the Sparidæ the teeth replace one another vertically instead of laterally as in most fish. The successional teeth lie immediately beneath those in use and within the substance of the bone.

If the enamel of these unerupted teeth is examined by the fuchsin method it is seen to differ very considerably in appearance from that of the erupted teeth (figs. 44 and 45).

The tubes from the outside have very widely open orifices and are stained deeply in broad vertical stripes within the enamel; these broad bands pass about half-way across and then become fused in a deeply stained area which extends horizontally across the enamel, being sharply limited at the lower margin by the band of calcified prismatic material previously described. If a tooth is examined which is a little farther advanced towards eruption, the stained horizontal band is seen to be broken up, only a few

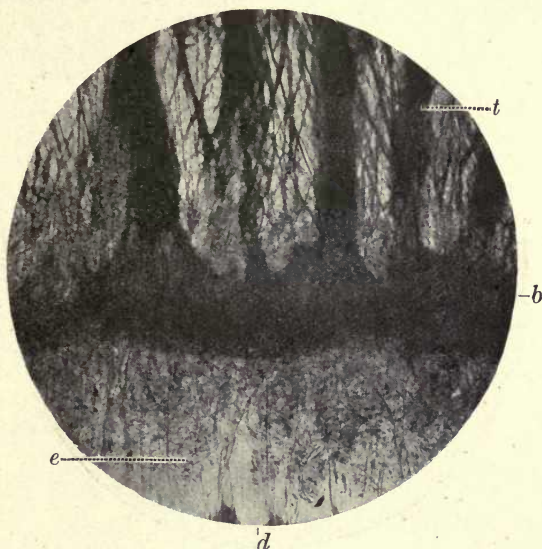


FIG. 45. As fig. 44, more highly magnified. *t*. Stained channels; *b*. horizontal stained band; *d*. dentine; *e*. enamel prisms. ($\times 130$.)

patches of stained material being seen in its former position, but many of the entering stained spaces are still very wide and show laterally expanded areas. All stages of this gradual contraction of the stained area are to be seen in the molar teeth in different stages of development, to the completed enamel of the tooth in wear.

From these appearances it seems impossible to avoid the conclusion that these tubes have a calcifying function, conveying the lime salts to the organic foundation substance of the enamel previously laid down. In no instance could this stained horizontal band be seen to pass beyond the

layer of dense enamel (fig. 44, c), which would suggest that this layer bordering the dentine had been calcified previously to the calcification of the main bulk of the tissue. A study of the development of the enamel in these fish probably gives the true explanation of this appearance. As shown elsewhere (p. 186), the part near the dentine appears to be laid down under the influence of true ameloblasts; after its formation the ameloblasts disappear as such and the remainder of the enamel is deposited by a structure which has assumed the form of a vascular secreting organ.

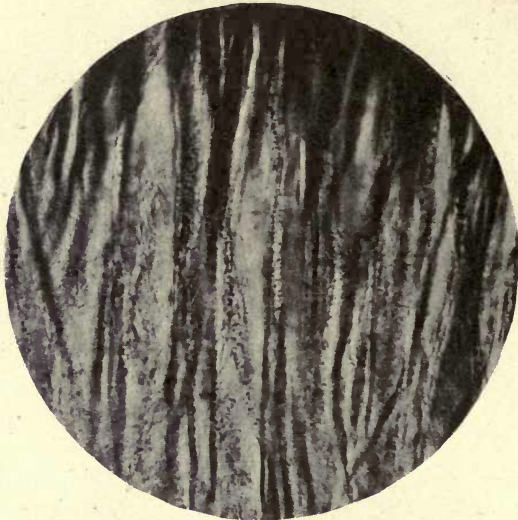

FIG. 46. *Sargus noct.* Granules in tubes of enamel of unerupted tooth. ($\times 250$.)

In many sections of these unerupted teeth of *Sargus* the tubes are seen to be closely packed with small dark granules which do not take the stain and which would appear to be the calcifying substance conveyed to the enamel (fig. 46). The principal points brought out by this investigation are :

1. That the enamel of *Sargus* and many other fish which show this outer striation is penetrated by tubes into which a stain freely passes, their tubular nature being still further evidenced by the presence of small granules which are seen not only at the circumference but also deeply in the enamel near their terminations.

2. That in the Sparidæ a tube system from the dentine is fully developed in some species, the outer and inner systems of tubes existing together.

3. That a progressive calcification of the larger part of the enamel takes place in its interior in teeth that have not yet come into use, and that this process is continued by the agency of the tubes and their contents.

In the group *Scarus* of the Labridæ (Wrasses) there is a still more complete penetration by tubes from without than in *Sargus*. In the specimens examined the tubes took




FIG. 47. Tubular enamel of *Pseudoscarus*. *d.* Dentine ;
e. enamel. ($\times 50$.)

the stain freely, entering the enamel in parallel straight lines as in *Sargus*, but more intricately crossed and interwoven in the deeper parts than in any of the Sparidæ. The enamel of the pharyngeal teeth of *Scarus* forms a very thick investment to the tooth, and the tubes, after passing in for about one-third of its width, cross one another in all directions and course along the dentine margin parallel to its surface, but appear to have no connexion with it, at all events in the species of *Scarus* examined. Fig. 47 shows the great abundance of these tubes and the complicated pattern which they form. A very remarkable peculiarity of these teeth of *Scarus* is the very small amount of dentine in comparison with the bulk of the enamel seen in most specimens, both of the pharyngeal teeth and those

of the beak-like jaws. Large tubes resembling those of a true vascular dentine are seen in the dentine and in several places even entering the enamel. They not only form loops at the amelo-dentinal junction which encroach upon the enamel, but broad tubes pass in several places well into its substance. These are not merely the small isolated loops described by C. S. Tomes in *Sargus*, but they form a connected system (fig. 48).¹

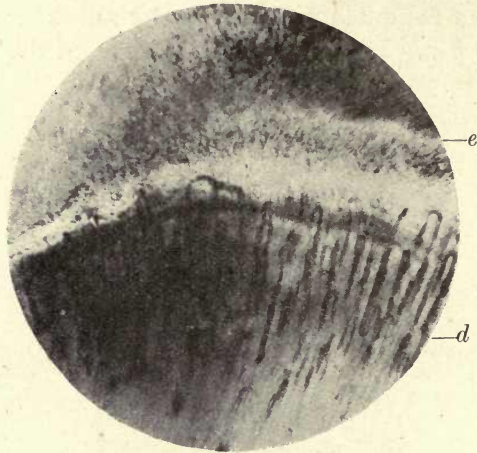


FIG. 48. Vascular loops in tooth of *Pseudoscarus*. e. Enamel; d. dentine. Ground section. ($\times 150$.)

In the maxillary teeth of *Scarus*, according to Von Boas (4), the dentine is much more reduced than in the pharyngeal teeth, and he considers that a resorption of the dentine occurs after its first formation and describes absorption contours or Howship's lacunæ between the enamel and dentine.

In a freshly preserved specimen of *Pseudoscarus*, kindly sent to the author by the Curator of the New York Aquarium, he found confirmation of these observations of Von Boas, as shown in fig. 49, photographed from preparations from this specimen. In many places absorption lacunæ are seen between the enamel and the dentine in the superimposed teeth of the maxilla. These can also be seen in the pharyn-

¹ A similar condition in the crown of the incisor teeth of *Sargus ovis* is described on p. 258.

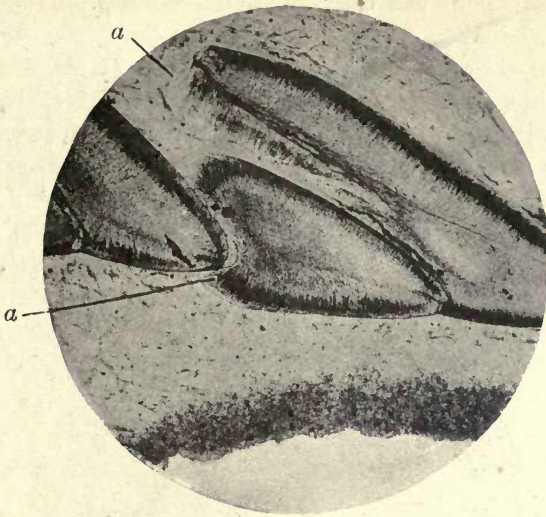


FIG. 49. *Pseudoscarus*. The maxillary denticles—the dentine is almost entirely absorbed, the bulk of the tooth consisting of the tubular enamel. Ground section of freshly preserved preparation. ($\times 60$.)

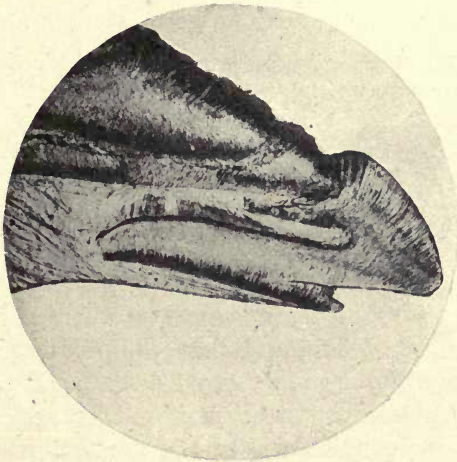


FIG. 50. *Pseudoscarus*. Margin of jaw showing one of the maxillary denticles in use—both enamel and dentine have undergone absorption. Ground section from a freshly preserved specimen. ($\times 60$.)

geal teeth where vascular loops encroaching on the enamel are also visible.

Fig. 50 shows one of the teeth in use at the margin of the maxilla, which has undergone very extensive absorption of the dentine, and also of the enamel where the successional denticles are advancing. Fig. 49 also shows the excavation of the denticles farther back in the jaw, the dentine at *a*, as in fig. 50, having almost entirely disappeared. Fig. 51




FIG. 51. Section of upper jaw of *Pseudoscarus* showing arrangement of denticles in the bone. ($\times 10$.)

shows under lower magnification the superimposed teeth of the maxillary bone of *Pseudoscarus*.

The Tubular Enamel of Marsupials

The tubes in marsupial enamel are entirely connected with the dentinal tubes, and there is no penetration of the enamel from without as in many fish.

The determination of the exact nature and significance of this tubular condition is of the greatest importance in the study of the development of marsupial enamel and of mammalian enamel generally, and will be considered more fully in the chapter on 'Development of the Enamel'.

Sir John Tomes (17 *a*) in 1849 first described the existence of tubes in the enamel of marsupials, continuous with those of the dentine. This fact was denied by Waldeyer and Hertz, but, as C. S. Tomes says, 'it is very difficult to understand how any one looking at a section of a tooth of the Kangaroo or Wallaby could have any doubts on this point'. J. Tomes, moreover, showed that when marsupial enamel was decalcified the tubes were seen hanging out from the dentine after the removal of the lime salts.

In all marsupials, with the exception of the rodent-like Wombat, these tubes can be seen; but they are not by any means developed to the same extent in the different families of marsupials, where all degrees of penetration are seen—from the very complete one in *Macropus* to the scanty development of the tubes in many Phalangers. In *Macropus* the tubes not only enter in great abundance but traverse nearly the whole width of the enamel, in many places terminating just beneath the outer border.

If a ground section of the enamel of *Macropus* be examined under the microscope it is seen that the dentinal tubes pass across the boundary at the amelo-dentinal junction, and enter irregular dilatations or spaces, whence they are continued in more or less parallel lines into the enamel. A uniform bending of the tubes at an obtuse angle near the dentine is a very frequent appearance in marsupials.

The dilatations above referred to vary greatly in size and contour, and in some places are altogether absent, the tubes passing from the dentine directly into the enamel, as seen in many parts in the teeth of the Hypsiprymninæ. When teeth of the Wallaby or Kangaroo are examined which have been injected with alcoholic fuchsin from the pulp cavity, the stain is seen to have passed uninterruptedly across the boundary and along the whole length of the tubes. The interprismatic substance also shows a diffuse staining in places; in fact, in many of these sections the enamel appears to be more fully stained than the dentine (figs. 52 and 53 A, B).

This method of staining demonstrates very clearly the continuity of the enamel tubes with the dentinal tubes. In some sections of the teeth of *Bettongia* (fig. 54), one of

Terminations of tubes in *Bettongia*.

the Kangaroo rats, treated with silver nitrate by the process of Ramon y Cajal, the matrix of the enamel is uniformly stained of a yellowish brown, the tubes are very deeply stained and vary greatly in diameter, and very fine cross-branches pass horizontally at right angles to the tubes; these are also seen in some sections of the teeth of *Macropus*, and their origin is a little difficult to understand. Similar cross-branches are described by Sir John Tomes in the enamel of the rodents. This uniform staining of the matrix is not seen in other mammalian enamels, and would appear to indicate that in these animals it is not so completely calcified as in higher forms. Another appearance in the incisor teeth of *Bettongia* has a very strong bearing upon the disputed question of the origin of the tubes in marsupial enamel. In about the middle third of the length of the long lower incisor of *Bettongia*, many of the tubes from the dentine, after passing half-way across the width of the enamel, terminate in bulb-like closed ends; these terminations being directed towards the enamel surface and not towards the dentine would appear to indicate that they are true dentinal tubes, and not tubes of enamel origin which have become connected with them, according to the view of the nature of the tubes in marsupial enamel held by C. S. Tomes (figs. 38 and 55).

In the Cuscus (*Phalanger orientalis*) the tube system is very much reduced, but similar bulb-like terminations are seen, many of which are quite near the dentine and others farther within the enamel substance. These bulb-like endings have a great similarity to the so-called spindles seen in human teeth (see p. 78), and probably have a similar origin in areas of imperfect calcification of the interprismatic substance. A comparison of figs. 37 and 56 will demonstrate the great similarity between the spindles in human enamel and these expanded terminations of the tubes in marsupials. In the *Phalanger* (fig. 56 A) the tubes from the dentine are in many places seen to enter these spaces, and after traversing them to pass out on their distal ends and terminate deeper in the enamel. This is also occasionally seen in the similar spaces in human teeth, but tubes so prolonged do not pass in so deeply as in marsupials (fig. 56 B).

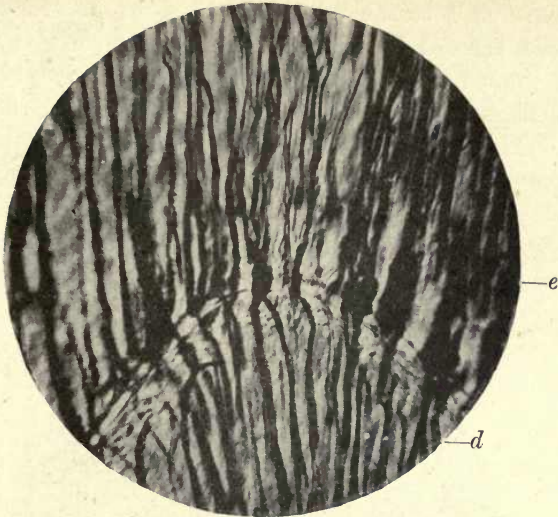

FIG. 52. Dentine and enamel of *Macropus* injected with fuchsin from the pulp cavity. *d.* Dentine; *e.* enamel. ($\times 250.$)

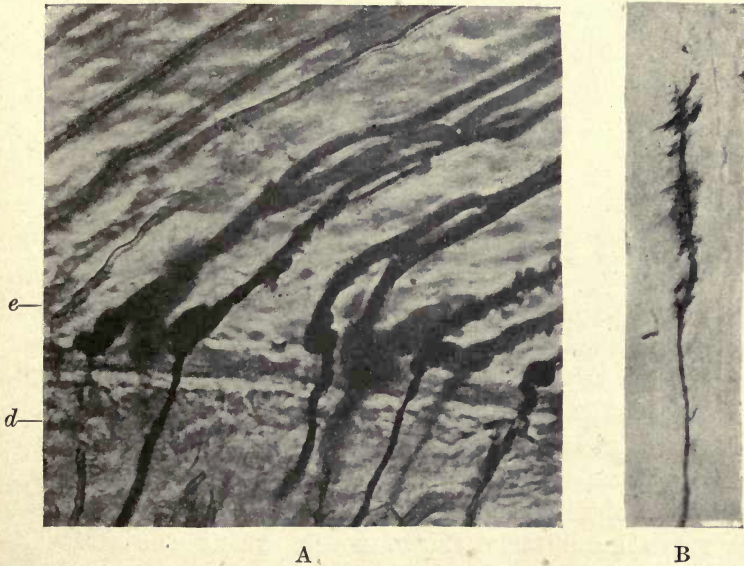


FIG. 53. A. Enamel of *Macropus*; tubes at enamel margin. Fuchsin injected preparation. *e.* Enamel; *d.* dentine. ($\times 700.$)

B. Showing the escape of the fuchsin stain from the tube into the surrounding imperfectly calcified fibrillar basis substance. ($\times 250.$)

Transverse sections of the enamel of *Macropus* which had been treated by the fuchsin method showed that the interprismatic substance is abundant and is deeply stained, and in some places there is a faint staining of the prisms themselves (fig. 57). The transverse sections of the tubes are much more deeply stained than the interprismatic substance, and are seen to be lying within this interprismatic substance and not within the prisms. In those sections that are directly transverse, the author could find no tubes

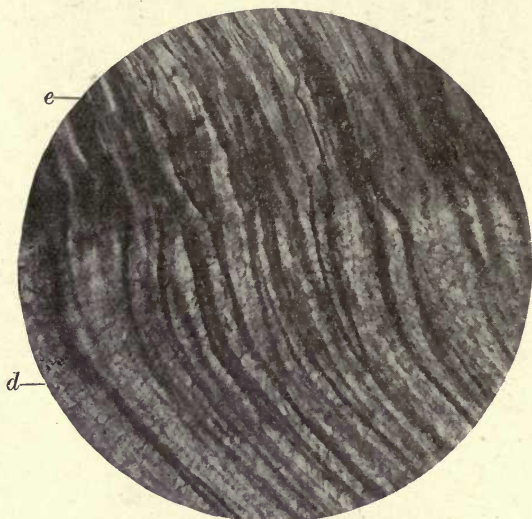


FIG. 54. Passage of dentinal tubes into the enamel in Bettongia. Weil ground section. *e*. Enamel; *d*. dentine. ($\times 150$.)

that could be considered to be within the prisms. Here and there one is seen which at first sight might be thought to be within the prism, but careful focusing shows that this appearance is caused by the spiral course of many of the tubes which are seen through the thickness of the sections. In very thin preparations, which are very difficult to obtain, the author cannot but consider that the tubes are indubitably shown to lie within the stained interprismatic substance.

C. S. Tomes describes transverse sections of marsupial enamel in which he says that three-fourths of the tubes appear clearly to be in the substance of the prisms, the

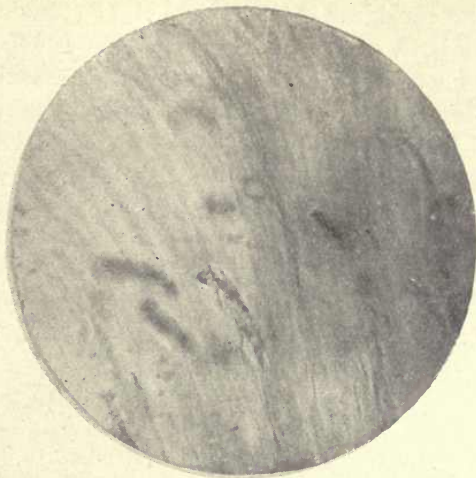


FIG. 55. Spindle-like bodies terminating dentinal tubes within the enamel of Bettongia. Ground section. ($\times 50$.)

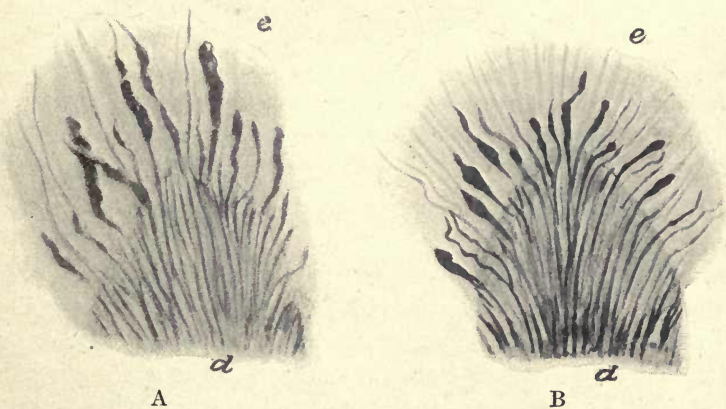


FIG. 56. A. Longitudinal section at apex of dentine cusp of *Phalanger orientalis* showing tubes passing into enamel and others entering the spindle-shaped spaces. *d*. Dentine; *e*. enamel. ($\times 130$.)

B. Section in same position of human temporary molar injected with fuchsin from pulp. ($\times 130$.)

remaining fourth appearing as though they were between them, but he considers it is *a priori* highly improbable that they occupy both positions. Von Ebner (6*b*) considers that the tubes lie between the prisms in the interprismatic spaces, and his figure of transverse marsupial enamel shows, according to C. S. Tomes, that all but one appear to do so; the drawing, however, scarcely indicates that *one* lies within the prism, and any appearance of its so doing may probably

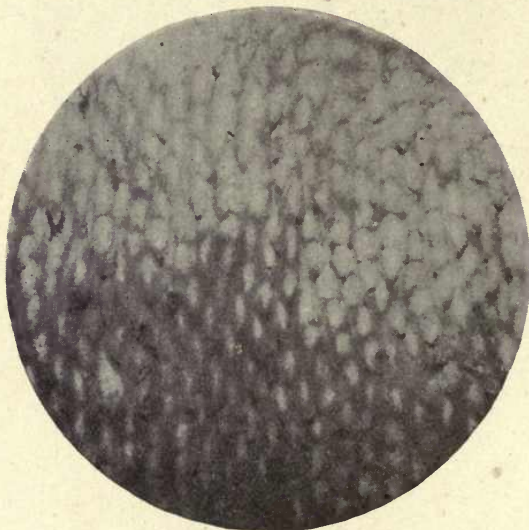


FIG. 57. Transverse section of enamel of Macropus (injected with fuchsin from the pulp cavity). Interprismatic substance strongly stained and transverse sections of enamel tubes more deeply stained and within the interprismatic substance. ($\times 800$.)

be fully explained as being due to the thickness of the section.

J. Tomes (17*a*) and Kölliker considered there was no doubt that the dentinal tubes pass into the enamel. This is denied by Waldeyer. Von Ebner agrees with Kölliker and J. Tomes. The passage of tubes from the dentine to the enamel is held by Von Ebner to be analogous to the ingrowth of nerve fibres into epithelium. He says it is evident that in young marsupial teeth the canals run in the interprismatic substance. By decalcification experiments he showed that the tubes held together and had much the appearance of elastic

fibres, and he states that one could see by such experiments that the floating tubes are isolated twisted objects and are not held together by any membrane. In the author's decalcification experiment to be presently described, a distinct fibrillar basis to the enamel remained, in which these tubes lay.

From an examination of his own stained preparations the author considers there can be no doubt that the tubes lie between and not within the prisms. Professor Von Ebner and Professor Paul both consider that the tubes lie between the prisms, but C. S. Tomes looks upon the tubes of marsupial enamel as canals in the centre of the prisms, considering that calcification in marsupial and other mammalian enamels takes place centripetally, leading in some cases to the complete obliteration of the central channel as in human teeth, in others not reaching the centre and so leaving tubes within the prisms; there is a squeezing up, as it were, of the central canal by the advancing calcification. According to this view there would be no true interprismatic substance in enamel, calcification with regard to the prisms proceeding from without inwards. The tubes in the enamel of marsupials are, he considers, entirely a product of the enamel organ and cannot properly be called dentinal tubes, and their connexion with the dentinal tubes he would look upon as a joining up of the enamel tubes with those of the dentine.

One cannot but consider, however, that the evidences given by finished structure and development are very strongly in favour of the existence of a very distinct interprismatic substance, and further corroborative evidence has lately been advanced in the paper by the late Dr. Black on the curious endemic disease of the teeth in the Rocky Mountains above referred to, where the interprismatic substance appears to be the sole part of the enamel affected (see p. 71).

It would appear that the organic basis of marsupial enamel is more persistent than that of the enamel of the higher mammalia.

If a piece of a ground section of marsupial enamel and dentine is decalcified on a slide, with suitable precautions,

to prevent the disturbance and washing away of the dissolving enamel which usually occurs in these experiments, a residue, indestructible by acids, is left which retains the form and arrangement of the calcified tissue faintly indicated on the slide. In the author's experiment a thin ground section of the enamel and dentine of the Kangaroo (*Macropus rufus*) was stained with toluidin blue and placed in a drop of Farrant's solution on a microscope slide. Strong hydrochloric acid was added drop by drop to the Farrant solution and the action watched under the microscope. No cover-glass was used and the specimen was not disturbed by the action of confined bubbles of gas. Decalcification proceeded very rapidly, and, when all the calcified enamel had disappeared, the tubes were seen lying in a faintly-tinted fibrillar stroma and had retained their positions as in the formed tissue. The whole contour of the piece of enamel could be traced upon the slide, and the tubes were so little disturbed that their characteristic bending in parallel lines near the dentine, so commonly seen in the enamel of *Macropus*, was quite evident. The decalcification experiment described by Sir John Tomes was carried out in a watery medium and the delicate stroma was not retained as in the dense medium employed by the author, but he was able to demonstrate that the tubes passing from the dentine to the enamel retained their form and could be seen waving about in the acid solution.

Further evidence of the delayed or only partial disappearance of the organic basis of marsupial enamel is also seen in the stained preparations of the completed tissue. As shown in fig. 53 B, in many places the stain has penetrated from the interprismatic spaces into a delicate fibrillar structure within the matrix of the enamel; this would appear to be a portion of the organic basis which has escaped calcification and has taken the stain as freely as the interprismatic spaces themselves, which certainly in *Macropus* appear from their staining reaction to have undergone in many places very little or no calcification.

Enamel of *Hyrax*. The enamel of *Hyrax* (the biblical Coney) is very completely penetrated by tubes from the dentine which pass in many places all across it to the outer margin. At the junc-

tion with the dentine there is no appearance of the spaces into which the tubes pass, so conspicuous in the enamel of *Macropus*. The tubes bend slightly and often branch at their entry into the enamel, but otherwise pass uninterruptedly across the boundary. In other respects the enamel is very similar to that of marsupials, but the absence of the dilatations points probably to a more complete calcification of the interprismatic material in *Hyrax*, a point which will be further considered in treating of the development and calcification of the enamel in marsupials.

As previously mentioned, penetration of the enamel by tubes continuous with those from the dentine is also seen in the shrews (*Sorex*), among the Insectivora, and in the Rodents in *Jerboa*. Slight penetration of the enamel from the dentine is also seen in many Carnivora (18 f), and has been described by the author in the molar tooth of the Elephant (11 a), and may often be seen in human teeth where occasionally scattered tubes penetrate to a considerable depth.

These examples of tubular enamel, as Tomes says, 'distinctly point to this penetration of the epiblastic enamel by tubes continuous with those of the mesoblastic dentine, being a primitive character, to which some slight tendency to revert has not been quite lost by placental mammals'.

Owing to some resemblances to the dentition of marsupials found in the teeth of Creodonts, C. S. Tomes was led to examine numerous teeth of this fossil sub-order (the members of which are considered by most authorities to be the ancestors of the Carnivora, and possibly also of the Insectivora), and to determine if the histological characters of the teeth showed any resemblance to those of marsupials. The conclusions he arrived at from the examination of teeth of *Hyenodon*, *Mesonyx*, and many other forms, were that, so far as the structure of the enamel was concerned, none of these animals show any greater resemblance to marsupials than do the recent Carnivora, but the patterns of the enamel in Creodonts closely resemble those of the Carnivora. Tubular enamel was not found in the teeth of the Creodonts examined, and so far as the histological evidence is concerned, they do not show any affinity to marsupials (18 f).

Creodonts.

The Enamel of Rodents

There are certain peculiarities in the enamel of the Rodents which render it advisable to consider its structure in a separate section.

The incisors of Rodents are of great length and very large in proportion to the other teeth ; they extend a long way back in the jaws and describe a sharper curvature in the upper than in the lower jaw.

The exposed portions of these incisors terminate in a chisel-shaped edge produced by the unequal wear of the three tissues which make up the tooth. The dentine core is coated with enamel, which is confined to the outer or anterior surface, and with cement beneath. The cement does not cover the surface of the enamel as was originally stated by Owen, but in the Rodent-like marsupial, the Wombat, the enamel has an external covering of cement. The unequal wear of the three tissues gives rise to the sharp cutting edge, the cement wearing down most rapidly, the dentine less so, and the enamel least, so that the latter tissue projecting beyond the others forms a sharp chisel edge to the tooth. As the wear rapidly proceeds at this free edge the tooth is maintained at the same level by constant advance from behind, the additional growth taking place during the whole life of the animal from its persistent pulp, and the curvature of the teeth in the jaws preventing injury to this pulp from direct pressure. The incisor teeth of many rodents show a deep orange coloration of the enamel on the outside. This pigmentation is confined chiefly to the outer surface, but penetrates some little distance within the enamel substance, gradually fading away towards the dentine. This coloration is very strongly marked in the Porcupine, Beaver, and Squirrel, but is absent in the Hares and Rabbits. The molar teeth of the Capybara and Beaver and of the Hares and Rabbits also grow from persistent pulps. In the Capybara (*Hydrochærus*) the large molar tooth is built up of a series of plates or laminæ, each consisting of dentine surrounded by enamel, the separate plates being united by cement. The wear of the tissues being unequal, as in the incisors, a sharp grinding surface

is maintained by the projection of the ridges of enamel. Each plate has its own separate pulp cavity with a distinct persistent pulp, thus differing from the molars of the Elephant, which show a similar disposition of the tissues on the grinding surface, but not growing from a persistent pulp the plates have a common pulp cavity.

As the incisor teeth of Rodents are continually growing, it can be easily understood how in the case of fracture or dislocation of the exposed part of one tooth the opposing tooth will continue to grow forward following the curve

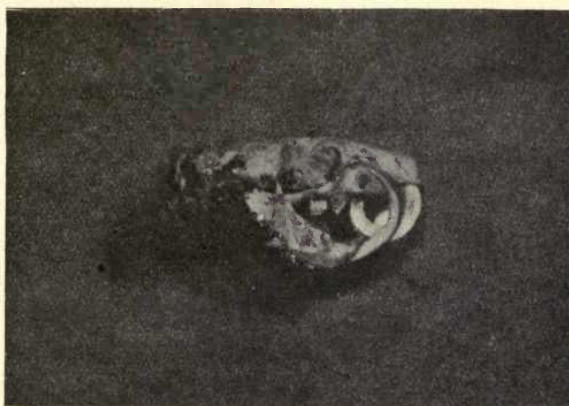


FIG. 58. Skull of Rat (*Mus decumanus*). Dislocation and overgrowth of incisors. The right upper incisor penetrates the skull. (From a specimen lent to the author by Mr. Montagu Hopson.)

within its socket, and various malformations may result. Instances are recorded in rats and rabbits where, one incisor not being opposed owing to accident, it has elongated to such an extent that it has penetrated the skull of the animal.

Fig. 58 shows the effects of fracture and dislocation of the incisors of a rat, photographed from a specimen kindly lent to the author by Mr. Montagu Hopson.

The course of the enamel prisms in human enamel is difficult to define, and their spiral twistings and longitudinal curvatures render it very difficult to follow their actual direction in any one part, but the general trend of the prisms,

independently of all these secondary curvatures, is from the dentine to the enamel surface. In the Manatee the prisms in many parts have a straight course from dentine to surface, but this is the rarest condition in the enamel of mammalia. The enamel of Rodents is in the majority of species characterized by its arrangement on the inner side in decussating layers, while on the outside the layers are parallel to one another. This division into two layers was pointed out by Professor Owen (12), but the most complete research on the structure of Rodent enamel was carried out by Sir John Tomes and described in a paper read before the Royal Society in 1850 (17 *b*). This paper, the result of a very complete investigation of the enamel of the different genera and species of Rodents, showed that the structure of the enamel was to be looked upon in many cases as an assistance in the identification of species. In the words of this author, he was enabled to show that 'the teeth of some species of the order have specific characters by which they can be distinguished from any other known teeth'. 'That in all Rodentia except the Leporidae (hares and rabbits) a portion of the enamel has a laminated arrangement of its fibres'; 'that the enamel laminae have a different and distinctive character in each of the larger groups, and that the variety of structure is constant throughout the members of the same group.' The outer and inner portions of the enamel in all Rodents (except the Leporidae) show two distinct areas, the portion near the dentine exhibiting a decussation or crossing of the laminae, and the outer portion a disposition in parallel lines. In the different species there is a great variation in the width of these layers, in the angle of inclination of the prisms to the dentine surface, and in the pattern formed by the decussation of the inner layers.

Castoridae. In the Beaver (*Castor fiber*) the decussation of the inner layers is very distinct, as is also the change in the direction of the prisms in the outer layer. In describing the arrangement in the enamel of the Beaver, to avoid confusion it may be explained that by a longitudinal section is meant a section taken parallel to the long axis of the tooth, by a transverse section one taken across the tooth at right angles to the long axis, but of course in both instances the

enamel prisms are for the most part viewed longitudinally from dentine to surface. Examining, in the first place, a transverse section of Beaver's enamel, the separation into two layers is very distinctly seen (fig. 59). The inner portion, which extends not quite half-way across the width of the enamel, is traversed by lines arranged at right angles to one another and making an angle of 45° with the dentine surface. The crossing prisms lie in different laminae, all those of one lamina passing in the same direction and being crossed by

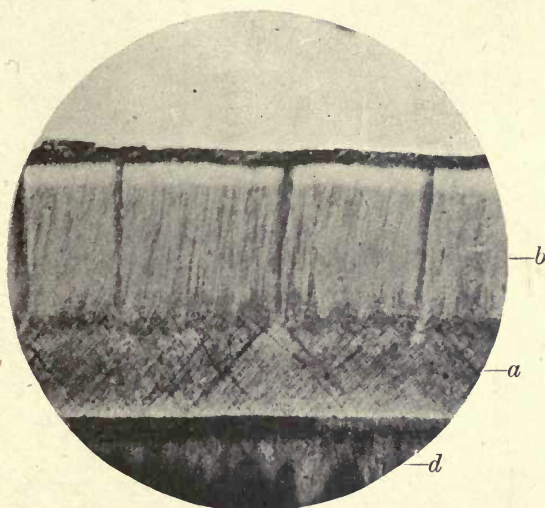


FIG. 59. Enamel of Beaver. *d.* Dentine; *a.* inner layer of enamel—decussating layers; *b.* outer layers of enamel. ($\times 225$.)

those of the superimposed lamina which lie at right angles to them. If it were possible to obtain a sufficiently thin section exactly parallel to the layers, the prisms would be seen in the single layer to be all passing in the same direction; but it is not possible to make such a section, as the layers are not in the same longitudinal plane as the dentine but are inclined from the perpendicular.

A little less than half-way across the enamel each individual prism, whether passing from right or left, is bent upwards, and they all lie parallel to one another to the surface, their direction being at an angle of about 70° to the dentine surface. At the point where they alter their direction they show a slight sigmoid curve.

In a longitudinal section (fig. 60) there is quite a different appearance. The prisms are arranged at an angle of 60° to the dentine surface and are not seen to decussate, but

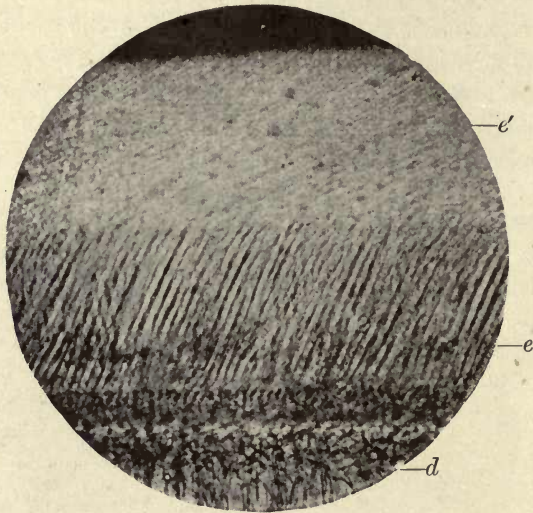


FIG. 60. Enamel of Beaver (Castor). Longitudinal section. *d*. Dentine; *e*. enamel, inner layer; *e'*. outer layer. ($\times 250$)

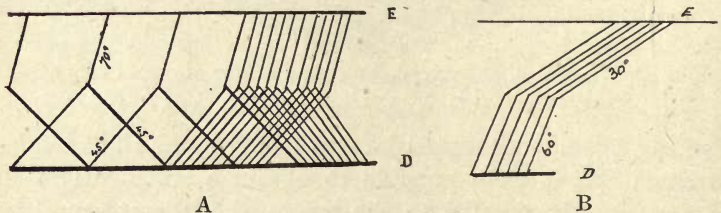


FIG. 61. A. Diagram to show the arrangement of the prisms of the Beaver as viewed in a transverse section. E. enamel surface; D. dentine surface.

B. As viewed in a longitudinal section.

are parallel to one another, the intercrossing laminae being viewed on edge. At a little less than half-way across the enamel they abruptly change their direction to one at an angle of 30° to the dentine surface.

The structure may be perhaps better explained by the accompanying diagram, fig. 61 A and B, as it is difficult to clearly comprehend the

arrangement without some such device, but it may be much better understood by a rough model. If some wooden matches are strung on a wire or pin exactly through the middle of their length, and are then alternately placed to form a series of rectangular crosses, two arms of which are placed on a level surface, the appearance of the inner layer in a transverse section is represented. To allow for the obliquity of the prism the crosses must be inclined backwards from the base line at an angle of 60° . Another match attached to the upper ends of the arms of the cross and sloped backwards at an angle of 70° to the base line represents a prism of the outer layer. If this model is viewed sideways the appearance in longitudinal section is at once explained. The cross laminae leaning backwards at an angle of 60° are seen in the longitudinal view as parallel lines at an angle of 60° to the base line, and the piece representing the prism of the outer layer slopes at an angle of 30° . The cut ends of the crossing prisms which are directed obliquely forwards are not very evident in the Beaver, but are better seen in some other Rodents, as the Squirrel.

A transverse section of the enamel of the Squirrel (*Sciurus*) Sciuridæ shows a similar rectangular crossing of the laminae near the dentine, but this inner layer extends across two-thirds of the width of the enamel and the crossing laminae are at right angles, or upright to the dentine surface, and when viewed in longitudinal section the laminae are seen to be arranged at right angles to the dentine surface, not inclined at an angle of 60° as in the Beaver.

In the Squirrel, as previously stated, the cut ends of the crossing laminae can be distinctly seen in many longitudinal sections.

The prisms of the outer layer in *Sciurus* are bent at an angle of 45° from the direction of the crossing laminae, and are arranged in a single layer almost at right angles to the enamel surface, but are very slightly curved, the convexity of the curve being directed towards the cutting edge of the tooth. In the Squirrel there is a very thin layer of enamel, its width being according to a measurement by Sir John Tomes only $\frac{1}{4\frac{1}{2}8}$ th of an inch, and he also speaks of the colour as confined to the outer third; but in a specimen from which the photograph, fig. 62, was taken the deep orange colour extends more than half-way across, gradually fading, however, towards the dentine.

There are very slight differences in the arrangement of the prisms in other members of the family, but, as the author

above named says, the enamel of *Pteromys* (flying squirrel) and *Spermophilus* (the American Souslik) may be recognized at first sight as belonging to the Sciuridæ.

In the Porcupine (*Hystrix*), although the portion of enamel near the dentine is laminated as in other Rodents, the structure is much complicated by the flexuous course of the prisms. The laminae which leave the dentine at an angle of 80° become confluent, and, as Sir John Tomes says, the enamel prisms appear as if thrown into waves, 'they pursue

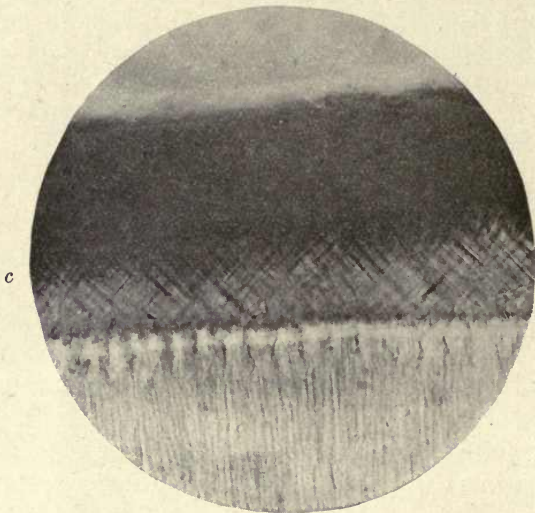


FIG. 62. Enamel of Squirrel (*Sciurus*). Transverse section.
c. Enamel; d. dentine. ($\times 250$.)

a serpentine course and in the lamelliform portion describe three tolerably uniform curves', but lie parallel to one another in the outer portion of the enamel as in other Rodents.

The enamel of the Capybara (*Hydrochærus*) is very similar in structure to that of the Porcupine, but the lamellæ of the inner layer are more confluent and more parallel. The enamel near the dentine is crowded with small rounded spaces.

The enamel of the Marmots (*Arctomys*) differs from that of the Sciuridæ, but is not wholly different in type. The prisms in the first part of their course are seen in longitudinal sections to lie in parallel layers at right angles to the dentine,

Hystri-
cidae.

Hydro-
chærus.

Arctomys.

as in the squirrel, and extend across the inner two-fifths of the enamel. In transverse section they form a diamond pattern and become parallel and waved in the outer portion, but in the outer layer there is also some intercrossing faintly to be seen and an appearance of diamond-shaped spaces.

In the Rats and Mice (*Muridæ*) there is also a decussation *Muridæ*. of the laminæ on the inner half of the enamel. The prisms are, as seen in longitudinal section, at an angle of 55° to

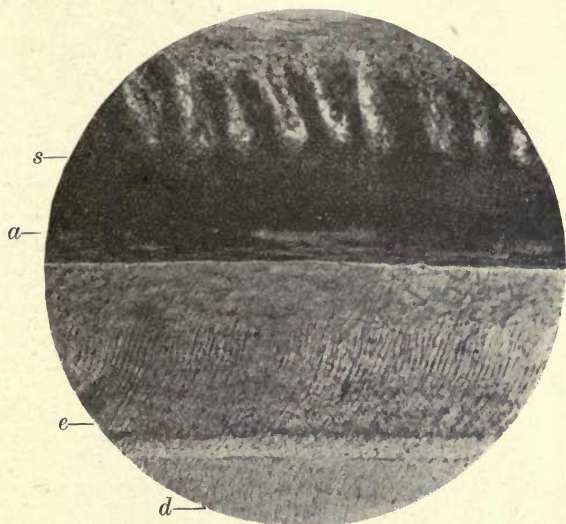


FIG. 63. Enamel of Rat. *s.* Papillæ and vessels in the enamel organ; *a.* ameloblasts; *e.* enamel; *d.* dentine. ($\times 250$.)

the dentine surface and form a diamond-shaped pattern in this area. They are slightly curved (fig. 63), the curvature being most evident near the dentine, and in the outer part of the enamel they proceed in a single layer in straight lines at an angle of 25° with the surface of the dentine. Sir John Tomes speaks of the lamellæ as being serrated, and C. S. Tomes says, 'The borders of the individual prisms are slightly serrated, the serrations of contiguous rods interlocking' (fig. 64). An examination of thin sections of rat enamel cut by the Weil process suggests, however, that these projections are not a portion of the prisms but of an interprismatic calcified material which separates the prisms from one another, as the

processes appear to pass between the prisms where viewed in transverse section and to project from them in places where viewed in longitudinal section. In fig. 65, at *a*, a single transversely-cut prism is seen with a narrow process on either side of it which certainly suggests the presence of some intervening substance and not a serration of the prism. The markedly fibrous nature of rat's enamel was drawn attention to by Leon Williams in his paper on enamel (21), where he says, 'Enamel from the teeth of rats and mice

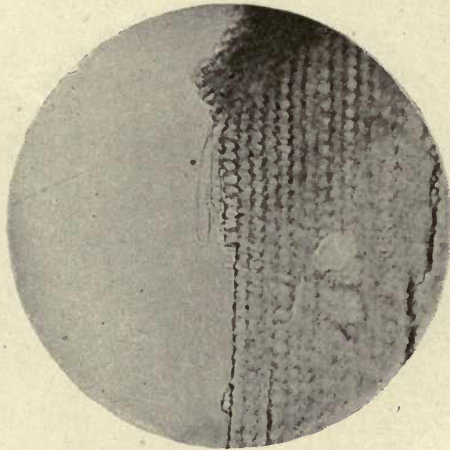


FIG. 64. Enamel of Rat. Interdigitation of transverse and longitudinal prisms and interprismatic substance. ($\times 700$.)

shows a more marked fibrous character than any other that I have examined, and the most striking feature of arrangement of the fibres is the interlacing or weaving together of those running in different directions like warp and woof in a web'. He compares the appearance of the broken edge of the enamel to that of a torn fabric. This fibrous condition of the enamel is shown in fig. 67 from a ground section accidentally torn in the middle, and it is also very noticeable in the outer layer of enamel close to the surface, where an interlacement of fine fibres is seen mostly running in a direction parallel to the surface (fig. 66).

Leporidæ. In the Hares and Rabbits (Leporidæ) there is no division of the enamel into an outer and an inner layer, and the prisms are not arranged in alternating lamellæ. Von Ebner

describes tubes in the enamel of the hare, which have no communication with the dentinal tubes. He considers that these enamel tubes were originally continuations of the

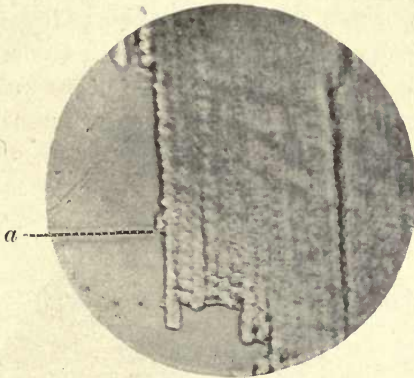


FIG. 65: Enamel of Rat. Transversely cut prisms showing projection of the interprismatic substance on either side. ($\times 800$.)

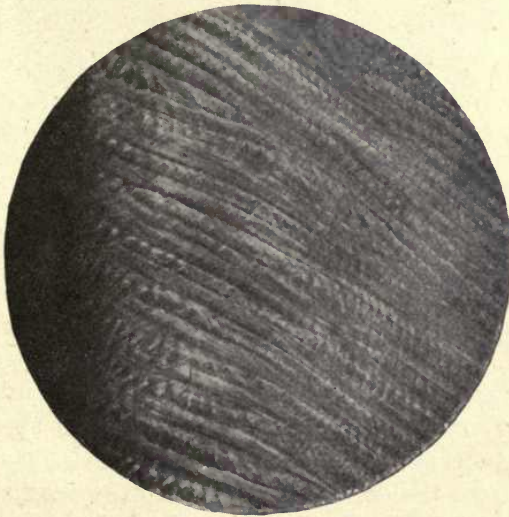


FIG. 66. Enamel of Rat near outer margin. ($\times 650$.)

dentinal tubes, but have been cut off from them by a process of resorption in the early stages of development, and he would explain the isolated enamel tubes found in the marsupial *Petaurus* in the same manner.

A rodent type of dentition is found in two animals widely separated from the Rodents and from each other. In Australia the marsupial Wombat has long scalpriform teeth growing from persistent pulps, and in Madagascar a similar dentition is found in a Lemur, the Aye-aye (*Cheiromys*). In both of these countries indigenous true Rodents are unknown. As C. S. Tomes says (18 c), 'In past times . . . a large number of animals, widely apart from one another in their affinities, have more or less approximated to a rodent

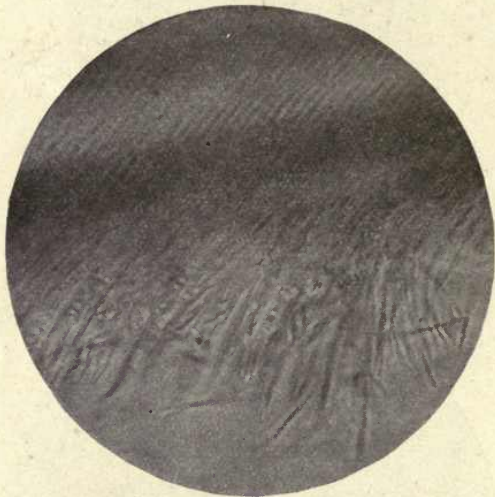


FIG. 67. Enamel of Rat showing fibrous nature. ($\times 450$.)

dentition, and as this adaptive resemblance would give to them advantages in getting access to food which was denied to animals with relatively blunt and weak front teeth, it is possible that some of these may have left descendants, and that hence the existing Rodents may have sprung from more than one stock'.

Tubes from the dentine passing into the enamel are seen in abundance in the teeth of the Rodent Jerboa (*Dipus*), and Von Ebner says it is not difficult to find tubes in the enamel of other Rodents, as mouse and guinea-pig, but these are not continuous with the dentinal tubes. He considers that a resorption of the first-formed dentine takes place whereby the ends of the dentinal tubes are left open, and

that this resorption may be due to the action of the enamel cells. This resorptive process, he thinks, has cut off the enamel tubes from any connexion with the dentinal tubes. In man, where only very short portions of the dentinal tubes enter the enamel, isolated enamel tubes are not found. The crevices in human enamel he considers only occur through drying or shrinking of the interprismatic substance.

REFERENCES

1. Black, G. V., and McKay, F. S. 'Mottled Teeth.' *Dental Cosmos*, Feb. 1916, lviii. 129.
2. v. Bibra. *Chemische Untersuchungen über die Knochen und Zähne des Menschen und der Wirbelthiere, &c.*, 1884.
3. v. Beust. 'A Contribution to the Study of Immunity in Dental Caries.' *Dental Cosmos*, 1912, liv. 659.
4. v. Boas. 'Die Zähne der Scaroiden.' *Zeits. f. wissensch. Zoologie*, 1879, Bd. xxxii, pp. 189-216.
5. Caush, D. 'Is there Uncalcified Tissue in the Enamel?' *Dental Cosmos*, vol. xlvii, Feb. 1905. ✓
6. v. Ebner, V. (a) 'Über die histologischen Veränderungen des Zahnschmelzes während der Erhärtung, insbesondere beim Menschen.' *Archiv f. micr. Anat.*, Bd. lxxvii, 1905. ✓
(b) 'Strittige Fragen über den Bau des Zahnschmelzes.' *Sitzungsb. d. k. Akad.*, Wien, 1890, Bd. xcix, pp. 57-104. ✓
7. Harting, P. *Sur la production artificielle de quelques formations calcaires organiques*, Amsterdam, 1872; and *Quart. Journ. Micr. Sci.*, London, 1872, vol. xx, N.S., pp. 118-23.
8. Hopewell Smith. *The Histology and Patho-histology of the Teeth*, 1903. ✓
9. Hoppe-Seyler, E. *Handbuch der Physiologisch- und pathologisch-chemischen Analyse &c.*, Berlin, 1893 (new ed.).
10. Lovatt Evans. *Transactions, International Medical Congress*, 1913 (Section of Stomatology).
11. Mummery, J. H. (a) 'On the Structure and Arrangement of the Prisms, especially as shown in the Enamel of the Elephant.' *Proc. Roy. Soc. Med.*, vol. ix, 1916, Odontol. Section, pp. 121-38. ✓
(b) 'On the Nature of the Tubes in Marsupial Enamel, and its bearing upon Enamel Development.' *Phil. Trans. Roy. Soc.*, Ser. B, ccv. 295-313. ✓
12. Owen, R. *Odontography*, pp. 404-6. ✓
13. Paul, F. 'Some Points of Interest in Dental Histology; the Enamel Organ.' *Dental Record*, 1896, xvi. 493-517.
14. Pickerill, H. P. 'The Structure of Enamel.' *Dental Cosmos*, Oct. 1913. ✓
15. Römer, O. *Nerven im Zahnbein: zahnhistologische Studie*. Freiburg, 1899. ✓

16. Smreker, E. (a) 'Über die Form der Schmelzprismen menschlicher Zähne,' &c. *Archiv für micr. Anat.*, 1905, lxvi. 18-81. ✓
 (b) 'Über die Darstellung der Kittsubstanz des Schmelzes menschlicher Zähne.' *Anat. Anzeig.*, Bd. xxii, 1903. ✓
17. Tomes, J. (a) 'On the Structure of the Dental Tissues of Marsupial Animals, and more especially of the Enamel.' *Phil. Trans. Roy. Soc.*, London, 1849, vol. cxxxix, pt. ii, pp. 403-13.
 (b) 'On the Structure of the Dental Tissues of the Order Rodentia.' *Phil. Trans. Roy. Soc.*, London, 1850, pt. ii, pp. 529-69. ✓
18. Tomes, C. S. (a) 'On the Chemical Composition of Enamel.' *Journ. Physiol.*, Camb., 1896, xix. 217-23.
 (b) 'On the Development of Marsupial and other Tubular Enamels, with Notes upon the Development of Enamel in General.' *Phil. Trans. Roy. Soc.*, 1898, clxxxix. 107-22. ✓
 (c) *Dental Anatomy*, 7th ed. ✓
 (d) 'On the Structure and Development of the Enamel of Elasmobranch Fishes.' *Phil. Trans. Roy. Soc.*, 1898, Ser. B, vol. cxc, pp. 443-61.
 (e) 'Upon the Development of the Enamel in certain Osseous Fish.' *Phil. Trans. Roy. Soc.*, 1900, Ser. B, vol. cxci, p. 42.
 (f) 'On the Minute Structure of the Teeth of Creodonts, with especial reference to their suggested Resemblance to Marsupials.' *Proc. Zool. Soc. Lond.*, 1906, i. 45-58. ✓
19. Underwood, A. *Aids to Dental Anatomy and Physiology*, 3rd ed., p. 63.
20. Walkhoff, O. (a) *Die Erdsalze in ihrer Bedeutung für die Zahncaries*. Berlin, 1913.
 (b) 'Die vermeintliche Kittsubstanz des Schmelzes.' *Anat. Anzeig.*, Bd. xxiii, S. 199.
 (c) 'Beitrag zur Lehre von der Struktur des Schmelzes.' *Deutsche Monatschr. f. Zahnheilkunde*, xxi. Jahrg., Dezember 1903, S. 625. ✓
21. Williams, Leon. 'On the Formation and Structure of Dental Enamel.' *Dental Cosmos*, 1896, xxxviii. 101-269 and 453 ff. ✓
22. Zsigmondy, O. 'Über die Retziusschen Parallelstreifen im menschlichen Schmelze.' *Osterreich. Zeit. für Stomatol.*, Vienna, 1913. ✓

CHAPTER III

DEVELOPMENT AND CALCIFICATION OF THE ENAMEL

1. The Enamel Organ of Mammalia

As explained in Chapter I, the enamel is developed from the deeper layers of the epithelium of the mouth. It is thus of ectodermic origin, and the several layers of cells into which this involution becomes differentiated are collectively spoken of as 'the enamel organ' (fig. 68).

This enamel organ commences as a bud-like process, which grows downwards into the sub-epithelial tissue, and

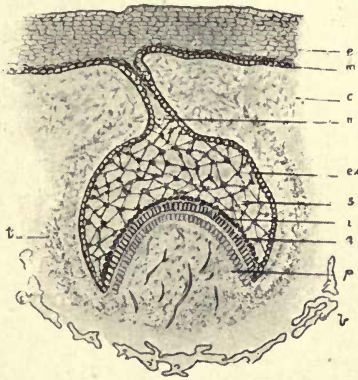


FIG. 68. Diagram showing the enamel organ and its connexions before the commencement of calcification. *e.* Epithelium of mouth; *m.* Malpighian layer; *c.* connective tissue; *n.* neck of enamel organ; *ex.* external epithelium; *s.* stellate reticulum; *i.* stratum intermedium; *a.* ameloblasts; *p.* pulp; *b.* bone; *t.* commencing tooth-sac.

is formed by an invagination of the Malpighian layer of the oral epithelium.

The rounded end of the bud becomes indented from beneath, and the sides of this indentation grow round the mesodermic connective tissue which afterwards forms the dentine papilla. It thus comes to have a bell shape, the connecting band with the epithelium of the mouth forming the handle.

The cells constituting the walls or sides of this inflection,

at first in contact, become separated from one another by a layer of stellate cells which fills the space between them. This, 'the stellate reticulum' eventually in Mammalia, occupies the greater part of the area of the enamel organ during the earlier stages of enamel development.

The sides of the bell, the section of which appears as a crescent, continue to grow downwards, the horns of this crescent further enclosing the dentine papilla.

The investment of the dentine papilla is considered not to be produced by the upward growth of this papilla, but by the down growth of the epithelial enamel organ around it. Those cells which immediately invest the papilla between the two horns of the crescent and form the inner layer of the enamel organ become columnar in shape, and are known as the ameloblasts or enamel-forming cells.

The continuation of this layer on the outer side of the stellate reticulum forms the external epithelium of the enamel organ which separates it from the connective tissue of the capsule. These cells, however, do not become columnar in shape, as do those forming the internal epithelium. A layer of rounded cells also appears, intervening between the internal epithelium or layer of ameloblasts and the stellate reticulum (fig. 68 (a)). This layer, called the stratum intermedium, is only seen in contact with the internal epithelium, and does not pass beyond the horns of the crescent.

The enamel organ is thus seen to be made up of four distinct layers from without inwards :

The external epithelium.

The stellate reticulum.

The stratum intermedium.

The internal epithelium.

The External Epithelium (figs. 69 to 72). This layer, which forms the periphery of the enamel organ, is made up of polygonal nucleated cells, which in later stages are often elongated, their longer axes lying parallel to the surface. The cells of this layer merge into those of the stellate reticulum.

It has been debated whether the cells of this layer have any distinct function beyond that of limiting the boundary

of the enamel organ. Its intimate relations, however, with the blood-vessels of the capsule would suggest that it serves a much more important purpose. Dr. Paul says its 'chief function seems to be the separation from the blood of the constituents of enamel which are elaborated by the internal epithelium' (17). It would seem highly probable that this is the function of these cells, at all events in the early stages of calcification. The budding of the cells of the external

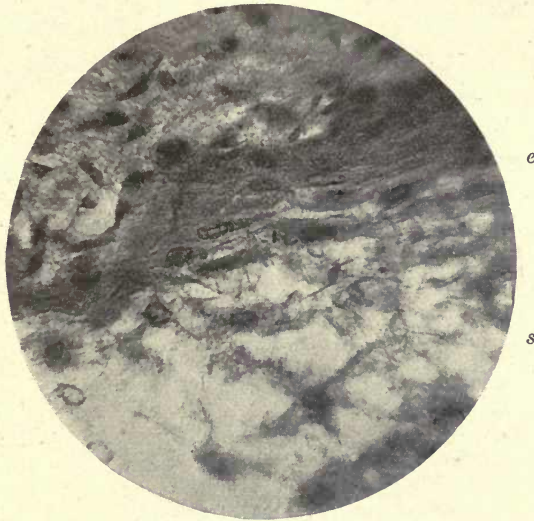

FIG. 69. External epithelium of enamel organ of *Macropus* showing elongated fusiform cells. e. External epithelium; s. stellate reticulum. ($\times 350$.)

epithelium, to be presently described, would also indicate a more important function of this layer than is usually ascribed to it. The blood-vessels in the follicle are in close relation with the external epithelium of the enamel organ, and in places it is seen to be discontinuous, and these blood-vessels are distinctly in contact with the cells of the stellate reticulum (fig. 70).

In marsupials they have been seen to penetrate the external epithelium in many instances and to enter the stellate reticulum. In the Wallaby (*Macropus billiardieri*) they have been shown to do so by Marett Tims and Hopewell Smith

(24), and Professor Poulton long ago described blood-vessels in the stellate reticulum of the rat (18).

In fig. 71, from a preparation of the author's of *Macropus rufus*, blood-vessels are seen crossing the external epithelium and also lying within the stellate reticulum, an appearance seen in many sections, and a photograph sent to him by Mr. Law shows numerous blood-vessels in this layer. There is little doubt that many preparations, said to show blood-vessels in the stellate reticulum, really showed them, not

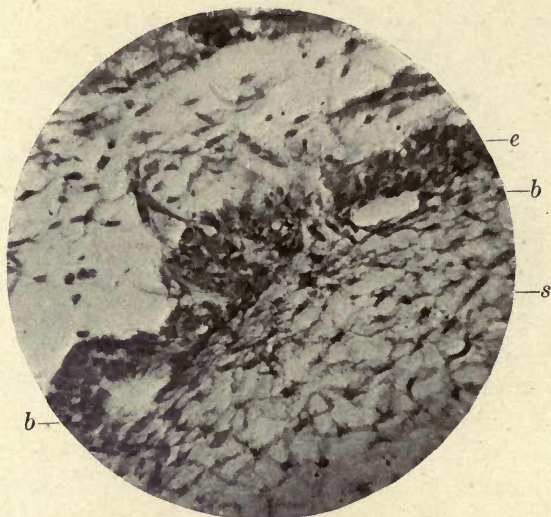


FIG. 70. The external epithelium in a human tooth germ showing breaks of continuity and blood-vessels in contact with the stellate reticulum (photographed from a preparation by Mr. W. James). *e.* External epithelium; *b.* blood-vessels; *s.* stellate reticulum. ($\times 150$).

in this layer, but in the connective tissue outside the enamel organ, which, when the stellate reticulum has disappeared, lies in contact with the stratum intermedium, and often very strongly resembles it in appearance. There is, however, no longer any doubt that vessels are found, at all events in marsupials, within the enamel organ.

Mr. Thornton Carter (5) has lately described blood-vessels deeply within the stellate reticulum.

It was long ago shown by Malassez and by Robin and Magitot, that the external epithelium of the enamel organ

in human tooth germs is in many places not continuous, but shows numerous indentations and interruptions, and the blood-vessels of the capsule are in actual contact with the cells of the stellate reticulum (see fig. 70). They also showed that epithelial buds arise from the outer surface of the external epithelium and proliferate within the follicle, as shown in fig. 72 (photographed by the author from a preparation by Warwick James).

Malassez says, 'This' (the external layer of the enamel

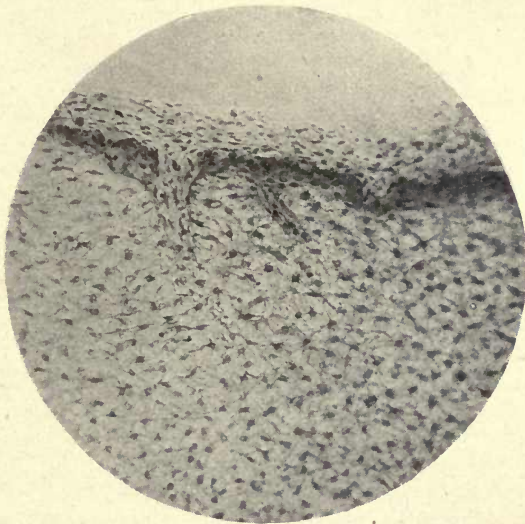


FIG. 71. Blood-vessels penetrating the external epithelium and entering the stellate reticulum in *Macropus rufus*. ($\times 125$.)

organ) 'does not form everywhere and always a continuous investment, as is generally thought. One sees in it, in certain regions, numerous lacunæ or windows which give it the appearance of an epithelial network.'

The papillary projections into the external layer of the enamel organ, first described by Herrissant (14), were supposed by him to be charged with the function of secreting the enamel. They no doubt represent these vascular prolongations described by Malassez, and probably serve to convey a blood supply to the stellate reticulum, but there is no evidence that they have any directing influence on the enamel prisms as some authors have imagined.

This penetration by blood-vessels may, perhaps, be looked upon as a vestigial survival of the condition described by the author in certain families of osseous fish in which the enamel organ is permeated by blood-vessels or sinuses enclosed in a delicate sheath, forming a regular layer around the forming enamel, to which further reference will be made in describing the development of the enamel in fish.

The Stellate Reticulum (figs. 73 and 74). There has been some controversy and considerable difference of opinion as

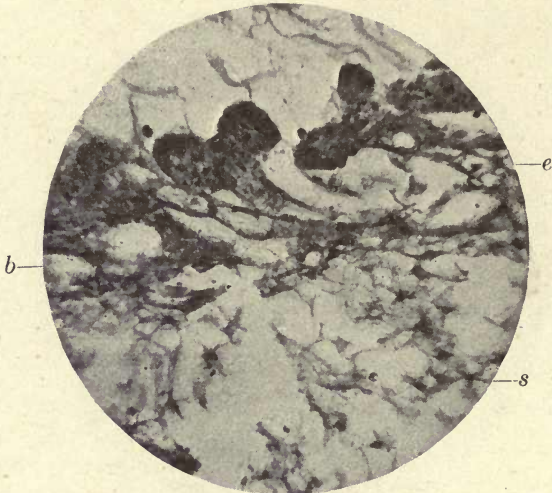


FIG. 72. Budding of the external epithelium (human tooth). *s.* Stellate reticulum; *e.* external epithelium; *b.* blood-vessels. (Photograph from a preparation of Mr. W. James.) ($\times 150$.)

to the structure and function of this layer. A great part of this uncertainty has been caused, as was first pointed out by Leon Williams, by the unsuitable methods of preparation, and the bare skeleton of the stellate reticulum only has been seen.

The shrinkage caused by the use of alcohol in both fixing and dehydration, and the further distortion caused by clearing oils and Canada balsam, are fatal to such a delicate tissue as the stellate reticulum, as they are indeed to many others of a similar nature, and while these routine methods are perfectly applicable to many preparations, they should not be adopted in the investigation of tissues of this nature.

A specimen fixed in formol and cut in gum on the freezing microtome will, when mounted in glycerine or Farrant solution, give quite a different picture, and one that with little doubt gives a much better indication of the real structure.

Such a preparation of the stellate reticulum (fig. 74) of a mammalian enamel organ shows that it is made up of large cells, showing under high powers of the microscope a delicate reticulated structure with oval or round,

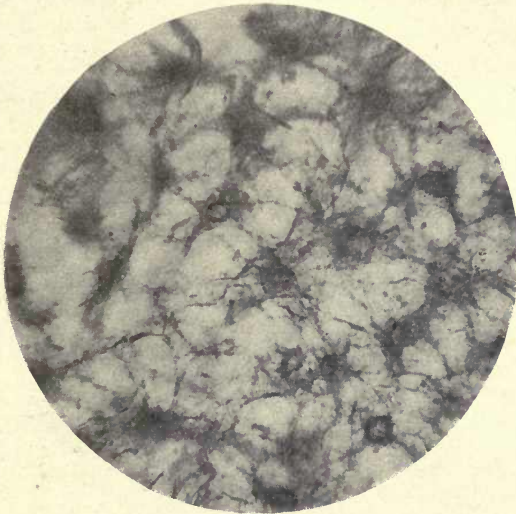


FIG. 73. Stellate reticulum. *Macropus*. ($\times 600$.)

very conspicuous nuclei, which in well-stained preparations also show one or more nucleoli. These cells are connected by broad processes with one another and by finer thread-like processes, giving to the whole structure its characteristic stellate appearance. The intervals between the cells are filled with a gelatinous or colloidal material which shows no visible structure, but takes a very faint stain, showing that these spaces are not empty, even in the microscopical preparation. Leon Williams considers that the stellate structure is simply the intercellular substance which is left after the removal of the cell contents, and that the stellate appearance is due to the persistence of the slightly modified cell wall. It would appear advisable, however, to confine

the term intercellular substance to the jelly-like substance above referred to, and not to apply it to these extensions of the cell wall. It appears very probable that this altered tissue of the outer part of the cell may by its persistence give rise to the stellate appearance in balsam mounted sections. In such preparations the intercellular substance, as well as the cells, has disappeared. In sections mounted without the use of alcohol the cells themselves are seen to have a stellate form with broad connecting processes or bridges, the outer layer of these cells extending into other

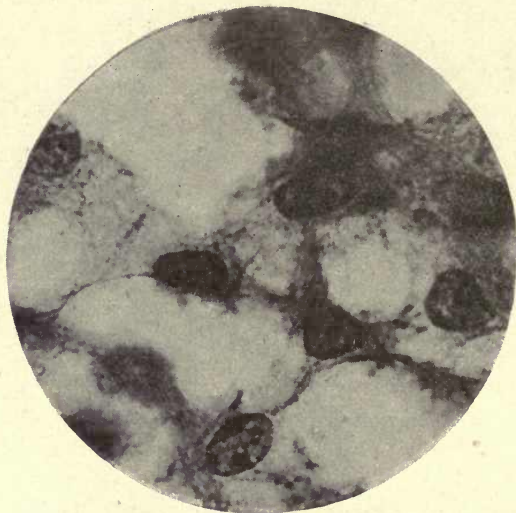


FIG. 74. Stellate reticulum. Macropus. ($\times 1,000$.)

long, narrow processes which communicate with one another over the whole area of the tissue and enclose spaces containing an apparently homogeneous material.

It is apparently the network formed by these connecting processes which forms the web-like tissue seen in the balsam preparations, and which remains after the more delicate tissue of which they form the boundary has fallen away.

The appearances would suggest that this outer layer and its processes have undergone some change which makes them more resistant than the rest of the cell, and they therefore persist after the removal of the body of the cell with its nucleus.

According to Röse (21), the formation of the cells of the stellate reticulum commences in the centre of the enamel organ. The cells of the rete mucosum of the oral epithelium, closely packed under the enamel epithelium, increase in size in this situation, the nuclei becoming larger and separating as the cells grow larger. He says: 'Between these cells a clear protoplasmic fluid is secreted, causing the appearance of small intercellular spaces. These spaces increase and press against the neighbouring cells to such an extent that the cells are finally connected with one another only by means of narrow protoplasmic bridges.' He considers that they 'form a wide-mouthed canal system, containing a thin fluid protoplasm, apparently highly suitable for a rapid circulation of nutritive fluids'.

Messrs. Underwood and Wellings (28 *b*) consider that 'the cells (where no alcohol has been used) are round or oval, with round or oval nuclei, the latter occupying most of the cell. The processes which connect these cells with their neighbours are wavy and not straight, and the cell envelope is not drawn out where the processes are given off.' They consider that the stellate appearance is artificially produced. As shown, however, in fig. 74, the cells themselves are mostly stellate rather than round or oval, and in some there is a considerable area of cell substance around the nuclei, and one would be inclined to consider that the stellate appearance is decidedly an indication of real structure and not artificially produced, although the distortion so commonly apparent in preparations and in published drawings and photographs might suggest this.

With regard to the functions of the stellate reticulum, there is also very considerable difference of opinion. C. S. Tomes says it has been supposed to have no more important function than to fill up the space subsequently taken up by the growing tooth, and quotes Dr. Paul in support of this view.

As Röse points out, in the rapidly forming and speedily worn out teeth of lower vertebrata there is no stellate reticulum, the enamel organ being of very simple structure; but in higher animals this tissue is present, the teeth are developed more slowly, and as the epithelial enamel organ

contains no blood-vessels, nutrition must take place by osmosis, and a special arrangement is necessary to carry nutriment to the growing epithelial cells. He states also that the development of the stellate reticulum is intimately associated with the deposition of a thick enamel cap in the higher vertebrata.

It certainly seems more reasonable to suppose that a tissue consisting of such fully developed cells should take part in the process of calcification by acting as a storehouse of material and serving as a channel for the conveyance of substances to the more active cells, than that its function should be merely a mechanical one.

C. S. Tomes is inclined to look upon the stellate reticulum as a tissue which has undergone colloid degeneration, such as is seen in epithelial tumours. This view was supported by Eve in a paper read before the Odontological Society of Great Britain in 1885 (9). In this condition the cells often become enlarged and the nuclei pressed against the cell wall; but this last appearance does not occur in satisfactory preparations of the enamel organ, although it may possibly be seen in shrunken preparations or in later stages of development, when the stellate reticulum is disappearing and degenerating, and Röse's view of its functions would appear much more consistent with those of a vital, developing tissue.

The Stratum Intermedium (fig. 75, *s*). The cells of this layer communicate by their processes with those of the stellate reticulum. Their nuclei are somewhat smaller than those of the cells of the stellate reticulum, and when calcification has commenced the cells and their nuclei are generally seen to be slightly elongated in a direction parallel with the surface of the internal epithelium, but many cells retain a rounded or polygonal form.

Before the commencement of calcification, many cells of the stratum intermedium are seen lying close to and often between the distal ends of the ameloblasts; but after calcification has commenced they are completely shut off from these cells by a membrane, the outer ameloblastic membrane of Williams.

After the stellate reticulum has disappeared in the later

stages of enamel formation, the external epithelium lies in close contact with the stratum intermedium, and the blood-vessels of the capsule are in close proximity to its cells. It is contended by Leon Williams (30) that in the rat the blood-vessels enter the stratum intermedium, and that their loops dip into the spaces between the cells, from which they can be pulled away, the vessels then projecting as long processes, and he claims for the stratum intermedium the functions of a true secreting organ in this animal.

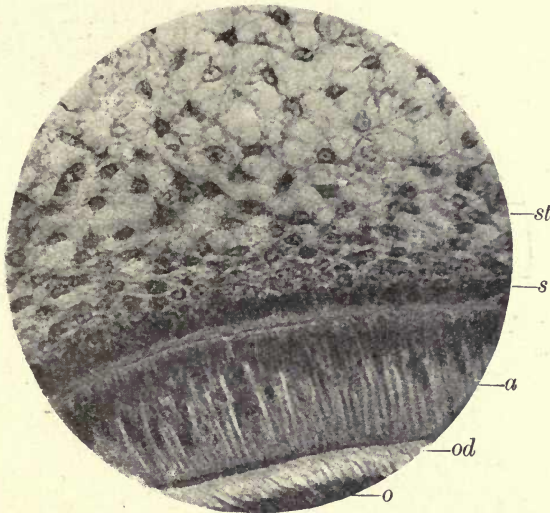


FIG. 75. The enamel organ of *Macropus* at the commencement of calcification. *st.* Stellate reticulum; *s.* stratum intermedium; *a.* ameloblasts; *od.* odontogenic zone; *o.* odontoblasts. On the left calcification of the dentine has just commenced and the outer ameloblastic membrane appears, but is not seen on the right side where there is no calcification. (× 400.)

Certainly the photographs accompanying his description give every evidence of such an arrangement, and the conditions found in certain fish in which blood-vessels or sinuses form a conspicuous part of the enamel organ, as shown by the author in a recent paper, would tend to confirm this observation. Fig. 76, from a photograph of a preparation by the author, shows these papillæ and loops in the enamel organ of the rat.

The Internal Epithelium. Ameloblast or Adamantoblast

layer (fig. 77, *a*, and Plate IV at *a*). This, the most constant and most important structure of the enamel organ, forms its innermost layer, and before calcification has commenced lies in immediate contact with the dentine papilla. The cells of this layer are columnar in shape, with very distinct oval nuclei, which lie for the most part at the distal extremity of the cell, the end farthest removed from the point where the earliest deposit of calcific matter takes place. Here and there, however nuclei are to be seen near the proximal ends

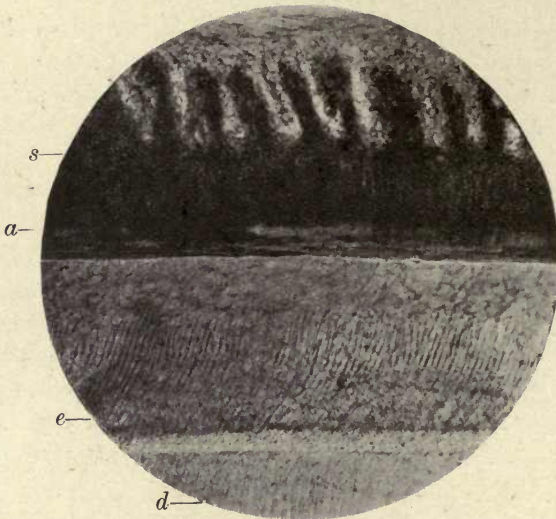


FIG. 76. Enamel of Rat. *s.* Papillæ and vessels in the enamel organ; *a.* ameloblasts; *e.* enamel; *d.* dentine. ($\times 250$.)

of the cells, and in late stages of calcification in marsupials very many nuclei occupy this position, and are crescentic in shape, as first pointed out by C. S. Tomes (26), who also described the horns of the crescent as looking as if they were continued into filamentous processes. Many preparations of the author's seem to show that there can be little doubt that these processes are connected with the nuclei (fig. 85).

The nuclei of the ameloblasts have very distinct nucleoli, and show a fine nuclear network in suitably stained preparations, and the body of the cell is occupied by very delicate strands of protoplasmic fibres arranged chiefly in



Tooth germ of Kitten. A drawing by the author from a preparation by Prof. Milroy. $\times 1000$.

S. Stratum intermedium; *a.* ameloblasts; *e.* enamel; *t* Tomes' processes;
*m*₁. outer ameloblastic membrane; *m*₂. inner ameloblastic membrane.

a longitudinal direction (see Plate IV). The cells are generally considered to be in close contact with one another, their transverse section having an hexagonal form from mutual apposition, but Messrs. Underwood and Wellings (28 *b*) describe intervals between them which they say appear to correspond in diameter to the intercolumnar spaces in the formed enamel. The proximal ends of the cells are square in shape before the commencement of calcification and form a more or less straight line where they are in contact with the tissue of the

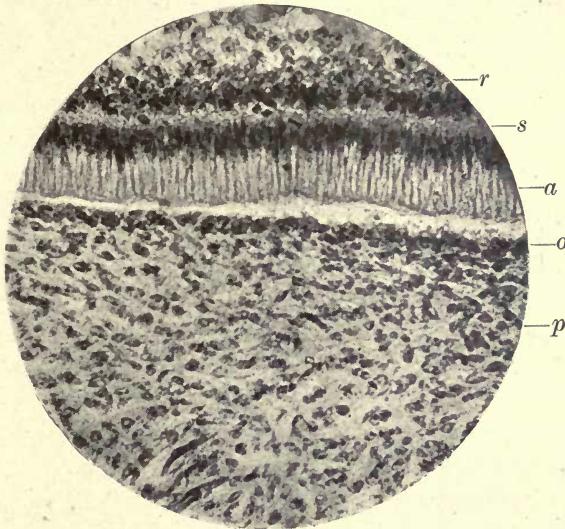


FIG. 77. Macropus. Before the commencement of calcification. The cells of the stratum intermedium (*s*) are seen to be blended with those of the internal epithelium (*a*). *r*. Stellate reticulum; *s*. stratum intermedium; *a*. ameloblasts; *o*. odontoblasts; *p*. pulp. ($\times 150$.)

dentine pulp. When calcification has commenced each ameloblast is seen to be provided with a process which extends to the surface of the forming enamel. This, the Tomes' process of the ameloblast, is often seen very much pulled out and elongated, especially in balsam mounted specimens, and also has a tapered form in such preparations.

In specimens, however, which have not been decalcified or dehydrated, these processes are very little narrower than the cell itself. They are very distinct in marsupials, and their fine fibrillar structure is well shown, this being a

continuation of the same material seen in the ameloblast cell itself. The existence of these processes has been doubted by some authorities, who look upon it as an artificial product caused by the dragging or pulling away of the forming enamel from the ameloblast cell; but a study of marsupial enamel organs where they are continued into fibres which pass across the whole area of the forming enamel, renders it impossible to doubt their existence as a definite and important part of the cell, as will be better understood after the development of the enamel in marsupials has been considered (see p. 153).

Inner and
outer
ameloblastic
membranes.

In developing enamel, membranes have been described between the ameloblast cells and the forming enamel, and also between these cells and those of the stratum intermedium.

The question of the existence of membranes in these situations has been the subject of much controversy. Professor Huxley held the view that there was a 'membrana preformativa' between the ameloblasts and the forming enamel, and that the calcification of enamel took place by the transference of crystallizable products through a membrane.

This theory has been revived by Leon Williams and others. Williams (30), in his study of enamel, is convinced of the existence of these membranes, and has called them the outer and inner ameloblastic membranes. The outer membrane intervenes between the stratum intermedium and the ameloblasts, and the inner ameloblastic membrane separates the ameloblasts from the forming enamel, but is pierced by the 'Tomes' processes. An examination of many sections of developing teeth prepared in different ways will, we think, clearly show that such membranes really exist, or certainly a substance which retains its continuity when the cells have fallen away from it, perhaps the thickened cell walls united at their margins. Fig. 78 shows the outer ameloblastic membrane in the enamel organ of *Macropus*, where the ameloblasts have become detached from its under side and it still persists as a distinct membrane, and Leon Williams has published a photograph in the illustrations to his paper which shows the *inner* ameloblastic membrane

attached to the ameloblasts, and torn away from its connexion with the forming enamel. Both the outer and inner ameloblastic membranes are well shown on Plate IV.

Tomes is inclined to look upon these membranes as non-existent, or as artificial products, but in sections which have not been treated with either alcohol or acids they are easily to be seen.

The membranes appear to be dependent upon the calcifying process, for before its commencement they are not to

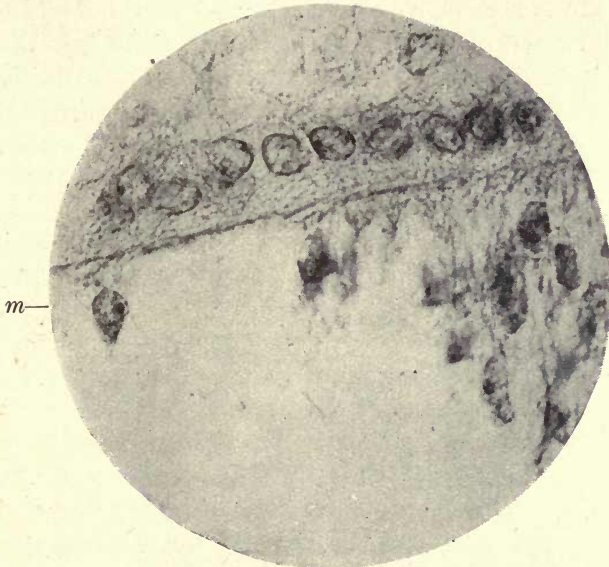


FIG. 78. Macropus. Outer ameloblastic membrane (*m*) where ameloblasts have been detached. ($\times 1,000$.)

be seen, and the cells of the stratum intermedium are mingled with the ameloblasts (figs. 75 and 77), although afterwards entirely shut off from them by the outer ameloblastic membrane.

Processes from the cells of the stratum intermedium apparently penetrate this membrane and communicate with the ameloblasts.

In criticizing Leon Williams's statements, C. S. Tomes says that little reliance can be placed on differential staining as evidence of the existence of the membranes. No doubt many conditions affect these staining results, as the previous

fixation of the tissue, the length of time during which the preparation is exposed to the staining reaction, and the composition and concentration of the stain, while many compound stains are unreliable. These membranes are, however, clearly visible in unstained preparations of marsupial enamel organs and in those treated with hæmatoxylin, and require no differential stain to make them apparent.

2. Calcification

With the exception of horny teeth which are hardened by the cornification of the stratum corneum of the epithelium, all teeth are calcified, or impregnated with lime salts. The organic matter in which they are first laid down is permeated with the salts in different degrees, producing structures of sufficient hardness to resist the severe strain to which they are subjected, the calcification of enamel being so complete that its original structure is considerably veiled or lost, and it is the densest and hardest of all the animal tissues.

The formation of enamel and the mode of deposition of the lime salts have long been among the most difficult problems in the histology of the teeth.

Many contradictory theories have been held on the subject, and while much fresh light has been thrown upon it in late years by the investigations of Röse, Von Ebner, Leon Williams, and others, there still remain many difficulties to be overcome in arriving at a clear understanding with regard to it.

Owing to the complicated courses of the enamel prisms, the difficulty of obtaining sections in which the calcified portion of the tissue is in normal relations with the formative cells, and the great care necessary to avoid distortion of the preparations and the consequent deceptive appearances produced, there are few tissues that present more difficulties to the investigator.

The subject of the calcification of enamel is so intimately bound up with certain chemical and physical phenomena, that a brief statement of these is necessary before proceeding to a more detailed consideration of the subject, that it may be made clear, at all events in some degree, what part

these physical processes take in the phenomena under consideration.

The author undertook some experiments with solutions of lime salts in inorganic solutions, to ascertain, if possible, to what extent the deposition of these bodies in the forms found in calcifying tissues was produced by purely physical agencies, and how far the phenomena of osmosis were concerned in bringing this about.

Professor Leduc's experiments on the production of osmotic growths in chemical solutions suggested the examination of the production of similar growths under the microscope.

When a solution of silicate of potash in tap water (containing lime salts) was employed, into which a few particles of copper sulphate were dropped, the phenomena were easily followed under a low power of the microscope. When the copper salt was dropped into the solution, the smaller particles immediately gave rise to a number of small convoluted tubes, but in the larger pieces the process was less rapid and more easily followed. A globular projection appears at the margin of the little mass of crystals; this is still further protruded by a series of small explosive impulses, and eventually the limiting membrane formed between the dissolving crystalloid and the surrounding colloidal medium is pushed forward in the form of a steadily growing tube. These tubes can be watched as they rapidly pass across the field of the microscope, some terminating in pointed extremities, others reaching the margin of the microscope slide. The growth of these tubes is due to the rapid passing of water through the membranous wall from the surrounding solution by osmosis, the distension caused by the water pushing the tube forward, the resistance of the membrane at the same time preventing the lateral bulging of the tube.

These membranes were first described by Traube (27), who called them 'membranes of precipitation'. The most interesting point, however, to notice in this experiment is that in many places, as the tube nears the end of its growth, a line is seen to be drawn across it, dividing it with a distinct septum. It is difficult to explain what determines the production of these transverse membranes. It can hardly be

Osmotic
mem-
branes.

Traube's
mem-
branes of
precipita-
tion.

due to fracture, as has been suggested, for the course of the tube is not altered, as one would expect to find if this were the case.

That this membrane completely closes the tube is shown by the fact that small crystalline particles of the copper salt accumulate upon its upper or proximal surface, the lower part of the tube remaining clear.

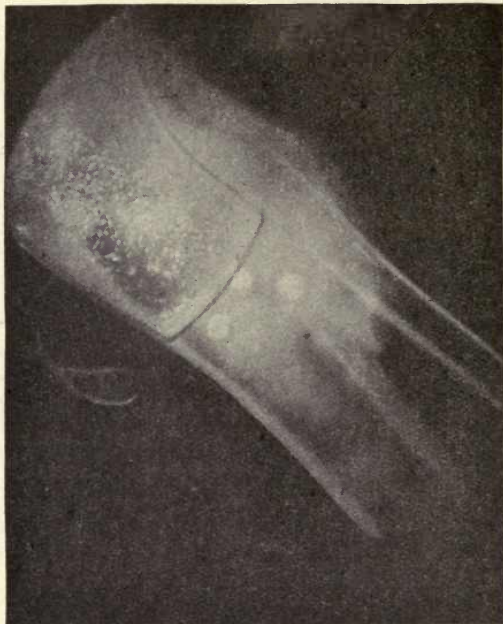

FIG. 79. Osmotic tube formed with copper sulphate in silicate of potash. Osmotic membrane showing crystalline particles above and calcospherites below. ($\times 15$.)

After some hours, however, spheroidal bodies appear in the clear part of the tube below the membrane, many being in close contact with it (fig. 79). These bodies have all the appearances of calcospherites of the radial type. They are probably composed of silicate of lime, the lime salts being derived from the tap water in which the silicate is dissolved.¹

¹ These bodies below the membrane form also when distilled water is used to dissolve the silicate, but, as Dr. Lovatt Evans says, this would

The interesting point is that true calcospherites are formed by dialysis through membranes which are formed in inorganic solutions by purely physical processes.

Graham (10), as the result of his experiments on the diffusion of liquids through membranes, divided substances into crystalloids and colloids—crystalloids having the power when in solution of passing easily through membranes; colloids, on the other hand, passing through with difficulty, or not at all. The particles of a colloid solution are held together by a very feeble force; they consist of very fine particles in a state of suspension, rather than solution in the solvent. The exact line of demarcation, however, between crystalloids and colloids is not always very pronounced, and according to Krause there is a steady transition from the crystalloids to the colloids.

The living body is built up of substances essentially colloidal in character. These substances may exist either in the solid condition, when they are called 'gels', or in the fluid state, when they are spoken of as 'sols'.

If the colloids throughout the body are brought into the condition of irreversible 'gels', life ceases, but there are conditions in which the transition of 'sols' into 'gels' does not lead to death, but to the formation of the important structures before referred to, the membranes of precipitation. This partial gelation of the colloids takes place when two different colloids, or a colloid and a crystalloid, come into contact.

These membranes of precipitation of Traube (27) are generally considered to be permeable to water only, but, as has been evidenced in the organic tissues of plants, salts are capable of passing through them, and Loeb¹ is of opinion that cell walls are not impermeable to salts, but there is only a difference in the rate of diffusion, many salts diffusing only very slowly into the protoplasm. Leduc (15) says: 'Osmotic membranes were formerly called semi-permeable membranes, being regarded as membranes which allow water to pass through them but not be a proof of the absence of lime, as calcium salts are present in ordinary specimens of sodium silicate.

¹ *Dynamics of Living Matter*, 1906.

arrest the passage of the solute. This definition is inexact, since no membrane permeable to water is absolutely impermeable to the solutes. All we can say is that certain membranes are more permeable to water than to the substances in solution, and are, moreover, very unequally permeable to the substances in solution. The term "osmotic membrane" should therefore in all cases replace that of "semi-permeable membrane".

In the experiment with the copper sulphate above described, it was seen that although the crystals accumulated on the proximal side of the membrane very rapidly, the part of the tube on the distal side remained clear for several hours, when the slow diffusion of the salts through the membrane caused the production of the calcospherites which appeared in this situation, the lime salts contained in the water which had permeated the tube wall diffusing through the septum. We thus see that under purely physical conditions we have a dialysis of salts of lime through these inorganic membranes, and this observation points to the suggestion that the same thing may occur from physical causes in the calcification of the various hard tissues of man and animals.

How far the membranes found in the living body are the result of purely physical agencies, and to what degree they are affected by physiological and vital conditions, we are unable to determine, but it is seen that very firm membranes do arise in the absence of all organic substances, although, as Professor Philip says (19), 'a purely physical theory of the exchanges which take place across a living membrane is inadequate; there is a physiological as well as a physical permeability'.

The bearing of these observations will be better understood after the calcification of enamel and dentine has been considered.

In the year 1858 Rainey published his work on molecular coalescence (22), showing that lime salts were deposited in colloidal solutions not in a crystalline but in a globular form, the globules having a very definite structure and arrangement. He also showed that in many animal organisms, as Mollusca and Crustacea, similar forms appeared

during the calcification of the shell. The first experiments were made with a solution of carbonate of potash in gum (which contains salts of lime). The bodies so produced were globular in form, showing concentric lamination and radial striæ. Professor Harting of Utrecht (12) independently carried out a similar research, and succeeded in producing a great variety of these spherical bodies in various substances, his most instructive experiment being one in which small fragments of calcium chloride and of sodium carbonate were placed on the opposite sides of a flat dish containing egg albumin. The dish was left perfectly still and undisturbed for two or three weeks; the salts diffusing through the albumin from the opposite sides formed a crust upon the surface. This crust was found to consist of a deposit of carbonate of lime in the globular form, showing a great variety of spheres and disks of varying size, and very similar to those produced in gum in Rainey's experiments. He found that they retained their form after they had been subjected to the action of an acid, some portion of the lime having become so intimately blended with the albumin that it remained in combination with it. To this substance, left after decalcification, Harting gave the name of 'calcoglobulin', distinguishing the calcified globular bodies by the name of 'calcospherites'. If a microscope slide be prepared with gum containing carbonate of potash or soda, and examined under the microscope, minute granules appear after a short time, which increase in size by coalescence until small globular bodies are formed—the process of molecular coalescence described by Rainey.

In this experiment the formation of the particles is considered to be due to surface tension; by this agency 'the first ultramicroscopic particles are brought together', and these further coalesce into visible particles, and finally into the large calcospherites.

It is surface tension that maintains the form of a drop of fluid, and in considering the chemistry of colloids Ostwald has shown that when a substance begins to separate out from a solution it always makes its appearance first as a liquid. In colloidal suspensions the material appears first in a condition of solution, and as it passes from this to the

condition of suspension, the rounded contour of the liquid form produced by surface tension is maintained, while a process of crystallization tends to take place throughout this little liquid globule. This is the explanation which has been given of the first determination of the rounded forms which occur in colloidal substances, and there are many phenomena which point to the correctness of this view.

The more recently investigated phenomena of adsorption which are intimately associated with surface tension no doubt take an important part in the processes of calcification in the living body.

These phenomena depend upon the power of the adsorbed substance to lower the surface tension, and itself accumulating at the surface it leads to the formation of membranes, and bears an intimate relation to the phenomena of osmosis.¹

Both Rainey and Harting found that when calcium phosphate was present in the solutions in excess of the carbonate, globular bodies were not formed, but the deposit was crystalline, but if there was only a small proportion of phosphate to carbonate, larger and more perfect spheres were produced than with carbonate alone. This observation has a most important bearing on the subject of the calcification of the hard tissues of the teeth, as in completed dentine and enamel the phosphates are largely in excess; but this question will be further considered in discussing the calcification of enamel.

In the works of Harting and Rainey a full and minute description is given of the various forms in which the calcific matter is deposited.

Two main forms of calcospherites may, however, be conveniently distinguished—those in which radial striæ are most evident and those especially marked by concentric lamellæ or rings, although there are many which show both structures. In developing enamel it will be shown that the deposited spherites belong to the radial system, while in dentine they are of the concentric form (fig. 80).

¹ For a further study of the phenomena of adsorption the following works may be consulted: D'Arcy W. Thompson, *Growth and Form*, p. 277, &c.; Bayliss, *Principles of General Physiology*, pp. 54-73; Taylor's *Chemistry of Colloids*, p. 221, &c.; and W. Ostwald, *Grundriss der Kolloidchemie* (1909).

In many parts of the calcareous deposit in the albumin experiments, the globules are seen to have coalesced; they are often arranged in rows around a central extension filled with minute spherites, and in other places where in contact, have become fused into larger bodies, hour-glass-shaped and double spherites being very frequent.

The larger ones show a tendency to disintegrate, the central part breaking down into smaller elements (fig. 80, *f*). In many of the larger radial spherites, beside the delicate

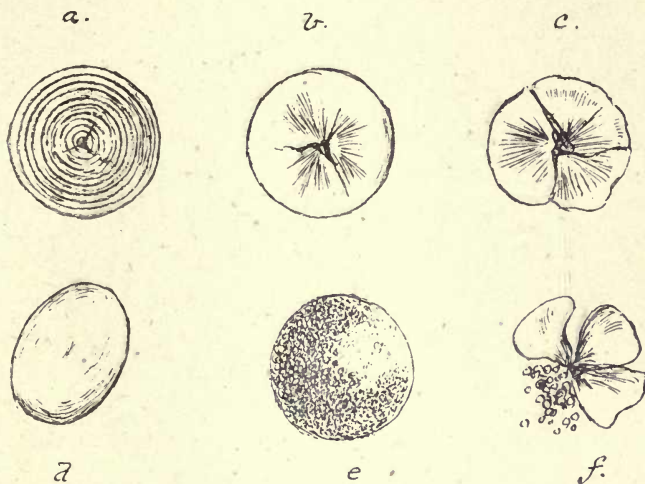


FIG. 80. Calcospherites. *a*. Concentric form (formed in albumin); *b*. radial form (formed in albumin); *c*. radial spherite from marsupial forming enamel; *f*. a similar one disintegrating; *d*. oval spherite from human developing enamel; *e*. granular spherite from human enamel.

radial striæ, wider spaces are seen extending from the centre to the circumference, of an irregular shape, and evidently indicating a splitting or dividing of the spherite into sections. This is frequently seen in the disintegrating globules in enamel, presently to be referred to.

The occurrence of calcospherites in the living animal may be well studied in the carapace of the prawn and in the claw of the crab, as was pointed out by Rainey. A fragment of the transparent carapace of the prawn, mounted in glycerine without any previous preparation, shows the spherites very beautifully in all stages of coalescence and disintegration (fig. 81), and in the crab their incorporation in the hard

shell can be very distinctly followed in thin ground sections (fig. 82).

In all these organisms, in Crustacea, Mollusca, and Brachiopoda, there is a distinctly visible delicate fibrillar basis substance which appears to serve as a support to the deposited material secreted by the animal, and in which calcification takes place. This is a clear, apparently structureless, substance, and does not seem in any way to determine the actual arrangement of the particles. It is not a con-

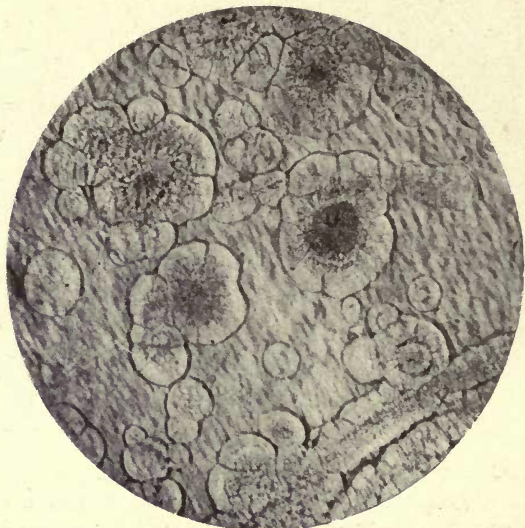


FIG. 81. Calcospherites in the carapace of the Prawn. ($\times 100$.)

nective tissue, and shows no connexion with cells. It is evident in all these examples that the shell is ultimately formed by the fusion of the calcospherites.

The view held by Bowerbank (3) and Carpenter (4) with regard to the formation of shell in the Mollusca was that 'shell is an organic formation growing by interstitial deposit in the same manner as in the teeth and bones of the higher animals'. This view, which accorded with the opinion held at the time, that enamel and dentine were formed by actual deposit in the formative cells, supposed that the same thing occurred in the Mollusca, and that in

Pinna and in other shells the membrane left after decalcification represented the organic cells in which the deposit of the lime salts had taken place. The view now generally held with regard to shell formation is that it is due to a process of secretion. This is more in accordance with modern views regarding the calcification of the teeth, which is considered to be produced by deposit in a material separated and secreted by the cells, and not by the direct

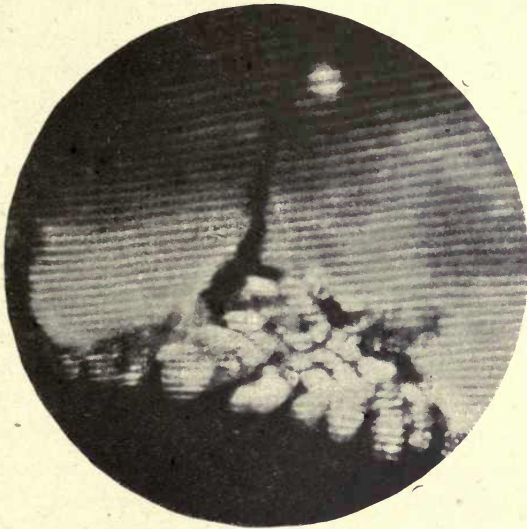

FIG. 82. Carapace of Crab showing striation and incorporation of spherites. Dark ground illumination. ($\times 500$.)

conversion of the cell into the calcified substance by interstitial deposit. The organic remainder after decalcification of a shell of *Pinna* would not, then suggest that these hexagonal outlines indicate cells, but that they were due to the remains of the fibrillar organic material present in all shells, in which the deposit takes place—the remains of the basis substance between the crystalline calcareous plates by which the prisms of this shell are built up.

In the brachiopod *Terebratula*, the fibrillar substance is very clearly to be seen in the mantle, and also in the remains of the decalcified shell there is no evidence of

any deposit in cells but in a very strongly defined irregular network of clear homogeneous material¹ (16 *b*).

Calcareous deposits are not then considered to be due to the plastic agency of the living cell but to physical processes, although, as stated by Professor D'Arcy Thompson, 'the developing concretion is somehow or other so associated with living cells that we are apt to take it for granted that it owes its peculiarities of form to the constructive or plastic agency of these', and further, 'the appearance of direct association with living cells, however, is apt to be fallacious, for the actual precipitation takes place, as a rule, not in actively living, but in dead, or at least inactive, tissue, that is to say, in the "formed material" or matrix which (as for instance in cartilage) accumulates round the living cells, in the interspaces between these latter, or at least, as often happens, in connexion with the cell wall or cell membrane, rather than with the substance of the protoplasm itself' (25).

3. Calcification of the Enamel

Two essentially different views have been held as to the part taken by the cells of the enamel organ in the process of calcification. By some, especially the earlier authorities, it was held that enamel is produced by the actual conversion of the cells into the calcified substance, and the incorporation of these cells in the formed enamel.

By others it is considered that the process is one of secretion by the ameloblasts, being comparable to the process of shell formation in the Mollusca, where the hard tissue is produced by a secretion from the mantle of the living animal.

According to the first view the calcifying salts would be deposited within the substance of the cell, which would thus be converted into the calcified enamel, but recent views on the subject would appear to suggest that the process is to some extent a combination of the two methods; that while

¹ Dr. Carpenter in his work on the microscope (4 *b*), published subsequently to his original paper, is disposed to agree with Professor Huxley 'in the belief that the entire thickness of the shell is formed as an excretion from the surface of the epidermis'.

the ameloblasts are receding as calcification advances, they do not themselves undergo conversion into enamel, but their processes, the Tomes' processes to be afterwards described, do become incorporated in it and form the organic foundation of the finished tissue. This will be more clearly understood when the appearances seen in forming enamel have been described.

While in Mammalia the ameloblast cells are undoubtedly the formative agents of the enamel, it has been pointed out by C. S. Tomes in the *Gadidæ* (26 *b*) among osseous fish, and in *Sargus* and *Labrus* by the author, that although in the earliest condition of the tooth-germ in these fish the ameloblasts are distinctly present, they disappear at an early stage, and their place is taken by other structures, into which the enamel cells have been apparently converted.

This disappearance of the ameloblast cells, as such, is especially remarkable, as even in the placoid scales of Elasmobranchs (the hard prominent tubercles of the skin of the sharks and rays) a layer of ameloblasts is distinctly evident during their development, and enamel appears to be formed by their agency, as in the true teeth. This will be further referred to in considering the development of the enamel in fish.

In the study of the calcification of mammalian enamel we shall include that of the tubular enamel of marsupials, for although the higher existing Mammalia may not be in the direct line of descent from the marsupials, the structure of their enamel is in all essential particulars similar to that of human teeth, and the presence of tubes probably only an indication of less complete calcification. The enamel is formed in the same manner as in higher orders, and is, as it were, a stage in the development of the teeth of more advanced forms. It is more slowly and less completely calcified, and consequently the stages in its formation are more easily studied.

A tubular condition of the enamel is seen in *Hyrax*, *Jerboa*, and the Shrews, where the enamel is in other respects similar to the enamel of other orders of the higher mammalia.

It may be stated that although in man and the higher mammalia no blood-vessels are seen deeply within the enamel organ, it was shown by Malassez, as explained

above, that the external epithelium in man is in many places discontinuous, and blood-vessels lie in direct contact with the cells of the stellate reticulum (see fig. 70). It has been demonstrated in many instances that beyond all doubt blood-vessels do penetrate the external epithelium, and are seen within the stellate reticulum of marsupials.

Mr. Thornton Carter says that in marsupials the ramifications of these vessels extend often as far as the stratum intermedium, but his fig. 21 is from a transverse section, and does not show to what depth this vascular network penetrates. He states, however, that in his preparations vessels are frequently seen 'in contact with the cells of the stratum intermedium' (5 a).

They do not, however, form any regular system in this situation, but are irregularly scattered in the reticulum, and suggest that they show a vestige of an earlier condition in which the presence of blood-vessels in the enamel organ was a more constant and regular phenomenon, and the condition gives rise to more interest in view of the observations of the author in recent investigations on the enamel organs of the Sparidæ and Labridæ, to be presently referred to, where a regular system of blood-vessels is seen in the enamel organ, and where it evidently takes a very important part in the calcifying functions.¹

If we agree with the statement of Röse (21) that the development of the stellate reticulum is intimately associated with the deposition of a thick enamel cap in the higher vertebrata, we must assign to this layer an important function in the process of calcification, and it is considered by Röse that the arrangement of the cells favours osmosis and the conveyance of nutriment to the growing cells of the internal layers; it may also assist in the separation of calcifying salts from the blood circulating in the vessels of the capsule.

The stratum intermedium, which is in intimate relation with the cells of the stellate reticulum, their processes communicating with one another, was considered by many to be the recuperating layer for the cells of the internal epithelium or ameloblasts; but after the formation of enamel has

¹ In *Pseudoscarus*, which is very closely allied to the Labridæ, blood-vessels also penetrate the enamel organ.

commenced, these cells, as has been shown, are cut off from the ameloblast layer by a separating membrane, so that it seems more reasonable to suppose that the principal recuperating effect they have on the ameloblast cells must be due to osmosis and the passage of nutrient material and lime salts through this membrane, although, as stated in discussing the inner ameloblastic membrane, the penetration of this separating layer by processes of the cells is quite comprehensible.

A very distinct function is, however, assigned by Leon Williams to the cells of the stratum intermedium in the later stages of enamel formation, when the stellate reticulum has disappeared and the external epithelium is in contact with the cells of the stratum intermedium.

He describes blood-vessels in the stratum intermedium at this stage, and that there are blood-vessels in this layer is fully evidenced by the photographs in illustration of his paper.

When, however, this author speaks of the incorrectness of the statements of Wedl and the majority of observers that no blood-vessels are seen in the cells of the enamel organ proper, he scarcely conveys the true meaning of their statement. In the early stages of enamel formation, when the stellate reticulum intervenes between the external epithelium and the stratum intermedium, no blood-vessels are seen in the enamel organ except vestiges of them in the stellate reticulum of marsupials, and at the outer border of the stellate reticulum in man (see figs. 70 and 72). It is only in the later stages of calcification that this supply of blood-vessels can be seen, when the stellate reticulum has disappeared and the external epithelium is in contact with the stratum intermedium, and the abundant vessels of the connective tissue of the follicle are in intimate relation with this layer of cells. He has shown, and one cannot but think very conclusively, that in the rat blood-vessels enter the stratum intermedium in these later stages very abundantly, and that they have a special arrangement with regard to the cells.

In this later stage of calcification he says that the characteristic forms of the cells of the stratum intermedium have

entirely disappeared, and their place is taken by a definite secreting structure.

He describes and figures capillary loops alternating with epithelial papillæ, and in fig. 15 in the illustrations to his paper shows these 'secreting papillæ' pulled away from the capillary loops, and it is very evident that the vessels dip in between the papillæ.

Fig. 76, from a photograph of the enamel and enamel organ of the rat, from a specimen of the author's prepared by the Weil process, also shows these papillæ and blood-vessels.

The same author also describes these papillæ as being in intimate relation with the ameloblast cells beneath them, 'each ameloblast seeming to have a root-like process which extends into and is lost in the substance of the papilla to which it belongs'.

It would be evident, however, that if this is the case, the outer ameloblastic membrane separating the cells of the internal epithelium from those of the stratum intermedium must have either disappeared, or it must be perforated by 'the root-like processes of the ameloblasts'. That such processes do pass through this separating layer between the stratum intermedium and the ameloblasts is, we think, evident in many preparations.

The present author, in his investigations on enamel development in certain fish, found and figured a similar condition in the enamel organ of one of the *Læbridæ* (*Pseudolabrus japonicus*), and, as shown in the paper on the subject (16 d), in these fish the whole of the enamel organ appears to be converted into a secreting structure, there being no trace of the cells of the internal or external epithelium, unless the cells within the secreting papillæ represent some constituent of the enamel organ of mammalia.

Leon Williams was unable to detect this definite arrangement in other mammalian enamel organs, but only in the Rodents, although in the sheep he found the cells of the stratum intermedium show a more or less orderly arrangement around capillary loops.

In some specimens of the enamel organ of *Macropus* the cells of the stratum intermedium are seen to have lost their

characteristic form, and large highly refractive globular bodies are seen in their place (fig. 83).

Leon Williams, in summing up this part of his subject, says: 'It is now perfectly evident, however, that in the development of enamel the cells of the stratum intermedium play the most important part in the selection from the blood of the material for the construction of this tissue. The formation of enamel begins, however, before the full develop-

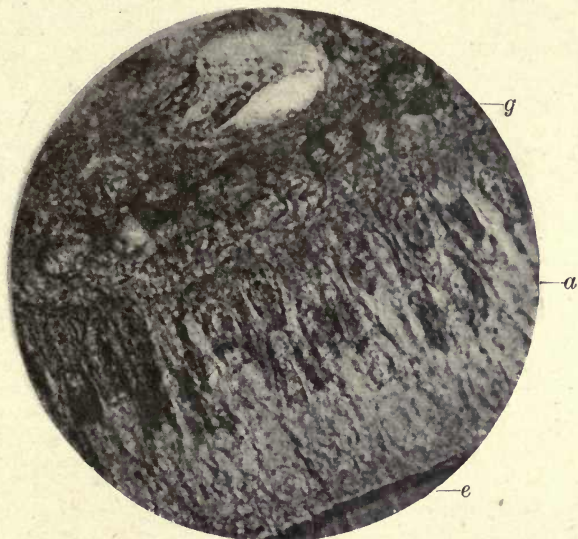


FIG. 83. Developing tooth of *Macropus*. Late stage of calcification of the enamel. *e*. Enamel; *a*. ameloblasts; *g*. globular bodies in stratum intermedium. No Tomes' processes are visible. ($\times 700$.)

ment of the stratum intermedium, and it is highly probable, as has been pointed out by previous writers, that the material for the commencement of enamel formation is stored in the stellate reticulum.'

The cells of the internal epithelium of the enamel organ, or ameloblasts, are in Mammalia the active agents in the formation of the enamel. These are elongated columnar cells with large nuclei, which are situated in that part of the cell most distant from the forming enamel (figs. 84 and 85 and Plate IV).

Ameloblasts.

The cell shows a fine reticular structure, and in thin sections the fibrillar constituents are seen to be arranged more or less parallel with the long axis of the cell. The

nucleus shows a delicate nuclear network and one or more nucleoli, and as Leon Williams says, 'it seems almost a foregone conclusion that these cells must be renewed, or at least that the necessary increase in number during the progress of enamel development must come from cell division', but the actual process of cell division in the ameloblasts had not, however, been observed.¹

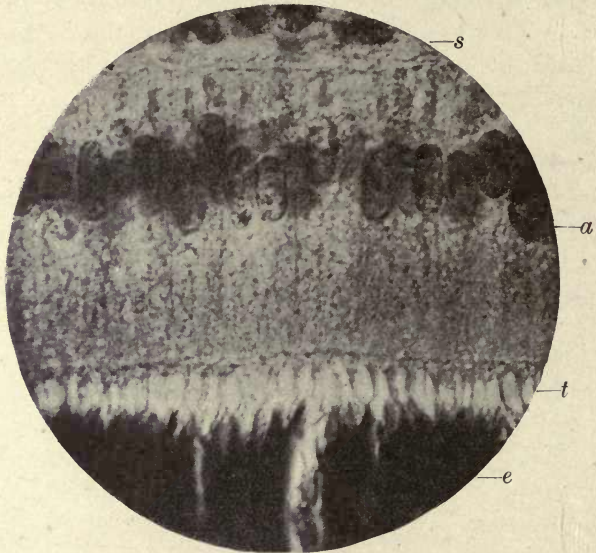


FIG. 84. Developing tooth of *Macropus* cut without decalcification. *a*. Ameloblasts; *t*. Tomes' processes; *e*. enamel; *s*. stratum intermedium. ($\times 700$.)

Mr. Thornton Carter has, however, lately described mitosis in the ameloblast cells and in those of the stratum intermedium of marsupials at the stage immediately preceding the formation of a thin layer of dentine over the pulp, but was unable to detect it in later stages. He divides the life-cycle of the ameloblasts in marsupials into fourteen different stages (5 *a*).

As first pointed out by C. S. Tomes, sometimes during active deposition of the enamel the nucleus is crescentic in form (26 *d*), and the fine fibrillar elements of the cell body

¹ For the description of amitosis in the late stages of the enamel organ cells see under 'Nasmyth's Membrane', p. 333.

appear to be connected with the horns of the crescent, which are directed towards the forming enamel (see fig. 85).

Granules and clear oval bodies are also seen within the cell when the deposition of enamel has commenced. These oval bodies are variable in size and shape, and do not react

Globules
in amelo-
blasts.

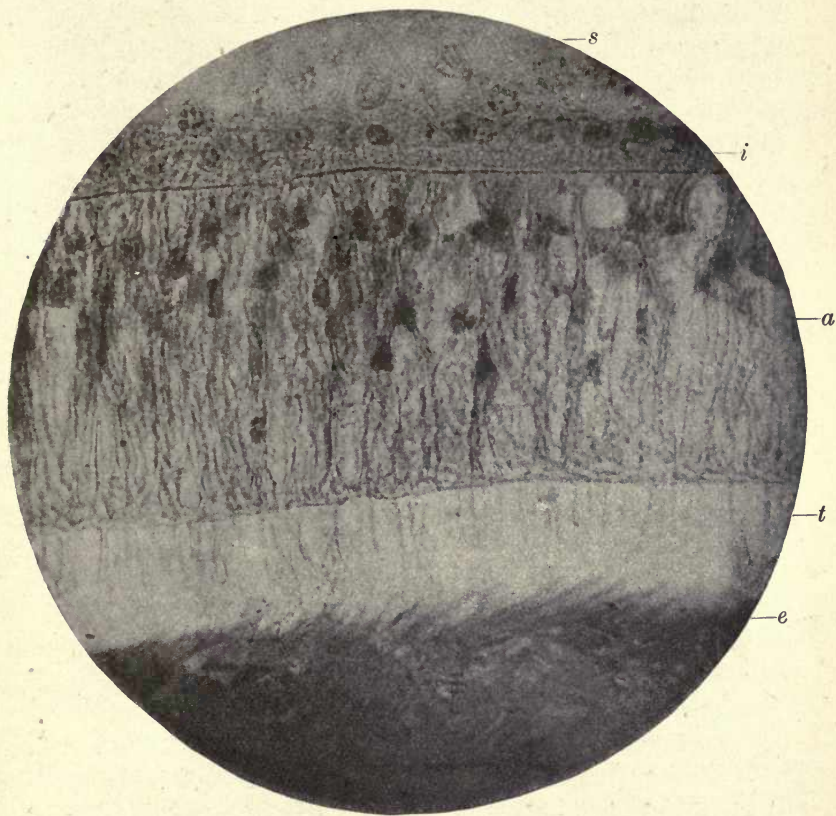


FIG. 85. Enamel organ of *Macropus* (cut without decalcification). *s.* Stellate reticulum; *i.* stratum intermedium; *a.* ameloblasts; *t.* Tomes' process; *e.* forming enamel. (The interlacing of the fibres of the Tomes' processes and the continuity of these fibres with the cytoplasmic threads in the ameloblasts are seen.) $\times 800$.

to polarized light. They would appear to be globules of material of a colloidal nature secreted by the cell, and in all probability the material which is elaborated by the cell and containing the calcifying salts.

These globular bodies in the ameloblasts have been

described more especially by Arnell (2), Graf v. Spee (23), Von Ebner (8), and Leon Williams. They are very evident in the cells as soon as enamel deposition has commenced, and that they do contain the calcifying elements there seems to be very little doubt, although C. S. Tomes and others, while quite convinced of the appearance of these bodies, do not feel in a position to give any positive opinion as to their nature.

When calcification is about to commence, the ameloblast cells become separated from the cells of the stratum intermedium by a delicate membrane, although prior to the commencement of the process they show no signs of such separation, but the cells of the stratum intermedium are in many places seen to be lying between the ameloblasts as shown in figs. 75 and 77.

This membrane once formed, no such intermingling of the cells of the two layers can ever be seen, but they remain quite distinct from one another.

At the same time another delicate membrane-like layer is formed between the ends of the ameloblasts and the forming enamel. These two membranes, called by Leon Williams the outer and inner ameloblastic membranes respectively, are supposed to take an important part in the calcifying process, and to act as dialysing membranes to separate the lime salts from the albuminoid material contained in the cells. As shown in the experiments with inorganic solutions above referred to, such a process takes place through the membranes of precipitation formed in the solution of silicate of potash, the lime salts contained in the water being separated by dialysis and deposited on the distal side of the membrane as calcospherites.

Professor Huxley, as previously stated, described an inner ameloblastic membrane under the name of *membrana preformativa*, and he also considered that the calcification of enamel took place 'by the transference of crystallizable products through a membrane'.

In a recent paper, referred to more fully on p. 174, Mr. Thornton Carter denies the existence of an outer ameloblastic membrane, but fig. 78 will, we think, give a clear indication of its existence. Whether these membranes are

separate structures or are formed by the union of the limiting membrane or wall of the cell, has not been determined. That in the case of both the outer and inner membranes, processes pass through them from the cells, both of the stratum intermedium and the ameloblasts, there can be little doubt, but the protoplasm of the cell wall is not a rigid substance like a sieve, and is quite capable of acting as a dialysing membrane, although these processes do pass through it.

Both Tomes and Carter consider it an inexplicable anomaly that the dialysing membrane should be penetrated by the fibrils of the Tomes' processes; but while Tomes denies the existence of such separating membrane, Carter apparently allows the existence of some such structure, but not the processes of the cell, as he considers with Tomes that we could not have a dialysing membrane which is perforated by processes. In this connexion it may be mentioned that Ramon y Cajal¹ describes the intercellular bridges of epithelial cells as being covered with a prolongation of the cell membrane.

In order to avoid the distortion of the delicate tissues of the enamel organ so frequently produced by the employment of such reagents as alcohol and balsam, and the employment of heat in the process of embedding, the author in his investigations of enamel development made use of preparations hardened in formol and cut in the freezing microtome. These were stained with watery solutions of the dyes and mounted in glycerine or Farrant solution. By this method preparations were obtained which showed all the parts of the enamel organ in their proper relations to one another and free from the shrinking and distortion so often seen in preparations of tooth-germs.

The first notable point brought out in marsupial germs prepared in this way is the great distinctness of the Tomes' processes of the ameloblasts, as was pointed out by C. S. Tomes (figs. 84 and 85). They are not drawn out into thin lines or apparently pulled apart from the forming enamel, and are seen in many places to be nearly as wide as the cells from which they arise. C. S. Tomes says that these

¹ *Int. Monatschr. f. Anat. u. Histol.*, iii. 1886.

processes do not show any minute fibrillar structure, but certainly such structure appears to be indicated by the photographs (figs. 86 and 87).

Owing to the wide area of enamel which has only undergone partial calcification in early enamel germs of *Macropus*, the prolongations of the Tomes' processes can be traced in many sections all across this space to the dentine, and it was no doubt these extensions of the Tomes' processes which were described by Andrews, who was the first to draw attention to this fibrillar foundation of the calcified enamel (1).

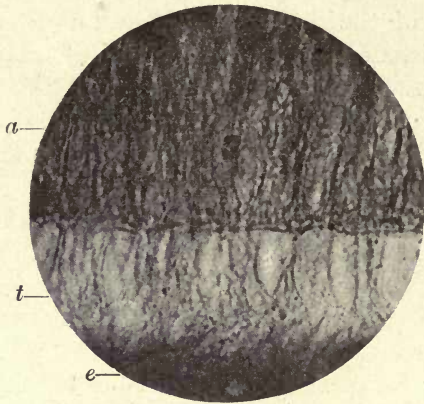


FIG. 86. Developing tooth of *Macropus*. *a*. Ameloblasts; *t*. Tomes' processes spreading out into the forming enamel (*e*). ($\times 700$.)

As the ameloblasts are separated from the forming enamel by a membrane, the inner ameloblastic membrane, this must be pierced by the Tomes' processes, which are processes of the ameloblast cell.

It has been long known that a fenestrated membrane can be detached from the surface of growing enamel by acids, but in some of the author's preparations, where no acids were employed, such a membrane is detached where the enamel is slightly separated from the cells. It is difficult to say whether this fenestrated membrane shown in fig. 88 was in contact with the ameloblasts or with the surface of the forming enamel, but it certainly does not require the action of an acid to bring it into view.

A structure has been described in forming enamel which

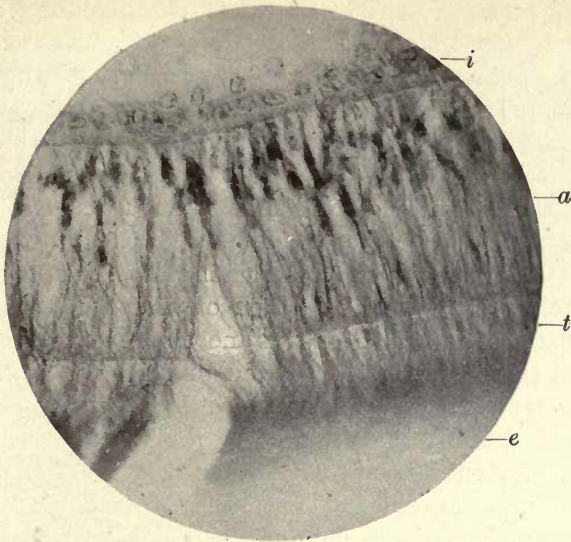


FIG. 87. Continuity of cytoplasmic threads of ameloblasts with Tomes' processes and forming enamel. *i*. Stratum intermedium; *a*. ameloblasts; *t*. Tomes' processes; *e*. enamel. ($\times 700$.)

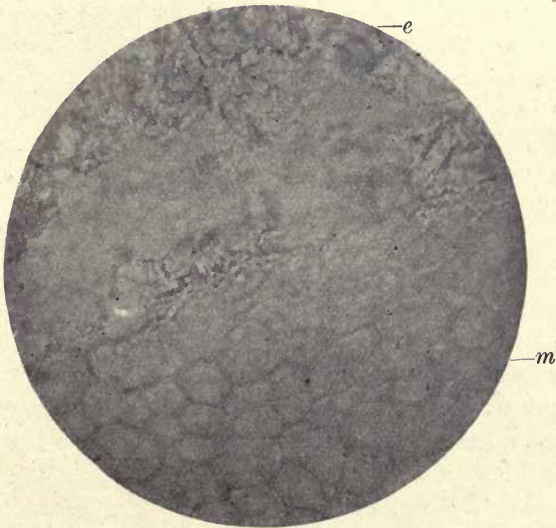


FIG. 88. Fenestrated membrane over forming enamel. Separated without the action of acid. *e*. Enamel organ; *m*. fenestrated membrane. ($\times 600$.)

The
honey-
comb.

appears to be present in all mammalian tooth-germs—the so-called 'honeycomb'.

At the point where the Tomes' processes enter the enamel, a structure is seen resembling a section of the cells of a honeycomb. This appears to consist of a substance on the borderland of calcification. It is resistant to acids, and exists only during the early stages of enamel formation. C. S. Tomes describes this structure as identical with the fenestrated membrane above described, which is raised from the surface of forming enamel by the action of acids; but, as already shown, this fenestrated membrane also becomes detached without the action of an acid, and would thus not appear to have a very intimate connexion with the forming enamel. Tomes considers that, although probably present in all mammalian enamels, the honeycomb is much more conspicuous and of greater depth in marsupials (26). It is much more evident in oblique sections than in those that are directly transverse, and he describes the Tomes' processes as entering this structure and filling up the orifices between the septa, the fibres adhering to the septa when the enamel is pulled away from the ameloblasts.

He consequently concludes that the process of calcification is a centripetal one, commencing at the septa of the honeycomb and gradually filling up the spaces between them. In marsupials, the centre remaining open owing to this process of gradual closing in of the space being incomplete, a tube remains in the central axis of the prism. In non-tubular enamel calcification advances to the complete closing and obliteration of this central tube. C. S. Tomes would thus look upon the tubes in marsupial enamel as entirely a product of the enamel organ, and their connexion with the tubes of the dentine with which they become continuous as a secondary matter.

According to this view of enamel calcification, there would be no true interprismatic substance.

It would appear as if the honeycomb was a structure of a transitory nature, and according to the present author's view it acts more as a directing structure to the fibres of the Tomes' processes than as a permanent constituent of the enamel prisms, for the evidence is very strong that the

calcification of the interprismatic substance takes place, at all events to a very great degree, independently from the calcification of the prisms.

It can be seen in figs. 86 and 87 that at the honeycomb region the fibres of the Tomes' processes spread out in a fan shape, the fibres from neighbouring processes crossing one another and intermingling, to be again drawn together to form the columns of the prismatic substance of the enamel. We thus see that the ultimate bundles of fibres which form the basis of the enamel prisms do not appear to be the direct prolongations of one particular ameloblast, but are contributed to by those in contact with it on either side.

As was first pointed out by Dr. Andrews of Boston, there is a delicate organic fibrillar foundation to enamel as there is in dentine, an organic network or scaffolding in which calcification takes place. The fibres described by Andrews were the prolongations of the Tomes' processes so clearly seen in marsupial enamel, and which, as previously described, are seen to extend all across the area of forming enamel to the dentine, when the process of calcification is but very little advanced.

Fibrillar
basis of
enamel

There are also other delicate fibres passing in a transverse direction, which are very evident in marsupial forming enamel and which are also derived from the ameloblast cells (fig. 89). This fibrillar foundation is also very evident in the enamel of the rat, as shown in Leon Williams's illustration on p. 22 of his paper taken from a preparation by the author, and the fibres, as he says, 'bear a striking resemblance to the effect produced by tearing a woven fabric of any sort'. Further evidence of the existence of this substructure in enamel is afforded by the experiment described on p. 104, where a delicate membrane-like foundation was left on the slide after the decalcification by strong acids, and the tubes of the enamel remained undisturbed within its substance.

Also in ground sections of marsupial enamel which had been treated with alcoholic fuchsin there is in many places an appearance of transverse stained lines which are evidently portions of the transverse fibres which have escaped calcification (fig. 53 B).

The existence of a fibrillar condition in forming enamel is

also clearly demonstrated by the following method. If an unerupted tooth of *Macropus* is taken from its crypt when the enamel forms a thin friable investment to the cap of dentine, and scrapings from this enamel are allowed to fall into glycerine and examined on a microscopic slide, it will be seen that when they are broken up with needles the fragments split into laminae which lie parallel to one another, and both the longitudinal and transverse striae are very clearly seen.

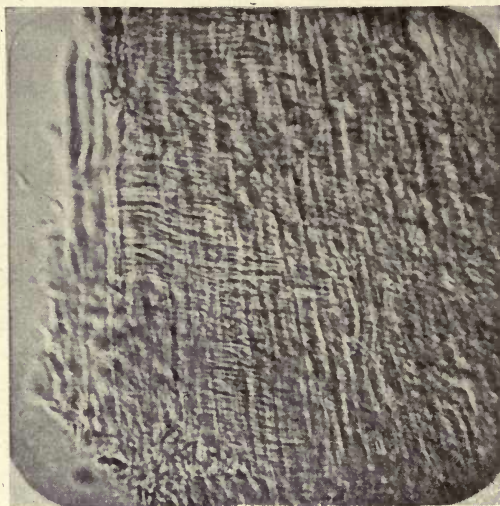


FIG. 89. Transverse striation in developing enamel of *Macropus*.

The most interesting point, however, demonstrated by this method is the presence of granules and large calcospherites between and upon the laminae.

In fig. 90, from a specimen prepared in this manner, the laminae are seen to have separated in the direction of the columns of the prisms, and a cross striation is also very evident. Large globular bodies are seen between the laminae and attached to their edges, while many of the larger bodies are lying free in the surrounding fluid.

Examination of a portion of these laminae with a high power shows that these globular bodies are true calcospherites of the radial type, and scattered granules are seen between

them. Some of the large calcospherites are seen to be splitting in a radial manner into three or four segments, and are surrounded by small granules. These large calcospherites vary greatly in size, but they also show the radial type of formation, no concentric spherites being visible.¹

Fig. 91 is particularly instructive, for it shows that small uniform calcified bodies are building up the enamel prisms, while large calcospherites are lying between the laminae and showing indications of breaking down into smaller particles.




FIG. 90. Fragment of enamel from developing tooth of *Macropus* teased out in glycerine, showing laminae and spherites. ($\times 140$.)

These appearances would seem to indicate that the enamel prisms are calcified independently of the interprismatic substance, the prisms being formed by the fusion of these small calcospherites into the regular blocks of calcified substance seen in mature enamel, while the larger bodies by their fusion and disintegration form the cementing or interprismatic substance. As will be shown later, however, and distinctly seen in fig. 94, these larger bodies are not always broken up, but become fused with one another.

¹ The calcospherites in these figures may be compared with the artificially formed spherites shown in fig. 80.

An examination of fragments of the enamel cap in human unerupted teeth, treated in the same manner, also showed the same appearances (fig. 92), but owing to the more rapid and dense calcification in human teeth the calcospherites are more difficult to detect, the separation of the laminæ not taking place to the same depth in the forming enamel as in marsupials. As in the first case, large calcospherites are seen free in the surrounding fluid; but while in marsupials these bodies are all round in form, in human enamel they

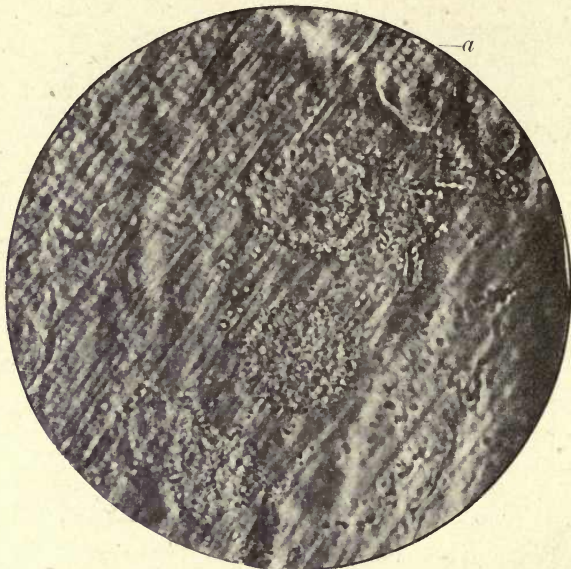


FIG. 91. Portion of enamel from specimen shown in fig. 90 more highly magnified, showing the beading of the prisms (*a*) and large radial calcospherites in the laminæ. ($\times 1,000$.)

are mostly oval, very few round ones being seen. They have the same radial structure, however, and two or more are frequently found fused together, forming an irregular mass.

A scraping from the surface of the enamel of a human tooth still in the crypt showed a large mass of calcospherites, the larger ones all having this oval form (fig. 93). Large scattered spherites are also seen in human enamel, which are uniformly and finely granular.

It is thus seen that there are in forming enamel two

different forms of deposit of the calcospherites: the small regularly arranged bodies which are deposited in the substance of the longitudinally arranged prolongations of the

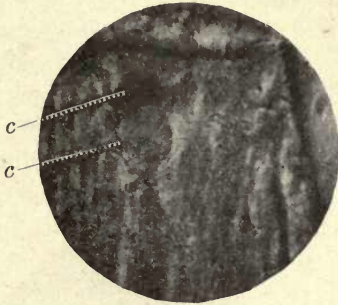


FIG. 92. Large spherites in human forming enamel. Teased preparation.
c. Calcospherites in the laminae. ($\times 500$.)

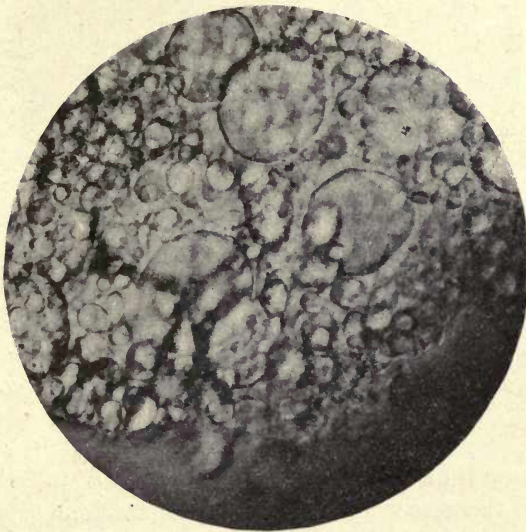


FIG. 93. Mass of calcospherites from surface of forming enamel of temporary human molar within the tooth-sac. ($\times 600$.)

Tomes' processes, and which build up the prisms of the enamel, and the larger scattered calcospherites between the laminae, which appear to be the calcifying agents of the interprismatic substance. These larger spherites are seen to be disintegrating in many places, and in others the large

spherites become fused together and form a calcified matrix for the enamel prisms.

That the interprismatic substance is formed by the fusion of these larger bodies and that they can be distinguished in fully formed enamel is shown by the following observation. A thin ground section of a human tooth which was affected by commencing caries, and showed a deep fissure in the enamel, nearly but not quite reaching the dentine, was examined under the microscope. Surrounding the fissure,

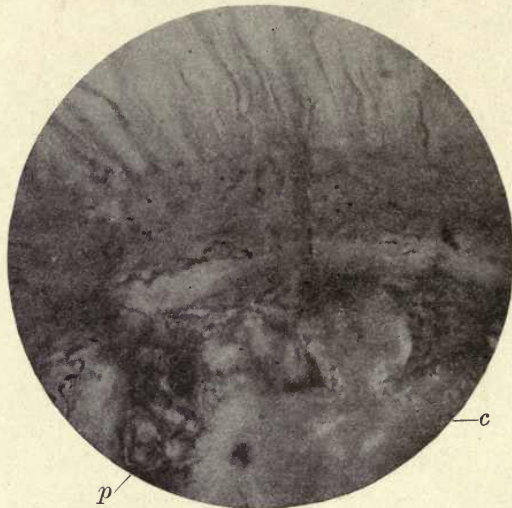


FIG. 94. Enamel of carious adult molar. Ground section (Weil process). *c.* Large spherites revealed by action of the acid in caries; *p.* transverse sections of the prisms showing their granular structure (compare with fig. 91). ($\times 1,000$.)

the contours of large calcospherites of a radial nature, similar to those seen in the teased preparations of marsupial enamel, are clearly visible, the acids produced in the carious process having dissolved a portion of the lime salts and revealed the actual contours of the calcific deposit. It would, therefore, appear that although many of these larger bodies in the process of calcification break up and become granular, others become fused together and still retain their original form (fig. 94).

Professor Underwood (28 *a*) described a similar appearance

in enamel which was not carious, but the subject of erosion, the contours of the spherites being there also distinctly visible, and he compared this appearance to that of the interglobular spaces in dentine.

These observations would appear to be strongly corroborative of the view held by Leon Williams and the author, that the interprismatic substance of enamel is calcified independently of the prisms, for it can be distinctly seen that the small regular calcifying elements of the prisms are quite distinct from these large calcospherites both during development and in the completed enamel.

Von Ebner does not hold with the view of Leon Williams and Andrews that the prisms are calcified independently of the interprismatic substance. He considers that each ameloblast is provided with a separate Tomes' process, which deeper in the first-formed enamel forms a separate enamel prism, and that all the enamel cells together form an interprismatic substance, in which the young prisms lie, and by which they are surrounded. The prisms he considers increase in thickness at the cost of the interprismatic material, and in quite homogeneous enamel are completely calcified.

He also states that thin layers of uncalcified cement substance extend to the free surface of the enamel, where they become continuous with Nasmyth's membrane.

With regard to the existence of laminae in formed enamel, which are arranged longitudinally between the dentine and the surface, evidence is afforded by sections of human teeth which have been treated with alcoholic fuchsin by capillary attraction. The stain is seen to have spread over the ground surface of the section in places, and if a section is examined during the process of grinding it is seen that these stained laminae are gradually ground away, portions of them often remaining in the finished section. The staining of these areas was long ago pointed out by Mr. Douglas Caush (6), and corroborates the evidence afforded by the teased preparations of marsupial enamel, which as pointed out previously break up into plates or sheets at right angles to the surface.

In the chapter on tubular enamel the reasons are given,

as evidenced in the completed tissue, for considering that these tubes are not an enamel product but are penetrating dentinal tubes, and the evidence in favour of this view, afforded by developing teeth, may now be considered.

Although, as in all other mammalian enamels described, calcification in the dentine in marsupials precedes that in the enamel, yet when a small layer of calcified dentine only is laid down, it can be seen that the area of enamel between

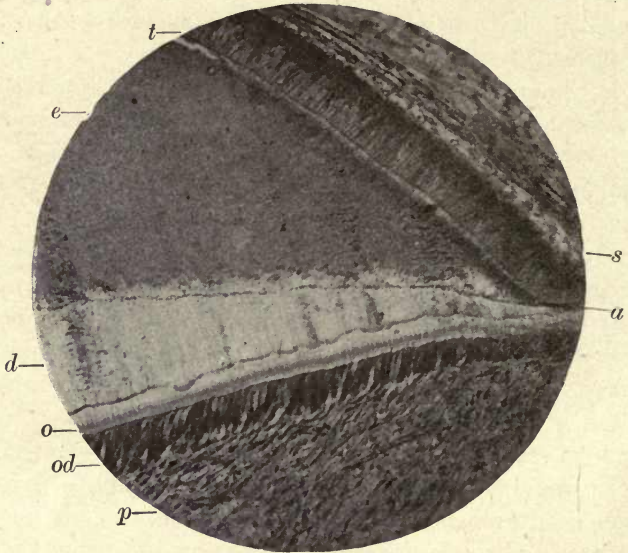


FIG. 95. Developing tooth of *Macropus* cut without decalcification. *s.* Stratum intermedium; *a.* ameloblasts; *t.* Tomes' processes; *e.* enamel; *d.* calcified dentine; *o.* odontogenic zone; *od.* odontoblasts; *p.* pulp. ($\times 75$.)

the ameloblasts and the dentine is very much wider than that of the dentine (fig. 95), but this space is occupied by the extended fibres of the Tomes' processes, and the calcification within and between them is very incomplete. In this section of an advanced germ of *Macropus* cut without decalcification, and in which there is no disturbance of the tissues, it is seen that a very much wider area of enamel than of dentine is laid down; in one part measured, the enamel was found to be three times the width of the calcified dentine. The stain employed (methylene blue) has uniformly

coloured the enamel a strong blue throughout the whole section, showing that very little calcification has taken place, and large calcospherites are seen near the dentine junction. The calcified dentine is quite unstained, while the odontogenic zone and the odontoblasts are a deep blue. It is also noticeable that the part of the enamel first laid down, bordering on the dentine, shows signs of still more incomplete calcification than the rest of the tissue. This appears a somewhat anomalous and curious condition. It would appear as if the ameloblast processes, where they extend to the dentine, leave spaces between them which very slowly become obliterated by calcification. These spaces can be clearly seen in figs. 96 (s) and 97, and lying in the spaces are round calcospherites such as are seen in the teased preparations. The presence of these spaces and of the large calcospherites would appear to indicate that a gradual closing in upon the enamel prisms takes place, while the enamel above has become more completely calcified, and may help to explain the presence of the dentinal tubes in the enamel.

C. S. Tomes says : 'The first-formed layer of dentine contains only the fine terminations of the dentinal tubes' (26 d), but an examination of many sections shows that although some tubes terminate in fine branching extremities before reaching the enamel junction, others, and often the majority, pass as large unbranched tubes to the enamel margin, and fig. 96 shows these tubes actually passing into the open spaces above described.

It is therefore probable that these spaces, which form the 'clumsy joint' of Tomes, are not due to inclusions of dentine matrix as suggested by Professor Paul (17), or to dilatations of the tubes in this situation, but to the imperfect calcification of the interprismatic substance surrounding them. If such spaces were due to intrusions of dentine matrix we should expect to find them well defined in early stages of enamel development, but instead of these irregular spaces we find an area of uncalcified tissue of an irregular form. As calcification advances, these spaces around the tubes are gradually encroached upon by the calcifying substance, but in most marsupials not completely closed in, and remain as the irregular spaces seen in finished marsupial

enamel. In some marsupials and in the tubular enamel of *Hyrax* the calcification is more complete in this situation, and the dentinal tubes pass into the enamel without showing any spaces or apparent enlargements. These spaces have

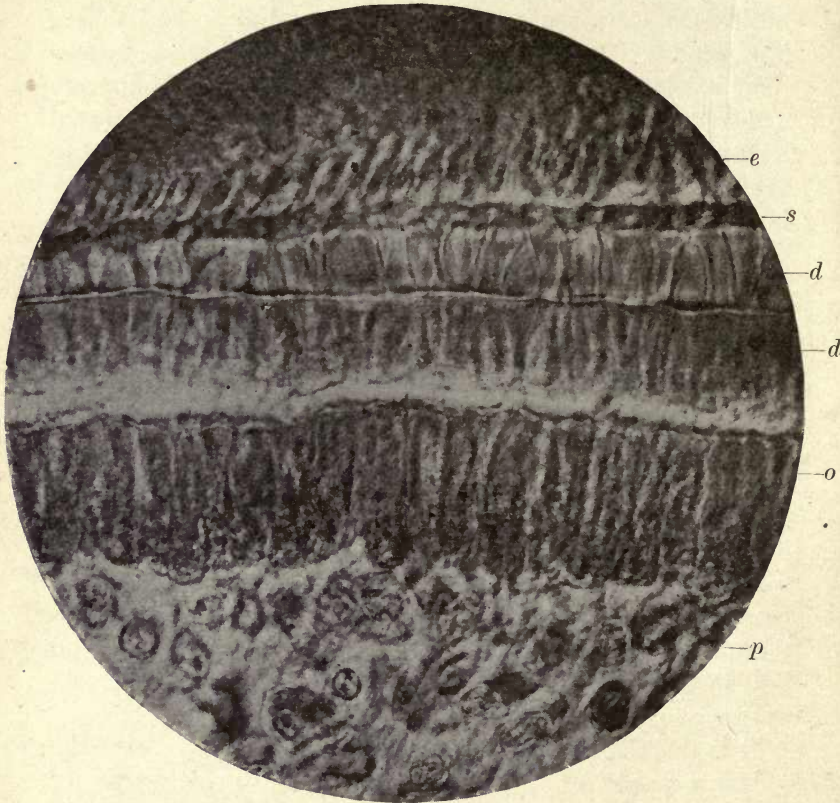


FIG. 96. Developing tooth of *Macropus* (cut without decalcification). *e.* Enamel; *s.* area of incomplete calcification; *d.* calcified dentine; *d'*. odontogenic zone; *o.* odontoblasts; *p.* pulp. In several places the dentinal tubes are seen passing into the area *s.* ($\times 800$.)

been previously referred to on p. 81, and this view of their causation agrees in the main with those of Von Ebner and Pickerill.

If, at the first formation of the dentine, the dentinal fibril passes into the organic substance of the enamel, and a connexion is thus established between the cells of the dentine

and the enamel matrix, it can easily be understood that the fibril would continue to penetrate this slightly resisting substance until eventually closed round by calcification.

The chemical composition of adult enamel presents a problem which it is somewhat difficult to elucidate in view of these observations on calcification.

It is seen that the calcific deposit in the interprismatic substance takes place in the form of large calcospherites, and that, despite opinions to the contrary, the globular form

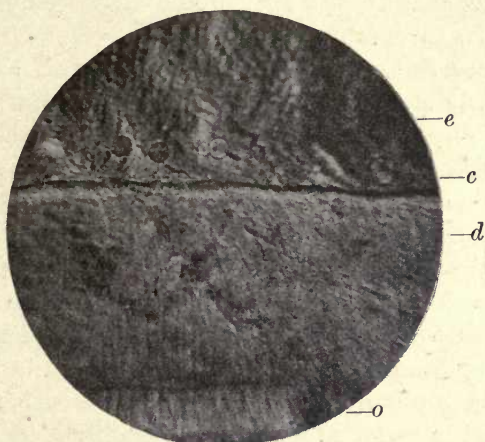


FIG. 97. Developing tooth of *Macropus*. *e*. Forming enamel; *c*. calcospherites; *d*. calcified dentine; *o*. odontogenic zone (cut without decalcification). ($\times 500$.)

is the form in which lime salts are deposited in the hard tissues of the teeth.

In the artificial experiments where these large calcospherites are deposited in albumin and other media, they consist of carbonate of lime, and although it was shown by Professor Harting that when a little phosphate of lime was present with the carbonate the largest and most perfect spherites were formed, if the phosphates were at all in excess of the carbonates, spherites were not formed but the deposit was crystalline.

The analyses of adult enamel show a very great preponderance of phosphates over carbonates—roughly 89 per cent. of phosphates to 4 per cent. of carbonates. In view of this

fact it is hard to understand how the large spherites, which in all outward appearance resemble the artificially produced carbonate calcospherites, are produced. We see no alteration of the spheroidal to the crystalline form, and when the structure of finished enamel is revealed by the action of caries and erosion the outlines of these large spherites can still be traced.

The question arises whether in the early stages of calcification the carbonates preponderate; but there are no analyses of forming enamel, and they would be very difficult, if not impossible, to obtain.

Professor Sims Woodhead (29), however, suggests that in the early stages of bone formation, which also shows an excess of phosphates in the completed tissue, the carbonates may be present in excess. He says, 'Newly formed bones, or new bone tissue of any kind, where the cells are extremely active in building up the matrix, almost invariably have a larger proportion of carbonate of lime than fully formed ones, because here the active cells set free a larger proportion of carbonic acid, as a result of which more phosphoric acid may be replaced by the carbonic acid lime salts'. The same conditions probably apply to the other calcified organic tissues of the body, as enamel and dentine. The conditions in young growing animals, where the metabolic changes are very active, are eminently favourable to the production of carbonic acid, and it is quite conceivable, and in fact probable, that in the early stages of enamel and dentine formation the carbonates may be greatly in excess of the phosphates, and thus the deposit of lime salts as calcospherites be better understood.

As stated by C. S. Tomes, Hoppe-Seyler considers that the salt in teeth and bone is a double salt, consisting of three equivalents of calcium phosphate with one of calcium carbonate.

Whether in this combination the influence of the carbonate may be effective in causing a globular deposit might be considered; but in whatever way we explain the chemical conditions which allow of their formation, we cannot escape the evidence that in both dentine and enamel the lime salts are deposited in the globular form.

There are no doubt many objections to the above explanation, and further researches are very desirable before we can have a clear understanding of the exact chemical conditions in calcification, but very considerable light has lately been thrown upon this question by the researches of Pauli and Samec (1910) (20), referred to by Professor D'Arcy Thompson in his work on *Growth and Form* (25), from which the following quotation is taken : ' It has been shown, in the first place, that the presence of albumin has a notable effect on the solubility in a watery solution of calcium salts, increasing the solubility of the phosphate in a marked degree, and that of the carbonate in still greater proportion ; but the sulphate is only very little more soluble in the presence of albumin than in pure water, and the rarity of its occurrence within the organism is so far accounted for. On the other hand, the bodies derived from the breaking down of the albumins, their " catabolic " products, such as the peptones, &c., dissolve the calcium salts to a much less degree than albumin itself ; and in the case of the phosphate, its solubility in them is scarcely greater than in water. The probability is, therefore, that the actual precipitation of the calcium salts is not due to the direct action of carbonic acid, &c., on a more soluble salt (as was at one time believed), but to catabolic changes in the proteids of the organism, which tend to throw down the salts already formed, which had remained hitherto in albuminous solution. The very slight solubility of calcium phosphate under such circumstances accounts for its predominance in, for instance, mammalian bone, and wherever, in short, the supply of this salt has been available to the organism.

' To sum up, we see that, whether from food or from seawater, calcium sulphate will tend to pass but little into solution in the albuminoid substances of the body ; calcium carbonate will enter more freely, but a considerable part of it will tend to remain in solution ; while calcium phosphate will pass into solution in considerable amount, but will be almost wholly precipitated again, as the albumin becomes broken down in the normal process of metabolism.' ¹

¹ D'Arcy W. Thompson, *Growth and Form*, pp. 434 and 435.

These observations perhaps afford a clearer insight into the actual method by which calcium phosphate comes to predominate in teeth and bone than any that have been hitherto presented, and if fully confirmed will remove many difficulties in the clear comprehension of the actual physical and chemical processes in calcification.

A very interesting research has been recently undertaken by Mrs. E. Melanby, the first results of which are embodied in a paper published in the *Lancet* on December 7, 1918. These experiments were undertaken to throw additional light on the influence of diet on tooth formation, and were carried out on the teeth of puppies. It would appear that the incorporation of the proper amount of calcium salts with the teeth is dependent not so much on the amount of calcium in the diet as on the action of some determining factor in the food which is the cause of the efficient allocation of calcium salts to the forming teeth. This determining factor would appear to be, in the author's words, 'a diet containing an abundance of those articles with which the fat soluble A accessory food factor is associated, e.g. cod-liver oil, butter, &c.', allowing 'the development in puppies of sound teeth'. A diet otherwise adequate, but deficient in the substances with which fat soluble A is associated, brings about defects in puppies' teeth. These effects are described as delay in the loss of the deciduous and eruption of the permanent teeth, and defective conditions of the enamel. The calcium may be present in the food in such a form that it can be easily taken up by the blood, but if this accessory food factor is absent, the cells of the formative organs of the teeth are unable to perform their calcium-separating functions with success 'owing to the lack of one or more factors in the blood-stream which normally regulate this function'. The further record of the results of these experiments will be awaited with much interest.

Summary It is generally considered that the calcification of enamel is brought about by a process of secretion from the cells of the enamel organ, and not, as stated in former times, by an actual conversion of the substance of the cell into enamel.

The Tomes' processes of the ameloblasts, however, *do* become incorporated in the formed enamel.

Blood-vessels are not usually seen in the enamel organ of mammalia, but vestiges of these are found in the external epithelium and in the stellate reticulum of some marsupials, and are described by Leon Williams in the stratum intermedium in the later stages of calcification in the rat. In the enamel organs of some fish, however, blood-vessels are

regularly arranged within the enamel organ and extend from the circumference to its free inner surface.

While the stellate reticulum probably serves as a storehouse of material for the commencement of calcification, the cells of the stratum intermedium play, according to many authors, the most important rôle in the selection of material from the blood for the completion of the process.

The ameloblast cells which constitute the internal epithelium of the enamel organ are the active agents in the elaboration of the calcifying products.

They contain clear oval bodies which are considered to consist of the colloidal material which is separated by them.

When calcification has commenced, a separating membrane is seen between the stratum intermedium and the internal epithelium and another between the cells of the internal epithelium and the forming enamel. These are called the external and internal ameloblastic membranes respectively.

Each ameloblast is furnished with a process or prolongation of a fibrillar nature—the Tomes' process. These processes pass from the ends of the ameloblasts to the forming enamel, and are incorporated in its substance, forming with other transversely arranged fibres the organic network or foundation substance of the enamel. This is most evident in marsupial enamel, but the same structure exists in other mammalian enamels, although it is much earlier veiled by dense calcification. Decalcification experiments confirm the existence of a fibrillar basis substance after the removal of the lime salts in marsupial enamel. This organic residue is derived from the ameloblast cells. It is within the substance of the longitudinal fibres or prolongations of the Tomes' processes that the calcification of the enamel prisms takes place.

The honeycomb is a fenestrated membrane-like substance seen in the outer part of the forming enamel to which the fibres of the Tomes' processes pass, and, according to C. S. Tomes, the fibres enter the interspaces and are attached to the septa. This honeycomb is considered by Tomes to be identical with the fenestrated membrane raised from the surface of forming enamel by acids; it also sometimes

becomes detached without the action of an acid. According to the author's observations the fibres of the Tomes' processes spread out in a fan shape at the honeycomb region, portions of the fibrillar process intermingling with those that surround them, and he considers that a rearrangement of the fibres takes place in the honeycomb region, resulting in the formation of the strands which extend in marsupials from the honeycomb throughout the whole width of the forming enamel to the dentine.

The forming enamel of marsupials and in a less degree human enamel, when teased out in glycerine, shows that the tissue is formed in distinct parallel laminae lying at right angles to the surface. Longitudinal and transverse striæ are visible in the laminae, and large radial calcospherites lie upon and between them. A regular deposit of small calcified bodies of uniform size is also seen in the forming enamel prisms.

The large bodies are concerned in the formation of the interprismatic material, while the smaller ones build up the columns of the prisms. The persistence of these large calcospherites in the interprismatic substance is shown in certain cases of caries and erosion in completed human enamel. Many of these bodies, however, split asunder and break down into small granules.

The clear bodies which are seen in the ameloblasts have been described by several authors; they are called by Leon Williams the enamel globules, and he describes them as 'passing down the ameloblasts and emerging from the membrane beneath their inner ends', the inner ameloblastic membrane before described. On the enamel side of the membrane these bodies, which are more or less regular in size and shape, are arranged along the fibres of the forming enamel and apparently become calcified as fine granules which become fused into the small blocks which form the calcified elements of the finished prisms. These blocks and their constituent granules are seen in figs. 18 and 91. He speaks of these bodies being 'compressed into disk-like shapes and sometimes partly or quite melted into one another'. The interprismatic substance appears to be formed independently of the prisms, and is produced

within a substance also dialysed through the inner ameloblastic membrane.

Large irregular-sized bodies are formed in this substance and by their fusion form the interprismatic material. As shown by the present author, these bodies take the form of large radial calcospherites such as are formed by carbonate of lime in the artificial experiments, and they are seen to be revealed in certain cases of caries and erosion. In fully formed perfect mammalian enamel these elements become so fused together and veiled by the dense deposit of the lime salts that it is difficult or almost impossible to detect them in many situations.

With regard to the origin of tubular enamel two fundamentally different opinions have been held. C. S. Tomes considers that the tubes are entirely an enamel formation, and are due to the calcification commencing at the septa of the honeycomb and gradually closing up towards the centre of what may be described as the cell of the honeycomb; in non-tubular enamels this closure is complete and a solid enamel prism results; in tubular enamels the calcification does not reach the centre but remains open and uncalcified as the tube.

The calcification of all mammalian enamel he would look upon as a centripetal process, and he would deny the existence of a true interprismatic substance in finished enamel.

The other view is that held by Professor von Ebner and the author, that the tubes of the enamel are not an enamel organ product but are true dentinal tubes included in the enamel. The arguments in favour of this view are given in the chapter on tubular enamel so far as the finished tissue is concerned. In developing enamel it is not considered that there is any evidence of an open space in the honeycomb, but the fibres of the Tomes' process enter, interlace, and are rearranged in the honeycomb region, and the deposit of the lime salts, as described by Leon Williams, takes place within them as a regular deposit of calcified granules arranged longitudinally, the interprismatic substance being separately formed and in marsupials remaining in great part uncalcified for a considerable time. The spaces described above between the forming enamel prisms at the

dentine junction permit the penetration of the rapidly growing dentinal fibril which eventually becomes closed round by advancing calcification.

According to this view there is a distinct interprismatic substance, and the process of calcification is a centrifugal one. Tomes considers that the process of calcification in all mammalian enamels is made clear by the view he takes of the process that tubular enamel only marks a stage in the formation of solid enamel prisms. The process is, however, quite as clearly explained by the other view, for the solid enamels would be due to the early and more complete calcification of the interprismatic substance preventing the penetration of the fibril from the dentine, and it appears to be more in accordance with the present knowledge of the development and structure of mammalian enamel.

In a recent paper (5*a*) Thornton Carter has adopted a new view of the nature of the tubes in marsupial enamel. He considers that marsupial enamel is not tubular, but that what is thought to be the tube is a colloidal product, and apparently not, strictly speaking, of an organic nature, and he does not consider that the Tomes' processes of the ameloblasts are processes of the cell, and thus acknowledges no fibrillar organic basis to enamel. He also considers Leon Williams's view of the structure of the enamel prisms to be erroneous.

Mr. Carter appears to consider the so-called enamel tube to be a naked fibril within the septa of a honeycomb structure arising 'from the coagulation or gel formation of an organic substance not usually present in the colloidal secretion shed by the enamel cells of most other mammals'. He would thus interpret the definite persistent structure seen in the enamel of marsupials as part of the 'gel' formation of a colloidal material secreted by the ameloblasts, yet he speaks of an organic substance present in this colloidal secretion which he considers to be of a protein nature. One had always considered that such colloidal product of secretory cells contained the lime salts in suspension, and that calcification took place within it. Analogy would lead us to expect that the colloid would be effused into an organic basis substance, and not that it would contain this invisible

organic material in suspension. The persistence of part of this colloid as a permanent 'gel' in the finished tissue is not, it appears, consistent with what we know of the physical processes involved in calcification. Uncalcified substances in the finished tissues are usually protoplasmic, and it is difficult, moreover, to see how the junction of this 'gel' substance, which he considers composes these fibrils, is effected with the living protoplasmic dentinal fibrils. The evidences of the actual presence of tubes in marsupial enamel are, however, so complete that it is very difficult to allow Mr. Carter's contention.

The passage of coloured fluids from the dentinal tubes along channels in the enamel, and the fact that in dried specimens these fluids run out again unless due precautions are taken, seems conclusive evidence of their tubular nature. In this method of staining applied to teeth in which the soft parts have been fixed, the fluid does not run out, but is retained by the tube contents which we have considered to be of a protoplasmic nature.

Mr. Carter says there are no spaces between the prisms, not even at the dentine junction, but figs. 96 and 97 scarcely support this contention. The author denies the existence of Tomes' processes of the ameloblasts and says, 'there is not the slightest evidence of any cytoplasmic structures such as Tomes and Mummery believe to be present'; and again, 'in forming marsupial enamel there is no trace of the existence of such prolongations of the cytoplasm of the ameloblasts as those on which Tomes has based his theory of enamel development'.

In his own investigations the present author has traced the cytoplasmic threads of the ameloblasts distinctly into these processes, and also can see them in numerous preparations becoming incorporated in the forming enamel as shown in figs. 86 and 87. From these appearances it seems impossible to accept Mr. Carter's explanation of them as a colloidal deposit, and there is every evidence they are of an organic nature and a portion of the ameloblast cell, and that Mr. Tomes's view that they enter into the formation of the prisms is correct. It would appear that these processes being proved to be prolongations of the cell, the whole of

Mr. Carter's argument as to the structure of marsupial enamel must fail, as it would be shown that the enamel is laid down in a fibrillar organic basis substance and is not merely a colloidal product. With regard to the deposition of the lime salts, Mr. Carter considers Leon Williams's views are erroneous, and describes a sponge-work formation with large meshes in which what he considers to be the fibril is

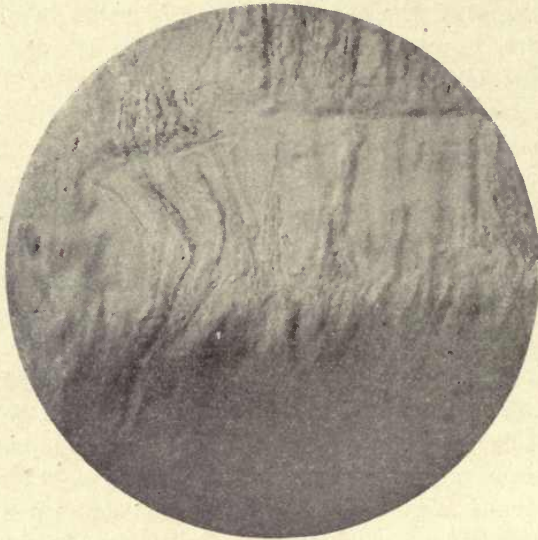


FIG. 98. Macropus. Incorporation of Tomes' processes in the forming enamel. ($\times 1,000$.)

laid down and a further congelation of the colloid with regular meshes in which the lime salts are deposited to form the prisms, the regular meshes being as it were the moulds in which the calcific matter is deposited. The illustrations to this book we think give the strongest support to Leon Williams's view.¹

Fig. 98 shows very clearly the incorporation of the Tomes' processes in the forming enamel.

¹ For a fuller discussion of this question see the author's reply to Mr. Carter in the *Proceedings of the Royal Society of Medicine*, May 1918.

Development and Calcification of the Enamel in Fish.

The first appearance of a true enamel organ in vertebrates is seen in the development of the placoid scales or dermal spines of the Sharks and Rays (fig. 99).

Hertwig's well-known researches on this subject demonstrated that a distinct enamel organ and dentine germ is concerned in the calcification of the placoid scale, and this is clearly comprehensible in view of the fact before referred to that teeth and dermal scales are similar structures, the one merging into the other at the margin of the jaws.

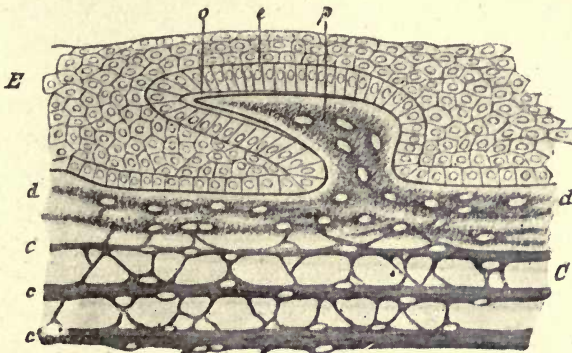


FIG. 99. Vertical section through the skin of an embryo shark. *C*. Dermis; *c, c, c, d*. layers of the dermis; *E*. epidermis; *e*. enamel organ; *o*. enamel layer; *p*. papilla of the dermis. From Wiedersheim in *Camb. Nat. History*.

These scales are developed in the mucous membrane and have no developmental relation to the bones. The teeth are produced in the same manner and their connexion with the bones is purely secondary, so that the teeth in all vertebrates may be accurately described as dermal appendages.

These external skeletal appendages are formed both from the ectodermic cells and from the mesoderm. In general histology the cells which secrete the hard structures of both dentine and bone are termed scleroblasts, a term which would include both odontoblasts and osteoblasts. The scales of the bony fish (Teleostomi) and of the Dipnoi (*Lepidosiren*, &c.) are derived solely from the dermis and

possess no enamel cap, but the dermoid scales of the Elasmobranchii (Sharks and Rays) are composed of enamel formed from the ectodermic epithelial cells, and of dentine produced from the mesodermic scleroblasts.¹ The papilla of the dermis forms a pulp cavity around which the dentine is secreted, and the dentine is covered by a layer of true enamel formed by ameloblasts. Beneath the dentine is a basal plate of bone which is perforated for the passage of blood-vessels to the pulp cavity. It is thus seen that placoid scales and teeth are both structurally and developmentally identical, but the true teeth of the sharks, which are developed under the thecal fold of mucous membrane which covers them, attain to a larger size and more complete differentiation of the tissues composing them.

In Plagiostomes.

In the Plagiostome fish the nature of the outer layer of the tooth has been the subject of much controversy, Röse and several other authors considering it to be a form of dentine, but Tomes, after a consideration of all the evidence, looks upon it as enamel.

In the developing tooth of the sharks the cells of the dentine papilla do not appear to be specialized as an odontoblast layer, but the surface of the mesoblastic dentine papilla consists of a delicate fibrillar tissue, the fibres lying parallel to the surface, and long processes of the underlying cells, which rapidly increase in number, are continued into this layer. As Tomes says, 'The great and most striking peculiarity of these tooth germs lies in the fact that the first apparent calcification of the true dentine, whether it is a fine-tubed dentine as in *Carcharias*, or an osteodentine as in *Lamna*, takes place, *not at the outside of the whole papilla as invariably happens in mammals, but at the inner side of the specialised layer*, thus cutting it off from the rest of the pulp' (26 a). Beneath this specialized layer the calcification of the dentine proceeds as in ordinary tooth germs, and it is within this previously formed layer that the calcification of the tissue considered to be enamel takes place. This calcification is not, however, brought

¹ It has been affirmed by Klaatsch that the scleroblasts are also of epidermic origin, but this statement has not been generally received. Klaatsch, *Morph. Jahrb.*, xvi, 1890, pp. 97 and 209.

about by the cells of the dentine pulp, but takes place under a distinct layer of large ameloblasts derived from the epiblastic epithelium of the mouth. It is seen that a deposit of enamel takes place within the tissue which is previously laid down by the mesoblastic dentine papilla, and we have the apparent anomaly of a deposit of enamel by true enamel cells within a matrix derived from the dentine papilla.

It was considered by Hertwig and Röse that these ameloblasts are concerned only in the production of a surface membrane (*Schmelzoberhäutchen*), but C. S. Tomes states that 'no such membrane can be raised from the surface when advanced in calcification'. Tomes, to whom our knowledge of the development of the enamel in Plagiostome fish is chiefly due, sums up his important researches on the subject as follows :

'The outer hard layer which covers the teeth of *Selachia* and Ganoids does not correspond exactly either with the dentine or the enamel of mammalia.

'In structure it ranges by slight gradations from the simple and thoroughly enamel-like tissue met with in the Rays to the complex tubular tissues' in many sharks.

'It is not a dentine, because it has no collagen matrix, the organic tissue which it contains being easily soluble in weak acids.

'While this organic matrix is beyond question furnished by the mesoblastic dentine papilla, the epiblastic ameloblasts over it are in a state of development which implies that they take an active part, and that the tissue is a joint production.

'Though it is not fully demonstrable what that may be, it upon the whole seems probable that they furnish it with its calcifying salts.

'Just as the entire teeth of Selachians present the problem of tooth formation reduced to its simplest aspects, so this layer appears to be the first introduction of enamel as a separate issue, and therefore, to avoid multiplication of terms, it may be appropriately called enamel.'

The structure of the enamel organ and development of the enamel in osseous fish has only been thoroughly studied in a few families, and much further research is necessary,

In osseous fish.

especially in view of the very remarkable conditions which have been found in many of those already examined.

An investigation of the development of the enamel in the Gadidæ (Cod family) was published by C. S. Tomes in 1900 (26*b*), and a special investigation of the conditions in the Sparidæ and Labridæ (Sea-breems and Wrasses) was published by the present author in 1917.

A very curious and anomalous condition is seen in the enamel organ of the Cod family as described by Tomes. In the early stages of development there are no marked peculiarities of the enamel organ; the odontoblast layer is well developed, and there is a distinct external epithelium, but no stratum intermedium or stellate reticulum separating the two layers, and the enamel organ is enclosed within a definite tooth-sac. In the next stage described, the ameloblasts have entirely disappeared and their place is taken by a delicate reticulate structure.

A considerably greater amount of forming enamel is laid down than of dentine, in one measurement taken the width of the dentine being $18\ \mu$, while that of the enamel was $90\ \mu$. This, he states, 'is a reversal of the order of procedure obtaining in mammals, in whom the dentine always antedates the enamel considerably'. In marsupials, however, a similar condition is seen, the width of the layer of forming enamel far exceeding that of the dentine (see fig. 95). C. S. Tomes also describes an appearance of fibrillation within the delicate stroma—this fibrillation being arranged at right angles to the dentine—and he considers that the appearances are not very different from those which would result from the approximation of thin-walled tubes and perhaps some interstitial substance, a sort of honeycomb with enormously elongated cells. He also states there are no cells visible. Transverse sections are described as showing circular clear spaces surrounded by a stained area in sections treated with hæmalum. He describes abundant blood-vessels in the walls of the tooth-sac, but states that they do not enter the enamel organ. The same author points out that a peculiarity in the development of the enamel in these fish is 'that after the transformation of the ameloblasts into the stroma there are no conspicuous cells to which can be assigned the

function of separating out the lime salts, a function which is apparently discharged by the ameloblasts in mammalian tooth germs . . . so that one is driven to the conclusion that, the stroma once formed, it is able to draw into itself the required lime salts and to deposit them at that point which is furthest from the vessels'.

A paper by Mr. Thornton Carter on the development of the enamel in the Hake has recently appeared. He states that the cells of the external epithelium and the ameloblasts 'remain in contact throughout the whole life history of the enamel organ', and describes the changes which take place in the ameloblast cells. He denies the disappearance of these cells and states that they do not disappear but become elongated and vacuolated, and there is no evidence that the ameloblasts become transformed into a stroma which becomes incorporated in the enamel. For a consideration of the evidences in favour of this view the reader is referred to the original paper (5 b).

The present author has found large nucleated cells lying in a stroma in the Haddock (*Gadus æglefinus*), the whole bearing a strong resemblance to a stellate reticulum, but not being able to procure absolutely fresh material was unable to carry out the investigation. The cell structure of the enamel organ cannot be properly studied in imperfectly fixed material, as the author found in his first attempts to demonstrate the structure of the enamel organ of *Sargus ovis*. Mr. Carter states that an interval of even five minutes after death, before fixation, is sufficient to interfere with the finer reactions of cells to stains, and specimens of fish should be placed in the fixing solution as soon as caught.

Tomes confined his investigations chiefly to the enamel organs of the Gadidæ. He also examined the development of the enamel in *Sargus* and *Labrus*, but was unable to obtain satisfactory preparations owing to difficulties which he considered 'almost insuperable', the tooth germs being so deeply placed in the bone that fixing agents did not reach them.

It appeared to the author that if the jaw of a fresh specimen of *Sargus ovis* was cut up at once and placed in the fixing solution, this difficulty might be overcome, and

through the kindness of Dr. M. Cryer of Philadelphia he was able to obtain material prepared in this manner, which gave very satisfactory results, and he ventures to think, shed an entirely new light on the process of calcification in certain fish.

From the preparations of *Sargus* germs which he did obtain, Tomes considered that the process was in all essentials the same as in the *Gadidæ*. It is, however, very evident from a study of the author's sections that the process is not the same as described by Tomes in the *Gadidæ*.

The dental germs of fish are so very delicate that the ordinary treatment with alcohol and paraffin is quite inapplicable to them.

Specimens hardened in formol were decalcified in formic acid, embedded in gum solution, and cut in the freezing microtome. The use of alcohol at any stage was avoided, and the specimens were mounted, after staining, in Farrant's medium. Some specimens of *Sargus* made in the ordinary manner and embedded in paraffin showed that in early stages there is a distinct layer of ameloblasts and an external epithelium as in the *Gadidæ*, and that a layer of enamel had been deposited under the influence of the ameloblasts.

Later germs showed the apparent disappearance of the ameloblasts as in *Gadidæ*, but although a stroma was seen with parallel striæ their structure was very indefinite, and while there were indications of the presence of blood-vessels in the enamel organ they could not be clearly distinguished. The frozen sections, however, showed that the earlier ones were badly shrunk from the treatment with heat and alcohol, and gave a very different appearance.

In these sections there is a very clearly defined capsule with abundant blood-vessels, and a structure is seen between the capsule and the forming enamel which is arranged in parallel lines at right angles to the surface, and does not quite reach the forming enamel, from which it is separated by a narrow band of delicate reticular tissue (fig. 100). An examination of these parallel striæ shows that they are made up of blood-vessels in direct continuation with those of the capsule, regularly alternating with an apparently tubular substance with concave margins (figs. 101 and 103). Between

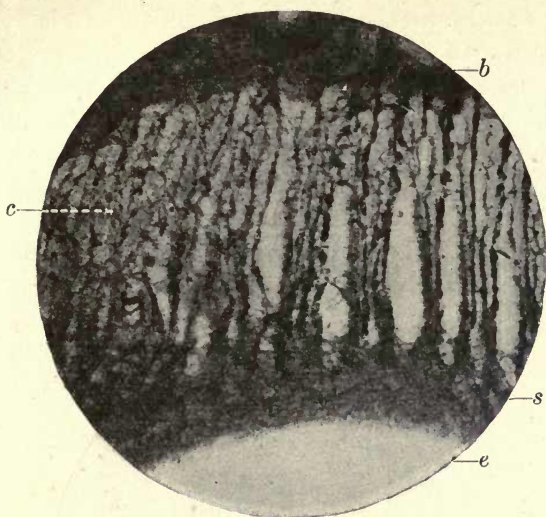


FIG. 100. Enamel organ of *Sargus ovis* showing vascular channels alternating with secreting tubes. *b*. Blood-vessels of capsule; *c*. secreting cells; *s*. stroma; *e*. position of decalcified enamel.

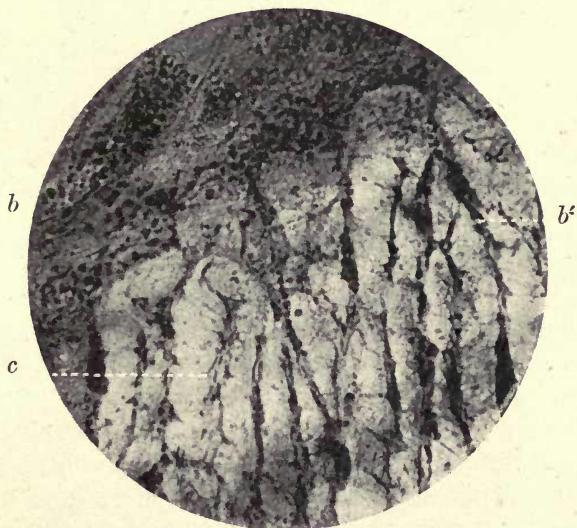

FIG. 101. *Sargus ovis*. Portion of fig. 100 more highly magnified (upper portion). *b*. Blood-vessels of capsule; *c*. secreting cells and tubes; *b'*. vascular tubes.

the blood-vessels and these tubular prolongations is a delicate tissue continuous with the margins of the concavities, filling up the space between the tubes and the blood-vessels, and the alveoli so formed are occupied by delicate cells with very distinct round nuclei. The blood-vessels, which arise from those in the capsule, terminate in loops just short of the inner margin of the enamel organ (fig. 102). The tubular processes, on the other hand, pass into the stroma which is in connexion with the forming enamel and become blended

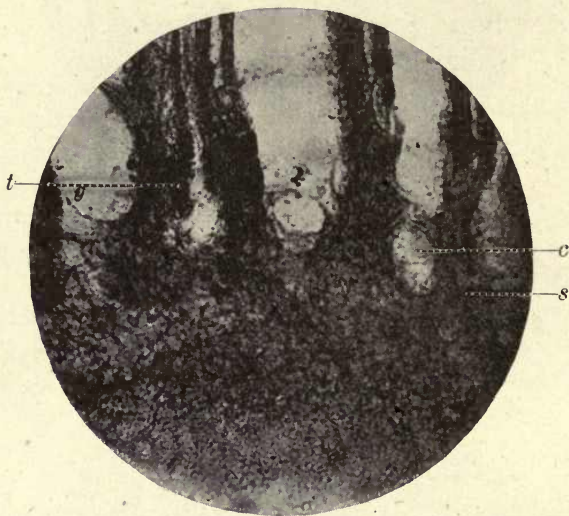

FIG. 102. *Sargus ovis*. Lower portion of fig. 100. *t*. Termination of vascular tubes; *s*. opening of secreting tubes into stroma; *c*. cellular elements between the tubes. The delicate cellular portions shown in figs. 101 and 103 have been partially destroyed in cutting the section. ($\times 250$.)

with it, but at their outer extremities they do not reach the capsule, their free ends lying between two of the blood-vessels or vascular tubes, as we may more conveniently call them.

We thus see that we have here a structure in all respects analogous to a secreting organ—the cells between the vascular and secreting tubes probably serving to separate the lime salts from the circulating blood in the vascular tubes, and they would be passed by the secreting tubes to the interior of the enamel organ and the forming enamel.

While there is no evidence of the presence of blood-vessels in the enamel organ of the Gadidæ, in *Sargus* they form a very important and regular portion of its structure. In specimens where a portion of the enamel has escaped decalcification it is seen that both systems of tubes stop short of the forming enamel, a narrow interval separating them from it. This interval is occupied by a delicate reticulum filled with fine granules and larger scattered bodies which appear to be calcospherites deposited in this reticular structure. The tubular structure of the finished enamel of

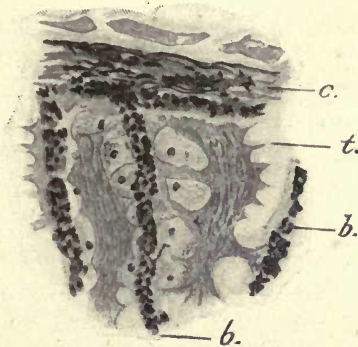


FIG. 103. A portion of the enamel organ of *Sargus ovis*, showing the relations of the tubular organ with the vascular tubes and the cells with their nuclei which occupy the spaces between them. Abbé prism drawing. ($\times 290$.) *c.* Capsule with blood-vessels; *t.* secreting tubes and cell nuclei; *b.* blood-vessel tubes.

Sargus is not due to the actual passage of these tubular structures into the forming enamel (at all events until calcification reaches the inner circumference of the capsule), for they do not reach it, and the pattern of the enamel is laid down by the delicate organic stroma in which calcification takes place, the vascular and secreting tubes and cells taking the part in this calcifying process which is fulfilled by the ameloblasts in Mammalia.

Tomes, in his paper, speaks of the apparent anomaly in the Gadidæ—that the lime salts are separated from the blood at a distance from the place where they are deposited. This certainly does not appear to be the case in the Sparidæ, for the materials for calcification can be elaborated within the enamel organ itself, the blood-vessels and secreting cells

being in the immediate neighbourhood of the forming enamel. Similar conditions exist in the Labridæ, as will be presently explained. If, however, in the Gadidæ the presence of cells in the enamel organ is substantiated, this anomaly would cease to exist in them also, although the absence of blood-vessels in this family would not bring about quite the same conditions, and the deposit of the lime salts would be probably due to a process of dialysis as in mammalian tooth germs.

It was shown that in *Sargus ovis* the portion of enamel next to the dentine is not traversed by any enamel tubes but consists of interlaced enamel prisms. In *Sargus noct* and *S. vulgaris* it is traversed by tubes (figs. 43 and 44), but these are derived from the dentine. Tomes also points out that the inner layer of enamel in the Gadidæ is not tubular. It would appear that this is the portion of the enamel laid down by the ameloblasts, the tubular portion of the enamel both in *Gadus* and *Sargus* being deposited by the structure which arises after the disappearance of the ameloblasts. Further investigation is desirable to ascertain if this secreting structure is confined to those enamels which are traversed by tubes from without, as we know that in many osseous fish the whole enamel appears to be deposited by ameloblasts as in Mammalia.

As pointed out in a former chapter, a thin pellicle of the enamel organ remains attached to the surface of the enamel when it is apparently completed and just about to erupt. It appears as if, at this late stage, when the calcification has reached the inner surface of the capsule, the enamel is in direct contact with the blood-vessels at the margin, for nuclei of blood-vessels can be sometimes detected in the tubes, which at this stage are widely open and very incompletely calcified (fig. 46).

In studying the development of the tubular enamel of the Labridæ or Wrasses, the following examples were taken: *Tautoga onitis*, the Black fish of the Atlantic coast of America; and two Japanese fish, *Halichoeres poecilopterus* and *Pseudolabrus Japonicus*.

The enamel organs of these fish also show a similar secreting structure to that of *Sargus*, but there are some

marked differences of arrangement in the different species examined.

As in *Sargus*, the enamel organ is penetrated by a regular system of vascular tubes which are mostly arranged in a radiating manner more or less at right angles to the surface (fig. 104). At the sides of the enamel organ, however, many of these tubes are arranged more or less horizontally. As shown in fig. 105, the blood-vessels are enclosed in a very distinct sheath, and these can be teased out and separated from the surrounding tissue. The separation of the masses

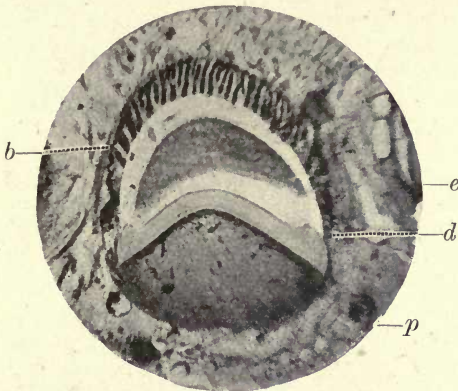


FIG. 104. Tooth germ of *Tautoga* (Labridæ). *b*. The vascular tubes in the enamel organ; *e*. points to detached uncalcified enamel; *d*. dentine showing section of the flange on which the enamel rests; *p*. pulp. ($\times 50$.)

of blood corpuscles would appear to be partially due to clotting, and also to the fact that the sheath appears to be continued in a transverse direction across the enamel organ.

When a true vertical section is procured it is seen that the vascular tubes are surrounded by cellular elements arranged exactly like a simple tubular gland (figs. 106 and 107), and that within the centres of these gland-like structures channels are visible filled with granules, these channels becoming approximated below and passing into a similar delicate stroma to that seen in *Sargus* intervening between the enamel organ and the forming enamel. This apparatus would apparently serve the same purpose as the somewhat identical arrangement in the enamel organ of *Sargus*, conveying the lime salts elaborated in these gland-like structures from the blood-

vessels to the calcifying stroma. At this stage there is no vestige of an ameloblast layer or of an external epithelium, the outer margins of these bodies being only separated from the connective tissue of the capsule by a delicate basement membrane. In the earliest germs of *Tautoga*, as in *Sargus* and the Gadidæ, an ameloblast layer and an external epithelium are present, but very soon a remarkable change takes place in the enamel organ.

At the time when a narrow layer of enamel is laid down

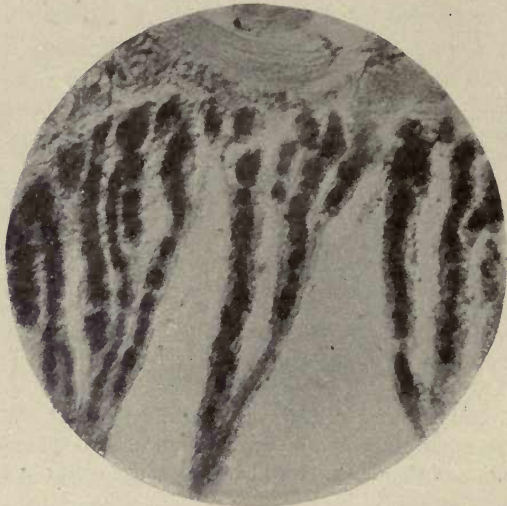


FIG. 105. The vascular tubes in *Tautoga* teased out. ($\times 500$.)

and no dentine is formed, and no differentiation of any odontoblast layer in the pulp, a mass of epithelial tissue is seen to have penetrated the capsule from without and to be enveloping the enamel organ very much as the first epithelial inflection envelops the dentine papilla in mammalian tooth germs. The external epithelium together with the ameloblast layer soon disappears, and the whole of the circumference of the enamel organ is occupied by this gland-like tissue and the penetrating blood-vessels.

At this stage, then, we have an enamel organ made up of blood-vessels or vascular tubes, gland-like tissue, and a granular stroma intervening between this tissue and the

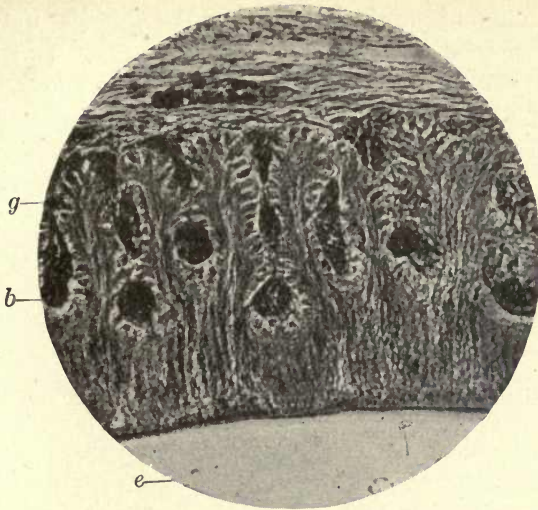


FIG. 106. The enamel organ of *Tautoga onitis* (Labridae). The tubular gland-like bodies with their ducts. *g*. Glands; *b*. blood-vessel tubes; *e*. position of forming enamel. ($\times 350$.)

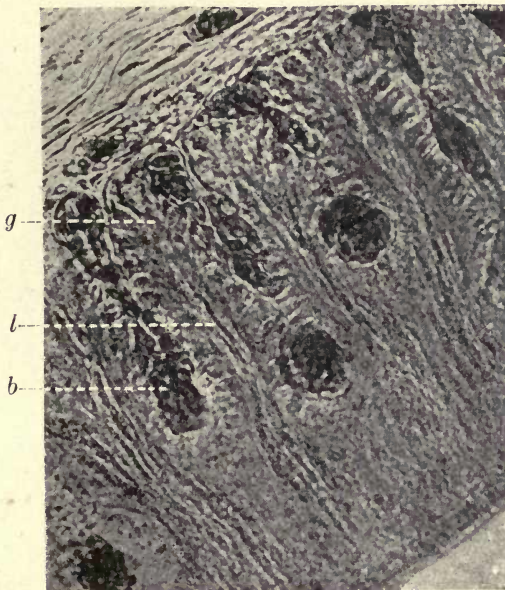


FIG. 107. As fig. 106 under higher magnification. *g*. Tubular gland-like structures; *l*. lumen; *b*. blood-vessel tubes. ($\times 650$.)

calcifying enamel, and within this stroma lie numerous irregularly-shaped bodies which would appear to be the first deposit of the lime salts in the form of calcospherites. In *Tautoga* it appears that not only is the enamel in advance of the dentine in the calcifying process, but a considerable amount of enamel is laid down before *any* dentine is formed. The line of demarcation between the enamel and the dentine is very evident in the Labridæ, as all around the first-formed dentine is a projection which forms the groove into which the enamel fits, as in the Gadidæ. The tubular enamel cannot therefore be mistaken for dentine. From the above description it is seen that the glandular tissue has not been produced by any invagination of the epithelial cells of the early enamel organ, as might perhaps have been assumed, but it invades the enamel organ from without. In sections which have been cut in such a manner as to include the mucous membrane of the mouth in the same vertical plane, the connexion of this tissue in the enamel organ with the layers of gland substance immediately beneath the mucous glands on the surface of either the mouth or pharynx is very clearly shown, and many sections demonstrate that this connexion is maintained during the whole period of the deposition of the enamel when this structure has once appeared.

In the two other species of *Labrus* examined there are certain modifications of structure which although differing in arrangement would serve the same purpose.

In *Halichæres* and in *Pseudolabrus* no connexion with the glandular tissue of the mucous membrane can be detected as in *Tautoga*, but the secreting tubes, as we have called them, are much convoluted and alternate with the vascular tubes as in *Sargus*. In *Halichæres* the blood-vessels have more the appearance of very thin-walled sinuses, which are of very large proportions compared with the tubes (fig. 108). The secreting tubes form loops around the sinuses, and from their lower margins bundles of minute processes extend to the stroma, in which masses of calcospherites are also visible. Fig. 109, from a specimen in which the enamel was retained *in situ*, shows this arrangement very completely.

In both *Halichæres* and *Pseudolabrus* cellular bodies are

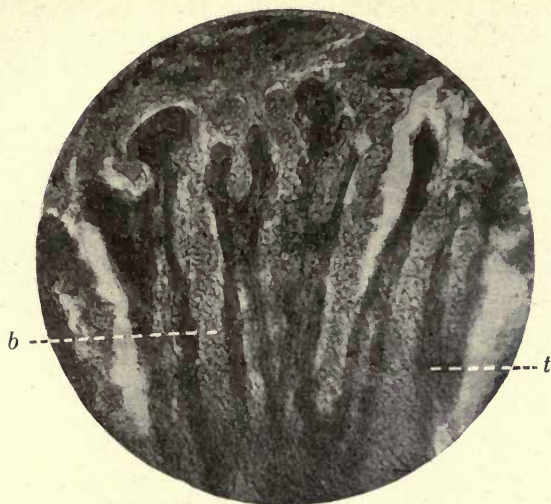


FIG. 108. Part of enamel organ of *Halichoeres* (Labridæ) showing secreting tubes and blood channels. *t.* Tubes; *b.* blood-vessels. ($\times 500.$)

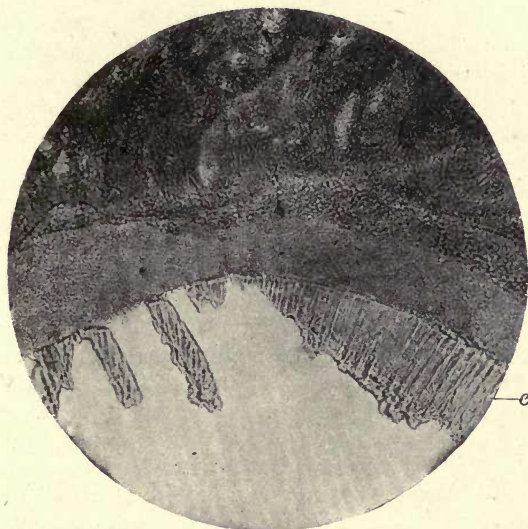


FIG. 109. Portions of calcified enamel in stroma of enamel organ of a Wrasse (*Halichoeres pœcillopterus*). *e.* Enamel. ($\times 150.$)

seen within the tubes ; these take stains deeply and would appear to be the elements which separate the lime salts from the blood in the vascular tubes and sinuses, and take the place of the more definite glandular structures seen in *Tautoga*.

For further details on the subject the reader may be referred to the original paper (16 d).

In the paper before alluded to (5 b) Mr. Thornton Carter refers to the author's description of the enamel organs of *Sargus* and *Labrus*, and says his own material lends no support to these views. He did not examine the species described by the author, and however anomalous it may appear there are apparently considerable differences in the mode of development of the enamel within the same family of fishes. There can, we venture to say, be no doubt about the appearances in the enamel organs of *Tautoga* in *Sargus ovis* and in the two Japanese fish ; while in another fish belonging to the Labridæ, the freshly-preserved head of which was sent him from America, the author could find no evidence of any such change in the enamel organ, which showed, in all the germs examined, the external epithelium and ameloblasts and no penetration by blood-vessels. The whole fish not having been received, it was not possible to identify the species. Mr. Carter says that in *Pagellus centrodontus*, one of the Sparidæ, and in *Labrus bergylta*, which he examined, although he found the vascular canals in the enamel organ described by the author, he did not find the tubes or gland-like bodies, but persistent ameloblasts. Mr. Carter says the author's figures show no cytological details, but a reference to the photographs will show the presence of cells, although these have no resemblance to ameloblasts or the cells of the external epithelium, but are arranged as are the cells of a secreting gland in definite relations to the channel or lumen which they surround. Their minute round nuclei are also characteristic of glandular cells (see figs. 101 and 103).

It is scarcely necessary to repeat that the specimens of *Tautoga* and *Sargus* were freshly preserved, and the appearances are not due to imperfect preservation. Whether these cells which surround the central lumen are derived from ameloblasts may be a doubtful point, but in the very large series of slides prepared by the author there was no indication of this, neither was there any trace of the cells of the external epithelium, as the photographs plainly show. Mr. Carter suggests that these views are based on those of C. S. Tomes with respect to the Gadidæ, but the observations above recorded were quite independent of these and followed on an attempt to trace the process in *Sargus* with freshly fixed material, as Tomes considered this to be similar to what he described in the Gadidæ. The author was enabled to show that the enamel organ in both the Sparidæ and Labridæ is penetrated by blood-vessels ; this penetration, as shown both by Mr. Carter and by C. S. Tomes, does not occur in the Hake. To clear up this question much further investigation is required, as the

development of the enamel in osseous fish has been but very imperfectly studied, and it is only by examining a large series of specimens of the various families that any systematically arranged conclusions can be arrived at; but that very remarkable variations in the structure and arrangement of the enamel organ do exist we appear to have very complete evidence. The remarkable fact that the circulating blood is brought into intimate relations with the cells of the enamel organ within its substance certainly points to a mode of development of the enamel which seems to have no parallel in other vertebrates.

In the Elasmobranchii, according to Tomes, both the Summary. epiblastic epithelial cells and those of the mesodermic dentine papilla take part in the formation of the enamel, the enamel being calcified by the ameloblast cells in a matrix which is furnished by the dentine papilla. In the osseous fish the investigation of only a few families has been thoroughly carried out, but while in many the enamel organ is both in structure and function similar to that of the higher vertebrata, in those which possess a more or less tubular enamel a very different structure of the enamel organ is found. Although at first, as in the Gadidæ, in the Sparidæ and Labridæ the enamel organ is composed of a true layer of ameloblasts and an external epithelium, only a very narrow zone of enamel is laid down by the ameloblasts, which soon disappear, a delicate stroma taking their place, and within this stroma is differentiated an enamel organ of an altogether different structure, consisting in the case of *Sargus* and *Labrus* of an apparently definite secreting apparatus, the lime salts being elaborated by cells which are arranged between and around vascular tubes which penetrate the enamel organ from the capsule. The calcifying substance is conveyed by special channels to the stroma, which occupies the interval between this structure and the forming enamel and in which calcification takes place. In *Tautoga* the secreting structure takes the form of tubular gland-like structures regularly disposed within the enamel organ.

In the Gadidæ no such *definite* tubular structure has been described, but C. S. Tomes was the first to draw attention to these changes in the enamel organ. No blood-vessels are present in the enamel organ of the Gadidæ, and according to Tomes there are no cells to which can be assigned the function of separating the lime salts.

Further investigation is necessary to determine if this conversion of the first-formed enamel organ into a secretory structure is peculiar to the enamels which contain tubes from the outer surface, but the fact that the first-formed layer of enamel in all the fish examined contains no tubes and is laid down under the influence of normal ameloblasts, would tend to indicate that the various modifications of this secretory structure are peculiar to those forms which possess tubular enamel.

From the evolutionary standpoint the method of calcification above described presents a curious problem. In Elasmobranchs we see the first evidence of the formation of enamel, which takes place by the agency of true ameloblasts, arranged as a well-defined internal epithelium of the enamel organ as in mammalia, and it is also present in the placoid scales of the skin of Elasmobranchs. While this mode of calcification of the enamel appears to be exactly similar to that of the higher vertebrata, in many Sparidæ and Labridæ, although the deposit of enamel begins in this manner, only a very small amount of the tissue is deposited under these conditions, and the secreting structure before described takes up the functions of the ameloblasts.

The attention of the author was drawn by J. T. Carter to a paper by N. R. Harrington (11), in which he describes the microscopic structure of the lime-secreting glands of the earthworm (*Lumbricus*). In these glands there is a regular arrangement of sinuses or vascular tubes with secreting cells between them, but there are no separate definite channels for the conveyance of the secretion as in the fish, but it passes back between the laminae to be discharged into the oesophagus. The author has been unable to trace any other structure of a similar nature adapted to this purpose, either among the vertebrata or invertebrata.

A comparison might also be made with one of the ductless glands as far as structure is concerned, although it is not engaged in the secretion of lime salts. Dahlgren and Kepner (7) figure a section through the infundibular gland of the flounder (*Pseudopleuronectes americanus*). This shows that the secreting cells are arranged along sinusoids filled with blood; each sac-like invagination of the secreting cells is

interposed between two sinusoids, and the secreted substance is discharged into the lumen between the rows of secreting cells. We thus see among the ductless glands a similar arrangement to that found in the fish above described, although this secretes some substance, the nature of which is not known, into the brain cavity fluids.

REFERENCES

1. Andrews, R. (a) 'Formation of Enamel.' *Intern. Dental Journal*, 1891.
(b) *Trans. Columbian Dent. Congress*, 1894.
2. Arnell. 'Zur Kenntniss der zahnbildenden Gewebe.' *Retzius' Biologisch. Untersuchungen*, II., 1882.
3. Bowerbank. 'The Structure of the Shells of Molluscous and Conchiferous Animals.' *Trans. Microscop. Soc.*, 1869, i. 123.
4. Carpenter, W. B. (a) 'On the Microscopic Structure of Shells.' *Brit. Assoc. Rept.* (1844-7), 1844, pp. 12 ff. ; 1847, pp. 93-134.
(b) *The Microscope*, 1875.
5. Carter, Thornton. (a) 'The Cytomorphosis of the Marsupial Enamel Organ,' &c. *Phil. Trans. Roy. Soc.*, Ser. B, ccviii. 271-305.
(b) 'On the Cytomorphosis of the Enamel Organ in the Hake.' *Quar. Journ. Micr. Sci.*, vol. lxiii, pt. 3, Dec. 1918, pp. 387-400.
6. Caush, D. 'Is there Uncalcified Tissue in the Enamel?' *Dental Cosmos*, Feb. 1905, xlvii.
7. Dahlgren and Kepner, W. A. *A Text-book of the Principles of Animal Histology*, 1908, p. 40.
8. v. Ebner, V. 'Strittige Fragen über den Bau des Zahnschmelzes.' *Sitzungsber. d. k. Akad.*, Wien, 1890, Bd. xcix, pp. 57-104.
9. Eve, F. 'On Cystic and Encysted Solid Tumours of the Jaw, with Observations on the Structure of the Enamel Organ.' *Trans. Odontol. Soc. Great Brit.*, 1885, xviii. 39-61.
10. Graham. *Researches*, ed. Angus Smith, 1877, also *Phil. Trans. Roy. Soc.*, 1850 and 1861, cli. 183.
11. Harrington, N. R. 'The Calciferous Glands of the Earthworm.' *Journ. of Morphology*, Suppl., vol. xv (1889), p. 106.
12. Harting, P. *Sur la production artificielle de quelques formations calcaires organiques*. Amsterdam, 1872.
13. Hertwig, O. (a) 'Ueber den Bau und die Entwicklung der Placoidschuppen und Zähne.' *Jenaische Zeitschr. f. Naturw.*, 1874, Bd. viii, pp. 331-404.
(b) 'Ueber das Zahnsystem der Amphibien u. seine Bedeutung für die Genese des Skeletts der Mundhöhle.' *Archiv für Micr. Anat.*, 1874, Bd. xi, Suppl., pp. 1-208.
(c) *Lehrbuch der Entwicklungsgeschichte*. Jena, 1888.
(d) 'Ueber das Hautskelett der Fische.' *Morphologische Jahrb.*, 1876, Bd. ii, pp. 328-95 ; Bd. v, pp. 1-21 (part ii) ; Bd. vii, pp. 1-41 (part iii).

14. Herrissant. 'Nouvelles recherches sur la formation des dents et sur celle des gencives.' *Hist. de l'Acad. R. des Sciences*, Paris, 1754 mémoires, p. 433.
15. Leduc, S. *The Mechanism of Life*, 1911, p. 45.
16. Mummy, J. H. (a) 'On the Process of Calcification in Enamel and Dentine.' *Phil. Trans. Roy. Soc.*, Ser. B, ccv. 95-113.
 (b) 'Comparative Studies in Calcification.' *Proc. Roy. Soc. of Med.*, 1915, vol. ix (Odontological Section), pp. 6-31.
 (c) 'On the Nature of the Tubes in Marsupial Enamel and its Bearing on Enamel Development.' *Phil. Trans. Roy. Soc.*, Ser. B, ccv. 295-313, 1914.
 (d) 'On the Structure and Development of the Tubular Enamel of the Sparidæ and Labridæ.' *Phil. Trans. Roy. Soc.*, Ser. B, ccviii. 251-69.
17. Paul, F. 'Some Points of Interest in Dental Histology: The Enamel Organ.' *Dental Record*, 1896, xvi. 493-517.
18. Poulton, E. B. 'True Teeth and the Horny Plates of Ornithorhynchus.' *Quar. Journ. Micr. Sci.*, 1888, vol. xxix, N.S., pp. 9-48.
19. Philip, J. C. *Physical Chemistry: its Bearing on Biology and Medicine*. London, 1910.
20. Pauli, W., and Samec, M. 'Ueber Löslichkeitsbeeinflussung von Elektrolyten durch Eiweisskörper.' *Biochem. Zeitschr.*, xvii. 235, 1910.
21. Röse, C. 'Contributions to the Histogeny and Histology of Bony and Dental Tissues.' *Dental Cosmos*, Nov. and Dec. 1893.
22. Rainey, G. *The Mode of Formation of Shells of Animals, &c., by a Process of Molecular Coalescence*. London, 1838.
23. Spee, Graf v. 'Ueber die ersten Vorgänge der Ablagerung des Zahnschmelzes.' *Anat. Anzeig.*, 1887.
24. Tims, H. W. Marett, and Hopewell Smith, A. 'Tooth-germs in the Wallaby, *Macropus billiardieri*.' *Proc. Zool. Soc.*, London, 1911, pt. iv, pp. 926-42.
25. Thompson, D'Arcy W. *Growth and Form*. Camb., 1917.
26. Tomes, C. S. (a) 'Upon the Structure and Development of the Enamel of Elasmobranch Fishes.' *Phil. Trans. Roy. Soc.*, Ser. B, cxc. 443 (1898).
 (b) 'Upon the Development of the Enamel in certain Osseous Fish.' *Phil. Trans. Roy. Soc.*, Ser. B, cxci. 42 (1900).
 (c) *Dental Anatomy*, 7th ed.
 (d) 'On the Development of Marsupial and other Tubular Enamels, &c.' *Phil. Trans. Roy. Soc.*, 1898, clxxxix. 107-22.
27. Traube. 'Reichert's and Du Bois Raymond's Archives (1867). *Gesammelte Abhandlungen*, Berlin, 1899, p. 213.
28. Underwood, A. (a) *Journ. Brit. Dental Assoc.*, xix. 470.
 (b) Underwood and Wellings. *Trans. Int. Med. Congress*, 1913, Section of Stomatology.
29. Woodhead, G. Sims. 'On Inflammation in Bone.' *Trans. Odontol. Soc. Great Brit.*, 1892-3, xxv. 30-53.
30. Williams, Leon. 'On the Formation and Structure of Dental Enamel.' *Dental Cosmos*, 1896.

CHAPTER IV

THE DENTAL PULP

DEPARTING from the more usual method of treating the subject, it may be better to consider the formation and structure of the pulp before proceeding to a description of the dentine, as it is the formative organ of the dentine and in intimate relation with it in the completed tooth. The dental pulp does not disappear as a complete organ during the functional life of the tooth, as does the enamel organ after the completion of the enamel. The pulp, with its cells, nerves, and blood-vessels, maintains the nutrition of the dentine during the whole period of its functional activity.

The main supporting structure of the pulp is the connective tissue. This is of the myxomatous or gelatinous variety, similar to the Wharton's jelly of the umbilical cord, although also containing ordinary fibrous connective tissue.

Con-
nective
tissue.

As stated by Schafer (20), the manner in which these connective-tissue fibres arise is by no means clear, and two distinct and opposed views are held by histologists upon the subject.

The pulp of the tooth in early stages of its development is chiefly made up of embryonic mesodermic cells, and those which give rise to connective tissue are known by the name of mesenchyme cells (Hertwig). These cells possess very large nuclei and are surrounded by a very small amount of cytoplasm. They are furnished with many protoplasmic prolongations or branches, and lie in an albuminoid or mucoid ground substance of a jelly-like consistency.

According to some histologists, as Waldeyer (33) and Fleming (7), the fibres are processes of the cells, but it is considered by Kölliker, Ranvier (25), and others, that the fibres arise within the intercellular substance. F. Mall (19) and Haidenhain (9) hold that the ground substance is as much a portion of the cell network or 'syncytium' as the substance of the cell itself, and that the fibres arise in this, which they term the exoplasm, distinguishing it from the

endoplasm or cytoplasm of the cell. Apart from the processes of the cell, there would appear to be a distinct development of fibres within the exoplasm, as seen in the so-called Wharton's jelly of the umbilical cord, which, as previously stated, has a strong histological resemblance to the tissue of the developing tooth-pulp.

That these large cells of the tooth-pulp have long intercommunicating processes is very evident in preparations of actively growing pulps (figs. 110 and 111). These photo-

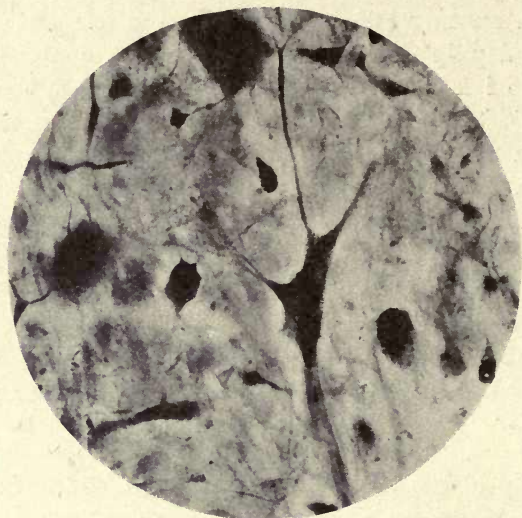

Fig. 110. Human tooth-pulp. Open-ended premolar (pyridin silver). Large connective tissue cells and processes. ($\times 450$.)

graphs were taken from an erupted human premolar in which the root portion was still in an early stage of development. The preparations were stained by the pyridin silver method, and the pulp is seen to be crowded with large cells of very various sizes and shapes, which are provided with long connecting processes interlacing in the pulp. Their nuclei are very conspicuous and the fibrillation is seen to pass across the interior of the cell. This is very evident in the part of the preparation from which fig. 110 was taken, but the strong yellow colour of the section prevents this fibrillation being distinctly brought out without over-exposure of the rest of the image. There is evidence in these

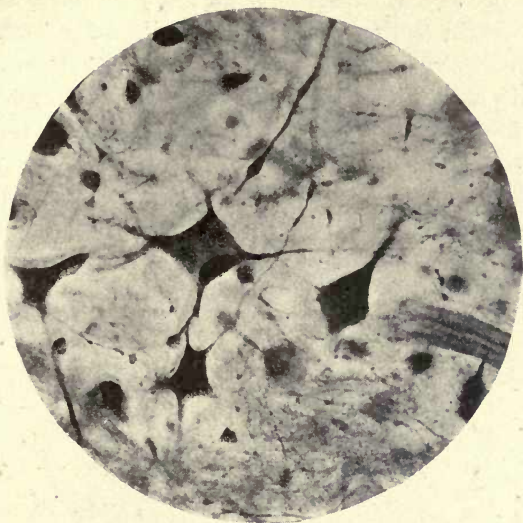


FIG. 111. Similar to fig. 110. ($\times 450$.)



FIG. 112. Human tooth-pulp at forming root. Cajal silver nitrate. ($\times 150$.)

preparations of a finer fibrillation between the larger cells and their processes, which may perhaps be the development of fibres within the exoplasm as described by Mall. If this be the case it seems possible that the connective-tissue fibres of the pulp are formed in both ways—by prolongation from the cell protoplasm or endoplasm and within the ground substance or exoplasm. Fig. 112, however, from a similar

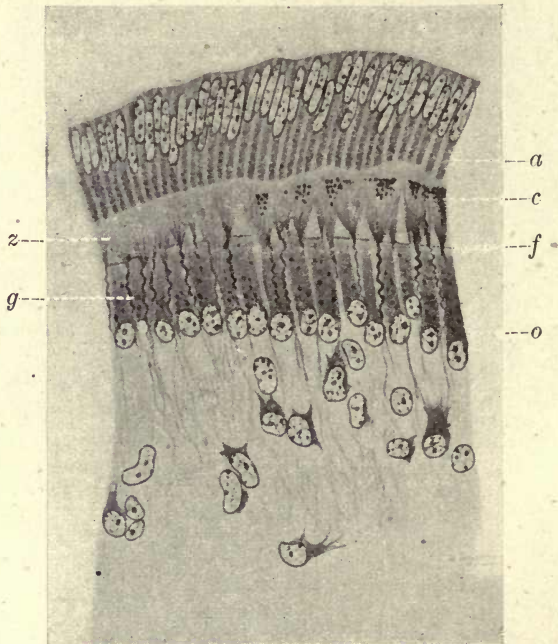


FIG. 113. Fibres of Von Korff in tooth germ of Cat. *o*. Odontoblasts; *f*. fan-like expansion of fibre bundles; *g*. corkscrew-like fibres; *z*. odontogenic zone; *c*. commencing calcification; *a*. ameloblasts. (From illustration to his paper.)

pulp prepared by Ramon y Cajal's silver nitrate process, would seem to indicate that the fibres in this early stage are all processes of cells, and the finer fibrillation seen in figs. 110 and 111 appears to arise from minute cells. In the dentine papilla in the early stages of the developing tooth germ in the embryo, bundles of connective tissue have been described by Von Korff (fig. 113), and the delicate connective-tissue fibres which enter into the formation of the dentine at all

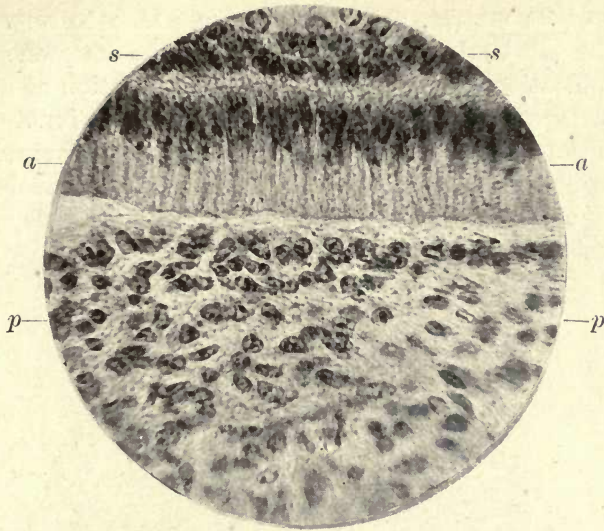


FIG. 114. Macropus. Pulp in early stage before commencement of calcification. No differentiation of odontoblasts. *s*. Stratum intermedium of enamel organ; *a*. ameloblasts; *p*. pulp tissue. ($\times 400$.)

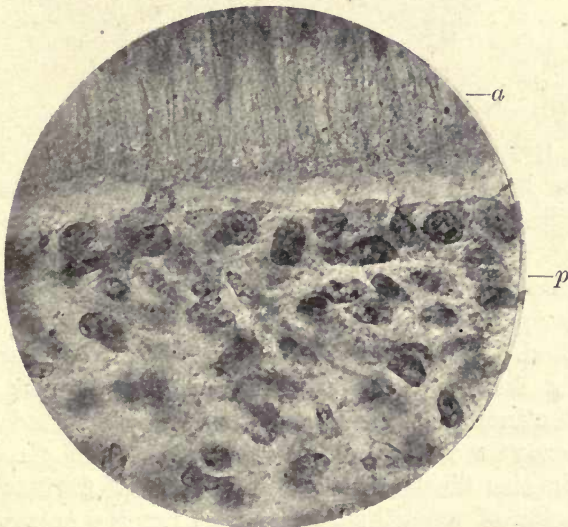


FIG. 115. Rounded cells at the margin of the pulp. *a*. Ameloblasts; *p*. pulp. ($\times 500$.)

stages of its development and constitute the foundation fibres of its matrix, are in many cases seen to arise from cells, as will be described later. Before the commencement of calcification there is no distinct differentiation of a peripheral layer of cells so characteristic of the functionally active pulp, but rounded cells are soon seen accumulating at the periphery (figs. 114 and 115) with large nuclei and a very small amount of cytoplasm, so that the cells appear to consist almost wholly of nuclei.

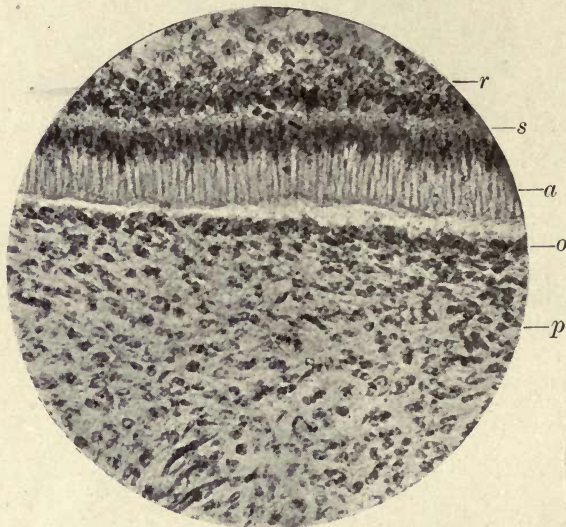


FIG. 116. Macropus. Rounded cells forming a definite layer at the margin. *p.* Pulp; *o.* first indication of odontoblast layer; *a.* ameloblasts; *s.* stratum intermedium; *r.* stellate reticulum. ($\times 150$.)

In fig. 116 short processes can be detected prolonged from the cytoplasm of the cells, but no definite dentinal fibril has appeared. In a later stage, shown in fig. 117, the outer cells form a definite layer, and their prolongations extend as the dentinal fibril traversing the first deposited colloidal substance in which calcification later takes place. It is seen in this illustration that the dentinal fibril is a broad expansion of the cell substance and not the narrow process often shown in shrunken preparations.

The early stages of development of the cells of the human

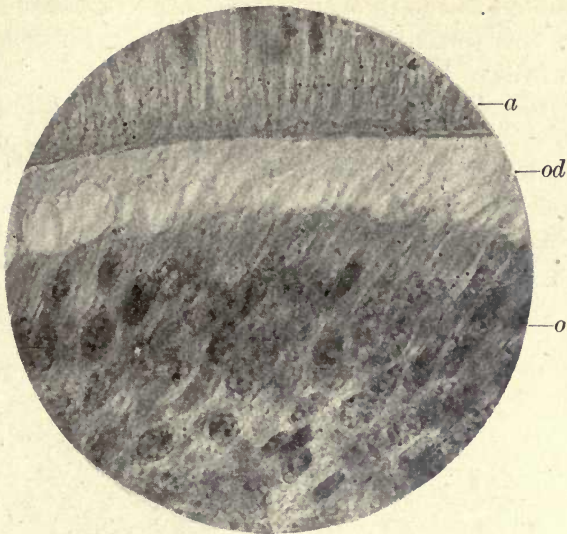


FIG. 117. Differentiation of odontoblasts. No calcification commenced.
o. Odontoblasts; *od.* odontogenic zone; *a.* ameloblasts. ($\times 500.$)

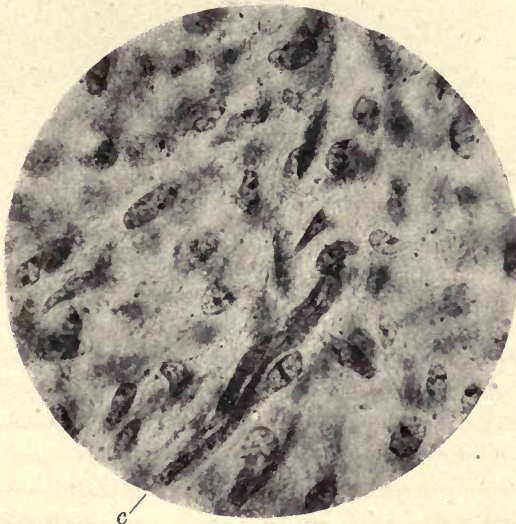


FIG. 118. Developing cells of pulp. *c.* Developing capillary vessel. ($\times 500.$)

pulp are well described and figured by Dr. Paul in a paper contributed to the Odontological Society in 1899 (23).

The development of the cells of the dental pulp is further shown in figs. 118 and 119.

The rounded cells are thus seen to become differentiated into a definite layer of more or less cylindrical cells, the odontoblasts, which surround the pulp and form the *membrana eboris* of Waldeyer. These cells are larger and more fully developed at the coronal portion of the tooth-pulp, and smaller and less conspicuous in the fully formed root.

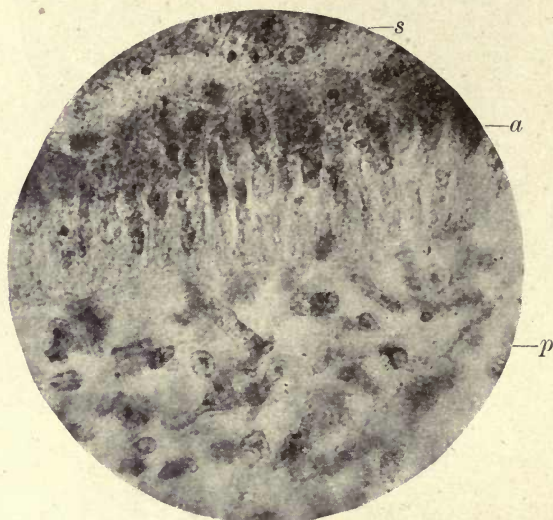


FIG. 119. Large irregularly-shaped cells at pulp margin. *a*. Ameloblasts; *p*. pulp; *s*. stratum intermedium. ($\times 500$.)

Each odontoblast has a large round or oval nucleus and the cell protoplasm, or cytoplasm, is finely granular. On its dentine aspect it is somewhat flattened, and the dentinal fibril, which is a continuation of its cytoplasm, slightly tapers to its entrance into the dentinal tube (figs. 120 and 121). It has been described as not possessing a cell wall, but this is highly improbable, and we must assume that the cell wall is of such extreme tenuity that it is not observable in ordinary preparations. As, however, it has been shown by Hanazawa (10) that an outer layer to the dentinal fibril is distinctly stainable by hæmatoxylin within

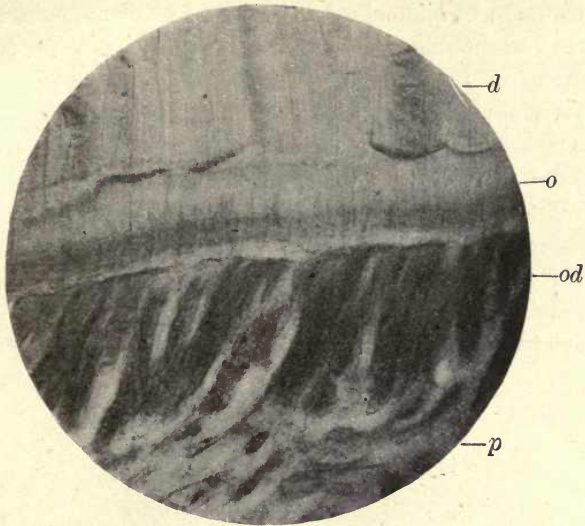


FIG. 120. Section of tooth of Macropus cut without decalcification. *d.* Calcified dentine; *o.* odontogenic zone; *od.* odontoblasts; *p.* pulp. ($\times 450$.)

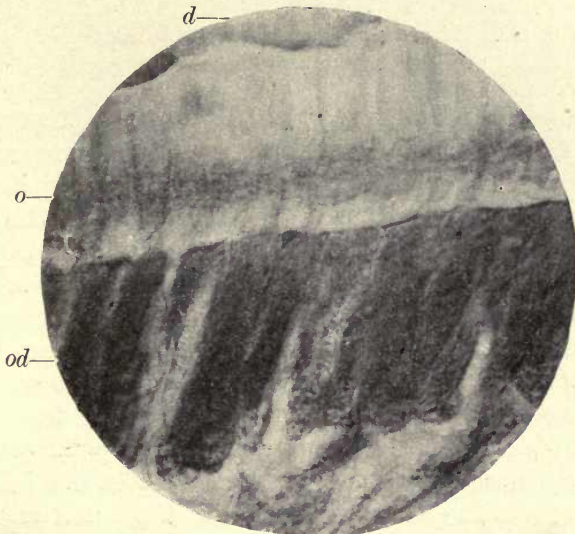


FIG. 121. Large odontoblasts. Macropus. Section cut without decalcification. *od.* Odontoblasts; *o.* odontogenic zone; *d.* dentine. ($\times 650$.)

the dentinal tube, it appears that this must necessarily be an extension of the cell membrane of the odontoblast.

Each odontoblast is furnished with this protoplasmic prolongation into the dentinal tube and with a delicate process at its pulp extremity which passes into the connective tissue; this process is, however, often difficult to detect. A lateral process of the cell has also been described connecting the cells to one another at the dentine margin. Professor Paul describes these lateral processes as 'collars' consisting 'of a delicate network of pulp fibrils', and does not consider them to be any portion of the cell itself (23). He says they are only visible in developing teeth and entirely

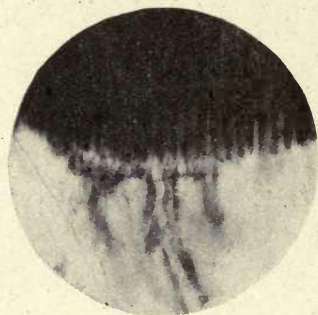


FIG. 122. Human adult premolar showing transverse processes of odontoblasts. ($\times 75$.)

absent in adult pulps. In fig. 122, however, a photograph from a fully formed functional premolar tooth shows lateral processes connecting the odontoblasts very clearly, and these certainly appear to form portions of the cell. This was photographed from a specimen of the author's stained with iron and tannin, and the same appearance is to be seen in many sections.

In fig. 123 a curious condition of the dentine is represented. The photograph was from a carious tooth, and the dentinal tubes are seen to be connected to a transverse tube with which they form anastomoses; the tubes are filled with micro-organisms. This same condition was seen in a healthy developing tooth in several parts of the circumference near the pulp margin. It is very difficult to account for this condition. A comparison of figs. 122 and 123 might suggest

that these connecting lateral processes of the odontoblasts become sometimes involved in the calcification and persist

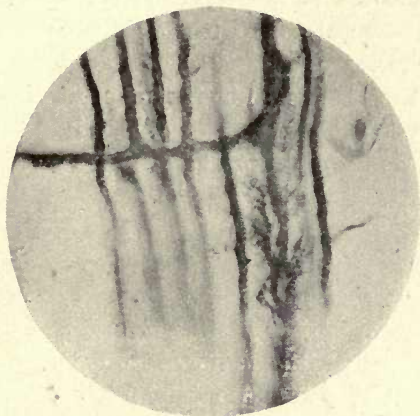


FIG. 123. Human molar. Transverse anastomosing branches of dentinal tubes. ($\times 350$.)

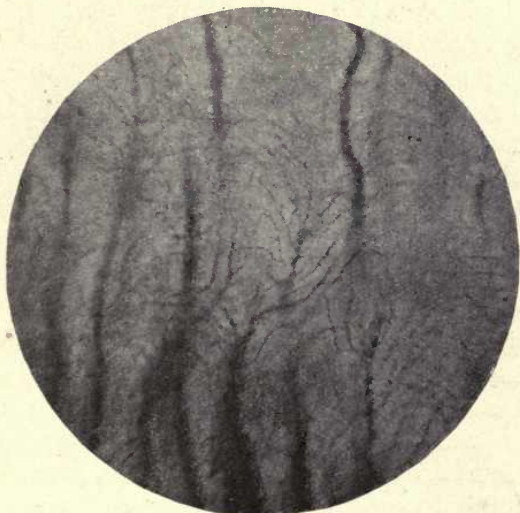


FIG. 124. Termination of tubes within the dentine. ($\times 350$.)

as horizontal tubes in the matrix. These transverse tubes within the dentine are, however, very rarely met with, and the author has only found them in the instances above mentioned.

Sometimes more than one dentinal fibril arises from a single odontoblast, but in many cases, especially where shrivelled odontoblasts are represented, these appearances are deceptive, several cells with their processes being seen grouped together.

A dentinal tube is sometimes seen to terminate in a clear space in the matrix between the surrounding tubes, and end in numerous fine terminal branches (fig. 124).

Vessels of the Pulp

The blood-vessels of the tooth-pulp enter the apical foramen in one or more arterial branches. They traverse the pulp in company with the nerve trunks (figs. 125 and 127), branch frequently, and ultimately form a vascular plexus beneath the odontoblast layer. While, however, the capillary vessels which arise from them for the most part form loops in this situation, many pass across the odontoblast region and are seen in contact with the forming dentine in developing teeth.

According to Guido Fischer (6) the capillary vessels in transverse section are seen in two forms—one in which there is a distinct adventitia, and smaller ones in which only the endothelial coat is visible. The veins are apparent as open spaces in the connective tissue of the pulp, with very delicate walls. The vessels are in intimate relation with the nerve trunks in the pulp, the latter often partially surrounding the blood-vessels (fig. 126).

Lymphatics. It has usually been considered that the dental pulp contains no lymphatics, but recent researches appear to have demonstrated that a lymphatic system is present. G. Fischer, writing in 1909 (6), says that lymph vessels, although found around the roots of teeth, are not present in the pulp, but he describes perivascular lymph spaces as being present, especially around the odontoblasts. Dewey and Noyes, in a recent study of the lymphatic vessels of the dental pulp, describe the work of Schweitzer on this subject and consider that the recent date of this investigation is the reason why it is not sufficiently known, and the statement that there are no lymph vessels in the dental pulp still maintains its

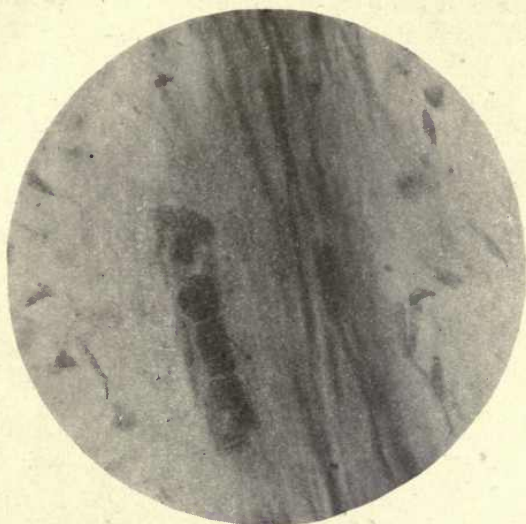

FIG. 125. Nerves and blood-vessels of human tooth-pulp. Blood corpuscles *in situ*. ($\times 800$.)

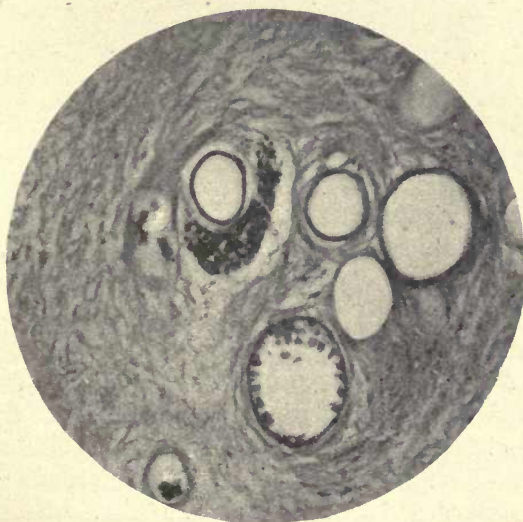


FIG. 126. Arterial and venous capillaries in human pulp. Nerve bundles partially surrounding blood-vessels. ($\times 450$.)

position in the text-books. Schweitzer in 1907 and 1909 (31) published the results of his experiments on animals, and was able to demonstrate the presence of lymph vessels in the pulp; this discovery was confirmed by Bartels in 1909 (1), and also by Testut (32), who says, referring to Schweitzer, 'This author has clearly demonstrated the presence of true lymph vessels in the dental pulp'. The earlier observers, as Körner and Halle, found that although they could not find lymph vessels in the pulps of the animals experimented

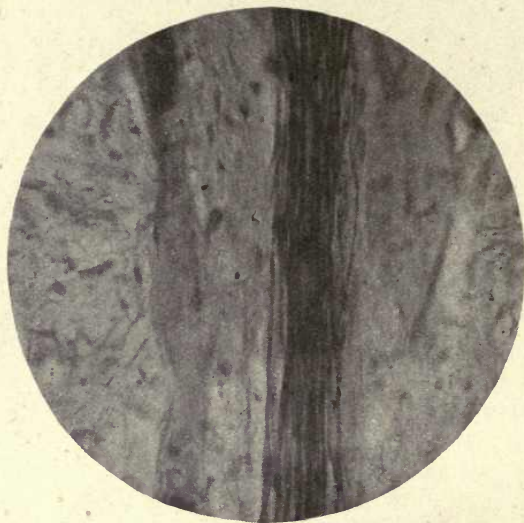


FIG. 127. Blood-vessels and nerves of the pulp. ($\times 600$.)

upon, single particles of the insoluble Prussian blue employed, painted on the pulp at its upper end, were found as far as the apex, but these results were not sufficiently convincing even to establish the statement that although no lymph vessels could be demonstrated, the pulp had the power of resorption, and, as was suggested by Morgan, these particles might be carried by wandering cells (20).

Dewey and Noyes repeated the experiments of the previous investigators, and made use of both the methods employed by them: that of Körner, Starr, and Ollendorf of injecting Prussian blue directly into the pulp, and Schweitzer's method of injecting the lymph vessels in the gums. These authors

were able to confirm Schweitzer's results by both methods, and say, 'There is every evidence to support the correctness of Schweitzer's statement that in the upper jaw the lymphatics leaving the dental pulps course within the bony portion of the maxilla and emerge through the infra-orbital and other foramina into the subcutaneous tissue; those of the lower jaw enter the inferior dental canal, where they run along with the blood-vessels and nerves, and thence pass into the subcutaneous tissue. From either jaw lymph vessels enter the submaxillary and deep cervical glands.'

The Nerves of the Pulp

The nerves of the pulp and teeth are derived from the fifth cranial nerve. The upper teeth are supplied by the *superior maxillary nerve*, which arises from the Gasserian ganglion, and the branches of this nerve which are distributed to the teeth are the anterior, middle, and posterior superior dental nerves.

The posterior superior dental nerve arises from the trunk of the superior maxillary nerve before it enters the infra-orbital groove, and divides into two branches which enter the posterior dental canal and supply the upper molar teeth and the mucous membrane of the antrum, also contributing small filaments to the mucous membrane of the gum and cheek.

The middle superior dental nerve arises at the back of the orbital foramen, passes along a special canal in the anterior wall of the antrum, and supplies the premolar teeth.

The anterior superior dental nerve arises near the infra-orbital foramen and is the largest branch of the superior dental nerve. It traverses the canal in the front wall of the antrum and supplies the canine and incisor teeth. It has a nasal branch to the inferior meatus and to the floor of the nasal fossæ.

The inferior maxillary nerve is the largest division of the fifth nerve and consists of two portions, the larger one arising from the Gasserian ganglion, and the smaller consisting of the motor root of the fifth nerve, which unites with the larger branch after passing through the foramen ovale of the sphenoid bone. Beneath the external pterygoid

muscle this nerve divides into two branches, a small anterior branch chiefly consisting of motor fibres and distributed to the temporal, masseter, and external pterygoid muscles, and a buccal branch, which is its only sensory portion. The posterior, the larger branch of the inferior maxillary nerve, consists chiefly of sensory fibres and divides into the auriculo-temporal, lingual, and inferior dental nerves.

The inferior dental nerve passes beneath the external pterygoid muscle to the outer side of the lingual nerve and enters the inferior dental canal, whence it supplies branches to the molar and premolar teeth and the canine. At the mental foramen it issues from the canal and divides into the incisor branch distributed to the lower incisors, and the mental branch passing to the face in the mental region.

Several bundles of medullated fibres enter the pulp in company with the blood-vessels, and maintain an intimate association with them throughout their course. The main bundles divide and subdivide and give off numerous branches to the periphery of the pulp, but the larger nerve trunks pursue a more or less direct course to the crown portion of the pulp, where they lose their medullary sheath and the axis cylinders spread out to their ultimate distribution. Many preparations show that in company with these medullated fibres are other nerve fibres which do not stain with osmic acid, and probably are derived from the sympathetic system and possess trophic functions. The passage of the larger medullated bundles to the crown of the pulp before dividing is accounted for by the much larger area of dentine to be supplied at the crown portion of the tooth than at that of its lateral margins. These larger bundles of nerve fibres can often be seen at a definite point in the pulp to lose their medullary sheath and neurolemma, and give rise to a brush or fan-shaped expansion of delicate fibres (fig. 128). These are the fibres of the axis cylinder of the nerve, and the neurofibrils constituting them pass into a plexus beneath the odontoblast region—the plexus of Raschkow.

At the lower margin of the odontoblast layer, as shown by the author in a recent paper,¹ the delicate nerve fibres

¹ Communicated to the Royal Society in May 1918.

of the plexus form synaptic connexions with nerve-end cells which are present in a distinct row among the odontoblast cells on their pulp aspect (fig. 129).

These cells are mostly stellate in form and associated in groups. Each cell is provided with a distal process or axon, which is unbranched and passes direct to the dentine, where it enters the dentinal tube in company with the dentinal fibril but forms no connexion with it. Other processes or 'dendrons' are given off from the peripheral portions of

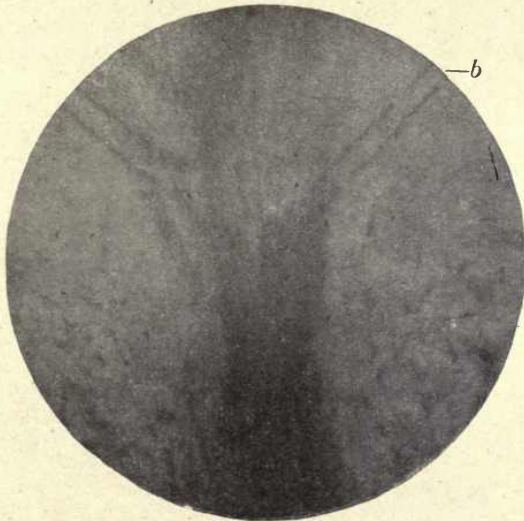


FIG. 128. Human pulp. Ground section (Weil process: iron and tannin). *b*. Blood-vessel. Axis cylinder of medullated nerve expanding in a brush-like form at crown of pulp. ($\times 600$.)

the 'end cell' (as it may for convenience be called), which are branched, and pass to the odontoblast cells to form a delicate network around them and communicate with the dendrons of neighbouring 'end cells'. The dendrons from one 'end cell' do not become directly continuous with those from neighbouring 'end cells', but their communications with these as with the fibres of the deep plexus (or plexus of Raschkow) are synaptic (see fig. 129); for it has been shown that throughout the nervous system each nerve with its nerve-end body forms a separate and distinct neuron, and the impulses which pass from cell to cell are passed across

minute spaces which exist between the terminal branches of the dendrons of communicating cells. This is known as the neuron theory, and has been confirmed by many observations and experiments.

Although able to show in 1912 (22 *a*) that neurofibrils enter

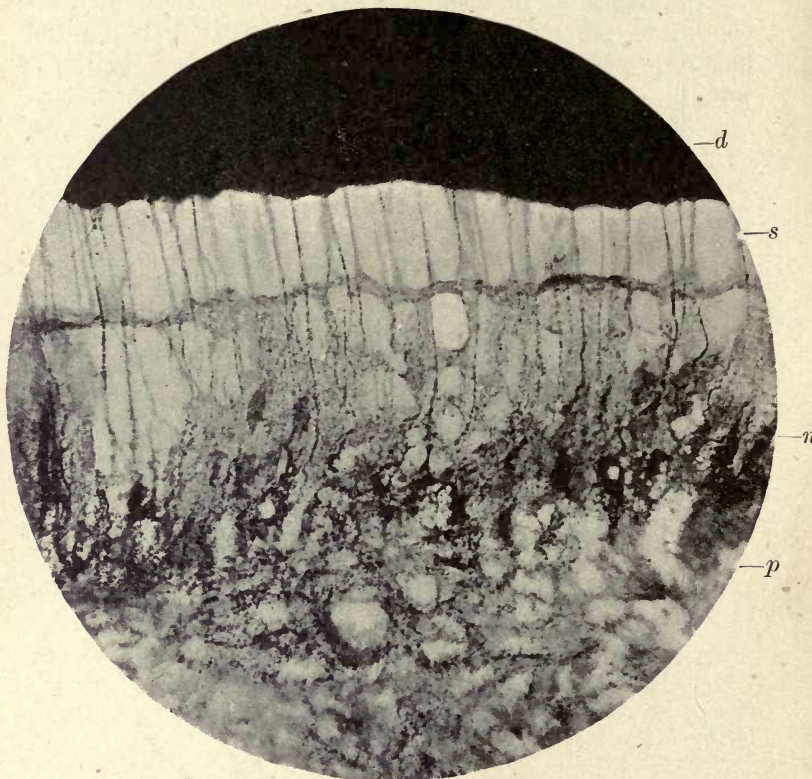


FIG. 129. Human premolar. Nerve cells and their processes in the pulp. *d*. Dentine; *s*. separation between pulp and dentine crossed by axon processes and dentinal fibril; *n*. nerve-end cells; *p*. pulp. ($\times 800$.)

the dentinal tubes and are distributed to the dentine, it was long before the author was able to establish the correct mode of distribution of the nerves of the pulp. In former preparations he had noticed as a very puzzling fact that the nerve fibres which passed up to the dentine from the deep plexus were very much larger and thicker than those which entered into the plexus beneath the odontoblasts, and attributed this

to the collection or drawing together of these fine fibres of the plexus into larger strands where they enter the odontoblast layer (fig. 130). As shown above, however, it is seen that these larger strands passing to the dentine are processes of the 'end cells'.

The bundles of neurofibrils vary very much in size, and even in the deep plexus many much larger strands are seen passing across it to the 'end cell' layer. At the crown of the pulp these strands of neurofibrils are so much larger that

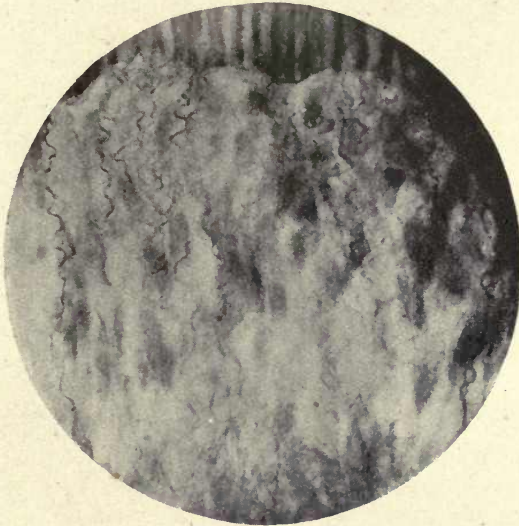


FIG. 130. Neurofibrils entering the dentine at the cornu of the pulp. ($\times 800$.)

it appears in specimens in which the 'end cells' are not stained that they pass direct from the medullated fibres to the dentine, but when the 'end cells' are fully stained it is seen that none of these strands pass direct to the dentine but they all enter the 'end cell' before their final distribution. These bodies have so long eluded observation because they remain transparent and invisible even in preparations in which the nerve fibres are very completely demonstrated.

Further experiment, however, showed that in these cases the gold had not been thoroughly reduced, and unless the reduction is very complete, the pulp showing a deep

purple coloration, the 'end cells' are not visible. In these sections the 'end cells' are a deep black and the odontoblast cells and their processes are only very faintly stained a purplish brown, but the dentinal fibril is in many parts distinctly traceable into the dentinal tube and the beaded black nerve fibre is seen passing in with it (fig. 129).

The photographs from which the accompanying figures were taken were mostly from parts of the sections where the pulp was slightly separated from the dentine, as these

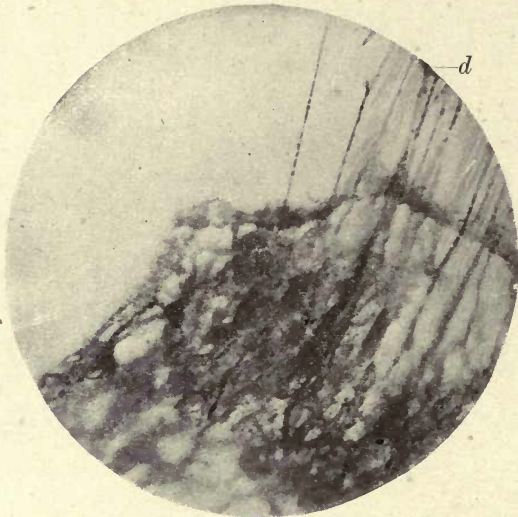


FIG. 131. Nerve-end cells with their axon processes passing to the dentine (*d*). The beaded fibre on the left under strong tension. ($\times 800$.)

show more clearly the relations of the nerves to the odontoblasts and their processes the fibrils. They also show clear evidence of the great extensibility of the neurofibrils, and exhibit with great distinctness their characteristic beading. It can be seen in fig. 130 that when the pulp is in contact with the dentine, the axon of the 'end cell' has a wavy or undulating course, but when the pulp is partially pulled away the fibres become straightened out, and if the separation is very wide they are further pulled out of the tubules of the dentine and are seen as strands of great tenuity. These eventually part asunder as seen in fig. 131, but they

undergo a very great amount of stretching before they finally give way.

The nerve fibre in this respect shows a very great difference from the connective-tissue fibre, which is possessed of a very slight amount of extensibility. Many preparations were examined with a high power of the microscope to ascertain if any of the nerve fibres in the deep plexus are distributed to the odontoblast layer without the intervention of the 'end cells', but there was no evidence of this in sections where

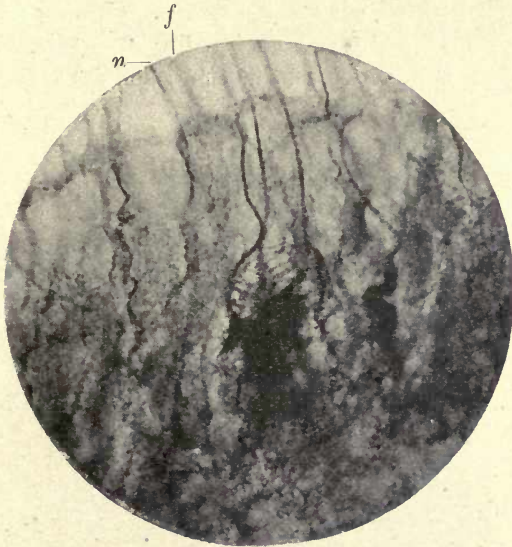


FIG. 132. Nerve-end cells showing lateral communications. *n.* Nerve fibre; *f.* dentinal fibre. ($\times 1,200$.)

the 'end cells' were distinctly stained. Sometimes one of the larger 'end cells' is seen with fine processes radiating from it on all sides; but these are scarce, and in most places the beaded delicate fibres which form a network around the odontoblast cells are distinctly seen to be given off from lateral processes of the 'end cells'. Sometimes the processes to the dentine appear to be wound together in spirals, and there is often an appearance of fibrillation in the cell body. In many places clear nuclei are seen in the cells.

There is great variation in the size of these cells, but probably many which appear to be single are really groups

of cells (figs. 132 and 133). Small enlargements are seen upon the nerve fibres distributed to the odontoblasts, but these definite enlargements are not seen upon the axon processes, which only exhibit the irregular beading characteristic of neurofibrils.

Huber (12), Guido Fischer (6), and others, looked upon these enlargements as constituting the end bodies of the nerve fibres of the pulp. They are very abundantly seen in fish and reptiles, as shown by Retzius (26).

It is these fibres with the nodes or enlargements which the author first described as forming the marginal plexus from which the processes to the dentinal tubes arose.

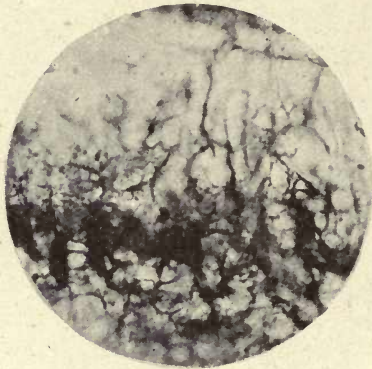


FIG. 133. Nerve-end cells in the pulp. ($\times 1,000$.)

What was formerly described, however, as the marginal plexus is evidently a portion of the network of fine nerve fibres which envelop the odontoblasts and reach up to the surface of the dentine, this network being derived as described above from the dendrons of the 'end cells'.

The fibres distributed to the odontoblasts form no connexions with them, but closely invest and surround them. The passage of the axon fibres into the dentinal tube is very clearly demonstrated, and can be traced in suitably stained preparations as a winding black fibril within the tube. Nodes or enlargements are often seen upon the fibrils within the tubes, and here and there very delicate branches are given off from these nodes to the finer branches of the dentinal tubes (fig. 135). In fig. 136 are seen the nerve

fibres within the tubes just beneath the granular layer of Tomes under the cement. At the enamel junction they spread out in fine arborizations within the terminal branches of the dentinal tubes, and some enter the interprismatic



FIG. 134. The network of nerve fibrils enveloping the odontoblasts. ($\times 800$.)



FIG. 135. Neurofibrils in dentinal tubes near pulp, showing nodes or enlargements. ($\times 800$.)

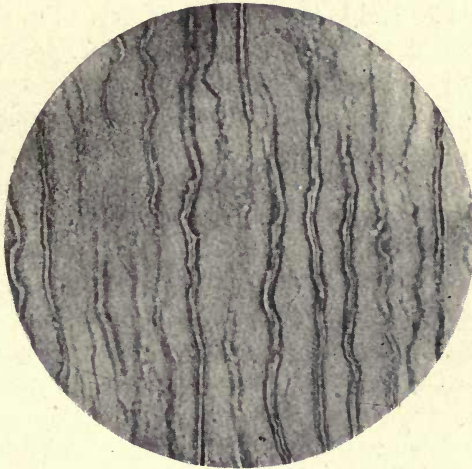


FIG. 136. Neurofibrils in the dentinal tubes near the cement margin. ($\times 700$.)

spaces of the enamel and terminate in small bulbous enlargements. In the very fine terminal branches of the dentinal tubes at the cement margin, only a very delicate uniform dotting can be seen in these gold preparations, and this appearance is also seen in the canaliculi of the cement with

which these fine branches are continuous. But while these appearances would seem to indicate that there is a direct nerve communication between the pulp and the cement, we cannot definitely prove this until the fibre in this situation is seen to be clearly continuous, since in all metallic impregnations deceptive appearances may arise from deposits. It is, however, noticeable that in these fine divisions of the tubes the dotting is uniform and does not show the variation in size of the particles which so often occurs in imperfectly reduced preparations.

Where the so-called spindles are present in the enamel, especially at the apices of the cusps, fine winding fibres are sometimes seen within them which do not appear with ordinary staining reagents, but these spindles do not appear in the author's preparations to contain definite nerve-end organs as described by Römer (28). It is impossible, however, to speak with certainty on this point, and the spindles being comparatively infrequent a great many teeth should be examined to decide the question. From the preparations already made, however, one would be inclined to consider the penetration of these bodies by nerve fibres more as due to the fact that nerve fibres in the tubes would be likely to penetrate into any open space with which the tubes communicate than as constituting definite nerve-end organs.

The refraction in these spindles greatly interferes with accurate observation even in thin sections. It is considered by many, as previously stated, that the spindles are inter-prismatic spaces which have remained uncalcified, and the author's own observations on the enamel of marsupials appear to confirm this interpretation of their nature.

In fig. 137 the mode of distribution of the nerves of the pulp and dentine is represented diagrammatically.

The mode of distribution of the nerves of the pulp above described appears to be peculiar to the teeth, as such a mode of termination of sensory fibres in 'end cells' is not met with in other organs. It would appear to show the interposition of a peripheral sensory neuron in the course of the distribution of a sensory nerve, a condition not seen elsewhere in the body. Of the sensory nature of at all events the majority of these nerve fibres there can

scarcely be any doubt. Dentine is an extremely sensitive structure. Healthy dentine, when fractured without exposure of the pulp, is usually very sensitive; it is also a common clinical observation that in coning a living tooth for crowning, when the enamel has been removed, the grinding of the dentine causes acute pain.

In the excavation of a carious tooth, although little

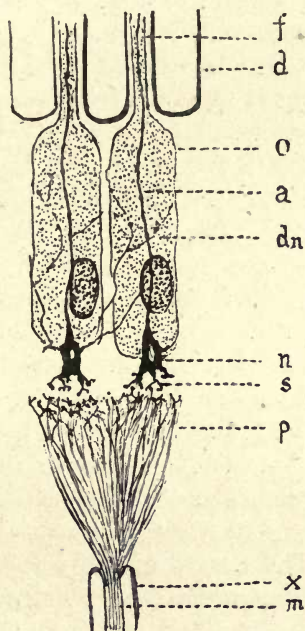


FIG. 137. Diagram. Scheme of distribution of the nerves of the pulp. *m.* Axis cylinder of medullated nerve; *x.* medullary sheath; *p.* nerve plexus; *s.* synaptic terminations; *n.* nerve-end cell; *dn.* dendrons; *a.* axon; *o.* odontoblasts; *d.* dentine; *f.* dentinal fibril.

pain is felt on removal of the superficial layers, when the lowest layer is raised from the healthy dentine beneath the pain is acute. From these and other observations we must conclude that sensory nerve fibres are distributed to the dentine, but the question arises whether all the nerves of the pulp are made up of sensory fibres. We know also that the surface of an exposed pulp is very sensitive, so we must suppose that sensory fibres are distributed to the odontoblast layer. We should, therefore, imagine that both sensory

and trophic fibres would be distributed to the pulp and also to the dentine which contains within the tube a protoplasmic prolongation of the odontoblast cell, the maintenance of the functions of which would probably require a nervous supply.

Historical Review

The question of the innervation of the dentine has long been a matter of much controversy, the majority of observers holding that sensation was conducted by the dentinal fibril, while others thought it probable that true nerve fibres were supplied to the dentine.

For a long period it was considered that dentine is not sensitive, and even such an eminent authority as John Hunter was of this opinion. He says (13): 'We may presume that the bony substance' (of the teeth) 'itself is not capable of conveying sensations to the mind, because it is worn down in mastication and occasionally worked on by operators in living bodies without giving any sensation of pain in the part itself.' Duval showed, in a paper which he read before the Academy of Medicine in Paris in 1831, that there is sensation in the dentine, and was of opinion that it is chiefly manifested just beneath the enamel (5).

Salter, in his classical work on *Dental Pathology*, writing in 1874, says: 'The nerves of the tooth-pulp form loops towards the periphery which may be readily demonstrated by the action of caustic alkali, and from these, according to Boll, large numbers of very minute fibrils proceed outwards between the ivory cells and their tubular prolongations. It is highly probable that these are the nervous elements distributed to the dentine, but whether they pass into the intertubular substance, or, fastening upon the tube walls, are so piloted into the ivory structure, is quite uncertain. It is, however, highly improbable that they pierce the wall of the ivory cell and occupy the axes of the tubes' (29).

Boll's observations were made in 1868 (2), on the teeth of Rodents, which he treated with a very weak solution of chromic acid ($\frac{1}{16}$ to $\frac{1}{32}$ per cent.). His preparations showed fine fibres in great abundance, which passed between the odontoblasts, and where the dentinal fibril was pulled out

from the dentine he could also trace them between these fibrils. From these observations he concluded that the nerve fibres entered the tubes of the dentine. Boll was not successful in actually tracing them into the hard substance, but he appears to have been the first observer who had succeeded in tracing them so far in their course from pulp to dentine.

Kölliker (1867), speaking of the nerves of the pulp, says : 'As regards their endings, one sees, here and there, loop-like curves of the fibres, but it is beyond doubt that these are not the last endings.'

Professor Klein, in 1883 (15), says : 'Numerous medullated nerve fibres, forming plexuses, are met with in the pulp tissue ; on the outer surface of the pulp they become non-medullated fibres, and probably ascend in the dentinal tubes.'

Several histologists have attempted to account for sensation in the hard substance of the tooth apart from the actual presence of nerves, considering that the soft material occupying the dentinal tubule conducted sensation to the nerves of the pulp. The principal supporters of this view have been Hopewell Smith and Dr. Aitchison Robertson, although they differ in their views as to the actual anatomical path by which sensation is transmitted.

Hopewell Smith (11) has long held the view that the function of the odontoblast cell is that of a nerve-end organ, sensation being conveyed through the dentinal fibril, which is a protoplasmic prolongation of this cell. He was able to show, by means of teased-out preparations from the pulp, that the nerve fibres when stained with methylene blue, took on the characteristic varicose appearance, and were seen in great abundance immediately around the odontoblasts. He was unable to trace fibres into the cells, although they enclosed them in a fine network.

Hopewell Smith, while allowing the objection that the epiblastic nerve fibres are connected with cells derived from the mesoblast, says : 'Accepting the statement of Schafer (that all nerve fibres and nerve cells are originally derived from the neural or neuro-sensory epiblast) one is led to the conclusion that odontoblasts cannot possibly be, from

the developmental point of view, ganglion cells in which sensory, or tactile, or trophic influences arise *de novo*. But it is no argument against the idea that they serve as sensation transmitters.' In the last edition of his *Histology*, 1919, this author says: 'As the result of his researches the author has the strongest conviction that these fibres terminate in a basketwork of varicose fibres embracing and often closely attached to the cell walls of the individual odontoblasts.'

In the absence of evidence of the passage of nerves into the dentine we can understand this to be a possible, although an improbable, explanation of the mode in which the dentine transmits sensory impulses, but we do not think there has ever been any proof that such mode of transmission occurs in the mammalian tooth. Weil of Munich held a similar view and says: 'As things stand at present nothing lies in the way of the theory that each delicate fibril of the basal layer of the *membrana eboris* is a means of connexion between the nervous system and the odontoblasts, and that the latter formations may be regarded as nerve endings,' but he goes on to say that it is only an hypothesis that time may prove to be true, and must limit himself to saying that nerve fibres or groups of such cannot be found beyond the cortical layer of the pulp.

Magitot in 1879 (18) described certain ramified cells beneath the odontoblasts which he said were in continuity by their processes with the nerve fibres on one hand and the basal prolongations of the odontoblasts on the other, thus 'forming a direct chain of sensation'. The existence of such an arrangement has, however, never been corroborated by other observers.

In 1891 Aitchison Robertson contributed a paper to the Royal Society of Edinburgh in which he asserted his conviction 'that the central processes of the odontoblasts become continuous with nerve fibres' (27).

'The central process seems to become the axis cylinder of a nerve fibre which gradually acquires a primitive sheath in which the medullary substance slowly accumulates till an ordinary medullated nerve fibre results.' He would thus look upon the odontoblasts and dentinal fibrils as the

terminal organs of the nerve fibres, and says: 'We may regard the odontoblast and its peripheral process as an end organ, which, if not itself sensitive, at once transmits sensory impulses to the nerve with which it is connected.'

He would thus agree with Hopewell Smith's views, but goes further than that author in describing a direct continuation of the pulp process of the odontoblast into a true nerve fibre.

One is aware that there is some analogy to this mode of termination in the endings of the olfactory nerves. From the olfactory cell with its peripheral termination in the olfactory hairs a nerve process proceeds towards the olfactory bulb, but in this case the olfactory cell is an epiblastic cell and the nerve fibre apparently represents the axon of a true nerve cell. The cell and the nerve fibre are formed from the same layer of the blastoderm.

Carl Huber, in 1898 (12), by the use of methylene blue, traced nerve fibres to the plexus beneath the odontoblasts, and from that to what he considered their terminations at the inner border of the dentine. In this he corroborated the researches of Retzius (26), who in 1894 traced nerve fibres in the pulp of the mouse to the inner surface of the dentine; but while Huber does not believe in the possibility of their entering the dentine, Retzius appears to be more doubtful on this point, for he says: 'In vertical sections the fibres, like a string of tiny beads, stretch between the odontoblasts to the surface, and run a little way tangentially. In a tangential section they can be partially traced under the dentine.'

Retzius has figured and described the nerve distribution in the teeth of reptiles and fish, and figures them as terminating within the tooth-pulp.

Morgenstern (21) in 1892 and 1895 published his views on the distribution of the nerves to the hard tissues of the teeth. He made use of Golgi's method and described *medullated* fibres entering the dentine. He considered that they occupied tubes distinct from the dentinal tubules and also traversed the dentinal tubules, and terminated either at the dentine-enamel margin or in the substance of the enamel, in the knob-shaped enlargements seen

often at the crown of the tooth projecting into the enamel (the spindles).

We should be very unwilling to translate the thick black lines often obtained in the dentine in Golgi preparations as medullated nerves; they appear more in the nature of irregular deposits of the chromate of silver, and these appearances probably led this observer to the extraordinary conclusion at which he arrived.

Professor Römer of Strassburg (28) has been for several years engaged in an investigation of the nerves of the teeth. There is little doubt he succeeded in tracing nerve fibres into the dentine, but he was unable to carry conviction with the few preparations he procured, and his statement that the nerve fibres enter the dentinal fibril (which he considers to be a tube) has not been substantiated. He considered that there was a normal termination of the nerves to be found in the spindles at the enamel margin.

Pont, in 1900 (24), compared the odontoblasts to peripheral neurons (nerve cells with their processes), which occur in other peripheral organs such as the retina, and considered that the nerve fibres, without forming any direct anatomical communication with the odontoblast, formed synapses, that is, that the nerves which envelop the cell transmit sensation from the cell to the afferent nerve, actual anatomical connexion not being necessary for the transmission of impulses from the peripheral cells. The same objection would hold good here that applies to Hopewell Smith's view, that we should not expect a synaptic any more than a direct communication between a cell formed from the mesodermic layer and a true nerve fibre of ectodermic origin. It is now generally considered that independent neurons never form direct communications, but that all such between individual nerve cells and their processes with neighbouring cells are synaptic.

Since the publication of the author's paper in 1912 the late Professor Dendorf of Leipzig has published the results of his researches on the same subject (3). He employed many different staining and impregnation methods, usually staining small pieces of teeth in bulk, and he corroborated the author's observation that the nerve fibres of the

pulp enter the dentinal tubes. He also described the small nodes or enlargements on the fibres. Certain statements of this author as to the passage of nerve fibres *across* the tubes on the surface of the sectioned dentine and figured as quite independent of the tubes, are difficult to understand. He says: 'From the dentigenous substance and in the dentine they' [the neurofibrils] 'are distributed in the area of the intercellular substance, and take a course independent of Tomes' fibres, forming a wide-meshed network. Neurofibrillæ are also found in the area of Tomes' fibres within the dentinal tubuli. Hence the nerve fibres in the dentine have two courses: one within the basic intercellular substance, the other within the dentinal tubuli, and there may be a possible connexion between these fibres. Possibly their function differs, one group governing sensation, the other, nutrition.' A paper on the innervation of the dentine was also published by Fritsch in 1914 (8).

The present author's own investigations date back to 1891, when he made use of various stains in the attempt to demonstrate the distribution of the nerves of the pulp. Pulps treated with weak chromic acid by the method of Boll showed a multitude of fine fibres close to the dentine, but they could not be traced further.

The iron and tannin method gave much better results, and showed very clearly the connexion of these fine fibres with the medullated fibres of the pulp,¹ and in a few cases the actual passage of the fibre into the dentinal tube, but the demonstration was not sufficiently convincing to be made use of.

The intra-vitam method with methylene blue was carried out on two occasions—once with Professor Miller in Berlin, and was again kindly conducted for the author by Professor Starling at University College.

These preparations showed an abundance of neurofibrils proceeding to the dentine, but it was impossible to obtain sections, as the colour cannot be retained during decalcification. The recent results have been obtained with a modification of the Beckwith gold chloride method, the specimens,

¹ Tomes, C. S., *A Manual of Dental Anatomy*, 7th ed., p. 79.

impregnated with a very weak solution of gold chloride (1 in 5,000), being reduced in alkalis.

As shown by the author in several communications (22), this method, as first employed, demonstrated nerve fibres in connexion with the medullated fibres of the pulp passing

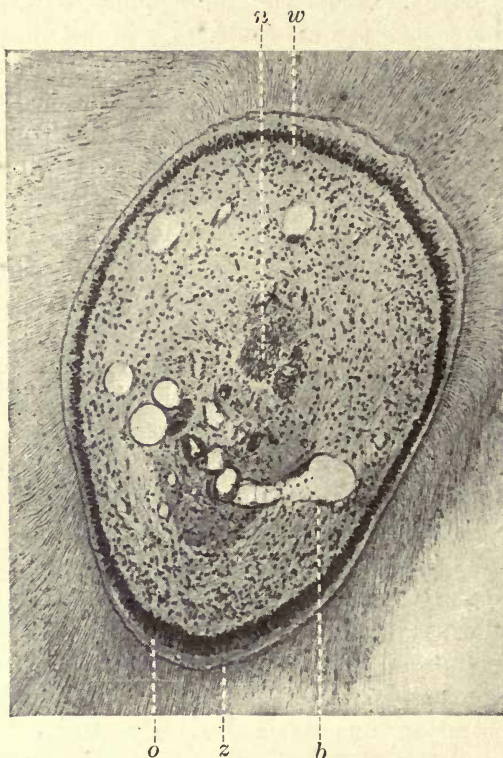


FIG. 138. Pulp of human premolar prepared by the Weil process. Stained borax carmine. *o.* Odontoblasts; *z.* odontogenic zone; *b.* blood-vessels; *n.* nerve trunks; *w.* basal layer of Weil. ($\times 50$.)

in extraordinary abundance to the dentine and entering the tubes; it also revealed an intricate plexus of neurofibrils between and around the odontoblasts. The 'end cells', however, were not shown in these preparations, and only appeared when the modified method, above described, was adopted.

The basal layer of Weil. Professor Weil (34) of Munich described a layer or space which lies immediately beneath the odontoblast layer (fig. 138), and which is especially

visible in preparations which have been made by the Koch-Weil balsam process, but is also seen in many decalcified sections.

With low powers of the microscope no distinct structure is visible in this area, but with higher powers it is seen to be occupied by an interlacement of delicate fibres. Weil compared this layer to a basement membrane, looking upon the odontoblasts as being analogous to a layer of epithelial cells, but there is very little evidence to support any such view, and the actual structure of this layer can, we think, be quite clearly demonstrated.

The denser connective tissue of the pulp extends in this position as an interlacement of delicate connective-tissue fibres which pass between the odontoblasts to the dentine, and there become incorporated in the matrix, but the same area is also occupied by the plexus of fine nerve fibres beneath the odontoblasts which communicate with nerve 'end cells' within the odontoblast layer. It is also crossed by the pulp processes of the odontoblasts, which are usually delicate and not very evident in many preparations. In order to show that this so-called layer of Weil was not a clear space, but occupied by fibres which do not stain by ordinary methods, the author removed the balsam from a Weil preparation which showed the area very distinctly, by soaking it in chloroform. The section was then restained with gold, reduced by the Beckwith process; the clear layer was no longer visible, being entirely occupied by a dense plexus of delicate nerve fibres forming the deep plexus, or plexus of Raschkow, the delicate connective-tissue fibres remaining unstained.

The plexus of Raschkow is much more evident in some parts of the pulp than in others, and this is also noticeable with regard to the basal layer. It is not seen at the root end of the tooth where the nerve plexus is also absent, and at the coronal portion where the nerve fibres from the dividing medullated trunks pass more directly to the odontoblast layer this area described by Weil cannot be detected.

Von Ebner and Röse doubted its existence as a distinct structure and considered it was artificially produced, but that this rarified area of the pulp tissue is present in many

sections we think there can be no doubt, and in properly prepared Weil sections there is no evidence of any stretching of the pulp tissue or disturbance of any of the tissues; in fact, they are seen in their definite relations to one another probably more perfectly than by any other process (22 *d*).

In 1908 Mr. Law (17) read a paper before the Odontological section of the Royal Society of Medicine in which he described his investigations with Bethe's methylene blue process. He found large fibres running up to the dentine in the pulp, but the few sections made use of did not show any connexion with nerve fibres in the pulp, and it could not therefore be clearly demonstrated that they were nerve fibres. He stated that in these preparations he could find no trace of the deep plexus, or plexus of Raschkow.

Dr. Dentz of Utrecht found in some sections of developing human teeth a row of pear-shaped bodies near the outer margin of the dentine. These bodies had very much the appearance of nerve-end organs; they each contained several large bodies resembling nuclei, and the area of dentine surrounding the outer club-shaped end showed a certain amount of modified dentinal tissue with few or no tubes. These bodies apparently represent some abnormality in development, as being of very large size ($\frac{1}{400}$ th inch), they must have been conspicuous in other preparations had they been constantly present in deciduous teeth. No nerve fibres could be traced into them, and it is difficult to account for their occurrence in these preparations. These bodies are shown in figs. 139 and 140 under a high and low power, and were photographed from the specimen kindly lent to the author by Dr. Dentz.

Persistent Pulp. Persistent pulps are found in teeth which are subjected to constant and severe attrition, as the incisors of Rodents. The pulp is not completely enclosed within a bony cavity as in the majority of teeth, but remains open at the base, and is continually growing during the life of the animal, new hard tissue being deposited by the formative cells of the pulp as the tip of the tooth becomes worn down in use. The nerve trunk to the pulp runs backward beneath the tooth and then bends abruptly and enters the pulp, showing that the tooth is continually

growing in a backward direction from its original position in the jaw. Remarkable effects sometimes result from this

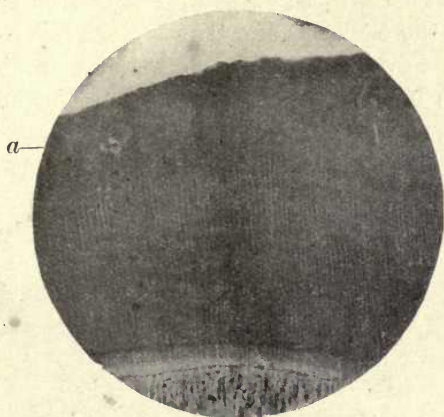


FIG. 139. Dr. Dentz's specimen showing position of corpuscle-like bodies (*a*) shown in fig. 140. ($\times 50$.)

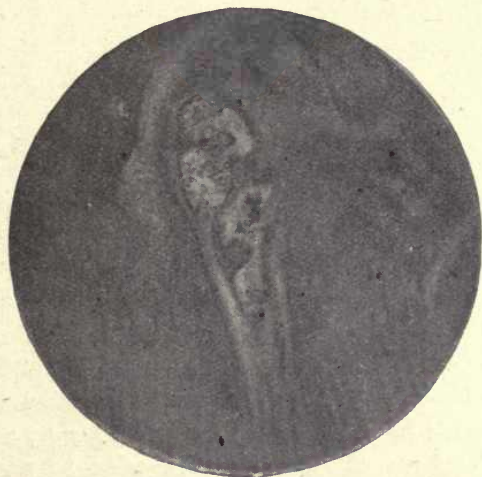

FIG. 140. Dr. Dentz's specimen. Curious corpuscle-like body in dentine of a temporary tooth. ($\times 250$.)

continuity of growth. Many instances are on record where, from fracture or displacement of the upper incisor of a rabbit, the lower tooth, being no longer worn down at its cutting edge, continues to grow forward, and following

the curve of the tooth sometimes turns directly backwards, penetrating the skull and brain.

The persistent growth of the great incisor teeth forming the tusks of the elephant sometimes gives rise to remarkable conditions. Several cases have been recorded where an elephant has been struck by a javelin or loaded spear-head which has penetrated the pulp at the free-growing end, and the vitality of the tissues has been so great that the death of the pulp has not followed, but the spear carried forward by the growing tooth has been completely surrounded

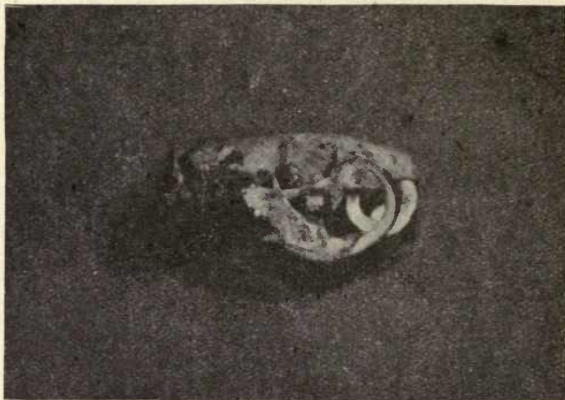

FIG. 141. Skull of Rat (*Mus decumanus*). Dislocation and overgrowth of incisors. The right upper incisor penetrates the skull. (From a specimen lent to the author by Mr. Montagu Hopson.)

by the subsequently deposited ivory and has become immovably fixed in the tusk. Such a case is shown in the photograph (fig. 142). The head of the javelin and a portion of the iron shaft are embedded solidly in the ivory. This specimen was obtained from the ivory worker by a merchant in the City, who could not be persuaded to part with it but lent it to the author to be photographed. There are two somewhat similar specimens in the Hunterian Museum at the Royal College of Surgeons. The effects of the continuous growth of teeth with persistent pulps is also shown in fig. 141, the skull of the rat previously referred to on p. 107.

Other examples of teeth with persistent pulp are found in the incisor of the Dugong, the large upper canines of the

Walrus, and in many marsupials—as in the lower incisors of the Kangaroo—the procumbent incisors of the *Hypsi-primninae*, and both the incisors and molars of the rodent-like Wombat. In the Wombat also a layer of cement is continued over the surface of the incisors covering the enamel, while in Rodents the cement is not continued over the surface of the enamel. In these scalpriform incisors a sharp edge of enamel is maintained by the unequal wear of the tissues of the tooth, the dentine and cement wearing




FIG. 142. Spear-head embedded in tusk of Elephant.

down much more quickly than the hard enamel which projects as a sharp cutting edge.

In the fish, the rostral teeth of the Saw-fish (*Pristis*) grow from persistent pulps, and they are also implanted in sockets.

There are certain peculiarities in the shape and extent of the pulp cavities in the teeth of ancient forms of man recently discovered.

In the Heidelberg mandible the pulp cavities are very much larger in proportion to the hard tissues than in modern man. Especially in the Krapina teeth, as shown in Professor Keith's skiagrams, is this noticeable, the pulps

being very large and extending deeply into the root (14). The meaning of this large pulp cavity and the special purpose it served are somewhat difficult to understand.

REFERENCES

1. Bartels. *Das Lymphgefäß-System*. Jena, 1909.
2. Boll, Franz. 'Untersuchungen über die Zahnpulpa.' *Archiv f. Micr. Anat.*, 1868, vol. iv, p. 73.
3. Dependorf. 'Beiträge zur Kenntniss der Innervirung der menschlichen Zahnpulpa und des Dentins.' *Deutsche Monatschr. f. Zahnheilkunde*, 1913, vol. xxxi, p. 689.
4. Dewey, K., and Noyes, F. B. 'A Study of the Lymphatic Vessels of the Dental Pulp.' *Dental Cosmos*, vol. lix, 1917, pp. 436-44.
5. Duval, J. R. *Observations pratiques sur la sensibilité des substances dures des dents*. Paris, 1833.
6. Fischer, G. *Bau und Entwicklung der Mundhöhle des Menschen*, 1910.
7. Fleming. 'Virchow's Festschrift, 1891.' *Archiv für Anatomie*, 1897.
8. Fritsch, C. 'Untersuchungen über den Bau und die Innervirung des Dentins.' *Archiv f. Micr. Anat.*, 1914, pp. 307-20.
9. Haidenhain, M. *Plasma und Zelle*, 1907.
10. Hanazawa, K. 'A Study of the Minute Structure of Dentine, especially of the Relation between the Dentinal Tubules and Fibrils.' *Dental Cosmos*, Feb. 1917 and March 1917, vol. lix.
11. Hopewell Smith, A. (a) *Histology and Patho-histology of the Teeth*, 1st ed., p. 170 and appendix.
(b) *Normal and Pathological Histology of the Mouth*, 1919, vol. i.
12. Huber, C. 'The Innervation of the Tooth-pulp.' *Dental Cosmos*, 1898, vol. xl, p. 803.
13. Hunter, J. *John Hunter's Works*. Palmer's edition, 1835, ii, p. 50.
14. Keith, A. *Proc. Roy. Soc. Med.* (Odontological Section), 1913, vol. vi, p. 105.
- 14 a. Keith, A., and Knowles, F. H. S. 'A Description of Teeth of Paleolithic Man from Jersey.' *Journ. Anat. and Phys.*, 1912, vol. 46, pp. 12-27.
15. Klein, E. *Elements of Histology*, 1883, p. 174.
16. Kölliker. *Gewebelehre*, 1889.
17. Law, W. J. *Proc. Roy. Soc. Med.* (Odontological Section), 1908, p. 45.
18. Magitot et Legros. 'Morphologie du follicule dentaire chez les Mammifères.' *Journ. de l'Anat. et de la Phys.*, Paris, 1879, vol. xv, pp. 248-93.
19. Mall, F. *American Journal of Anatomy*, vol. i, 1901-2.
20. Morgan, G. 'Lymph Glands in relation to the Teeth and Gums.' *Brit. Dent. Journ.*, 1903, vol. xxiv, p. 521-8.
21. Morgenstern. 'Ueber das Vorkommen von Nerven in den harten Zahnsubstanzen.' *Deutsche Monatschr. f. Zahnheilkunde*, 1892, p. 436, and 1895, p. 111.

22. Mummery, J. H. (a) 'On the Distribution of the Nerves of the Dental Pulp.' *Phil. Trans. Roy. Soc.*, 1912, vol. ccii, pp. 337-49.
- (b) 'The Nerve Supply of the Dentine.' *Proc. Roy. Soc. Med.* (Odontological Section), 1912, vol. v, pp. 166-88.
- (c) 'The Innervation of Dentine.' *Dental Cosmos*, March 1916.
- (d) 'Basal Layer of Weil.' *Journ. Brit. Dent. Assoc.*, 1892, vol. xiii, pp. 777-81.
23. Paul. 'A Contribution to the Histological Study of Dentine.' *Trans. Odontol. Soc. Great Brit.*, 1902, p. 25.
24. Pont. 'La Cataphorèse en art dentaire et plus spécialement dans les cas de dentine hypersensible.' *Trans. Third Int. Dent. Congress*, Paris, 1900, p. 232.
25. Ranvier. *Traité technique d'Histologie*, 1889.
26. Retzius, G. *Biologische Untersuchungen*, Neue Folge, iv, v, and vi, 1892, 1893, and 1894.
27. Robertson, Aitchison. 'On the Relations of Nerves to Odontoblasts and on the Growth of Dentine.' *Trans. Roy. Soc. of Edinburgh*, vol. xxxvi, p. 323.
28. Römer, O. *Nerven im Zahnbein: Zahnhistologische Studie*. Freiburg, 1899.
29. Salter, James. *Dental Pathology and Surgery*, 1874.
30. Schafer, E. A. 'Microscopic Anatomy.' Vol. ii, pt. i, of *Quain's Anatomy*, 1912.
31. Schweitzer. 'Ueber die Lymphgefäße des Zahnfleisches u. der Zähne beim Menschen u. bei Säugethieren.' *Archiv f. Micr. Anat.*, 1907, p. 807; 1909, p. 27.
32. Testut. *Traité d'Anatomie humaine*, 1912, p. 58.
33. Waldeyer. *Sitzungsberichte d. Pr. Akad.*, 1895.
34. Weil, W. A. *Zur Histologie der Zahnpulpa*, Leipzig, 1887, p. 55.

CHAPTER IV

DENTINE

THE bulk of the human tooth, as well as that of the teeth of other mammalia and many vertebrates, consists of dentine, and although found throughout the animal kingdom in many different forms, this tissue has certain common characteristics which clearly separate it from the other hard tissues of the teeth. In distinction from enamel it has a collagen basis, and when subjected to the action of acids this gelatinous substance retains the form of the calcified dentine. In this respect it resembles bone, but there are differences in structure in all the different varieties of dentine which distinguish it as a special tissue peculiar to the teeth and dermal appendages.

The form of dentine found in the human tooth, and the teeth of mammalia generally, is the so-called tubular dentine, the organic matrix being permeated by a series of parallel tubes with fine branches which everywhere penetrate it.

This tubular dentine has been called by Tomes 'orthodentine' to distinguish it from other varieties which might also be described as tubular.

The classification of dentines adopted by Tomes is as follows :¹

Orthodentine.

Plicidentine.

Vasodentine.

Osteodentine.

Röse, however, has suggested a different classification :

Orthodentine including { Vasodentine.
Vitrodentine.

Trabecular dentine.

Bone dentine.

Röse includes under his vitrodentine the outer layer of the teeth of *Selachia*, which Tomes considers to be enamel. There are certain objections to Röse's classification which are considered by Tomes in a paper on the subject in 1898 (22*b*), and as his classification of dentines appears to be the simplest and least open to objections, it has been adopted in the present work. As Tomes points out, the term 'trabecular dentine' is perhaps a better descriptive term than 'osteodentine', and we may conveniently describe this variety as osteo- or trabecular dentine.

Orthodentine (tubular dentine). To the naked eye typical orthodentine, as seen in human teeth, is a yellowish white semi-translucent substance covered by enamel in that portion of the tooth which is raised above the gum margin, and in contact externally with the overlying cement at the neck and root of the tooth.

If a tooth is placed in an acid solution, such as a 3 to 5 per cent. solution of nitric or hydrochloric acid, the lime salts are removed and the collagen basis substance alone remains and still exhibits the general structure and appearance of the calcified dentine; it is soft and elastic and can be penetrated by a needle. The resulting substance is collagen, which is converted into gelatine by boiling, thus having the same characteristics as bone.

When both bone and dentine are treated with strong acids a residue remains which consists of elastin, and is probably present in the dentine in the Neumann's sheaths of the tubules.

Chemical Composition. As in enamel, the salt which greatly predominates in dentine is calcium phosphate, the other salts present being calcium carbonate and magnesium phosphate, and according to Von Bibra (2) traces of calcium fluoride. The same author also gives the percentage of animal matter as 27.61, while the percentage of organic matter in enamel according to recent analysis is from 1 to 2.

Tomes, however, considers that the amount of organic matter in dentine has been over-estimated, and would place it at about 19 per cent., as he considered that the water retained in combination with dentine, even when dried at 212° F., amounts to about 8 per cent. of the whole, and he

would therefore consider the following to be a much nearer approach to the actual proportions in dentine.

Fresh human dentine :

Free water (which can be dried out at 212° F.) .	10
Dry dentine	90
	<hr/>
	100

Dried human dentine :

Organic matter	19.6
Combined water	8.4
Salts	72
	<hr/>
	100

Von Bibra in one analysis gives :

Organic matter (tooth cartilage)	27.61
Fat	0.40
Calcium phosphate and fluoride	66.72
Calcium carbonate	3.36
Magnesium phosphate	1.08
Other salts	0.83
	<hr/>
	100

In these analyses the large amount of organic matter present in dentine compared with that in enamel is especially to be noticed, and the great preponderance of phosphate over carbonate of calcium in both dentine and enamel.

Black (3) undertook a careful investigation to determine the percentage of lime salts in the dentine of teeth of apparently different density, and came to the conclusion that there is a scarcely appreciable difference between the percentages of lime salts in all the teeth examined.

He stated 'that neither the density, nor the percentage of lime salts, nor the strength, is in any degree a factor in predisposing the teeth to caries or hindering its inception or progress'. It was pointed out, however, by Professor W. D. Miller that the resisting power might not depend so much on the percentage of lime salts in the teeth as upon the molecular conditions present; the degree of stability of the compounds formed with the organic material of the tooth. Although the amount of the salts in the tissues may

be approximately the same, the manner in which they are bound together in the dental tissues may vary considerably.

The Dentine Matrix. This is a clear, more or less homogeneous looking substance traversed by the dentinal tubes. In young teeth, where the deposition of the dentine is still proceeding, the denser part of the tissue is bordered by a clear layer between it and the odontoblasts in which the tubes are clearly seen but not so sharply defined (fig. 143); this is the odontogenic zone (the prardentine of Continental authors), and is occupied by tissue on the borderland of calcification in which the salts are not yet fully deposited. The calcified

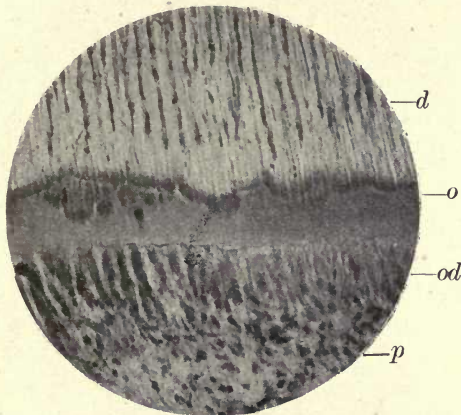


FIG. 143. Human tooth—near open end. *d.* Dentine; *o.* odontogenic zone; *od.* odontoblasts; *p.* pulp. ($\times 150$.)

dentine has a festooned outline towards this zone, made up of rounded bodies, the contours of which are formed by the calcospherites or spherical masses of lime salts which build up the fully calcified substance of the dentine, as will be more fully described in treating of its development. Delicate fibres derived from the connective tissue of the pulp are present in the matrix and form its fibrillar basis, the existence of which is usually completely veiled by the dense calcification; but it appears occasionally in parts acted upon by the acids of caries, the slow action of the weak acid gradually undoing, as it were, the process of development and revealing the foundation substance. At the borders of carious cavities a very fine lamination is sometimes

seen more or less parallel with the dentine surface (fig. 144), and in young, growing teeth treated with silver nitrate by the Cajal process these parallel lines are seen to be concentrically arranged. This part of the subject, however, will be further considered under the development of the dentine.

The Granular Layer of Tomes. Within the marginal portion of the dentine and in contact with the cement, although sometimes separated from it by a clear layer, is seen a line

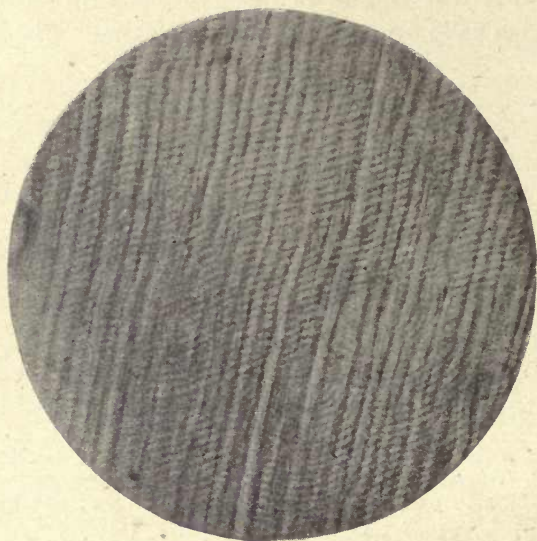


FIG. 144. Adult human molar affected by caries. Action of acids of caries, showing striation and contours as in figs. 178 and 179. ($\times 600$.)

of dark contours, angular or crescentic in form, which has a granular appearance under the microscope, and owing to this appearance was named 'the granular layer of Tomes', Sir John Tomes having been the first to describe it. These small spaces are usually confined to the dentine beneath the cement, but are occasionally, although rarely in man, found under the enamel. They appear to be a normal portion of the structure of the dentine and are found in all teeth; the tubes of the dentine communicate with them by their fine terminal branches. The rounded contours of the calcifying substance are seen to surround them, and

they are in this sense interglobular spaces, but they are not apparently due, as are the interglobular spaces presently to be described, to a want of complete coalescence of the calcospherites but are normal structures surrounded by the calcifying bodies, for the tubes enter them and do not pass uninterruptedly across them as in the large interglobular spaces beneath the enamel. These bodies probably afford a channel of communication between the pulp and the canaliculi of the cement; they are in fact seen to do so in

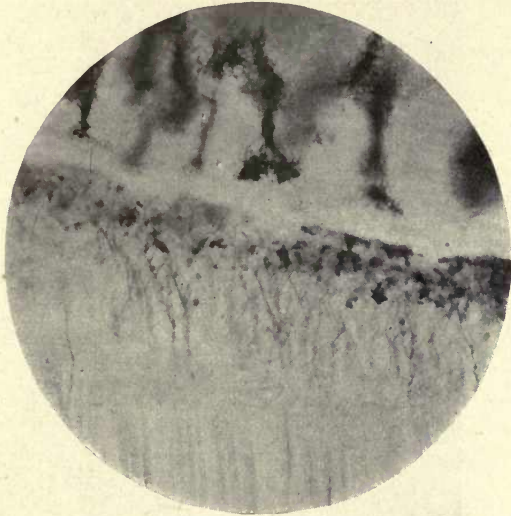


FIG. 145. Human molar. Communication of dentinal tubes with spaces of granular layer. ($\times 250$.)

many instances (fig. 145). We should then look upon this layer as part of the normal structure of dentine. They are found in many Mammalia, and are very conspicuous in the dentine of the Cetacea, where they are arranged in concentric rows. In many teeth other much larger interglobular spaces are seen, generally situated beneath and not far from the enamel in the substance of the first-formed dentine (fig. 146). They are evidently formed by the want of coalescence of the calcospherites which form the calcified portion of the matrix. In teeth from rickety subjects, in whom the calcification of the bones and teeth is very

imperfect, these interglobular spaces are very abundant, and are usually associated with very conspicuous defects in the enamel. The contents of the interglobular spaces are usually granular, but sometimes appear quite clear. It was noticed by Tomes that in caries of the dentine the tubes filled with micro-organisms are more expanded or dilated within the interglobular spaces, as they probably meet with less resistance than in the calcified dentine. In advanced caries beneath the enamel the interglobular spaces break down

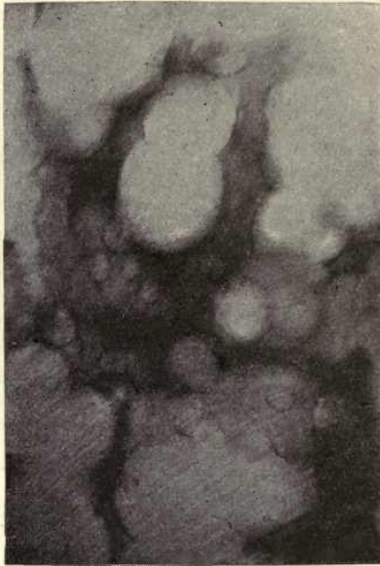

FIG. 146. Interglobular spaces in dentine. ($\times 300$.)

and are often seen to be crowded with micro-organisms. The spaces are probably occupied by the uncalcified ground substance of the dentine as first stated by Kölliker.

The fact that the tubes of the dentine communicate with the spaces of the granular layer, while in the larger spaces they form no such communication, would apparently point to the explanation that the spaces of the granular layer represent a normal and functional structure, while the larger spaces are due to a defect in calcification.

A curious condition which the author has met with

several times in dentine is shown in fig. 123, previously referred to, where a transverse dentinal tube anastomosing with several normally-directed longitudinal ones is seen. It is very difficult to account for this condition, but in one unerupted human premolar a similar arrangement of the tubes was seen in many places around the circumference of the pulp.

The Dentinal Tubes. As seen in a dry section, the tubules of the dentine arise by open ends at the periphery of the pulp cavity and gradually become narrower as they extend

Fine branching of the tubes.

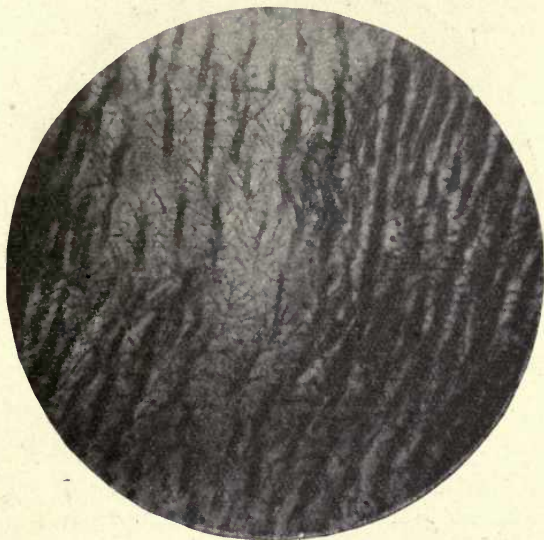


FIG. 147. Branching of dentinal tubes (silver pyridin). ($\times 150$.)

throughout its substance, terminating at the cement and enamel margins in very fine subdivisions or branches. These fine branches are, however, not confined to the terminations of the tubes, but suitable stains show their presence in all parts of the dentine (see figs. 147-151). Referring to these fine ramifications of the dentinal tubules, Röse says (19) that at the edge of the dentine the ramifications represent a true dichotomous branching of the dentinal tubes, and that this occurs but rarely in the portions of the dentine nearer to the pulp; in the preparations from which the accompanying illustrations are taken such a termination of the tubes

is, however, frequently seen. He considers that this dichotomous branching (fig. 124) represents the 'real branching of the protoplasmic dentinal fibres—formed by the fusion together of the dentine processes of the young odontoblasts so as to form a single process', and that they have no similarity to the very delicate connecting branches between the dentinal tubules (shown in figs. 147, &c.); these he considers are not lateral outgrowths of the dentinal fibril, but are the remains of the uncalcified ground substance

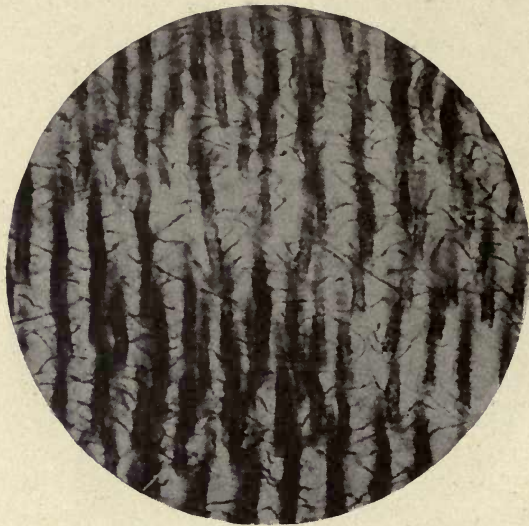

Fig. 148. Branching of dentinal tubes (pyridin and silver). ($\times 250$.)

or matrix of the dentine. A glance at the illustrations in the present work will, we think, afford convincing proof that these fine branches are connected with the dentinal tubes and emanate from them. In the specimens shown in Röse's figures the dentinal tubes only show short stunted branches, the Golgi method of staining not having brought out the finer extensions.¹ He further says, '*We look in vain for these connecting branches in sections of decalcified dentine, though the true terminal branches of the dentinal tubules are all the more distinct*'. The specimens here shown are,

¹ As stated elsewhere, the author considers that the method of Golgi, excellent as it is for many tissues, is not applicable to the study of dentine.

however, all from decalcified teeth except fig. 151, which was taken from a ground section. In ground sections the author has found that the finer branches cannot be brought out in the same preparation in all parts of the dentine as they can in the decalcified sections. Röse states that in transverse sections the branches cannot be seen to communicate with the dentinal fibril, but figs. 149 and 150, where the tubes are seen cut transversely, distinctly show that they can be seen to do so. As the stain penetrates these ramifications



FIG. 149. Branching of dentinal tubes (silver pyridin). ($\times 250$.)

uninterruptedly there seems very strong evidence that they contain fine subdivisions of the protoplasmic fibril. It is difficult to explain the origin of these fine divisions, but it was supposed by Von Ebner and Kölliker that they arise secondarily by an outgrowth from the dentinal fibril. Waldeyer considered that they were the connecting bridges between the odontoblasts, but Röse says he has never succeeded in demonstrating these connecting bridges, and that 'nowhere in the animal kingdom has such a phenomenon been observed as a process of a connective-tissue cell giving off numerous lateral branches in the form of a feather'. Despite these objections, and whatever may be the explanation of the origin and formation of these delicate

offsets from the dentinal tubes, the evidence that they exist and arise from the tubes is, we think, not capable of contradiction. In fig. 124 the fine terminations are seen at the cement margin of the dentine, and in the photograph of the ground section (fig. 151) they are seen just beneath the enamel. The decalcified sections afford very beautiful microscopic objects, especially under a low power, the ground substance being everywhere traversed by these delicate ramifying processes passing in every

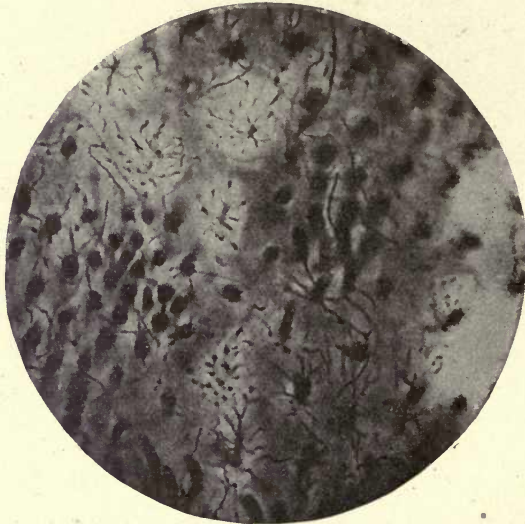


FIG. 150. Branching of dentinal tubes. Transverse section (silver pyridin). ($\times 250$)

direction and seen in transverse as well as longitudinal section. In fig. 149 there is an appearance of very minute thorny projections bordering these fine branches. Both the ground and decalcified sections were made from teeth in which the soft parts had been retained and fixed in formol.

The tubes do not pass in a straight course from the pulp to the margin, but in an undulatory manner, and the curves or undulations are seen to be both short and abrupt and longer and more open. The long undulations are called the 'primary curvatures' and the shorter ones the 'secondary curvatures'. This appearance of curvature is due to the

Primary
and
secondary
curva-
tures.

more or less spiral course of the tubes, but the degree of curvature varies very greatly in different teeth and in different parts of the same tooth. This arrangement of the tubes gives rise to an appearance in the dentine described as Schreger's lines. These lines are parallel with the surface contour of the dentine, and are due to the primary curvatures of the tubes coinciding with one another in the thickness of the dentine.

Schreger
lines.

The contour lines of Owen also describe markings due

Contour
lines of
Owen.



FIG. 151. Branching of dentinal tubes just beneath the enamel (silver pyridin). Ground section. *g*. Interglobular space. ($\times 250$.)

to the same cause, and others due to the presence of rows of interglobular spaces which occur in great abundance in the teeth of Cetacea and in the ivory of the Elephant's tusk.

In some places tubes are seen to terminate in branches within the substance of the dentine (figs. 124 and 147).

In transverse sections of dry dentine the tubes appear as round holes within the matrix with a strongly-marked surrounding border giving them the appearance of rings (fig. 152). This appearance, however, is somewhat deceptive, even very thin sections having an appreciable thickness. The appearance may be due to this fact, and the double

contour may not indicate a distinct wall to the tube.¹ The existence of such wall to the tube is denied by some observers, and considerable controversy has arisen as to the exact structure, and the relations of the dentinal tube, matrix, and dentinal fibril within the tube. Most authorities, however, consider there is a distinct lining substance to the tube—the sheath of Neumann (16). This is considered to be of the nature of a tissue on the borderland of calcification; it is indestructible by strong acids and remains, after thorough

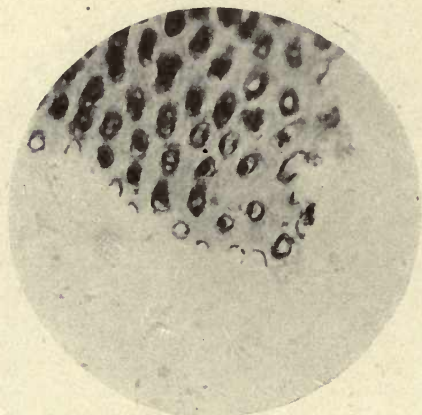


FIG. 152. Human premolar. Transverse section (silver pyridin). Showing stained sheath of Neumann. ($\times 800$.)

destruction of the collagen basis, as a confused mass of fibres consisting of elastin (C. S. Tomes).

The den-
tinal fibril
and
sheath of
Neumann.

In living dentine the tubes are occupied by a soft fibril, the dentinal fibril, which is a prolongation of the substance of the odontoblast cell in the pulp. The dentinal fibril was first described by Sir John Tomes (21). It is accompanied within the tube by one or more neurofibrils prolonged from the nerve-end cells in the pulp, which course with it throughout the dentine. The neurofibrils are not visible in dentine when stained by ordinary methods, but are only revealed by the employment of special methods of staining. As stated above, various opinions have been held as to the exact

¹ In caries of the dentine an extraordinary amount of thickening of the tube wall is often seen.

relations of the dentinal fibril to the tube of the dentine. Römer considers that there is no definite wall to the dentinal tube, which is merely an interval or channel in the matrix : he thus does not acknowledge the existence of the sheath of Neumann as a definite structure. He considers the so-called Neumann's sheath to be a part of the soft fibril, and that in the preparations in which it is claimed that the sheath is stained, what is really stained is the outer surface of the soft dentinal fibril. He shows a figure in the illustrations to his paper on the subject in which, in transverse section, the fibril has fallen out, and there is a perforation in the dentine with no wall to it. Judging by the illustration it would seem that in this instance the fibril only is stained, and the sheath not, as the author has several preparations which show an outer ring enclosing another dark-stained ring which is the border of the dentinal fibril.

In these preparations stained by a modification of the silver nitrate method of Ramon y Cajal, the sheath of Neumann is stained a deep black, and the dark-stained fibril is seen lying within the ring, an appearance which cannot be explained on the assumption that the supposed sheath is the outer border of the stained fibril (fig. 152). In this photograph it is to be seen that at the thinned-off margin of the section the segments of circles are visible, surrounded by a thin black line, and at the margin of these segments this thin line is seen to project from the dentine, indicating that it is a firm substance not connected with the fibril and firmer than the surrounding matrix substance.

A very elaborate examination into the minute structure of dentine has lately been undertaken by Professor Hana-zawa of Tokyo (11). He made use of very many different reagents and methods of staining, and concludes that the wall of the dental tubule has no special resistance to acids or alkalis, and cannot be isolated, and it is unreasonable to call it a sheath, and that the fibrillar substance isolated by mechanical and chemical methods is the dentinal fibril and not the sheath of Neumann. A strong argument, however, for the view that this residue consists of Neumann's sheath is found in the fact mentioned by Tomes, that a tooth section boiled in a caustic alkali or allowed to putrefy still

shows the dentinal sheaths, but, as stated by Kölliker, the fibrils cannot be seen. Hoppe (10) and others have also demonstrated it in fossil teeth, where it is quite certain that no protoplasmic material can be present.

Römer considers that the dentinal fibril or process of the odontoblast is tubular and contains a fluid or semifluid substance, but his description of this hollow fibril as the dentinal tubule is, we think, singularly unfortunate and leads to much confusion. The nerve fibres which he describes as entering the dentine he thus considers run *within* the tubular dentinal fibril. For the history of these different views and the full literature on the subject the reader may be referred to the original paper (18). From this and other observations on the structure of the tubes and fibril the following would appear to be the best-established views of these structures. The odontoblast cell is provided with a process, the dentinal fibril, which enters the dentinal tube. This process is a prolongation or extension of the protoplasm of the cell, and carries with it into the dentine an extension of the delicate cell membrane which invests the odontoblast cell. This enclosing membrane stains, according to Hanazawa, with hæmatoxylin, but the fibril cannot, we think, be accurately described as a tube, but simply as a protoplasmic process with a slightly denser, stainable outer layer. The fibril does not, judging from appearances, entirely fill the tube, but there is a slight space around it along which fluids can pass.

The lining of the dentinal tube along which this fibril passes would appear to be of a distinctly different consistence to the rest of the matrix, and it colours with basic stains and with silver nitrate. This lining, usually described as the sheath of Neumann (and not considered to exist by Römer), is shown by Hanazawa to be present, but he says it is *not* unusually resistant to acids, thus differing from Neumann, Tomes, and others.

The substance which is isolated after the dentine matrix has been destroyed by strong acids he considers to consist of the dentinal fibrils themselves, which he says show more resistance to acids than the walls of the tubes. He describes the fibril as nearly filling the dentinal tube, only a very slight

interval being perceptible between it and the tube wall, and that acids do not cause contraction or shrinkage of the fibril. He also describes slight enlargements of the fibril at the points where processes are given off to the finer divisions of the tubes.

The dentinal fibril contributes delicate protoplasmic offsets to the branches of the dentinal tubes which also contain the finer subdivisions of the neurofibrils.

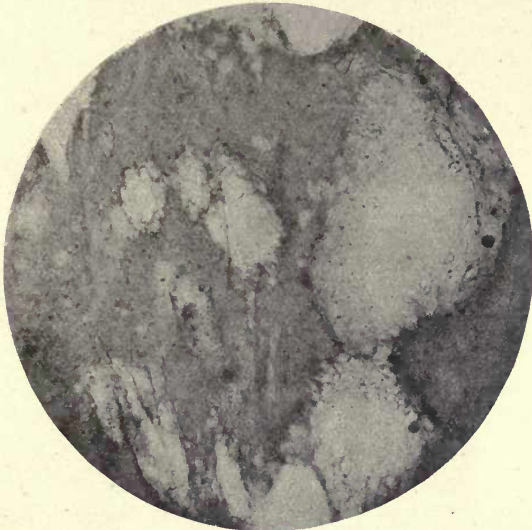

FIG. 153. Calcified deposits in pulp, showing incorporation of connective-tissue fibres and cells. Compare with fig. 206 showing calcification within connective tissue of the follicle. ($\times 150$.)

Secondary Dentine. Erratic deposits of calcified substance are occasionally found in the pulp, the cells of the pulp taking on a calcifying function. This deposit may appear as detached masses or as an incremental deposit upon the inner surface of the already formed dentine. The latter form, called by Hopewell Smith adventitious dentine, is frequently found to be formed as a protection against the approach of caries.

The detached masses (fig. 153) are round, oval, or irregular in form; they sometimes appear to be tubular, but the arrangement of the apparent tubes is not uniform as in

normal dentine, but they are collected into bunches or extend as radiating irregular prolongations. This deposit may apparently take place as a normal physiological process, but is usually a pathological one, more or less associated with degenerative changes. We know that calcification may take place in any degenerating tissue deprived of its natural blood supply, as occurs in many tissues and organs under such conditions.

Secondary deposits in the pulp cavity are met with

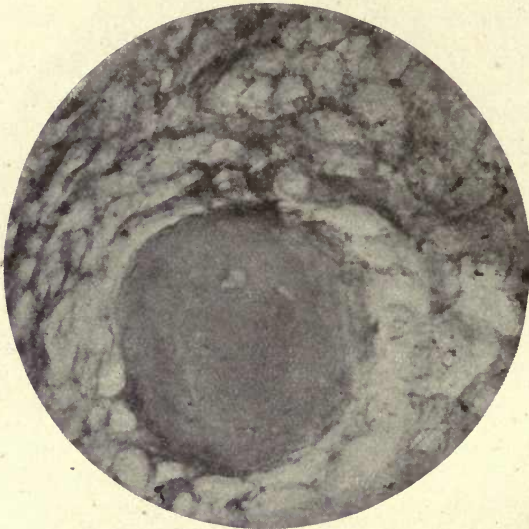


FIG. 154. Pulp stone in Elephant's incisor showing incorporation of connective tissue. ($\times 350$.)

in great frequency in other Mammalia, and may partake of the characters of osteo- or vaso-dentine. In the Elephant, where the pulp cavity of the tusk has been injured, the deposit of the secondary nodules is an attempt at repair by the active cells of the pulp, and results in the formation of numerous rounded, often concentrically marked bodies, which frequently are seen to be fused into a larger mass (fig. 154).

The author has shown (15*a*) that in the Elephant these masses of calcified matter in the pulp are calcified within a very evident connective-tissue stroma.

The odontoblasts in old age atrophy and disappear, and sometimes the whole pulp is occupied by dense connective tissue in which no cells, blood-vessels, or nerves are to be seen. The pulp may also undergo fatty degeneration.

Vascular canals are occasionally seen in human dentine, especially in the root portion of the tooth.

Plicidentine. The ultimate structure of plicidentine is similar to that of ordinary orthodentine, but the pulp chamber, instead of being of a simple form and occupying the

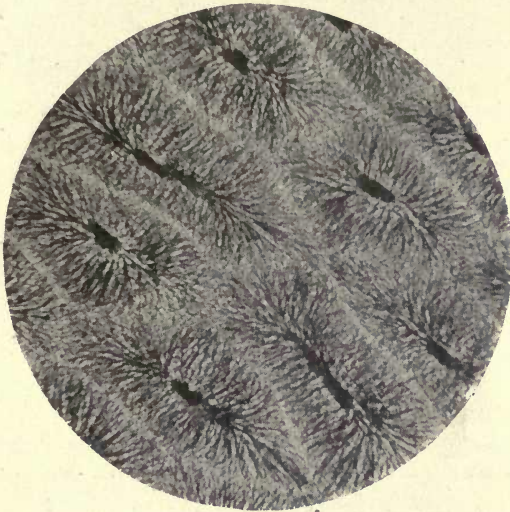


FIG. 155. Transverse section of plicidentine tooth of *Zygodontis*, showing intercommunicating tubes of the columns radiating from the pulp cavities. (250.)

centre of the tooth, is folded upon itself, each portion of the pulp having its separate system of radiating tubes, the intricate foldings so produced forming a very complicated pattern in many of these teeth (fig. 155). There may be a central pulp cavity which sends out offshoots to the different portions of the folded dentine, forming a star-shaped figure as seen in *Lepidosteus*, or as in *Lepidosteus spatula* there may be no definite central pulp cavity but the position of this central portion is occupied by numerous small radiating systems of tubes around small ingrowths of the pulp. Around this central system are long processes of

dentine in which the tubes are given off from the foldings of the pulp, as Tomes says, 'like a paddle-wheel'.

These radiating portions are sometimes branched and subdivided, showing a still more complicated pattern, and the effect of a convoluted tubular system is given as in the fossil *Labyrinthodon* (fig. 56).

As shown by Tomes there are two systems on which plicidentine is formed: one in which the foldings may be described as lateral, as in the lizard *Varanus*, in the bony pike, *Lepidosteus*, and in *Labyrinthodon*, and another

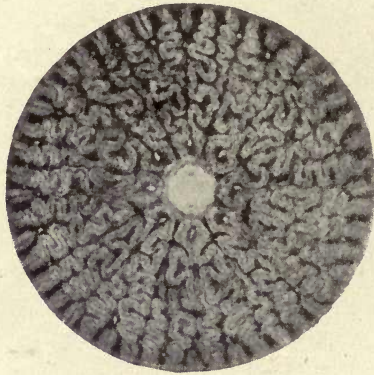


FIG. 156. Transverse section of tooth of *Labyrinthodon* showing highly convoluted plicidentine. Reduced from Owen's *Odontography*.

in which parallel vertical columns of the pulp give rise to radiating dentinal systems around them, these systems lying side by side and the terminations of the tubes of one system often communicating with those from neighbouring columns (figs. 157 and 158).

This latter structure is seen in the Rays, *Myliobates*, and *Zygobates* (fig. 155), and in the rostrum of the saw-fish (*Pristis*) and in the teeth of the Cape Ant-eater (*Orycteropus*). In the lower part of the tooth in these animals the pulp is more or less fused by the union of the pulps of the separate denticles. 'Instead of being regarded as a plicidentine such a tooth might be said to be built up of a series of small, parallel, fused denticles, or exceedingly broadened and fused cusps.'¹

¹ C. S. Tomes, *Dental Anatomy*, 7th ed., p. 89.

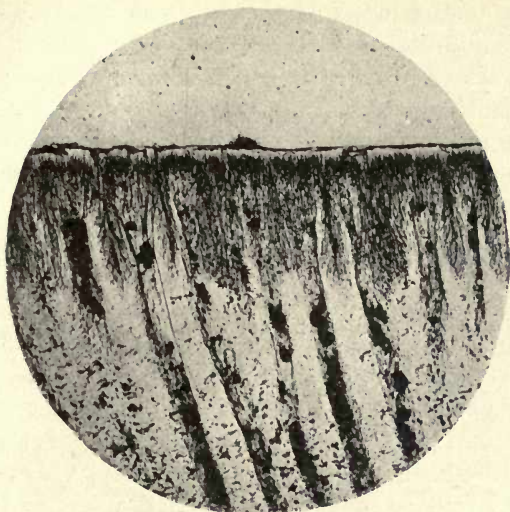


FIG. 157. Tooth of a tertiary fossil fish (*Aëtobatis*) showing the plicidentine in longitudinal section. From a specimen lent to the author by Mr. J. Humphreys.

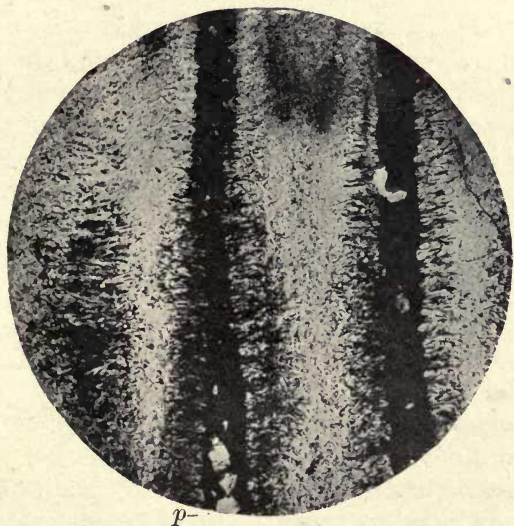


FIG. 158. Longitudinal section of plicidentine from the fossil eocene fish *Edaphodon*. From Mr. Humphrey's collection. *p*. Pulp cavity.

While we may look upon plicidentine as orthodentine in which the arrangement of the tubes is so modified as to produce a number of different and complicated patterns, the next variety of dentine which we shall consider has an altogether different structure.

Vasodentine. Vasodentine differs from orthodentine mainly in the fact that it contains no dentinal tubes, but their place is taken by a system of blood channels containing blood-vessels in connexion with the vessels of the tooth-pulp. These blood-vessels have a very definite and regular arrangement in typical vasodentines, blood corpuscles are seen within them, and the blood in life circulates through them.

‘The arrangement of the vascular canals is regular and striking, reminding one of the appearance of the vessels in an intestinal villus; in fact, an intestinal villus petrified, whilst its capillary network remained pervious, and red blood continued to circulate through it, would form no bad representation of a typical vasodentine tooth.’¹

Perhaps the most typical vasodentine is seen in the tooth of the Hake (*Merluccius*) (fig. 159 and Plate VI).

A strongly-marked lamination of the matrix parallel to the surface of the pulp cavity is very evident in these teeth, and that this is a structural condition is shown by the breaking up of sections of the Hake’s tooth into parallel laminæ. Thorn-like projections from the vascular tubes along the lines of the laminæ are also evident in many places (fig. 159).

The outer layer of the tooth in the Hake contains no blood channels and shows a faint indication of lamination. This layer is described by Röse as vitrodentine, but as this part of the dentine does not differ in structure or development from the matrix material which intervenes between the vascular tubes, Tomes does not consider that a distinctive name should be applied to it.

The vascular canals which do not enter this layer form loops at its inner boundary which sometimes communicate with a single peripheral channel in this situation (fig. 181).

In the flounder, at and near the tip of the conical tooth, the dentine is of the true orthodentine variety; but lower down

¹ C. S. Tomes, *Dental Anatomy*, 7th ed., p. 91.

scattered vascular tubes appear, and in the lower portion of the tooth there are no dentinal tubes, but a typical vasodentine has taken their place. From this, as Tomes says,¹ 'it may be learnt that hard dentine and vasodentine are not fundamentally dissimilar, and that they may pass into one another by imperceptible gradations, so that it cannot be said exactly at what point the name of vasodentine is to be given to it'. The teeth of the extinct *Megatherium* show a regular system of vascular canals on the inner portion of

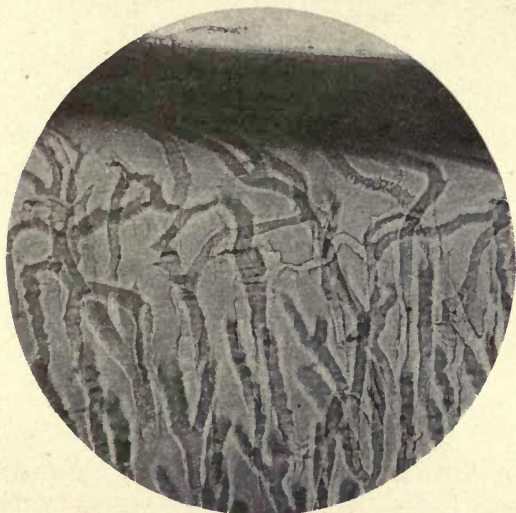

FIG. 159. Vasodentine of Hake (*Gadus Merluccius*) showing thorn-like projections and longitudinal striation of the matrix. ($\times 150$.)

the dentine terminating at a definite line, the rest of the tissue being made up of tubular or ortho-dentine. The outer part of the dentine of the Manatee shows forms which have the general appearance of vascular loops, but considerably modified by the encroachment of calcification upon them, the rounded contours of the margins suggesting a resemblance to elongated interglobular spaces (Tomes).

From the evolutionary standpoint the above observations are of considerable interest; it is an undecided question whether the ancestral form of dentine was of the tubular or vasodentine variety. They seem to exist side by side

¹ C. S. Tomes, *Dental Anatomy*, 7th ed., p. 94.

in very early forms, but in the higher Mammalia the tubular or ortho-dentine seems to have supplanted in most cases the probably more primitive vasodentine.

In *Sargus ovis* loops are seen within the dentine which appear to be the remains of vascular tubes, and may indicate that the dentine of *Sargus* was derived from a vasodentine. Similar loops at the base of the tooth in *Sargus* are evidently, in the author's preparations from freshly-fixed material, in communication with the pulp cavity, while isolated crescentic forms are seen deeply in the dentine. In ground preparations

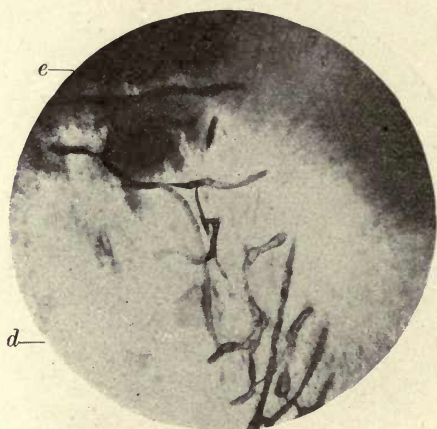


FIG. 160. Vascular network in centre of incisor tooth of *Sargus ovis*. e. Enamel; d. dentine. Ground section. ($\times 150$.)

of similarly preserved incisor teeth of *Sargus*, what certainly appear to be vascular canals are seen passing out from the narrow prolongation of the pulp cavity in the crown and forming a branched network which reaches up to the enamel (fig. 160). This was found in all the teeth examined, when they were so cut as to expose the central part of the axis of the tooth, and this branching system appears to be confined to this area and to extend in a direction parallel to the flattened surfaces of the tooth. Again, in *Scarus*, loops having every appearance of being vascular tubes are seen in abundance in the dentine, and at the enamel margin they distinctly project into the enamel (fig. 161).

In the teeth of the Tasmanian Devil (*Sarcophilus ursinus*) of which a good preparation, preserved in formol, was

given to the author by Dr. Mackenzie, not only scattered crescentic loops are found in the deeper parts of the dentine, but in several places around the circumference of the pulp channels are seen in the dentine communicating with the pulp, and blood-vessels enter them, the endothelial cells and blood corpuscles being evident within the canals in the dentine. The blood-vessels can be traced along the pulp and seen to cross the odontoblast layer and enter the tubular canals, which penetrate some little distance into the dentine. As, however, these vascular canals pursue a very

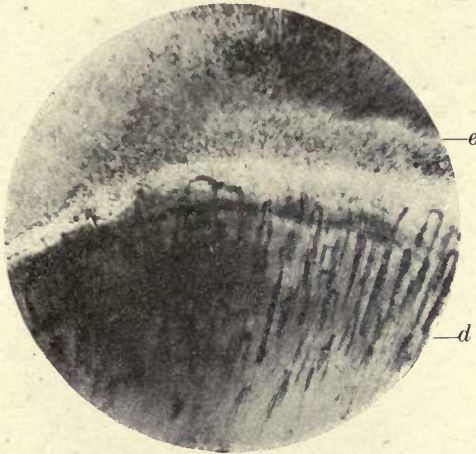


FIG. 161. Vascular loops in tooth of *Pseudoscarus*. *e*. Enamel; *d*. dentine. Ground section. ($\times 150$.)

twisted course, more deeply in the dentine only portions of them are seen, cut across (fig. 162).

In the *Cynomys* (Prairie Marmot) (fig. 163) the author found the dentine to be permeated by vascular canals in great abundance. He has not been able to find any record of the previous observation of this condition in *Cynomys*, but it is very evident in ground sections of the incisor and can scarcely have failed to be detected. Short vascular canals in the dentine of many rodents are described by Owen (17) and J. Tomes (21 *b*).

From these observations we see that the most permanent and highly developed form of dentine would appear to be tubular or ortho-dentine, and that in the course of develop-

ment to higher forms the vasodentine structure has gradually disappeared, only existing here and there as vestiges ; but in *Sarcophilus* and *Cynomys* there would appear to be a more complete indication of reversion to the original structure.

A similar argument applies to the tubular enamel of marsupials, where we see a reduction of the tube system even in the same class of the mammalia, until in the Wombat it has ceased to be apparent, but in *Hyrax*, *Dipus*, and *Sorex*

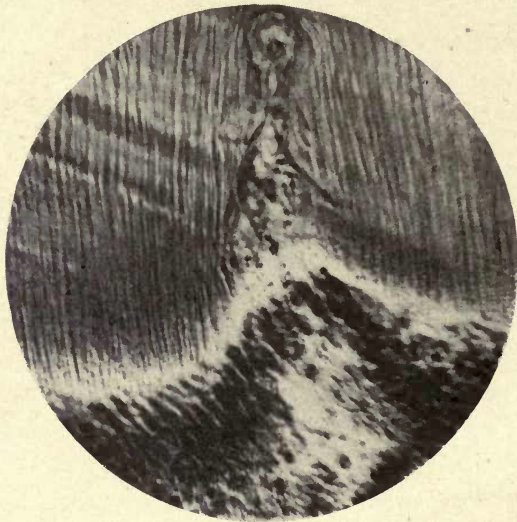


FIG. 162. Dentine of *Sarcophilus ursinus*. Capillary vessels entering dentine. ($\times 350$.)

among the higher mammalia we find a more or less complete reversion to the original tubular enamel, and in man and other mammals a slight penetration by tubes shows that all traces of such a condition have not been finally lost.

Osteodentine or Trabecular Dentine. Osteodentine is very nearly allied to bone in structure. There is no distinct pulp cavity, but the interior of the tooth is traversed by bony trabeculæ, the interspaces being occupied by medullary canals and blood-vessels which may be considered to take the place of the pulp. The large medullary channels at the base of the tooth divide and ramify like the branches of

a tree, spreading out on every side towards the circumference. In some sharks, and in the Pike, a more regular arrangement of these medullary spaces is seen at the periphery, giving this layer more the appearance of orthodentine; but the tubes do not enter at their bases into a pulp cavity, but are continuous with the main branches of the medullary system in the centre of the tooth as in *Lamna* (fig. 164).

If treated with alcoholic fuchsin (allowed to penetrate by

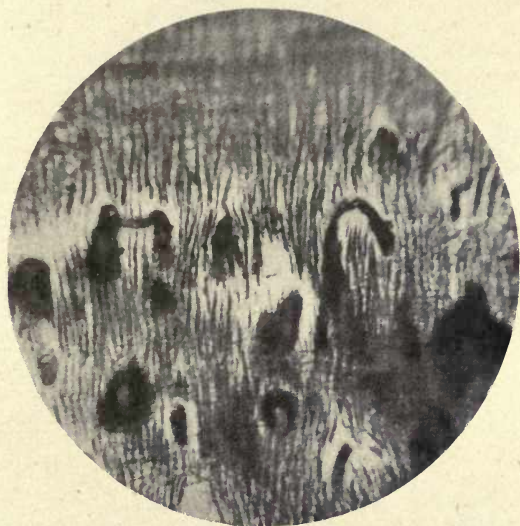


FIG. 163. Dentine of incisor of *Cynomys* (Prairie Marmot) showing vascular loops. ($\times 350$.)

capillary attraction) the structure of an osteodentine tooth is beautifully brought out, the stain penetrating into the very finest divisions of the branching processes, which resemble the canaliculi of bone (fig. 165).

In some examples of osteodentine the resemblance of the tissue to bone is much more marked than in the specimens shown in the illustrations, and traces of lamination are seen. 'The similarity of the channels of the pulp in osteodentine to Haversian canals in bone is in some respects close; so similar, that when teeth consisting of osteodentine become, as in many fish they do, anchylosed to the subjacent bone,

it becomes impossible to say at what point the dentine ends and the bone commences ; and this difficulty is intensified by the fact that the bone of many fishes lacks lacunæ and is almost exactly like dentine.'¹

The Development and Calcification of Dentine. As previously stated, dentine is developed from the mesodermic dentine papilla, which is a condensation of the cells of the mesoderm beneath the previously-formed ectodermic enamel-forming cells. As shown by Von Brunn (4), in several orders

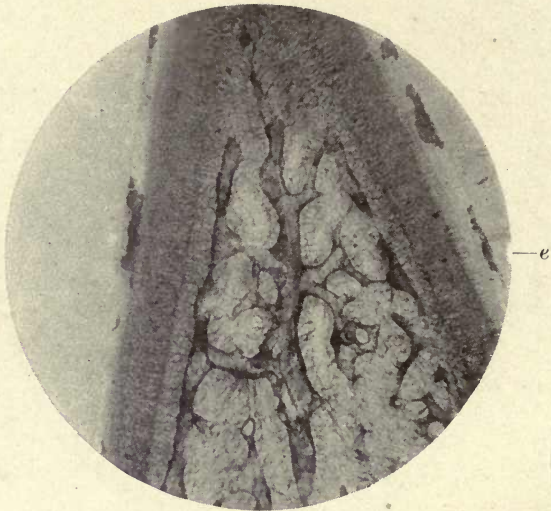


FIG. 164. Osteodentine tooth of *Lamna cornubica* (Porbeagle Shark). Osteodentine; central tubes radiating from medullary channels. *e*. Enamel. Fuchsin stain by capillary attraction. ($\times 50$.)

of the Mammalia the appearance of epithelial cells always precedes and appears to determine the formation and limits of growth of the dentine. Von Brunn and Von Ebner (6) were unable to substantiate the existence of this determining epithelial organ in the formation of the dentine of the root in man, but as explained in the chapter on 'The Tooth Follicle and its Connexions', the author has found a similar condition in human teeth. He has shown that this epithelial sheath proceeds from cells of the follicle which are not differentiated to form an enamel organ. This, however,

¹ Tomes's *Dental Anatomy*, 7th ed., p. 100.

will be more fully considered when treating of the 'Sheath of Hertwig'.

In teeth in which enamel is present, however, the formation of an enamel organ always precedes the differentiation of the cells of the papilla to form a dentine organ, although *calcification* in Mammalia commences first at the summit of the dentine papilla. In some fish the calcification of the enamel precedes that of the dentine, and in marsupials, although the process of calcification commences in the

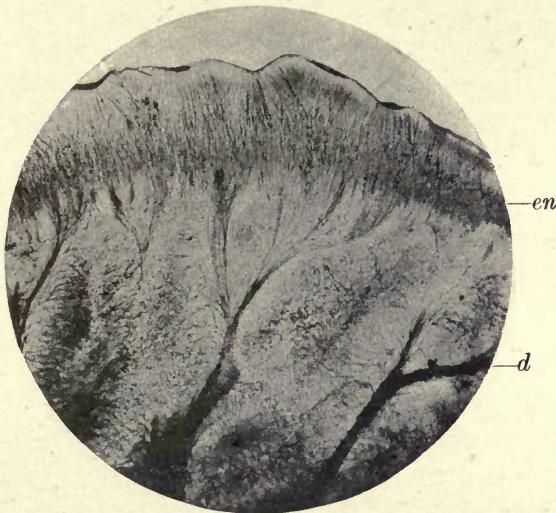

FIG. 165. Enamel and osteodentine of *Heterodontus* (*Cestracion*).
Fuchsin stain by capillary attraction. ($\times 50$)

dentine, a very much larger proportion of enamel is soon laid down above it; this enamel, however, is not at this stage fully calcified.

When the dentine papilla is first seen to form a definite dentine organ or tooth-pulp, and is enclosed above and at the sides by the prolongation of the enamel organ, there is no differentiation of the connective-tissue cells to form a distinct peripheral layer beneath the enamel organ, but they are uniformly distributed throughout the pulp.

Very soon, however, larger rounded cells are seen accumulating at the margins of the pulp. These cells have large nuclei and a very small amount of cytoplasm, and many have short truncated prolongations, but there is no appearance

of a distinct process as shown in fig. 115, &c. The connective tissue of the pulp is seen passing between these cells, which lie in its meshes. The rounded cells at the circumference soon assume a pyriform or subcylindrical form, and a long process extends from their upper end which develops into the dentinal fibril (fig. 166). These cells are described as odontoblasts. The first appearance of the dentine occurs in the form of a clear layer of a semi-transparent substance which borders the pulp and is in contact with the enamel

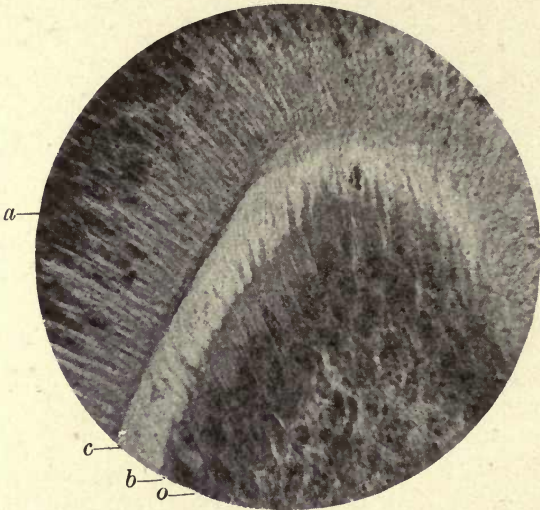


FIG. 166. Macropus. First commencement of calcification of the dentine at the coronal part of the pulp. *a*. Ameloblasts; *o*. odontoblasts; *c*. commencing calcification of the dentine; *b*. odontogenic zone. ($\times 650$.)

organ cells externally and with the now distinctly differentiated odontoblasts internally, and their dentinal processes can be seen passing across this area. A thin line of calcification commences with rounded contours towards the pulp, and is separated from the odontoblasts by the clear layer above described.

Two different views have been held as to the mode of formation and calcification of dentine. These may be called the 'conversion' and 'secretion' theories. For a long time the view most widely received and embodied in all the principal text-books was the conversion theory of Waldeyer,

Boll, and others, and upheld by C. S. Tomes in the earlier editions of his *Dental Anatomy*, where he says: 'The dentine is, I believe, formed by the direct conversion of the odontoblast cells just as the enamel is by the enamel cells, and is derived from them and from them alone.' Schwann also looked upon the dentine as being probably the ossified substance of the pulp, and Waldeyer, considering the process of ossification to be identical with that of ordinary bone, held that the dentinal fibrils are the central remains of the odontoblasts, while their peripheral portions become basis substance.

The other view, that of secretion, was held by John Hunter, who says, 'The ossified part of a tooth would seem to have much the same connexion with the pulp as a snail has with its shell'.

Kölliker, Lent, Hertz, and Baume looked upon the formation of dentine as a secretion process. Baume says: 'The odontoblasts secrete a material which calcifies, rather than that they themselves are converted.'

Tomes, in the later editions of his book, considers that the dentine is calcified by a process of secretion, and following the previous investigations of Von Ebner and others, the conversion theory of the formation of dentine has been to a great extent abandoned, this conversion theory being that the odontoblast cell becomes actually converted into dentine matrix, its centre remaining uncalcified as the soft fibril, and the rest of the cell forming in different degrees of calcification the Neumann's sheath and the matrix. The view held by the author and by numerous histologists at the present day is that the cells of the pulp secrete a material which calcifies, they themselves not entering into the calcified substance but receding farther and farther into the pulp as calcification advances, and the fibril becomes more and more elongated.

The Dentine Matrix. Professor von Ebner, in his paper in the *Handbuch der Zahnheilkunde*, 1891, described the resemblances of dentine to bone: he showed that in decalcified dentine (treated with hydrochloric acid in a salt solution) a fibrillar structure can be detected, and that by tearing the decalcified dentine the fibrillæ could be some-

times isolated. He describes these fibrillæ as being very fine, scarcely more than 5μ thick, and as showing the same characteristics as the glue-giving connective-tissue fibres, but they are not arranged in lamellæ as in bone. The fibres cross each other and mostly in planes perpendicular to the dentinal tubules. Von Ebner considered that these fibres were due to a change in the upper and peripheral portion of the odontoblast cell, and according to Röse's explanation of this view, in some cases 'the peripheral ends of the odontoblasts are first of all changed into a homogeneous layer of non-granular protoplasm in which the fibrils become visible only later'.¹ This author also says 'the dentinal fibrils are those remains of the cell bodies which are left when the odontoblasts are changed into gelatine-yielding fibrils, and which retain their protoplasmic structure'. According to this view there would be a gradual using up of the peripheral portion of the odontoblast cell as calcification advances, the layer of uncalcified dentine in the odontogenic zone being formed 'by the change of the peripheral portion of the odontoblasts into gelatine-yielding fibrils. The dentine calcifies by the deposition of salts of lime *between* the fibrils.' In fig. 167 delicate fibres are seen crossing the odontoblasts and entering the odontogenic zone which certainly appear to be fine fibres from the pulp, and in fig. 168, from the tooth of a calf treated with chromic acid, fibres can be seen crossing the odontoblasts and entering the odontogenic zone.

The author has but lately found further corroboration of his view that connective-tissue fibres prolonged from the tissue of the pulp enter the dentine and form its fibrillar basis as explained on p. 268.

It appears possible that a portion of this fibrillar foundation substance, forming the odontogenic zone, may be laid down by the odontoblasts as Von Ebner describes; but many

¹ Röse, in his paper above referred to, says: 'As Partsch *correctly remarks*, Mummery has examined pathologically changed human teeth or unfavourably preserved preparations.' This assumption of Professor Partsch endorsed by Röse is made without any evidence, he never having seen the preparations or made any inquiry concerning them. Such a method of criticism needs no further comment.

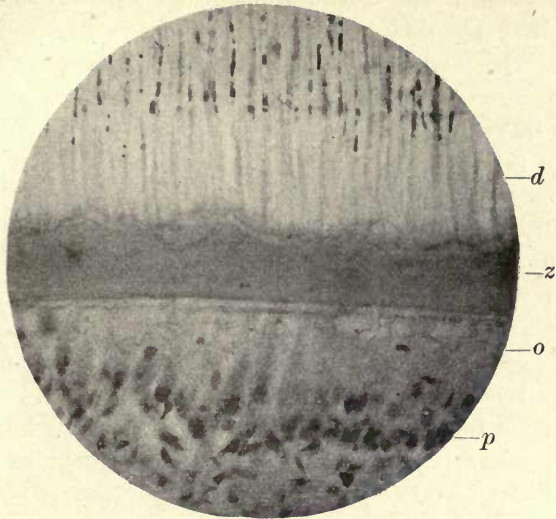


FIG. 167. Human premolar. Weil process, showing the fine connective tissue investing the odontoblasts. *d.* Dentine; *z.* odontogenic zone; *o.* odontoblasts; *p.* pulp. ($\times 250$.)

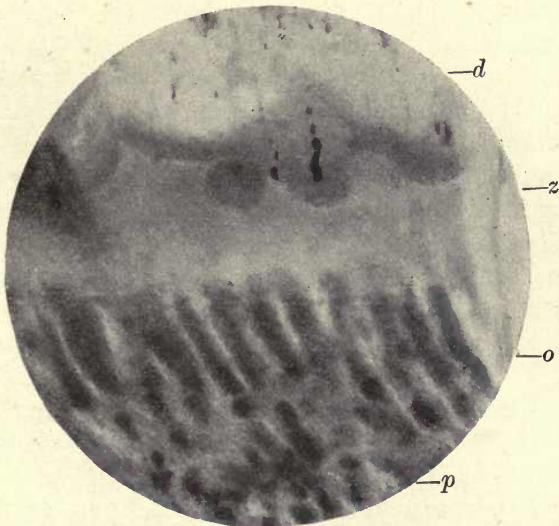


FIG. 168. Tooth of Calf. Ground section, by the Weil process, showing fibres between and around odontoblasts becoming incorporated in odontogenic zone. *d.* Dentine; *z.* odontogenic zone; *o.* odontoblasts; *p.* pulp. ($\times 400$.)

preparations of the author's suggest that this zone is also penetrated by delicate connective-tissue fibres from the pulp (15 a). The opinions of such an authority as Professor von Ebner, who has studied this subject for many years, must always be received with the greatest respect.

Klein (12 a) held that the network of reticular tissue in the substance of the odontoblasts is the reticular basis of the dentine matrix, which would be thus an intracellular substance.

The author in a paper published in 1892 (15 a) showed that connective-tissue fibres *from the pulp* pass into the forming dentine, and considered that the fibres seen in its substance are the incorporated connective-tissue fibres of the pulp which thus form a meshwork or foundation in which calcification takes place. The fibres are intercellular and not intracellular as considered by Klein.

As described in this paper, in preparations cut by the Koch-Weil process and consequently not decalcified, processes were seen springing from the dentine and blending with the connective tissue of the pulp all around the margin of the pulp cavity. These processes have the appearance of connective-tissue bundles partially impregnated with lime salts.

At the inner margin of the dentine they are seen to spring from its substance in a direction more or less parallel to the surface, these horizontal bundles of fibres blending together into larger bundles at right angles to the surface of the dentine, much as the spreading roots of a tree coalesce to form its trunk. These bundles, the high refractive index of which suggests their partial calcification, are plainly seen to be continuous with the general connective tissue of the pulp. One is reminded, in looking at these larger processes, of the similar appearances in the formation of bone in membrane, where spiculæ are seen shooting out in advance of the calcified substance (figs. 169 and 170).

At the apex or coronal portion of the pulp cavity these processes are more slender, form wide open loops, and can be traced for some distance into the pulp.

In sections cut somewhat obliquely (not in the same plane as the odontoblasts) there is an appearance of small deeply-

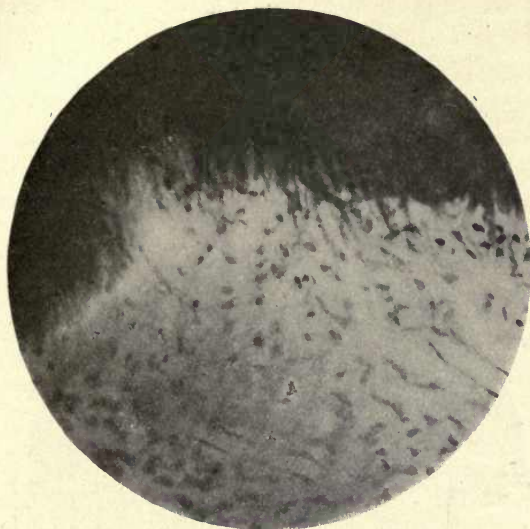


FIG. 169. Inner margin of pulp of human tooth. Large bundles incorporated in dentine. ($\times 350$.)

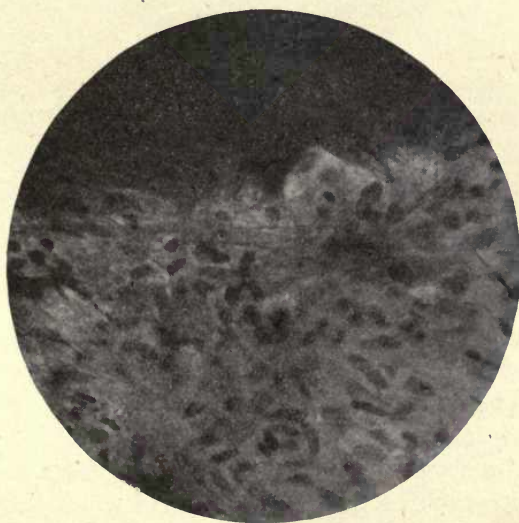


FIG. 170. Similar to fig. 171. ($\times 350$.)

stained cells or cell nuclei crowded upon and following the course of the bundles of connective-tissue fibres above described.

These cells are distinctly smaller than the odontoblasts, so that one would conclude that among the odontoblasts are other cells which play an important part in dentine development but are not arranged in a definite layer. The author has since shown that these cells are not destitute

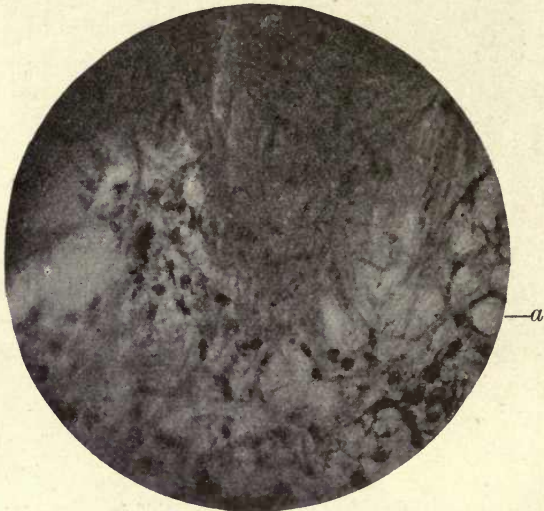

FIG. 171. Human premolar. Margin of pulp cavity. *a.* opposite a stellate connective-tissue cell sending processes into the forming dentine. ($\times 350.$)

of processes as stated in his paper, but a differential connective-tissue stain shows long processes proceeding from them and a very definite amount of cytoplasm around the nucleus (fig. 171).

In sections cut in the plane of the odontoblasts, where these larger fibre bundles are not present, a distinct reticulum of fine connective-tissue fibres can be seen passing between and enveloping the odontoblasts, and by careful focusing they can be seen to be gathered into bundles and incorporated with the matrix substance out of which they appear to spring. The small elongated and irregular-shaped connective-tissue cells are seen mingled with the onto-

blasts. It is difficult to trace these fine fibres within the clear odontogenic zone, but in the tooth of the calf kept for a long time in chromic acid they are very distinctly visible (fig. 168). These observations were very clearly corroborated by the examination of sections of the incisor teeth of a rat prepared by the Weil process. A very strong connective tissue is seen in the pulp, and an open-meshed reticulum of connective-tissue fibres at the margin of the dentine surrounded by small cells similar in appearance to those of the main substance of the pulp. In these specimens the fibres can be clearly traced into the formed dentine.

It has been recently stated¹ that the author has receded from his view of the part taken by the odontoblasts in the calcification of the dentine, as expressed in his paper in 1892 (15 a), and it is made to appear that he did not then look upon the odontoblasts as the calcifying cells; but in that paper he speaks of the dentine as a tissue 'which, according to the view of secretion here maintained, is a material *elaborated by the odontoblasts and other cells, upon a connective-tissue foundation*'. He never considered the odontoblasts to have any but a calcifying function, but considered that other small cells found in the pulp *also* took some part in the production of the matrix, and recent observations, as shown in fig. 171, have confirmed him in that conclusion. Nowhere in the paper referred to or elsewhere has he denied the principal part taken by the odontoblasts in the calcifying process, and never at any time has he considered that sensation was conducted by the dentinal fibril, as this criticism might appear to suggest.

In the rat the fibrous strands are very distinct within the formed dentine, forming a band of a slightly darker appearance than the rest of the dentine and fading away in the deeper parts of the tissue approaching the enamel (fig. 172).

The incorporation of connective-tissue fibres in the forming dentine of the Elephant is very evident (fig. 173), and, as described in considering the development of vasodentine, a very abundant connective tissue is incorporated in the tooth of the Hake, showing that in fish, as well as in several orders of the Mammalia and in man, connective tissue forms a framework or basis to the dentine (fig. 181).

Von Korff in 1905 published a paper (13) in which he

¹ A. Hopewell Smith, *Normal and Pathological Histology of the Mouth*, vol. i, p. 290 (1919).

showed that in early stages of the development of dentine there was a penetration of pulp fibres between the odontoblasts, and argued that this indicated that the dentine was not a product of the odontoblasts but was formed by the connective tissue of the pulp. The fibres described by Von Korff in the early development of the dentine are arranged in a corkscrew-like form, terminating in the forming dentine in a fan-shaped expansion of fibres (fig. 174). He claimed in this paper that he was the first to describe connective tissue in the dentine, but as Von Ebner points out, he had

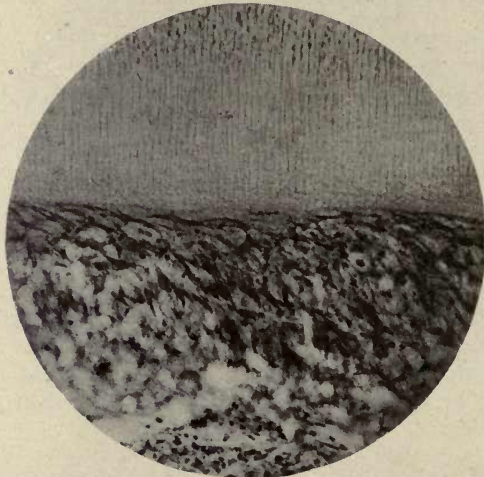


FIG. 172. Pulp and dentine of Rat showing incorporation of connective tissue in dentine. ($\times 175$.)

himself described it thirty years before and, as he states, it had also been demonstrated by Gebhart, Ramon y Cajal (1888), and Mummery (1892).

Guido Fischer (7), writing in 1910, says that while he was at first inclined to agree with Von Korff's theory, he cannot accept this author's conclusions. While pulp fibres are evident in developing dentine, as had been pointed out by previous authors, he does not agree to this interpretation of them as dentine producers, and agrees with Von Ebner that the collagen fibres of the dentine substance are arranged at right angles to the dentinal tubes, that they are not gelatine yielding, and do not show double refraction.

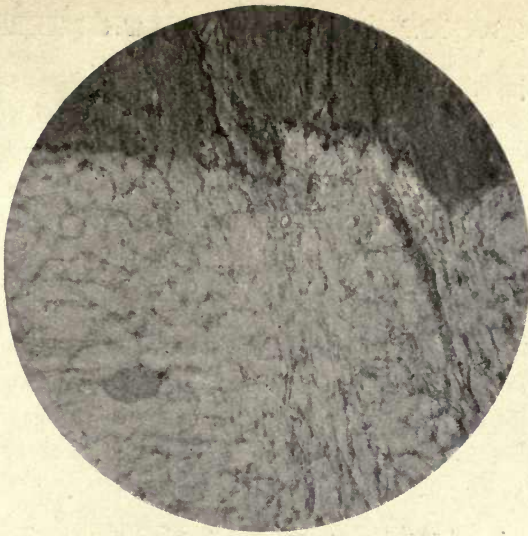


FIG. 173. Incorporation of connective tissue of pulp in ivory of Elephant's tusk. ($\times 100$.)

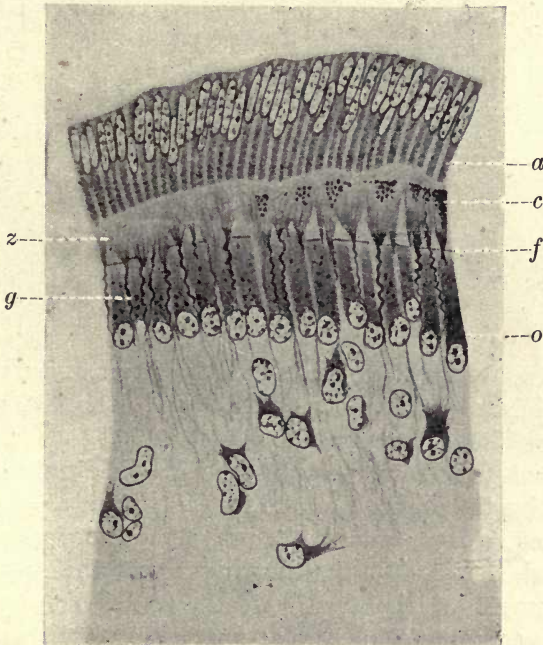


FIG. 174. Fibres of Von Korff in tooth germ of Cat. *o*. Odontoblasts; *f*. fan-like expansion of fibre bundles; *g*. corkscrew-like fibres; *z*. odontogenic zone; *c*. commencing calcification; *a*. ameloblasts. (From illustration to his paper.)

There is, we think, no doubt that bundles of connective-tissue fibres, which pass into the dentine as Von Korff describes, are to be seen in developing teeth, but, as Von Ebner says, they do not course parallel to the dentinal tubes as claimed by Von Korff, but pass within the dentine generally at right angles to the tubes. These corkscrew-like bundles of connective tissue are occasionally seen in the pulps of fully erupted teeth (fig. 175).

Studnicka adduces, as an example of the share of the pulp in dentine formation, the fibre bundles occasionally observed in growing dentine, which are identical in appearance with

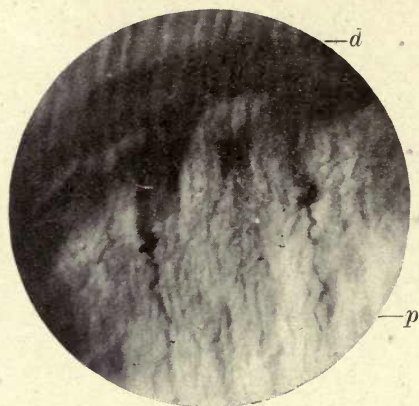


FIG. 175. Corkscrew-like fibres in human permanent tooth.
d. Dentine ; *p.* pulp. ($\times 250$.)

those described by Von Korff in early stages of development, and which are more to be compared with the Sharpey fibres in bone. Von Ebner considers that the fact that in the later stages of dentine formation gelatine-yielding bundles of connective tissue incorporated in the dentine are to be seen, which, as he says, he and the present author independently observed, has no direct bearing upon the typical first development of the dentine. He also looks upon these gelatine-containing bundles as analogous to the penetrating fibres of Sharpey.

The fibres described by Von Korff in developing teeth are not gelatine-yielding fibres and do not show double refraction, and we must conclude they are to be looked upon

as matrix or foundation fibres in which the lime salts are deposited by the agency of the odontoblasts.¹

That connective-tissue fibres from the pulp in young teeth with uncompleted roots are sometimes seen passing in a radiating manner into the dentine is shown in fig. 171. The specimen from which this photograph was taken was stained with Van Giesen stain, which brings out connective tissue very conspicuously. The fibres can be seen passing from the pulp and spreading out into the dentine; deeper within its substance they pass, not parallel, but more or less at right angles to the dentinal tubes. The appearance in these sections of small cells apparently in intimate relation with these fibres when the section passes in this direction is a little puzzling, as the odontoblasts are not visible as a distinct layer where these rows of cells are evident, although their nuclei can be seen in places lying between them. This appearance was illustrated in the author's paper of 1892, where he described the cells as being destitute of processes; a more selective connective-tissue stain has, however, since shown that a distinct cytoplasm surrounds these nuclei, and that processes of the cell are produced from it extending on every side (fig. 171 at *a*). In the later stages of dentine formation, when these penetrating fibres are seen in the dentine, they appear to be partially impregnated with lime salts in advance of the general line of calcification, and the question arises whether these smaller cells take any part in the calcification of the matrix.

In the paper above referred to the author expressed the opinion that 'These cells secrete a material which calcifies along the line of the odontogenic fibres', but it is very difficult to decide if this is the case or not.

¹ In the new edition of his *Histology* (1919) Professor Hopewell Smith says: 'It is probable that these connective-tissue fibres are considered by Howard Mummery to be the terminations of the myelinic nerve fibres of the pulp.' It is difficult to understand how any histologist could make such a mistake. V. Korff described these fibres only in young developing teeth at the very first commencement of calcification, and although a few are now and then to be met with in older pulps they are easily distinguished (see fig. 175). The nerve fibres shown by the author arise from unmistakable medullated nerve trunks, and moreover the fibres of V. Korff take the stain very differently and much more faintly in gold preparations.

Von Ebner says: 'Without doubt the odontoblasts are the essential and sole dentine formers in the growth of typical normal dentine; they are the gelatine-yielding cells as well as the lime-salt producers; under special conditions other cells of the pulp can, however, lay down a dentine-like substance.'¹

That calcification can take place in the pulp independently of the odontoblasts is seen in the formation of pulp-stones and irregular calcific deposit, and is consistent with what is shown of calcification in degenerations of connective tissues elsewhere.

A comparison of fig. 177, where the connective-tissue fibres of the periodontal membrane are entering the forming cement, with figs. 169 and 171 showing the incorporation of connective-tissue bundles in the pulp with the dentine, is interesting as showing the great similarity of the appearances in the two tissues.

To recapitulate:

Summary. (1) In the early development of the dentine, connective-tissue fibres from the pulp pass in bundles into the forming dentine in a more or less radiating manner, but they do not course, within the dentine, in a direction parallel to that of the tubes, but transversely to them. This incorporation of the connective-tissue fibres is not immediately connected with the *calcification* of the matrix. The fibres at this stage are not lime-containing and do not show double refraction, but they form an organic foundation or scaffolding in which calcification takes place.

(2) It is not only in the earliest stages of dentine formation that this meshwork of foundation tissue is laid down, but it also occurs throughout the active growth of the dentine, although in the later stage the fibre bundles have not the regular arrangement described by Von Korff in the early stages of development. Bundles of connective tissue are, however, evident, which are becoming incorporated with the forming dentine in later stages and appear to be analogous to the penetrating fibres of Sharpey in bone.

(3) In teeth in use, in which the first formation of root and crown is completed, but the cells at the circumference of the

¹ In a letter.




FIG. 176. Adult human molar affected by caries. Action of acids of caries, showing striation and contours as in figs. 178 and 179. ($\times 600$.)

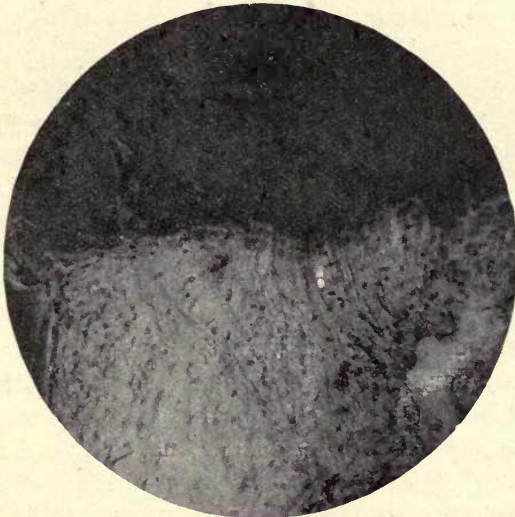


FIG. 177. Sharpey's fibres penetrating forming cement ; from the same tooth as that from which figs. 170 and 171 were taken. ($\times 350$.)

pulp are still depositing the dentine, delicate connective-tissue fibres from the pulp are continuously being incorporated with the forming dentine.

There seems to be every reason to believe that the principal active agents in the separation and deposition of the lime salts are the odontoblasts, and that they shed out their product into the organic framework laid down to receive it, and according to Von Ebner also contribute a delicate fibrillar foundation to the matrix substance.

Calcification of the Dentine. In young growing teeth there is a portion of the matrix bordering on the pulp forming a marginal band between the calcified dentine and the odontoblast cells. This layer, the odontogenic zone, shown in figs. 167 and 168, appears to consist of the collagenous basis substance of the dentinal matrix in which the deposit of the lime salts takes place. The uncalcified portion of the matrix, in teeth that have not been treated with acids, unlike the calcified part, takes the stain readily, and the advancing calcification is seen encroaching upon it in the form of rounded masses of the lime salts, or calcospherites, some of these calcospherites lying free in the surrounding uncalcified material (fig. 143). The spherites in this advancing layer are seen to be quite clear and to exhibit no radial or concentric markings in the calcified preparations.

When a young tooth is decalcified, the rounded contours of the calcifying border have exactly the same appearance as in the calcified tooth; they appear structureless and consist of the calcoglobulin basis of the spherites, which takes stains readily. The interglobular spaces in imperfectly-developed dentine show also very clearly the advance and coalescence of these bodies in the basis substance.

In some sections prepared by Ramon y Cajal's silver-nitrate method, and which were taken from an unerupted human premolar, a further stage in the consolidation of the matrix is revealed which appears to throw a strong light on the mode of calcification of dentine, and to make clear the meaning of certain appearances in the adult tissue which had not received a satisfactory explanation.

At the borders of carious cavities, a fine striation, very much like muscle striation, is seen in the dentine in some

cases, where the action of the secreted acid has been in considerable advance of the invading micro-organisms. An examination of the silver-stained developing tooth shows that this appearance is due to structural conditions which have been revealed by the action of the acid (fig. 176).

As previously stated, the calcospherites seen at the margins of human dentine appear clear and structureless, but it was pointed out by Rainey, referring to the calcification of the clear calcospherites in shell, that 'as the develop-

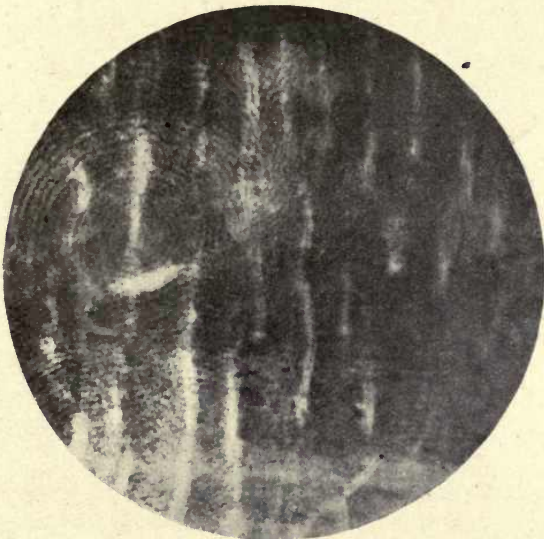


FIG. 178. Calcoglobulin contours in forming dentine.
Unerupted premolar. ($\times 700$.)

ment progresses the globules lose their bright and structureless character and begin to present laminae and radiating lines just as the artificial calculi do, the lines being more distinct when the globules are suffering disintegration'. Figs. 178 and 179 show that this is the case in the dentine. The decalcified calcospherites are seen to have first coalesced into larger bodies and then to have become laminated, showing strongly-marked concentric striæ. The dentine is stained a deep brown by the Cajal process and is everywhere traversed by these contours. The circular bodies are of very various sizes, and the outermost striæ composing the

rings are drawn out into laminæ which pass more or less parallel to the surface of the dentine. Fig. 179 shows the drawing out of the marginal striæ, which remain equidistant from one another. It is seen in this figure that the dentine, in a thin section, splits along these lines of lamination, the splitting not only following the extended laminæ but also the contours of the round bodies themselves, where they have not been drawn out in this manner. It will be noticed that the lines remain absolutely parallel and never join with

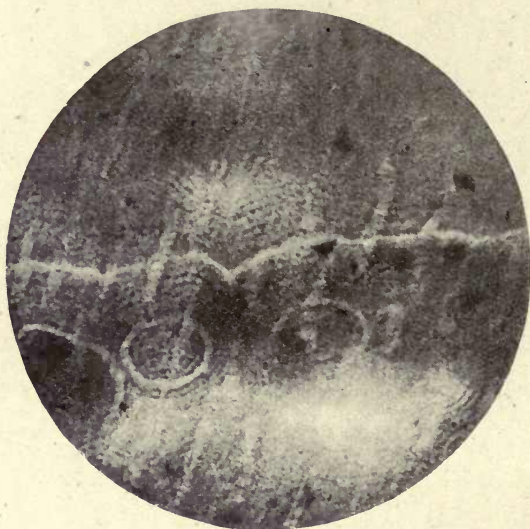


FIG. 179. Calcoglobulin contours in forming dentine. Unerupted premolar. ($\times 600$.)

one another in the same layer. This form of lamination of the dentine would thus appear to have nothing to do with physiological lines of growth, but to be due to a purely physical cause, the extension of the elements of the globular bodies in parallel lines. In teeth in a further stage of development the rounded contours are to a very great extent lost, and only the parallel striæ remain as evidence of the original structure.

In the completed dentine the striæ are hidden by the dense calcification, but as shown above, occasionally revealed in caries by the action of the bacterial acid products

upon the matrix. In the finished dentine of the Wombat's incisor this lamination is particularly well marked and conspicuous. That this lamination or stratification of the dentine is due to the structure of the calcospherites is, we think, very evident, and is the result of the rhythmic or periodic deposit of the lime salts in the colloid. The phenomena of the production of Liesegang's rings (fig. 180) gives strong evidence of this, showing that the phenomena of diffusion are periodic. As Leduc says (14) : ' The growth of an osmotic production shows itself not as a continuous process but periodically.' D'Arcy Thompson (20) also refers




FIG. 180. Liesegang's rings. Stratification by periodic diffusion. (Produced by diffusion from a drop of silver nitrate in a solution of gelatine to which a drop of sodium arsenite has been added.) From Leduc.

to this when he says : ' Among these various phenomena, the concentric striation observed in the calcospherite has acquired a special interest and importance. It is part of a phenomenon now widely known and recognized as an important factor in colloid chemistry under the name of Liesegang's rings.' These rings are formed when a salt, such as bichromate of potash, is placed on gelatine poured upon a glass plate, the diffusion of the salt in the colloidal gelatine solution showing a rhythmic deposit, leading to the formation of concentric rings, and it is this rhythmic deposit which occurs in the formation of the calcospherite in the colloid. As Leduc says, all the phenomena of life are periodic,¹ although Mr. Carter states, referring to Leon Williams's

¹ For a discussion of periodicity and rhythmic deposit see Leduc's *Mechanism of Life*, chap. vi, p. 67, and D'Arcy W. Thompson's *Growth and Form*, pp. 427-31.

work on enamel, 'There is no support for any theory which endeavours to explain the appearances found in formed or forming enamel as being due to intermittent rhythmical secretion from the cells' (5).

Mr. F. J. Bennett, in a paper read before the Odontological Society in 1888, described the appearances produced by the action of glycerine on dentine in which laminae were brought into view, but the structure of the calcospherites was not apparent in these preparations (1).

From these observations it would appear that the stages in the calcification of dentine are :

Summary.

First, the appearance of the small, clear, circular bodies which form in a colloidal matrix by the coalescence of minute particles, as seen in artificial experiments.

Secondly, the coalescence of these clear bodies, which becoming incorporated in the basis substance of the dentine are still more completely fused together, lose their structureless character, and exhibit concentric lines.

Thirdly, the coalesced calcospherites undergo disintegration, their concentric elements being spread out into the laminae of the dentine and the lime salts becoming equally diffused in the calcified matrix.

Fig. 80 shows calcospherites formed in Harting's albumin experiment referred to on p. 140. It is seen that the concentric markings on the calcified artificially-produced spherite are precisely similar to those in the calcoglobulin substance of the decalcified dentine. It is noticeable that while in the calcification of enamel we meet with spherites having radial striæ, these are not seen in dentine, where all the component spherites are seen to be of the concentrically-arranged variety.

As to the exact mode and channels of secretion of the lime salts in dentine we have still but little accurate knowledge. We know that the deposit takes place, not in direct contact with the odontoblasts but gradually advances from above upon the odontogenic zone; this would suggest that the lime salts pass by dialysis from the tubes of the dentine, containing the protoplasmic prolongation of the secreting odontoblast cell, into the dentinal matrix, and the minute subdivisions of the tubes with their protoplasmic

contents would afford a very efficient means of distribution of the calcifying substance within the matrix. It was pointed out by Erwin Höhl (9), that in longitudinal section, while the sheath of Neumann is very evident, with suitable staining, in the calcified portion of the dentine, it is not to be seen in the odontogenic zone, where the tubes appear to have no definite walls. This observation is confirmed by the author's silver-stained sections. Höhl considers that this fact points to 'the dependence of the sheath of Neumann on calcified dentine substance'.

Whether this sheath is concerned in the calcifying process and serves the purpose of a dialysing membrane might be considered, but if this lining sheath to the tubules really exists or not is still considered by some a matter of controversy; its presence would not, however, appear to be necessary to account for this mode of impregnation of the matrix, for such dialysis could take place through the outer limiting membrane of the dentinal fibril into the matrix substance, and, as stated above, its permeation by the minute subdivisions of the tubes would much facilitate the process.

It is difficult to explain the deposit of the lime salts at a distance from the odontoblast cell itself, unless we consider that the dentinal fibril which is an extension of the cell takes an active part in the process, as suggested.

The Calcification of Vasodentine. Vasodentine is developed around the walls of a central pulp cavity which is traversed by large and abundant blood-vessels, these vessels becoming incorporated in the dentine as calcification proceeds, and not receding deeper into the pulp as they do in Mammalia.

As C. S. Tomes says: 'In the calcification of the formative pulp into vasodentine, this recession of its vessels does not take place; the whole vascular network of the papilla remains, and continues to carry blood circulating through it, even after calcification has crept up to and around it.' In a vasodentine pulp the connective tissue is very abundant, and forms a definite layer of fibres around its circumference. These fibres had originally been looked upon as odontoblasts; they occupy the position of the odontoblast cells in

the formation of orthodentine, and are arranged very much in the same manner, but a careful examination of a thin section shows that there are no nuclei, and that the tissue composing this layer is made up of fibres and not cells (fig. 181).

Rounded or polygonal cells are, however, to be seen lying among them in places which have a strong resemblance to osteoblasts. The absence of odontoblasts would appear to be consistent with the absence of dentinal tubes in vaso-

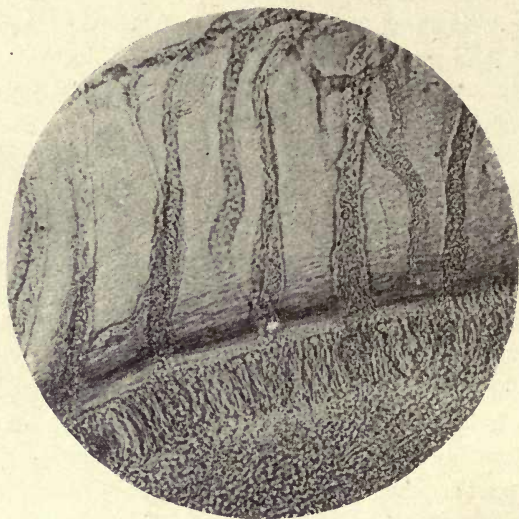


FIG. 181. Connective-tissue fibres lining pulp cavity of Hake (Merluccius). Ground Weil section (unstained). ($\times 150$.)

dentine, as the typical odontoblast is provided with a process, the dentinal fibril, which is not found in vasodentine. In teeth in which orthodentine is found in one portion of the tooth, while the rest is composed of vasodentine, as in the flounder, odontoblasts are seen in the area of the pulp tissue beneath the tubular dentine, although absent farther down, where vasodentine has taken its place. Tomes had at first considered that this layer around the pulp consisted of elongated odontoblasts, but after a reconsideration of his own and the author's preparations, he agreed that there was no evidence of this, and that it really is composed of

pecially arranged connective-tissue fibres. Thin sections of freshly-fixed preparations of the teeth of the Hake, which had not been decalcified and were prepared by the Weil process, confirmed the author's conclusions, as neither these nor the earlier preparations showed any nuclei in the layer, and its connexion with the connective tissue of the pulp was quite evident. As further evidence of the nature of this bordering layer, the teeth of the Hake often break up in the direction of the bordering fibres, and this splitting appears to be continuous with them.¹

The Calcification of Osteodentine. From the great similarity of osteodentine to bone we should expect to find a similar mode of development to that of membrane bone.

In osteodentine there is no separate pulp cavity, but medullary spaces traversed by trabeculæ of bony substance. The spiculæ or trabeculæ are clothed with cells in every way resembling osteoblasts; they are continuous with bundles of connective-tissue fibres, and at the junction of the tooth with the bone of attachment these trabeculæ become incorporated with the bone tissue of which they form a part. The development is in every respect similar to that of bone in membrane, and the connective-tissue bundles become incorporated in the calcified tissue as Sharpey's fibres do in bone.

It is thus seen that orthodentine, vasodentine, and osteodentine are all calcified on a connective-tissue foundation, and as Tomes says: 'The development of the several varieties of dentine which seem to run into one another structurally by almost imperceptible gradations comes into line and so seems more intelligible.'

¹ As pointed out on p. 256, the teeth of the Hake are often seen to break up in a transverse direction as well, following the transverse lamination of the dentine.

REFERENCES

1. Bennett, F. J. 'On certain Points connected with the Structure of Dentine.' *Trans. Odontol. Soc. Great Brit.*, vol. xxi, p. 6, 1889.
2. v. Bibra. See ref. on p. 117.
3. Black, G. V. 'An Investigation of the Physical Characters of the Human Teeth in Relation to their Diseases.' *Dental Cosmos*, May 1895, vol. xxxvii, p. 353 et seq.

4. v. Brunn. 'Ueber die Ausdehnung des Schmelzorganes in seiner Bedeutung f. die Zahnbildung.' *Archiv f. Mikr. Anat.*, 1887, Bd. xxix, pp. 367-83.
5. Carter, Thornton. 'The Cytomorphosis of the Marsupial Enamel Organ,' &c. *Phil. Trans. Roy. Soc.*, vol. ccviii, p. 288.
6. v. Ebner, V. *Handbuch der Zahnheilkunde*, p. 253.
7. Fischer, G. *Bau u. Entwicklung der Mundhöhle des Menschen*, 1910.
8. Hunter, John. *John Hunter's Works*, Palmer's Edition, 1835.
9. Höhl, Erwin. 'Beitrag zur Histologie der Pulpa und des Dentins.' *Archiv f. Anat.*, 1896.
10. Hoppe, F. 'Untersuchungen über die Constitution des Zahnschmelzes.' *Virchow's Archiv f. Pathol. Anat.*, Berlin, 1862, Bd. xxiv, pp. 13-32.
11. Hanazawa, K. 'A Study on the Minute Structures of Human Dentine.' *Trans. Panama Pacific Dental Congress*, 1915, p. 80, and *Dental Cosmos*, Feb. 1917 and March 1917, vol. lix.
12. Klein, E. (a) *Elements of Histology*.
(b) Klein and Noble Smith. *Atlas of Histology*. London, 1879.
13. v. Korff. 'Die Entwicklung der Zahnbeingrundssubstanz der Säugthiere.' *Archiv f. Mikr. Anat.*, xlvii. 1.
14. Leduc, S. *Mechanism of Life*, p. 68.
15. Mummery, J. H. (a) 'Some Points in the Structure and Development of Dentine.' *Phil. Trans. Roy. Soc.*, London, 1892, Ser. B., vol. clxxxii, pp. 527-45.
(b) 'On the Process of Calcification in Enamel and Dentine.' *Phil. Trans. Roy. Soc.*, vol. ccv, pp. 95-113, 1914.
16. Neumann. *Ein Beitrag zur Kenntniss des normalen Zahnbeins und Knochengewebes*. Leipzig, 1863.
17. Owen, R. *Odontography*, p. 406.
18. Römer, O. *Zahnhistologische Studie*, 1899.
19. Röse, C. 'Contributions to the Histogeny and Histology of Bony and Dental Tissues.' *Dental Cosmos*, Nov. and Dec. 1893.
20. Thompson, D'Arcy W. *Growth and Form*, p. 427.
21. Tomes, J. (a) 'On the Presence of Fibrils of Soft Tissue in the Dental Tubes.' *Phil. Trans. Roy. Soc.*, 1856.
(b) 'On the Structure of the Dental Tissues of the Order Rodentia.' *Phil. Trans. Roy. Soc.*, 1850, pp. 529-68.
22. Tomes, C. S. (a) *A Manual of Dental Anatomy*, 7th ed., p. 83.
(b) 'Upon Röse's proposed Classification of the Forms of Dentine.' *Anat. Anzeig.*, Bd. xiv, No. 13, 1898.

CHAPTER VI

CEMENT

THIS tissue, both by its structure, its chemical composition, and its mode of development, is seen to be simply a slightly modified form of bone. This, the 'crusta petrosa' of early authors, is usually termed cement by the general anatomist; but *cementum* is the term which has been usually applied to it by dental histologists, although the French have retained the word 'cément'.¹

Cement in man is confined to the roots of the teeth, where it forms a continuous investment of the dentine, but in many compound teeth it forms the cementing substance between the plates, as in the Elephant and the Capybara, and in Ungulates before the teeth come into use it forms a complete investment of the crown.

As previously pointed out and as shown in the compound teeth above referred to, a sharp masticating surface to the tooth is maintained by the unequal wear of the different tissues. The cement, being the least resistant, is worn down more readily than the dentine, and the latter more easily than the hard enamel, which by projecting above the other tissues affords a rough sharpened surface for the purposes of mastication.

At the neck of the human tooth the cement is usually considered to terminate at the point of contact with the enamel, but there are considerable variations in the relations of the two tissues in this situation in normal teeth. This question was especially studied by J. Choquet, who from the

¹ In the present work the author has ventured to adopt the word 'cement' for this tissue. The Committee on nomenclature of the Anatomical Society have confirmed the use of the word cement, and it is the term in use in all the text-books of general anatomy. It would appear very desirable that one word only should be employed to describe the same tissue, and for these reasons the author has thought it advisable to use the word cement instead of *cementum*, although the latter has been in use for a long time in English and American works on dental anatomy

examination of a large number of teeth found four different conditions present :

1. The enamel overlaps the cement.
2. The cement overlaps the enamel.
3. The two tissues terminate in direct contact.
4. There is a solution of continuity and an exposed surface of dentine between the enamel and cement (3).

In the first case, where the enamel overlaps the cement there is a marked difference in the percentage of cases between the teeth of young subjects and those of adults. In the young teeth this arrangement of the tissues was found in 57 per cent., and in adults in 12.5 per cent. In the second case, where the cement was seen to overlap the enamel, the difference between the teeth at different ages was more marked, this condition not being observed in a single case in young teeth ; but in adults 62.5 per cent. of teeth examined showed this overlap. These results are easily understood on considering the process of development. The formation of the cement proceeding after the enamel is fully laid down, the osteoblasts continuing to deposit cement add somewhat to the thickness of the tissue at the neck of the tooth, and an overlap is easily comprehended, and would be only found in adult teeth.

The conditions 3 and 4 exist according to this investigation in exactly similar proportions in adult teeth. In some few cases a large overlap of cement with numerous lacunæ is seen, as shown in fig. 182. This is probably a pathological condition, and is of rare occurrence, produced by an over-activity of the cells of the follicle wall, probably due to some chronic irritation of the tissues surrounding the tooth ; but it is to be noticed that this deposit of cement takes place outside the Nasmyth's membrane, which has been clearly proved to be of an epithelial nature and derived from the ectodermic enamel organ.

The basis substance or matrix of the cement appears almost structureless or very faintly granular, and its collagen foundation retains its form and structure after decalcification by acids. Like bone, cement has a lamellar structure and encloses lacunæ and canaliculi, the lacunæ enclosing a nucleated cell (an included osteoblast), whose processes

are prolonged into the canaliculi (figs. 183–186). The lacunal cells are very clearly seen in specimens prepared by the Weil process, which have been previously stained with borax carmine.

The lacunal cells in bone were first described by Virchow. They entirely fill the lacuna in the fresh state and send processes along the canaliculi. The lacunal cells in cement are identical in essential structure with those of bone, enclosing a large readily stained nucleus with one or two

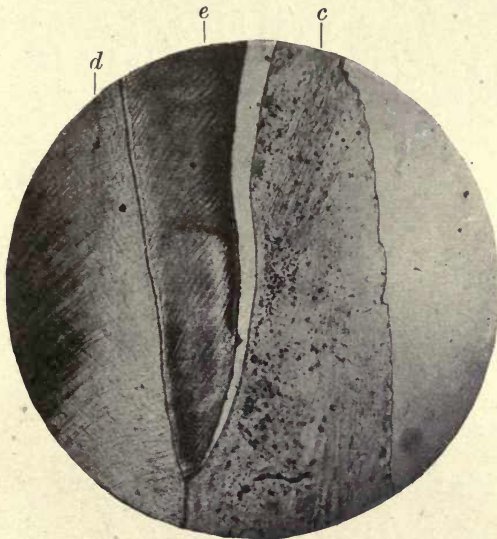


FIG. 182. Large overlap of cement, human molar.
d. Dentine; e. enamel; c. cement. ($\times 50$.)

nucleoli. In several instances the lacuna with its contained cell and processes has been isolated from the bone, the walls of the space having resisted the decalcifying acid, as the Neumann's sheaths do in dentine; and fig. 183, from Schafer's *Microscopic Anatomy*, shows such a separated lacuna with its contained cell and processes. As this author says, 'It can scarcely be doubted that the protoplasm of the nucleated corpuscle takes an important share in the nutritive process in bone, and very probably serves both to modify the nutritive fluid supplied from the blood and to further its distribution through the lacunar and canali-

cular system of the bony tissue' (7). These remarks will apply with equal force to cement.

It is claimed by Walkhoff and by Hopewell Smith (4) that normal cement does not contain lacunæ, but while these are rarely found in the thin layer at and near the neck of the tooth, there seems little doubt they are abundantly present in that of the root, and in the development of the cement at the growing root tip they are distinctly seen becoming included in the forming tissue. It would appear that if all cement containing lacunæ is to be looked upon as pathological, there would be very few teeth that could be said to possess normal cement. In fig. 190 lacunæ are seen in the thin layer on the outside of the root where

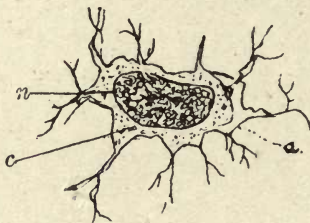

FIG. 183. Bone cell isolated (Schafer after Joseph). *a*. Proper wall of lacuna shown at a part where the corpuscle has shrunk away from it; *c*. cell; *n*. nucleus.

the deposition of this tissue has apparently been quite normal.

The cement at the neck of the tooth is clear and translucent, and seldom shows any trace of lamination; but in the root portion of the tissue the lamellæ are very conspicuous, and represent lines of incremental growth as in bone.

The processes of the lacunal cells communicate with one another and with the fine terminations of the dentinal tubes in the granular layer of the dentine. They thus, where present, form a chain of communication of protoplasmic material between the periodontal membrane and the pulp, as is clearly shown in figs. 184–186 from a tooth of a marsupial, and in a human molar in fig. 187. Those who deny the existence of lacunæ in normal cement would not admit that such intercommunication exists.

As in bone, the perforating fibres of Sharpey are seen to

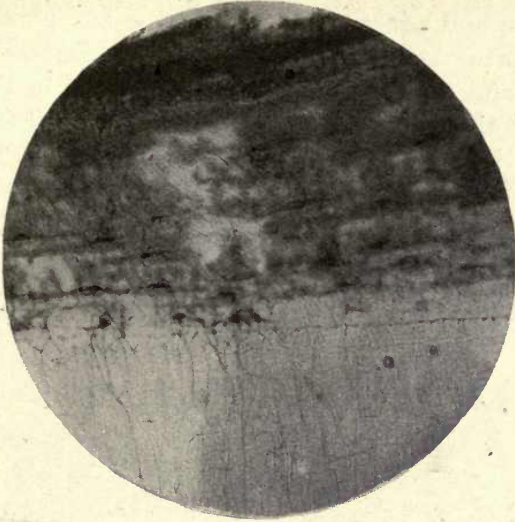


FIG. 184. Tooth of *Bettongia*, showing communication of dentinal fibrils with periodontal membrane. ($\times 250$.)

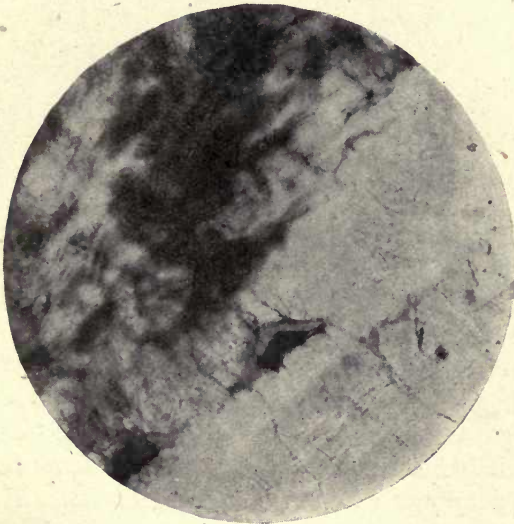


FIG. 185. Lacunal cells within the lacunæ of cement (*Bettongia*), showing communication of dentinal fibrils with canaliculi. The lacunal cell is seen to occupy the whole lacuna. Two nucleoli are seen within the dark-stained nucleus. ($\times 350$.)

enter the substance of the cement from the periodontal membrane and penetrate it in more or less parallel lines. These fibres are prolongations of the connective-tissue bundles, and serve to attach the membrane to the tooth. It is undecided if they are calcified or not. In caries of cement the micro-organisms penetrate along the lines of these fibres exactly as they do along the canals of the dentine, which would lead us to suppose that they are not

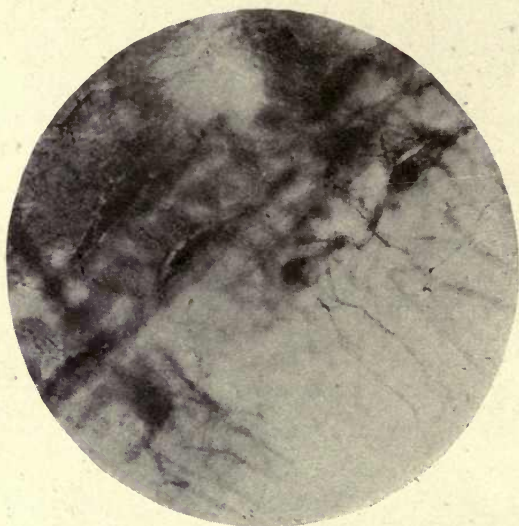


FIG. 186. Similar preparation to fig. 185. ($\times 350$.)

so fully impregnated with lime salts as the surrounding matrix.

Haversian canals are said to be occasionally seen in the cement of human teeth, but are of rare occurrence, and when present are generally found in the thick portion between the roots of the molars. The lamellæ are arranged concentrically to the canal, as in bone. Vascular canals are also occasionally seen, which do not exhibit the structure of Haversian canals, but simply appear as channels or perforations in the substance of the tissue.

In the specimen figured (fig. 192) there were numerous canals in the dentine of the root, and each of these is seen to be surrounded by a layer of cement containing lacunæ.

The cement appears to be in contact with the granular layer of the dentine (fig. 184), but a clear layer often, but not always, intervenes. It is sometimes described as a structureless layer of dentine, sometimes as cement. In figs. 184, 185, and 186, the granular layer is seen in immediate contact with the cement, and the fine terminal branches of the dentinal tubules are continuous with the canaliculi. This condition is also seen in many of the

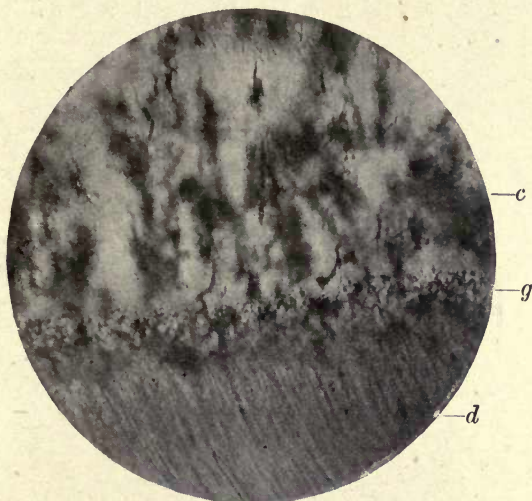


FIG. 187. Communication of dentinal tubes with cells of granular layer and with canaliculi of the cement. *c.* Cement; *d.* dentine; *g.* granular layer. (Human molar.) ($\times 150$.)

author's preparations of human teeth. The majority of the canaliculi are directed towards the outer surface (figs. 187, 188, and 189). Many appearances suggest that the outer layer consists of the first-formed cement, but it is very difficult to speak with any certainty on the point (see figs. 186 and 190).

The lacunæ and their canaliculi are scattered or arranged in rows; they are much more irregular in form than the lacunæ of bone, and often have a tufted appearance, and the canaliculi are frequently seen in the roots of teeth extending across several lamellæ and of great length. In irregularly deposited cement some of the lacunæ have no apparent canaliculi; these are the bodies which Hopewell

Smith calls abrachiate lacunæ. The incremental lines in cement follow the contour of the root and form the laminæ in thick cement; they are, as in bone, the indication of the incremental deposit of the calcified tissue, and have been known as 'the incremental lines of Salter'.

Development of Cement. In the cement of human teeth, which is confined to the roots, the process of ossification is exactly similar to that of bone in membrane. In ungulates and animals possessing coronal cement, a cement organ has

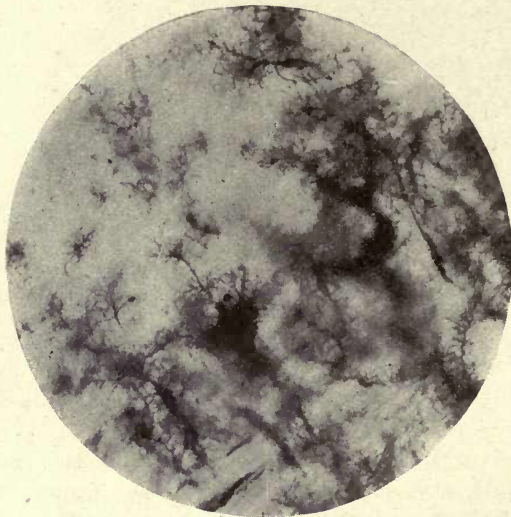


FIG. 188. Feathery canaliculi in cement in root of human molar. ($\times 150$.)

been described by Robin and Magitot (6). They say: 'The coronary cement is produced by the mode of ossification, called ossification by substitution, or by the ossification of preceding cartilage of the same form, for which is substituted a corresponding osseous layer.' The details of the process of ossification given by these authors do not, however, exactly correspond to those of the ossification of bone in cartilage generally accepted. They describe the invasion of the fibro-cartilaginous basis substance by points or spots of ossification which form small plates produced into prolongations or trabeculæ which arise from their periphery,

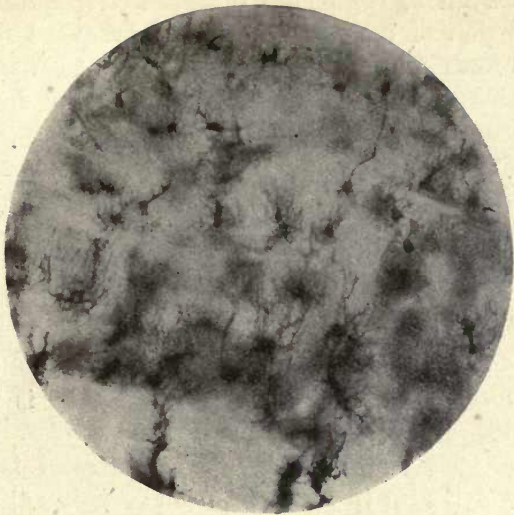


FIG. 189. Similar to fig. 188. Laminae of the cement (human). ($\times 150$.)

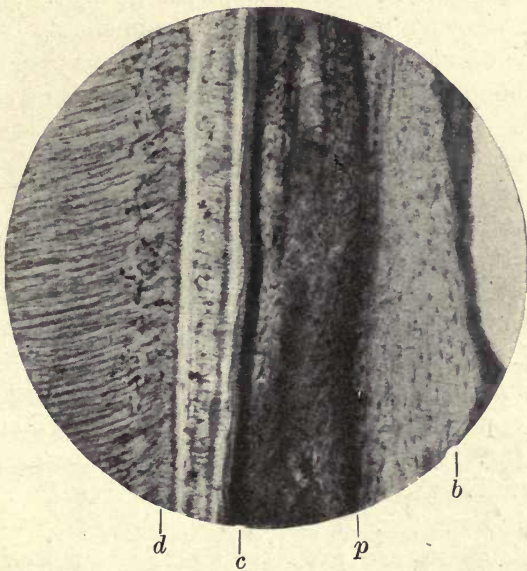


FIG. 190. Dentine cement and bone *in situ*. Lacunæ are visible in the cement. *b.* Bone; *c.* cement; *p.* periodontal membrane; *d.* dentine. ($\times 80$.)

the vessels having completely disappeared from the cartilage in the region of ossification. The subsequent removal of this first-formed bone and the re-deposit of bony matter in the interior of the cartilage are however, not described by them in considering this mode of calcification of the cement. In the radicular cement of human teeth, where the process is similar to that seen in membrane bones, the connective tissue of the follicle with its rich vascular supply invests the forming root; but a layer of epithelial cells, extending from the epithelial elements in the coronary portion of the follicle, and known as the sheath of Hertwig, extends downwards along the margin of the dentine as far as it is formed, and as described on p. 320 is the form-determining organ of the dentine as first shown by Von Brunn (2). The dentine is laid down beneath this epithelial sheath, which always intervenes between it and the connective tissue of the periodontal membrane during the active growth of the root. Where no cement has begun to form, as can be seen at the tip of the forming root, the epithelial layer is in contact with the dentine. As soon as the development of the cement commences, bundles of connective tissue and osteoblasts in every respect similar to those of bone pass between the epithelial cells of the sheath from the surrounding connective tissue of the follicle, separating the epithelial masses composing the sheath from one another, and the fibrous bundles become firmly attached to the dentine. The osteoblasts can be seen in sections to occupy little spaces or divisions between the connective-tissue bundles, and as in bone, some of them become included within the forming tissue, and remain as the lacunal cells of the finished cement (figs. 191 and 193).

As was first pointed out by Kölliker, the calcareous substance is deposited in little flakes or plates which afterwards coalesce (fig. 194). The connective-tissue bundles become incorporated in the forming cement, and form the Sharpey's fibres as in bone (fig. 193, &c.).

The osteoblasts are probably modified connective-tissue cells, but they are considered by some authorities to be leucocytes derived from the circulating blood; they are very abundant and lie in the first-deposited cement

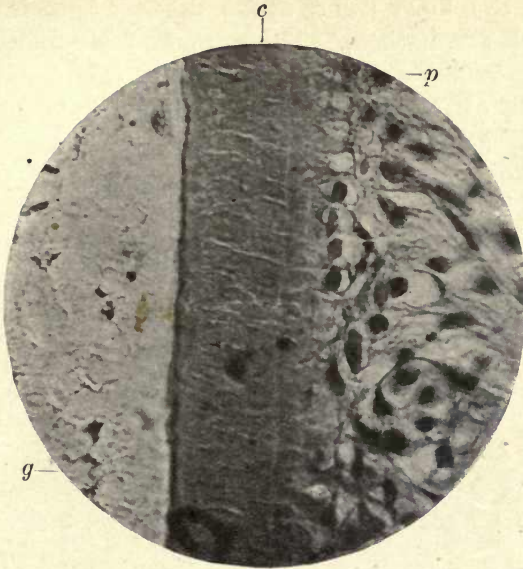


FIG. 191. Cement and periodontal membrane in an adult tooth
g. Granular layer of dentine; *c.* cement with Sharpey's fibres; *p.* perio-
 dontal membrane and osteoblasts. ($\times 700$.)

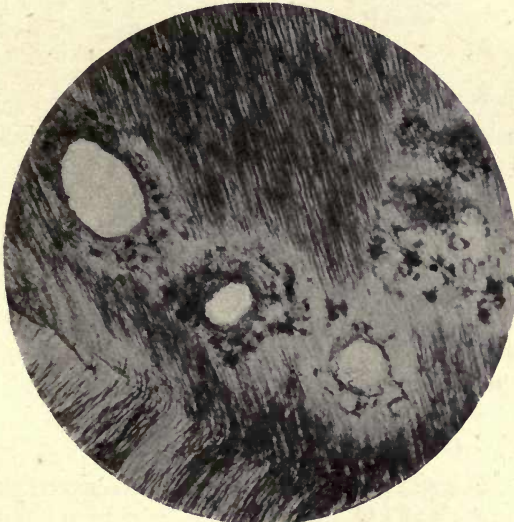

FIG. 192. Vascular canals in dentine surrounded by cement.
 Root of human molar tooth. ($\times 150$.)

between the little flakes above described, their processes passing between them. These are the more faintly stained cells seen between the flakes in fig. 194.

Schafer (*Microscopic Anatomy*) says: 'Osteoblasts are probably specially modified connective-tissue corpuscles, perhaps of the nature of plasma cells; but after being included in the lacunæ they may undoubtedly be regarded as homologous with the lamellar cells of connective tissue.'

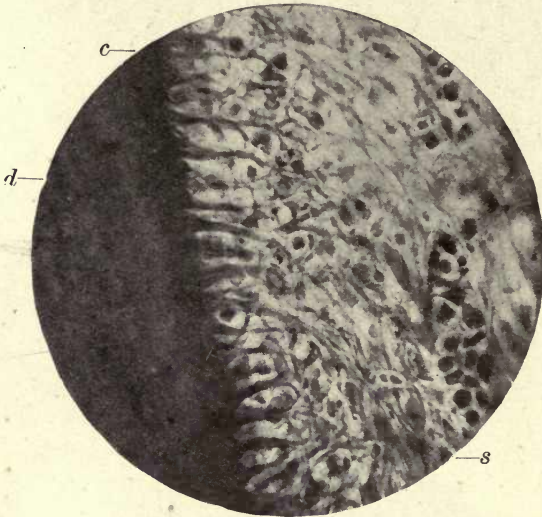


FIG. 193. The penetrating fibres of Sharpey in forming cement, osteoblasts lying between them. *s.* Remains of Hertwig's epithelial sheath; *d.* dentine; *c.* cement. ($\times 450$.)

It is not probable that they are produced from leucocytes, as suggested by Kassander ' (5).

Calcification. Two different views have been held as to the mode of calcification in bone and cement, one being that the osteoblasts are actually converted into bony substance, the other that they secrete the calcifying material.

A similar controversy has been held over the mode of deposition of enamel and dentine, but the view more generally held with regard to the process occurring in bone is in harmony with that chiefly received in reference to the other tissues of the tooth, that it is formed by the secretion of a material which calcifies and not by an actual conversion

of the cell substance into bone. This view was upheld by Gegenbaur and Kölliker, while Waldeyer (9) and others maintain that there is a 'direct conversion of the protoplasm of some of the osteoblasts into bony tissue'. Schafer, in supporting the secretion theory, points out that there is no indication of cell areas in the formed tissue, and no half-calcified osteoblasts are to be seen.

As is seen in fig. 191, which shows the penetrating fibres in the cement in a Weil preparation from a tooth freshly

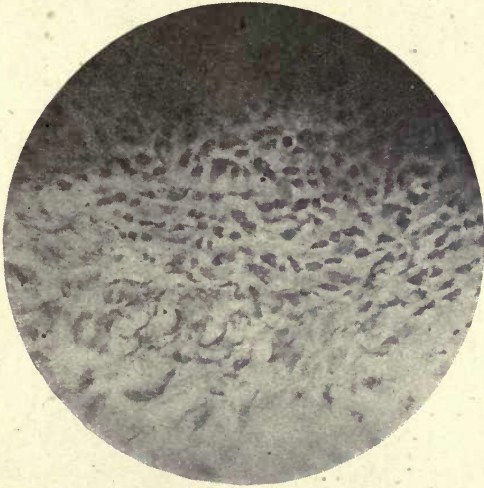


FIG. 194. Forming cement showing that it is deposited in flakes. The faintly stained cells between the flakes are the osteoblasts. ($\times 450$.)

fixed in sublimate, the Sharpey's fibres appear as channels in the substance of the tissue communicating with the exterior and in close contact on the inner side with the granular layer of the dentine. If these run, as they appear to do, in actual channels in the cement, they may serve as a means of communication between the fibrils of the dentine and the periodontal membrane, and in the absence of lacunæ with their canaliculi, may serve to keep up this communication. In caries in the cement the microorganisms penetrate the tissue along the lines of these fibres exactly as they do the tubes of the dentine.

Absorption. Absorption occurs in the temporary teeth as a normal physiological process, and is the agency by which

the deciduous teeth are removed to make room for their permanent successors. In the permanent teeth the process is chiefly a pathological one, although the moulding of the forming roots appears to be by an alternation of absorption and deposition as in the formation of bone.

In the temporary teeth, absorption commences in the cement, but not necessarily at the nearest point to the erupting permanent tooth, and is not due to pressure from beneath. The cement and dentine show semilunar indenta-

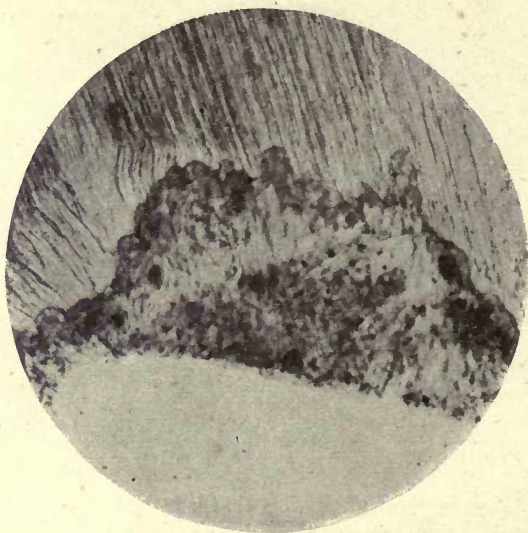


FIG. 195. Absorption of temporary tooth. Weil process. ($\times 150$.)

tions, the lacunæ or foveolæ of Howship, and if the tooth is not previously shed, absorption will proceed to the excavation of the enamel (figs. 195 and 196).

These excavations are occupied by large multinucleated cells, the osteoclasts, which are the active agents in absorption both in bone and teeth. By what means they produce this result is not determined. It is considered probable that they secrete an acid which has a solvent effect upon the lime salts, but this has never been definitely proved. It has also been suggested that they cause absorption by the protrusion of amœbiform processes into the hard tissues, but the view more generally held is that they secrete some

solvent agent, probably of an acid nature. The osteoclasts are usually multinucleated or giant cells, and vary very much in size and in the number of their nuclei. It is considered by many that both osteoclasts and osteoblasts are modified connective-tissue cells and are interchangeable, osteoblasts becoming converted into osteoclasts and vice versa. Another view of their origin is that they result from the fusion of leucocytes, but the former is the view more generally held. Hopewell Smith states, speaking of the

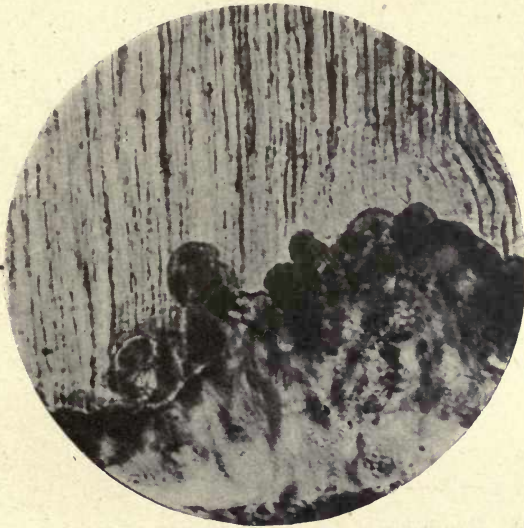

FIG. 196. Absorption of a temporary tooth. Howship's lacunæ and osteoblasts. Weil process. Stained carmine. ($\times 250$.)

absorption of permanent teeth, that osteoclasts do not exist 'in the innermost zone of the root membrane'; he denies the presence of osteoclasts in the absorption of the dentine and cement of permanent teeth, and also considers that true Howship's lacunæ are not found on the tooth side of the membrane (4). It is, however, very evident in many instances that Howship's lacunæ and osteoclasts are present in both dentine and cement which is undergoing absorption (fig. 197), and they show no recognizable difference to those seen in absorbing bone or temporary teeth.

Cement being but a modified form of bone, it is reason-

able to expect that the same process of absorption accomplished by the same agents would be found in the teeth. Osteoclasts have been shown to be present in the absorption of the dentine of implanted teeth, by Wilkinson, and were also present within the lacunæ of Howship in the absorption of the implanted tooth in a dog, in Scheff's implantation experiment.

In the roots of teeth which have been the subjects of slight pathological changes, alternations of absorption and

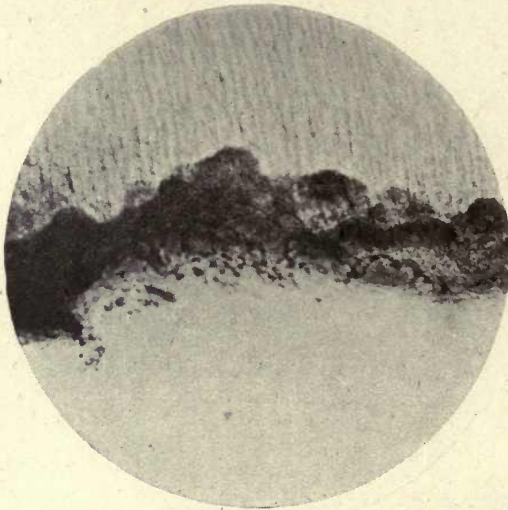


FIG. 197. Absorption of dentine in permanent molar. Howship's lacunæ and osteoblasts. Weil process. ($\times 150$.)

deposition are seen to have taken place, the semilunar excavations in both bone and dentine being occupied by a deposit of cement, sometimes containing ordinary branched lacunæ and canaliculi and sometimes small lacunæ destitute of processes. In an abscessed tooth large portions of the root are often seen to be excavated and absorbed by the osteoclasts (fig. 198).

As previously stated, both in the bone and in the permanent teeth alternations of absorption and deposition are seen, in the permanent teeth generally as the result of pathological conditions, but in the formation of the roots of permanent teeth this alternation can often be detected.

A moulding or shaping process appears to take place, the osteoblasts apparently laying down more tissue than is eventually required and the osteoclasts removing the superfluous material. This double action of the formative cells of the cement can be well seen in fig. 216, where osteoblasts are laying down the tissue, and large giant cells are absorbing it on their inner side.

Many authorities, especially the French histologists, deny the existence of a distinct absorbent organ, and look upon




FIG. 198. Absorption of dentine and re-deposit of cemental tissue. Weil process. ($\times 150$.)

the absorption of the temporary teeth as a physiological process of rarefying osteitis, in which absorption and deposition alternate. This view is held by Redier, Malassez, and Galippe, and was embodied in a paper contributed to the International Dental Congress of 1910 by J. Choquet, who came to the same conclusion from his own researches (3). As Professor Sims Woodhead states (10), 'Rarefying osteitis must be looked upon as a process rather than a distinct disease'; and again on p. 477: 'In rarefying osteitis there is increased absorption of bone accompanied by a corresponding new formation.'

That such a process does occur in temporary teeth is

evidenced by the fact that alternations of removal and deposition of tissue are often seen in these teeth during the process of absorption, and this is also evident in the absorption of the roots of permanent teeth. As previously stated, osteoblasts and osteoclasts appear to be interchangeable, the same cells sometimes performing one function, sometimes another; the multinucleated osteoclasts being simply modified osteoblasts.

In a recent paper (8) Dr. Eugene Talbot says: 'When once the absorption of cementum has occurred, it is rarely if ever reproduced.' The tissue which fills up the absorbed areas in many teeth which have undergone chronic absorption certainly appears to be an irregular deposit of cement, which in many of the author's specimens is laminated.

Black also says: 'These absorptions . . . are afterwards repaired by the deposits of cementum, and the lamellæ of cementum subsequently laid down are seen to pass over them without any material disturbance.' (1).

One would imagine that in the very recent absorptions produced in Talbot's experiments on dogs sufficient time had not been allowed for the process of re-deposition to take place.

REFERENCES

1. Black, G. V. *The Periosteum and Peridental Membrane.*
2. v. Brunn, A. See references to Chapter VIII.
3. Choquet, J. (a) 'Notes sur les rapports anatomiques entre l'Émail et le Cément.' *L'Odontologie*, Feb. 1899.
(b) 'Études sur la résorption des racines des dents temporaires,' &c. *Trans. Fifth Int. Dent. Congress*, Berlin, 1910.
4. Hopewell Smith, A. *Normal and Pathological Histology of the Teeth*, 1919, p. 84.
5. Kassander. *Anat. Anzeig.*, 18, 1900.
6. Robin et Magitot. Genèse et développement des follicules dentaires.' *Journ. de l'Anat. et de la Physiol.*, vol. iv, 1861.
7. Schafer, E. A. *Microscopic Anatomy*, 1912, p. 148.
8. Talbot, Eugene. 'Bone Absorption around the Roots of Teeth.' *Dental Cosmos*, May 1919.
9. Waldeyer. *Archiv f. Mikr. Anat.*, i. 1865.
10. Woodhead, G. Sims. *Practical Pathology*, Edin., 1892, p. 474.

CHAPTER VII

THE PERIODONTAL MEMBRANE

THE periodontal membrane, alveolodental periosteum or pericementum, surrounds the implanted part of the tooth in man, intervening between the cement of the root and the bone of the alveolus. It is derived from the connective tissue of the tooth-sac or outer portion of the follicle, and consists of connective-tissue fibres and cells with nerves and blood-vessels, but no elastic tissue.

It is held by Malassez (2) that the term alveolodental periosteum commonly employed in describing this membrane is 'as false from the physiological point of view as from the anatomical'. He considers it shows none of the characteristics of an enveloping membrane, but solid fibrous fasciculi, which he considers form a kind of circular ligament. He further says: 'Reviewing the evidence of comparative anatomy, we see that in many animals the teeth are not enclosed in alveoli, but they are seen to be simply included in the mucous membrane of the gum, but are also attached to the maxilla by solid ligamentous fasciculi, the analogue of the so-called alveolodental periosteum.'

Ranvier¹ also stated that 'there exists between the tooth and its alveolus no separable membrane such as is present around the long bones', and looks upon the alveolar cavity as 'nothing but an enlarged medullary space, communicating with neighbouring spaces'.

The white fibrous connective-tissue bundles, of which this membrane is chiefly composed, pass from tooth to bone in a more or less transverse direction, and they become blended with the tissue of the gum at the neck of the tooth. These bundles are attached to the cement by strong fibrous bands which pass into its substance (figs. 191, 193, and 199) as Sharpey's fibres, and they penetrate the bone of the alveolus in a similar manner. The direction of the connective-tissue strands or bundles varies considerably in different parts.

¹ Ranvier, *Unpublished Lectures at the College of France.*

Near the end of the root they are chiefly oblique, passing upwards and outwards to their attachment to the bone, but are crossed by bundles of fibres passing in the opposite direction and interlacing with them. It is thus seen that there is no separate membrane connected with the tooth and another with the alveolus, but its fibres are continuous from one side to the other, although they are coarser on the outer side of the membrane and finer on the side of the cement; but there is no distinct arrangement in layers,

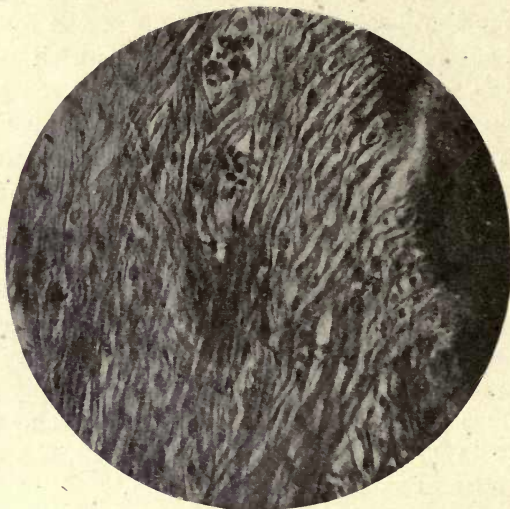


FIG. 199. Periodontal membrane showing oblique direction of fibres and their intercrossing. ($\times 450$.)

the finer fibres passing insensibly into the coarser ones. The oblique direction of the fibres and their intercrossing with others passing in an opposite direction are well shown in fig. 199.

The general arrangement of the fibres is such as to swing or suspend the tooth within the socket and allow of a certain amount of movement, preventing undue pressure on the nerves and blood-vessels of the alveolus.

Blood-vessels are abundant in the periodontal membrane midway between the bone and the tooth, and numerous capillaries are seen near the cement, and it is richly supplied with nerves.

Both the blood-vessels and nerves of the membrane are chiefly derived from the main trunks which are supplied to the tooth-pulp.

The final terminations of the neurofibrils bordering the cement have not hitherto been satisfactorily demonstrated.

Dr. Black says that after destruction of the nerves entering the apical foramen, such as occurs in alveolar abscess, the membrane still remains sensitive, and considers 'it follows, therefore, that the nerves entering the membrane through the walls of the alveolus are sufficient for the maintenance of the sensory functions'. Black describes nerve bundles entering the wall of the alveolus by way of the Haversian canals, but he does not actually demonstrate any such nerve supply, and although nerve fibres enter the bone in company with the arteries we do not think it has ever been shown that they have any distribution without the bone, but are supplied to the coats of the arteries.

The same author in his work on the *Periosteum and Peridental Membrane* devotes a chapter to the description of lymphatics in the membrane, but there can, we think, be little doubt that the structures which he describes as lymphatics, and which he compares to the Peyer's patches of the small intestine, are not glands but the epithelial remains of the sheath of Hertwig, present in all teeth.

The remains of the epithelial sheath are seen as isolated collections of epithelial cells lying in a more or less complete row at a little distance from the cement.

The continuous sheath which extends downwards during the formation of the root becomes cut up by the invading fibrous bundles, and in many places disappears; but where the membrane is not very dense, remains as rounded or elongated collections of cells which have a strong resemblance to glandular tissue.

The limiting membrane which Black describes appears to be the result of the union of the cell walls of contiguous cells, and is very marked in the network of epithelial cells forming the sheath of Hertwig beneath the forming roots of the teeth, as described on another page.

Fusiform connective-tissue cells are everywhere present

between and among the fibrous elements of the membrane, and the osteoblasts, probably derived from them, are in contact with the bone and the cement. Calcified bodies are often found in the periodontal membrane, the so-called 'epithelial pearls', which appear to be due to calcification in the cell nests or epithelial remnants (fig. 200).

Large multinucleated cells, the osteoclasts, are often seen in the situation where absorption of the cement is in progress. Under the influence of these different cells,

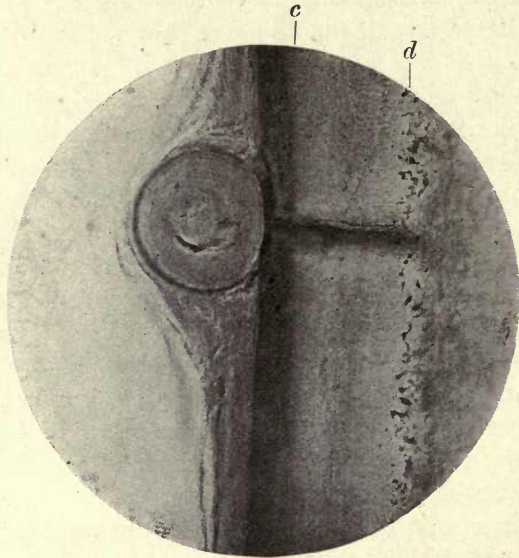


FIG. 200. A so-called epithelial pearl in the periodontal membrane. *c.* Cement; *d.* dentine. ($\times 150$.)

absorption and re-deposition of cement is often seen to be taking place at the surface of the tissue as above described.

The periodontal membrane is derived from the connective tissue of the capsule, which, as described in the chapter on development, extends around the dentine papilla; the connective-tissue fibres which it contains penetrate the cement which is deposited around them, and they thus become involved in the calcified tissue, as are the penetrating fibres of Sharpey in bone, with which they are strictly analogous. As in bone, it is doubtful if they are fully calcified, and the occurrence of caries in the cement where the micro-

organisms pass along the course of the Sharpey's fibres suggests that they are not calcified, the organisms penetrating channels in the cement occupied by the fibres exactly as they do the tubes of the dentine.

It can be easily understood from its mode of development that the blood-vessels and nerves which are supplied to that portion of the papilla which afterwards becomes the dental pulp are common to both pulp and membrane, some branches passing to the pulp, others to the membrane. It is evident that the principal vascular supply comes from the large vessels at the apex of the root, but these also form communications with the vessels of the gum and alveolus.

The rich supply of both blood-vessels and nerves to the membrane would fully account for its great sensibility in inflammatory conditions. If lymphatics are present, as must be expected, in the periodontal membrane, it is not at present known whether they form a perivascular network or exist as distinct lymphatic vessels, but there is, we think, every evidence that the lymphatic system described by Black is in reality the sheath of Hertwig, the remarkable resemblance of these regularly arranged cells to a tubular system easily lending itself to such an interpretation.

The Gum

The gum is the name given to that portion of the mucous membrane of the mouth which surrounds the teeth. It is continuous with, and identical in structure with, the mucous membrane of the rest of the oral cavity, but is slightly denser and is blended with the periosteum of the alveolar bone and with the periodontal membrane.

The microscopic structure is characteristic of all mucous membranes. The surface layer is made up of flattened epithelial cells, beneath which, as in the epidermis, are found the stratum corneum, stratum lucidum, stratum granulosum, and the cylindrical cells of the Malpighian layer. The flattened epithelial cells of the external layer are continually being shed from the surface, and their characteristic forms are seen in all preparations of the fluids of the mouth along with the mouth bacteria shown in all

cover-glass preparations. The gum tissue is firmly bound down to the bone beneath, its firm fibrous tissue being blended with that of the periosteum, with which it is continuous. Numerous large papillæ, single or compound, cover its surface, and involved in the gum tissue near its outer margin cell nests or more or less open spaces (epithelial coils) are found, probably the bodies which were considered by Serres to be glands. The structure and probable function of these bodies will be considered in treating of the tooth follicle and its connexions, but there is little doubt they are derived from the epithelial cells of the dental lamina or tooth-band.

The gum is very poorly supplied with nerves, as its well-known lack of sensibility would indicate, but it has an abundant vascular supply.

Simple mucous glands are abundantly found in the gum tissue.

REFERENCES

1. Black, G. V. *Periosteum and Peridental Membrane*, chap. x.
2. Malassez, L. 'Sur l'existence d'amas épithéliaux autour de la racine des dents,' etc., with appendix on the so-called Alveolar Periosteum. *Archives de Physiol.*, 1885, Sér. 3, vol. v, pp. 129-48.

CHAPTER VIII

THE TOOTH FOLLICLE AND ITS CONNEXIONS

IN the present chapter it is proposed to consider the histology of the permanent tooth follicle and the sheath of Hertwig, which is intimately connected with it.

The Follicle. As shown in Chapter I, the tooth is enclosed in a sac within the bony crypt of the jaw. This sac is composed chiefly of connective tissue derived from the outer layer of the mesodermic dentine papilla, and surrounds the whole tooth, including the enamel germ. This extension of the papilla is generally described as an upgrowth from its margins, which is continued until it meets over the contained tooth germ, thus completely enclosing it. Whether, however, such upgrowth really occurs is somewhat doubtful, and Tomes considers it is more probable that the tissue in which the dentine organ is formed has become 'more pronounced', that the follicle is in fact formed by a condensation of the connective tissue in the neighbourhood of the tooth germ.

The bony crypt of the temporary teeth does not completely surround the tooth, but is open at the top, and is more comparable to a deep groove than a closed crypt. The follicle can be easily separated from the bony crypt and from its attachment to the tissue of the gum, and removed as a separate sac, the mucous membrane of the gum remaining undisturbed, as explained in the chapter on Development, p. 11.

The dental follicle of the temporary teeth has been very fully described by Magitot (8) in collaboration with Robin and with Legros, (6) and the epithelial elements were first fully investigated by these authors and by Malassez, the latter having specially studied the remnants of the tooth-band in connexion with the occurrence of epithelial tumours in the depth of the jaws.

Malassez (7) showed that independently of the epithelial process, which develops into the enamel organ, the tooth-band

produces other buds, and that there is a growth or proliferation of these buds within the follicle.

He divides these epithelial products into three principal groups, including those found in the connective tissue of the capsule between the follicle and the surface :

1. A superficial group attached to the deep surface of the epithelium of the gum.

2. An intermediary group situated between the mucous membrane and the follicle.

3. A deep group connected with the enamel organ.

Under the first group he includes products composed of cells of the Malpighian type and other club-like collections and strands of cells which have a cylindrical form.

In this layer are found the epithelial bodies spoken of by the French authors as 'globes épidermiques'. These have been further studied by Warwick James in a paper on the eruption of the teeth (5), who gives them the more descriptive term of 'epithelial coils'. These coils appear to originate from the club-like cell accumulations which bear a strong resemblance to the cell nests in epithelioma, and can be seen in various stages of transition in the epithelial coils.

In the later condition of the epithelial coil it is difficult to trace in its structure any indication of the epithelial cells, and it has more the appearance of being made up of concentric layers of a delicate connective tissue, but the stages of development shown in figs. 202, 203, 204, make its epithelial nature quite evident. These epithelial coils open out more and more until at last, near the surface of the gum, the concentric striæ have disappeared, and they merely remain as wide spaces in the connective tissue and open on the gum surface.

Warwick James considers they take an important part in the eruption of the temporary teeth, causing the tissues to give way and open out to form a channel for the erupting tooth. A similar function is assigned by Malassez to the epithelial strands found in the gubernaculum of the permanent teeth (see p. 21). It is probably these bodies in the gum which Serres described as glands.

The intermediary group is situated between the mucous

membrane and the dental follicle, and the cellular masses are seen to form a kind of band or irregular network (see

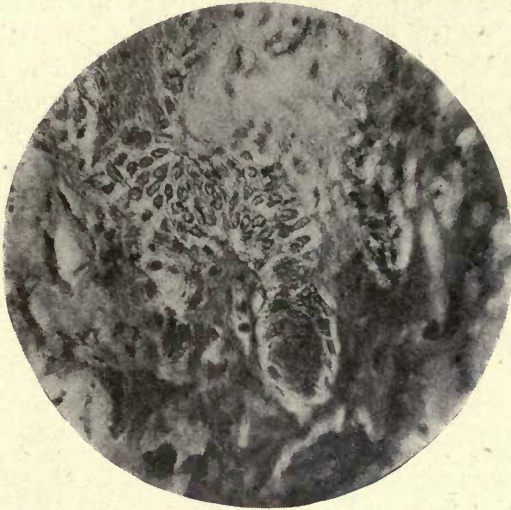


FIG. 201. Elongated mass of epithelial cells in follicle. ($\times 350$.)

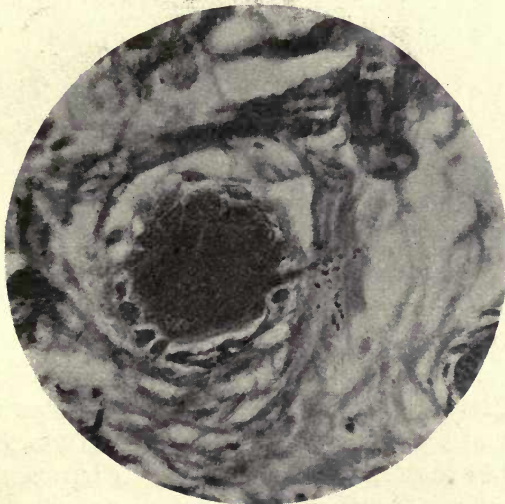

FIG. 202. Cell nest in follicle. Early stages of epithelial coil. ($\times 350$.)

fig. 201); these strands communicate with the prolongations of the mucous membrane, and also with cells deeper placed

and within the follicle. Epithelial coils are sometimes present among the cells of this group.

The third group of epithelial products, which is found within the follicle itself, is chiefly derived from the enamel organ and the buds which separate from it, but is also in connexion with the cells of the intermediary group.

It was shown both by Robin and Magitot and by Malassez, that the external epithelium of the enamel organ does not form a continuous investment, but in many places shows

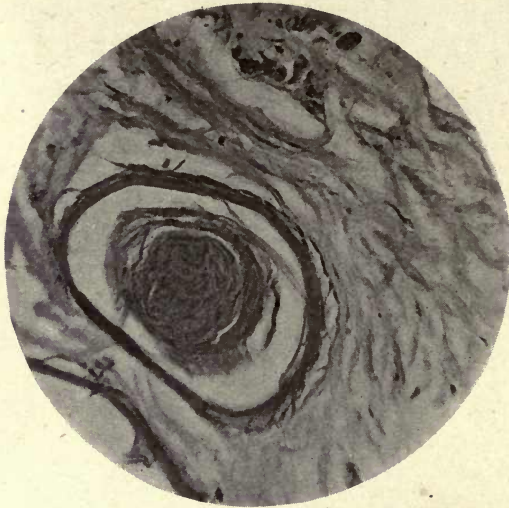


FIG. 203. Epithelial coil. ($\times 150$.)

openings or intervals penetrated by blood-vessels, which thus come to lie upon the outer cells of the stellate reticulum and in direct contact with them.

The external epithelium is also seen to give off conspicuous buds from its outer surface (fig. 205). It is thus seen that the epithelial cells present in the follicle of the temporary tooth and in the tissue which intervenes between this and the mucous membrane of the gum are abundant, and, far from degenerating, are proliferating in this situation.

The broad band of epithelium which forms the neck of the enamel organ, derived from the tooth-band, becomes broken up as previously described (Chap. I), and the con-

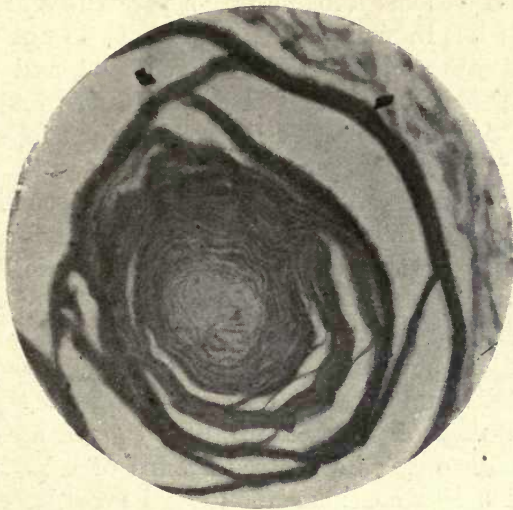


FIG. 204. Epithelial coil (globe épidermique). ($\times 150$.)

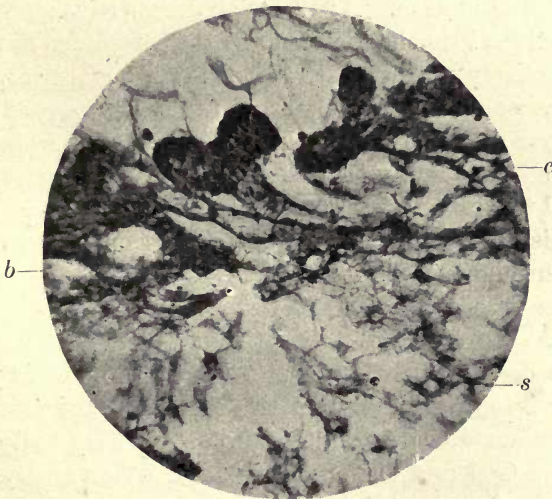
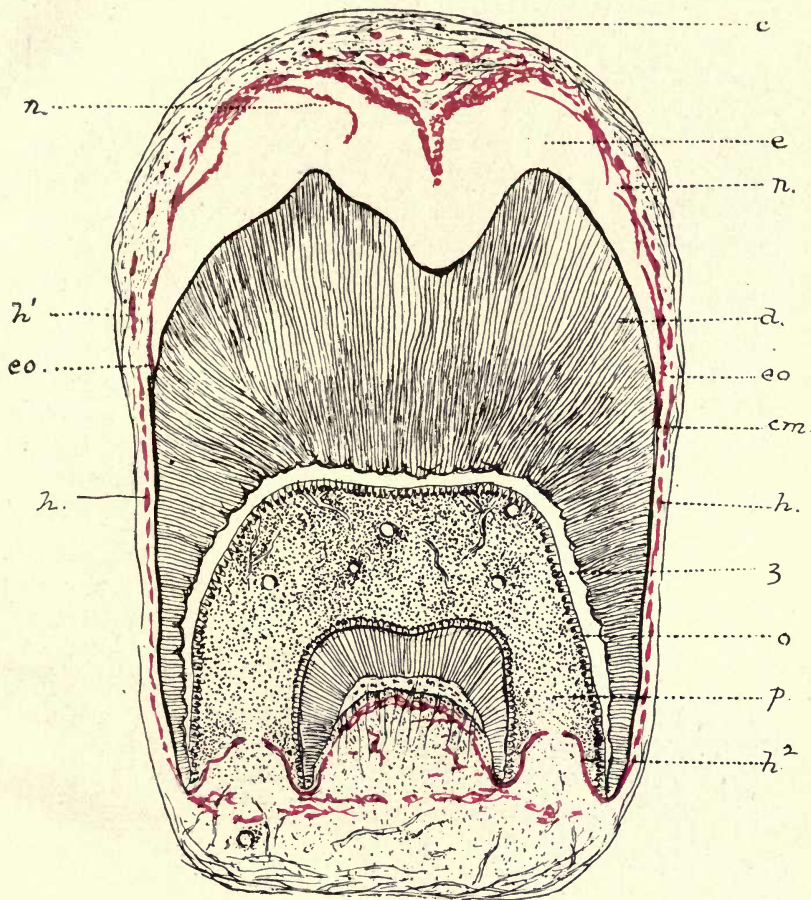


FIG. 205. Budding of the external epithelium (human tooth). *s.* Stellate reticulum; *e* external epithelium; *b.* blood-vessels. (Photograph from a preparation by Mr. W. James.) ($\times 150$.)

necting bridges with the neighbouring teeth and with the tooth-band become broken up, separated, and partially absorbed; but in many places these cells do not disappear but proliferate within the connective tissue, and are found in the different forms described by Malassez and Magitot. Malassez described these cell proliferations in connexion with the formation of tumours in the gum and periodontal membrane, and did not fully recognize their true histological and physiological significance; but he was the first to show that not only in the coronal part of the follicle but in the periodontal membrane surrounding the root of the tooth such epithelial remains are found.

As will be shown later, the epithelial masses in the periodontal membrane are also derived from the cells of the upper part of the follicle, and although seen in fully formed teeth only as separated groups of cells, are really the remains of a continuous epithelial layer known as the sheath of Hertwig, as was first pointed out by Von Brunn.

The follicle of the permanent teeth just prior to eruption does not appear to have been hitherto very fully described, chiefly owing to the difficulty of obtaining suitable material for the investigation. As Warwick James says: 'Previous investigations into the histology of these remains have been almost entirely restricted to foetal tissues; after birth they have been considered chiefly from the standpoint of pathology;' and he further says: 'The authors' (referred to above) 'seem to imply that the primary connexion with the epithelial tooth-band is lost, and that a secondary connexion is established between the buds of the epithelium which extend throughout the follicle.' Warwick James considers that 'the proliferation and formation of buds indicates a continuous growth, which continues with variable activity until the eruption of the teeth takes place'. This process certainly appears to occur in the follicle of the permanent teeth, although Legros and Magitot state that 'all end by being absorbed and disappearing', and other authors, probably referring to this statement, have concluded that nothing remains in the follicle prior to eruption but connective tissue and tiny masses of epithelium, the so-called glands of Serres.



Molar tooth in the follicle—semi-diagrammatic. *c.* Connective tissue of the capsule; *e.* position of enamel; *d.* dentine; *cm.* cementum; *h.* Hertwig's sheath; *h¹.* continuation of Hertwig's sheath; *h².* inflexions of Hertwig's sheath around the forming roots; *n.* partially detached layers of cells forming Nasmyth's membrane; *eo.* termination of enamel organ at neck of tooth; *z.* odontogenic zone; *p.* pulp; *o.* odontoblasts. (The epithelial elements are coloured red. $\times 8$.)

It is clearly seen in the author's preparations of the permanent tooth follicle that, far from this being the case, the epithelium at this late stage is present in great abundance, and Warwick James's conclusion with regard to the temporary teeth is no doubt also true as regards the permanent, that 'the epithelium is produced continuously up to the period of eruption', and that while some cells are proliferating, others are degenerating, those immediately over the enamel organ appearing to be undergoing degenerative changes, while those in the centre of the follicle would seem to be in a normal, active condition.

There are probably some differences in the arrangement of the epithelial tissue within the follicle of the permanent teeth, as they are more completely enclosed within the bony crypt than are the temporary teeth, and thus further cut off from the oral epithelium and its extensions.

The author had an excellent opportunity of studying the histology of the follicle of the permanent tooth in a specimen kindly given to him by his friend Mr. Dolamore. This, a lower second molar entirely enclosed in the follicle and freshly preserved in formol, enabled him to procure a series of sections by the freezing method, including the whole width of the tooth, and the connexion of the follicle with the tooth at the neck was fortunately maintained, the enclosed area representing the calcified enamel (which had been decalcified in formic acid). These preparations of the follicle are represented by the drawing on Plate V, which, though semi-diagrammatic, accurately shows the relations and connexions of the tissues as seen in the sections.

Apart from the epithelial cells, two rather remarkable appearances are met with in the follicle. Calcified masses of irregular shape are seen in the centre (fig. 206). These are within the connective tissue and not in contact with epithelium. The calcification encloses small rounded or fusiform cells which do not resemble osteoblasts, but appear to be the unaltered connective-tissue cells of the surrounding tissue. These small masses are exactly similar in structure to the calcified bodies in the centre of the pulp in many teeth (see fig. 153). They do not appear to show the structure of

cement, and are always well separated from the inner epithelial layers.

The other noticeable appearance is the presence of a fenestrated membrane-like expansion which is seen only opposite the sulcus between the cusps of the molar tooth (fig. 207). It is difficult to decide what this membrane represents; if it forms a portion of the inner layer of Nasmyth's membrane it is difficult to account for its fenestrated nature, as the clear layer in preparations of the membrane is never

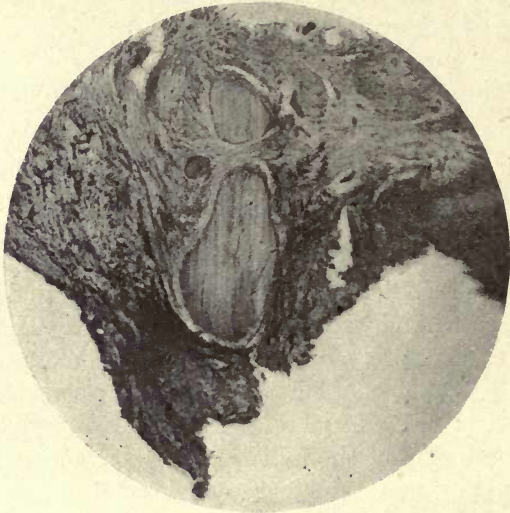


FIG. 206. Calcified masses within the follicle at its centre. ($\times 50$.)

fenestrated but entire. The openings in the membrane are of very unequal sizes, and the whole structure appears to be of a stouter and tougher nature than the thin fenestrated membrane which can be raised from the enamel surface, especially in marsupials.

At the point of junction with the tooth, the follicle is narrow and composed of strong connective tissue. Epithelial cells are present in this narrow part of the follicle, and can be traced upwards to its coronal portion, where they are in great abundance, and can be seen in all stages of growth and degeneration.

It is noticeable that the epithelial masses appear to have

no connexion with the connecting band or bridges; they appear to form, as Warwick James suggests they do in the temporary tooth follicle, a secondary system established by the anastomosis of the buds, and in the permanent tooth follicle they are apparently cut off from connexion with the oral epithelium.

Figs. 208, 209, 210 show the broad masses of epithelium at the inner margin of the follicle, the positions of which are indicated in the diagram.

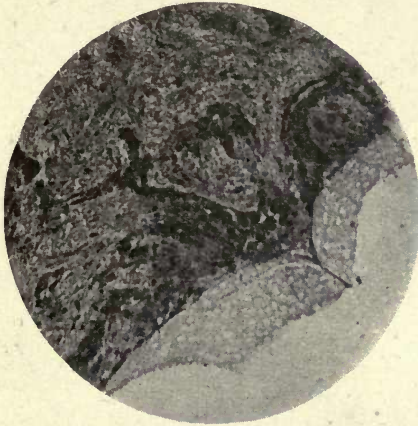

FIG. 207. Fenestrated membrane at the centre of the follicle margin at the point where a prolongation of the cells passes between the enamel cusps. ($\times 750$.)

It is seen that while some of these cells, especially those in contact with the enamel organ, are flattened and arranged in many layers, deeper in, a network of epithelial cells is present which show no apparent signs of degeneration. In fig. 209 it can be seen that rounded cell accumulations are present, resembling cell nests, and in many places show multiple nuclei. They are apparently undergoing amitotic division in this situation, and it has been shown that this form of cell division in which the nucleus divides with or without the division of the cell body is generally found in stratified epithelia when undergoing degenerative changes such as keratinization.¹ In this case there is no division of the cell body but merely of the nucleus, and in many cells

¹ Schafer, E. A., *Microscopic Anatomy*, p. 96.

the author has been able to detect as many as eight nuclei in an individual cell, as shown in the description of Nasmyth's membrane.

The most striking point in these preparations is the great abundance of epithelium, and this in a stage when the enamel is completed and the tooth about to erupt; they also show that Nasmyth's membrane is attached at this stage to the inner margin of the follicle, although in most places its connexion is very slight and it is easily detached.

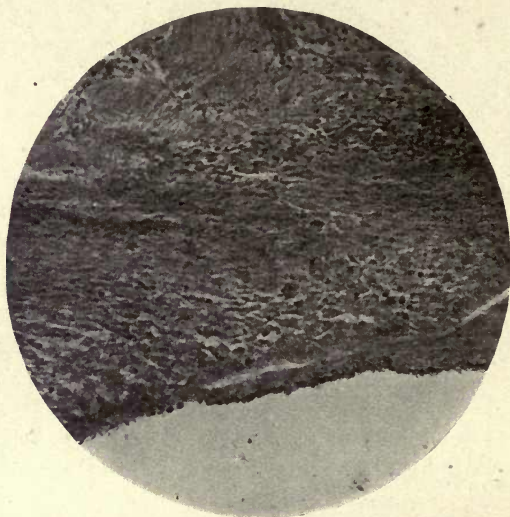


FIG. 208. Mass of epithelium at inner margin of follicle. Some portions of last-formed enamel still attached. ($\times 150$.)

This point is further considered in describing Nasmyth's membrane.

The Sheath of Hertwig. Although it was long ago shown that an epithelial investment of the whole tooth is found in mammalian teeth, the real importance and significance of this discovery has scarcely been sufficiently recognized.

Not only is the enamel laid down by epithelial cells, but the growing dentine, although a mesodermic product, is also under the influence of an epithelial organ, the 'sheath of Hertwig', and, as will presently be shown, it would appear that the conclusion of Von Brunn that where there is 'no

epithelial sheath there are no odontoblasts and no dentine formation' is probably correct, and is also true for the teeth of man, and it is demonstrated that the forming tooth



FIG. 209. Epithelium at inner margin of follicle. Cell nests and multiple nuclei. ($\times 150$.)

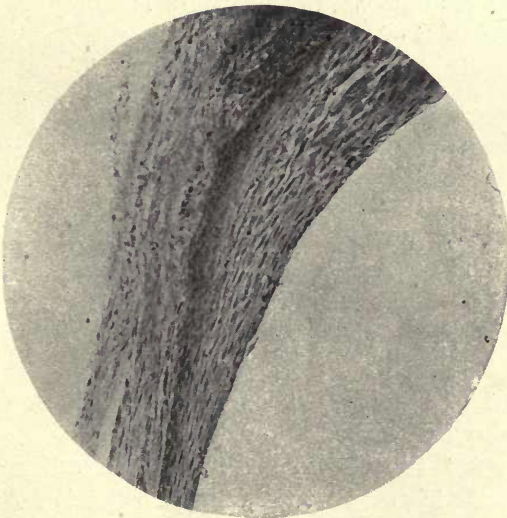


FIG. 210. Inner margin of follicle. Flattened epithelial cells at lateral margin. ($\times 150$.)

is surrounded by an investing open-meshed network of epithelium which extends from the upper or coronal part of the follicle, enveloping the forming roots on their outer aspect.

It was shown by O. Hertwig (4) that in certain amphibia the teeth are more or less surrounded by an epithelial sheath or investment, and Von Brunn (2), carrying the investigation farther, showed that in many mammalian orders such an epithelial sheath exists; in fact in all the specimens examined, which included those of Rodents, Ungulates, and Carnivora. He concluded, from his observations, that the epithelial sheath which surrounds the roots of the forming teeth really determines the deposition and limits of the dentine, and as it were moulds the dentine of the roots, confining it within certain limits and preventing its extension into the surrounding connective tissue. He says that where there is no Hertwig's sheath there are no odontoblasts and no dentine, that it is in fact the moulding or determining organ of the dentine of the root. He was unable to find this sheath in human teeth, and although its presence in Mammalia seemed to indicate that it must be present also in man, the material at his disposal did not show it.

The preparations of human teeth made by Professor Von Ebner also failed to reveal it, but both he and Von Brunn concluded that it must be present, and would be seen if suitable preparations could be made (3).

It was considered by Von Brunn, in common with all those who have described this sheath in Mammalia, that it was produced by a downward growth of the inner and outer layers of the enamel organ, the function of which, they considered, was not only the formation of enamel but also that of determining the limitation of the growth of the dentine.

The author's preparations of the follicle and tooth in position above described would appear to show, however, that on this point the previously mentioned authorities were mistaken. It is seen that the enamel organ is not prolonged beyond the point where the follicle is attached to the tooth at its neck, but that the enamel organ terminates where the enamel terminates. This is seen not only in all the sections

from this one specimen but in several other less perfect preparations of the follicle procured, and an investigation of a Rodent developing tooth for comparison confirms the conclusion arrived at. In the mouse, which was one of the animals examined by Von Brunn, it is seen that the enamel organ terminates at the point of junction of the follicle with the tooth, and is clearly not continued downwards on to the roots (fig. 211).

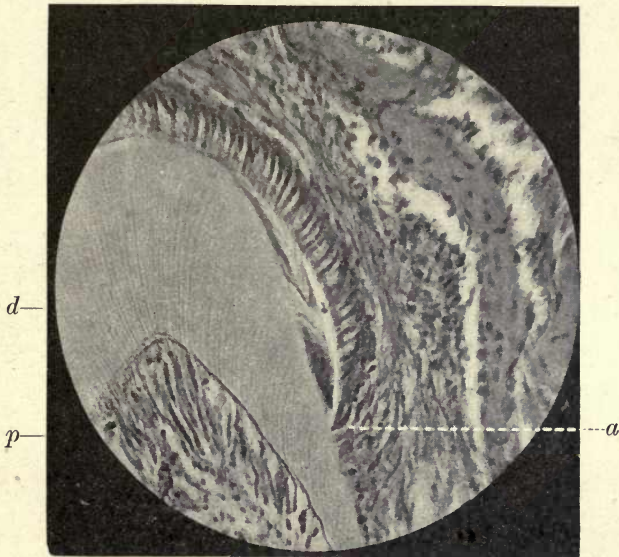


FIG. 211. Developing tooth of Mouse. *a*. Termination of enamel organ at the point where the enamel terminates: the space occupied by the enamel, of which some portions have escaped complete decalcification, is contracted by disturbance of the section in cutting; *d*. dentine; *p*. pulp. ($\times 400$.)

It would appear that the great difficulty of obtaining sections showing the attachment of the follicle with distinctness has led to this misinterpretation of the conditions. Especially in the tooth germs of the lower animals with their irregular crowns it is very difficult to be sure of the exact relations of the follicle to the tooth, but in the simpler teeth of man it is very clearly visible in complete longitudinal sections.

We thus see that the sheath of Hertwig is not a downward extension of the cells of the enamel organ, and we have to look elsewhere for its origin.

In figs. 212 and 213 the strand of cells composing the sheath can be seen passing to the outside of the enamel at the point of junction of the follicle with the tooth, and the termination of the cell layers of the enamel organ is distinctly

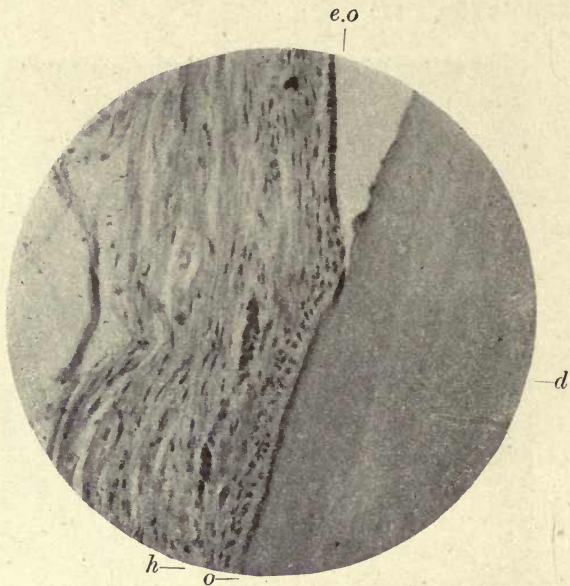


FIG. 212. The junction of the follicle with the tooth at the neck. *e.o.* Enamel organ; *h.* Hertwig's sheath passing to the outer side of enamel organ; *o.* osteoblasts and thin layer of cement; *d.* dentine. ($\times 150$.)

visible. It is seen that the sheath of Hertwig has no connexion whatever at this point with the enamel organ, but is completely shut off from it within the connective tissue of the follicle.

The strands of epithelial cells of which the sheath is composed pass to the coronal part of the follicle, and appear to be derived from the cell elements which are there present in such abundance.

While these cell extensions are plainly seen at the neck of the tooth passing to the outer side of the terminal portion of the enamel organ, they cannot be traced very far into the

tissues of the follicle above, as these tissues are very much narrowed just above the line of junction (see fig. 210 and Plate V) with the tooth, and the nests of epithelial cells are much compressed and obscured by the dense bands of connective tissue; also it must be remembered that in the upper part of the follicle these epithelial cells have ceased their functional activity and are probably undergoing absorption, while lower down, around the root, they are active and

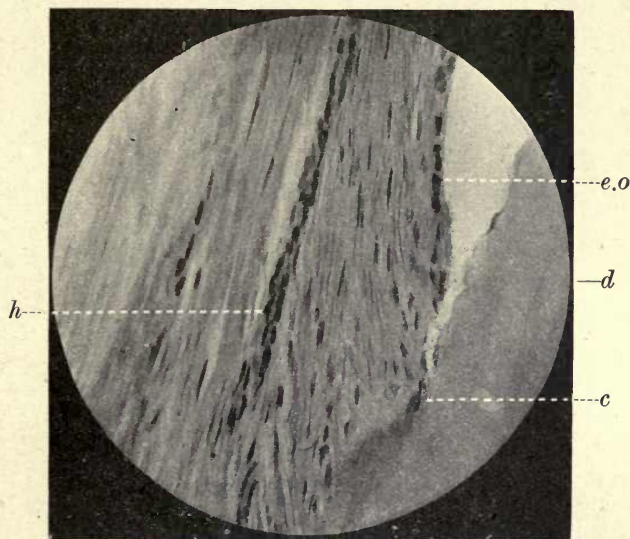


FIG. 213. Junction of follicle and tooth under higher magnification from a similar preparation. *h.* Hertwig's sheath; *e.o.* enamel organ; *c.* cement; *d.* dentine. ($\times 400.$)

fully developed during the formation of the dentine and cement of the growing root.

With regard to the actual sources of these cells, they are probably derived from proliferations of the tooth-band within the follicle, and possibly also from the buddings or proliferations of the external epithelium of the enamel organ with which the epithelial cells of the follicle form connexions. See fig. 205.

In young teeth with forming roots, the sheath of Hertwig is seen passing down the side of the root parallel to its surface but not in contact with it, and is a more or less

continuous band, often arranged as a distinct network, so that the tooth at this stage is enclosed in an epithelial net with open meshes. The sheath is continued to the forming root tip, and as it nears this point it approaches more closely to the dentine; the network arrangement is not seen, but two distinct layers of epithelial cells in close contact, which at the tip of the root lie upon the dentine and turn round it to extend into the connective tissue of the forming pulp in a long curling band, the termination of this band being

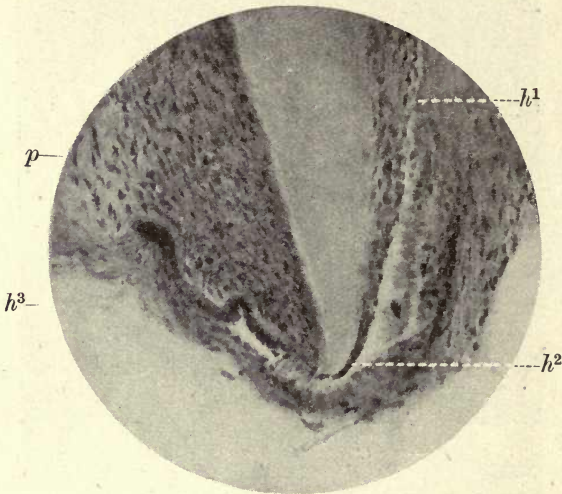


FIG. 214. Hertwig's sheath surrounding forming root. Root about half formed. The sheath is seen to be in contact with the dentine at the lower end (h^2); the osteoblasts and depositing cement are seen to the inner side of h^1 ; h^3 , the curling band of Hertwig's sheath separating the pulp (p) from the connective tissue of the follicle. ($\times 150$.)

formed by the reflection of the two layers of cells, which form a close loop. A similar loop is continued from the opposite side of the root tip, but these two loops do not meet, but leave a space between them occupied by the developing pulp with its entering nerves and blood-vessels. It can be seen in figs. 214, 215, and 216 that the odontoblasts and the forming dentine are completely cut off from the surrounding connective tissue of the follicle by this epithelial band. An examination of the forming root at different stages of growth shows that this epithelial inflection in man gradually shortens

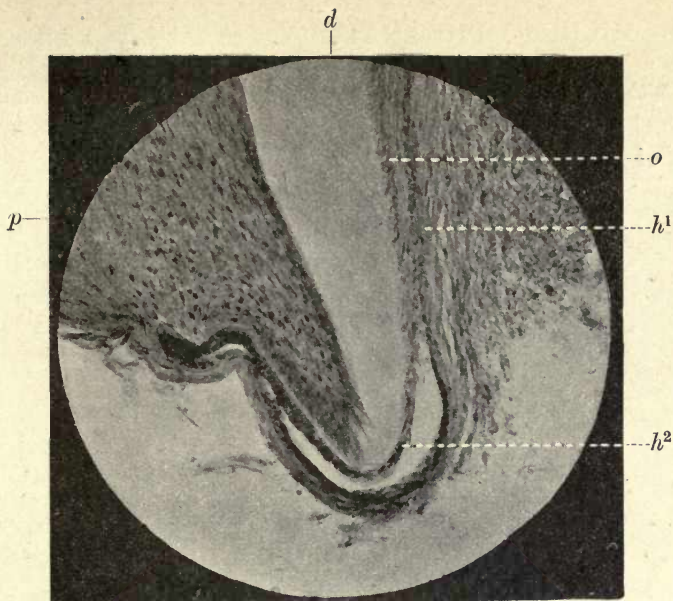


FIG. 215. Root tip at later stage. Shortening of the epithelial sheath. *o.* Osteoblasts; *h*¹. Hertwig's sheath; *h*². Hertwig's sheath in contact with the dentine; *d.* dentine; *p.* pulp. ($\times 150$.)

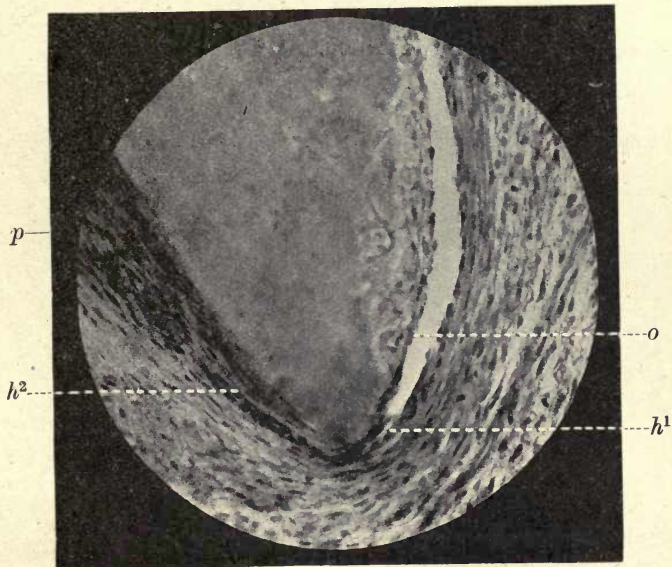


FIG. 216. Root tip at still later stage. Involution of Hertwig's sheath much shortened. *o.* Osteoblasts and osteoclasts in forming cement; *h*¹. Hertwig's sheath in contact with dentine; *h*². termination of sheath in pulp (*p.*). ($\times 150$.)

as the development of the root progresses, until when the apical foramen is completely formed it only just reaches the tip of the root (fig. 217).

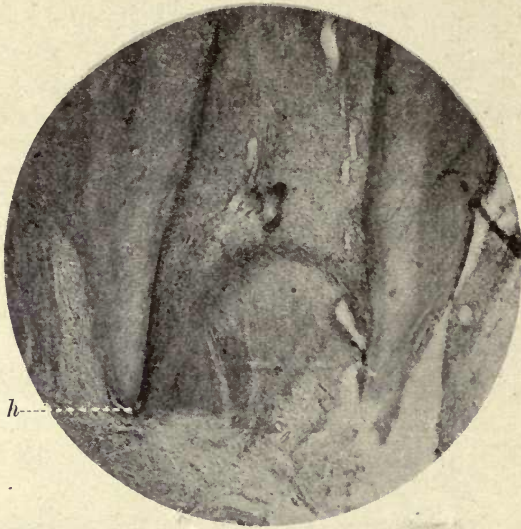


FIG. 217. From a specimen in which the root was nearly completed. The epithelial band (*h.*) only just turns round the root tip and does not enter the pulp. *h.* Hertwig's sheath.

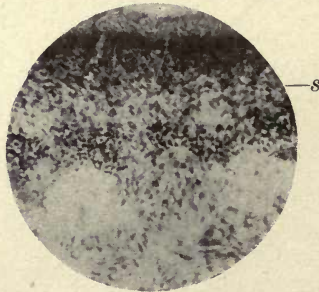


FIG. 218. Hertwig's sheath (*s.*) around root of molar. ($\times 50$.)

There is thus every evidence that in man also the epithelial sheath is the determining or moulding organ of the dentine of the root, as claimed for the lower Mammalia by Von Brunn.

Between the roots of a molar tooth not only is the sheath seen in the neighbourhood of the dentine, but a band of

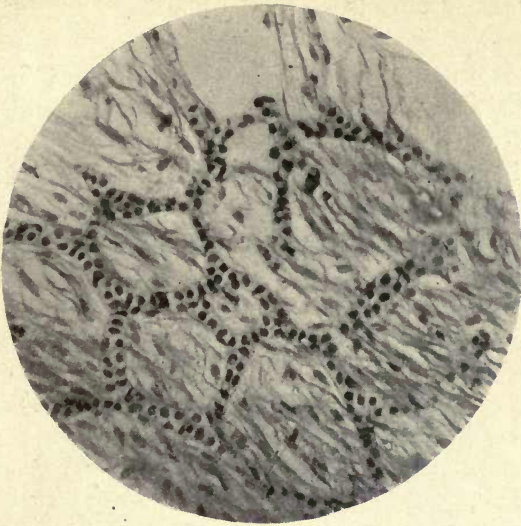


FIG. 219. Epithelial sheath beneath root in nearly completed tooth. Network of epithelial cells. ($\times 250$.)

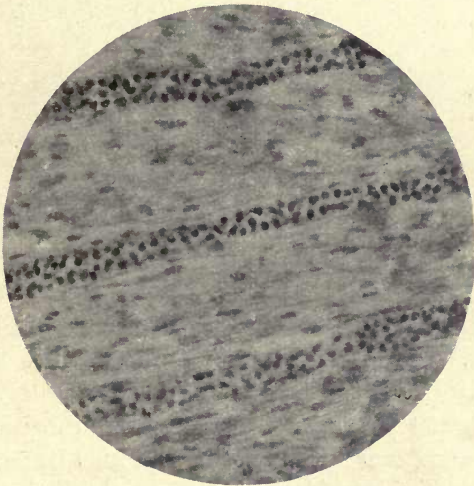


FIG. 220. Bands of epithelial cells of Hertwig's sheath beneath root of growing tooth. ($\times 250$.)

epithelium passes directly across beneath the two root tips. In this interval between the roots the sheath is often seen to form a very dense network, and scattered epithelial

cells are also found in the neighbouring connective tissue (fig. 218).

The network in this situation is well shown in fig. 219, and fig. 220 shows parallel strands of epithelium at a farther distance from the root end.

In one instance a large mass of epithelium resembling the accumulations in the coronal part of the follicle was seen within the connective tissue below the roots. The larger strands forming the network often appear to have a limiting

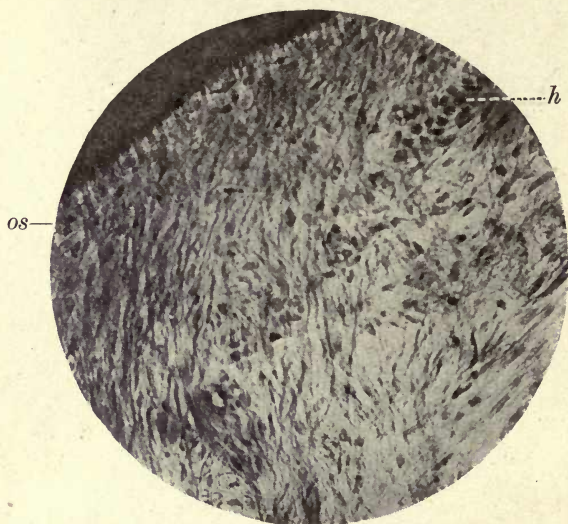


FIG. 221. The breaking up of the network of Hertwig's sheath by invading connective-tissue fibres of periodontal membrane. *os*. Osteoblasts and forming cement; *h*. remains of Hertwig's sheath. ($\times 250$.)

membrane as if they were enclosed in a tube. This appearance, however, is probably due to union of the cell walls of contiguous cells.

If the sheath is traced upwards from the root tip it is seen to become less and less a continuous band, being cut up and separated into isolated groups of cells by the invading connective-tissue bundles of the periodontal membrane, which pass between them to become attached to the forming cement as Sharpey's penetrating fibres; these with the osteoblasts lie to the inner side of the sheath and continue the formation of the cement (fig. 221). Many of these

isolated groups of epithelial cells disappear, but in most adult teeth a few can be seen in the periodontal membrane at the side of the tooth, and in many cases they are met with in great abundance.

Summary

It has thus been shown that the enamel organ proper is not continued downwards to form the Hertwig's sheath, that the enamel organ terminates at the point of termination of the enamel, and that the sheath is a prolongation of other epithelial cells in the follicle which lie to its outer side. It is shown that in man, as in other Mammalia, there is every evidence that it moulds and determines the dentine of the root, and is always present where dentine is laid down.

As it is shown that the sheath is not the continuation of the enamel organ, it may be considered that two separate epithelial organs are formed from the tooth-band and the cells derived from it—the enamel organ, which is especially differentiated to form enamel, and the epithelial sheath, which is the form-determining organ of the dentine.

The enamel which covers the exposed part of the tooth is an epithelial product derived from the ectoderm; the dentine and cement are products of the mesoderm; but the whole tooth is surrounded at different stages of its growth by an ectodermic structure, the sheath of Hertwig.

It can, therefore, consistently be maintained that the formation of the whole tooth depends upon the proliferation of the ectodermic epithelial elements. The two structures would have a common origin, but while one presides over the formation of the enamel, the other is developed for the determination and limitation of the growth of the dentine, and as the enamel organ atrophies when the enamel is completed, and only persists as the cornified cells of Nasmyth's membrane, so the epithelial sheath becomes absorbed after the complete deposition of the dentine, and only a few epithelial cells remain as the epithelial débris of Malassez.

It has been stated by several authors, especially by C. S. Tomes (9), that in the Edentata an enamel organ is present, although no enamel is formed, and in a paper published in 1876 he showed the presence of enamel organs

to be universal and quite independent of any after-formation of enamel. The question arises as the result of the observations above recorded, if this epithelial organ in the Edentates can be properly called the 'enamel organ'.

It is an arrangement of epithelial cells which no doubt bears a strong resemblance to an enamel organ, but the function of these cells is not that of enamel production; and as it has been shown that in all Mammalia examined and in some other Vertebrates (by Hertwig) that an epithelial sheath is present, we should conclude that it cannot be absent in the Edentates, and is in them also the dentine limiting organ, probably having no relation to the formation of enamel either as a functional or vestigial characteristic.

A paper on the enamel organ of the Edentates was published by Ballowitz in 1892 (1).

REFERENCES

1. Ballowitz, E. 'Das Schmelzorgan des Edentaten, seine Ausbildung im Embryo und die Persistenz seines Keimrandes bei dem erwachsenen Thiere.' *Archiv f. Mikr. Anat.*, 1892, Bd. xl, pp. 133-57.
2. v. Brunn, A. (a) 'Ueber die Ausdehnung des Schmelzorganes in seiner Bedeutung für die Zahnbildung.' *Archiv f. Mikr. Anat.*, 1887, Bd. xxix, pp. 367-83.
(b) 'Beitrag zur Kenntniss der Zahnentwicklung.' *Archiv f. Mikr. Anat.*, 1891, Bd. xxxviii, pp. 142-56.
3. v. Ebner, V. *Handbuch der Zahnheilkunde*, Wien, 1890, pp. 252-4.
4. Hertwig, O. 'Ueber das Zahnsystem der Amphibien und seine Bedeutung für die Genese des Skeletts der Mundhöhle.' *Archiv f. Mikr. Anat.*, Bd. xi, Suppl., 1874.
5. James, W. W. 'A Preliminary Note on the Eruption of the Teeth.' *Proc. Roy. Soc. Med.*, 1909.
6. Legros et Magitot. 'Origine et formation des follicules dentaires chez les Mammifères.' *Journ. de l'Anat. et de la Physiol.*, vol. iv, 1873.
7. Malassez, L. 'Sur le rôle des débris épithéliaux paradentaires.' *Archives de Physiol.*, Paris, 1885, 3^e sér., v. 309-40, and vi. 379-449.
8. Robin et Magitot. 'Genèse et développement des follicules dentaires.' *Journ. de Physiol.*, vol. iv, 1861.
9. Tomes, C. S. 'On the Development of the Teeth of the Newt, Slow-worm, Frog, and Green Lizard.' *Phil. Trans. Roy. Soc.*, 1876, vol. clxv, pt. i, pp. 285-96.

CHAPTER IX

NASMYTH'S MEMBRANE

NASMYTH's membrane, or the enamel cuticle, is a very delicate membrane which can be detached from the surface of the enamel by the action of acids, but which is not otherwise visible to the naked eye.

The nature of this acid-resisting membrane was for a long time a matter of controversy. It was called by Nasmyth the persistent dental capsule, but this designation does not suitably describe its anatomical relations, as it has been conclusively shown to be in its principal part an epithelial product, and the connective tissue of the capsule appears to have no part whatever in its formation.¹ The view that Nasmyth's membrane consisted of cement was held by Professor Owen, who says, speaking of human teeth (5), the cement 'is thinnest upon the crown, and very gradually increases in thickness as it approaches the end of the fang; it is only on the implanted part of the tooth that the radiated cells which demonstrate the close analogy between cement and bone exist; elsewhere the clear basis of the cement alone is present, and this is soon worn away from the enamel of the crown'. It was also considered by Sir John Tomes (9), and afterwards in the earlier editions of the *Dental Anatomy* by C. S. Tomes, that this membrane represented a thin layer of cement (10) corresponding to the layer of cement covering the enamel in Ungulates. The chief argument in favour of this view brought forward by these authors was that encapsuled lacunæ occurred in the fissures of enamel in many instances, the very great overlapping of the enamel by the cement which is occasionally, but rarely seen in human teeth, and which would appear to be of a pathological nature, lending further evidence in support of this view. Professor Huxley (3) considered that Nasmyth's

¹ A paper on 'The Presence of the Sheath of Hertwig in the Teeth of Man, with Notes on the Follicle and Nasmyth's Membrane', was communicated to the Royal Society by the author in 1918.

membrane was the 'membrana preformativa' between the enamel organ and the forming enamel, and Lent (4) in 1853 was of the same opinion. Nasmyth was the first to show that a membrane could be raised from the surface of formed enamel which had not been exposed to wear.

Kölliker held that the membrane was a final product of the enamel cells, while Waldeyer considered it was derived from the external epithelium of the enamel organ. The true histology of the membrane had, however, never been demonstrated until Dr. Paul published his researches (6). He separated the membrane from the tooth by immersing it in acids, employing in his first experiments 5 per cent. nitric acid, and stripped it from the enamel, staining with silver nitrate or with eosin, but later found he obtained better results by decalcifying in phloroglucin and staining in Ehrlich's hæmatoxylin.

These preparations demonstrated that Nasmyth's membrane consists of two distinct layers—an inner clear layer in immediate contact with the enamel, and lying upon this a layer or layers of epithelial cells which from their position must have been derived from the enamel organ.

In former observations on this membrane it had been considered that the polygonal markings observed upon the clear layer of the membrane were the impressions of the enamel prisms, but Dr. Paul points out that these markings are very many times larger than those caused by the enamel prisms, which can also be seen in the clear layer.

It can be seen, as shown in fig. 222, that the epithelial cells are distinctly visible upon the upper surface of the membrane, while the impressions of the enamel prisms from beneath are also visible, and are seen in this figure in the same field of the microscope as the cells and their impressions. It needs no measurement to show the great disproportion of size between the two sets of markings. The preparations from which these photographs were taken were made by the author from specimens prepared by a slightly different method from that employed by Dr. Paul. The membrane was floated off from the tooth in formic acid, the detached fragments being well washed and stained with Weigert's iron hæmatoxylin. •

There are certain appearances in many of these specimens not described by Dr. Paul in his original papers, and very difficult to explain on the assumption that the epithelial cells are those of the external epithelium of the enamel organ only, as they have previously been considered to be. These appearances can be, we think, clearly accounted for if Nasmyth's membrane is viewed in connexion with the follicle and studied in longitudinal section.

The clear layer is in direct contact with the enamel, and,

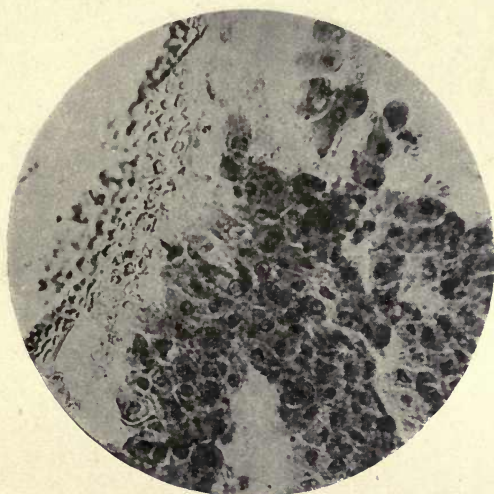


FIG. 222. Nasmyth's membrane, floated off the enamel in acid. Cellular and clear layers. Clear layer showing impressions of enamel prisms. ($\times 250$.)

as stated above, was considered by Kölliker to be a final product of the enamel cells, although he apparently did not recognize the double nature of the membrane.

Whether this be so or not it is difficult to say, but in the longitudinal sections a clear layer is often seen on the under side of the detached enamel organ cells, and refractile particles of enamel which have escaped complete decalcification are attached to it. This might suggest that the clear pellicle represents a membrane corresponding to the 'membrana preformativa' of Huxley or the internal ameloblastic membrane of Leon Williams.

It can be seen in fig. 223 that the outlines of the epithelial cells are impressed upon the clear layer in areas where the cells themselves are absent, and are distinctly visible on the upper surface of the clear membrane, while the impressions of the enamel prisms from beneath are seen at the margins. These impressions of the prisms are very distinct, and in many parts are arranged in parallel lines or striæ. There seems no doubt that the impressions so arranged indicate the structure of the enamel surface which produces them,

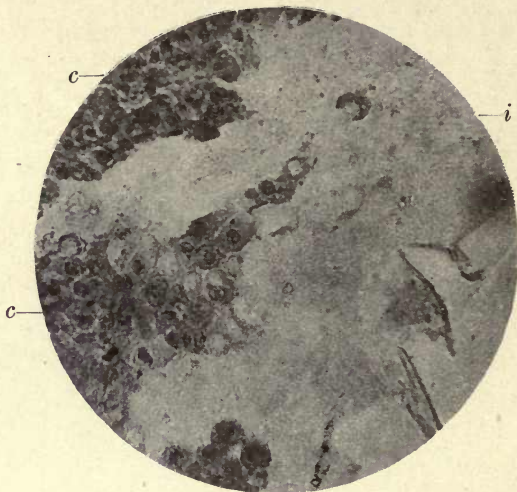


FIG. 223. Nasmyth's membrane showing impressions of cells of cellular layer on clear layer. *c.* Epithelial cells; *i.* impressions of cells on clear layer. ($\times 250.$)

showing that the enamel is not smooth, but is arranged in a series of ridges apparently produced by the outcrop of the enamel prisms (fig. 224). The impressions would appear to be produced by the incremental lines of Pickerill, which he considers with several other authors to give rise to the appearance of the striæ of Retzius in enamel.

That such imbrication lines are present in enamel is clearly shown by this moulding of the inner membrane upon them. In some specimens, where the clear layer is seen alone, having entirely separated from the cellular layer, this stratification is very marked. It was shown by Pickerill

that these imbrication lines are constantly present in the enamel of healthy teeth, and he drew attention to the fact that specimens of Nasmyth's membrane stained with silver nitrate show a distinct striation which he considered corresponds to the furrows between each imbrication line.

In fig. 224 the impressions of the individual prisms are clearly visible along these lines, which evidently in this case represent the summits of the ridges.

The Cellular Layers.—In some parts of the floated preparations a single layer only of epithelial cells is seen, but

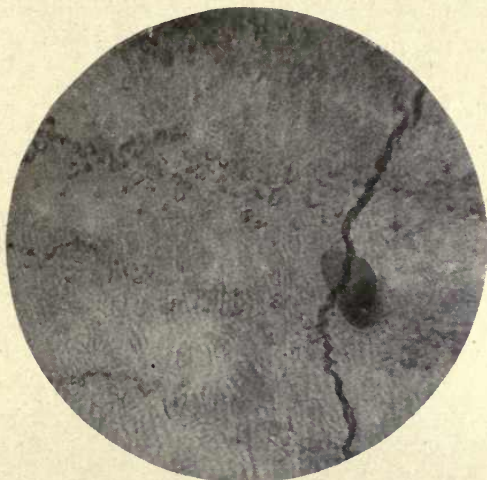

FIG. 224. Floated preparation of Nasmyth's membrane showing impressions of enamel prisms in parallel lines. ($\times 250$.)

in most places there are two or many layers. The cells vary considerably in size, so much so that an average measurement will not give any clear idea of their dimensions. They are mostly polygonal in outline, separated from one another by a distinct interval, as in epithelia elsewhere, and these channels are crossed by bridges or processes. These processes are in many cases very strongly marked, and in some parts, at the margins, quite thick horny projections from the cell are seen. According to several authors, this strongly marked fibrillation of the cell is intimately associated with the condition of keratinization (Schafer).

The cytoplasm of the cell body is clearly defined, and the

nuclei exhibit the ordinary nuclear structure with one or two strongly marked nucleoli.

As stated in describing the follicle, amitotic division of the nucleus without division of the cell body is apparent in many of these cells in the floated preparations, corresponding to the same appearances in the cells of the follicle itself (fig. 225). It is interesting to note that according to several authorities, and as stated by Dahlgren and Kepner, 'In nearly all stratified epithelia, especially in the higher vertebrates, the nucleus divides by mitosis to increase the number of cells, but it changes to amitosis without a division of the cell body in the latter part of the cell's life. The probable object is

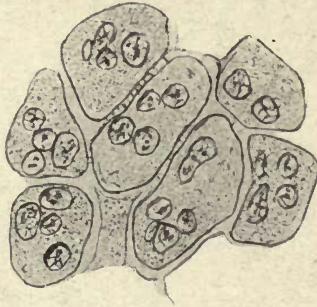


FIG. 225. Amitotic division in the cells of Nasmyth's membrane. Floated preparation. Camera lucida drawing ($\times 800$.)

to enlarge the nuclear surface for increased metabolism, the formation of keratin in this case' (2).

Wilson says (12), 'Those cells that divide amitotically are on the road to ruin,' and quotes Von Rath, who reached the conclusion that 'when once a cell has undergone amitotic division it has received its death warrant—it may indeed continue for a time to divide by amitosis, but inevitably perishes in the end'.

Certain areas of the membrane show accumulations of cells arranged more or less concentrically, and apparently surrounded by a delicate limiting membrane (fig. 226). Dense concentric bodies are also seen in parts of the membrane forming definite cell nests (fig. 227); these are very opaque and stain badly, and apparently represent a late stage in the degeneration and keratinization of the cells. Cells arranged in

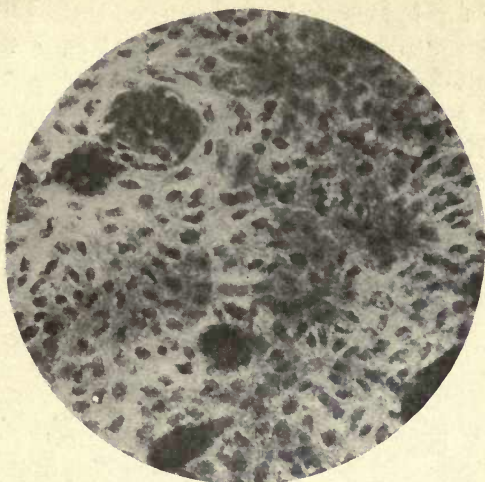

FIG. 226. Cell accumulations in a floated preparation of Nasmyth's membrane. ($\times 250$.)

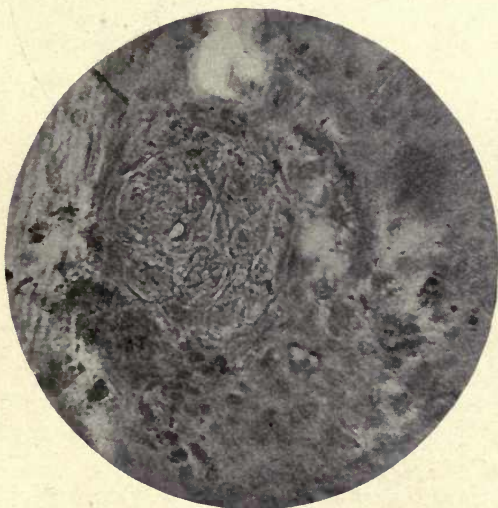


FIG. 227. Cell nest in Nasmyth's membrane. Floated preparation. (Compare with nest in follicle, fig. 202.) ($\times 250$.)

an extended series giving very much the appearance of tubes are also seen, and have every resemblance to similar cell extensions in the follicle. Scattered among the cells in these

preparations are elongated crescentic or thread-like bodies, which appear to be degenerated nuclei as described by Römer in altered epithelial cells.

In many parts of these preparations cells are seen which are quite different in appearance. They are elongated, with nuclei at their distal ends, and appear to be attached to the clear membrane by broad expansions; they have, in fact, a strong resemblance to altered and shrivelled ameloblasts (figs. 228 and 229). Owing to the method of preparation this

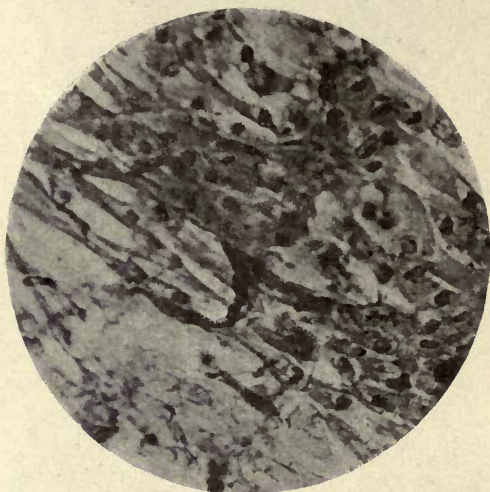

FIG. 228. Elongated cells in Nasmyth's membrane ($\times 250$.)

elongation of the cells cannot be due to stretching, and when these specimens are compared with those of Nasmyth's membrane seen in longitudinal section (figs. 230, 231, and 232), it seems impossible to avoid the conclusion that these are cells of the inner epithelium of the enamel organ which have undergone keratinization.

Passing to an examination of these longitudinal sections, it is seen that these appear to shed a new light on the nature and extent of the cells included in the membrane.

There have been considerable differences of opinion with regard to the persistence of the external epithelium in the later stages of calcification, some authors, as Professor Underwood (11), stating that it becomes blended with the

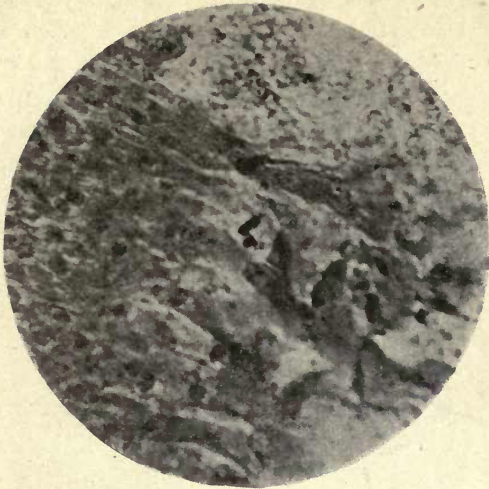


FIG. 229. Nasmyth's membrane. Elongated cells on membrane and impressions of enamel prisms on clear layer. ($\times 250$.)

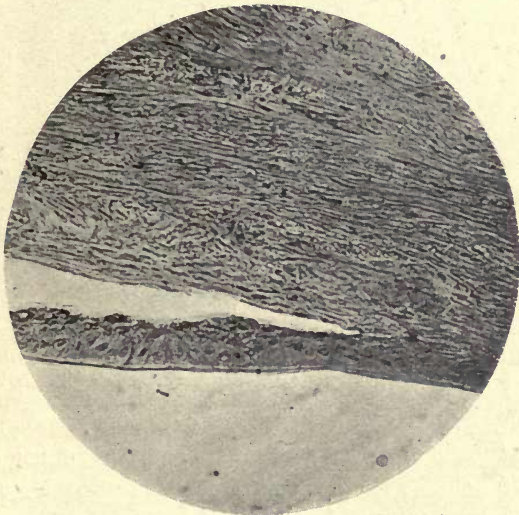


FIG. 230. Separation of the layers of the enamel organ from the follicle. ($\times 250$.)

capsule, others, as Legros and Magitot, asserting that the cells of the external epithelium of the enamel organ atrophy before the completion of the calcification of the enamel.

These preparations of the follicle show that both the external and internal epithelium persist up to the period immediately before eruption. The attachment to the cells of the follicle is very slight, and in most of the preparations large portions of Nasmyth's membrane are seen loose and lying across the section, being attached by one or both extremities to the follicle (see figs. 230, 231, and 232).

As shown in figs. 231 and 232, the internal epithelium, the stratum intermedium, and flattened cells of the external

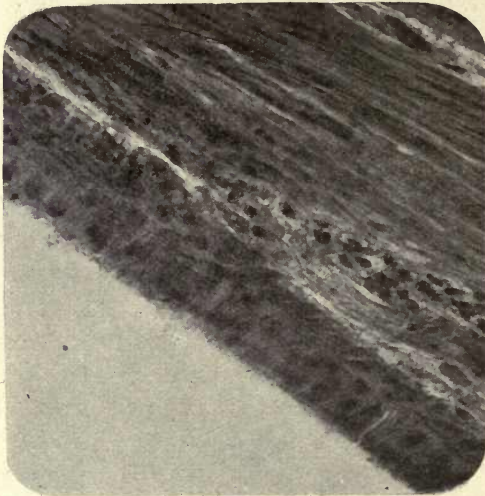


FIG. 231. The enamel organ cells on the inner margin of the follicle, showing commencing detachment. Farther along these layers are completely separated. Longitudinal section. ($\times 400$.)

epithelium are all seen blended with the follicle, but showing a tendency to detach in places. In fig. 231 the whole of the enamel organ, with the exception of the stellate reticulum, which has long since disappeared, is seen becoming detached from the follicle. It is also seen in these figures that not only these cells but others deeper within the follicle here and there become detached with them. The attachment to the enamel is probably more complete than that to the follicle, but when the enamel has been decalcified without disturbance of the neighbouring tissues, as in this case, the attachment to the cells of the follicle is better maintained.

This detachment of other cells than those constituting the enamel organ will account for the presence, in the floated preparations of the membrane, of the rounded cell masses and the cell nests above described, and we must consider that Nasmyth's membrane consists not only of the external epithelium, but also, and more evidently, of the two innermost layers of the enamel organ, which have not disappeared on the eruption of the tooth but remain attached to the enamel.

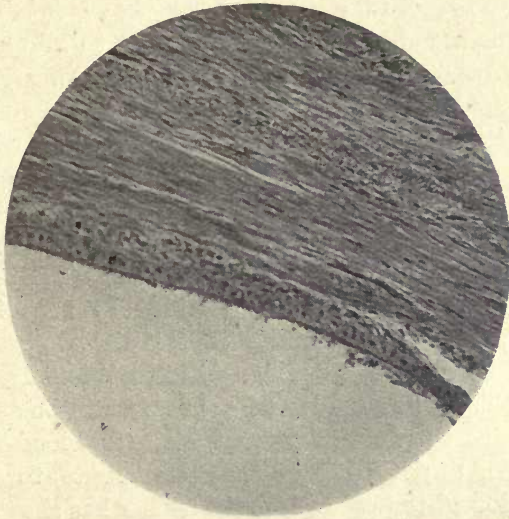


FIG. 232. Partial detachment of Nasmyth's membrane from follicle. Columnar cells, many vacuolated. ($\times 250$.)

Summary

In preparations of Nasmyth's membrane by separation from the surface of the enamel by acids, cells are seen which do not appear to have any connexion with the enamel organ, such as the rounded bodies and the cell nests.

These preparations would appear to be explained by the longitudinal sections of the tooth in the follicle. It is seen that the attachment of the enamel organ with other altered and degenerated cells in contact with it is very slight, and these latter cells show a tendency to separate from the follicle with those of the enamel organ. It is evident that

far from the external epithelium of the enamel organ disappearing, it persists with the two inner epithelial layers, so that we cannot avoid the conclusion that the membrane consists of the altered cornified cells of the whole enamel organ with the exception of the stellate reticulum, and also includes other altered and degenerated cells of the follicle.

The clear layer was considered by Kölliker to represent a continuous structureless layer formed by the enamel cells after their work is completed.

Another view of its nature may be that it is a persisting ameloblastic membrane, which according to Leon Williams and many others is definitely to be seen between the ends of the ameloblasts and the forming enamel, and corresponds to one position of the 'membrana preformativa' of Huxley. If the internal ameloblastic membrane had not previously disappeared, it would certainly come to occupy the position of the clear layer of Nasmyth's membrane over the completed enamel, favouring the conclusions of Huxley and Leon Williams that enamel is calcified by the dialysis of lime salts through a membrane. As this dialysing membrane persists while the tooth remains within the follicle, the cells of Nasmyth's membrane would probably still be active and functional, as they are in contact with the blood-vessels of the capsule, and they thus may contribute to the final consolidation of the enamel, as the author has shown is in all probability the case in the teeth of *Sargus*. It has been suggested that after the eruption of the tooth, when the cells are undergoing keratinization, the whole membrane may serve as a dialysing membrane separating the lime salts from the saliva. Pickerill, who adopts this view, says: 'The enamel, after the eruption of the tooth, is covered with a dead membrane, Nasmyth's membrane; it is immersed in a fluid saliva, containing in solution lime salts and organic material (mucin and albumin), and it has been shown that fluids with solids in solution can pass into the outer layers of enamel' (in experiments conducted by Pickerill on the permeability of enamel from without). 'It would seem therefore in every way probable that Nasmyth's membrane acts as an ordinary dialysing membrane, through which crystalloids pass, but colloids do not.

Therefore, other things being equal, and so long as the lime salts, especially the calcium phosphate, remain in solution, they must tend to pass through the membrane and penetrate the enamel, and the mucin and albumin are kept back. No doubt the process is very slow and gradual, depending largely on the relative osmotic pressures on either side of the membrane, but it must undoubtedly take place' (7).

These considerations are, however, more or less of a speculative nature, and it is difficult to arrive at any definite conclusions with regard to the functions of Nasmyth's membrane; still it would appear that, given a membrane separating a colloid from a crystalloid, diffusion must, by the laws of osmosis, take place through it. It has been considered by some that Nasmyth's membrane acts as a protective covering to the enamel, preserving it from the action of acids, but it is difficult to conclude how far this can be the case, for in healthy conditions any acid normally present in the mouth would not be likely to have any injurious effect upon the enamel, and we cannot consider that Nasmyth's membrane has been evolved for the protection of the teeth from a pathological process such as caries.

So long as it is a continuous membrane it would no doubt serve the latter purpose, but when detached in places, would in all probability rather favour the process than otherwise, as bacteria would proliferate beneath the separated membrane, which would retain their acid products in contact with the enamel surface.

In view of the direct evidence of the cellular nature of Nasmyth's membrane it is scarcely necessary to discuss at any length the earlier views of its origin. Although not the usual function of the follicle in its coronal portion to lay down cement in teeth the crowns of which are not normally covered with this tissue, it seems theoretically conceivable that a kind of attempt to do so might occasionally result in the deposition of a thin layer *outside* Nasmyth's membrane.

It seems, however, highly improbable, and we cannot but think that, as has been suggested, the so-called encapsuled lacunæ may be isolated cells of the enamel organ, especially as a thin layer of cement does not show lacunæ in its

normal situation on the roots of teeth in man. The presence of the large cornified epithelial cells with projecting processes occasionally seen in preparations of the membrane, would lend support to this view.

The calcified isolated bodies, above described, sometimes found in the follicle, are within the connective tissue and well separated from the bordering epithelial layers. They do not appear to have the characteristic structure of either bone or cement, and resemble the similar erratic calcification which sometimes occurs in the centre of the connective tissue of the pulp.

In 1914 a series of papers was published at Milan by Dr. Arturo Beretta of Bologna (1) on the enamel cuticle. The author has not had an opportunity of seeing the original paper, but only a review which appeared in the *Dental Cosmos* (May 1915). This author concludes that Nasmyth's membrane results from the transformation of the ameloblastic layer into the basal membrane (probably referring to the clear layer) and of the upper ameloblastic epithelia into areas of granular consistence, which may be called cuticular epithelial remnants. He would thus agree partially with Kölliker's view, so far as the inner transparent layer is concerned; but it is difficult to understand what is meant by the areas of granular consistence, as preparations of the membrane show a definite layer or layers of cells. He says that the enamel cuticle remains throughout life, and with the advance of age increases in thickness. This statement is hardly in accordance with previous observations.

Eruption of the Teeth

The teeth, both of the temporary and the permanent set, are formed deeply in the tissues of the jaw, but soon after the crowns are fully formed take their positions on its upper margin, and the crowns of the teeth are fully exposed within the mouth. The exact method by which this eruption of the teeth is brought about has been a matter of much controversy. It seems quite evident that there are several factors concerned in the process, and no one theory

that has been brought forward is sufficient in itself to account for the phenomenon.

In a recent paper by Warwick James and A. T. Pitts, the authors consider that there are two chief factors concerned in eruption (16).

(1) A process of advancement of the tooth in the tissues.

(2) A process of denudation by absorption of the tissues overlying and surrounding the tooth.

In the process of advancement they consider that the point of eruption is determined by the presence of the epithelial columns connecting the oral epithelium with that lining the tooth follicle. The advancement of the tooth is partly due to unequal rates of growth between the various tissues surrounding the tooth, and they consider that the elongation of the root plays some part in eruption.

As pointed out by Tomes (17), the elongation of the root is alone quite inadequate to produce the effect. Teeth with stunted roots are frequently erupted, and a tooth with fully completed root may remain within the jaw and erupt late in life.

He compares eruption in man with that in reptiles, showing that 'a force quite independent of increase in length shifts the position of and "erupts" successive teeth'.

Messrs. James and Pitts compare the eruptive process to 'the opening of a book, the hinged portion being advanced, *pari passu*, with the separation of the pages of the volume, until it comes to occupy the same level as the free edges'. This implies the movement of the tooth, the cause of which still has to be accounted for; for while the degeneration and absorption of the cells of the follicle and capsule, and especially the opening out of the epithelial coils (figs. 203 and 204) described on p. 312, would afford a path for the tooth to the surface, it must still be moved forward in this path to its final position in the jaw.

Blood pressure was considered by Constant (13) to be the cause of the movement of the tooth, the vascular tissues beneath the tooth serving as the propulsive force. It seems very probable that this is one of the factors in eruption, but not sufficient in itself to account for the whole process.

It was considered by A. Underwood that eruption may be caused by the movement of the soft parts surrounding the tooth, due to the growth and changes taking place in the periodontal membrane, and comparable to some extent with the movement of the mucous membrane carrying the teeth over the jaw in the Sharks (18).

A somewhat similar explanation of the process of eruption is given by Thornton Carter.¹ He describes a slight amount of ossification of the margin of the cartilaginous jaw in the Dog-fish, and says: 'The crust of bone, which is of a transitory nature, being constantly absorbed and deposited, is instrumental in causing a progressive movement of the sliding membrane,' and further, 'When a functional tooth is shed, absorption of the underlying bone takes place, and also absorption of the fibrous membrane at its outcrop. As a natural consequence of the absorption of the underlying bone and fibrous membrane there is a rapid proliferation of cells at the margin of the cartilage with formation of bony tissue over the same area. The newly formed bony tissue operates on the fibres of the sliding membrane, which is poor in cellular elements and ill-adapted for active growth, and causes the membrane to move upwards and bear with it the next successional tooth.' That the presence of this bony deposit, however, is not essential to the process appears to be indicated by the fact that it is not always found in Elasmobranchs. The section of the edge of the jaw of *Lamna* at the Natural History Museum does not show the presence of any bone, and no bone is figured in Ridewood's drawing of the eruption of the teeth in *Carcharias* in the *Cambridge Natural History*.

Carter's conclusions regarding eruption of the teeth in man are as follows: 'Thus we may conclude that in man the cause of eruption, or at least an active factor in producing eruption, is to be found in the disproportionate growth occurring in the tissues forming the tooth and the tissues surrounding the tooth.'

It seems impossible to deny that there is a forward movement of the tooth in eruption, which is probably due to

¹ Colyer's *Dental Surgery and Pathology*, 1919.

many causes, such as the elongation of the roots, the growth of the bone of the jaw, the development of the periodontal membrane, and the blood pressure in the vascular tissues around and beneath it.

This advancement of the tooth is therefore probably due to several concomitant forces, and is one factor in eruption, the other being the absorption and opening out of the tissues overlying the tooth.

Warwick James, in a previous paper (15), showed very clearly how such a path is prepared by the opening out of the overlying tissues of the capsule as the tooth erupts. He showed that the *globes épidermiques* or epithelial coils, as he prefers to call them, which are due to degenerative changes in the epithelial elements of the capsule, form very wide spaces within the connective tissue over the tooth; that these increase in size until they appear as mere openings in the connective tissue, all trace of their epithelial structure being lost, and they eventually open out upon the surface; but this opening out takes place not by the advance of these bodies, but by a separation or rarefaction of the tissue of the capsule, which is gradually withdrawn on either side of the erupting crown, yielding in the first place at the situation of the epithelial coils.

The changes which take place in the epithelium of the follicle and the formation of the epithelial coils have been more fully considered in treating of the follicle (p. 311).

Guido Fischer (14), in his paper on the eruption of the teeth, described the union of the outer and inner layers of the enamel organs into one continuous epithelial layer which just previous to eruption becomes blended with the epithelium of the mouth. These observations were made on the erupting teeth of the cat, and the illustrations to the paper show this epithelial layer blended with the surface epithelium on either side of the opening through which the erupting tooth is advancing.

It is difficult to reconcile this description with what is seen in the sections of the human follicle just before eruption, described in Chapter VIII, for Fischer's figures do not show the detachment of any layer or layers of cells to form Nasmyth's membrane, and one would be more inclined to

look upon this epithelial layer which he describes as consisting of the cells of the deeper part of the follicle.

Nasmyth's membrane not being shown would suggest the probability that the separating layers forming this membrane, as shown in figs. 230 and 231, &c., have become completely detached and lost in the preparations figured in the paper. In several of the author's sections this has occurred, and would be probably still more likely to happen with paraffin sections treated with alcohol.

In this case, as suggested, it is the deeper epithelial cells of the follicle which are connected with the surface epithelium and not the cells of the enamel organ.

As it is considered by Fischer that the outer and inner layers of the enamel organ become united and blended with the surface epithelium, he cannot apparently agree with the views of Von Brunn and Ballowitz that these layers are continued downwards as the sheath of Hertwig, and in fact, in his figures, the sheath of Hertwig is shown as discontinuous at the neck of the tooth and is neither a prolongation of the cells of the enamel organ nor of the deeper epithelial cells of the follicle.

Teeth do not always erupt in a vertical direction as in man, where the new tooth appears immediately beneath that which is being shed.

In osseous fish the successional teeth usually appear at the sides of the tooth in use, but in *Sargus* both the molars and incisors erupt directly beneath the tooth which is shed, and in the pharyngeal teeth of *Labrus* the same mode of succession is seen. In the Sharks new teeth come into use in successive rows, being carried forward by the movement of the mucous membrane over the rounded cartilaginous jaws.

Some teeth never erupt, but remain embedded in the jaws, as in the female Narwhal, and many instances are recorded in man where teeth have never erupted or have appeared long after the normal period of eruption.

Although we have some knowledge of the phenomena accompanying the process, the actual conditions necessary and the forces which govern the process of the eruption of the teeth are still but very imperfectly understood.

REFERENCES

1. Beretta, A. 'The Enamel Cuticle—Histological and Histogenetic Researches.' *La Stomatologia*, Milan, No. 9, 1914.
2. Dahlgren and Kepner, W. A. *A Text-book of the Principles of Animal Histology*, 1908.
3. Huxley, T. H. 'On the Development of the Teeth and on the Nature and Import of Nasmyth's Persistent Capsule.' *Quar. Journ. Micr. Sci.*, No. 3, 1853.
4. v. Lent, E. 'Ueber die Entwicklung des Zahnbeins und des Schmelzes.' *Zeitsch. für wissenschaftl. Zoologie*, Sechster Bd., p. 121, 1885.
5. Owen, R. *Odontography*, p. 466.
6. Paul, F. T. 'The Enamel Organ.' *Dental Record*, 1896, vol. xvi, pp. 493-8.
7. Pickerill, H. P. *Prevention of Dental Caries*, 2nd ed., pp. 135-6.
8. Schafer, E. A. 'Text-book of Microscopic Anatomy.' *Quain's Anat.*, vol. ii, pt. i, 1912, p. 96.
9. Tomes, J. *A System of Dental Surgery*, 1st ed., 1859, pp. 266-72.
10. Tomes, C. S. *Dental Anatomy*, 7th ed., p. 122.
11. Underwood, A. *Aids to Dental Anatomy and Physiology*, 3rd ed., p. 24.
12. Wilson, E. B. *The Cell in Development and Inheritance*. New York, 1896, p. 82-4.
13. Constant, T. E. 'The Eruption of the Teeth.' *Troisième Congrès Dentaire Intern.*, Paris, 1900, vol. ii, pp. 180-92.
14. Fischer, G. 'Beiträge zum Durchbruch der bleibenden Zähne u. zur Resorption des Milchgebisses.' *Anatomische Hefte*, 1. Abtheilung, 116. Heft (38. Bd., H. 3), Wiesbaden, 1909.
15. James, W. 'A Preliminary Note on the Eruption of the Teeth.' *Proc. Roy. Soc. of Med.*, 1909 (Odontological Section).
16. James, W. W., and Pitts, A. T. 'Some Notes of the Dates of Eruption in 4,850 Children under 12.' *Proc. Roy. Soc. Med.* (Odontological Section), vol. v, No. 5, pp. 80-101.
17. Tomes, C. S. *Dental Anatomy*, 7th ed., pp. 238-9.
18. Underwood, A. *Aids to Dental Anatomy and Physiology*, 3rd ed., p. 86.

CHAPTER X

THE ATTACHMENT OF TEETH

WHILE the general study of the attachment of teeth may be better considered in works on dental anatomy, the microscopic structure of the teeth and bone and their connecting tissues concerned in the different modes of attachment render it necessary to dwell somewhat on the different methods by which the union of the teeth with the jaws is brought about.

Our knowledge of the forms of attachment, especially in fish, is chiefly due to C. S. Tomes, who was the first to describe the existence of a special bone of attachment in reptiles and fish.

The various modes of attachment of teeth may be classified as follows :

1. Fibrous attachment.
2. Attachment by an elastic hinge.
3. Anchylosis.
4. Socketing or gomphosis.

(1) **Attachment by Fibrous Membrane.** This form is seen in the Sharks and Rays.

The class Plagiostomi, to which these forms belong, is characterized by a cartilaginous skeleton. The teeth of the Sharks have no direct attachment to the jaw, but are attached to the mucous membrane by strong fibrous bands which envelop the spurs or processes at the base of the tooth and firmly bind it down to the tough fibrous membrane covering the jaws. A sliding movement of this fibrous mucous membrane takes place over the jaws as the teeth come into use, the membrane with its attached rows of teeth rolling, as it were, over the rounded margin of the jaw and thus bringing the functional rows of teeth successively into an upright position. As the movement progresses the teeth of the front row are cast off, or shed, and the next row of teeth take their place.

That this forward movement of the whole fibrous mem-

brane, carrying the teeth with it, really occurs, was clearly shown by the well-known specimen figured and described by Professor Owen (2). In this case the jaw of a shark (*Galeus*) was penetrated by the spine of a Sting-ray. The spine entered the jaw in the region of the developing teeth and the scar extended from this position to the front row of the teeth in use, which showed a malformation, the result of arrested development in the region of the injury. This could not have occurred unless the whole of the mucous membrane had been carried forward, sliding over the jaw beneath (fig. 233).

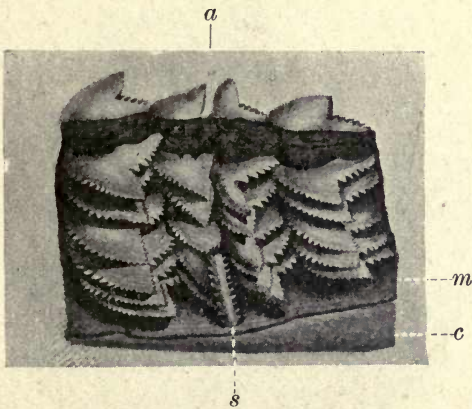


FIG. 233. Part of the lower jaw of a Shark (*Galeus*) pierced by the barbed caudal spine (*s.*) of a Sting-ray (*Trygon*), showing the effect of the wound of the dental matrix on the teeth, which have advanced in their revolving course over the jaw. *m.* Mucous membrane; *c.* cartilaginous jaw; *a.* injured calcified teeth.

Various modifications of the method of attachment by fibrous membrane are seen in fishes. In some the attachment admits of a very slight amount of rocking movement, and transitional forms between this and true hinging are met with in great abundance.

As seen in the Eel (fig. 234), the teeth are situated on little pedicles of bone, the bone of attachment, first described by C. S. Tomes. This bone of attachment corresponds to the alveolus of a socketed tooth; it is developed for the attachment of the tooth, and is removed or absorbed when the tooth is shed.

It has not the regular microscopic structure of the bone

of the jaw, with which it is continuous. Both in its lamination and in the irregular lacunæ and other spaces which it exhibits it has a coarser appearance than the bone beneath. It is well developed in the teeth of *Ophidia*. The fusion of the teeth with the bone of attachment is often so complete that it is difficult to distinguish tooth from bone, especially in osteodentine teeth.

(2) **Attachment by an Elastic Hinge.** A simple form of




FIG. 234. Teeth of Eel showing union to bone of attachment, and enamel tips. (Photographed from a specimen lent to the author by Sir Charles Tomes.) *e*. Enamel tips; *b*. bone of attachment.

attachment by a hinge allowing of movement of the tooth upon the bone of attachment is seen in the *Echineis*, the sucking fish of the Shark, which attaches itself by a sucker on the back of the head to the skin of the Shark, and although also capable of free movement, obtains most of its nourishment from the crustacea and other organisms found in the slimy substance on the shark's skin.

The sucker allows of free movement of the fish in a forward direction, but it cannot be detached backwards by any force applied from the front. Each tooth is attached to a special bone of attachment, but is not ankylosed to it;

it slides freely upon the bone, and exhibits a modified form of hinge. The summit of this pedestal of bone is in the form of a convex ring, slightly raised on one side, resembling the socket of a ball-and-socket joint with the centre cut out, leaving an elevated ring of bone. The base of the tooth is accurately adapted to this surface, and slides easily upon it, forming the convex side of the joint; the opening for the passage of the tissues of the pulp is large, to allow of the

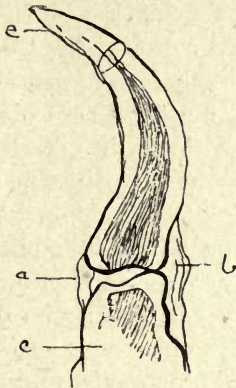


FIG. 235. Hinged tooth from lower jaw of *Echineis squalipeta*. *e*. Enamel tip; *a*. part of capsule; *b*. capsule containing fibres forming hinge; *c*. bone of attachment.

movements of the tooth taking place without injury to the nerves and blood-vessels. A capsular ligament surrounds the whole, giving a still greater likeness to a ball-and-socket joint (fig. 235).

The capsule is strengthened anteriorly and posteriorly by a fibrous band, there being a distinct depression on the bone and also on the tooth, for the attachment of these fibres. It will be seen that this arrangement would allow of a sliding movement of the tooth on the bone of attachment in every direction, but the ring of bone being slightly more elevated on the anterior aspect, the motion is limited in this direction more than in the opposite, and the tooth can be bent over much more in the direction of its point than in any other direction. The strong elastic ligamentous band being stretched, no doubt serves to draw the tooth into

position again. The amount of bending down of which these teeth are capable is not very great when compared with such complete forms of hinging as those of the Hake and the Pike, but when the minute teeth are examined under a hand lens and pushed inwards with a needle, they are seen to be considerably depressed and to recover their position immediately upon removal of the pressure, while owing to the shape of the bony pedestal they resist pressure in the opposite direction.

The amount of movement is quite sufficient, associated with the strong inward curve of the tooth, to make escape very difficult or impossible for any small creatures captured as prey, which would meet with no obstruction in passing over the crowns of the teeth in entering the mouth. We have thus, in *Echineis*, a stage in the transition from the fixed teeth of the Shark to true hinged teeth, for here there are elastic ligamentous bands in addition to the capsule seen in the Eel, directing the motion of the tooth chiefly in a particular direction, and the shape of the opposed surfaces, above described, would appear to be of especial value in giving to this form of hinge as free a movement as possible.

For a further description of the teeth of *Echineis*, the reader may be referred to the author's original paper (1).

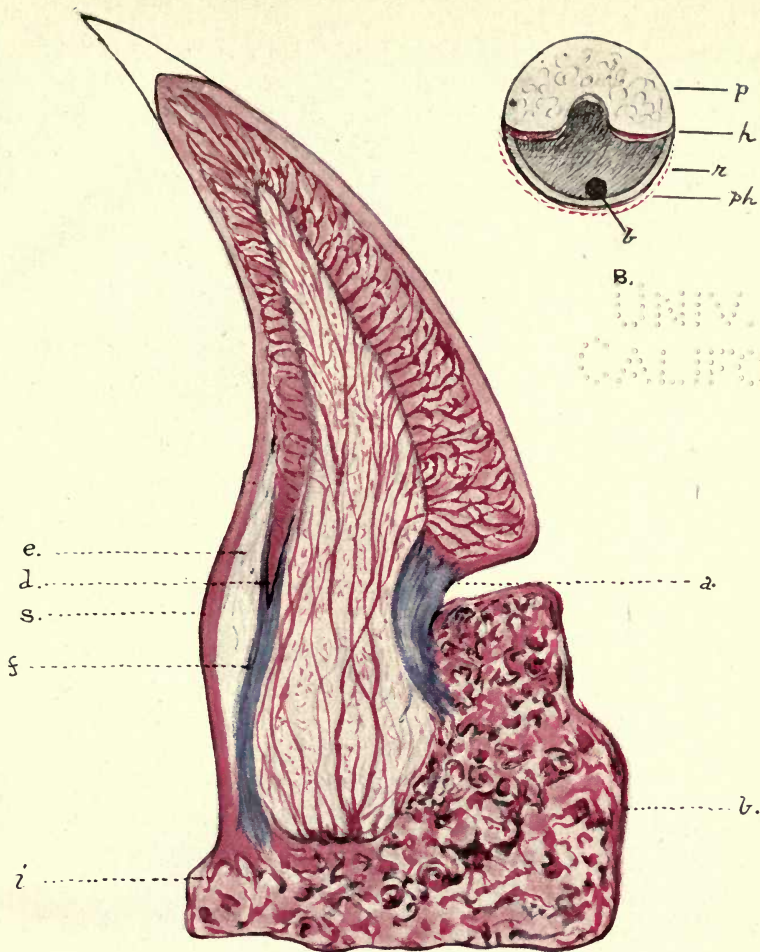
Hake.

From the foregoing description it is easier to comprehend the structure of the more perfectly hinged teeth of the Hake (*Merluccius*).

In this fish the outer row of teeth are ankylosed to the jaw (fig. 236), but the inner row are hinged, and the hinging is of a very complete nature, the tooth being able to be bent inwards to an angle of about 45° and to recover its position with a snap.

In fig. 237, which is a photograph of a ground section of the hinged tooth of the Hake, and in Plate VI the tooth is seen in its partially depressed position. The front portion of the tooth is thickened at its base, and when returned to its place, this thickened portion is received on an elevated pad or buttress of bone.

In this preparation it was noticed that the tooth was also attached to the inner margin of the bony pedestal. In the published figures of the hinged teeth of the Hake



Hinged tooth of the Hake (*Merluccius*) from a longitudinal section taken to one side of the middle line. *b*. Bone of attachment; *f*. uncalcified portion of posterior hinge; *a*. anterior hinge; *s*. stiffened elastic part of posterior hinge; *d*. insertion of calcified tooth into posterior hinge; *e*. triangular space occupied by interlacing elastic (?) fibres; *z*. insertion of outer portion of posterior hinge into bone of attachment (*b*). (Drawn by the author from a specimen stained with Mann's methyl-eosin.) $\times 50$.

B. Diagrammatic representation of bone of attachment viewed from above, the tooth being removed. *h*. The two halves of the anterior hinge coloured red; *p*. pedestal of bone; *r*. opposite pulp cavity; *ph*. the red dotted line represents the attachment of the posterior hinge; *b*. foramen for passage of blood vessels to pulp.

70 1000
1000000000

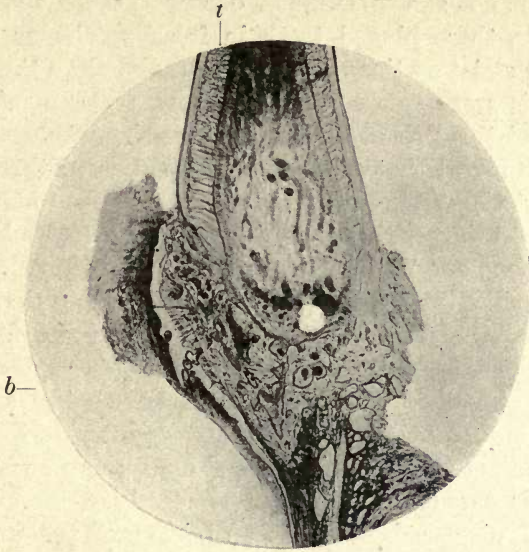


FIG. 236. Ankylosed tooth of Hake (Merluccius).
t. Tooth ; *b.* bone of attachment. ($\times 50.$)



FIG. 237. Hinged tooth of Hake (Merluccius). Ground section to one side of middle line. *p.* Thickened base of tooth ; *a.* anterior hinge ; *b.* bone of attachment forming raised pedestal ; *e.* triangular space ; *f.* fibrous part of posterior hinge. ($\times 30.$)

this band is not shown, and this observation led the author to examine these hinged teeth in fresh specimens and in decalcified serial sections in order to make clear the meaning of this appearance in the ground section. A fresh specimen of this fish of unusually large size was examined, and it was found that a probe could be passed through to the pulp at the centre, but met with resistance to the right and left of this position, showing that the tooth lies free upon the bone only in the middle line of the pedestal. Teeth were decalcified and examined in a series of sections from one side of the tooth to the other. These preparations showed that there is a band of fibrous tissue attached to the tooth and bone on either side of the central opening. On dividing the anterior bands in the fresh tooth, the tooth resumed its position when depressed almost as well as when these bands were entire, but it was unsteady on the pedestal, and easily displaced laterally. Division of the posterior hinge entirely prevented the return of the tooth to the upright position. The function of this anterior hinge would thus appear to be the increase of the resiliency of the whole structure and the prevention of lateral displacement. In the figure in Tomes's *Dental Anatomy*, the section, presumably a ground one, had been taken through the centre of the longitudinal axis, and the anterior hinge consequently is not shown. In Plate VI B a diagrammatic drawing of the bone of attachment is shown, the tooth having been removed. The upper part of this diagram represents the elevated pad of bone or pedestal, and it is seen that the pulp cavity is prolonged forward, forming a semicircular hollow at the posterior margin of the pedestal. The two bands which make up the anterior hinge reach from each side only as far as this depression. The ridge of bone at *r* is at a considerably lower level than the pedestal, and the larger posterior hinge is attached to it, encircling the posterior half of the tooth and bone.

The structure of the posterior or principal hinge is shown in fig. 238, photographed from a decalcified section. The outer border of the dentine on the inner side of the tooth is continued downwards to its attachment to the bone, as is well shown at *k* in fig. 238 and in Plate VI. This portion of the

dentine is not calcified, but appears to be somewhat of the consistence of whalebone, although as a mesoblastic product having no other analogy with it; acids have no effect upon it. It contains no vascular canals, and at its upper portion at *f* in this figure is continuous with the dentine at the inner margin of the pulp cavity, and in this portion a few scattered vascular canals are seen, but it terminates at *e*, where the fibres of the fibrous band *d* are inserted into it. These fibres again

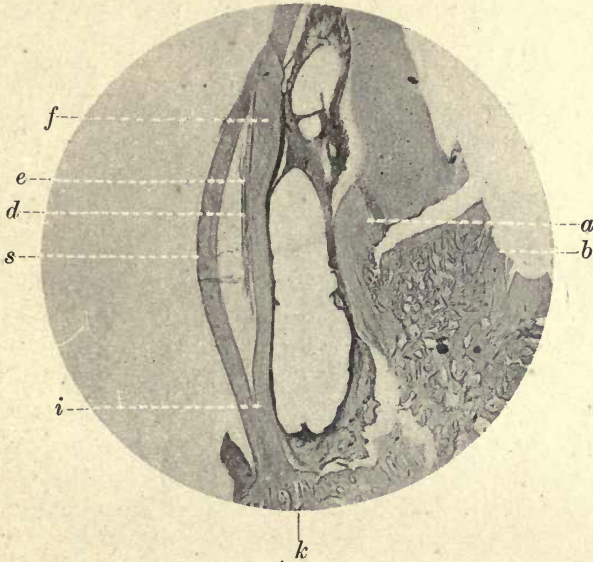


FIG. 238. Section of decalcified tooth of Hake (*Merluccius*) taken to one side of middle line, showing anterior hinge on one side (*a*.) stained with Mann's methyl eosin. *e*. Triangular space; *d*. insertion of calcified tooth into fibrous portion of posterior hinge; *s*. stiffened elastic part of posterior hinge; *i*. junction of fibrous part with *s*.; *b*. bone of attachment; *k*. insertion of posterior hinge into bone. ($\times 50$.)

unite at *i* with the outer band *s*. Between these two portions of the hinge is an elongated space in which separated strands of fibres are seen. That the two portions of the hinge above described are of a different structure is shown by their staining reactions. When sections are stained with methyl eosin, the dentine and bone are stained red, but the fibrous band *f* in the plate is of a bright blue, taking the colour in the same manner as uncalcified connective tissue; the posterior portion of the band *s* is coloured uniformly red.

It would thus appear that the posterior hinge consists of two different substances—an outer stiffened portion which is possessed of considerable rigidity but great elasticity, and an inner fibrous portion made up of strands of fibres of an elastic nature, which become relaxed when the tooth is pushed backwards and straighten out when the pressure is removed, and with the stiffer arched spring-like portion at the back immediately return it to its position on the bone.

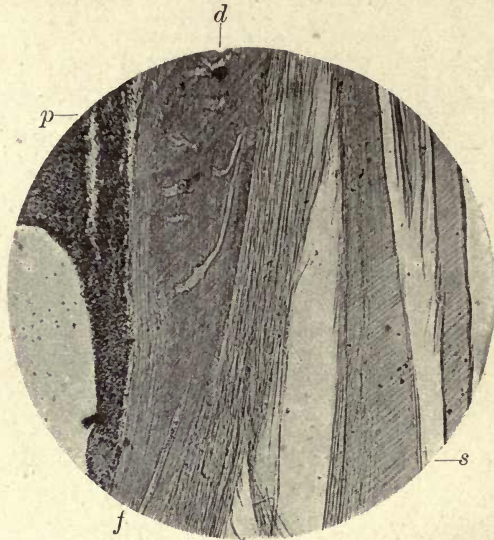


FIG. 239. The posterior hinge of the tooth of the Hake (Merluccius). *d*. Calcified portion of the tooth inverted into the fibrous portion of the hinge *f*. ; *s*. stiffened elastic part of posterior hinge ; *p*. pulp of the tooth. ($\times 150$.)

In fig. 239 the fibrous portion of the hinge is shown under higher magnification and its attachment to the prolonged portion of the vasodentine (*d*). These fibres, when teased out in glycerine or water, curl very much in the same manner as those of ordinary elastic tissue.

The anterior hinge, as shown in Plate VI B and fig. 238, *a*, is divided into two portions, the tooth in the centre lying free on the bony pedestal.

This hinge is made up of stout fibres, which are inserted into the tooth above and the bone below. It is of considerable thickness and stains blue like the fibrous portion of the

posterior hinge (Plate VI A). Serial sections show that when the central longitudinal axis is approached, this band is no longer visible, and the thickened portion of the lower end of the dentine lies free in the section, portions of the pulp only being attached to it.

This apparatus is perfectly adapted to the capture of active prey; the small fish and other creatures which form the food of the Hake depress the teeth on entering the mouth, a very slight pressure only being necessary, and their escape is prevented by the springing back of the teeth into position.

The passage of the captured creature backwards in the mouth is still further facilitated by the hinged teeth on the vomer and pharyngeal bones.

Most of these predatory fish swallow their prey in a whole and living condition, and their teeth are not available for any process of mastication.

In other members of the Cod family a transitional form of hinging is met with. In the Haddock (*Gadus aeglefinus*) Haddock. the tooth rests upon a ring of what appears to be dentine, which becomes blended below with the bone of attachment. The upper part of the tooth is quite separated from this lower portion so far as the continuity of the hard tissues is concerned, but surrounded at the point of contact with a fibrous band forming a kind of capsular ligament which is attached to the circumference of the portions above and below the flange. This evidently forms a hinge and allows (fig. 240) of a limited amount of rocking movement, as can be seen in several sections where teeth are seen to be inclined to one side, the opposite side of the ligament being stretched. The pulp, as pointed out by C. S. Tomes, is continued into the cavity below the flange, and he describes odontoblasts in this portion of the pulp, so that we must look upon the tissue in this part of the tooth as a not very clearly defined dentine, and as this author states, its implantation would indicate a transition in the teeth of the Haddock to a socketed type.

The hinged teeth of the Angler (*Lophius piscatorius*) Angler. are attached by radiating fibrous ligamentous bands to the bone, the front of the tooth being free and resting on the bone; but there is no definite differentiated elastic hinge as in the

Hake. The elasticity is, however, very complete, and the tooth instantly returns to its position when the pressure is removed.

Pike.

In the Pike (*Esox lucius*) the marginal teeth are ankylosed and the palatal teeth are hinged, but the hinging is obtained in a different manner. As pointed out by Tomes, the osteodentine pulp is traversed by elastic bands or trabeculæ, which remain uncalcified, and are firmly attached to the dentine at the margin of its dense peripheral portion

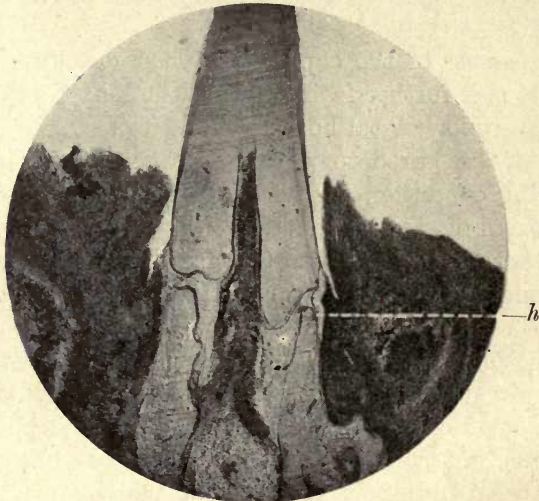


FIG. 240. Tooth of Haddock (*Gadus aeglefinus*) showing modified hinging at *h*.

and to the bone of attachment beneath, on which the tooth rests.

The strong fibrous bands attaching the tooth to the bone on its inner side are not elastic, and the elasticity resides in the trabeculæ within the pulp; when pushed back the tooth recovers its position by the contraction of these bands.

The arrangement of the teeth of the Pike is eminently adapted for the retention of living prey, the position of the hinged teeth on the palatal bones directing the captured prey in a longitudinal direction, and thus enabling it to pass into the throat as described by Tomes. Every

angler for pike knows that the fish may often be held for a considerable time and even drawn out of the water when not hooked, the retention of the living bait between the teeth being so complete that it cannot be withdrawn. The above-named author found examples of hinged attachment in many specimens of deep-sea fish obtained on the *Challenger* expedition.

(3) **Anchylosis.** This is the more common form of attachment in fish and reptiles ; there is no intervening vascular and fibrous membrane, and the union does not take place directly with the bone of the jaw, but through the medium of the bone of attachment. The fusion of the tooth with the bone of attachment is usually very complete, so much so that, as C. S. Tomes points out, in grinding a section of an anchylosed tooth the bone of attachment often comes away from the bone, while it is firmly attached to the tooth (fig. 236).

A curious modification of this mode of attachment is seen in the Mackerel, where the tooth is anchylosed to the bone at its lateral margins but unattached below, being, as it were, slung within the bone. Mackerel

The author in an examination of two species of Wrasse (*Labrus*) found a curious modification of anchylosis in these fishes. The tooth when about to erupt has a large pulp cavity with the usual dentine pulp consisting of connective tissue and blood-vessels and a layer of large odontoblasts. The pulp is extremely vascular and the vessels form a continuous network of loops within the odontoblast layer in close contact with the tubular dentine. The pulp tissue is seen to merge into bone beneath the open end of the rootless tooth. When the tooth is erupted and the deposition of the dentine is completed, the bone tissue invades the pulp chamber and entirely fills it, the bone becoming continuous with the dentine around the inner margin of the pulp, the odontoblasts having entirely disappeared.

This is not the same condition as in the anchylosed teeth of the Pike, where the tissue of the tooth is an osteodentine, but an actual substitution of the dentine-forming pulp by true bone (figs. 241 and 242).

Anchylosis is found in the teeth of the Python and the

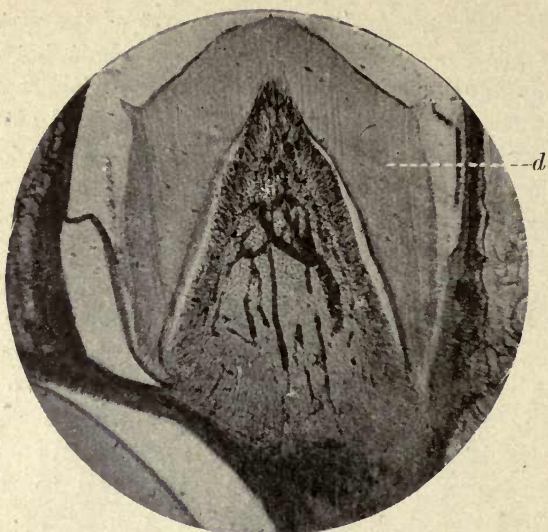


FIG. 241. Pharyngeal tooth of a Wrasse (*Tautoga*). Unerupted tooth showing pulp and odontoblasts and large vascular supply. *d*. Dentine. ($\times 25$.)

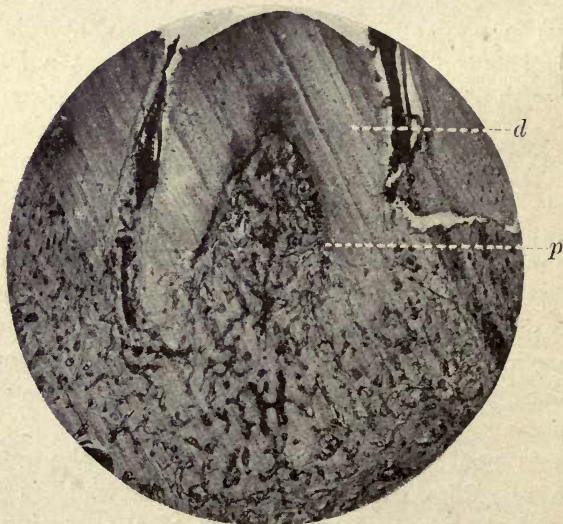


FIG. 242. Pharyngeal tooth of Wrasse (*Tautoga*), erupted. The dentine pulp is completely filled with bone. *d*. Dentine; *p*. bone tissue in pulp. ($\times 25$.)

lizards, and in the poison fangs of the viperine snakes. When the tooth is attached to the bone on the outer side, as in *Varanus*, the attachment is described as *pleurodont*; when to the summit of the bone of attachment, as in the Eel, it is spoken of as *acrodont*.

(4) **Gomphosis or Socketing.** This is the mode of attachment seen in human and mammalian teeth generally. The tooth is implanted in a cavity in the bone forming the socket, and is separated from the bone by a fibrous and vascular membrane or ligament, the periodontal membrane.

A separate socket is developed for each tooth in Mammalia, but in the Crocodile, as shown by Tomes, 'the successive teeth come up and occupy a socket which is more or less already in existence'.

In this form of attachment we have the intervention of a vascular membrane, and the bone of attachment is represented by an alveolus, which is a special process of bone developed to receive the tooth, and which becomes absorbed and removed when it is shed.¹

The teeth of the rostrum of *Pristis* (the Saw-fish), which consist of plicidentine and are of persistent growth, afford an example of socketed teeth in fish, a very rare mode of attachment in this class.

¹ This special development of the alveolar process is well shown in the Manatee and in the Sheep, the forming teeth at the back of the mandible lying in a separate tube of bone as seen in two preparations in the Odontological Section of the Hunterian Museum of the Royal College of Surgeons.

REFERENCES

1. Mummery, J. H. 'On the Teeth of Echineis.' *Trans. Odontol. Soc. Great Brit.*, vol. xxxi, No. 3, p. 62.
2. Owen, R. *Odontography*, p. 39, Plate xxviii.
3. Tomes, C. S. 'Studies upon the Attachment of Teeth.' *Trans. Odontol. Soc. Great Britain*, 1874-5, vol. vii, pp. 41-56.

CHAPTER XI

HORNY TEETH

THE teeth of the Cyclostomata (Lampreys, &c.) are horny cones; they show no true calcification, but are made up of cornified cells of the stratum corneum of the epidermis. New horny cones are formed beneath the tooth in use, and successively take its place when shed.

In the Lamprey (*Petromyzon*) these horny structures are found at the sides of the mouth and on the tip of the tongue.

In the Hagfish (*Bdellostoma*) there is a single tooth in the roof of the mouth and minute teeth upon the tongue. This fish is partly parasitic in its habits, living on the mud at the sea bottom, and often boring its way into the bodies of large fish, especially the cod, to which it is often very destructive, eating out the soft parts of its prey by means of the rasping action of its tongue teeth.

Beard (2) has described in *Bdellostoma* the existence of a true layer of odontoblasts and the formation of a cap of imperfectly calcified dentine, and he considered that his preparations showed a small cap of enamel upon this dentine. Warren (8), however, denies the presence of calcified enamel or dentine, and shows that a differential stain (picronigrosin) indicates that there is no calcification, but the tooth is entirely horny. There is simply a superficial resemblance to calcified teeth, and no odontoblasts are formed. He considers that the dentine cap described by Beard is the succeeding horny tooth beneath that in use, and that it arises in the same manner by the cornification of epithelial cells. Professor Howes (4) in 1894 expressed the opinion that the 'odontoblasts' which Beard described showed no calcification, and Ayres (1) in the same year could find no trace of dentine or enamel.

If Warren's views are accepted, and the evidence afforded by his specimens would appear to be conclusive, these teeth

are in both *Petromyzon* and *Bdellostoma* horny structures derived from the epithelium, and have no likeness or analogy to calcified teeth.

It has been considered that the teeth of the Cyclostomes are vestiges of the calcified teeth of former types, but it is now more generally held that they represent a stage in tooth evolution.

As Dr. Bridge says (3), 'The structure and development of the teeth in the Cyclostomes lend no support to the view that these teeth are degenerate calcified structures. With greater probability they represent a stage in the evolution of teeth and dermal spines, which has been succeeded by a later stage in which calcification superseded cornification as a method of hardening.'

There is, in the first place, a downgrowth of the epithelium forming a kind of tooth follicle, and beneath this a small mesodermic papilla. The first indication of a forming tooth occurs above this papilla, and the epidermal cells become flattened. The tooth penetrates the superimposed cells and appears on the surface, the indication of another tooth being already present in a cornified layer of cells beneath it, as shown in the figure taken from Warren's paper (fig. 243). He draws attention to the close resemblance which this structure, with the mesodermal papilla below, bears to a developing hair. The figure shows that the tooth arises within the corium, and is not formed from cells derived from the mesoblastic papilla.

The Teeth of *Ornithorhynchus*. Horny structures which serve the functional purposes of teeth are seen in the *Ornithorhynchus*; but they are more correctly described as horny plates, for, as will be seen, these are the plates in which the true teeth of the animal are embedded, and are not developed, as in the Cyclostomata, as independent dental structures. For a long time these horny plates were considered to represent the only functional teeth of *Ornithorhynchus*, until in 1888 Professor Poulton (5) discovered true calcified teeth in an embryo. From an examination of the available material he concluded that the true teeth were beneath the horny plates, but Oldfield Thomas in 1889 (7), from an examination of other specimens, found that the calcified teeth were above

and embedded in the horny plates, and persist for a considerable portion of the life of the animal, and 'are only shed after being worn down by friction with food and sand'.

Dr. Semon, who has studied the habits of the *Ornithorhynchus*, says that it feeds chiefly on 'grubs, worms, snails, and, most of all, mussels', which are stowed into its cheek pouches, 'the food being chewed and swallowed above the surface as the animal drifts slowly along'. He considers

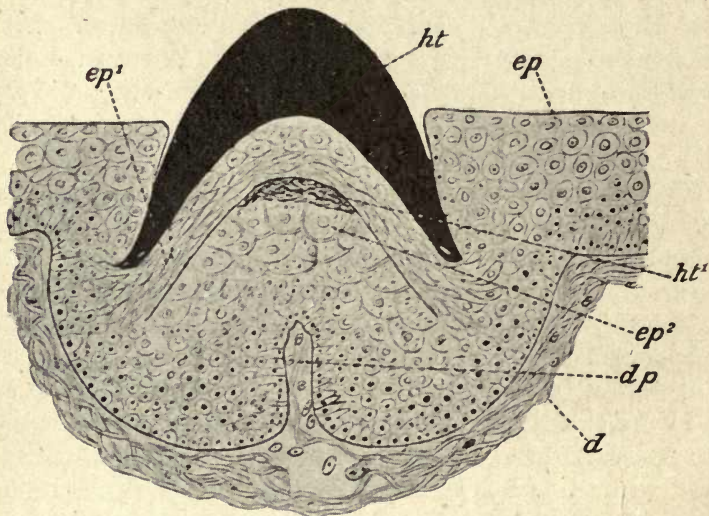


FIG. 243. Vertical section of developing tooth of *Petromyzon marinus*, showing a successional tooth which is just beginning to cornify at its apex beneath the functional tooth. *d*. Dermis; *dp*. dental papilla; *ep*. epidermis lining buccal funnel; *ep*¹. epidermis which has formed the horny functional tooth *ht*; *ep*². epidermis forming the horny cone of the successional tooth *ht*¹. (From Warren.)

that for cracking the hard shells of the mollusc upon which it mainly feeds, the horny plates are preferable to brittle teeth (6).

The eight or ten molar teeth which form the calcified dentition of the animal are replaced by the horny structures, which, developed from the epithelium of the mouth, are produced around and under the true teeth, embedding them, the short roots of the teeth passing through them to the bone of the jaw. As Dr. Beddard says, 'The epithelium of

the mouth grows gradually under the calcified teeth, a method of growth which has possibly something to do with the shedding of the latter'.

The calcified teeth, which are all molars, consist of dentine and enamel of somewhat imperfect structure, the dentine being characterized by the immense number of interglobular spaces present, which would appear to be an indication of imperfect calcification, which is still more apparent in the short roots; these, as C. S. Tomes says, 'are of a softer, coarser material than the crown, which itself is not of a high type of dentine structure'.

In the Tadpole, prior to the commencement of the formation of true calcified teeth, there are horny plates upon the jaws, and on the inner margins of the lips are numerous horny projections, each one of which is, according to C. S. Tomes, the product of a single epithelial cell; these little conical teeth, as well as the larger plates on the jaws, are continually being shed and renewed from beneath.

In the Chelonia (Turtles and Tortoises) there are no calcified teeth, but a horny casing covers both upper and lower jaws, which is broad and crushing in the vegetable feeders and elevated into a sharp ridge in the carnivorous species, as in *Chelone imbricata* (the Hawk's-bill turtle), where this horny covering forms a hooked beak with a sharp edge.

Horny plates are also present in the jaws of the Sirenia (Manatee and Dugong), which are considered to be allied to the Ungulates, although formerly classed as Cetaceans. These horny plates in the lower jaw of the Dugong cover the abortive rudimentary calcified teeth which never become functional.

REFERENCES

1. Ayres. *Biological Lectures at Wood's Hall*, 1894.
2. Beard, J. (a) 'The Nature of the Teeth of Marsipobranch Fishes.' *Morph. Jahrb.*, 1889, Bd. iii, pp. 727-53.
(b) 'The Teeth of Myxinoid Fishes.' *Anat. Anzeig.*, 1888, Bd. iii, pp. 169-721.
3. Bridge, T. W. *Cambridge Natural History*, vol. vii, p. 248.
4. Howes. *Nature*, Nov. 1894.

5. Poulton, E. B. (a) 'True Teeth in the Young Ornithorhynchus paradoxus.' *Proc. Roy. Soc. Lond.*, 1888, vol. xliii, pp. 353-56.
(b) 'The True Teeth and the Horny Plates of Ornithorhynchus.' *Quar. Journ. Micr. Sci.*, 1889, vol. xxix, N.S., pp. 9-48.
6. Semon, Dr. *In the Australian Bush.*
7. Thomas, O. 'On the Dentition of Ornithorhynchus.' *Proc. Roy. Soc. Lond.*, 1889, vol. xlvi, pp. 126-31.
8. Warren, E. 'On the Teeth of Petromyzon and Myxine.' *Quar. Journ. Micr. Sci.*, 1902, vol. xlv, pp. 631-7.

INDEX

- Abrachiate lacunæ, 294.
Absorption, 299.
 in temporary teeth, 300.
 in permanent teeth, 302.
Acrodont, 365.
Adsorption, 140.
Adventitious dentine, 251.
Aitchison Robertson, odontoblasts
 and nerve fibres, 224.
Alternations of absorption and
 deposition, 302.
Alveolodental periosteum, 305.
Ameghino on concrescence, 33.
Ameloblastic membranes, 132, 152.
 differential staining of, 133.
Ameloblasts, 129.
 Carter on Tomes' processes, 175.
 clear bodies in, 151, 172.
 communicating processes of, 133.
 crescentic nuclei in, 130, 150.
 cytoplasm of, 130.
 in Elasmobranchs, 179, 193.
 in Gadidæ, 180, 193.
 in Labridæ, 188, 193.
 in Sparidæ, 193.
 mitosis in, 150.
 Tomes' processes of, 131, 153, 171.
Amelo-dentinal junction, 77.
Amitotic division in cells of
 follicle, 319.
 in cells of Nasmyth's membrane,
 338.
Amphibia, epithelial sheath of
 Hertwig, 322.
Analysis of dentine, 238.
Analysis of enamel, 47.
 C. S. Tomes on, 48.
 Lovatt Evans on, 49.
Anaptomorphus, 35.
Anchylosis of teeth, 352, 363.
Andrews, R., on fibrillar basis of
 enamel, 157.
Angler, hinged teeth of, 361.
Ant-eater (Cape), 254.
Anterior superior dental nerve, 211.
Anthropoid apes, defects in enamel
 of, 57.
Archæopteryx, 3.
Arctomys, enamel of, 112.
Area, proportion to that of dentine,
 164.
Arnell on globular bodies in amelo-
 blasts, 152.
Arrhenius, 12.
Attachment of teeth, 352.
 by anchylosis, 363.
 in *Echineis*, 354.
 by elastic hinge, 352, 354.
 by fibrous membrane, 352.
 in Haddock, 361.
 in Hake, 356.
 by implantation in sockets, 365.
 in Pike, 362.
Attachment, bone of, 5, 353.
Auriculo-temporal nerve, 212.
Axon of nerve-end cells, 213.
Aye-aye, rodent type of dentition,
 116.
Ballowitz on sheath of Hertwig,
 332.
Bartels on lymphatics of pulp, 210.
Basal layer of Weil, 229.
Bateson, 8.
Baume, 15, 265.
Bdellostoma, 4, 366.
Beading of neurofibrils, 216.
Beaver, incisors of, 3.
 enamel of, 108.
Beckwith, gold process for nerves,
 227.
Bennett, F. J., action of glycerine
 on dentine, 282.
Beretta, A., on Nasmyth's mem-
 brane, 346.
Bettongia, enamel of, 97.
Beust, Von, fuchsin staining me-
 thod, 82.
Bibra, Von, 47, 237.
Birds, teeth of, 3.
Black, G. V., on absorption in
 cement, 304.
 on lime salts in dentine, 238.
 on lymphatics of periodontal
 membrane, 307.
 on mottled teeth, 71, 103.
 on nerves of periodontal mem-
 brane, 307.

- Blocks of calcified substance in enamel, 55.
- Blood-vessels in enamel organ, 184, 187, 193.
of pulp, 208.
- Boar, tusks of, 3.
- Boas, Von, on *Scarus*, 94.
- Bolk on evolution of molar teeth, 37.
- Bone of attachment, 5, 353.
- Bone dentine (Röse), 236.
and dentine, Von Ebner on, 265.
- Born, system of modelling, 18.
- Bowerbank on shell formation, 142.
- Branching of dental tubes, 244.
of prisms, 52.
- Bridge, T. W., on origin of horny teeth, 367.
- Bridges, connecting, in enamel, 65.
- Brunn, Von, on epithelial sheath, 262.
- Brush-like termination of nerves in pulp, 212.
- Budding of external epithelium, 123.
- Bulbous ending to tubes in *Bettongia*, 98.
- Cajal, Ramon y, on intercellular bridges, 153.
silver nitrate process, 98.
- Calcareous deposits due to physical processes, 144.
- Calcification, 134.
at birth, 30.
in fish, 177.
of dentine, 262, 278.
of enamel, 134.
- Calcified masses in follicle, 317.
- Calcium phosphate, influence of, 140, 168.
- Calcoglobulin, 139.
in forming dentine, 278.
- Calcospherites, 140.
coalescence of, 140.
in caries, 162.
in Crab, 141.
in dentine, 279.
in enamel, 159.
in Prawn, 141.
under osmotic membrane, 136.
- Calf, connective tissue in forming dentine of, 271.
- Cape ant-eater, 254.
- Capybara, cement in, 287.
enamel in, 112.
molar of, 106.
- Carious dentine, lamination at border of, 239.
- Carpenter, W. B., on shell formation, 142.
- Carter, T., on colloidal nature of fibril, 174.
on development in *Gadidæ*, 181.
on eruption, 348.
on marsupial enamel, 175.
on mitosis in ameloblasts, 150.
on outer ameloblastic membrane, 152.
on penetration of blood-vessels, 146.
on rhythmic deposit, 281.
- Carnivora, partial penetration of enamel by tubes, 105.
- Caush, D., on staining of enamel, 163.
- Cell accumulations in Nasmyth's membrane, 338.
division in ameloblasts, 150.
of follicle, 319.
of pulp, differentiation of, 202.
nests in Nasmyth's membrane, 338.
theory, 10.
- Cement, 287.
canaliculi of, 293.
Choquet on, 287.
connexion with dentine, 290.
conversion theory of development of, 299.
development of coronary cement, 294.
deposit in flakes, 296.
Hopewell Smith on lacunæ, 290.
incremental lines of Salter, 294.
Kölliker on, 296.
lacunæ of, 290.
lacunal cells in, 290.
lamination of, 290.
micro-organisms in, 292.
osteoblasts in, 296.
outer layer of, 293.
overlap of cement, 288.
in Ungulates, 287.
vascular canals in, 292.
- Cement organ, 294.
- Cement substance in enamel, 55.
- Cementum, *see* Cement, 287.
- Centrifugal calcification of enamel, 174.
- Centripetal calcification of enamel, 156.
- Cestration*, penetration of enamel by tubes, 84.
- Cetacea*, granular layer in, 241.
- Cheirromys*, dentition of, 116.
- Chelonia, 369.

- Chemical composition of dentine, 237.
of enamel, 47.
- Choquet, I., on absorption, 303.
on cement at neck of tooth, 287.
- Chromic acid, employed by Boll for nerves, 222.
- Cingulum, 33.
- Coalescence of calcospherites, 140, 279.
- Collagen, basis of dentine, 236.
- Collars of F. Paul, 206.
- Colloidal suspensions, 139.
- Communication of dentinal tubes with cement, 290.
- Concavo-convex form of enamel prisms, 69.
- Concomitant variation, 9.
- Concrescence theory, 33.
- Conical stage in development, 31.
- Connecting bridges, 16, 66.
- Connective tissue in dentine, 239, 266, 268, 272.
in dentine of Elephant, 271.
cells in developing dentine, 270.
in pulp-stone of Elephant, 252.
of pulp, 266.
in vasodentine, 285.
- Constant, T. E., on blood pressure in eruption, 347.
- Contour lines of Owen, 247.
- Conversion theory of development, 144, 264.
- Cope, E. D., on trituberculism, 11, 33.
- Copper sulphate experiment, 135.
- Creodonts, teeth of, 105.
- Crescentic nuclei of ameloblasts, 130.
- Crusta petrosa, 287.
- Cryer, M., 182.
- Cuscus, bulb-like ending to tubes, 98.
- Cyclostomata, 366.
- Cynomys*, vascular canals in dentine of, 259.
- Darwin, 7.
- Dahlgren and Kepner on amitotic division, 338
on infundibular gland, 194.
- Decussation of enamel layers in rodents, 108.
- Degenerated nuclei in Nasmyth's membrane, 340.
- Delabarre, 23.
- Dendrons of nerve-end cells, 213.
- Dental lamina or tooth-band, 15.
- Dentinal tubes in enamel, 82.
- Dentine, 236.
action of glycerine on, 282.
adventitious, 251.
calcification of, 262, 278.
calcoglobulin contours in, 278.
of *Cestracion*, 263.
chemical composition of, 237.
classification of, 236.
coalescence of spherites in, 279.
communication with cement, 290.
connective tissue basis of, 239.
development of, 262.
direction of calcific deposit, 282.
disintegration of spherites in, 161.
fibril, 248.
fibrillar nature of matrix, 265.
fine branches of tubes in, 244.
of Flounder, 256.
germ, 21.
granular layer of, 240.
Hanazawa on, 249.
Hoppe on sheath of Neumann, 250.
interglobular spaces in, 242.
lamination of, 280.
of *Lamna*, 262.
matrix of, 239, 265.
odontogenic zone, 239.
orthodentine, 237.
osteodentine, 260.
papilla, 21, 263.
plicidentine, 253.
primary curvatures of tubes, 246.
resemblances to bone in, 268.
Römer on dentinal fibril, 250.
of *Sarcophilus*, 260.
Schreger's lines in, 247.
secondary curvatures of tubes, 246.
sheath of Neumann, 248.
striation in, 278.
striation in Wombat, 281.
trabecular dentine, 237, 260.
transverse sections of, 247.
vasodentine, 256.
- Dentz on corpuscles in dentine, 230.
- Dependorf on nerves of dentine, 226.
- Dermal appendages, teeth considered as, 5.
- Descent with modification, 7.
- Development of cement, 294.
of dentine, 262.
of enamel, 119.
- Dewar, Sir J., 12.

- Dewey on lymphatics of pulp, 208.
 Dialysis, Graham on, 137.
 Diameter of enamel prisms, 55.
 Differential staining in tooth of Hake, 359.
 Dilatations in marsupial enamel, cause of, 166.
 Diphyodont, 32.
 Dipnoi, 177.
Dipus, enamel of, 84.
 Dogfish, eruption of teeth in, 348.
 Dominants, 7.
Dromotherium, 34.
 Dursy, 21.
 Duval on sensitiveness of dentine, 222.
- Ebner, V. von, on basal layer of Weil, 229.
 on detached tubes in enamel, 116.
 enamel of *Petaurus*, 115.
 enamel tubes in Hare, 115.
 fibres in dentine, 274.
 fibrillar nature of dentine, 266.
 fine branches of dentinal tubes, 245.
 function of odontoblasts, 276.
 globular bodies in ameloblasts, 152.
 Hertwig's sheath, 262.
 ingrowth of enamel tubes, 102.
 Leon Williams's views, 163.
 marsupial enamel, 173.
 Nasmyth's membrane and interprismatic substance, 163.
 resemblances between bone and dentine, 265.
 staining of enamel, 56.
 striæ of Retzius, 74.
- Echineis*, attachment of teeth in, 354.
 Edentates, Hertwig's sheath in, 331.
 Eel, attachment of teeth in, 353.
 Elasmobranchs, 84, 193.
 Elastic hinge, 354.
 Elephant, cement in, 287.
 connective tissue in dentine, 271.
 enamel prisms of, 66.
 incisors, 3.
 pulp stones in, 252.
 spear-head in tusk of, 232.
- Enamel, 46.
 analysis of, 48, 49.
 Bibra, Von, on, 47.
 calcified disks of, 56.
 calcium salts of, 47.
 of Capybara, 46.
 connecting bridges in, 56.
 cross striæ of, 55, 59.
 crypt, 39.
 defects in structure, 56, 58, 83.
 of Elephant, 46.
 Frankland's method for, 49.
 germ, 119.
 Harting on spherites in, 59.
 Hertz on, 59.
 Hoppe-Seyler on double salt in, 47.
 hypoplastic, 76.
 interprismatic substance, 71.
 Lovatt Evans on analysis of, 48.
 magnesium phosphate in, 47.
 organic matter in, 48, 55.
 penetration of, 82.
 position of, 46.
 radiating fibres in, 83.
 Retzius, striæ of, 72.
 Schreger's lines, 77.
 septum, 39.
 spindles in, 78.
 staining of, 58.
 thorn-like processes in, 78.
- Enamel prisms, 50.
 arcade arrangement of, 60.
 branching of, 53.
 concavo-convex forms, 61.
 course of, 64.
 diameter of, 54.
 Ebner, Von, on, 60.
 of Elephant, 66, 69.
 forms of, 60.
 granular nature of, 55.
 hexagonal forms, 52.
 impressions of, 76, 337.
 interlocking of, 66.
 Leon Williams on, 55.
 in Manatee, 52.
 membrane-like expansions on, 70.
 needle splitting of, 65.
 of *Phacochoerus*, 53.
 Pickerill on, 54.
 Smreker on, 60.
 supplementary, 53.
- Encapsuled lacunæ, 333.
 End cells, 217.
 Endoplasm, 200.
 Entoconid, 36.
 Epithelial coils, 24, 312.
 inflection, 13.
 pearls, 20, 308.
 remnants, 331.
- Erosion, calcospherites in, 163.
 Eruption of teeth, Carter on, 348.
 Constant on, 347.
 Fischer on, 349.
 W. James on, 347.

- Eruptive stage of Goodsir, 13.
 Eskimo, molar of, 35.
 Evans, Lovatt, on chemical composition of enamel, 48.
 Eye on stellate reticulum, 128.
 Evolution of tubular dentine, 257.
 Exoplasm, 200.
 Experiment on decalcification of enamel, 104.
 Extensibility of neurofibrils, 217.
 External epithelium, functions of, 121.
 not continuous, 314.
- Factors in eruption, 347.
 Fan-shaped spreading of Tomes' fibres, 157.
 Fat soluble in food, 170.
 Fenestrated membrane, 154, 319.
 Fibril, dentinal, 248.
 development of, 202.
 Fibrillar basis of enamel, 104, 157.
 of shell, 142.
 Fibrillar nature of dentine matrix, 265.
 Fibrous attachment of teeth, 352.
 nature of Rat enamel, 114.
 Fischer, G., on eruption, 349.
 Fish, early calcification of enamel in, 263.
 Retzius on nerve terminations in, 225.
 tooth development in, 30.
 Fixation, T. Carter on, 181.
 Flakes, cement deposited in, 296.
 Flounder, dentine of, 256.
 Fluoride of calcium, 237.
 Follicle of tooth, 311.
 epithelium in, 320.
 junction with tooth, 318.
 origin of, 311.
 Follicular stage (Goodsir), 13.
 Foramen ovale, 211.
 Forsyth Major, 36.
 Foundation fibres of dentine, 239, 265, 266.
 Frankland's method, 49.
 Fritsch on innervation of dentine, 227.
 Functions of stellate reticulum, 127.
 of stratum intermedium, 147.
- Gadidæ, 84, 180.
Gadus aeglefinus, 181, 361.
Galeus, injury of jaw by spine, 353.
 Galippe on absorption, 303.
 Gasserian ganglion, 211.
 Gebhart, 272.
 Gegenbaur on osteoblasts, 299.
 Gelatine-yielding fibres, 274.
 Gels, 137.
 Germ cells, 10.
 Gidley, 37.
 Gland-like enamel organ of *Tautoga*, 187.
 Glands of Serres, 17, 23, 310.
Globes épidermiques, 24, 312.
 Golgi method for dentine, 225, 244.
 Gomphosis, 352, 365.
 Goodsir on development, 13.
 Graham on dialysis, 137.
 Granular layer of dentine, 240.
 Granularity of prisms at dentine margin, 83.
 Granules in ameloblasts, 151.
 of enamel blocks, 57.
 in enamel of *Sargus*, 92.
 Gubernaculum, 23.
 Gum, structure of, 309.
- Haddock, modified hinge in, 361.
 Hagfish, 366.
 Haidenhain on connective tissue, 197.
 Hair and teeth, relations of, 5.
 Hake, hinged teeth of, 356, 358.
 striation in dentine of, 285.
 connective tissue in pulp, 271.
 vasodentine of, 256.
Halichoeres, 186.
 Halle on lymphatics of pulp, 210.
 Hanazawa on dentine, 204, 249.
 Haplodont, 34.
 Hare, absence of pigment in enamel, 106.
 Harrington, N. R., on lime-secreting glands, 194.
 Harting, P., on calcospherites, 139, 167.
 on structure of prisms, 59.
 Haversian canals in cement, 292.
 Heidelberg mandible, pulps of teeth in, 233.
 Hertwig, O., on epithelial sheath, 296.
 on placoid scales, 177.
 Hertz on enamel striae, 59.
 on secretion theory, 265.
 on spindles of enamel, 78.
 Heterodont, 32.
 Höhl, E., on Neumann's sheath, 283.
 Homodont, 32.
 Honeycomb, 156.

- Hopewell Smith on absence of lacunæ in cement, 290.
 on absorption in permanent teeth, 301.
 on blood-vessels in enamel organ, 121.
 on dentine development, 271.
 on myelinic fibres and connective tissue, 275.
 on nerves of pulp, 224.
 on odontoblasts as sensation transmitters, 223.
 on tubes in *Sargus*, 88.
- Hoppe on sheath of Neumann in fossil teeth, 250.
- Hoppe-Seyler on double salt in teeth, 47, 168.
- Hopson, M., on overgrowth of Rat incisors, 107, 232.
- Horny plates of *Ornithorhynchus*, 367.
- Horny teeth, 366.
- Howship's lacunæ in absorption, 301.
- Huber on nerve terminations, 218, 225.
- Humphreys, J., on evolution of teeth, 43.
- Hunter, J., on secretion theory, 265.
 on sensitiveness of dentine, 222.
- Hutton, 12.
- Huxley, T. H., on dental lamina, 14.
 on evolution, 10.
 on 'membrana preformativa', 152-335.
 on Nasmyth's membrane, 333.
- Hydrochaærus*, molar of, 106.
- Hyenodon*, 105.
- Hypocone, 35.
- Hypoconid, 36.
- Hypoconulid, 36.
- Hypoplastic enamel, 76.
- Imbrication lines in Nasmyth's membrane, 336.
- Imperfections in enamel, 56.
- Implantation of teeth, 5.
- Impressions of cells on Nasmyth's membrane, 336.
 of prisms on Nasmyth's membrane, 336.
- Incremental lines in enamel, 75.
- Independent calcification of inter-prismatic substance, 161.
- Inner dental nerve, 212.
 maxillary nerve, 211.
- Inner ameloblastic membrane, 132.
- Intercolumnar bridges, 66.
- Interglobular spaces, 241.
- Interlocking of tissues in Elephant, 78.
- Internal epithelium, processes of nuclei of, 130.
- Involution of epithelial cells, 119.
- Iron and tannic stain for lateral processes of odontoblasts, 206.
 for nerves, 227.
- James, W. W., on cells of follicle, 316.
 on epithelial coils, 24, 312.
 on eruption, 347.
- Kangaroo rats, persistent pulps in, 233.
 spindles in enamel of, 81.
- Kassander on osteoblasts, 298.
- Keith on Krapina teeth, 233.
- Kelvin, Lord, 11.
- Keratinization of follicle cells, 319.
- Klaatsch, 178.
- Klein on intracellular fibrillæ of dentine, 268.
 on termination of nerves of pulp, 223.
- Kölliker on deposit of cement in flakes, 296.
 on development, 14.
 on enamel tubes, 102.
 on fine branches of dentinal tubes, 245.
 on inner layer of Nasmyth's membrane, 334, 344.
 on origin of connective tissue fibres, 197.
 on osteoblasts, 299.
 on secretion theory, 265.
 on termination of pulp nerves, 223.
- Korff, Von, on connective tissue in dentine, 200, 271, 274.
- Körner on lymphatics of pulp, 210.
- Krapina teeth, pulp cavities in, 233.
- Kükenthal on concrecence, 33, 42.
- Labio-dental lamina, 15.
- Labridæ, penetration of enamel by tubes in, 84, 93.
- Labrus bergylla*, 192.
- Labrus*, eruption in, 6.
- Labyrinthodon, 254.
- Lacunæ of cement, 288.
- Lacunal cells, 289.
- Lamarck, 10.
- Lamellæ of cement, 288.
- Laminæ in dentine of Hake, 256.

- Laminæ in enamel, 159.
 Lamination of dentine, 239, 280.
Lamna cornubica, enamel of, 84, 86.
 Lamprey, 366.
 Lankester, Sir E. R., 12.
 Lateral enamel ledge of Bolk, 38.
 Law, W. J., on blood-vessels in enamel organ, 122.
 on nerves of dentine, 230.
 Layers of Nasmyth's membrane, 325.
 Leche on dentine papilla, 21.
 on development, 14.
 on development in fish, 30.
 Leduc on osmotic growths, 11.
 on rhythmic periodic deposit, 281.
 Lent on Nasmyth's membrane, 334.
 on secretion theory, 265.
Lepidosteus, 253.
 Leporidae, 108.
 Leucocytes, as origin of osteoblasts, 298.
 Liesegang's rings, 281.
 Lime salts in dentine, Black on, 238.
 Lingual nerve, 212.
 Loeb on semi-permeable membranes, 137.
Lophius, 361.
Lumbricus, lime-secreting glands in, 194.
 Lymphatics of periodontal membrane, 307.
 of pulp, 208.
 McKay on mottled teeth, 71.
 Mackenzie, Dr., 259.
 Mackerel, attachment in, 363.
Macropus, blood-vessels in enamel organ, 122.
 slow calcification in, 263.
 staining of enamel in, 164.
 teased preparations of, 66, 158.
Macropus billiardieri, vessels in, 121.
 Magitot on cement organ, 294.
 on dental follicle, 311.
 on external epithelium, 122.
 on nerve terminations, 224.
 Malassez on absorption, 303.
 on dental ligament, 305.
 on epithelial débris, 311.
 on external epithelium, 122.
 on follicle, 312.
 on gubernaculum, 23.
 Mall on connective tissue fibres, 197.
 Manatee, alveolus of, 365.
 dentine of, 257.
 enamel of, 52.
 Marcusen, 14.
 Marginal plexus, 218.
 Marmot, Prairie, dentine of, 112.
 Marsupial tubular enamel, 96.
 ameloblastic membranes in, 152.
 bending of tubes in, 97.
Bettongia, termination of tubes in, 98.
 calcospherites in, 159.
 Carter, T., on, 174.
 decalcification of, 104.
 development of, 173.
 dilatations in enamel of, 97, 165.
 fibrillar foundation of, 104, 157.
 honeycomb in, 156.
 organic basis of, 103.
 Paul on, 165.
 staining of, 100.
 teased preparations of, 66.
 Tomes, C. S., on tubes of, 103.
 on development of, 173.
 Tomes, J., on tubes in, 97.
 Tomes' processes of, 153.
 transverse sections of, 100, 102.
 transverse striation in, 158.
 variations in amount of penetration by tubes, 97.
 Matrix of cement, 288.
 of dentine, 239, 265.
 Medullary canals of osteodentine, 261.
Megatherium, dentine of, 257.
 Mellanby, feeding experiments, 170.
 'Membrana preformativa' of Huxley, 335.
 Membrane-like expansions in enamel, 65.
 Membranes in enamel organ, 132.
 Mendel, researches of, 7.
 Mental branch of inferior maxillary nerve, 212.
 Mesenchyme cells, 197.
Mesonyx, 105.
 Metacone, 34.
 Metaconid, 36.
 Methylene blue intra-vitam staining, 227.
 Middle superior dental nerve, 211.
 Miller, W. D., on interlocking of tissues in elephant, 78.
 on lime salts in dentine, 238.
 Molar, evolution of human, 32.
 Monophodont, 32.
 Morgan on lymphatics of pulp, 210.
 Morgenstern on nerves of pulp, 225.
 Motor root of fifth nerve, 211.

- Mouse, termination of enamel organ
 in, 323.
 Multitubercular theory, 32.
 Muridæ, enamel of, 113.
 Myliobates, 254.
Myxine, 4.
- Narwhal, incisor of, 3, 350.
 Nasmyth's membrane, 333.
 as a dialysing membrane, 344.
 attachment to follicle, 342.,
 Biretta, A., on, 346.
 cell accumulations in, 338.
 cell nests in, 338.
 cells involved in, 335.
 cellular layer of, 337.
 clear layer of, 335.
 considered as cement, 333.
 elongated cells in, 340.
 impressions of cells on, 336.
 of prisms on, 336.
 inclusion of deep cells of follicle
 in, 343.
 keratinization of cells of, 337.
 longitudinal sections of, 340.
 methods of preparation of, 334.
 Navel, enamel, of Bolk, 39.
 Needle-like splitting of prisms, 65.
 Neo-Lamarckians, 11.
 Nerves of the pulp, 212.
 accompanying blood-vessels, 208.
 at cornu of pulp, 212.
 axons of nerve cells, 213.
 Beckwith method of staining,
 227.
 brush-like spreading of axis
 cylinder, 212.
 dendrons of end cells, 213.
 end cells, 213, 218.
 medullated nerves of pulp, 212.
 of periodontal membrane, 306.
 plexus of Raschkow, 213, 229,
 230.
 supply to odontoblasts, 218.
 subdivisions of, in pulp, 212.
 authors on, 222.
 Aitchison Robertson, 223.
 Boll, 222.
 Dependorf, 226.
 Duval, 222.
 Fritsch, 227.
 Hopewell Smith, 223.
 Huber, 225.
 Hunter, J., 222.
 Klein, 223.
 Kölliker, 223.
 Law, 230.
- Magitot, 224.
 Morgenstern, 225.
 Pont, 226.
 Retzius, 225.
 Römer, 226.
 Salter, 222.
 Weil, 224.
- Neumann's sheath, 237, 248.
 dependent on calcification, 283.
 Neurofibrils around odontoblasts,
 218.
 beading of, 216.
 extensibility of, 216.
 in dentinal tubes, 218.
 wavy course of, 216.
 Neuron theory, 214, 220.
 New Mexico mammals, 33.
 Noyes on lymphatics of pulp, 208.
- Odontoblasts, Aitchison Robertson
 on, 224.
 dentinal process of, 206.
 development of, 202, 264.
 functions of, 276.
 Hopewell Smith on, 223.
 lateral processes of, 206.
 Paul on, 206.
 pulp processes of, 206.
 Odontogenic zone, 239, 264.
 Olfactory nerve, 225.
 Ollendorf on lymphatics of pulp,
 210.
 Organic basis of enamel, 103.
 Origin of enamel spindles, 81.
 of Hertwig's sheath, 322.
 of species, 7.
Ornithorhynchus, teeth of, 4, 367.
 Orthodentine, 237.
Orycteropus, 254.
 Osborn on mammalian molar, 32.
 on neo-Lamarckism, 11.
 Osmotic membranes, 136.
 Osseous fish, development in, 180.
 Osteoblasts, origin of in forming
 cement, 296.
 Osteoclasts, 308.
 in implanted teeth, 302.
 Osteodentine, 260.
 calcification of, 285.
 in *Heterodontus*, 261, 263.
 in *Lamna*, 262.
 in Pike, 362.
 Ostwald on colloids, 139.
 Outer ameloblastic membrane, 132.
 Outer layer of dentine in relation
 to cement, 293.
 of teeth in *Selachia*, 237.

- Oval bodies in ameloblasts, 151.
 spherites in enamel, 160.
 Overgrowth of Rodent incisors, 107.
 Owen, R., contour lines of, 247.
 on coronal cement, 333.
 on penetration of Shark's jaw by
 Sting-ray, 353.
 on Rodent enamel, 108.
- Pagellus*, 192.
 Pangenesis, 11.
 Papillary stage of Goodsir, 13.
 Paracone, 34.
 Paul on collars of odontoblasts, 206.
 on external epithelium, 121.
 on functions of stellate reticulum, 127.
 on inclusions of dentine matrix, 165.
 on Nasmyth's membrane, 334.
 on tubes of marsupial enamel, 103.
- Pauli and Samec on solubility of calcium salts, 169.
 Pavement epithelium, 60.
 Pea, Mendel's experiments on, 7.
 Periodicity of deposit, 281.
 Periodontal membrane, 305.
 blood-vessels of, 306.
 direction of fibres in, 305.
 lymphatics of, 307.
 nerves of, 306.
 origin of, 308.
 sensibility of, 309.
- Peripheral sensory neuron, 220.
 Persistence of cells of tooth-band, 316.
 of external epithelium, 340.
 Persistent pulps, 230.
- Petaurus*, Von Ebner on enamel of, 115.
Petromyzon, 366.
Phalanger, terminations of enamel tubes, 98.
 Philip on osmotic membranes, 138.
 Physical phenomena in calcification, 135.
 Pigmentation in Retzius's striae, 74.
 of Rodent enamel, 106.
- Pike, hinging in tooth of, 362.
Pinna, shell-membrane in, 143.
 Pitts, A. T., on eruption, 347.
 Placoid scales, 145, 177.
 stage of development, 31.
 Plagiostomes, development, 178.
 succession of teeth in, 352.
- Pleurodont, 365.
 Plicidentine, 253.
- Polybunty, 36.
 Polyphyodont, 32.
 Pont on peripheral neurons, 226.
 Porcupine, enamel of, 112.
 Posterior superior dental nerve, 211.
 Post-permanent teeth, 21.
 Poulton on blood-vessels in enamel organ, 122.
 on teeth of *Ornithorhynchus*, 367.
- Pradentine, 239.
 Prairie marmot, 259.
 Prawn, calcification in, 142.
 Precipitation of phosphates, 169.
 Pre-milk teeth, 20.
 Preponderance of phosphates in enamel and dentine, 167, 237.
- Primary curvatures of dentinal tubes, 246.
 Primitive dental groove of Goodsir 13.
 Primitive dental lamina, 15.
 Prisms of enamel, 50.
 Processes of connective-tissue cells, 198.
 Proliferation of cells of follicle, 311.
 Protocone, 34.
 Protoconid, 36.
 Protodont, 34.
 Prussian blue for lymphatics of pulp, 210.
- Pseudolabrus*, 186.
 secreting organ in, 148.
Pseudoscarus, absorption of enamel in, 94.
 blood-vessels in enamel organ, 146.
 maxillary teeth of, 96.
- Pulp stones in Elephant, 252.
 Python, anchylosis in, 363.
- Rainey on disintegration of spherites, 279.
 on molecular coalescence, 138.
 Ranvier on origin of connective tissue, 197.
 on periodontal membrane, 305.
- Raschkow, plexus of, 212, 230.
 Rat, connective tissue in dentine, 271.
 course of prisms, 113.
 fibrous nature of enamel, 114.
 overgrowth of incisors, 232.
 secreting organ in, 129.
- Rath, Von, on amitotic division, 338.
 Recessives, 8.
 Redier on absorption, 303.
 Reduction of organs, 9.

- Relations of areas of enamel and dentine, 180.
 of nerves and vessels in pulp, 208.
 Reptiles, tooth development in, 30.
 nerve terminations in, 225.
 Resorption of enamel tubes, 117.
 Retzius, brown striæ of, 72.
 on nerve terminations, 218, 225.
 on nerves in fish and reptiles, 218.
 Robin and Magitot on cement organ, 294.
 on external epithelium, 122.
 on structure of follicle, 314.
 Rodent enamel, 106.
 Rods of enamel, 55.
 Römer, O., on degenerated nuclei, 340.
 on nerves of dentine, 226.
 on non-existence of Neumann's sheath, 249.
 on spindles of enamel, 80.
 on structure of dentine, 250.
 on branching of dentinal tubes, 243.
 Röse, C., on basal layer of Weil, 229.
 on classification of dentines, 236.
 on concrecence, 42.
 on development of teeth in reptiles and fish, 30.
 on incorporation of fibres from odontoblasts in dentine, 266.
 on stellate reticulum, 127, 146.
 on surface membrane in Plagiostomes, 179.
 on tooth-band in birds, 3.
 Ryder, 11.
- Salter, J., on termination of pulp nerves, 222.
 Sappey, 23.
Sarcophilus ursinus, 258.
Sargus, enamel organ of, 193.
 blood-vessels in, 182.
 eruption in, 350.
 staining of tubes in enamel, 86.
 vascular canals in, 94.
Sargus noct, 89, 186.
ovis, 87.
vulgaris, 90.
 Sawfish, persistent pulp in, 233.
 Schafer, Sir E. A., on connective tissue, 197.
 nutrition of enamel organ, 24.
 osteoblasts, 298.
 secretion theory in cement, 299.
 Schreger's lines in dentine, 247.
 in enamel, 77.
- Schwann on conversion theory, 265.
 Schweitzer on lymphatics of pulp, 208, 210.
Sciurus, enamel of, 111.
 Scleroblasts, 177.
 Scott on origin of premolar, 36.
 Secondary curvatures of dentinal tubes, 246.
 Secondary dentine, 251.
 Secreting organ in *Sargus*, 184.
 in *Tautoga*, 187.
 Secretion theory, 144, 265.
 Segregation, 8.
 Semon on habits of *Ornithorhynchus*, 368.
 Sensory and trophic fibres, 221.
 Sensory nature of nerves of pulp, 220.
 Sensory neuron, 220.
 Serration of prisms in rat, 113.
 Serres, glands of, 17, 310.
 Sexual selection, 9.
 Sharpey's fibres in cement, 290.
 Sheath of Hertwig, 296, 320.
 source of cells of, 325.
 Sheath of Neumann, 237, 248.
 Shell, calcification of, 139.
 Smreker on enamel prisms, 60.
 Socketing of teeth, 352.
 Sols, 137.
 Somatic cells, 10.
Sorex, tubular enamel of, 84.
 Spaces at amelodentinal junction, 165.
 Spee, Graf von, on globular bodies in ameloblasts, 152.
 Speech, teeth as aids to, 3.
 Spindles in enamel, 78.
 relation of nerves to, 220.
 Staining of enamel, 58.
 Starling, Professor, 227.
 Starr on lymphatics of pulp, 210.
 Stellate reticulum, 120.
 absence in lower vertebrates, 127.
 form of cells, 125.
 Leon Williams on, 125.
 part in calcification, 146.
 Röse on, 127, 146.
Sterna Wilsoni, tooth germs in, 3.
 Stratum intermedium, blending with ameloblasts, 128.
 nuclei of cells of, 128.
 processes of cells of, 133.
 Striation in dentine, 278.
 of enamel prisms, 59.
 Stroma in enamel organ of Gadidæ, 180.

- Studnicka on fibres in dentine, 274.
 Successional teeth, formation of, 16.
 Superior maxillary nerve, 211.
 Supernumerary teeth, origin of, 20.
 Surface tension, 139.
 Symington, J., skiagram of development, 24.
 Synapses, 213, 226.
- Tadpole, horny teeth of, 369.
 Taeker on paracone, 37.
 Talbot, E., on absorption in cement, 304.
 Talon, 34.
 Tarsius, 35.
 Tasmanian devil, 258.
Tatusia, 32.
Tautoga onitis, 186, 193.
 Teased preparations of marsupial enamel, 62, 158.
Terebratula, membrane in, 143.
 Terminations of nerves at cement margin, 219, 246.
 at enamel margin, 219.
 in enamel spindles, 226.
 of tubes in *Macropus*, 165.
 Testut on lymphatics of pulp, 210.
 Thomas, Oldfield, on teeth of *Ornithorhynchus*, 367.
 Thompson, D'Arcy W., on adsorption, 140.
 on calcareous deposits, 144.
 on Liesegang's rings, 281.
 on organic particles in space, 12.
 on Pauli and Samec's views, 169.
 Tims, W. Marett, on blood-vessels in enamel organ, 121.
 on cingulum, 33.
 on monophyodonts, 32.
 on pre-milk teeth, 21.
 on teeth of Canidæ, 37.
 Tomes, Sir Charles, on ameloblastic membranes, 133.
 on bone of attachment, 5, 353.
 on chemical composition of enamel, 48.
 on classification of dentines, 236.
 on clumsy joint, 165.
 on conversion theory, 265.
 on crescentic nuclei, 130.
 on development in Elasmobranchs, 178.
 on development in Gadidæ, 180.
 on development in marsupials, 153.
 on enamel of *Selachia*, 84.
 on eruption of teeth, 347.
 on incorporation of Tomes' processes, 145.
 on interprismatic substance, 71.
 on Nasmyth's membrane, 333.
 on nature of tubular enamel, 103, 173.
 on origin of Rodents, 116.
 on post-permanent teeth, 21.
 on stellate reticulum, 128.
 on teeth of Creodonts, 105.
 on terminations of dentinal tubes, 165.
 Tomes, Sir John, decalcification of marsupial enamel, 104.
 on dentinal fibril, 248.
 on enamel of marsupials, 97.
 on enamel of Rodents, 108.
 on granular layer in Rodents, 240.
 on serration of prisms in rat, 113.
 Tomes' processes of ameloblasts, 131, 153.
 Torrens, 7.
 Trabecular dentine, 236, 260.
 Transverse fibrillation of marsupial enamel, 157.
 sections of marsupial enamel, 100.
 tubes in dentine, 206.
 Traube's membranes of precipitation, 135.
 Triconodon, 34.
 Trigon, 34.
 Trigonid, 36.
 Trituberculism, 33.
 Tschermak, 7.
 Tubes in enamel from without, 84, 96.
 Tubular dentine, 236.
 enamel, 84.
- Underwood on cells of stellate reticulum, 127.
 on external epithelium, 340.
 on spaces between ameloblasts, 131.
 on spherites in erosion, 163.
 on striæ of Retzius, 74.
 Unequal wear of tissues, 107.
 Unerupted teeth of *Sargus*, 91.
 Ungulates, cement in, 287.
- Varanus*, attachment in, 365.
 Vascular canals in cement, 292.
 in dentine, 253.
 in dentine of Rodents, 259.

- Vascular loops in dentine of
 Manatee, 257.
 of *Cynomys*, 259.
 of *Sarcophilus*, 258.
 of *Sargus*, 258.
- Vascular tubes in *Labrus*, 185.
 in *Sargus*, 185, 193.
- Vasodentine, 236, 256.
 calcification of, 283.
 connective tissue in, 285.
 transition to orthodentine, 257.
- Vertical succession of teeth, 90,
 350.
- Vries, De, on evolution, 7.
- Waldeyer on connective tissue, 197.
 on conversion theory, 264.
 on Nasmyth's membrane, 334.
 on spindles in enamel, 78.
- Walkhoff on cement substance of
 enamel, 71.
 on imperfections in enamel, 58.
 on Smreker's views, 61.
 on spindles of enamel, 80.
- Wallaby, blood-vessels in enamel
 organ of, 121.
- Walrus, tusks of, 3.
 persistent pulps in, 233.
- Wart-hog, enamel of, 54.
- Water in combination in enamel,
 237.
- Wavy course of neurofibrils, 216.
- Wedl on blood-vessels in enamel
 organs, 147.
- Weil on basal layer, 228.
 on nerves of pulp, 224.
- Weissmann on acquired characters,
 10.
- Wellings on spaces between amelo-
 blasts, 131.
 on stellate reticulum, 127.
- Wharton's jelly, 198.
- Wilkinson on absorption in im-
 planted teeth, 302.
- Williams, Leon, on enamel, 163,
 173.
 on fibrous enamel of Rat, 114.
 on functions of stratum inter-
 medium, 149.
 on globular bodies in ameloblasts,
 152.
 on independent calcification of
 prisms, 163.
 on secreting organ in Rat, 129.
 on striæ of Retzius, 74.
- Wilson on amitotic division, 338.
 on the cell, 10.
- Wing processes of prisms, 62.
- Woodhead, G. Sims, on calcification,
 168.
 on rarefying osteitis, 303.
- Woodward, S., on evolution of
 molar, 37.
- Wombat, absence of enamel tubes,
 97.
 persistent pulps in, 233.
 striation of dentine in, 281.
- Zsigmondy on striæ of Retzius, 76.

SOME OTHER
OXFORD MEDICAL PUBLICATIONS.

THE SCIENCE AND PRACTICE OF DENTAL SURGERY. Edited by **NORMAN G. BENNETT, M.B.**, Dental Surgeon to St. George's Hospital, &c. Assisted by 34 well-known Dental Surgeons. Crown 4to ($10 \times 7\frac{1}{2}$). Cloth. 993 illustrations. Pp. 797. Price £2 2s. 0d. net. Complete in one volume.

‘We commend it as a book of reference to every medical man.’—*British Medical Journal*.

STOMATOLOGY IN GENERAL PRACTICE :
or Diseases of the Teeth and Mouth. By **H. P. PICKERILL, CH.B., M.D.S. (Birm.), L.D.S. (Eng.)**. Demy 8vo ($8 \times 5\frac{1}{2}$). Cloth. 65 illustrations. Pp. 280. Price 17s. net.

This work fills the gap between medicine and dentistry. It includes the anatomy and physiology of the teeth, deformities of the jaw and teeth, fractures of the jaw, oral tumours, &c. The surgical treatment of the teeth is limited practically to the local treatment of deep cavities, pericementitis and alveolar abscess. The operation of extraction is described, but the filling of teeth is merely mentioned. The technic of mechanical dentistry is not entered into. The surgery of the jaw, and especially the treatment of fractures, is fully described.

‘The book is comprehensive, and reference is made to almost every condition of disease which occurs in the mouth.’—*British Medical Journal*.

OXFORD MEDICAL PUBLICATIONS.

17 WARWICK SQUARE, NEWGATE STREET, LONDON, E.C. 4.

PRINTED AT OXFORD, ENGLAND
BY FREDERICK HALL
PRINTER TO THE UNIVERSITY

THIS BOOK IS DUE ON THE LAST DATE
STAMPED BELOW

AN INITIAL FINE OF 25 CENTS

WILL BE ASSESSED FOR FAILURE TO RETURN
THIS BOOK ON THE DATE DUE. THE PENALTY
WILL INCREASE TO 50 CENTS ON THE FOURTH
DAY AND TO \$1.00 ON THE SEVENTH DAY
OVERDUE.

BIOLOGY LIBRARY

FEB 10 1940

MAR 11 1941

APR 12 1948

MAR 13 1950

MAY 18 1950

JUN -2 1950

APR 20 1959

MAY 22 1964

MAY 22 1964

~~DEC 14 1963~~

U.C. BERKELEY LIBRARIES



C026157827

462588

QL757

M9

summary

BIOLOGY
LIBRARY
G

UNIVERSITY OF CALIFORNIA LIBRARY

