

③ OUTLINE
OF
PHYSICAL DIAGNOSIS
OF THE
THORAX
—
CORWIN

RC

76

C83

10
4492

LIBRARY OF CONGRESS.

RC 76
Chap. Copyright No.

Shelf. C835

UNITED STATES OF AMERICA.





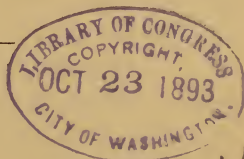
OUTLINE
OF
PHYSICAL DIAGNOSIS
OF THE
THORAX

BY

ARTHUR M. CORWIN, A. M., M. D.,

Demonstrator of Physical Diagnosis in Rush Medical
College; Attending Physician to The Central Free,
and Bethesda Free Dispensaries, Depart-
ment of Rhinology, Laryngology
and Diseases of the Chest.

10
4192



45730y1

CHICAGO:
THE W. T. KEENER COMPANY,
96 WASHINGTON ST.
1893.

— K

~~RC 74
C 35~~

RC 76
C 83

COPYRIGHT, 1893,
BY ARTHUR M. CORWIN.

PREFACE.

THE following outline aims to present in systematic form the gist of the science of physical diagnosis, as applied to the thorax.

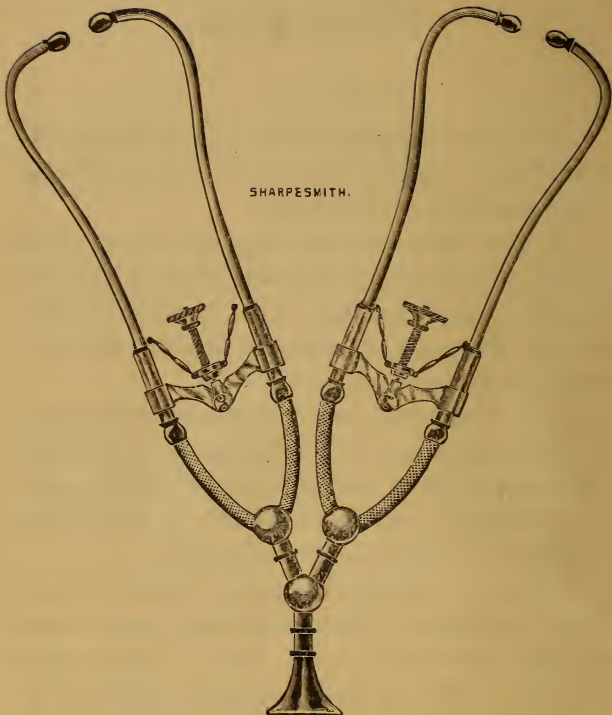
In this form it is hoped that the salient points of the subject may be the more readily grasped by those who are all too busy, while in medical college, to seek them out of extensive treatises and to arrange them for proper assimilation.

It is designed to meet the immediate demands of the student, and to be a further guide to a more elaborate study of the theme as set forth in existing literature, and as furnished in the clinical material of public and private practice.

While the intention has been to confine the subject to the thorax, reference has been made to some of the abdominal organs, and to various phenomena of the circulatory system outside of the chest, where these have seemed to be specially related to the chest cavity and its organs.

I am indebted to Drs. John M. Dodson, James B. Herrick, John Edwin Rhodes and George H. Weaver, for suggestions in the correction of proof.

A. M. C.



SHARPESMITH.

DOUBLE BINAURAL STETHOSCOPE.

This instrument is the author's combination of two of Knight's stethoscopes, and is designed for use in class instruction.

INDEX.

	Page
Adventitious sounds.....	83
Ægophony.....	81
Alar chest.....	32
AMPHORIC breathing.....	73
cough.....	83
voice.....	82
Aneurismal fremitus.....	52
Angle of Lewis.....	27
Aorta, landmarks of.....	24
Aortic diastolic murmur.....	103
Aortic pulsation.....	40
Aortic systolic murmur.....	98
Aortic valve, position of.....	23
Apex beat.....	22, 41, 44
Apnoea.....	35
Arterial movements.....	46
Auscultation.....	66
Axillary lines.....	16
Barrel-shaped chest.....	32
Bell sound.....	89
Bradycardia.....	50
BREATHING, amphoric.....	73
bronchial.....	71
broncho-cavernous.....	73
cavernous.....	72
cogwheel.....	76
exaggerated.....	74
feeble.....	74
interrupted.....	76
laryngeal.....	71
metamorphosing.....	73
puerile.....	74
suppressed.....	76
tracheal.....	71
Bronchial voice.....	80
Bronchi, primary.....	21
Bronchophony.....	80

Capillary pulsation.....	40
CARDIAC dulness.....	23
flatness.....	23
or endocardial murmurs.....	96
sounds, normal.....	89
Carotid pulsation.....	40
CAVERNOUS breathing.....	72
cough.....	83
whisper.....	82
Cerebral blowing.....	109
Cheyne Stokes breathing.....	36
Cogwheel breathing.....	76
Collapsing pulse.....	48
Color.....	28
Cough, varieties of.....	83
Cracked-pot resonance.....	65
Crepitant rales.....	86
Crumpling sounds.....	87
Diastolic, organic murmurs.....	101
DULNESS.....	61
cardiac.....	23
hepatic.....	24
splenic.....	26
Dyspnoea.....	35
ELEMENTS OF percussion sounds.....	58
sounds.....	79
Emphysematous chest.....	32
Epigastric pulsation.....	44
EXAGGERATED breathing.....	74
pulmonary resonance.....	60
vocal resonance.....	80
Expiratory sound prolonged.....	78
Fissures of the lung.....	18
FLATNESS.....	61
cardiac.....	23
hepatic.....	24
splenic.....	26
Form of the chest.....	31
Fremitus.....	51, 53

FRICION sounds	87
pericardiac.....	95
pleuro-pericardiac.....	95
Functional murmurs	106
Funnel breast.....	32
HEART, landmarks of.....	22
normal sounds of.....	89
HEPATIC dulness.....	24
flatness	24
pulsation.....	39
Hypopnœa	35
Innominate artery.....	24
Inspection.....	28
INSPIRATORY SOUND.....	
shortened	77
Intra-ventricular murmur.....	105
JUGULAR murmur.....	110
presystolic pulsation	39
Laryngeal breathing.....	71
LIVER, dulness of.....	24
outline of	24
LUNGS, fissures	18
lobes of... ..	20
outline of	17
Mammillary lines.....	16
Mensuration.....	55
Metallic tinkling.....	88
Metamorphosing breathing.....	73
Methods of physical diagnosis.....	28
Mitral valve, position of.....	24
Moist rales.....	83
MOVEMENTS, arterial	46
circulatory.....	39
MURMUR, aortic, diastolic.....	103
aortic, systolic.....	98
mitral systolic.....	69

MURMUR, non-valvular, organic.....	105
pulmonic, diastolic.....	105
systolic.....	100
tricuspid.....	99
presystolic.....	104
MURMURS, diastolic, organic.....	101
endocardial.....	96
exocardial.....	95
functional.....	106
valvular.....	96
NORMAL, pulmonary resonance.....	59
cardiac sounds.....	89
modifications of.....	91
vesicular breathing.....	69
vocal resonance.....	79
Nutrition.....	28
Orthopnoea.....	36
Palpation.....	45
Para-sternal lines.....	16
Pectoriloquy.....	81
PERCUSSION.....	55
sounds.....	58
Pigeon breast.....	31
PITCH, factors in its production.....	59
of sound.....	58
Pleximeter.....	56
Plexor.....	56
Præcordial pulsation.....	44
PULMONIC valve, position of.....	23
regurgitant murmur.....	105
systolic murmur.....	100
PULSATION, aortic.....	40
capillary.....	40
carotid.....	40
epigastric.....	44
hepatic.....	39
jugular.....	39
præcordial.....	44

PULSE, collapsing.....	48
characteristics of.....	46
dicrotic.....	49
factors in its production.....	46
force of.....	48
frequency of.	50
fullness of.....	47
intermittent.....	49
irregular.....	49
quality of.....	46
rhythm of.....	49
tension of.....	46
PULSUS bigeminus.....	49
paradoxicus.....	46, 47
trigeminus.....	44
Quality of sound.....	58
Radial Pulse.....	46
Rales.....	83
Reduplication of the heart sounds.....	92, 94
Regions of the chest.....	10
RESONANCE, bone.....	61
cracked-pot.....	65
exaggerated pulmonary.....	60
normal vesicular.....	59
tympanitic.....	63
vocal.....	79
Respiration, <i>vide</i> breathing.....	
Respiratory expansion.....	30
Rhachitic chest.....	32
Rhonchal fremitus.....	53
RHYTHM, respiratory.....	70, 76
of the pulse.....	49
Ribs.....	27
Scapula.....	28
Shoemaker's breast.....	32
Sibilant rales.....	85
Size of the chest.....	30
Sonorous rales.....	85

SOUNDS, auscultatory.....	96
cardio-pulmonary.....	96
elements of.....	58, 79
friction.....	87
normal cardiac.....	89
percussion.....	58
pitch of.....	58
pulmonary.....	69
quality of.....	58
respiratory.....	69
rhythm of.....	69
succussion.....	89, 111
tussive.....	82
vascular.....	108
whispering.....	82
Spleen.....	25
Stethoscope.....	67
Sternal lines.....	16
Subcrepitant rales.....	84
Tachycardia.....	51
TRICUSPID presystolic murmur.....	104
systolic murmur.....	99
valve, position of.....	24
Tympany.....	63, 64, 65
Valves of the heart.....	23
Vascular fremitus.....	52
Venous hum.....	110
Vertebræ.....	27
Vesicular breathing.....	69
VOCAL fremitus.....	53
resonance.....	79
sounds.....	79
Voice, amphoric.....	82
Water-hammer pulse.....	48
Whispering sounds.....	82

THE PHYSICAL DIAGNOSIS
OF THE CHEST.

THE PHYSICAL DIAGNOSIS OF THE CHEST.

DEFINITION. Physical Diagnosis is the science and art of objective examination of the body as practiced upon its surface.

THE SCIENCE of physical diagnosis deals with the character, causes and significance of physical signs and the methods of eliciting them. * *Signs* are objective features as distinguished from *symptoms*, which are purely subjective.

THE ART of physical diagnosis is the practical application of the science.

THE TOPOGRAPHY OF THE CHEST.

The topography of the chest deals with the regions, their boundaries and their contents.

ANTERIOR REGIONS.

SUPRA-CLAVICULAR regions.

BOUNDARIES:

ABOVE, the line drawn from the upper ring of the trachea to the junction of the external with the middle third of the clavicle.

BELOW, the superior border of the inner two-thirds of the clavicle.

INTERNALLY, the anterior border of the sterno-cleido-mastoid muscle.

CONTENTS: the apices of the lungs; parts of the subclavian and carotid arteries; and the subclavian and jugular veins, on either side.

CLAVICULAR regions.

BOUNDARIES, the margins of the inner two-thirds of the clavicle.

CONTENT:

RIGHT SIDE, the apex of the lung.

EXTERNALLY, the subclavian artery.

INTERNALLY, the innominate artery and recurrent laryngeal nerve.

LEFT SIDE, the apex of the lung.

EXTERNALLY, parts of the subclavian vessels.

INTERNALLY, parts of the subclavian and carotid vessels.

INFRA-CLAVICULAR regions.

BOUNDARIES:

ABOVE, the lower border of the clavicle.

BELOW, the lower border of the third rib.

INTERNALLY, the border of the sternum.

EXTERNALLY, a line let fall from the junction of the middle with the outer third of the clavicle, and passing down an inch to the outer side of the nipple, (some authorities give the mammillary line.

CONTENTS:

EITHER SIDE, lung tissue.

RIGHT SIDE, a part of the aorta, descending vena cava, and right bronchus.

LEFT SIDE, the pulmonary artery, and left bronchus, the base of the heart and great vessels.

MAMMARY regions.

BOUNDARIES:

ABOVE, the lower border of the third rib.

BELOW, the lower border of the sixth rib.
INTERNALLY, the margin of the sternum.
EXTERNALLY, the line let fall from the junction of the middle with the outer third of the clavicle passing an inch to the outer side of the nipple.

CONTENTS:

RIGHT SIDE, the lung, right lobe of the liver, right auricle, right ventricle and diaphragm.

LEFT SIDE, the lung and heart.

INFRA-MAMMARY regions.

BOUNDARIES:

ABOVE, the lower border of the sixth rib.

BELOW, the lower border of the false ribs and cartilages (the costal arch).

INTERNALLY, the costal arch.

EXTERNALLY, the line let fall from the junction of the middle with the outer third of the clavicle.

CONTENTS:

RIGHT SIDE, the lung on deep inspiration, the right lobe of the liver.

LEFT SIDE, the lung and the left lobe of the liver.

SUPRA-STERNAL region.

BOUNDARIES:

ABOVE, the first ring of the trachea.

BELOW, the inter-clavicular notch.

LATERALLY, the anterior borders of the sterno-cleido-mastoid muscles.

CONTENTS: the trachea, thyroid gland, vessels and œsophagus.

SUPERIOR STERNAL region.

BOUNDARIES:

ABOVE, the inter-clavicular notch.

BELOW, the line on a level with the third costal cartilages.

LATERALLY, the margins of the sternum.

CONTENTS: the lung below the level of the second costal cartilage, the descending vena cava, aorta, pulmonary artery, and bifurcation of the trachea.

INFERIOR-STERNAL region, includes the sternum below the level of the third rib.

CONTENTS: a part of the right auricle and the origins of the pulmonary artery and aorta; a small part of the left lung; a part of the right ventricle, right lung and liver, and a part of the attachment of the pericardium to the diaphragm.

LATERAL REGIONS.

AXILLARY regions.

BOUNDARIES:

ABOVE, the axilla.

BELOW, a line on a level with the lower border of the mammary region.

ANTERIORLY, the vertical line let fall from the junction of the middle with the outer third of the clavicle.

POSTERIORLY, the anterior or axillary border of the scapula.

CONTENTS: lung tissue, and the main bronchi deeply placed.

INTRA-AXILLARY regions.

BOUNDARIES:

ABOVE, the axillary region.

BELOW, the margins of the false ribs.

ANTERIORLY, the external boundary of the infra-mammary region.

POSTERIORLY, a line let fall from the inferior angle of the scapula (scapular line).

CONTENTS:

EITHER SIDE, lung tissue.

RIGHT SIDE, the right lobe of the liver.

LEFT SIDE, the spleen and part of the stomach.

POSTERIOR REGIONS.

SUPRA-SCAPULAR regions.

BOUNDARIES, those of the supra-spinous fossæ.

CONTENTS: the apices of the lungs.

SCAPULAR regions.

BOUNDARIES, those of the infra-spinous fossæ.

CONTENTS: lung tissue.

INTER-SCAPULAR region.

BOUNDARIES:

EXTERNALLY, the posterior borders of the scapulæ. The region extends from the level of the second to that of the seventh dorsal vertebra.

CONTENTS:

RIGHT SIDE, the lung, bronchial glands, and main bronchus.

LEFT SIDE, the lung, glands, main bronchus, aorta, thoracic duct, and œsophagus.

INFRA-SCAPULAR regions.

BOUNDARIES:

ABOVE, inter-scapular and scapular regions.

BELOW, the margins of the false ribs.

POSTERIORLY, the spines of the dorsal vertebræ, below the seventh.
ANTERIORLY, the scapular line.

CONTENTS:

RIGHT SIDE, the liver, lung and upper end of the kidney.

LEFT SIDE, the lung and a part of the spleen, kidney and intestines.

LANDMARKS OF THE CHEST.

LINES OF REFERENCE.

VERTICAL lines of reference.

MESO-STERNAL line, the mid-line of the sternum.

STERNAL lines, right and left, corresponding to the lateral margins of the sternum.
MAMMILLARY (loosely termed mammary) lines, right and left, passing vertically through the nipples.

PARA-STERNAL lines, right and left, passing vertically midway between the mamillary and sternal lines on the respective sides.

ANTERIOR AXILLARY lines, right and left, passing vertically through the points at which the pectorales majores leave the chest, the arms being at right angles to the body.

POSTERIOR AXILLARY lines, right and left, passing vertically through the points at which the latissimis dorsi leave the chest, the arms being at right angles to the body.

MID-AXILLARY lines, right and left, midway between the anterior and posterior axillary lines.

SCAPULAR lines, right and left, passing vertically through the inferior angles of the scapulæ.

VERTEBRAL line, passing through the spines of the vertebræ.

HORIZONTAL line of reference.

HORIZONTAL NIPPLE LINE.

OBLIQUE line of reference.

LINEA-COSTO-ARTICULARIS, drawn from the left sterno-clavicular articulation to the free end of the left eleventh rib.

LANDMARKS OF THE LUNGS.

OUTLINE of the lungs.

OUTLINE OF THE RIGHT LUNG.

THE APEX extends an inch and a half above the first rib, and is apt to be a little lower than the apex of the left lung.

THE ANTERIOR BORDER lies in the meso-sternal line from the level of the second to the level of the sixth costal cartilage.

THE INFERIOR BORDER lies as follows, in the average position; on deep inspiration it is depressed an inch and a half lower.

IN THE MAMMILLARY LINE at the sixth rib.

IN THE MID-AXILLARY LINE at the eighth rib.

IN THE SCAPULAR LINE at the tenth rib.

OUTLINE OF THE LEFT LUNG.

THE APEX extends one inch and a half to two inches above the first rib.

THE ANTERIOR BORDER lies in the meso-sternal line from the level of the second to the level of the fourth costal cartilage.

THE INFERIOR BORDER lies (in the average position),

IN THE MESO-STERNAL LINE, at the fourth costal cartilage.

IN THE PARA-STERNAL LINE, at the fifth rib.

IN THE MAMMILLARY LINE, at the sixth rib.

IN THE MID-AXILLARY LINE, at the eighth rib.

IN THE SCAPULAR LINE, at the tenth rib.

FISSURES of the lungs.

FISSURES OF THE RIGHT LUNG.

THE LONG FISSURE.

ITS POSITION: it separates the lower from the middle and upper lobes.

ITS DIRECTION is from above and behind, obliquely downward and forward.
ITS RELATION to the chest is about as follows:

NEAR THE VERTEBRAL COLUMN, it is three inches below the apex of the lung (near the inner end of the spine of the scapula).

IN THE MID-AXILLARY LINE, it is about the level of the fourth rib.

JUST WITHIN THE MAMMILLARY LINE, it cuts the lower margin of the lung at the sixth rib.

THE SHORT OR LESSER FISSURE.

ITS POSITION: it separates the upper from the middle lobe.

ITS DIRECTION is obliquely downward and forward from a point near the anterior border of the scapula, where it joins the long fissure.

ITS RELATION to the chest wall is about as follows: It lies at first nearly under the third rib, but crosses the third intercostal space about the mammillary line, and cuts the anterior border of the lung about the junction of the fourth costal cartilage with the sternum.

FISSURE OF THE LEFT LUNG.

THE LONG FISSURE (the left lung has but one fissure).

ITS POSITION: it separates the upper from the lower lobe.

ITS DIRECTION is from above and behind, obliquely downward and forward.

ITS RELATION to the chest wall is as follows: (in the average position.)
NEAR THE VERTEBRAL COLUMN, it is about three inches below the apex of the lung.

IN THE MID-AXILLARY LINE, it is about the level of the fourth rib.

IN THE MAMMILLARY LINE, it cuts the lower margin of the lung at the sixth rib.

LOBES of the lungs.

ANTERIORLY:

ON THE RIGHT SIDE,

THE UPPER LOBE lies above the third intercostal space.

THE MIDDLE LOBE lies below the third interspace, reaching to the lower margin of the lung.

THE LOWER LOBE is practically absent anteriorly.

ON THE LEFT SIDE,

THE UPPER LOBE reaches from the apex to the lower margin of the lung.

THE LOWER LOBE is practically absent anteriorly.

LATERALLY:

ON THE RIGHT SIDE,

THE MIDDLE LOBE is present above the fourth rib.

THE LOWER LOBE reaches from the fourth rib to the lower margin of the lung.

ON THE LEFT SIDE,

THE UPPER LOBE lies above the fourth rib.

THE LOWER LOBE reaches from the fourth rib to the lower margin of the lung.

POSTERIORLY:

ON BOTH SIDES,

THE UPPER LOBE practically lies above the spine of the scapula.

THE LOWER LOBE reaches from the spine of the scapula to the lower margin of the lung.

THE TRACHEA.

DIMENSIONS.

LENGTH, four and one-half inches.

CALIBRE, three-fourths to one inch.

BIFURCATION, under the middle of the sternum about the level of the second costal cartilage, at the level of the third dorsal vertebra.

THE PRIMARY BRONCHI.

DIRECTION.

THE RIGHT bronchus is nearly horizontal.

THE LEFT bronchus is oblique.

POSITION.

THE RIGHT lies under the second rib.

THE LEFT lies under the second intercostal space.

LENGTH.

THE RIGHT is about one inch long.

THE LEFT is nearly two inches long.

CALIBRE.

THE RIGHT bronchus is larger than the left.

LANDMARKS OF THE HEART.

OUTLINE of the heart.

THE BASE nearly corresponds in level with the superior margin of the third rib.

THE APEX lies under the fifth intercostal space,

TWO INCHES BELOW the nipple (in the male) and

HALF AN INCH TO THE RIGHT of the left mammillary line.

THE RIGHT MARGIN corresponds with a line beginning on the third costal cartilage, half an inch to the right of the right sternal line, curving slightly to the right and downwards to the end of the sternum.

THE LEFT MARGIN corresponds with a line beginning on the third costal cartilage an inch to the left of the left sternal line, curving to the left and downward to the apex beat, but not including the nipple.

THE LOWER MARGIN corresponds nearly with a line joining the apex and the end of the sternum.

RELATION of the heart to the lung in front.

IT IS COVERED by the lung (*cardiac dullness*) from the upper margin of the third to the lower margin of the fourth rib, and below the fourth rib between the para-sternal line and left margin of the heart.

IT IS UNCOVERED by the lung (*cardiac flatness*) in the triangular or irregularly quadrilateral area bounded on the right by the meso-sternal line, on the left and above by a line drawn from the fourth costal cartilage to a point a little to the right of the apex beat.

VALVES of the heart.

POSITION (Gray).

SEMI-LUNAR VALVES.

THE PULMONIC valve lies behind the left sternal line at the level of the third costal cartilage.

THE AORTIC valve lies close to the left sternal line, behind the third intercostal space.

AURICULO-VENTRICULAR VALVES.

THE TRI-CUSPID valve lies behind the meso-sternal line about the level of the fourth costal cartilage,

THE BI-CUSPID or mitral valve lies about one inch to the left of the sternum behind the third intercostal space.

LANDMARKS OF THE AORTA.

The aorta is most superficial in the right second intercostal space at the edge of the sternum. The arch of the aorta lies an inch below the inter-clavicular notch.

LANDMARKS OF THE INNOMINATE ARTERY.

Its course may be traced by an oblique line drawn from the mid-sternal line at the level of the second costal cartilage to the right sterno-clavicular articulation.

LANDMARKS OF THE LIVER.

RIGHT LOBE of the liver.

ITS UPPER MARGIN lies

IN THE MAMMILLARY LINE, at the fourth intercostal space.

IN THE MID-AXILLARY LINE, at the sixth rib.

IN THE SCAPULAR LINE, at the eighth rib.
ITS LOWER MARGIN lies half an inch below the costal arch, in the average healthy adult male.

RELATION of the liver to the lung.

IT IS COVERED by lung (*hepatic dullness*.)

IN THE MAMMILLARY LINE, from the fourth interspace to the sixth rib.

IN THE MID-AXILLARY LINE, from the sixth to the eighth rib.

IN THE SCAPULAR LINE, from the eighth to the tenth rib (the lower margin of the lung may be depressed an inch and a half on deep inspiration).

IT IS UNCOVERED by lung (*hepatic flatness*) from these points (sixth, eighth, and tenth ribs) downwards.

LEFT LOBE of the liver.

THE UPPER MARGIN lies under and against the diaphragm, adjoining the heart.
ITS LOWER MARGIN (in the median line) lies about midway between the end of the appendix sterni and umbilicus.

ITS LEFT MARGIN reaches nearly to the left mammillary line.

LANDMARKS OF THE SPLEEN.

THE SPLEEN IS COMPLETELY SHELTERED beneath the ribs, and cannot be felt in health except in rare cases.

THE OUTLINE of the spleen.

ITS UPPER MARGIN lies under the ninth rib.

ITS LOWER MARGIN lies under the eleventh rib.

ITS ANTERIOR EXTREMITY nearly reaches the linea-costo-articularis, drawn from the free end of the eleventh rib to the left sterno-clavicular articulation.

ITS POSTERIOR EXTREMITY approaches within two-thirds of an inch of the body of the tenth dorsal vertebra.

THE DIRECTION is obliquely backward and upward, the long axis corresponding nearly with the direction of the tenth rib.

THE RELATION of the spleen to the lung.

IT IS COVERED by lung in its posterior and upper third, which lies in the infra-scapular region.

IT IS UNCOVERED by lung in its anterior and lower two-thirds, which lie chiefly in the infra-axillary region.

LANDMARKS OF THE VERTEBRÆ.

THE SEVENTH CERVICAL VERTEBRA, vertebra prominens, is readily made out.

THE TWELFTH DORSAL VERTEBRA may be located by reference to the twelfth rib, which may be felt when the lumbar muscles are relaxed; in muscular subjects it may be located by following the lower margin of the trapezius muscle.

ALL THE SPINES are located by slight friction with the finger, reddening the skin over their tips.

SLIGHT CURVATURE of the vertebral column to the right or left exists in right or left handed persons.

LANDMARKS OF THE RIBS.

THE SECOND RIB is on a level with the prominence (*angle of Lewis*) more or less marked in all persons, at the junction of the first and second pieces of the sternum.

THE SEVENTH RIB lies at the inferior angle of the scapula when the arms hang at the sides.

THE FIFTH RIB is just covered by the convex lower border of the pectoralis major.

THE THIRD COSTO-STERNAL JUNCTION is on a level with the body of the sixth dorsal vertebra.

THE HORIZONTAL NIPPLE LINE cuts the sixth intercostal spaces in the mid-axillary lines.

THE ELEVENTH AND TWELFTH RIBS can always be felt, when the abdominal wall is relaxed.

THE INFERIOR END OF THE STERNUM is on a level with the tenth dorsal vertebra.

LANDMARKS OF THE SCAPULA.

The scapula lies over the ribs from the second to the seventh. The inner end of the spine of the scapula is nearly on a level with the third dorsal vertebra, main bronchus and beginning of the pulmonary fissures behind.

METHODS OF PHYSICAL DIAGNOSIS.

INSPECTION.

Inspection gives the following points:

COLOR, which may be due to pigmentation, or vascularization, or both.

COLOR dependent upon *pigmentation* may be

NORMAL.

LOCAL, as in the areolæ about the nipples, color of the eyes and hair.

GENERAL, as in the Negro, Malayan, Indian, brunette and blonde.

ABNORMAL.

LOCAL, moles, lentigo, chloasma, the seat of scars.

GENERAL, icterus, argyria, Addison's disease.

COLOR dependent upon *vascularization*.

NORMAL, erythema, ruddy complexion or the opposite.

ABNORMAL.

LOCAL.

ARTERIAL, congestion, eruptions, etc.

VENOUS, ecchymosis, enlarged superficial veins and capillaries.

GENERAL.

ARTERIAL, congestion, or its opposite, pallor, chlorosis, anæmia.

VENOUS, cyanosis, morbus cæruleus.

COLOR dependent upon both vascularization and pigmentation, is observed in various cachexiæ, malignant disease, disease of the liver, etc.

NUTRITION is manifested by the degree of fatty deposits or muscular development, as well as by the color.

SIZE.

NORMAL size of the chest.

CIRCUMFERENCE of the chest at the level of the nipples.

AVERAGE circumference, thirty-four inches.

USUAL EXTREMES, twenty-eight to forty-four inches.

RESPIRATORY EXPANSION, two to seven inches.

AVERAGE two inches and a half.

USUAL EXTREMES, two to four inches.

SEMI-CIRCUMFERENCE laterally.

THE RIGHT SIDE is usually half an inch larger than the left in right-handed persons.

ABNORMAL, size in

CIRCUMFERENCE; this may be disproportionately

SMALL compared with the vertical diameter of the chest, when it is generally associated with flatness or hollowness of the upper anterior part of the chest, wing-like projection of the scapulæ, an acute costal angle, and deficient respiratory expansion. The circumference is apt to be disproportionately

LARGE in marked emphysema.

SEMI-CIRCUMFERENCE; either side of the chest may be

SMALL compared with the other, as a result of fibroid contractions of the lung on

that side, following pleurisy, pneumonia or collapse. It may be **LARGE** as compared with the other, in case of extensive pleuritic effusion or pneumo-thorax.

FORM of the chest.

NORMALLY the chest is a nearly symmetrical, truncated, conical pyramid, flattened slightly in its antero-posterior diameter.

ABNORMAL forms of the chest.

ASYMMETRICAL forms.

LOCAL BULGINGS may be due to swellings or tumors of the *chest-wall*: sarcoma, periostitis, abscess; or to pressure from the *intra-thoracic or abdominal organs*: aneurism, enlargement of the liver, prominence of the precordia from cardiac hypertrophy in children. Distension of one-half of the thorax occurs from pleuritic effusion or from pneumo-thorax.

LOCAL DEPRESSIONS, as the retraction of the supra and infra-clavicular regions from contraction of the apex of the lungs in phthisis; or the retraction of the chest in any region following fibroid induration of the lung.

RELATIVELY SYMMETRICAL forms of the abnormal chest.

THE PIGEON BREAST deformity of the chest, occurs chiefly in childhood and is characterized by lateral constriction of the thorax, with straightening of the true ribs and prominence of the lower end of the sternum; this is a result of rhachitis.

THE RHACHITIC CHEST is developed in early life; it is characterized by lateral retraction of the thoracic walls, the anterior surface being broader than in the pigeon breast, and the sternum less prominent; the costo-chondral junctions are thickened, presenting a series of bead-like eminences, known as the *rhachitic rosary*.

THE ALAR CHEST is characterized by wing-like projections of the scapulæ, usually associated with a narrow chest, sloping shoulders, and an acute costal angle. It is commonly significant of constitutional weakness, which favors the development of pulmonary phthisis.

THE EMPHYSEMATOUS OR BARREL-SHAPED CHEST is characterized by roundness of contour, the antero-posterior diameter being lengthened, the transverse diameter shortened and the upper end of the sternum prominent; the intercostal spaces are wide and full, the shoulders are thrown forward, the scapulæ separated, and the whole posture stooping.

FUNNEL BREAST, characterized by sinking in of the lower end of the sternum is a congenital deformity, sometimes observed in several branches of the same family; it may be so marked as to interfere seriously with respiration. *Shoemaker's breast* is an acquired deformity of similar form, and is caused by the pressure of tools against the lower part of the sternum.

HARRISON'S GROOVE is a horizontal line of depression along the false ribs, corresponding to the insertion of the diaphragm; it is sometimes observed in conditions of chronic dyspnœa necessitating powerful action of the diaphragm, especially in rachitic children.

SPINAL CURVATURES; the chest may be asymmetrical or symmetrical, deviations being either antero-posterior, or lateral, or both. These may be due either to defective development of the bodies of the vertebræ, or to caries.

MOVEMENTS.

GENERAL muscular movements are of interest as being normally or abnormally present or absent, paralysis, chorea.

RESPIRATORY movements.

NORMAL breathing is termed *eupnœa*.

THE NUMBER of respirations per minute in the adult is sixteen to twenty-four.

THE RHYTHM or ratio of the inspiratory to the expiratory *act* is as six to seven (Gibson), there being no pause between them.

THE TYPES of respiration include costal or *superior costal* breathing as observed in women, *inferior costal* breathing as usually observed in men, abdominal or *diaphragmatic* breathing as seen in children.

ABNORMAL breathing regards the—

FORM of the chest during respiration.

EXPANSION of the chest in abnormal breathing.

DIMINISHED expansion may be unilateral or bilateral (*vide* the conditions and causes of feeble respiration, **BULGING** of the intercostal spaces during expiration is observed in emphysema.

RETRACTION of the soft parts of the chest, xiphoid process and false ribs in inspiration occurs in croup, paralysis of the vocal cords, and other conditions involving obstruction of the upper air-passages.

RAPIDITY OF MOTION IN RESPIRATION.

ABNORMALLY RAPID respiration is termed *hyperpnœa*. This is observed **AFTER EXERTION** or as a result of **EMOTIONAL EXCITEMENT**;

IN FEVER especially in nervous persons, and **IN CHILDREN**, where a rate of sixty per minute has frequently been observed. **IN ALL CONDITIONS CAUSING PAINFUL BREATHING**, such as diseases of the pleura, diaphragm and peritoneum, fracture of the ribs, pleurodynia. **IN DISEASES NARROWING THE BRONCHIAL TUBES**: asthma, bronchitis.

IN CONDITIONS LESSENING THE AÉRATING AND CIRCULATORY AREAS OF THE LUNGS.

Pulmonary Diseases: emphysema, œdema, pneumonia, etc.

Pleuritic Affections: fluids, or solid tumors in the pleural cavity pressing upon the lungs.

Abdominal Affections: tumors, swellings, or effusion.

IN PARESIS OF THE RESPIRATORY MUSCLES.

ABNORMALLY SLOW RESPIRATION might well be termed *hypopnoea*. This is observed in the course of Cheyne Stokes respiration, and sometimes in diseases of the brain and meninges; in acute infectious diseases with marked mental dullness; in stenosis of the upper air-passages, due to intra-tracheal tumors, foreign bodies, inflammation, compressions from without, and paralysis of the abductors of the vocal cords.

SUSPENDED RESPIRATION is termed *apnoea*, which is due to want of a proper stimulus to respiration, owing to saturation of the blood with oxygen and the presence of a deficient amount of carbonic-acid gas; it is observed in the course of Cheyne Stokes respiration.

VARIATION IN THE RHYTHM OF RESPIRATION. An increase in the number or depth of respiration, or both, is the chief characteristic of *dyspnoea* or difficult breathing.

DYSPNOEA.

VARIETIES OF DYSPNOEA.

Inspiratory dyspnoea: dyspnoea may be purely inspiratory, or it may be asso-

ciated with difficult expiration in varying degree; it is the result of obstruction to the ingress of air into the lung, and is observed in croup, compression of the trachea and paralysis of the diaphragm, etc.

Expiratory dyspnoea, pure, or associated with difficult inspiration, is due to obstruction to the exit of air from the lung as is typically observed in asthma and emphysema.

Mixed expiratory and inspiratory dyspnoea is most frequent; it is observed in many diseases of the lungs and heart, and in fever.

Exaggerated dyspnoea, or *orthopnoea*, requiring the sitting or standing posture and the use of the extra muscles of respiration is observed in acute asthma and in advanced cardiac disease, etc.

Cheyne Stokes Respiration is characterized by a number of shallow respirations which become deeper to a given point, and then grow more superficial till they apparently entirely cease; after a pause (apnoea) the series is repeated, the whole cycle occupying from a few seconds to several minutes. During the pause the pupils are dilated and consciousness is usually lost. In some cases consciousness returns with deep breathing. This is *normal* in animals during hibernation; *abnormal* in man, due to cerebral or medullary disease (meningitis, hemorrhage, tumors); uræmia; certain affections of the heart; and in opium poisoning.

CAUSES OF DYSPNŒA.

Respiratory causes of dyspnœa may depend upon

Insufficient quantity of air supplied to the lungs, owing to

Imperfect respiratory movements, due to

Paralysis;

Pain, as in inflammation of the pleura and peritoneum; pleurodynia, intercostal neuralgia, trichinosis of the diaphragm, etc.

Muscular weakness;

Yielding walls of the chest due to rickets and fractures.

Lessened Capacity of the chest, due to

Bony malformations;

Pressure from thoracic or abdominal effusion or tumors.

Loss of elasticity of the chest wall: myositis ossificans; scleroderma of the chest.

Loss of elasticity of the lungs from emphysema, pleural adhesion, prolonged compression.

Lessened lumen of the air passages:

Extra-mural causes: cicatricial contractions, pressure of tumors.

Intra-mural causes: thickening of the walls of the air passages, muscular spasm, as in bronchitis, asthma and laryngismus stridulus.

Inter-mural: foreign bodies, secretions and false membranes within the air passages.

Diminished surface for circulation and interchange of gases in the lung, owing to

Inflammation of the lungs: pneumonia, fibrosis, tuberculosis.

Collapse or compression of the lung from pressure of air, fluid or solids: tumors, pleural effusion, pneumo-thorax.

Destruction of the alveolar capillary network, as in emphysema.

Modified quality of the air which is inhaled.

Insufficient density due to heat, high altitude, decreased atmospheric pressure.

Deleterious adulterations: noxious gases, etc.

Insufficient oxygen.

Circulatory causes of dyspnoea include

Diminished quantity of blood aerated, owing to:

Oligæmia, after acute hæmorrhage.

Pulmonary ischæmia, from

Vis a fronte, due to

Pulmonary Disease: emphysema, fibrosis, compression, etc.

Arterial Disease.

EXTRA-MURAL: compression, ligation.

INTRA-MURAL: inflammation of the arterial coat.

INTER-MURAL: embolism.

Vis a tergo, due to

Cardiac inefficiency from

VALVULAR DISEASE.

COMPRESSION OF THE HEART by pericardiac or pleuritic effusion.

MUSCULAR WEAKNESS of the heart from atrophy, myocarditis, degeneration, etc.

Modified quality of the blood.

Super-heated blood acts on the respiratory center, *heat dyspnoea*.

Deteriorated blood: pernicious anæmia, fevers, poisons.

CIRCULATORY MOVEMENTS.

VASCULAR MOVEMENTS.

VENOUS movements (pulsations).

NORMAL VENOUS MOVEMENTS.

JUGULAR PRESYSTOLIC pulsation is rarely visible to a slight degree in health. (Vierordt).

ABNORMAL VENOUS MOVEMENTS.

JUGULAR SYSTOLIC pulsation occurs in tricuspid regurgitation.

HEPATIC venous systolic pulsation is sometimes visible in marked tricuspid regurgitation.

ARTERIAL movements (pulsation).

NORMAL ARTERIAL MOVEMENTS.

CAROTID pulsation is frequently visible under the angle of the jaw, varying with the degree of adiposity, and the force and excitation of the heart.

AORTIC pulsation is exceptionally visible in the supra-sternal region (high position of the arch).

ABNORMAL ARTERIAL PULSATION.

CAROTID pulsation, when marked, may signify hypertrophy of the left ventricle, insufficiency of the aortic valve, arterial sclerosis (aortic), or aneurism. **AORTIC** pulsation

In the neck is sometimes due to insufficiency of the aortic valve, to aneurism, or to hypertrophy of the left ventricle.

In the right second intercostal space pulsation is always abnormal and is usually significant of one of the conditions just mentioned.

PULMONARY arterial pulsation appears to the left of the sternum in aneurism of this artery.

CAPILLARY pulsation may be seen in

Marked hypertrophy of the left ventricle, but more often in marked **aortic insufficiency**. The pulsation is observed in the bed of the finger nails, at the fundus of the eye, and in the mucous membrane of the lip under pressure of a glass slide.

CARDIAC MOVEMENT (pulsation).

APEX BEAT of the heart.

CAUSE of the apex beat: The heart changes in form, shortening and thickening in systole, and at the same time changes in position revolving on its axis, the apex being projected forward.

VISIBILITY of the apex beat.

NORMALLY the visibility varies with the

Shape of the chest, and the width of the intercostal spaces;

Thickness of the chest wall from the presence of fat, muscle and mammary gland;

Posture of the body, the apex being less visible in recumbency;

Force of the heart's action, as dependent upon its innate power and its excitation.

ABNORMALLY the visibility of the apex beat varies greatly.

Very marked pulsation is usually observed in hypertrophy;

Slight or absent pulsation is observed in

Conditions of cardiac weakness from

General debility, or

Local weakness of the heart's muscle, dependent upon cardiac atrophy; cardiac degeneration: fatty, fibroid, or amyloid; or cardiac dilatation.

Interposition between the heart and chest wall, of air: emphysema, pneumo-thorax, pneumo-pericardium; *fluid:* pleuritic or pericardiac effusion; *solids:* tumors, fibrinous deposit.

Thickening of the chest wall: excessive fat, scleroderma, œdema, emphysema of the chest wall.

Displacement of the heart, as by traction from behind by fibroid contraction.

• **LOCATION** of the apex beat.

NORMAL LOCATION OF THE APEX BEAT.

In the adult male it is in the fifth intercostal space, two inches below and one inch inside the nipple line.

Variations from the position in the healthy adult male accord with

Age: in children under ten years the apex beat is usually in the fourth intercostal space in or outside the left mamillary line; in old age it is apt to be lower down, sometimes in the sixth intercostal space.

Respiration. Deep inspiration may carry it down to the sixth interspace.

Posture on the

LEFT SIDE, may carry it to the left of the nipple line.

RIGHT SIDE, to the right of the usual position.

Physical exertion or emotion. The apex beat may become stronger or broader, or may be carried to the left when the individual is greatly excited.

ABNORMAL LOCATION OF THE APEX BEAT; it may be displaced, Upwards.

Pushed up by deformity of the chest wall; pericardiac effusion (here it is apparently so); abdominal tympanitis, tumors and ascites; paralysis of the diaphragm.

Pulled upwards by fibroid contraction of the upper lobe of the left lung. Upwards and to the left.

Pushed upwards and to the left by hypertrophy of the left lobe of the liver, or by abdominal tumors.

Pulled by fibroid contractions of the left lung. Downwards and to the left.

Pushed downwards and to the left by deformity of the chest wall; large aneurism of the arch of the aorta, mediastinal tumors; right pleuritic effusion or pneumo-thorax; hypertrophy of the left ventricle (strong apex beat); dilatation of the left ventricle (weak apex beat).

Pulled downwards and to the left by fibroid contractions of the pleura and lung.

To the right.

Pushed to the right by deformity of the chest wall, emphysema of the lungs, left pleuritic effusion or pneumo-thorax, hypertrophy of the right ventricle.

Pulled to the right by fibroid contractions of the right lung, or held by pleuritic adhesion.

Located on the right side in transposition of the thoracic organs (a rare condition).

PRECORDIAL PULSATION is observed together with the apex beat, **IN VALVULAR DISEASE** frequently; in cardiac irritability, especially in thin or young persons; in adhesive pleurisy with mediastinal pericarditis, here there is usually a systolic drawing in of several intercostal spaces.

EPIGASTRIC PULSATION.

HYPERTROPHY OF THE RIGHT VENTRICLE, especially if accompanied by pulmonary emphysema, frequently causes a systolic pulsation or trembling of the epigastrium.

PULSATION OF THE NORMAL HEART may be transmitted to the epigastrium through an hypertrophied left lobe of the liver.

PULSATION OF THE NORMAL AORTA may be seen in the epigastrium in thin persons, especially when the stomach is empty.

PULSATION OF AN ABDOMINAL ANEURISM of the aorta, may be visible in the epigastrium.

VENOUS HEPATIC PULSATION, observed in the epigastrium, may occur in marked tricuspid insufficiency (rare).

PALPATION.

Palpation is the method of physical examination by the sense of touch, and it confirms much of what has been obtained by inspection; it reveals

SIZE, SHAPE, contour, roughness, etc.
CONSISTENCE, fluctuation,
MOISTURE AND HEAT; and elicits
PAIN.

SUPERFICIAL pain as in pleurodynia.

LOCALIZED pain, as in intercostal neuralgia, (three tender points).

DEEP SEATED pain, as in pleurisy.

MOVEMENTS.

MUSCULAR.

RESPIRATORY.

CIRCULATORY.

CARDIAC MOVEMENTS, (apex beat, precordial pulsation, etc.; (*vide* under inspection.

EXTENT.

LOCALIZED.

DIFFUSED.

CHARACTER.

INTENSITY.

RHYTHM.

VENOUS MOVEMENTS.

ARTERIAL MOVEMENTS upon palpation.

AORTIC dilating pulsation of aneurism, etc.

CAROTID pulse.

RADIAL pulse.

FACTORS IN THE PRODUCTION OF THE PULSE.

FORCE OF THE HEART'S BEAT.

ELASTICITY OF THE LARGE VESSELS.

RESISTANCE AT THE VALVULAR ORIFICES of the heart.

RESISTANCE IN THE ARTERIOLES and capillaries.

VOLUME OF THE BLOOD.

CHARACTERISTICS OF THE PULSE, as regards

QUALITY of the pulse.

Degree of tension of the pulse.

Increased or high tension makes the incompressible or hard pulse.

Tension is increased:

At the beginning of expiration, except in pulsus paradoxicus.

By accelerated action of the heart.

By stimulation of the vaso constrictors, as by the action of cold, electricity and certain drugs.

By diminished outflow of blood at the periphery.

By disease of the vessel walls: atheroma, sclerosis, old age; drugs, e. g. lead poisoning.

By compression of the large arterial trunks, ligation or pressure.

By impeded venous flow, as in pregnancy, constipation, chronic bronchitis, emphysema, nephritis, etc.

Decreased or low tension makes the compressible or soft pulse; tension is decreased,

At the beginning of inspiration, except in pulsus paradoxicus.

After a hemorrhage.

By stoppage of the heart.

In elevated parts of the body.

By stimulation of the vaso dilators, action of drugs.

Degree of fullness of the artery, or volume of the pulse.

Increased volume of the pulse, make the large or full pulse. This is seen in cardiac hypertrophy, plethora, early stage of chronic nephritis.

Decreased volume of the pulse makes the small empty pulse as seen in general weakness from wasting disease; cardiac weakness; cardiac valvular

lesions (aortic stenosis); mitral stenosis, or marked insufficiency without compensation.

Alternate increase and decrease of the volume of the pulse is observed in aortic insufficiency, giving the collapsing or *water-hammer pulse* of Corrigan.

Degree of force of each pulse-wave depends chiefly upon the energy of the cardiac systole, and also upon the amount of vascular tone.

Increased force of each pulse-wave making the strong pulse occurs with increased cardiac energy and vascular tone.

Decreased force of each pulse-wave, making the weak pulse, is the result of cardiac debility.

Duration of each pulse-wave depends upon the dilatation of the artery by the blood current, and its contraction during the passage of the blood into the capillaries.

Prolonged duration of each pulse-wave, giving the slow or sluggish pulse, occurs in all diseases producing contraction of the smaller arteries, as nephritis, artero-sclerosis, angina pectoris.

Shortened duration of each pulse wave giving the active quick pulse, is present in all diseases and conditions giving relaxed arteries as in febrile affections and in aortic regurgitation.

RHYTHM OF THE PULSE.

Varieties of rhythm.

Irregular pulse, as respects time and volume.

Irregular in time: varying length of successive intervals between beats, either rhythmical or arrhythmical.

Irregular in volume: varying strength or fullness of successive beats.

Pulsus bigeminus: beats occurring in pairs, with intervals between each pair, the second beat of each pair being weaker than the first.

Dicrotic pulse: characterized by a double beat, i. e., a large beat followed by a small, after beat, occurring with each cardiac systole; it is a weak pulse of low tension. It is obtained in fever patients and in some conditions of great exhaustion.

Pulsus trigeminus: groups of three beats, the groups being separated by intervals.

Intermittent pulse; here a beat is dropped out or is abortive, cardiac systole not being strong enough to send through the arteries a wave of sufficient size to be felt at the wrist.

Irregularity or incoördination of the two radial pulses is sometimes observed in aortic aneurism or aneurism of the pulmonary artery.

Causes of broken rhythm of the pulse.

General causes of broken rhythm.

Nervous }
 } action of drugs or disease.
Circulatory

Local causes of broken rhythm.

Reflex, dyspepsia, etc.

Circulatory, diminished blood pressure in the arteries, as in anæmia.

Cardiac weakness from

Degeneration, atrophy, etc.

Mechanical interference with its action;

Acting within the cardiac apparatus, due to valvular disease, pericardiac effusion.

Acting from outside the heart: pleuritic effusion, distended stomach, hepatic enlargement, tumors, deformities of the chest.

FREQUENCY OF THE PULSE, rate or number of beats.

The average pulse rate in healthy adult males is seventy-one beats; in females, eighty per minute; the pulse is relatively more rapid in females, in infancy, in small persons, in the upright position, in high altitudes, in late periods of the day, after meals, during emotional excitement, intellectual exercise or muscular exertion.

The slow pulse, *bradycardia*, is characterized by a rate of sixty beats or less per

minute; it has been observed as low as fifteen beats. It is

Normal in certain healthy individuals habitually, and in old age.

Abnormal in icterus, diphtheria, cerebral hemorrhage, convalescence from acute disease.

The **rapid pulse**, *tachycardia*, is characterized by a rate of eighty-five beats or more per minute; it has been observed as high as two hundred and fifty beats in adults.

Normal the pulse is rapid in certain healthy adults habitually; and in children as follows:

Infants, - 130 to 150.

One year old, - 120 to 130.

Two years old, - 105.

Three years old, - 100.

Five years old, - 90 to 94. Variations from emotions and physical exercise, etc., *vide* the average pulse.

Abnormally the pulse is rapid in febrile states; in cardiac weakness; in certain nervous disorders, hysteria, neurasthenia, exophthalmic goitre, etc.

FREMITUS is a trembling felt by the hand on examination. It has been termed *frémissement cataire* from its likeness to the vibration felt upon the back of a purring cat.

CIRCULATORY FREMITUS or thrill is due to vibrations originating within the heart or great vessels, and it includes:

ANEURYSMAL or **VASCULAR FREMITUS**, sometimes felt over large superficial aneurisms, and occasionally over the carotids in valvular disease of the heart, and over the jugular veins in tricuspid insufficiency; also,

ENDOCARDIAL or **CARDIAC FREMITUS**, not infrequently obtained, upon palpation of the precordia, in certain valvular lesions.

CAUSES OF CARDIAC FREMITUS; like certain cardiac murmurs it may be due to the whirling of the blood stream against a roughened surface or past a constriction.

FREQUENCY OF CARDIAC FREMITUS.

IT GENERALLY OCCURS with loud cardiac murmurs, but comparatively few murmurs are accompanied by a thrill.

IT IS MOST COMMON with mitral obstruction (presystolic), and aortic obstruction (systolic).

IT IS MORE RARE with aortic regurgitation (diastolic), mitral regurgitation (systolic).

IT IS VERY RARE with lesions of the right heart.

LOCATION OF CARDIAC FREMITUS.

IT IS GENERALLY FELT BEST where the murmur is heard loudest, e. g.,

just above the apex in mitral obstruction; in the aortic area in aortic obstruction and atheroma; over the jugulars in case of constriction of these vessels from pressure, as in enlargement of the thyroid gland.

INTENSITY OF CARDIAC FREMITUS.

IT IS APT TO BE, LIKE MURMURS, increased by exertion.

IT MAY DISAPPEAR in cardiac weakness, and return with reviving strength or upon excitement.

FRICTION FREMITUS is a rubbing or grating sensation felt by the hand in palpation over a part where two roughened, inflamed, serous surfaces are moving upon each other; as in the first stage of pleurisy, occasionally in pericarditis, and rarely in peritonitis.

RHONCHAL, BRONCHIAL or râle **FREMITUS** is caused by the passage of air through fluid in the trachea and larger bronchi, during respiration; the vibrations produced are sometimes so marked as to be felt by the hand, upon palpation.

CAVERNOUS FREMITUS; this may sometimes be felt over superficial cavities in the lung, owing to the vibration of fluid within them.

VOCAL FREMITUS, variously termed voice fremitus, vocal vibration or pectoral fremitus, is a trembling felt by the hand when placed upon the chest of a person who is speaking aloud.

INTENSITY OF VOCAL FREMITUS.

INCREASED or marked vocal fremitus.

NORMAL, it is found with

Low pitched voices,

Strong voices; near to the

Larynx; over the

Trachea and

Great bronchi; it is more marked over the

Right apex than over the left, owing to the size and direction of the right bronchus; it is more marked over

Thin chests from the absence of muscle or fat.

ABNORMAL, increased vocal fremitus is found:

Over consolidation of the parenchyma of the lung, when the bronchial tubes, of large and medium size, are patulous, as obtains in phthisis and pneumonia;

Over compressed or collapsed lung above the level of the effusion;

Over a cavity near the surface, with dense walls and a free opening into a large bronchus.

DIMINISHED OR SUPPRESSED vocal fremitus.

NORMAL, vocal fremitus is weak or absent with

High pitched voices,

Weak voices; over the lower half of the chest of Women; over the whole chest in Children; at a

Distance from the larynx and large bronchi; over

Thick Chest walls from excess of fat, muscle or mammary gland.

ABNORMAL, diminished vocal fremitus is due to Interposition of

Fluid, as in hydrothorax, pleurisy with effusion, etc.;

Air, as in emphysema, pneumothorax;

Solids, as in adherent and markedly thickened pleura, large solid tumor.

Obstruction of the large bronchial tubes, from the presence of a foreign body, or compression by a tumor, or stricture.

MENSURATION.

Measurement determines size, and the symmetry, or asymmetry of the chest; in the latter case, it is instituted from the middle point behind to the middle point in front.

PERCUSSION.

Percussion is the art of eliciting sounds by striking the body.

METHODS of percussion.

IMMEDIATE, striking directly upon the part; this method is of comparatively little use.

MEDIATE, striking upon an intermediate object held against the part.

INSTRUMENTS, in mediate percussion (varieties).

HAMMER, plexor or plessor.

PLEXIMETER, or plessimeter, the medium upon which the hammer strikes.

The natural and most useful instruments are the middle or index fingers of one hand, serving as plexor, and one or more fingers of the other hand, as pleximeter. *Artificially*, they may be made of hard rubber, wood, etc.

RULES FOR PERCUSSION.

THE PATIENT.

THE SURFACE should be bare of clothing.

THE LIMBS symmetrical, the same position being maintained in the examination of the two sides.

TO EXAMINE THE FRONT of the chest the arms should be at the sides.

TO EXAMINE THE BACK the arms should be folded in front.

TO EXAMINE THE SIDES the arms should be folded above the head.

POSITION OF THE BODY.

EASE OF POSITION, to avoid discomfort and to insure like muscular tension on the two sides.

POSTURE; the erect, recumbent or sitting posture, or all these may be required, as in determining change of position of solid organs, or of the level of fluids; recumbency must be maintained if there is danger of heart failure.

THE EXAMINER should maintain a position symmetrical with regard to the patient the ear being at the same relative distance from the points percussed.

THE INSTRUMENTS. (their use).

THE PLEXIMETER should be applied

WITH FIRMFNESS, to avoid a cushion of air beneath it; the firmness of pressure should be uniform at all points of percussion.

PARALLEL TO THE RIBS, upon or between them.

OVER SYMMETRICAL POSITIONS on the two sides of the chest for comparison.

THE PLEXOR and its use:

THE STROKE should be made *WITH THE ENDS OF THE FINGERS* rather than with their pulps.

THE STROKE SHOULD BE MADE PERPENDICULARLY to the surface.

THE STROKE should be *REBOUNDING*, in using the hand the motion should be from the wrist.

THE STROKES should be *MODERATELY RAPID* in succession.

THE STROKE should be made with *MODERATE FORCE*, never causing pain, but more forcible for sounding deep seated organs than for superficial.

THE TWO SIDES SHOULD BE PERCUSSED IN LIKE STAGES OF RESPIRATION, preferably at the end of expiration.

PERCUSSION SOUNDS.

THE ELEMENTS OF SOUND in percussion.

QUALITY, the characteristic property, or chief attribute which distinguishes one sound from another, e. g., full, empty, shallow, clear, soft, hard, toneless, dead, "high sound."

INTENSITY, the quantity or loudness, largely governing the distance at which a sound can be heard; varying with

THE FORCE OF THE BLOW.

THE VOLUME OF AIR under the part.

THE THINNESS AND ELASTICITY OF THE CHEST WALL.

DURATION, the length of time a sound can be heard.

PITCH, the degree of elevation in the musical scale.

ITS RELATION to duration and intensity, the lower the pitch the longer the

duration, and the greater the intensity, and per contra.

THE FACTORS IN ITS PRODUCTION.

THE LARGER THE CAVITIES (containing gas) in the part, the lower the pitch, and per contra.

THE GREATER THE TENSION OF THE INCLOSING WALL, the higher the pitch and per contra.

PROXIMITY OF SOLID BODIES elevate the pitch.

THE LARGER THE OPENING in a cavity, the higher the pitch.

THE VARIETIES OF PERCUSSION SOUNDS.

NORMAL PULMONARY OR VESICULAR RESONANCE or lung sound.

LOCATION, over those parts of the healthy lung which do not overlap the heart, liver, or spleen, and which are not covered by the scapulae (*vide* the landmarks). The resonance obtained over the lung which overlaps these organs while normal vesicular, is relatively less resonant, and hence properly termed dulness. Resonance is less intense and higher in pitch over the right apex than over the left.

CAUSE of the normal vesicular resonance; it is probably due to the combined vibration of the walls of the chest, alveoli and bronchi, and the air contained within them, the resonance of the deeper parts being modified by the thickness of the fleshy parts, and by the elasticity of the bony elements.

CHARACTER of normal vesicular resonance.

QUALITY, soft, clear, full, resonant, vesicular.

PITCH, low.

INTENSITY, great.

DURATION, long.

VARIATIONS IN CHARACTER.

IN THE SAME INDIVIDUAL,

IN A GIVEN LOCATION vesicular resonance varies with the degree of respiratory expansion.

IN DIFFERENT LOCATIONS, it varies according to the size or amount of lung under the part, and the thickness of the chest wall.

IN DIFFERENT INDIVIDUALS, it varies according to the same factors.

EXAGGERATED PULMONARY RESONANCE.

LOCATION.

NORMAL, over both lungs in children.

ABNORMAL.

OVER BOTH LUNGS: in marked anæmia; in emphysema (the resonance present in this disease has also been termed by Flint, vesiculo-tympanitic,

OVER ONE LUNG when the other is partially or wholly crippled, by consolidation, compression, etc.

OVER SOUND PARTS of a crippled lung.

CAUSE, the lung is over-distended with air, either functionally, or from organic trouble, as in emphysema.

CHARACTER; this is like that of vesicular resonance, except for increase of intensity and duration, and slightly lower pitch.

VARIATIONS IN CHARACTER accord with the amount of air in the part, within reasonable limits.

BONE RESONANCE.

LOCATION, over the sternum and clavicle, and to a slight extent over the ribs.
CHARACTER.

QUALITY, non-tympanitic, resonant, ringing.

PITCH, higher than that of vesicular resonance.

INTENSITY, less than that of vesicular resonance.

DURATION, shorter than that of vesicular resonance.

DULNESS, diminished resonance.

LOCATION.

NORMAL, where the lung overlaps the heart, liver and spleen, and underlies the scapulæ.

ABNORMAL.

THICKENING OF THE CHEST WALL from œdema, tumor or inflammatory swelling.

INTERPOSITION, between the lung and chest wall, of solids or fluids; a moderately thick layer of inflammatory lymph on the pleural surface; a moderate amount of pleuritic effusion, inflammatory or non-inflammatory; extra-pulmonary tumors of small size.

CONSOLIDATION OF THE LUNG, moderate in amount: pneumonia, tuberculosis, syphilis, new growths, œdema, pulmonary hemorrhage, collapse of lung.
CAUSE, less air or relatively more solids beneath the part than in normal lung.

CHARACTER.

QUALITY, harder, emptier, less clear, less vesicular than normal pulmonary, vesicular resonance.

PITCH, higher.

INTENSITY, less.

DURATION, shorter.

VARIATIONS, in character in different individuals and in different localities, accord with the relative amount of air or solids, approaching the character of pure pulmonary resonance on the one hand, and flatness upon the other.

FLATNESS.

LOCATION.

NORMAL, over those organs or parts containing no air, hence over that portion of the heart, liver, spleen and kidneys uncovered by lung.

ABNORMAL, over the chest when there is an exaggeration of any of those morbid conditions, which in a slight degree produce dullness: pleurisy with effusion, emphysema, hydro-thorax, etc.

CAUSE, entire absence of air or gas in and for some distance beneath the organ under the part percussed.

CHARACTER.

QUALITY, hard, empty, muffled, non-resonant, the "thigh sound."

PITCH, very high, highest of all percussion notes.

DURATION, very short.

NO VARIATIONS OF ITS CHARACTER, as such, occur: it may be modified by tympanitic resonance, where hollow gas-containing organs like the stomach or colon underlie a solid organ like the liver, it is then termed tympano-flatness, really a modification of tympany.

TYMPANITIC RESONANCE or tympany.

LOCATION.

NORMAL, where the stomach or colon, distended with gas, underlies the infra-mammary, infra-axillary and infra-scapular regions; and sometimes over the

lower part of the mammary and inferior sternal regions; also over the trachea.
ABNORMAL.

OVER a part of the chest when **GAS** is present **IN THE PLEURAL SAC**,
pneumo-thorax.
OVER A PULMONARY AIR-CONTAINING CAVITY of large size,
phthisis, abscess.

COMPLETE SOLIDIFICATION OF A PART of the upper lobe of the lung,
tympany being obtained from the trachea beneath ("tracheal tone" of Williams),
second stage of pneumonia, phthisis.
BRONCHIECTASIS with surrounding solidification, interstitial pneumonia.
CONDUCTION OF STOMACH RESONANCE high up on the left side, when
the lower lobe of the left lung is solidified.

CAUSE, percussion over a hollow gas-containing organ or cavity, the walls of
which are more or less thin and tense.

CHARACTER.

QUALITY, non-vesicular, resonant, ringing, but harder than vesicular resonance.

PITCH, higher than vesicular resonance, variable.

INTENSITY and duration variable.

VARIETIES OF TYMPANY.

CLOSED TYMPANY is the sound obtained by percussion over a cavity filled with

gas, and not communicating freely by an opening with the external air, e. g., the stomach, and colon.

OPEN TYMPANY includes amphoric and cracked-metal resonance.

AMPHORIC RESONANCE is obtained over a cavity with a large opening, as in percussion of the cheeks with the mouth open.

Location.

Normal, sometimes over the upper part of the chest in children.

Abnormal, abscess or tubercular cavity communicating with a large bronchus.

Cause, percussion over a moderate sized gas-containing cavity with rigid, non-collapsing walls and free communication by a large opening; the examiner's ear or the mouth of the stethoscope should be near the patient's open mouth. **Character**, its *quality* is tympanitic but peculiarly ringing and hollow like the sound produced by blowing across the mouth of a bottle; its *pitch* is higher than vesicular resonance but varies with the size of the cavity and of the opening, and the condition of the adjacent lung. Its *intensity* and *duration* are variable.

CRACKED-METAL RESONANCE is a form of open tympany, and may be imitated by striking upon the knee with the hands loosely clasped palm to palm.

Location and Cause.

Normal.

If the chest be covered with much hair, under percussion.

If the pleximeter be loosely applied.

Sometimes it is obtained over the upper part of the chest in children especially when crying.

Sometimes in adults when singing a prolonged note.

Abnormal.

Over some air-containing pulmonary cavities communicating with a bronchus by a small opening; percussion should be firm, and during expiration, the patient's mouth being open.

Occasionally in pleurisy over the lung above the effusion; sometimes in the engorgement stage of pneumonia.

When an opening exists through the chest wall into the pleural sac.

AUSCULTATION.

METHODS of auscultation.

IMMEDIATE or direct.

MEDIATE or indirect.

INSTRUMENTS of mediate auscultation, the stethoscope.
VARIETIES.

UNIAURAL, hollow and solid.

BINAURAL, Knight's, Camman's, Dennison's, Allison's differential, etc.
OBJECTIONS to the stethoscope.

IT HAS A SPECIAL RING or roaring sound like a shell.
OFTEN POORLY MADE.

FRIGHTENS CHILDREN.

NOT ALWAYS AT HAND.

ADVANTAGES of the stethoscope.

SHUTS OUT OUTSIDE SOUNDS.

CONCENTRATES and circumscribes sounds.

INTENSIFIES sounds.

CERTAIN PARTS OF THE CHEST ARE INACCESSIBLE to the unaided ear.
IT IS SOMETIMES INDELICATE to apply the ear directly to the chest.

IT IS SOMETIMES UNPLEASANT and may be **DANGEROUS** to apply the ear to the chest.

RULES for auscultation.

THE PATIENT should have regard to

SYMMETRY, immobility and ease of position.

THE CHEST SHOULD BE BARE for mediate auscultation and should have a single layer of thin soft covering for immediate auscultation.

THE EXAMINER should have **THE HEAD** on a plane higher than the body to prevent congestion of the auditory apparatus;

THE ATTENTION concentrated upon one sound or set of sounds at a time.

THE INSTRUMENTS.

THE EAR-PIECE should fit the external meatus accurately and point in the same direction, as the canal, downwards and forwards.

THE LARGER CHEST-PIECE should not exceed one and one-fourth inch in diameter at the distal end. It is designed for the lung sounds.

THE SMALLER CHEST-PIECE is especially designed for the sounds of the heart and vessels.

THE ACT of auscultation.

THE ROOM should be quiet.

THE EAR OF THE STETHOSCOPE should be firmly applied to the chest.

THERE SHOULD BE NO FRICTION between parts of the instrument; between the chest and the instrument; between the hand and the instrument; between the hand and the chest; between the hand and the clothing; between the chest and the clothing.

CORRESPONDING PARTS OF THE CHEST should be compared; and in like stages of respiration.

THE ENTIRE CHEST should be examined.

SOUNDS HEARD upon auscultation.

THE ELEMENTS of sound.

QUALITY,

PITCH,

DURATION,

INTENSITY,

vide percussion sounds.

RHYTHM is the relation of sounds to each other; as that of inspiration to expiration; or the relation of the first and second sounds of the heart.

VARIETIES OF SOUNDS upon auscultation.
PULMONARY sounds.

RESPIRATORY sounds vary in kind, intensity and rhythm.

KINDS OR VARIETIES OF RESPIRATORY SOUND.

NORMAL VESICULAR BREATHING; (persons should breathe more forcibly than usual but with the same rhythm).

Locality, it is heard over the parenchyma of the lung away from the main bronchi; best in the infra-scapular regions.

Cause of the vesicular sound (opinion varies).

It may be produced at the glottis, and modified by conduction through the spongy tissue of the lung.

It may be due to the entrance of air into the alveoli during dilatation.

It may be due to the vibration of the lung substance from increased tension in inspiration and the reverse in expiration.

Character.

Inspiratory sound.

Quality, breezy, rustling, soft, vesicular.

Pitch, low compared with that of laryngeal breathing.

Intensity, variable.

Duration, coincident with the inspiratory act

Expiratory sound.

Quality, like the inspiratory but less vesicular, tubular but simply blowing.

Pitch, lower than that of the inspiratory sound.

Intensity, variable; the sound may not be appreciable but is generally so.

Duration, much shorter than the expiratory act.

Rhythm: the ratio of the inspiratory to the expiratory sound is as four or five to one, there being a slight interval between them.

Variation in character largely depends upon the nearness of the point of auscultation to the large bronchi.

BRONCHIAL BREATHING.

Locality, and cause.

Normal, heard over the trachea.

Abnormal, (as a sign of disease) heard over consolidated lung, the main bronchi leading to which are patulous, consolidated lung being a better medium of conduction of the sound from the larynx. It is heard in pneumonia and phthisis.

Character, it is substantially like that of tracheal breathing though slightly less intense (*vide* tracheal breathing).

LARYNGEAL AND TRACHEAL BREATHING differ from each other but little.

Locality, heard over the larynx and trachea.
Character.

Inspiratory sound.

Quality, tubular, blowing.

Pitch, higher than that of the inspiratory sound of normal vesicular breathing.

Intensity, great but variable.

Duration, a little shorter than the inspiratory act.

Expiratory sound.

Quality, very similar to that of inspiration.

Pitch, higher than that of inspiration.

Intensity, greater than that of vesicular breathing.

Duration, longer than that of the expiratory sound of vesicular breathing.

Rhythm; the expiratory sound is as long as the inspiratory, and a short interval exists between them.

CAVERNOUS breathing.

Locality, (it is an abnormal sound) heard over some pulmonary cavities.

Cause, empty pulmonary cavity with easily collapsing and expanding walls in expiration and inspiration.

Character.

Inspiratory sound.

Quality, soft, blowing, or puffing, but neither vesicular nor tubular.

Pitch, low.

Intensity, variable, but usually slight.

Duration, variable.

Expiratory sound.

Quality, like that of the inspiratory sound.

Pitch, lower than that of the inspiratory sound.

Intensity, variable, but usually slight.

Rhythm, the expiratory sound is about the same length as the inspiratory.
BRONCHIO-CAVERNOUS breathing.

Locality and cause, cavity surrounded by solidified lung, as is found sometimes in the late stage of tuberculosis, abscess or gangrene.

Character, both cavernous and bronchial elements are heard together.

Varieties, metamorphosing breathing; here the inspiratory sound is bronchial at first but suddenly becomes cavernous.

VESICULO-CAVERNOUS.

Locality and cause; cavity covered by more or less healthy lung.

Character, as indicated by its name.

AMPHORIC breathing.

Locality, over a large cavity with relatively rigid walls and with a large opening, as may be obtained in tuberculosis and occasionally in pneumo-thorax.

Cause, the peculiar vibration of air in its passage in and out of, or across the mouth of a flask-like cavity.

Character.

Inspiratory sound most distinct.

Quality, musical, hollow, metallic, harder than that of cavernous breathing.

Pitch of expiratory sound lower than that of bronchial breathing.

Intensity, usually greater than that of cavernous breathing.

Rhythm; amphoric breathing is usually heard best in inspiration.

INTENSITY OF RESPIRATORY SOUNDS.

EXAGGERATED, SUPPLEMENTARY, OR PUERILE BREATHING.

Locality.

Normal in childhood, the chest walls being thin and elastic.

Abnormal, over one lung when the other is crippled by consolidation, obstruction, etc.; over healthy parts of a crippled lung.

Cause, the lung is performing more than its usual function.

Character, like that of normal vesicular breathing, except of greater intensity; both inspiratory and expiratory sounds are louder and longer than usual.

FEEBLE RESPIRATION.

Locality.

Normal.

Over thick chest walls, as in muscular or fat persons; over the female mammæ and over the scapulae.

At a distance from the large bronchi, over the lower part of the chest, especially in women.

In superficial breathing.

The vesicular murmur is normally less intense on the right than on the left side.

Abnormal from

Imperfect transmission, due to œdema or swelling of the chest walls; air, fluid or inflammatory lymph in the pleural sac.

Loss of elasticity of the lung, emphysema.

Partial blocking of the air cells with blood or serum, as in pulmonary œdema.

Consolidation of lung with filling up of the bronchi.

Obstruction of the larynx, trachea or bronchi from a collection of pus, mucus, blood or fibrin; foreign body; thickening of the mucous membrane; pressure of tumors.

Constriction of the tubes from muscular contraction, asthma, bronchiolitis.

Deficient action of the respiratory muscles.

Mechanical obstruction, as in tympany, ascites, abdominal tumors.

Pain, as in pleurisy, peritonitis, pleurodynia, neuralgia.

Paralysis of the diaphragm.

SUPPRESSED RESPIRATORY SOUND; entire absence of respiratory sounds.

Locality and cause, an exaggeration of the conditions which produce feeble respiration: pneumo-thorax, hydro-thorax, occlusion of the larger air passages, etc.

RHYTHM OF RESPIRATORY SOUNDS.

INTERRUPTED, JERKING, WAVY, OR COG-WHEEL RESPIRATION.

Locality.

Normal, in nervous persons, agitated by examination; here it is apt to be heard more or less over the whole chest, but it may be localized; sometimes it is heard in healthy persons from no apparent cause.

Abnormal, it may accompany:

Pain, as in pleurisy, pleurodynia, intercostal neuralgia; it is generally heard over the whole chest.

Phthisis, here it may be an early sign, localized over the affected apex.

Cause of cog-wheel breathing: in some cases (pain and nervousness) it may be due to the irregular and undecided manner of respiration, in others (phthisis) it is probably caused by the break or delays in the passage of air passed through the affected bronchioles.

Character: either the inspiratory or expiratory sound, or both, may be broken

into several parts, or may be characterized by successive variations in intensity; usually it is most marked in inspiration.

INTERVAL BETWEEN INSPIRATION AND EXPIRATION may be more or less prolonged.

In emphysema, owing to a deferred expiratory sound.

In consolidation of the lung owing to shortening of the inspiratory sound.
SHORTENED INSPIRATORY SOUND.

Locality (where and when heard) and cause.

In emphysema, it is due to the beginning of the respiratory act before the beginning of the sound.

In consolidation (bronchial breathing) it is due to the ending of the inspiratory sound before the ending of the inspiratory act.
Character.

When due to emphysema.

Quality, vesicular.

Pitch, comparatively low.

When due to consolidation.

Quality, tubular.

Pitch, high.

PROLONGED EXPIRATORY SOUND.

Locality.

Normal, over the right apex; sometimes prolonged expiratory sound over the left apex in slightly less degree; over the larynx, trachea and bronchi, (*vide* the landmarks).

Abnormal, over consolidated lung; over a cavity; over emphysematous lung; in asthma; in certain valve-like obstacles in the air passages.

Cause: difficult and prolonged exit of air from the lungs, e. g., in emphysema, owing to loss of elasticity of the lung; in asthma, owing to spasm of the bronchial muscles.

Character.

When due to solidification of the lung.

Quality, tubular.

Pitch, high.

When due to a cavity.

Quality, blowing.

Pitch, low.

When due to emphysema.

Quality, vesicular.

Pitch, low.

VOCAL SOUNDS.

ELEMENTS OF SOUND; these are like those considered in respiration and percussion, though not all of them are so significant in the consideration of vocal sound.

VARIETIES OF VOCAL SOUND.

NORMAL (VESICULAR) VOCAL RESONANCE.

Locality, it is heard

Over the lung at a distance from the trachea and bronchi, while the person is speaking.

In adult males it is generally heard over the entire lung.

In women and children it is heard over the upper part of the chest, and but indistinctly over the lower part.

Cause: it is due to the transmission of the voice through the parenchyma of the lung, and the chest wall.
Character.

Quality, diffused, muffled, buzzing, seeming to come from the deep parts of the lung (articulation not transmitted).

Pitch, varies with the pitch of the voice.

Intensity, greater over the right apex than over the left, especially in the infra-clavicular region.

Variations from the normal are chiefly in intensity.

Diminished vocal resonance.

Locality and cause; it is the result largely of those conditions which cause feeble respiratory sounds.

Exaggerated vocal resonance.

Locality; it is heard over moderately consolidated lung; pneumonia, phthisis, etc.

Cause, consolidated lung is a better medium for transmitting sound from the larynx than is ordinary lung tissue.

Character; it differs from normal vocal resonance simply in being more intense, seeming to come from a point not far distant from the surface. It is usually associated with broncho-vesicular respiration.

BRONCOPHONY OR BRONCHIAL VOICE.

Locality.

Normal, heard over the main bronchi.

Abnormal, heard

Over consolidated lung as in the second stage of pneumonia, phthisis; above the level of the fluid in pleuritic effusion.

Over a vomica with firm walls (sometimes).

Cause, consolidated lung a better medium of transmission.

Character. It is more concentrated than normal vocal resonance and exaggerated vocal resonance, seeming to come from a point very near the ear, immediately under the stethoscope (no distinct articulation). It is usually associated with bronchial breathing though not necessarily. Its *pitch* varies, and its *intensity* also, though usually increased above that of normal resonance.

Varieties of bronchophony.
Egophony (goat voice).

Locality, over consolidated lung, covered by a thin layer of fluid in the pleural cavity, as in pleuro-pneumonia with slight pleuritic effusion.

Character, it is like that of bronchophony, except that it is of less intensity and has a tremulous sound, seeming to come from a considerable depth.

Pectoriloquy (speaking through the chest).

Locality and cause. It is heard,

Over consolidated lung, phthisis, pneumonia.

Quality, clanging, metallic.

Pitch, high.

Over a cavity with smooth walls and a large opening, abscess, bronchiectasis, etc.

Quality, soft.

Pitch, low.

Character, it is like that of bronchophony with the addition of distinct articulation in the transmitted voice.

AMPHORIC VOICE.

Locality, over pneumothorax or pulmonary cavity with a free opening.

Character.

Quality, hollow, musical.

Pitch and *intensity*, variable. It is frequently associated with amphoric respiration and resonance.

WHISPERING SOUNDS.

NORMAL WHISPERING RESONANCE.

EXAGGERATED WHISPERING RESONANCE.

WHISPERING BRONCHOPHONY.

CAVERNOUS WHISPER.

WHISPERING PECTORILOQUY.

AMPHORIC WHISPER.

These whispering sounds correspond largely, in locality, cause and character, to the vocal sounds, the sound of phonation being substituted by that of aspiration.

TUSSIVE OR COUGH SOUNDS.

RELATION to other auscultatory sounds. Cough may remove temporary obstacles

from the air passages thereby changing or destroying signs; cough necessitates subsequent deep inspiration with consequent distension of the air vesicles.
VARIETIES of cough.

LARYNGEAL COUGH, hacking, often spasmodic, and due to laryngitis, local irritation, or to reflex nervous trouble.

BRONCHIAL COUGH, dry or tight, quick, harsh and brassy. Loose, more or less rattling, owing to secretion within the tubes. It is frequently accompanied by pain along the attachments of the diaphragm, and more or less soreness under the sternum. Bronchitis.

CAVERNOUS COUGH, has a hollow quality and is usually intense and accompanied by gurgling sounds.

AMPHORIC COUGH is ringing, with the peculiar resonance heard in blowing across the neck of a bottle. Much the same laws govern the sounds produced by coughing as apply to vocal sounds in auscultation of the chest, in disease and in health.

ADVENTITIOUS SOUNDS.

RALES.

MOIST RALES.

Large, coarse or mucous rales.

Locality, where produced: large and middle sized tubes; "death rattle" heard in the trachea.

Cause, air bubbling through fluid, whether mucus, blood or pus.

Character.

Quality, bubbling, moist.

Pitch, usually low but variable.

Intensity, variable.

Duration, they may be removed by coughing or deep inspiration.

Rhythm, they may accompany inspiration, expiration, or both.

Condition, acute and chronic bronchitis, profuse pulmonary hemorrhage, etc.

Small, fine, mucous or subcrepitant rales.

Locality, small tubes.

Cause, air bubbling through fluid.

Character.

Quality, moist, fine, bubbling or crackling (mixed in size).

Pitch, varying with size of tube and condition of surrounding lung.

Intensity, variable.

Duration, they may be removed by deep inspiration or cough.

Rhythm, they may accompany either or both acts of respiration.

Condition, capillary bronchitis, third stage of tuberculosis, lobular pneumonia, pulmonary congestion and œdema, severe hemorrhage, chronic bronchitis, etc.

DRY RALES.

Sonorous rales.

Locality, large tubes.

Cause, narrowing of the lumen of the bronchi from viscid mucus adhering to their wall; swelling of the mucous membrane; spasm of the bronchial annular muscles; fibroid contractions; pressure upon the bronchi by an aneurism or other tumors or swellings.

Character.

Quality, snoring.

Pitch, low.

Intensity, variable, usually very loud.

Duration, they are usually not removable by cough or deep inspiration, except when due to viscid mucus.

Rhythm, they may accompany either or both acts of respiration.

Conditions, asthma, bronchitis, and other more rare conditions causing narrowing of the tubes.

Sibilant râles.

Locality, small tubes.

Cause, same as that of sonorous râles.

Character.

Quality, whistling, hissing, creaking.

Pitch, high.

Intensity, less than sonorous, but variable.

Duration, they may be removed by cough or deep inspiration.

Rhythm, they may accompany either or both acts of respiration.

Crepitant râles.

Locality, they are produced in the ultimate air vesicles.

Cause, (probably) sudden separation of the walls of collapsed air vesicles, adhering more or less, from the presence of fibrinous exudate upon their surfaces.

Character.

Quality, like the crackling of salt thrown upon the fire, dry, very fine, numerous, and uniform in size, as compared with the subcrepitant râles which are coarser, bubbling, moist, fewer in number and of different sizes.

Pitch, high.

Intensity, variable.

Duration, they are not disturbed by cough.

Rhythm, they are never heard in expiration, always in inspiration, usually at its end.

Condition, typically in the first stage of lobar pneumonia, sometimes in incipient tuberculosis at the apex of a lung; rarely in pulmonary hemorrhage and oedema.

Indeterminate rales.

Crumpling sounds.

Locality.

Normal, sometimes heard at the end of a forced inspiration, usually bilateral.

Abnormal, they are sometimes heard in emphysema.

Cause, none known definitely.

Character, something like the sound of parchment when wrinkled.

Rhythm, at the end of forced inspiration.

Condition, emphysema.

FRICION SOUNDS.

LOCALITY, over inflamed pleura or pericardium, rarely over the peritoneum.

CAUSE, rubbing together of two serous surfaces, roughened by exudate, or dry from diminished secretion.

CHARACTER.

Quality, rasping, grating, grazing, creaking, simulated by rubbing the hand upon the chest during auscultation. They are few in number compared with rales and are irregular in occurrence.

Duration, they are not removable by cough or deep inspiration.

Rhythm, usually they are most prominent at the end of inspiration or beginning of expiration.

UNCLASSIFIED ADVENTITIOUS SOUNDS.

METALLIC TINKLING.

Locality.

Normal, they may be heard at times over the stomach.

Abnormal, over the pleural cavity containing air and fluid, especially when communicating with a bronchus above the level of the fluid.

Cause; the dropping of fluid in a cavity containing fluid and air.

Character.

Quality, silvery, tinkling or splashing.

Pitch, high.

Intensity, slight, but variable.

Rhythm, either in inspiration or expiration, or during cough, or occasionally independent of them.

Condition, pneumo-hydrothorax, pulmonary abscess, etc.

SPLASHING OR SUCCUSSION SOUND.

Locality, same as that of metallic tinkling.

Cause, splashing of fluid within an air-containing cavity, heard when the body is shaken, with the ear of the examiner against the surface, over the part.

Character, splashing.

Condition, pneumo-hydrothorax or pneumo-pyothorax.

BELL SOUND.

Locality, it is heard over a large air-containing cavity.

Cause, with the ear against the cavity, percussion is made upon the chest at the opposite side of the cavity, two coins being used, as plexor and pleximeter; the sound heard is due to the vibration of the air within the cavity.

Character, ringing, hollow, metallic.

Condition, pneumothorax.

SOUNDS PRODUCED BY THE CIRCULATORY MECHANISM.

CARDIAC SOUNDS.

NORMAL CARDIAC SOUNDS.

FIRST SOUND OF THE HEART.

Cause of the first sound, it is chiefly due to the closure of the auriculo-ventricular valves (mitral and tricuspid). To a slight extent this sound may also

be due to contraction of the walls of the ventricle in systole, the impulse of the apex against the chest wall, and the rush of blood through the ventricles.

Elements of the first sound.

Mitral element, heard best at the apex, and behind at the angle of the scapula. It is slightly louder than the tricuspid.

Tricuspid element, heard best at the lower end, a little to the left, of the sternum.

Character of the first sound.

Quality, "lubb," dull, soft, booming.

Pitch, lower than that of the second sound.

Intensity, greatest at the apex beat, varying with the strength of the heart, the condition of the valves and cavities, and the amount of tissue interposed between the heart and the listening ear.

Duration, long as compared with the second sound.

Rhythm, systolic, synchronous with the systole of the ventricles, the apex beat and carotid pulse; preceded immediately by the long pause, succeeded immediately by the short pause.

SECOND SOUND OF THE HEART.

Cause of the second sound, it is chiefly due to the closure of the semilunar valves, augmented by the vibration of the neighboring parts.

Elements of the second sound.

Aortic element, heard best in the second intercostal space, close to the right of the sternum.

Pulmonic element, heard best in the second intercostal space to the left of the sternum; not so loud as the aortic.

Character of the second sound.

Quality, "dupp," sharp.

Pitch, higher than that of the first sound.

Intensity, greatest at the base of the heart; variable like the first sound.

Duration, shorter than the first sound.

Rhythm, it is preceded immediately by the short pause, and succeeded immediately by the long pause. The relation of the first and second sounds with the intervening pauses may be represented thus: "lubb," — "dupp," ———.

MODIFICATIONS OF THE NORMAL HEART SOUNDS.

MODIFICATION OF THE FIRST SOUND, in

Intensity and duration.

Diminished intensity of the first sound, from

Weakness of the heart as a result of

General diseases, fevers, chronic wasting disorders, aneurism, etc.

Local diseases of the heart: fatty degeneration, or infiltration; atrophy, amyloid or fibroid degeneration; valvular disease; pericardiac effusion, etc.

Interposition of tissues, as in emphysema, pleuritic effusion, thick chest walls from fat or muscle.

Increased intensity and duration of the first sound; it may be

Longer in Duration, loud and booming as in hypertrophy of the left ventricle cirrhotic kidney; aortic stenosis and sometimes in aortic aneurism, or

Shorter in duration and sharper, as in case of thin chest walls, emotional excitement, physical exertion, onset of febrile disease.

Quality; the first sound may be impure, it may be sharper or duller than usual, more flapping or clacking.

Rhythm.

Reduplication.

Cause, non-synchronous action of the mitral and tricuspid valves, or non-synchronous action of the cusps of either valve.

Character, as related to the second sound; it may be represented thus: "lubb," "lubb," — "dupp," ———.

Frequency; it is not uncommon, but the second or diastolic sound is more frequently reduplicated than the first or systolic sound of the heart.

Significance; it is usually temporary but may be permanent; it is either physiological or pathological, and it is not peculiar to any particular lesion or condition.

Irregularity may involve time or intensity, or both.

Intermittency or dropping of the first sound.

MODIFICATION OF THE SECOND SOUND.

Intensity.

Diminished intensity of the second sound from

Diminished power of the right or left ventricle by which less blood is thrown into the aorta and pulmonary artery, producing less tension in them, and hence, less forcible recoil of their elastic walls, and less sudden and forcible closure of the semilunar valves.

General debilitating diseases, or

Local diseases impairing the strength of the heart or elasticity of the main arteries.

Stenosis of the mitral or tricuspid orifices or of the orifices of the aortic or pulmonary artery, reducing the tension in those vessels.

Lesion of the pulmonary or aortic valves impairing their closure.

Increased intensity or accentuation of the second sound.

Pulmonic second sound may be accentuated as a result of increased tension in the pulmonary artery from hypertrophy of the right ventricle; obstructed pulmonary circulation dependent upon pulmonary disease or valvular disorder of the left heart.

Aortic second sound may be accentuated as a result of increased tension in the aorta from hypertrophy of the left ventricle or obstruction in the aortic or general circulation: chronic renal disease, and some cases of aortic aneurism.

Quality, the second sound of the heart may be sharper or duller, or flopping or more booming in character.

Rhythm.

Reduplication of the second sound.

Cause, non-synchronous action of the aortic and pulmonic valves, or non-synchronous action of the cusps of either of these valves.

Character, as related to the first sound it may be represented thus: "lubb"

— "dupp" "dupp" ———.

Frequency and significance, (*vide* reduplication of the first sound).

Irregularity and

Intermittency of the second sound (*vide* first sound of the heart).

ABNORMAL CARDIAC SOUNDS OR MURMURS. EXOCARDIAL MURMURS.

Pericardiac friction sounds.

Locality, over the præcordia, usually best heard over the base of the heart, or over the junction of the left fourth costal cartilage with the sternum.

Cause, inflammation of the pericardium causing roughness and dryness of the membrane in the first, and at the end of the third stages.

Character.

Quality, rubbing, grating, rasping, creaking.

Intensity, variable, increased by forced expiration, by pressure of the stethoscope, and by forward inclination of the patient. They seem to be more superficial than endocardial murmurs.

Rhythm, independent of respiration and synchronous with systole or diastole, or both.

Pericardiac splashing and Churning sounds have been heard occasionally in cases of sero- or pyo-pneumo-pericardium.

Pleuro-pericardiac friction sounds similar in character to pleuritic friction sounds, but produced by the motion of the heart in systole, causing to-and-fro rubbing of the inflamed pleura. The pleura alone, or both the pleura and pericardium may be involved in the inflammation.

Pneumo-pericardiac or cardio-pulmonary sounds are soft blowing murmurs of rare occurrence, produced by the motion of the heart in forcing air from an adjacent pulmonary cavity, the air supposedly being expelled from the cavity in systole and returning during diastole.

ENDOCARDIAL MURMURS include organic and inorganic.

Organic endocardial murmurs include valvular and non-valvular.

Valvular, organic, endocardial murmurs include systolic and diastolic.

Systolic, organic, valvular murmurs include those of the right, and those of the left heart.

Of the left heart.

Mitral systolic, indirect or regurgitant murmurs.

CAUSE, insufficiency of the mitral valve from

Tearing or perforation of a cusp.

Inflammatory retraction of the cusps.

Rigidity of the cusps.

Vegetations, preventing closure.

Rupture or shortening of the chordæ tendineæ.

Dilatation of the left ventricle without compensatory lengthening of the chordæ.

Spasm of the columna carneæ.

USUAL ACCOMPANYING SYMPTOMS AND SIGNS.

Pulse, compressible and more or less irregular.

Indications of pulmonary, hepatic and renal congestion with œdema of the feet and ankles are common in cases of non-compensation.

Enlargement of the left heart with especial increase in transverse diameter.

Pulmonic second sound accentuated.

CHARACTER of the murmur of mitral regurgitation.

Quality, apt to be blowing and soft.

Rhythm, systolic, accompanying, or replacing the first sound of the heart at the apex.

Intensity, varies in different cases, but the loudness of a murmur is not proportionate to, and does not indicate the severity of the lesions causing it. This is equally true of all organic murmurs.

AREA OF MAXIMUM INTENSITY, is at the apex.

PROPAGATION of the murmur is frequently to the left of the apex; it is often heard at the lower angle of the scapula, but is not usually heard at the base of the heart, and is never transmitted into the carotids.

FREQUENCY of the murmur of mitral regurgitation, it is the most frequent of all valvular murmurs.

Aortic systolic, direct murmur.

CAUSE.

Obstruction at the orifice, guarded by the aortic semi-lunar valve due to thickening and rigidity of the cusps from fibroid, calcareous or atheromatous change; vegetations; adhesion of the cusps; induration and contraction of the fibrous ring or margin of the aortic opening; congenital malformation (rare).

Simple roughening of the cusps

Marked dilatation of the aorta immediately beyond the valvular opening, the latter remaining relatively normal in size.

USUAL ACCOMPANYING SYMPTOMS AND SIGNS in cases of marked obstruction.

Pulse, hard, wiry, small, but regular unless the heart be greatly embarrassed.

Thrill or fremitus often felt over the base of the heart, especially over the aortic area.

Evidence of cerebral anemia not uncommon;

Enlargement of the left heart;

Pulmonic second sound, feeble; and

Aortic second sound, feeble or inaudible.

CHARACTER of the aortic direct murmur.

Quality, usually harsh when due to stenosis or marked obstruction, otherwise it is apt to be soft.

Rhythm, systolic, with the first sound.

AREA OF MAXIMUM INTENSITY, the right second intercostal space close to the sternum, sometimes over the left interspace or over the upper part of the sternum at the same level.

PROPAGATION, into the arteries of the neck and down the sternum, and toward the apex but with diminished intensity. It is also frequently heard when loud, behind to the left of the fourth dorsal vertebra, but is not usually transmitted to the left of the apex.

FREQUENCY, common.

Of the right heart. (Systolic, organic, valvular murmurs).
Tricuspid systolic, indirect or regurgitant murmur.

CAUSES may be similar to those of mitral regurgitant murmur, but usually it results from relative incompetency of the valve in dilatation of the right ventricle, secondary to diseases of the lungs or serious lesions of the left heart.

USUAL ACCOMPANYING SYMPTOMS AND SIGNS. Commonly pulmonary diseases or lesions of the left heart precede those of the right; the associated manifestations are often those of

Congestion of the brain and abdominal organs; pulsation of the *Jugular* and sometimes of the *Hepatic veins*.

Enlargement of the right heart and usually of the left.

Pulmonic second sound, feeble.

CHARACTER of the murmur of tricuspid regurgitation.

Quality, blowing.

Rhythm, systolic, with or replacing the first sound of the heart.

AREA OF MAXIMUM INTENSITY, the tricuspid area at the end of, and along the left side of the sternum.

PROPAGATION very limited; if anywhere, it is transmitted to the right, sometimes even to the axilla. It is not heard at the apex or behind or over the carotids, and is seldom audible above the third rib.

FREQUENCY. It is comparatively rare, and very uncommon, from primary lesion of the tricuspid valve.

Pulmonic, Systolic, direct murmur.

CAUSE, usually obstruction from conditions somewhat similar to those affecting the aortic orifice; rarely are lesions of this valve the result of rheumatism. They are generally congenital.

USUAL ACCOMPANYING SYMPTOMS AND SIGNS.

Enlargement of the right heart;

Evidence of venous engorgement;

Bruit de diable occasionally heard over the jugulars.

Pulmonic second sound weak.

CHARACTER of the murmur of pulmonic obstruction.

Quality, variable, apt to be harsh.

Rhythm, systolic, accompanying the first sound.

AREA OF MAXIMUM INTENSITY, in the left second intercostal space close to the sternum.

PROPAGATION, occasionally toward the left shoulder, never towards the apex, nor along the aorta. It is not heard over the lower part of the sternum, nor behind.

FREQUENCY, very rare.

Diastolic, organic, valvular murmurs.

Of the left heart.

Mitral diastolic (presystolic), direct murmur.

CAUSE, obstruction of the mitral opening. This murmur may possibly occur, according to Flint, without mitral lesion, where there is aortic regurgitation with marked dilatation of the left ventricle.

USUAL ACCOMPANYING SYMPTOMS AND SIGNS.

Pulse, in marked cases, small.

Purring thrill or fremitus, most distinct at the apex, not uncommon.

Evidence of pulmonary engorgement.

Enlargement of the left auricle.

Pulmonic second sound accentuated.

CHARACTER OF THE MURMUR OF MITRAL STENOSIS.

Quality, harsh, churning, grinding, blubbery.

Duration, it is apt to be longer than other murmurs.

Rhythm, diastolic (presystolic), probably occurring in auricular systole.

AREA OF MAXIMUM INTENSITY, at the apex beat or half an inch above it. Usually louder when the patient is erect.

PROPAGATION limited: not transmitted to the left of the apex, nor into the arteries of the neck, nor is it heard behind.

FREQUENCY, common.

Aortic, diastolic, indirect, regurgitant murmur.

CAUSE, insufficiency of the valve from much the same causes as those producing mitral insufficiency, except those referring to the chordæ tendineæ.

USUAL ACCOMPANYING SYMPTOMS AND SIGNS.

Pulse, full, strong, and collapsing in diastole; forcible beating of the *Carotids*.

Capillary pulsation in marked cases.

Enlargement of the left heart, with perhaps secondary enlargement of the right.

CHARACTER of the murmur of aortic regurgitation.

Quality, soft, blowing, rushing and frequently musical.

Rhythm, diastolic, accompanying, or replacing, or immediately following the second sound of the heart.

AREA OF MAXIMUM INTENSITY, over the sternum at the level of the second costal cartilage, frequently in the left, second interspace and sometimes at the xiphoid cartilage.

PROPAGATION, down the sternum to the epigastrium; to the apex, where it is sometimes very loud and conveyed to the left; to the arch of the aorta and into the carotids; and behind, along the right

side of the spinal column. It may be heard occasionally even in the radial and femoral arteries. The area of diffusion is greater than that of any other murmur.

FREQUENCY, it stands third in order of frequency.

Of the right heart.

Tricuspid, diastolic (presystolic), direct murmur.

CAUSE, obstruction at the tricuspid opening (*vide* aortic and mitral stenosis.)

USUAL ACCOMPANYING SYMPTOMS AND SIGNS, those of systemic venous engorgement. Sometimes there is a fremitus to be felt over the right heart.

CHARACTER OF THE MURMUR of tricuspid obstruction.

Quality, harsh.

Rhythm, presystolic.

AREA OF MAXIMUM INTENSITY, over the lower two-thirds of the sternum.

PROPAGATION, may be toward the base faintly, but never toward the apex; it is not heard above the base.

FREQUENCY, extremely rare.

Pulmonic, diastolic, indirect, regurgitant murmur.

CAUSE, insufficiency of the pulmonic valve, usually following pulmonary diseases or serious lesions of the left heart.

USUAL ACCOMPANYING SYMPTOMS AND SIGNS, are those of the antecedent lesion; evidence of venous engorgement; enlargement of the right heart.

CHARACTER of the murmur of pulmonic regurgitation.

Quality, soft, blowing.

Rhythm, diastolic, accompanying or replacing the second sound.

AREA OF MAXIMUM INTENSITY, over the left, second intercostal space.

PROPAGATION, downward towards the xiphoid cartilage.

FREQUENCY, rare.

Non-valvular, organic murmur.

Intra-ventricular or intra-auricular murmurs.

Cause, roughening of the endocardial lining in acute endocarditis; rarely it may be due to a tendinous cord stretched across the ventricle (congenital); or cardiac aneurism; or an abnormal congenital opening between the two cavities, patulous foramen ovale.

Usual accompanying symptoms and signs, none constant, though they may be those of acute endocarditis.

Character of the organic, intra-ventricular murmur.

Quality, variable.

Rhythm, systolic.

Area of maximum intensity at or near the apex.

Propagation, limited.

Frequency, quite common in acute endocarditis.

Inorganic, or functional, endocardial murmurs.

Inorganic, valvular murmurs.

Systolic, inorganic, valvular murmurs.

Of the left heart.

Mitral, systolic, inorganic, regurgitant murmur.

MAY OCCUR PURELY FROM FUNCTIONAL INCOMPETENCE without actual lesion of the valve. Its character does not differ from the organic murmur. Such a murmur may appear and disappear without previous, accompanying, or subsequent evidence of endocarditis.

FREQUENCY, it is comparatively rare.

Aortic, systolic, inorganic murmurs.

CAUSE, anæmia.

ACCOMPANYING SYMPTOMS AND SIGNS, those of

Anæmia: pallor, lassitude, weak pulse,

Venous hum over the jugulars, and frequently an

Arterial, systolic murmur, produced in the carotids which is usually of different quality and pitch from the cardiac murmur.

No cardiac enlargement is present or other sign of valvular lesion.

CHARACTER.

Quality, soft.

Rhythm, systolic,

AREA OF MAXIMUM INTENSITY over the base of the heart, above the third rib, frequently in the aortic area.

PROPAGATION occurs into the arch of the aorta and the carotids; frequently a louder murmur produced in, and heard over the carotids, may accompany it.

FREQUENCY, the inorganic, aortic, systolic murmur is more common than the organic.

Of the right heart.

Tricuspid, inorganic, regurgitant murmur.

CAUSE, functional incompetence of the tricuspid valve, similar to that of the mitral valve.

Pulmonic, systolic, inorganic murmur.

CAUSE, anæmia.

CHARACTER, similar to that of the aortic, systolic, inorganic murmur.

AREA OF MAXIMUM INTENSITY, is over the pulmonary area.

PROPAGATION is limited; it is not transmitted above the base of the heart, but may be accompanied by an anæmic murmur produced in the carotids, which is frequently of different quality and pitch.

Diastolic, inorganic murmur of both left and right heart are very rare and practically unimportant.

***Inorganic, non-valvular murmurs* are indefinite and unimportant.**

VASCULAR SOUNDS, sounds heard over the vessels.

ARTERIAL SOUNDS.

NORMAL ARTERIAL SOUNDS.

Over the aorta and commonly over the carotid and subclavian arteries are to be heard a systolic, indistinct, rushing sound produced by the blood pulsating through the arteries.

Diastolic second sound of the heart may be transmitted into the aorta and carotids. (It may be impure or entirely wanting.)

Over the Subclavian arteries at the end of inspiration, a systolic, blowing murmur may be frequently heard in health.

Over the abdominal aorta and crural arteries is sometimes to be heard a pulsating sound, corresponding in rhythm to the pulse in those arteries.

Over the small vessels nothing is to be heard.

Pressure of the stethoscope over any of the large arteries may produce a murmur occurring with the local pulsation.

Over the anterior fontanelle and sometimes over the carotids of children, between the ages of three months and six years, a blowing, systolic murmur, of variable intensity, is frequently heard, "cerebral blowing."

ABNORMAL ARTERIAL SOUNDS.

Over the aorta, carotid and subclavian arteries may be heard systolic and diastolic murmurs produced at the aortic orifice of the heart; in aneurism of these vessels a systolic whizzing or blowing murmur may frequently be heard over them.

Over the crural, brachial, radial and ulnar arteries, and even the peroneal and dorsalis pedis a murmur may be heard with the pulse in the respective vessels in some cases of aortic insufficiency.

Over the crural arteries a systolic murmur may sometimes be heard in anæmia and chlorosis, and in high fever, (as well as occasionally in health.)

Over the **crural arteries** a double murmur, diastolic and systolic, may be heard in some cases of aortic insufficiency (Traube); exceptionally in mitral stenosis (Weil); in lead-poisoning (Matterstock), and in pregnancy (Gerhardt).
 Over the **crural arteries** also, in many cases of aortic insufficiency, a double murmur may be produced by the pressure of the stethoscope over the artery, "Duroziez's double murmur." This can only occur with a large, quick pulse.
 Over the **subclavian artery** a systolic murmur (sometimes normal, as when due to pressure of the stethoscope) may be produced by pressure of tumors on the vessel; traction by lung in fibroid disease of the apex.

VENOUS SOUNDS.

NORMAL venous sounds.

Over the **right jugular vein** in health a continuous venous hum is exceptionally heard.

Over the **crural vein**, occasionally in health, especially in thin persons, a sound may be heard, produced by sudden straining efforts or coughing (Friedrich).

ABNORMAL venous sounds.

Over the **jugular vein**.

In tricuspid insufficiency, a systolic murmur may sometimes be heard.

In anæmia and chlorosis, a venous hum more or less continuous is often

present over this vessel, associated with a systolic, blowing murmur in the carotids.

Cause uncertain.

Character.

Quality, whizzing or humming, (like a singing top).


Duration, intermittent or constant, but disappearing with the anæmia.

Intensity, loudest over the right jugular, with the patient erect and the head turned to the left. The intensity is increased during ventricular diastole, during inspiration, by moderate pressure of the stethoscope, and by quickening of the circulation.

Over the crural veins, exceptionally, in tricuspid insufficiency may be heard a double sound, indicating first auricular then ventricular contraction, (Friedreich); this is not easily distinguished from like murmurs produced in the crural artery.

SUCCUSSION.

The succussion or splashing sound is produced in a cavity which contains both fluid and gas, by shaking the patient. Normally it may sometimes be heard over the stomach; pathologically it is a sign of pneumo-hydrothorax. The character of the sound is like that produced when a small keg, partly filled with liquid, is shaken (*vide* p. 89).







LIBRARY OF CONGRESS



0 021 062 276 7