


THE PRINCIPLES
OF
PATHOLOGIC HISTOLOGY

BY
FRANK B. MALLORY, M.D.

ASSOCIATE PROFESSOR OF PATHOLOGY, HARVARD MEDICAL SCHOOL
PATHOLOGIST TO THE BOSTON CITY HOSPITAL

*With 497 Figures Containing 683 Illustrations
124 in Colors, and All But Two Original
Printed Directly in the Text*



PHILADELPHIA AND LONDON
W. B. SAUNDERS COMPANY
1914

Copyright, 1914, by W. B. Saunders Company

PRINTED IN AMERICA

PRESS OF
W. B. SAUNDERS COMPANY
PHILADELPHIA

TO MY ASSISTANTS, PAST AND PRESENT, AT THE
PATHOLOGICAL LABORATORY OF THE BOSTON CITY
HOSPITAL, IN APPRECIATION OF THE KNOWLEDGE,
TRAINING AND STIMULATION WHICH I HAVE RECEIVED
FROM INTIMATE ASSOCIATION WITH THEM

PREFACE

THIS book treats of pathology from the morphologic point of view. The aim constantly in mind has been to present the subject biologically, first by ascertaining so far as possible the cellular elements out of which the various lesions are built up, and then by tracing the development of the lesions from the simplest to the most complex.

The principle followed may be stated in another way. In order to understand an end result such as sclerosis of an organ or tissue (for instance, cirrhosis of the liver or chronic nephritis) it is necessary to find and study all the various acute lesions which may terminate in sclerosis. Frequently much the same end result may be produced in several different ways. Once the complete development of the various lesions has been traced, then the final result becomes more intelligible, so that we are often able in a given instance to surmise or even to state definitely how it arose. In other words, we are in a position to read the process backward with some degree of certainty.

The morphologic side of pathology is difficult for many students to comprehend. To them it is a dead subject. They cannot read the cell changes going on and visualize them into an active process. Moreover, it requires patience often extending over many years to collect the tissues most suitable for study and for teaching purposes. Even then, with the pathologic problems made as simple as possible by having perfect tissues, perfect fixation, and the best of stained sections, the lesions are not always easy to read and to interpret. On the other hand, recourse to animal experimentation has often served to confuse a subject rather than to simplify and clear it up.

In pathology the lesions themselves are the original sources of information. It is necessary to keep going back to them in order, by means of constantly improved technic, to reinterpret the changes which are taking place. The literature of a pathologic subject represents the history of the study, understanding, and interpretation of the lesions. It is much less important than the study of the lesions themselves. Hence, not the literature of a pathologic subject, but perfect tissue, fixed and stained by the best methods, affords the greatest opportunities for advance. It is in

this way that this book has been written. It is based so far as possible on the study of lesions from the earliest to the most developed, not on what some one else has written about them. At the same time use has been made of the literature to avoid going astray, at least too far, and in order to obtain other men's ideas. The "Pathologische Anatomie," edited by Aschoff, has been particularly helpful in this respect and much use has been made of it.

This book is based primarily on a study and analysis of the pathologic material collected during the past sixteen years in the Pathological Laboratory of the Boston City Hospital. In addition, I am indebted to Drs. J. H. Wright, S. B. Wolbach and L. J. Rhea for the use of their collections, which they have freely and generously placed at my disposal. I am also under great obligations to many of my former and present assistants for help in many ways and especially for the use of tissues showing lesions which I had been unable to obtain.

The book is incomplete owing to lack of time and of pathologic specimens which would render possible the study of all stages in the development of the various lesions. The book as it stands affords a framework on which to build in the future if it seems to fill a want. Some parts of it are more or less representative of the ideal on which it was planned. Other portions are only partially completed. A few subjects are entirely omitted.

The majority of the photomicrographs are my own, but many were made with the assistance of Dr. S. Burt Wolbach, to whom I owe whatever knowledge I have acquired of the technic of this difficult branch of photography. For a small number of the photographic illustrations I am indebted to Drs. Wolbach and Ordway. Initials state the origin of all photographs except a few made long ago, of which the makers have been forgotten.

Finally, I am indebted to Miss Etta R. Piotti for all the drawings; they have been made with photographic accuracy from actual fields; to Miss Leonie M. Corcoran for her careful type-writing and proof-reading of the manuscript; and to Miss Lillian M. Leavitt for her versatile technical assistance in cutting and staining sections, making photographic prints and in various other ways.

F. B. MALLORY.

BOSTON, MASS.,
January, 1914.

CONTENTS

PART I

GENERAL PATHOLOGIC HISTOLOGY

	PAGE
INFLAMMATION	17
Introduction	17
The Normal Circulation	20
The Constituents of the Normal Blood	21
The Simple Constituents of Normal Tissues	24
Injurious Agents (Irritants)	27
The Injury Produced	31
Reaction	32
Emigration of Leukocytes	36
Varieties of Acute Inflammatory Exudation	41
Reaction to Mild Injurious Agents	48
Reaction to Injurious Agents Within the Circulation	49
REPAIR	51
Foreign Bodies	51
Organization of Fibrin	56
Regeneration of Cells	60
Regeneration of Parts of Cells	66
Healing of Organ and Tissue Injuries	70
Repair of Bone	75
Repair of Cartilage	78
Repair of Muscle	78
Healing of Tissue Defects in the Central Nervous System	78
RETROGRADE PROCESSES AND THE SUBSTANCES ASSOCIATED WITH THEM	79
Postmortem Changes	80
Atrophy	82
Albuminous Granules	86
Fat	88
Fluid	94
Necrosis	96
Hyaline Substances	99
Glycogen	99
Mucin	101
Amyloid	102
Colloid	107
Fibrin	108
Hyalin	108
Pigments	111
Petrification	119
SPECIAL INJURIOUS AGENTS AND THE LESIONS THEY PRODUCE	126
Staphylococcus Pyogenes Aureus	126
Streptococcus Pyogenes	131


	PAGE
Diplococcus Lanceolatus (Pneumococcus)	136
Micrococcus Intracellularis Meningitidis (Meningococcus)	138
Diplococcus Gonorrhœæ (Gonococcus)	143
Bacillus Diphtheriæ	146
Bacillus Anthracis	151
Bacillus Mucosus Capsulatus	156
Bacillus of Rhinoscleroma	157
Bacillus Mallei	158
Bacillus Aërogenes Capsulatus	161
Bacillus Typhosus	162
Bacillus Coli Communis	179
Bacillus Pertussis	182
Bacillus Tuberculosis	184
Bacillus Lepreæ	203
Actinomyces	209
Treponema Pallidum	213
Blastomyces and Oidium	230
Entameba Histolytica	236
Balantidium Coli	239
Trichinella Spiralis	243
TUMORS	251
Tumor Characteristics	252
SIMPLE TUMORS	276
Introduction to the Four Connective-tissue Tumors	276
1. Fibroblastoma (Fibroma, Fibrosarcoma)	277
2. Myxoblastoma (Myxoma, Myxosarcoma)	288
3. Chondroblastoma (Chondroma, Chondrosarcoma)	291
4. Osteoblastoma (Osteoma, Osteosarcoma)	295
5. Lipoblastoma (Lipoma)	301
6. Leiomyoblastoma (Leiomyoma)	305
7. Endothelioblastoma	309
8. Lymphoblastoma	326
9. Myeloblastoma (Myelogenous Leukemia; Chloroma)	334
10. Myeloma	338
11. Melanoblastoma (Melanoma, Melanotic Sarcoma)	340
12. Rhabdomyoblastoma (Rhabdomyoma)	343
13. Glioblastoma (Glioma)	348
14. Neuroblastoma (Neurocytoma, Neuroma)	355
15. Epithelioblastoma (Papilloma, Adenoma, Carcinoma)	358
MIXED TUMORS	406

PART II

SPECIAL PATHOLOGIC HISTOLOGY

ORGANS OF CIRCULATION	411
Pericardial Cavity	411
Endocardium	415
Myocardium	422
Blood-vessels	438
ORGANS OF RESPIRATION	464
Lungs	464
Pleural Cavity	477

	PAGE
ORGANS OF DIGESTION	479
Esophagus	481
Stomach	481
Intestine	485
Peritoneal Cavity	488
Liver	488
Gall-bladder	519
Pancreas	519
URINARY ORGANS	531
Kidney	531
Urinary Bladder	585
Urethra	588
MALE GENITAL ORGANS	589
Penis	589
Testicle and Epididymis	590
Seminal Vesicles	593
Prostate	593
FEMALE GENITAL ORGANS	597
Uterus	597
Oviduct	600
Ovary	601
Mammary Gland	602
Placenta	604
BLOOD-MAKING ORGANS	606
Bone Marrow	606
Spleen	610
Lymph-nodes	620
ORGANS OF THE CENTRAL NERVOUS SYSTEM	624
Brain and Spinal Cord	624
Pia	638
Dura	639
Dural Endothelium	640
ORGANS OF LOCOMOTION	641
Bones	641
OTHER ORGANS	651
Adrenal Glands	651
Thyroid Gland	655
INDEX	663





THE PRINCIPLES OF PATHOLOGIC HISTOLOGY

PART I

GENERAL PATHOLOGIC HISTOLOGY

INFLAMMATION

INTRODUCTION

Inflammation in a broad sense is the term applied to the reaction of living organisms to any injury done to them or to any part of them. It is a process tending toward removal or counteraction (neutralization) of the injurious agent and toward repair of the injury produced. In the higher animals the function of counteracting injurious agents is delegated largely to the fluid and cellular elements of the blood. If the injurious agent is within the circulation, this counteraction takes place there; if it is on a surface or within the lymph-spaces of an organ or tissue, the fluid and cellular elements of the blood exude onto the surface or into the lymph-spaces, in varying proportions according to the nature of the injurious agent, and combat it there.

The term inflammation is commonly used also in a restricted sense for the more active type of reaction, namely, acute exudation, called out by strong irritants acting outside of blood-vessels and producing severe injury to cells and tissues. The broad use of the term should, however, be constantly borne in mind because it aids in the understanding of the close relation which exists between the different types of reaction, caused by the various strong and mild irritants acting within and outside of the circulation.

As inflammation is the reaction to the injury produced by an injurious agent it is necessary, in order fully to understand the process, to study the injurious agent and the injury produced as well as the reaction. For this reason—

The logical order in which to study inflammation is as follows:

1. The injurious agent.

2. The injury done to the cells and intercellular substances.
3. The reaction to the injurious agent and to the injury.

The location of an injurious agent is very important as regards the injury produced and the inflammatory reaction. It may be—

1. On a surface, as on the skin or within a serous cavity, a duct, a gland, an alveolus.
2. In the lymph-spaces or vessels of an organ or tissue.
3. In the circulating blood.

If the injurious agent is within the circulation, the reaction between it and the elements of the blood takes place there. Under this condition the resulting injury is usually difficult or impossible of demonstration, because it may have been produced only on the elements of the blood, and the reaction is so generally distributed in the circulation that often little or no effect is visible.

When, however, the injurious agent is outside of the circulation, it is usually rather sharply localized in one focus or another, and the injury is often marked. The elements of the blood, in order to reach the injurious agent, must escape from the blood-vessels. As a result they accumulate in the affected area, and in this way striking lesions are often produced.

The reaction between the injurious agent and the blood elements is the same within and outside of the vessels, but the obvious effects produced are very different. Compare, for example, an anthrax septicemia with an anthrax pustule or a pure staphylococcus pyogenes aureus septicemia with an ordinary furuncle or carbuncle.

Some injurious agents act only outside of blood-vessels (heat), others only within them (plasmodium malarix); some act sometimes within, sometimes without (staphylococcus pyogenes aureus, b. anthracis); others often in both situations (b. tuberculosis, b. lepræ).

The reaction to injurious agents acting outside of the circulation is taken up first, because the effects produced are much more striking and, as a rule, much easier to follow.

The injury produced by the irritant may be evidenced in three ways:

1. Chemically, by changes in cellular metabolism, including secretion and excretion.
2. Morphologically, by retrograde changes on the part of the cells immediately affected.
3. Physiologically, by alteration or impairment of functional activity.

In studying the injury and reaction produced by an injurious agent, it must be borne in mind that the basis of all morphologic and physiologic changes is chemical. Sometimes the chemical

change is prominent, and we can recognize it (carbon monoxid hemoglobin in the blood following poisoning by illuminating gas); more often we observe the morphologic change (abscess, miliary tubercle); less often the physiologic (convulsions as a result of strychnin poisoning, or coma from an overdose of morphin).

The chemical changes bring about the morphologic and physiologic changes which we recognize as lesions, signs, and symptoms. The lesions, signs, and symptoms all together, representing the effects of the reaction of the body to injurious agents, constitute the diseases which are characteristic of the injurious agents producing them. We are concerned in this book chiefly with the morphologic changes which constitute the lesions.

The morphologic elements which are called out of the circulation by injurious agents producing their effect outside of the blood-vessels are comparatively few in number; by exudation, serum (from which fibrin may form under certain conditions); by emigration, polymorphonuclear and endothelial leukocytes, lymphocytes, eosinophiles, and possibly also mastcells; and by diapedesis, red blood-corpuscles. In addition the number of cells in and around the injured area may be increased by proliferation of endothelial cells, endothelial leukocytes, lymphocytes, fibroblasts and epithelial cells.

It is not alone the number of the exudative and proliferative elements of inflammation which leads to the great variety in the appearance of inflammatory lesions, but the proportions in which the various elements are combined, the great variety in the structure and character of the tissues in which the exudation takes place, and the various retrograde changes which the injured tissues and the exudative elements may undergo. Occasionally, too, the presence of the injurious agent may complicate the picture.

Some injurious agents call all the exudative elements of inflammation into action; others only one or two. The several elements do not appear synchronously and yet they do not necessarily follow in sequence. Exudation of serum takes place quickest; emigration of polymorphonuclear leukocytes next; then follow emigration of endothelial leukocytes and lymphocytes. Proliferation of cells seems to start almost at once, but requires time to be much in evidence. The character of the reaction depends on the elements which compose it, and the variety and number of the elements called out depend on the nature of the injurious agent.

It is advisable to study the elements of inflammation at first in the simplest tissues obtainable, so as to render the changes which take place as clear and evident as possible, and to study

later similar changes in tissues in which more or less highly differentiated cells occur. It is also advisable and customary to study, so far as possible, each element of the process of inflammation by itself so as further to simplify matters. For this reason experimental lesions in animals are commonly resorted to, and the use of certain tissues and certain irritants has become classical. Similar lesions occur in man but are not always obtainable. Tissues removed at surgical operations and fixed immediately furnish the best material. In animal lesions the tissue itself, the nature and strength of the injurious agent, and the duration of its action can all be accurately controlled. Moreover, the tissue can be obtained in an absolutely fresh condition before any postmortem changes have set in.

Before beginning to study the reaction of normal tissues to injurious agents, it is necessary to have as accurate a knowledge as possible of the normal circulation within blood- and lymph-vessels, of the elements which constitute the blood and lymph, and of the histologic structure of the normal tissues. To obtain such knowledge is not so easy a problem as it might seem to be, even when the simplest of the normal tissues are selected. Here only the simplest tissue elements will be considered. For more detailed information text-books on normal histology should be consulted. It is also strongly advised to study sections of normal tissues for comparison with the pathologic.

THE NORMAL CIRCULATION

The normal circulation in peripheral blood-vessels may be studied directly under the microscope in the mesentery, tongue, or web of foot of the frog. With certain precautions it may be studied also in the mesentery of warm-blooded animals.

The flow of the blood in the arteries is intermittent, faster in the systole of the heart, slower in the diastole. The red blood-corpuscles flow in the center of the vessel as a red core. Between them and the vessel wall is a colorless zone called the plasma zone. The white blood-corpuscles flow along the inner surface of the vessel in the plasma zone and travel much more slowly than the red blood-corpuscles.

The flow of the blood in the capillaries is slow and continuous, although often faster in one vessel than in another. The axial core and the plasma zone are lost because the lumen of a capillary is usually not much larger than a red blood-corpuscle.

The flow in the veins is slower than in the arteries and is continuous. The axial core and the plasma zone are present, but are not so sharply marked as in the arteries.

THE CONSTITUENTS OF THE NORMAL BLOOD

The chief constituents of the normal blood are eight in number. They consist of the red blood-corpuses, of the blood platelets, of five different types of white blood-corpuses, and of the blood plasma as shown in the following list:

1. Red blood-corpuses, erythrocytes.
2. Blood platelets.
3. Polymorphonuclear leukocytes.
4. Endothelial leukocytes.
5. Lymphocytes.
6. Eosinophiles.
7. Mastcells.
8. Blood plasma.

Some of the constituents of the blood are very characteristic and can be recognized under almost all conditions; others are less definite. Authorities disagree more or less in regard to the classification of the white blood-corpuses, especially in regard to the one labeled endothelial leukocyte. The usual way of studying the cells of the blood is by the cover slip method of Ehrlich. This method is, in general, the best for preserving the granules in the cytoplasm of the leukocytes so that a differential stain of them may be obtained. On the other hand, the cytoplasm itself and the nuclei are poorly preserved. This method of studying the leukocytes probably places too much emphasis on minor structures (the cytoplasmic granules) of the cells.

Fixation of the blood by the same methods that are used for tissues (Zenker's fluid) preserves the nuclei and cytoplasm perfectly, and to some extent the cytoplasmic granules, so that the cells appear much as they do in the tissues, and therefore can be more easily compared with them and identified.

1. **Red Blood-corpuses, Erythrocytes.**—They are bell- or cup-shaped masses of cytoplasm containing no nucleus. They vary little in size; their average diameter is 7.5 microns. One c. mm. of blood contains on the average 4,500,000 to 5,000,000 red blood-corpuses.

The red blood-corpuses contain hemoglobin which can be fixed in them by certain reagents (heat, chrome salts, formaldehyd). The hemoglobin thus fixed stains readily and deeply with acid dyes such as eosin, and thus renders the red blood-corpuses very prominent.

The red blood-corpuses are derived from the erythroblasts of the bone marrow.

2. **Blood Platelets.**—They are round or oval discs measuring about three microns in diameter. It is characteristic of them that

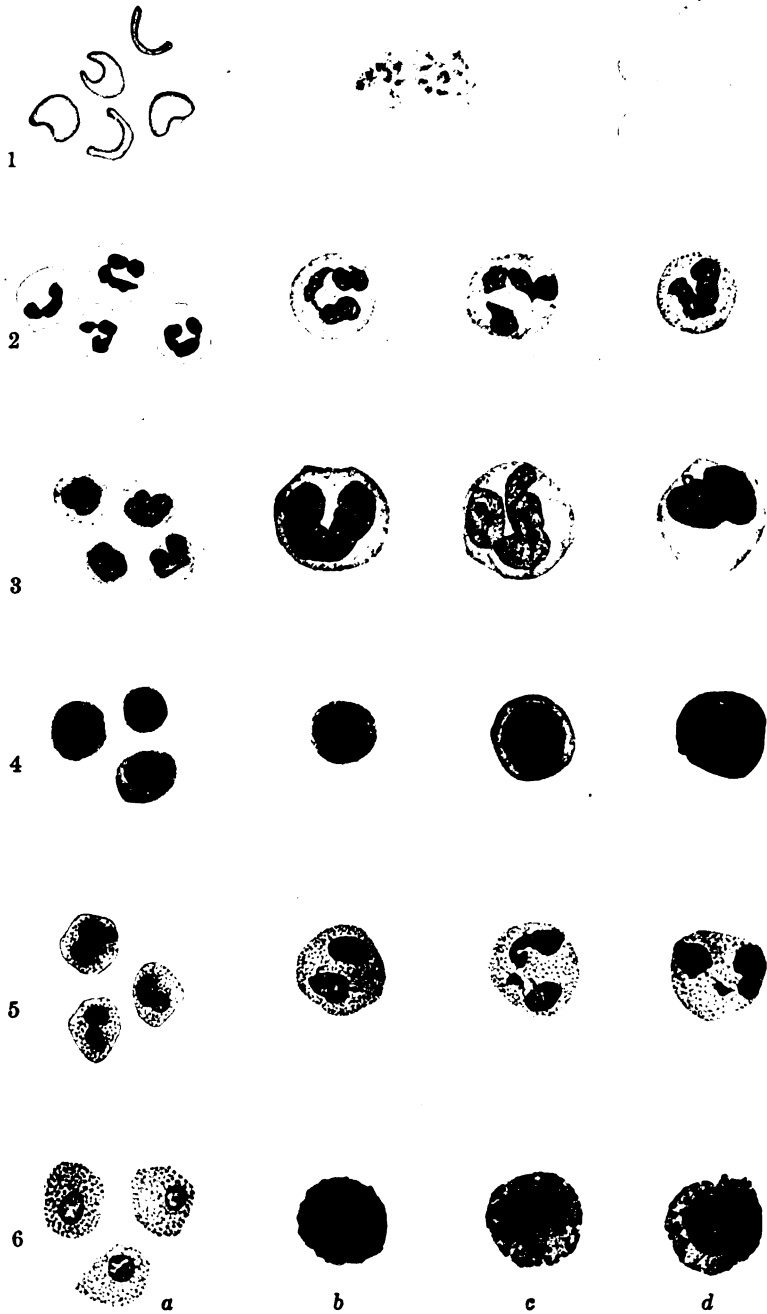


Fig. 1.—The cellular elements of the blood. Column *a*, as seen in Zenker fixed tissue preparations after staining with eosin and methylene blue. Columns *b*, *c*, and *d*, as seen in blood smear preparations stained by Wright's method. 1. Red blood-corpuscles with blood platelets between them; 2. polymorphonuclear leukocytes; 3, endothelial leukocytes; 4, lymphocytes; 5, eosinophiles; 6, mastcells.

they tend to collect in clumps and to disintegrate and disappear rapidly in preparations made in the ordinary way. They remain unclumped and intact in a 2.5 to 5 per cent solution of sodium metaphosphate.

One c. mm. of blood contains on the average 250,000 to 500,000 platelets, but variations within wide limits occur.

It has been demonstrated by J. H. Wright that blood platelets are detached portions or fragments of the cytoplasm of the megakaryocytes. He has shown by a special staining method that they consist of a hyaline substance which can be stained blue, in which are imbedded closely set minute red to purple staining granules.

White Corpuscles.—The white corpuscles are present to the number of 8,000 on the average in one c. mm. of normal blood. Their proportion to the red blood-corpuscles is as 1 to 600.

3. Polymorphonuclear Leukocytes: Neutrophilic, Granular Leukocytes.—They form from 70 to 72 per cent of all the white corpuscles. In size they are a little larger than the red blood-corpuscles. The nucleus is polymorphous, composed of several more or less irregular or rounded lobules which are united by slight filaments of nuclear material. The nucleus stains deeply with basic (nuclear) dyes.

The cytoplasm contains very numerous fine granules which, in cover-slip preparations prepared by Ehrlich's method, take a double (so-called neutrophilic) stain. In tissues hardened in Zenker's fluid these granules are, as a rule, rather poorly preserved and stain lightly with eosin. The cytoplasm is sharply limited by a distinct and characteristic cell membrane.

The polymorphonuclear leukocytes are formed from the neutrophilic myelocytes of the bone marrow.

4. Endothelial Leukocytes; Large, Mononuclear, Non-Granular Leukocytes.—They are usually a little larger than the polymorphonuclear leukocyte, being two to three times the size of a red blood-corpuscle. Each leukocyte contains an oval, eccentrically situated nucleus which is usually curved or indented. It is never divided into masses. It stains lightly, never intensely like the nucleus of the polymorphonuclear leukocyte. The cytoplasm contains no granules, and is limited by no definite cell membrane.

Endothelial leukocytes number from 2 to 4 per cent of all the white corpuscles. They are derived from the endothelial cells lining blood, and to a less extent lymph, vessels by proliferation and desquamation. They also multiply by mitosis after emigration from the vessels into the lesions.

5. Lymphocytes.—They form 22 to 25 per cent of all the white corpuscles. They are of about the size of the red blood-

corpuscles. By Ehrlich's method the nucleus is poorly preserved and stains homogeneously. After fixation in Zenker's fluid the nucleus is very characteristic. It is round, the periphery stains sharply, and small masses of chromatin project inwardly from the periphery, and are connected by chromatin threads with similar granules in the interior, giving the nucleus a granular reticular appearance, even under low power. The nucleus is generally slightly eccentrically located in the cytoplasm.

The cytoplasm is usually small in amount, forming often but a narrow rim, and sometimes even seems to be absent. It tends to stain rather deeply with basic dyes, especially with methylene blue, except in one small area near the nucleus in which lie the two centrosomes. By special methods it is possible to demonstrate in the cytoplasm minute elongated granules which are regarded by Schridde as diagnostic of these leukocytes.

Lymphocytes are produced in the lymphoid tissue in various parts of the body, but particularly in the lymph-nodes.

6. Eosinophiles.—They form two to four per cent of all the leukocytes. The nucleus is usually polymorphous, but may be horseshoe-shaped or round. The cytoplasm contains numerous coarse granules which after fixation by heat or by Zenker's fluid stain intensely with eosin and other acid dyes. The cells are often larger than the polymorphonuclear leukocyte.

Eosinophiles are derived from the acidophilic myelocytes of the bone marrow.

7. Mastcells.—They form about .5 per cent of all the leukocytes. The nucleus is polymorphous. The cytoplasm contains numerous fairly coarse granules which stain deeply with basic dyes. A differential stain of the granules may be obtained by means of certain polychrome dyes such as thionin. The granules are well preserved by alcohol, poorly by Zenker's fluid.

Mastcells arise from the basophilic myelocytes of the bone marrow.

8. Blood Plasma.—It forms the intercellular substance of the blood. Deprived of its fibrin, of which it contains .1 to .4 per cent by weight, it is called serum. The fibrin contains 9.2 per cent of solids, of which 7.6 per cent are proteids (albumin 4.5 per cent; globulin 3.1 per cent).

THE SIMPLE CONSTITUENTS OF NORMAL TISSUES

Leaving out of the question the various specialized cells, the histologic structures which have to be considered in nearly all the different organs and tissues of the body are the following:

1. Fibroblasts or connective-tissue cells with their fibroglia, collagen, and elastic fibrils.

2. Endothelial cells.
3. Nerves.
4. Lymph-vessels and spaces; lymph.
5. Blood-vessels (capillaries, veins, and arteries); blood.
6. Cement substance.

In many tissues under normal conditions the various leukocytes are frequently added to these structures. They mostly enter the tissues by emigration from the blood-vessels, but some

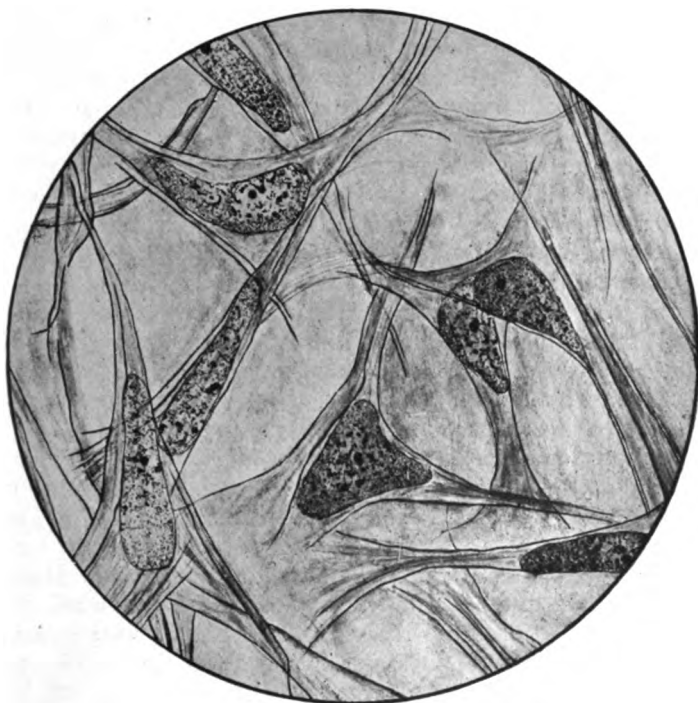


Fig. 2.—Fibroblasts from an organized thrombus. Fibroglia fibrils sharp and distinct. Collagen fibrils fill all the spaces between the cells.

of them probably travel along the lymph-vessels and spaces. Endothelial leukocytes and lymphocytes are perhaps the cells most commonly present, but eosinophiles, mastcells and even polymorphonuclear leukocytes are occasionally found.

1. **Fibroblasts, Connective-tissue Cells.**—They vary considerably in shape in different situations. As a rule, they are flat elongated cells with flat oval nuclei which lie more or less centrally, stain rather lightly, and show a distinct chromatin

network. The cytoplasm usually extends out in one or more processes at each end of the cell.

The fibroblast may produce under different conditions three kinds of fibrils in varying amounts, namely, fibroglia, collagen and elastic fibrils. Apparently every fibroblast produces the first two; but the elastic fibrils are found only in certain situations, as in the walls of blood-vessels, around ducts, and in the corium. Under other conditions as in lymph-nodules, the collagen fibrils appear in a modified form as a reticulum.

The fibroglia fibrils are very delicate fibrils which have an intimate relation to the cytoplasm of connective-tissue cells. They form a part of the periphery of the cell from which they arise and run along its cytoplasmic processes. They seem to extend to the surface of other fibroblasts, but this cannot be proved. Fibroglia fibrils differ chemically from the collagen and elastic fibrils, and can be stained differentially from them. They are most numerous and best studied in young, rapidly growing connective tissue.

Collagen fibrils are very delicate fibrils which usually are cemented closely together and run in wavy bundles; or, as in the cornea, in straight lines arranged in thin planes. They swell up in dilute acids such as acetic acid and become transparent. They are destroyed by caustic potash.

Under certain conditions, as in lymph-nodules, the collagen fibrils are formed into an interlacing branching network or reticulum of delicate fibrils which differ morphologically and possibly to some extent chemically, from ordinary collagen fibrils, but certainly are closely related to them.

The elastic fibrils occur in the form of a network of fibrils of varying size, or as fenestrated plates. In fresh tissue the fibrils are strongly refractive and have dark outlines. They are very resistant to acids and alkalies which may be used to render them prominent in histologic preparations of fresh tissues. In hardened tissues they are usually not visible, but may be demonstrated by several special differential staining methods.

2. Endothelial Cells.—They line blood- and lymph-vessels; they also occur in connection with the more indefinite lymph-spaces and associated with the reticular supporting framework of organs. They do not produce any intercellular substance unless it be cement substance.

In form the endothelial cell is always more or less flattened. The nucleus lies centrally located, is oval in shape, and stains more faintly than the nucleus of the fibroblast. The cytoplasm, as shown by the nitrate of silver stain, is usually irregular or wavy in outline, but never has prolongations or branches like the fibroblast.

3. **Nerves.**—They are simply cytoplasmic (axis cylinder) processes of nerve-cells. Single nerve-fibers and their terminations can be demonstrated only by means of special staining methods. Bundles of medullated nerve-fibers can be recognized in ordinary sections, best in cross-sections on account of the characteristic appearance of the axis cylinders and their sheaths. With a little care they can be recognized also when running horizontally or obliquely.

4. **Lymph-vessels and Spaces.**—They can be studied best after fixation of fresh tissues in nitrate of silver which stains the cement substance of cells brown and, therefore, defines very sharply the limits of the cells and of any spaces between them. This staining method demonstrates in the cornea, for instance, that the connective-tissue cells are surrounded by lymph-spaces which all communicate with each other, and which are also connected with lymph-vessels. This condition probably holds true of all connective tissues.

The lymph-vessels surround and form more or less definite spaces along the blood-vessels and nerves, but also occur elsewhere in the tissue. They are lined with the same kind of cells as the blood-vessels—that is, with endothelium—but the line of union of the cells is not so regular as in the blood-vessels. No tissue is free from lymphatics; the number of them is usually much under-estimated.

Lymph is a colorless fluid which in part escapes from the blood-vessels through the stomata between the endothelial cells; in part is secreted by the endothelial cells. It differs chemically from blood plasma. It circulates through the lymph-spaces around the connective-tissue cells, nourishing the cells and receiving waste products, and then passes into the lymph-vessels. Lymphocytes in small numbers are usually present in it.

INJURIOUS AGENTS (IRRITANTS)

Various influences may affect the human body injuriously; such as bad heredity; excess and especially deficiency of water, food, or oxygen; variations in the atmospheric pressure; over-use or lack of use of the different organs and tissues; but the actively injurious agents may for the sake of convenience be put into a very few groups.

1. *Mechanical:* Incision, blow, foreign bodies.
2. *Physical:* Heat, cold, sunlight, electricity, x -rays, radium.
3. *Chemical:* Of organic and inorganic origin; (a) Acids, alkalies, poisons. (b) Toxins derived from infectious agents, especially bacteria and protozoa.

Of these injurious agents the bacteria and protozoa, including

the toxic substances derived from them, are the most numerous and the most important. It is not necessary here to enter into a detailed description of them. Such information is readily accessible in the numerous text-books on bacteriology. Reference will be made only to certain appearances of the organisms as seen in connection with the lesions caused by them.

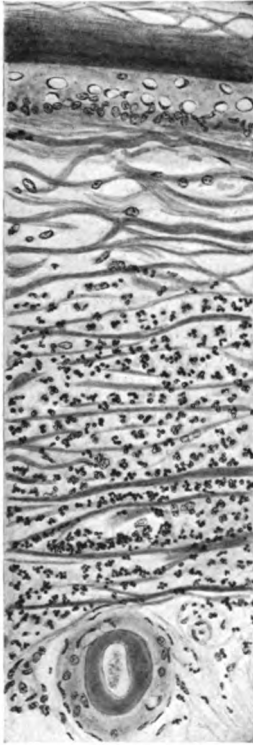


Fig. 3.—Acute inflammation. Emigration and accumulation of polymorphonuclear leukocytes in the subcutaneous tissues of a rabbit's ear as the result of rubbing the surface with dilute croton oil.

Some toxic substances are actively produced by living organisms (diphtheria toxin), others are set free by the dissolution of the bodies of the organisms after death (typhoid endotoxin). It is usual to speak of the organism itself as the active agent, rather than of its toxin. A few organisms seem to act chiefly or entirely mechanically (balantidium coli).

Nature of Action.—The action of an injurious agent may be severe or slight, brief or prolonged. The effect produced varies accordingly. Some injurious agents cause lesions in seconds, minutes, or hours; others act so slowly that they require days, weeks, or even months to produce macroscopic changes.

Some injurious agents produce a maximum effect at once (blow), others begin insidiously (bacteria, etc.), and as they increase in number produce gradually a greater and greater effect.

Some bacteria act for a definite period of time; then their action ceases (bacillus typhosus, diplococcus pneumoniae), probably owing to the production of an antitoxin; other organisms continue to act indefinitely (tubercle bacillus, leprosy bacillus).

An injurious agent may act only on the cells immediately around it (staphylococcus pyogenes aureus toxin), or it may be more or less soluble, and by absorption through lymph- and blood-vessels affect cells both near and at a

distance (bacillus diphtheriae toxin).

Agents Used Experimentally.—The injurious agents most commonly used in the experimental production of certain types of reaction and the tissues on which they are used are the following:

Hot water at the temperature of 54° C. If a rabbit's ear is dipped into it for three minutes an acute inflammatory exudation of serum and chiefly of polymorphonuclear leukocytes takes place into the tissues.

Croton oil, diluted one part to six with olive oil, if rubbed on a rabbit's ear, causes a similar exudation, with perhaps a greater proportion of polymorphonuclear leukocytes. If it is injected into muscle it causes extensive necrosis, followed by an abundant exudation of polymorphonuclear leukocytes.

Turpentine and carbolic acid are sometimes used for the same purposes as croton oil.

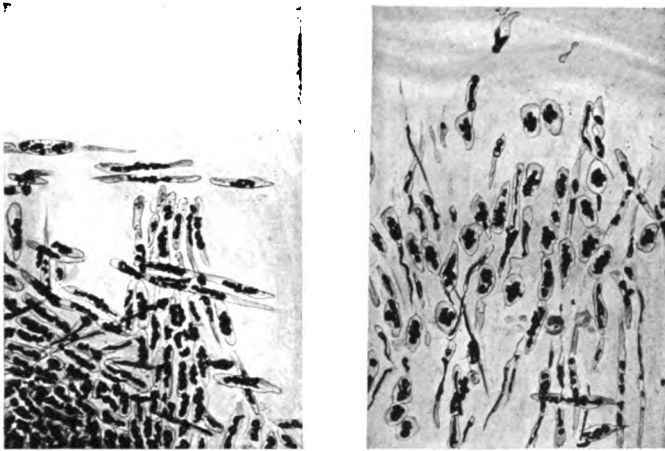


Fig. 4.—Acute inflammation. Migration of polymorphonuclear leukocytes in the cornea attracted by an injury produced in its center.

Caustic potash in the solid stick form is sometimes applied to the cornea of the etherized rabbit to cause necrosis in order to study the processes of exudation and repair.

Similar lesions occurring in man may often be obtained for control study, such as injuries of the skin due to heat, freezing, ammonia, and other active agents; diphtheritic colitis due to corrosive sublimate; acute gastritis caused by carbolic acid.

Chloroform has recently been much employed to cause necrosis of liver cells in animals. It is administered by inhalation. Swallowed with suicidal intent it has caused the same lesion in man.

Mechanical injury is often used for the study of regeneration and repair; as in incision of the cornea, drill holes into bones, fracture of bones, incision and suture of intestine, incision of abdominal wall and of muscles, tendons, and nerves.

Agar-agar is useful, injected subcutaneously, for the study of the exudation and proliferation of endothelial leukocytes and of the formation of foreign body giant-cells from them. The polymorphonuclear leukocytes called out at first by the injury to the tissues disappear in two to three days.

The staphylococcus pyogenes aureus is used for the study of suppuration. Injected subcutaneously it produces necrosis of the tissues in its immediate vicinity and exudation of polymorphonuclear leukocytes followed by softening of the necrotic tissue. The result is an abscess which heals in time by granulation tissue. Injected into the ear vein of a rabbit this organism gives rise to septicemia and to multiple miliary abscesses in the heart,

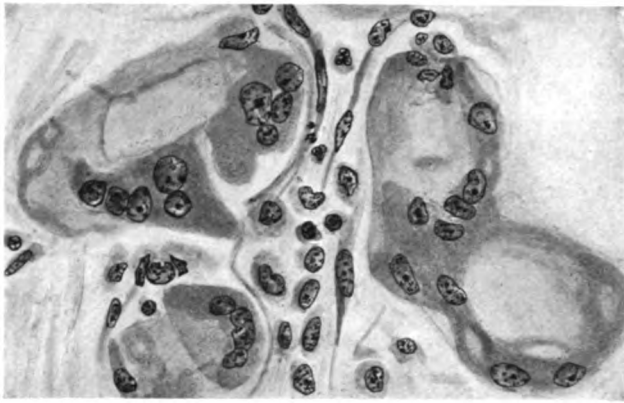


Fig. 5.—Repair. Foreign body giant-cells formed around agar-agar injected subcutaneously in a rabbit.

kidneys, and sometimes in the striated muscles; occasionally, septic infarcts are produced in the kidneys.

The tubercle bacillus causes a slower type of inflammatory reaction. It is usually injected subcutaneously, into the peritoneal cavity, into the ear vein of a rabbit or branches of the portal vein of a guinea pig, or inoculated into a rabbit's cornea.

Various other organisms such as the diplococcus pneumoniae, or the glanders or anthrax bacillus are used; but those cited above are the ones most frequently employed.

Tissues Commonly Used and Studied.—The following tissues are the ones most generally used in the study of acute inflammatory exudation:

The rabbit's ear is useful for demonstrating the clinical signs and symptoms (redness, swelling, heat, and pain) of acute inflammation, as well as for showing the histologic changes which

are taking place. Microscopically the tissues involved are comparatively simple.

Striated muscle readily shows the injury (necrosis) caused by croton oil and similar substances and the changes which follow such an injury.

The cornea is a very simple tissue consisting, beneath the covering of epithelium, of thin layers of fibroblasts and their fibrils with only lymph-spaces lined with endothelium and with terminal nerve fibrils to complicate the picture. It is especially useful for the study of repair of incised wounds in a simple tissue, and of the origin of certain cells which appear in inflammation.

For direct observation of the reaction of tissues to injurious agents of various sorts the following tissues have proved very serviceable: the web of the foot, the tongue, and the mesentery in the frog. They are delicate enough to permit direct study under the microscope. The mesentery in warm-blooded animals has been used for a similar purpose.

THE INJURY PRODUCED

Injury is the term applied to the changes produced in tissues and organs by harmful agents. Trauma is limited to an injury produced mechanically. Lesion is the term applied to any structural change in tissues and organs no matter how produced; it includes injury. Necrosis signifies death, and may be applied to a single cell or to groups of cells.

The injury produced by an irritant is often difficult or even impossible to demonstrate morphologically, as when a rabbit's ear is treated with hot water for only two or three minutes at 54° C., or with dilute croton oil, although the inflammatory reaction may be very marked. The same is true, for example, in pneumonia and in meningitis. We judge of the effect of the irritant largely by the reaction instead of by the injury.

In poisoning by prussic acid the reaction is physiologic; it is tremendous and almost instantaneous. Although the basis of the reaction is undoubtedly chemical, no morphologic change is evident.

In immediate death from chloroform inhalation no significant morphologic lesion is found, but if the patient or the animal experimented on lives two or three days before death, extensive necrosis of liver cells is present and demonstrates at least one injurious effect of the chloroform.

In tetanus and rabies the injury, aside from the primary lesion at the site of infection, is evidenced chiefly or entirely by the physiologic reaction. In rabies little or no morphologic change can be demonstrated beyond the presence of the Negri bodies in the ganglion cells.

When, however, croton oil is injected into such a highly differentiated tissue as muscle the effect (necrosis) is marked within twenty-four hours. Extensive injury is shown in the stomach following poisoning with carbolic acid, in the colon after poisoning with corrosive sublimate, in streptococcus infection of muscle, and frequently in the liver (central necrosis) when there is a septicemia.

Of the injuries directly produced by irritants, necrosis is the easiest to demonstrate histologically, but it requires time to make itself evident. At first, the nuclei stain intensely and uniformly; then they gradually disappear. The cytoplasm becomes homogeneous and stains deeply with acid dyes. Other effects produced sometimes in injured cells are direct division of nuclei; edema of the cytoplasm (hydropic degeneration); changes in the size and number of the albuminous granules in the cytoplasm; deposition of fat-droplets in the cytoplasm. They are due in part, at least, to interference with the chemical and physiologic activity of the cells.

Under the special injurious agents the characteristic retrograde changes caused by them will be referred to; but as the most conspicuous products of retrograde processes (fat, amyloid, hyalin) are usually not the direct and obvious effect of irritants, but the result of changes in metabolism, they will be treated of at some length under a separate heading—"Retrograde Changes."

The chief injury produced in tissues is not always due to the direct toxic action of the injurious agent, but is secondary to obstruction of the capillaries and lymph-spaces by the leukocytes which are attracted and accumulate around the organisms, as, for example, in the lesions occurring in typhoid fever, tuberculosis, and leprosy.

REACTION

The reaction to an injurious agent and to the injury produced by it varies within very wide limits, depending on the amount and the nature of the injurious agent and on the severity and character of the injury. The reaction may be evidenced chemically by metabolic changes, such as alteration of secretion and excretion; morphologically, by the presence of serum, fibrin, and leukocytes, and by the proliferation of cells; and physiologically by alteration of functional activity.

The reaction which occurs in inflammation has a twofold function—(1) to get rid of the injurious agent if still present or to neutralize its action so that it is no longer injurious and (2) to repair the injury, that is, remove and, so far as possible, replace the necrotic cells. In a bland infarct of the kidney we can study the

reaction to simple necrosis where toxic substances derived from the necrotic cells act as an injurious agent, but in a septic infarct we have a double reaction, on the one hand to the necrotic cells, on the other to the toxic agent and to the toxins it generates. As a rule, in infectious processes the injurious agent causes a greater and more characteristic reaction than do the injured cells. It is not customary, however, or perhaps often essential, to separate the two kinds of reaction, but they should be borne in mind.

The reaction of the body to an infectious agent and its toxins, uncomplicated by any marked tissue injury, beyond beginning general retrograde processes dependent partly on toxemia and partly on interference with nutrition, is best seen perhaps in septicemias, where the fight is directly between the irritant on the one hand and the blood plasma and the leukocytes on the other. Often the endothelial cells lining the blood-vessels play an important rôle also by incorporating many of the organisms, as in leprosy, tuberculosis, and dum-dum fever. We can get some idea of what is taking place by studying the variations in the relative proportions of the leukocytes, the chemical changes and altered serum reactions produced in the blood plasma and the clinical signs and symptoms.

The fluid and cellular elements in the blood- and lymph-vessels at the service of the body in combating injurious agents and in aiding in the repair of injuries are few in number. Sometimes only one of them is used; more often two or more. We ordinarily express the condition of affairs in another way by saying that a certain irritant attracts or is chemotactic for a certain kind of leukocyte.

The action exerted by the leukocytes is to some extent, perhaps, mechanical, but their chief effect is produced chemically—that is, is due to the action of chemical substances manufactured by the different leukocytes to neutralize the toxins secreted by microorganisms and to dissolve necrotic cells. Some of these chemical substances can be demonstrated; others are recognized chiefly by the effects they produce. A certain number of them are present in the serum under normal conditions.

The morphologic changes which take place as the result of the action of various injurious agents vary greatly, depending on the strength and character of the latter. Sometimes an irritant will produce one type of injury and reaction in one place (local action of the diphtheria toxin in the throat or of the diplococcus pneumoniae toxin in the lung), and a different type of injury and action in another place where the toxin is carried in a dilute state (diffuse action of the diphtheria toxin in the lymph-nodules of the spleen, etc., or of the diplococcus pneumoniae toxin in the

glomeruli of the kidney). Moreover, different strains of the same organism may produce more than one type of reaction.

In general we may divide the injurious agents into two groups, the strong and the mild irritants (with all gradations between), although it is difficult to confine some of them exclusively to either group. This is particularly true of the tubercle bacillus.

The reaction of tissues to strong irritants has been much studied because the lesions are readily produced experimentally. The reaction to mild irritants is, however, of equal importance, and should have more attention paid to it.

Reaction to Strong Injurious Agents.—The changes which take place as the result of the action of strong irritants and the injury to the cells produced by them are as follows:

1. Circulatory disturbances.
2. Inflammatory exudation.
 - (a) Exudation of lymph (including formation of fibrin).
 - (b) Emigration of leukocytes (chiefly of the polymorphonuclear leukocytes).

The inflammatory exudate is frequently contaminated by red blood-corpuscles due to diapedesis or hemorrhage.

3. Proliferation of emigrated endothelial leukocytes and lymphocytes, of fibroblasts, of vascular endothelium, and of epithelial cells, if included in the lesion.

These changes are partly physiologic, partly morphologic. They lead to certain gross functional and anatomic appearances which are usually recognized clinically when the injurious agent acts strongly on external tissues, and are known as the four cardinal signs of acute inflammation; namely, redness, heat, swelling, and pain. When the injurious agent acts mildly, one or all of these signs may be lacking.

The Four Cardinal Signs of Acute Inflammation.—If a rabbit's ear is rubbed with croton oil the effect produced will be visible in one to three hours. If the croton oil is diluted with six to eight parts of olive oil a longer time will be required. If preferred the rabbit's ear may be dipped for three minutes in water heated to 54° C.

The first point noted is that the circulation becomes more active throughout the ear. The main artery dilates and all the blood-vessels become more prominent. The affected ear appears distinctly redder than the normal ear (*rubor*). It also becomes warmer than the other ear (*calor*). Gradually the ear becomes thicker and may even pit on pressure (*tumor*). It is more sensitive to pressure (*dolor*). These symptoms, produced by injurious agents, are known as the cardinal signs.

Rubor.—The redness is due to increased influx of blood. When

the circulation is active, the color is distinctly red, as in the periphery of a furuncle. When the blood stagnates in the large veins congestion results, and the color is of a dusky bluish hue, as in the center of a furuncle. When the color is due to hemorrhage, the redness remains after pressure; when it is due to blood within vessels, the tissue blanches on pressure. Not only are the blood-vessels in the inflamed area dilated, but there is also dilatation of the arteries which go to the inflamed area and which have not been acted upon directly by the injurious agent.

Calor.—The heat of the part never exceeds the internal body temperature. No heat is produced in the affected area. The increased temperature is due to increased rapidity of circulation and increased supply of blood.

Tumor.—The swelling is produced almost entirely by the exudation; the dilatation of the blood-vessels plays a very unimportant part.

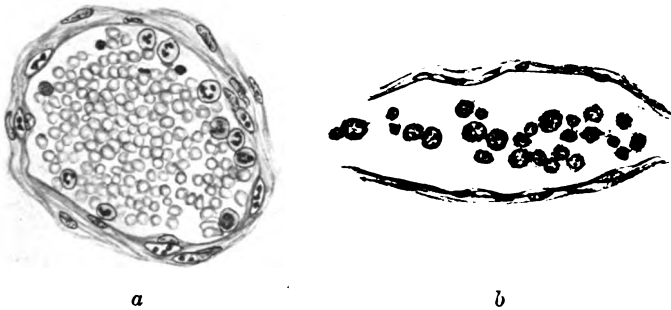


Fig. 6.—Acute inflammation. *a*, Peripheral arrangement of polymorphonuclear leukocytes in vein; *b*, serum and lymphocytes in dilated lymphatic.

Dolor.—The pain is due to the pressure of the exudate on the nerves. It is often possible to count the rate of the heart-beat by the exacerbations of pain due to the increased pressure caused with each systole of the heart, as, for example, in toothache. The degree and character of the pain vary according to the structure of the tissue and the extent of the injury.

To these four signs is sometimes added a fifth, *functio læsa*, impaired function, shown in the rabbit treated with croton oil by drooping of the ear.

The Circulatory Phenomena in Acute Inflammation.—The changes produced in the circulation can be observed directly in living tissues by means of the microscope. For this purpose the frog's mesentery usually is chosen. Although more active agents can be employed, exposure to air ordinarily furnishes sufficient injury.

The arteries show the following changes:

1. An initial temporary constriction followed by—
2. A dilatation of the vessels with more rapid flow of blood (the vessels may reach twice the normal size). Later,
3. The dilatation of the vessels continues, but the flow of blood is slower.

The capillaries in the beginning are dilated and the flow is more rapid; later, the dilatation continues or increases and the flow is diminished.

The veins show dilatation; the flow at first is more rapid, but later becomes slower.

In some of the capillaries and veins the flow may cease entirely.

In the arteries and veins the axial core is at first more pronounced; later, it becomes obliterated.

The leukocytes become attached to the walls of the veins and in a less degree to the walls of the arteries, so that the walls gradually become lined with them.

EMIGRATION OF LEUKOCYTES

The emigration of leukocytes can be followed, by direct observation under the microscope, in the mesentery or tongue of a curarized frog, or in the web of the foot. With certain precautions they can also be studied directly in the mesentery of warm-blooded animals. Various irritants may be used, but exposure to the air is usually sufficient. If desired, the tissues may be fixed at any stage of the process and the finer details studied in stained preparations.

It is chiefly the polymorphonuclear leukocytes which emigrate under these conditions, but in fresh preparations it is not easy to distinguish one type of leukocyte from another. In properly fixed tissues it is possible to demonstrate that under certain conditions endothelial leukocytes, lymphocytes, eosinophiles, and probably mastcells also emigrate.

A leukocyte in emigrating alters its contour. A pointed process of cytoplasm pierces the vessel wall. The nucleus and the remainder of the cytoplasm in turn become attenuated and follow so that the cell finally passes through the wall into the lymph-spaces of the tissue. This emigration of leukocytes takes place not only in the small veins, but also in the capillaries, and under certain conditions through the walls of arteries. It takes place not only from the vessels immediately acted on by the injurious agent, but also from adjoining vessels. The emigrated leukocytes travel toward the seat of injury.

Certain facts about the leukocytes which emigrate and about their functions may be stated briefly here.

1. **Polymorphonuclear Leukocytes.**—These cells play the most important part in acute inflammation, are the first to emigrate, and in the early stages of the process may be the only ones found. They travel to the point of greatest injury, invade masses of bacteria, frequently incorporate certain varieties of them, for example, streptococci, and gonococci, and often are killed in great numbers by the action of the toxins. They also invade necrotic cells and dissolve them through the action of ferments which they secrete.

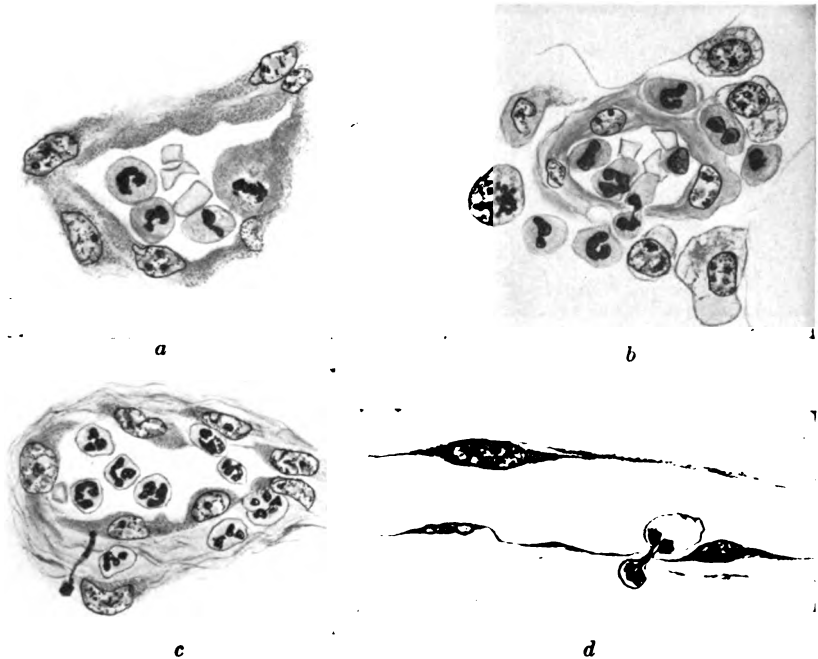


Fig. 7.—Acute inflammation. *a*, Mitosis of endothelial cell in wall of small vein; *b*, *c*, and *d*, emigration of polymorphonuclear leukocytes through the walls of small blood-vessels.

Polymorphonuclear leukocytes reach the injured tissues entirely by emigration; they do not multiply by mitosis in the tissues like some of the other leukocytes. They are called out in great abundance by certain micro-organisms, especially the pus-cocci, and by certain chemicals such as croton oil.

They never incorporate other cells, but they do take up small particles of material such as fragments of fibrin or the sarcous elements of digested muscle.

2. **Endothelial leukocytes** play a very important rôle in inflammation. They are little in evidence early in acute inflam-

matory processes produced by strong injurious agents. They often appear later, when the polymorphonuclear leukocytes are diminishing in number and the injurious agent is killed off or is weakened in activity or diminished in strength.

They are called out by mild injurious agents which act for a considerable length of time; by agents which are mildly toxic, or which act mechanically only. Thus they form the chief or only cell reaction to the leprosy bacillus, the typhoid bacillus, and usually to the tubercle bacillus. They accumulate in large numbers in the blood and lymph-vessels and lymph-spaces to counteract these bacteria and their toxins. The body relies on them also in its struggle against the protozoön of *Leishmania tropica* and against certain other micro-organisms.

Endothelial leukocytes also attend to most foreign bodies; to carbon and other pigments; to free fat in various more or less chronic lesions (arteriosclerosis, softening of brain, chronic abscess) and in fat necrosis; to fat and sodium urate crystals; to inspissated bile, to cholesterin crystals, hairs, and cornified epithelium around which they usually fuse to form foreign body giant-cells. They do this also around particles of bone, thus forming the osteoclasts of bone and the giant-cells in most of the so-called giant-cell sarcomas. They also fuse together to form the occasional giant-cells seen in leprosy and typhoid fever and the many giant-cells found in tuberculosis.

Endothelial leukocytes are phagocytic for certain micro-organisms. They are also phagocytic for other leukocytes (polymorphonuclear leukocytes and lymphocytes), and are the only leukocytes which possess this latter property. In this marked physiologic property they are like the endothelial cells from which they originate. Under certain conditions they incorporate and digest large numbers of other leukocytes and of red blood-corpuscles. They do this when the other cells are injured or killed and also apparently when they themselves need them as nutrition in their struggle to form antitoxins against injurious agents, as in typhoid fever.

Endothelial leukocytes emigrate in part from the blood-vessels, but are derived also from the endothelial cells of the lymphatic system. They multiply rapidly by mitosis in the tissues after emigration.

Their origin, multiplication and fusion to form giant-cells are best studied in lesions one to ten days old produced by the subcutaneous injection of agar-agar.

3. Lymphocytes.—These cells reach the tissues both from the blood and from the lymph-vessels by emigration and migration. They multiply by mitosis in the tissues. They are never pha-

gocytic for micro-organisms or cells. Some of them undergo a change in the tissues and appear in a form to which the term plasma cell is applied. The change is due to a large increase in the amount of cytoplasm which has marked basophilic properties, except for a small acidophilic area adjoining the nucleus in which the centrosomes are always found. The nucleus is eccentric. Frequently, a plasma cell contains two, three, or even four nuclei.

Lymphocytes are most abundant after inflammation has lasted several days, and are most numerous in exudative processes which have persisted for weeks. They are most abundant, as a rule, at the periphery of a lesion. In various toxic conditions they may infiltrate the different organs; for example, the kidney, spleen, and adrenal in diphtheria and scarlet fever.

When a lesion has apparently healed, lymphocytes often persist in numbers for a long while in the lymphatics leading away from the affected tissue, as, for instance, in a healed appendix.

Plasma cells occasionally undergo a change in their cytoplasm in consequence of which it swells and is filled with hyaline globules which stain rather deeply with eosin.

The phrase "cells of the lymphocyte series" is sometimes used to include the lymphoblast and all the cells derived from it (lymphoblast, lymphocyte, lymphoid cell, plasma cell).

The chief function of the lymphocyte seems to be to neutralize or to dispose of injurious substances which are being absorbed through the lymphatics.

4. Eosinophiles.—They are found in very small numbers, as a rule, in acute inflammation, but usually are more numerous during the stage of repair. Sometimes they are quite abundant; for example, in the mucous membrane and in the muscle coats of an otherwise healed appendix. Usually they are more common in chronic lesions. Often they are present in very large numbers in the stroma of cancer of the cervix uteri and in the scirrhous type of lymphoblastoma (often called Hodgkin's disease). Their number in the bone marrow and in the spleen is sometimes much increased.

The relative proportion of eosinophiles in the circulating blood is greatly increased in certain types of infection. This is particularly true in cases of trichiniasis, where it may run as high as thirty or forty per cent or even in rare instances up to sixty per cent.

The function of the eosinophile is unknown, but it certainly has one, probably to counteract certain injurious chemical substances.

In rabbits and some other animals the proportion of eosinophiles in the blood is much larger than in man; this condition must be borne in mind in studying tissues from such animals.

5. **Mastcells.**—Their function is not known, but they occur in a variety of lesions. They are also present under certain conditions in apparently normal tissues. Occasionally, they are abundant in leiomyomas of the uterus and in other tumors.

Diapedesis of Red Blood-corpuses.—In the capillaries not only the leukocytes but also the red blood-corpuses pass through the vessel walls; the red blood-corpuses escape passively through breaks between the endothelial cells, and give rise to small hemorrhages. This act is called diapedesis, and usually takes place after the emigration of leukocytes. Under the influence of certain agents diapedesis may be a more marked phenomenon than emigration. It is due apparently to the severe injury done to the vessel walls by these agents.

Diapedesis is an accidental complication of inflammation. It is not an essential part of the reaction.

Exudation of Lymph.—Besides the leukocytes and the red blood-corpuses, some of the constituents of the blood plasma pass through the walls of the capillaries. For the most part this is not a simple filtration, but is closely akin to secretion. This fluid, called lymph or serum, enters into and dilates the lymph-spaces and vessels of the tissue. It differs chemically both from normal lymph and from blood plasma. It is richer in albumin and poorer in salts than the latter. It escapes readily from the surface of mucous membranes, but collects in serous cavities. It cannot escape through the unbroken skin, but collects in the epidermis beneath the cornified layer, forming blisters. Its presence in the loose connective tissue (edema) can be demonstrated by pressure which forces it from the place pressed upon, leaving a depression. This is called pitting.

The uses served by lymph are to dilute the toxic substances derived from the injurious agents and, in certain instances, to neutralize their action by virtue of chemical substances already present in solution in the lymph.

Fibrin.—Fibrin forms in varying amount in the lymph under the action of fibrin ferment on fibrinogen. The fibrin ferment is set free by disintegration of leukocytes and other cells. Fibrinogen is present in the lymph. On microscopic examination the fibrin in the tissue appears as a network of fine threads with nodal points. In time the threads become coarse and may even form a dense hyaline reticulum. Sometimes it is granular or may occur within cells, such as those of the liver, in the form of globules and short rods. Fibrin is formed most frequently on surfaces such as the air-sacs of the lung and serous surfaces. Fibrin disappears on the addition of acetic acid. In hardened tissues it may be stained differentially.

When the tissue elements are destroyed and are bathed in lymph they often become coated and impregnated with fibrin and stain like it; they are sometimes said to have undergone a fibrinoid change.

When much fibrin forms in an exudation, its presence is sometimes recognized in classifying the lesion; for example, fibrinous pneumonia, fibrinous pericarditis.

Fibrin does not exude from the vessels. It is a pathologic product formed out of the serum which has exuded. Its presence is sometimes harmful, its removal often impossible, and its organization may lead to much trouble (pleural and pericardial adhesions), and may even cause death (internal hydrocephalus following organization of fibrin due to acute epidemic cerebrospinal meningitis).

The quantity of lymph called out by different injurious agents and the amount of fibrin formed vary greatly. A few examples will illustrate.

Mosquito Bite: Much serum quickly poured out; little or no fibrin formed; few leukocytes.

Croton Oil: Much serum; little fibrin; many polymorphonuclear leukocytes.

Diplococcus Pneumoniae: Moderate amount of serum; much fibrin; many polymorphonuclear leukocytes.

Bacillus Tuberculosis: Serum usually moderate in amount; often much fibrin formed (lung, pleural and pericardial cavities); in miliary tubercles usually very little serum, often much fibrin; many endothelial leukocytes.

Bacillus Anthracis: Much serum; considerable fibrin; moderate number of leukocytes; frequently diapedesis of red blood-corpuses.

VARIETIES OF ACUTE INFLAMMATORY EXUDATION

In acute inflammation, as a result of the varying nature of the injurious agents, serum or leukocytes may predominate in the exudation; fibrin may form in abundance from the serum and lie free in the tissue spaces or in a cavity, or be attached lightly or by reason of extensive necrosis intimately to an epithelial surface; much blood may be present in consequence of diapedesis or hemorrhage; epithelial cells and mucus may be mingled with the exudation from an epithelial lined surface; gas may be formed by the infectious agent or marked necrosis or putrefaction produced. Terms descriptive of these various peculiarities are often employed and serve a certain useful function.

The same injurious agent may and usually does cause more than one type of exudation.

1. **Serous Exudation.**—The exudation is chiefly fluid. Polymorphonuclear leukocytes are always present in at least small numbers and a little fibrin may form. An exudation often starts serous in character, but ends by containing much fibrin or many polymorphonuclear leukocytes or both. The serous type of exudation is often complicated by the presence of red blood-corpuses as a result of diapedesis or hemorrhage.

When a serous exudation takes place into the tissue lymph-spaces it is spoken of as inflammatory edema, and the tissue affected is characterized by swelling and a doughy consistence, and usually by redness. If the exudation persists a long time, the tissue cells may imbibe fluid and swell, and the collagen and other intercellular fibrils may undergo various retrograde changes.

If the exudation occurs beneath squamous epithelium, it may give rise to the formation of vesicles.

An excellent example of a serous exudation may be produced experimentally by dipping a rabbit's ear for three minutes into water heated to 54° C. In man it is produced (at least in susceptible individuals) by mosquito bites. It is usual in the first stage of lobar pneumonia due to the diplococcus lanceolatus. It is sometimes caused by the streptococcus pyogenes and by other organisms.

2. **Fibrinous Exudation.**—It consists of serum and leukocytes (chiefly polymorphonuclear), but fibrin forms so abundantly from substances in the serum that usually it dominates the gross and histologic picture and forms the most striking characteristic. This type of exudation may occur diffusely in lymph-spaces, but it is most common on serous and epithelial lined surfaces. It usually fills up small cavities such as the air-spaces of the lungs, but in the large cavities and on free surfaces it forms a definite layer or membrane composed of fibrin threads and meshworks matted together.

The amount of necrosis associated with fibrinous exudations varies greatly. If it is slight and superficial, the layer of fibrin is readily peeled off leaving a smooth but usually dull surface. If the necrosis is marked and extends deeply, as often happens on epithelial surfaces, fibrin forms all through the necrotic tissue and binds it more or less intimately to the fibrin layer on the surface, so that the combined layer either cannot be stripped off or leaves a ragged surface behind.

The effort to distinguish different types of fibrinous layers or membranes has led to the employment of descriptive terms, which are, to say the least, often confusing.

The trouble arises from two sources:

(a) The employment of the clinical term diphtheritic and its

derivatives, diphtheroid and pseudo-diphtheritic, in a purely anatomic sense for certain types of fibrinous membranes on epithelial surfaces.

(b) The attempt to distinguish three different types of fibrinous membranes according to the intimacy of their attachment to the underlying surface and according to the amount of necrosis present. The final distinction between them has to be made with the microscope, although we learn to recognize the different varieties with a certain amount of confidence according to the location of the lesion and the nature of the infectious agent.

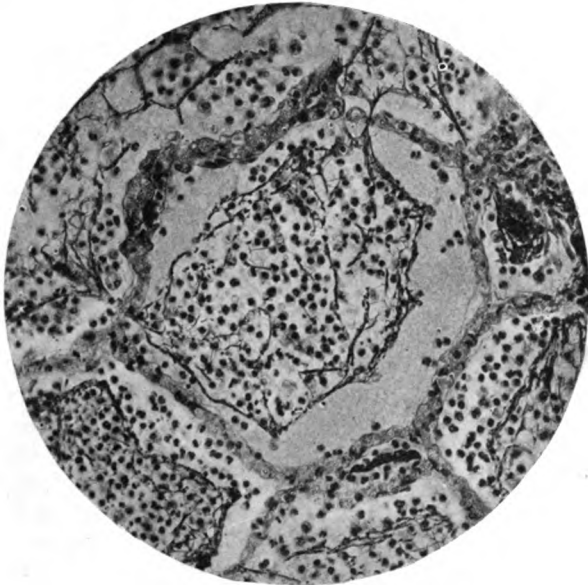


Fig. 8.—Lung. Lobar pneumonia. Alveolus filled with an exudation of serum and polymorphonuclear leukocytes. Much fibrin has formed. At two points it runs through openings in the alveolar wall. M.

The three varieties of membranes can be best distinguished by stating their chief points of difference and giving typical examples of each. It will be noticed that the diphtheria bacillus produces all three types, depending for the most part or entirely on the anatomic structure of the surface on which the toxin of the bacillus acts.

(1) *Fibrinous Exudation (Croupous Inflammation)*.—The necrosis is, as a rule, slight, and often demonstrable only with difficulty. It is limited to the lining epithelium or on a squamous epithelial surface to the upper layers of cells only. The threads

composing the fibrin reticulum are relatively delicate. The fibrin can be stripped off readily and leaves a smooth but usually dull surface. In the stage of organization of this fibrinous exudate, however, the fibrin threads usually thicken up, and the fibrin membrane becomes adherent owing to the growth of blood-vessels and connective tissue into it.

The typical fibrinous exudation is produced by the diplococcus lanceolatus in the lung, the pleural cavity, the meninges, etc. The same type of exudation is often produced by other organisms;

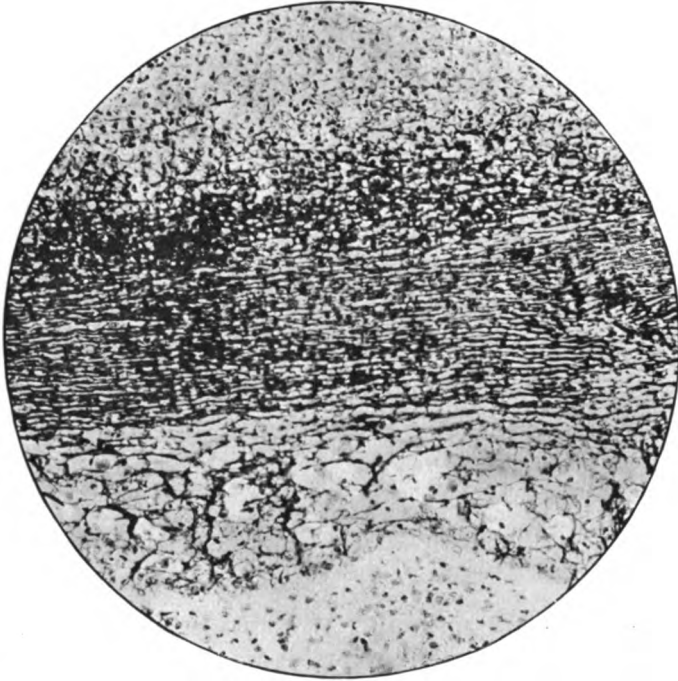


Fig. 9.—Acute inflammation. Diphtheritic (fibrinous) membrane on surface of trachea. Basement membrane appears as a broad pale line. M. and W.

by the diphtheria bacillus in the trachea, and, at the beginning of its action, on the tonsils, the pharynx and elsewhere; by the streptococcus in the lungs and meninges; sometimes by the tubercle bacillus, especially in the meninges.

(II) *Diphtheroid (Pseudo-diphtheritic) Inflammation.* — The necrosis is more extensive than in the simple fibrinous type and involves, on a surface covered with squamous epithelium, several layers of the epithelial cells and may even in places extend a little into the underlying connective tissue. The deeper lying threads

of the fibrin reticulum are coarse and hyaline. This type of membrane is tough and tenacious. It is stripped off with more or less difficulty, and leaves a ragged surface which may show bleeding points.

The diphtheroid membrane is produced by the diphtheria bacillus more often than the anatomically diphtheritic membrane, especially over the tonsils.

(III) *Diphtheritic (Necrotic) Inflammation*.—The necrosis is often the most prominent feature of the lesion and extends deeply into the tissues underlying the epithelial surface. In the gastro-

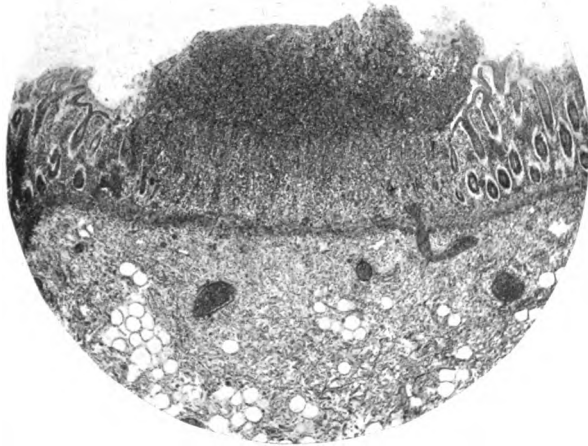


Fig. 10.—Large intestine. Diphtheritic colitis. Necrosis of mucosa, fibrin formation, leukocytic infiltration. M.

intestinal tract it may involve the entire thickness of the mucosa. The necrotic connective tissue and blood-vessels bathed in the exuding serum swell and undergo a fibrinoid change. The fibrin on the surface is often not conspicuous and may be absent owing to maceration and desquamation, or because the injurious agent was so strong and death so sudden that it had not time in which to form. The necrotic tissue resembles a membrane, but it cannot be stripped off.

This type of inflammation is most common in the urinary bladder, the intestine, and the uterus, but may occur elsewhere,

as in the stomach or mouth, and is often complicated with putrefaction.

It may be due to bacteria (dysentery, colon, and diphtheria bacilli) or to chemical agents (carbolic acid, corrosive sublimate).

To sum up: The simple fibrinous exudation shows much fibrin and little necrosis; the diphtheritic, much necrosis and sometimes little or no fibrin; the diphtheroid lies between the two extremes and is less definitely characterized.

3. Purulent Exudation or Suppuration.—Leukocytes are abundant; serum is present in varying quantities, rendering the exudation thick or thin accordingly; fibrin is usually scanty or lacking. Of the leukocytes the polymorphonuclear predominates, and frequently is practically the only one present. Endothelial

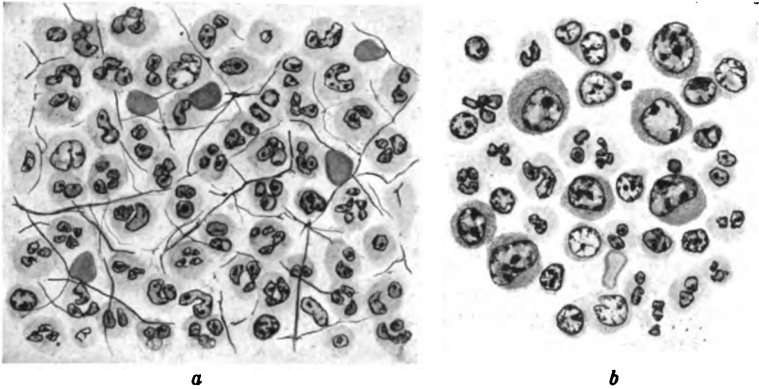


Fig. 11.—Acute inflammatory exudation. *a*, Chiefly polymorphonuclear leukocytes and fibrin; *b*, polymorphonuclear and endothelial leukocytes, also several lymphocytes.

leukocytes are usually present in small numbers and may be fairly abundant. Lymphocytes are sometimes numerous, while eosinophiles are rare.

This type of exudation is commonly called pus, and the cellular elements composing it pus-cells; hence the term pus-cell is generally regarded as synonymous with polymorphonuclear leukocyte, although it is not necessarily so. The leukocytes usually contain much glycogen and numerous fat-droplets.

Purulent exudations in organs and tissues are always combined with necrosis and solution of tissue. When this occurs focally, the resulting lesion is termed an abscess; when it spreads through the lymph-spaces and vessels, it is called diffuse suppuration. An abscess extending to the surface of the skin or a mucous membrane

and continuing to discharge its contents there becomes a fistula or ulcer according to its shape. Small localized collections of pus in the surface of the skin or mucous membranes are called pustules, while suppuration spreading rapidly and extensively through the subcutaneous tissue with solution of it and the overlying epidermis is known as phlegmon.

Suppuration in a pre-existing cavity, such as the pleural cavity or the gall-bladder, is usually termed empyema.

Suppuration is usually due to bacteria, especially to the staphylococcus pyogenes aureus and to the streptococcus pyogenes. Other organisms which may cause a purulent exudation are the gonococcus, the tubercle bacillus, the colon bacillus, the actinomyces, etc. Experimentally it has been shown that suppura-

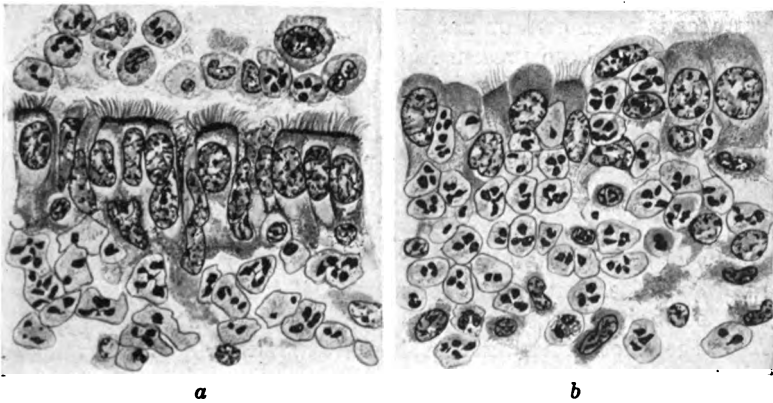


Fig. 12.—Acute inflammation. Oviduct. Migration of polymorphonuclear leukocytes between the lining ciliated epithelium into the lumen of the tube.

tion may also be produced without bacteria by purely chemical reagents, such as croton oil or calomel. Suppuration produced in this way does not spread, however, because the injurious agent cannot multiply and extend peripherally.

The tissue solution in suppuration is generally due to the action of ferments secreted by the polymorphonuclear leukocytes attracted by the injurious agent and the necrotic cells. Sometimes, however, the injurious agent itself causes tissue solution, as, for example, bacillus *aërogenes capsulatus* in infections of muscles.

4. Hemorrhagic Exudation.—Red blood-corpuseles in varying numbers are usually present as the result of diapedesis or of hemorrhage in the three common varieties of acute exudations already described. When they are very abundant and especially when they

form the most conspicuous feature, the exudation in which they occur and which otherwise would be called serous, fibrinous, less often purulent, is commonly termed hemorrhagic. The red blood-corpuscles form a contamination of the exudation and serve no useful function. They are foreign bodies which have to be removed for the most part through the agency of endothelial leukocytes. When they are poured out under arterial pressure, they may mechanically cause much injury which has to be repaired.

The hemorrhagic type of exudation is more common in connection with irritants which affect injuriously the vessel walls. Thus it frequently attends septicemias due to the diplococcus lanceolatus and the streptococcus pyogenes. It also occurs when marked congestion from any cause accompanies an inflammatory reaction.

5. Catarrhal Inflammation.—The exudation from mucous surfaces is often contaminated with mucus and desquamated epithelial cells whose presence is recognized in the term catarrhal inflammation. The term is also commonly used by the Germans as synonymous with simple acute inflammation.

REACTION TO MILD INJURIOUS AGENTS

We have seen that strong injurious agents produce more or less severe injury and a marked inflammatory reaction consisting chiefly of serum (from which much fibrin may form) and of polymorphonuclear leukocytes. Endothelial leukocytes, lymphocytes and eosinophiles usually play a minor part, at least at first. After the reaction has lasted a short time, however, one or another of these other leukocytes may become more abundant as various chemical products attract them.

Other injurious agents exist, however, which cause varieties of inflammatory reaction which are different from those already described. They are best classed as the mild injurious agents. They consist in part of micro-organisms which give rise to the production of weak toxins; in part, of strong toxins from various sources which if sufficiently diluted may act also as mild irritants. Belonging to this group of the mild injurious agents are the typhoid bacillus, the *Leishmania tropica*, the still more slowly acting leprosy bacillus, the diluted toxin produced by the diplococcus lanceolatus, carbon, fat and its products. The tubercle bacillus belongs usually with the mild irritants, but sometimes must be classed with the strong injurious agents. The blastomyces, the oidium, and the glanders bacillus likewise vary between the two groups, but usually are to be regarded as strong injurious agents.

The injury produced by the mild irritants is slight and certainly,

as a rule, cannot be demonstrated morphologically. On the other hand, the inflammatory reaction is usually marked and may itself lead to serious consequences.

The most common inflammatory reaction to mild irritants consists of an exudation and proliferation of endothelial leukocytes which sometimes accumulate in very large numbers. The endothelial leukocyte (to which must be added under certain conditions the attached endothelial cell) seems to be the only one capable, under ordinary conditions, of counteracting the toxins of bacillus typhosus, bacillus tuberculosis, bacillus lepræ, and Leishmania tropica. To the endothelial leukocytes may be added serum (from which much fibrin may form), lymphocytes, polymorphonuclear leukocytes, and rarely eosinophiles.

Other injurious agents attract lymphocytes in large numbers so that focal accumulations of some size may occur in various organs and tissues; for instance, in the heart, kidney, adrenal, and skin. In one type of acute tubular nephritis lymphocytes predominate to such an extent that the lesion has been termed acute interstitial non-suppurative nephritis.

Occasionally, the eosinophile plays an important part in exudations. It may increase greatly in number in the circulation in trichiniasis, for example (20 to 60 per cent), and emigrate to collect around the trichinæ in the muscles. Sometimes it collects in great numbers in other lesions so as to form the predominating leukocyte, thus often in the scirrhus type of lymphoblastoma, and occasionally in carcinoma of the cervix uteri.

The inflammatory reactions to mild irritants are usually not classified as such (endothelial or lymphocytic reaction) but etiologically. Thus we speak of typhoid lesions of the intestine, acute miliary tuberculosis, leprosy, Aleppo boil. On the other hand, we say acute intracapillary or capsular glomerulonephritis, although the lesion in the one instance may consist only of endothelial cells or leukocytes, in the other only of proliferated epithelial cells.

It is not necessary to go into details at this point in regard to these different varieties of exudation produced by mild injurious agents. They will be taken up at length in connection with the special injurious agents which produce them. Here it is only important to appreciate the relation of these inflammatory reactions to those which have been described as produced by the strong injurious agents.

REACTION TO INJURIOUS AGENTS WITHIN THE CIRCULATION

Some injurious agents act only outside of the circulation (tænia solium), others only within it (plasmodium malaris). Most infectious agents are found chiefly in one situation or the

other, but occur frequently in both (staphylococcus pyogenes aureus, tubercle bacillus).

The injury and reaction produced by injurious agents outside of the circulation have been described. Those produced within the circulation are rarely striking (destruction of red blood-corpuscles in malaria, for instance).

Nature's means for defense are nearly all present in the blood. Those leukocytes which are most effective in counteracting organisms or toxins or both are increased in number, thus the polymorphonuclear leukocyte in staphylococcus pyogenes aureus septicemia, the endothelial leukocyte (especially in the portal circulation) in typhoid fever, the lymphocyte in whooping cough, the eosinophile in trichiniasis. The chemical constitution of the blood plasma may be altered and new substances be produced in it (typhoid antitoxin), probably through the action of the leukocytes best fitted to counteract the injurious toxin. The bone marrow may become hyperplastic. The spleen may increase in size owing to the accumulation of numerous leukocytes in it (polymorphonuclear leukocytes in streptococcus pyogenes septicemia, endothelial leukocytes in typhoid fever).

The endothelial cells lining the blood-vessels often play an important part, acting in many respects like the endothelial leukocytes which are derived from them. They take up many kinds of organisms (tubercle bacillus, leprosy bacillus, *Leishmania tropica*). Some they destroy; in other instances they act as helpless hosts for the parasites multiplying within them. Sometimes they proliferate and desquamate fairly rapidly, thus causing increase in the number of endothelial leukocytes (typhoid fever, miliary tuberculosis).

While these points may seem of minor consideration in comparison with the gross lesions caused by exudations, it is important to bear them in mind because they help in the understanding of certain lesions. Thus, in generalized miliary tuberculosis each separate tubercle starts in a blood-vessel, usually a capillary, as the result of a tubercle bacillus being incorporated by one of the lining endothelial cells. The cellular reaction to the toxin derived from this tubercle bacillus and its descendants consists usually of nothing but an accumulation of endothelial leukocytes, first in the capillary, where the bacillus is lodged, then in the adjoining capillaries and lymph-spaces. By occlusion of the blood- and lymph-vessels, nutrition is cut off, and first the tissue cells and then the endothelial leukocytes undergo necrosis. In order to understand the lesions produced by the tubercle bacillus or any other injurious agent it is necessary to know nature's reaction to it, that is, what means she employs against the agent, whether it

is located in the blood, in a lymph-space or vessel, or in a cavity lined with epithelium or mesothelium.

No attempt will be made here to go farther into this subject from the general point of view, but under some of the special infectious agents the reaction which each causes in the circulation will be described.

REPAIR

Introduction.—Repair is a broad term applied to all the processes following the injury and exudation caused by an injurious agent. It includes removal and encapsulation of foreign bodies of all sorts, the organization of fibrin and lime salts, and the regeneration of cells and parts of cells.

The various processes included under repair are necessarily discussed separately. It must not be imagined, however, that they occur in nature in the order in which they are taken up and after the exudation has ceased. Instead, all the various steps described under inflammation (including injury, exudation, and repair) are usually more or less intimately combined and therefore confusing to the beginner. It requires long training and a thorough acquaintance with all the various processes to be able to disentangle them, and to recognize the significance and relative importance of each.

Under repair it is necessary to consider in due order the means employed to get rid of foreign bodies of every kind, the organization of fibrin, less often of lime salts, the regenerative ability of the different types of cells when some of them are destroyed without injury to the adjoining blood and connective tissues, healing or tissue repair when all cells in a given area undergo necrosis, and, finally, healing or tissue repair in certain special organs and tissues.

FOREIGN BODIES

Toxic substances derived chiefly from injurious agents, but also to some extent from the injured and necrotic tissue, are counteracted chemically so far as it is possible by substances already contained in the blood plasma, or manufactured by the leukocytes. Besides the toxic substances, however, which must be neutralized or excreted and the serum which must be absorbed through the lymphatics, there often remain numerous bodies of various sorts which must be regarded as mild types of irritants, and which have to be got rid of before regeneration of cells can result in more or less complete repair of a lesion. Some of these different kinds of foreign bodies are derived from the injurious agents, some from the injured tissues and from hemorrhage, while still others are to be regarded as pathologic products.

The following list will give an idea of the kind of foreign bodies which sometimes require removal from inflammatory lesions before perfect healing can take place:

Living and dead bacteria; capsules of pneumococci and of Friedländer's bacilli; colonies and clubs of actinomycetes; blastomycetes; fats from tubercle and leprosy bacilli; sodium urate crystals; sutures; hairs.

Necrotic cells and the intercellular products of some of them, such as collagen and elastic fibrils, cartilage and bone; myelin from nerve-sheaths; fat derived from necrotic cells of all kinds and especially from necrotic fat cells.

Secretions and pathologic products of various kinds, including fat and its derivatives; fatty acid and cholesterin crystals; bile; lime salts; hemorrhage and the pigments derived from the hemoglobin; colloid; amyloid; fibrin.

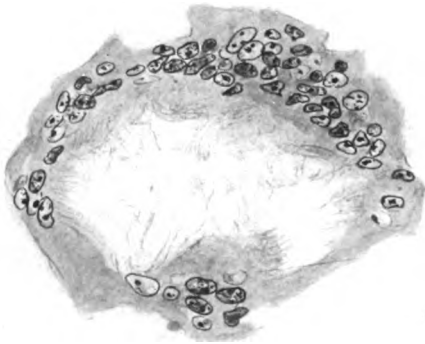

Fig. 13.—Repair. Foreign body giant-cell formed around fat crystals.

For removing foreign bodies nature uses apparently the activities of only the polymorphonuclear and endothelial leukocytes. These agents act by means of ferments which they secrete and which are able to dissolve or digest many of these foreign bodies.

Some of the foreign bodies, such as living and dead bacteria and their capsules, they incorporate and digest; others, such as necrotic cells, they invade or surround and dissolve. The two types of leukocytes, however, are not able to perform exactly similar functions. Both can incorporate bacteria although usually not the same kinds; and both may invade or surround and dissolve necrotic cells; but only the endothelial leukocyte takes up red blood-corpuscles and carbon, for instance, or attempts to dissolve cholesterin crystals or hairs or cornified epithelium.

Foreign Body Giant-cells.—When an endothelial leukocyte finds difficulty in dissolving a substance, as, for instance, lime or certain fat products or the blastomyces, it frequently fuses with other endothelial leukocytes to form a multinucleated mass of cytoplasm, commonly termed a foreign body giant-cell. If the

foreign body is too large for one leukocyte to incorporate (cholesterin crystals, hairs), one or more giant-cells are formed which surround it or plaster themselves on its surface.

Foreign body giant-cells are usually numerous in the lesions due to the tubercle bacillus and the blastomyces; also in many lesions involving bone. Frequently, they are present in large numbers around fat products, especially cholesterin crystals (old healing abscesses, chronic mastitis); also around elastic fibrils (healing furuncle); hairs (pilonidal sinus, inflamed dermoid cyst); cornified epithelium (inflamed wen, epidermoid cancer); urate of sodium crystals (gout).

Parasitism.—Many micro-organisms incorporated by leukocytes are not destroyed. Instead, they seem under ordinary

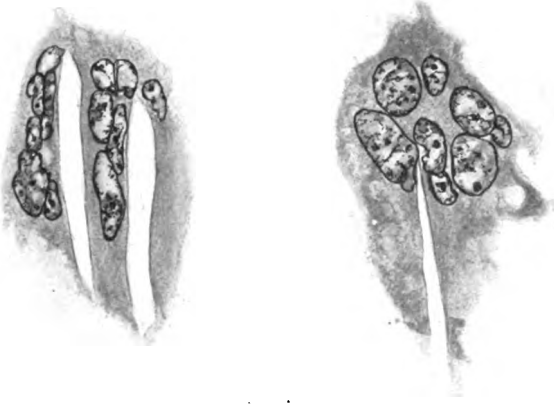


Fig. 14.—Repair. Foreign body giant-cells formed around cholesterin crystals.

conditions to flourish and multiply abundantly as parasites within the cells. Thus the gonococcus inhabits the polymorphonuclear leukocyte and the leprosy bacillus and the *Leishmania tropica*, usually the endothelial leukocyte and also the endothelial cell. The organisms are frequently present by dozens in these cells which they in turn do not destroy. Possibly the leukocytes neutralize to some extent the toxins eliminated by the organisms.

Necrotic Tissue.—Necrotic cells are usually readily dissolved by polymorphonuclear and endothelial leukocytes. Sometimes one does the work, sometimes the other; occasionally the two together. The reason for the presence of the one or the other leukocyte seems to depend, in certain instances at least, on the nature of the injurious agent which destroyed the cells.

Removal of necrotic cells on a large scale and in a comparatively short time is seen in the early stage of acute yellow atrophy of the liver. In this lesion the circulation of the organ is not interfered with. But in an infarction of the kidney, for example, where the blood-vessels and connective tissue are all destroyed as well as the epithelial cells, although the process starts actively enough at the periphery of the lesion, it soon quiets down and requires a very long time to transform the infarction into a scar.

In several forms of tumors, but especially in melanomas, the cells at some distance from the blood-vessels frequently undergo necrosis which may be very extensive. The necrotic cells rarely attract any leukocytes, probably because they very slowly dissolve and disappear by absorption leaving the blood-vessels surrounded by thin sheaths of living tumor cells.

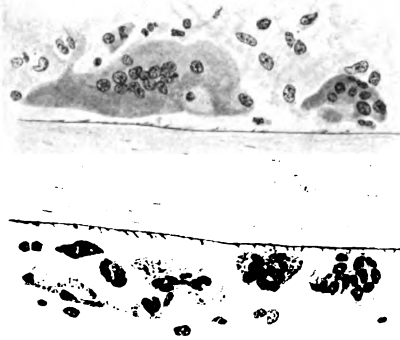


Fig. 15.—Repair. Foreign body giant-cells formed around a hair in a pilonidal sinus.

Collagen fibrils are more easily dissolved than elastic fibrils. The latter often require the long-continued action of foreign body giant-cells.

Bone is exceedingly difficult to dissolve. Even minute particles lead to the formation of giant-cells. Large masses may persist for years or indefinitely, unless removed mechanically.

Myelin and the fat derived from it are taken up by endothelial leukocytes which collect largely in the lymph-spaces around and within blood-vessels. There they apparently persist for a long time while they digest the fat.

Fat is also derived from necrotic cells and leukocytes and especially from necrotic fat-cells. In fat necrosis endothelial leukocytes collect and multiply by mitosis in numbers around the fat formerly contained in fat-cells. They often form a regular single or double row of cells which have been mistaken for regenerating fat-cells.

When fat collects in considerable quantities, as in old abscesses or in the ducts in chronic mastitis, it frequently undergoes chemical changes, giving rise to fatty acid and cholesterol crystals which in time may lead to the formation of numerous giant-cells.

Masses of inspissated bile in the bile capillaries of the liver

often escape through the surrounding wall of liver cells and are taken up by endothelial leukocytes and gradually digested.

Rarely colloid in the thyroid gland and amyloid in, for instance, the wall of the urinary bladder become foreign bodies and lead to the formation of numerous giant-cells.

Red Blood-corpuscles.—When red blood-corpuscles escape into the tissues through diapedesis or hemorrhage, one of two things may happen to them: They may be incorporated by endothelial leukocytes or they may disintegrate and set free their hemoglobin. From the hemoglobin thus set free hematoidin crystals may form in the same way that they may in blood preserved in a test-tube. Hematoidin is, therefore, not due to cell activity. Chemically it does not respond to the ordinary tests for iron. More often all or most of the hemoglobin gradually diffuses into the surrounding tissues, where it may in part at least be precipitated in the form of irregular granules.

The hemoglobin in the red blood-corpuscles incorporated in endothelial leukocytes is transformed by cell activity into hemosiderin, a collective term applied to pigments which give the iron reaction. The hemoglobin diffused from the disintegrated red blood-corpuscles is taken up also by endothelial leukocytes through imbibition or by phagocytosis, and transformed in the same way into hemosiderin. In the course of a long time (months to years) the hemosiderin is decolorized and digested and finally disappears from the cells. When carbon is also taken up by the endothelial leukocytes, as frequently happens in the lungs, the hemosiderin is deposited around it.

Red blood-corpuscles are more likely to be taken up by endothelial leukocytes when they are present in small numbers only. When the hemorrhage is large, the leukocytes can necessarily attack only the periphery of it. Under these conditions the blood clots, the red blood-corpuscles gradually disintegrate and the hemoglobin is set free, the fibrin stimulates organization and the blood from the hemorrhage is finally replaced by pigmented scar tissue. If the organization is incomplete, as frequently happens in the brain, a cyst eventually remains containing clear fluid, but with pigmented endothelial leukocytes in the walls.

There still remains one foreign body, namely fibrin, which is the most important of all, and requires separate consideration. It may be derived from exudations or from hemorrhage. It is a pathologic product, often useful as in stopping hemorrhage, but frequently causing great trouble.

ORGANIZATION OF FIBRIN

Fibrin does not of itself attract leukocytes unless it has undergone chemical changes. When it occurs in lesions into which numerous polymorphonuclear leukocytes are attracted by the injurious agent, as in fibrinous pneumonia, it is usually digested at least in part by the ferments which the leukocytes set free. Otherwise it persists and leads to what is termed organization of fibrin. This condition regularly occurs in the pleural and other cavities where the leukocytes can affect only the surface of the fibrin.

When fibrin occurs in suitable situations, it is quickly covered over with a layer of endothelial cells (thrombi in blood-vessels), or of epithelial cells (alveoli of lung, tubules of kidney). It exerts, however, a very specific attraction for the fibroblast which proliferates and grows into the fibrin and replaces it. In many situations the fibroblast is preceded or accompanied by vascular endothelium in the form of capillaries which arise only from capillaries; but in other situations the fibroblast works alone.

This replacement of fibrin by connective tissue, vascularized or not, is termed organization of fibrin. The process can be studied in a variety of situations, but three are sufficient fully to illustrate what occurs.

Pleural Exudation.—The fibrinous exudation on the surface of a serous cavity offers the best and most common material for the study of organization of fibrin. Various stages of the process are required and usually can be obtained. It is generally most convenient to select the pleural exudation on the surface of the lung.

The organization begins after the fibrin has existed about one week. It consists of an outgrowth of capillary blood-vessels followed by fibroblasts. The new vessels sprout from the superficial capillaries in the subpleural tissue and extend into the fibrin. They anastomose laterally with each other so as to form loops. This enables the blood which comes out in some of the vessels to return through others. Although the new-formed capillaries are very thin walled their lumina are relatively large.

The fibroblasts of the subpleural tissue proliferate and invade the fibrin rather slowly. A few extend along the capillaries and form a supporting sheath for them, but most of the fibroblasts are arranged in layers parallel with the pleural surface and in this way gradually encroach on the fibrin and replace it.

The fibrin does not attract leukocytes of any sort. It gradually disappears as the vascular endothelium and the fibroblasts advance. Apparently, it is dissolved and utilized as nourishment by these two varieties of cells, and this alone may explain its stimulating effect on these cells.

If the visceral and parietal layers of fibrin in the pleural cavity are in contact, the organizing cells may eventually meet and combine so as to cause obliteration of the pleural cavity. Fat products and lime salts in the fibrin sometimes lead to the formation of foreign body giant-cells.

Any mesothelial cells not destroyed multiply and cover the walls of the spaces in which they lie; thus, they may appear eventually as gland-like cavities in the dense pleural adhesions or covering sheet and string like adhesions due to the organization

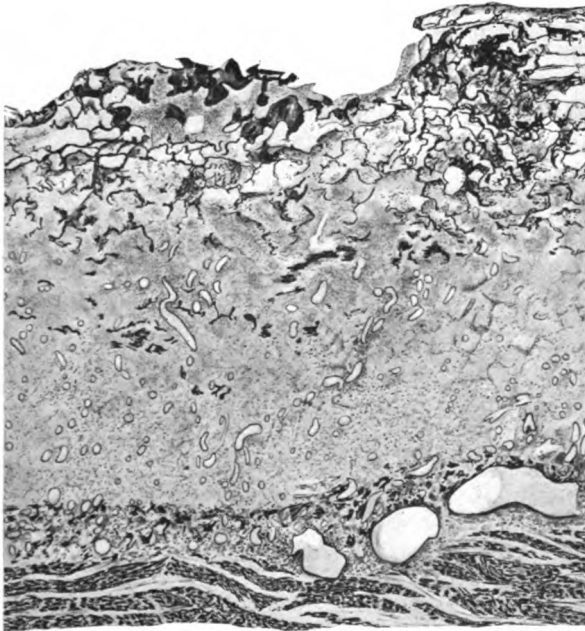


Fig. 16.—Heart. Organizing pericarditis. Fibrin still present along surface and beneath it.

of strands of fibrin originally kept apart by the presence of fluid which had not been absorbed.

In time the collagen fibrils produced by the fibroblasts contract, the blood-vessels to a large extent disappear, and the only reminder of the fibrin left is a thin layer of dense fibrous tissue.

Pneumonic Exudation.—Some of the fibrin on the surface of a pleural exudation is probably dissolved by the ferments derived from the leukocytes attracted by the infectious agent. In the alveoli and bronchi of the lung in pneumonia this dissolution of

the fibrin is the usual occurrence. The fibrin is dissolved either completely or to such an extent as to set it free from the walls of the air-spaces and thus permit it to be coughed up.

In certain instances, however, more or less of the fibrin remains attached in place and after a certain length of time (one to two weeks) undergoes organization. Its surface is first covered over with a layer of epithelial cells. Then capillary vessels and fibroblasts grow out from the walls of the alveoli and the bronchioles and organize it, replacing it from without in. The organization starts at the points where the fibrin is attached to the walls, especially around the minute holes in the alveolar walls, through which the fibrin runs from one alveolus to the next.

Whenever the epithelium has been completely destroyed, organization leads to obliteration of the air-spaces, and the transformation of the lung into solid fibrous tissue.

Fibrin is organized in the pericardial and peritoneal cavities in the same way as in the pleural cavity. In the meninges the changes are less easily followed, because the fibrin is in the lymph-spaces of the pia instead of being on a well-defined surface, but the process is essentially the same. In blood-vessels, however, and on the valves of the heart the process of organization is a little different.

Blood-vessels: Thrombi and Emboli.—In certain situations fibrin is organized by the action of fibroblasts only. The process can be studied best in the organization of thrombi and emboli within vessels. The fibrin is usually quickly covered over on the free surface by a layer of endothelial cells. The fibroblasts grow into the fibrin at the points where it touches the wall. If the thrombus is more or less spherical they organize its periphery first, and then gradually extend toward its center. If the thrombus is irregular in shape, the endothelial cells on the surface dip into all the depressions and slits, and line them so that on section it would seem as if new blood-vessels had formed in the organized thrombus, but there seems to be no evidence of so-called canalization of a thrombus taking place except in this way, unless there has been an infectious process of the vessel wall as a result of which blood-vessels have grown in from the adventitia.

Similar organization of fibrin by fibroblasts alone is common on the inner surface of the aorta and leads to the formation of the elevated fibrous plaques, so often found there. Fibrin on the surface of the heart valves is usually organized in this same way, and the process occurs also on the surface of the liver and spleen. In all these situations it is due in part at least to the condition of the tissue adjoining the thrombus; it is non-vascular at least in the blood-vessels and heart valves and over the spleen.

Fibrin seems to act as a direct stimulus (food?), especially to the fibroblasts, less often to vascular endothelium.

Organization of Lime Salts.—Lime salts occur normally in the intercellular substance of bone. If the bone cells are killed, the intercellular substance becomes a foreign body. Two different things may happen to it. It may be gradually dissolved and removed by osteoclasts (the usual process following osteomyelitis), or osteal cells may apply themselves to its surface and slowly

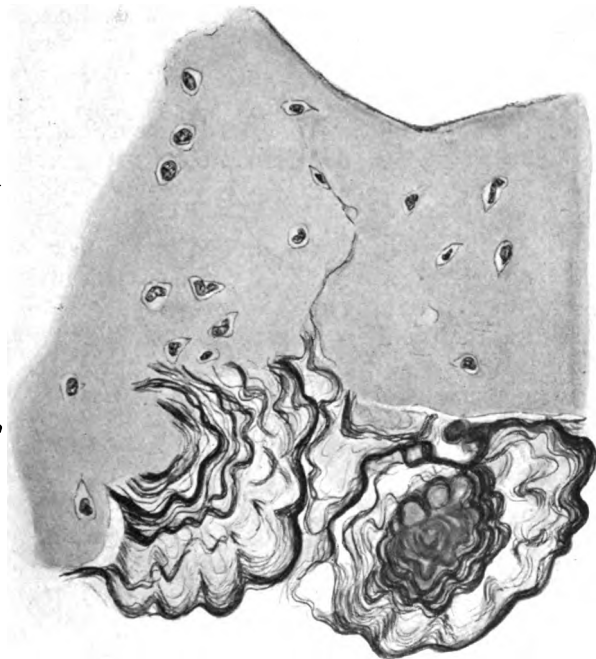


Fig. 17.—Cerebellum. Calcified corpora amylacea being transformed (organized) by fibroblasts into bone.

appropriate the lime salts to their own use. In this way they gradually replace or organize the calcified intercellular substance left by necrosis of the bone cells. They do this under sterile, non-toxic conditions, not when the bone cells have been destroyed by an infectious process.

This process of organization of the calcified matrix of dead bone is made use of to some extent by the surgeon in the operation of transplanting bone in order to fill in defects of bone, or to furnish rigid support during the stage of repair. The cells of the trans-

planted bone always die, but the calcified matrix serves a useful purpose by furnishing a framework on and within which the osteal cells lay down new bone while utilizing, to some extent, at the same time, the lime salts already at hand.

Under pathologic conditions lime salts are often deposited in the body; for instance, in necrotic tissue, in hyaline material of various sorts, and occasionally in masses of old fibrin. They frequently exert some effect on adjoining fibroblasts, in consequence of which these cells slowly invade and organize the lime salts, depositing them in their own intercellular substance and thus transforming themselves into true bone cells. As a result of this process true bone frequently replaces, in part or entirely, lime salts deposited in necrotic cells, etc., as, for example, in the walls of sclerosed arteries, in old hemorrhages in the eye, and in various tumors including gliomas of the central nervous system.

REGENERATION OF CELLS

Regeneration is a narrow term applied to the new formation of cells to replace cells of the same type which have been destroyed. The term is applied also to the new formation of parts of cells.

Cells multiply or proliferate by so-called indirect division, a method termed mitosis or karyokinesis. It is probable that all progressive new formation of cells in the human body takes place in this way. Direct division of cells, amitosis, is evidence of a retrograde change. Budding and direct division of nuclei without division of the cytoplasm is to be regarded as a retrograde process, except in the case of regeneration of parts of muscle-fibers which have been destroyed.

Multiplication of certain types of cells is constantly taking place in the body because many of these cells are being used up under normal conditions and have to be replaced. When it takes place under normal conditions, it is called physiologic regeneration; if it occurs under abnormal conditions, it is termed pathologic regeneration.

Physiologic regeneration is always perfect; the organ or tissue is kept intact, in perfect condition. Pathologic regeneration is usually much more extensive and rarely so complete. It succeeds best when the accompanying blood-vessels and connective tissue are uninjured, as in central necrosis of the liver, but sometimes even there it fails completely.

The cells with slightly differentiated cytoplasm regenerate better than those in which it is highly differentiated.

Regeneration of cells is more active in youth, at least in some types of cells, than in old age.

The cells which have to be replaced constantly under normal

conditions in order to maintain a certain cell equilibrium in the body are the red blood-corpuscles, the various leukocytes, the epithelial cells of the epidermis including those of the hair follicles, etc., the epithelial cells of the gastro-intestinal tract, of the genital organs, and of various other organs and tissues. The regeneration may take place in the immediate neighborhood of the destroyed cells (epithelium) or at a distance (erythroblasts, lymphocytes).

Other types of cells, such as fibroblasts and neuroglia cells, do not multiply at all normally, although endowed with great powers of regeneration which become evident under pathologic conditions. Still other cells like the ganglion cells have no powers of regenerating new cells and if destroyed are never replaced.

Cells proliferate only to replace cells of their own kind which have been destroyed. It is commonly taught that when the highly differentiated, so-called parenchymatous, cells of an organ or tissue are destroyed, blood-vessel endothelium and connective-tissue cells proliferate and fill up the space formerly occupied by them. There is no evidence for this teaching and much to the contrary. For example, in central necrosis of the liver lobule only the liver cells are destroyed. As a rule, complete regeneration of the liver cells occurs in from one to two weeks. If for any reason it does not occur, then, after the necrotic liver cells have been removed by the action of leukocytes, the blood-vessels collapse, the connective tissue contracts and thickens up, but the cells do not proliferate. The liver as a whole is diminished in size. The same condition holds in the heart when only the muscle-cells are destroyed as the result of the effect of toxins or of nutritive disturbances. Likewise in the central nervous system, if only the ganglion cells or their axis cylinder processes are destroyed, the neuroglia cells do not proliferate on that account. They multiply only to replace cells of their own kind which have undergone necrosis, or because they have been in some other way stimulated. Following necrosis of parenchymatous cells, if the collagen or neuroglia fibrils included in the area are unable to contract, the spaces left after absorption of the necrotic cells are filled with fluid.

In all these situations (liver, heart, central nervous system), however, marked proliferation of the fibroblasts and neuroglia cells and to a less extent the vascular endothelium takes place if they themselves have at the same time been destroyed.

Regeneration of cells often takes place in excess of the number of cells destroyed. Thus young blood-vessels and young connective tissue are regularly reproduced greatly in excess of actual requirements. Many of the new-formed cells later disappear, leaving only enough to care for the fibrils which have been produced. It also occurs, for example, in extreme cases of central

necrosis of the liver (acute yellow atrophy) where all the liver cells in many lobules are destroyed. Under these conditions excessive regeneration takes place from the liver cells remaining in other lobules so as to reform as much liver tissue as possible. As a result, while new lobules are not formed, the lobules in the regenerated areas are often much larger than normal. This excessive regeneration is particularly likely to occur in children, but it may also occur in adults, for instance, in the liver in alcoholic cirrhosis; some of the collections of regenerated liver cells may resemble adenomas.

Regeneration of cells on a large scale is best seen, perhaps, in the liver following extensive central necrosis, and in the kidney after marked tubular nephritis. In both these instances practically only epithelium is destroyed; blood-vessels and connective tissue remain intact. On the other hand, proliferation of fibroblasts and of vascular endothelium is found abundantly where they themselves have been destroyed, as in the granulation tissue of wounds, abscesses, etc.

The power of regeneration possessed by the different types of cells will be referred to briefly.

Epithelium.—The regenerative ability of epithelial cells is well marked and in some situations, such as the epidermis and the gastro-intestinal tract, is in constant evidence under normal conditions as shown by the presence of numerous mitotic figures. It is most frequently studied experimentally in lesions of the cornea where the extent and duration of the lesion can be perfectly controlled. Ulcers of the skin following burns or other destructive agencies afford excellent opportunities to study the rate at which the epidermis can grow in and cover over a denuded surface. Typhoid and tuberculous ulcers of the intestine sometimes offer good examples of the effort of the lining epithelium to replace the epithelial cells which have been destroyed, or as it is often stated, to cover over a bare surface.

Regeneration of epithelial cells in two organs is described in illustration of the process.

Liver.—Liver cells possess great powers of regeneration. Following extensive necrosis of the liver cells in the centers of every lobule complete regeneration will take place in from one to two weeks. The same condition can be shown experimentally in animals by administering chloroform and causing central necrosis of the liver.

Liver cells regenerate entirely from liver cells; not from bile-duct epithelium. If all the liver cells in a lobule are destroyed, that lobule will not be reformed. The bile-duct epithelium will multiply to some extent and elongate the ducts but will not form liver cells.

Mitotic figures in hepatic cells are occasionally found in normal-looking livers; they probably indicate that there has been some destruction of liver cells. In one apparently normal liver they were very numerous. The same condition was in one instance found in the adrenal glands following diphtheria.

In central necrosis of the liver the blood-vessel endothelium and the connective-tissue cells are unaffected; hence they do not multiply, even if for any reason the liver cells fail to regenerate. But following infection extending along the bile ducts, where the connective-tissue cells are often destroyed as well as the liver cells, the fibroblasts multiply actively and much fibrous tissue is formed.

In the extensive lesions of this type known clinically as acute yellow atrophy the liver may diminish to one-half or even one-third its original size; yet if necrosis has not been complete and if liver cells remain in each lobule, more or less complete regeneration may occur.

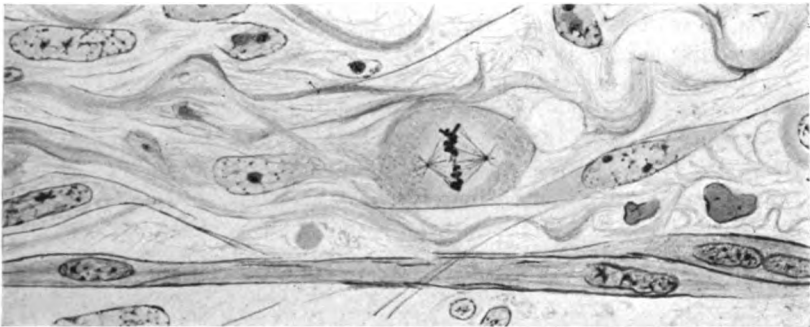


Fig. 18.—Repair. Mitosis of fibroblast in wall of chronically inflamed oviduct.

Kidney.—Regeneration of renal epithelium is very active following necrosis of the cells lining the tubules. Mitotic figures may be quite numerous. The cells at first are undifferentiated; they are low in type and stretch along the walls. The cytoplasm, like that of most young cells, tends to be basophilic. Later, these cells become fully differentiated renal epithelium. These regenerative changes occur most commonly in the convoluted tubules. No new tubules are ever formed; the pre-existing ones are simply relined.

In certain infectious processes in the kidney necrosis of all the tissue cells and abscess formation occur. As a result, marked proliferation of fibroblasts takes place and much sclerosis may result.

Fibroblasts; Connective-tissue Cells.—The ability of fibroblasts to regenerate is marked. Mitotic figures are often numerous; fibrogia and collagen fibrils are actively produced and in certain situations elastic fibrils.

Fibroblasts regenerate only when fibroblasts have been destroyed, never to take the place of parenchymatous (the more highly differentiated tissue) cells which have disappeared. Usually the cells appear to be regenerated in excess of actual needs because many of them later disappear.

Endothelial Cells; Vascular Endothelium.—New blood-vessels arise as capillaries and take their origin from capillaries by proliferation of the lining endothelial cells. The cells multiply by mitosis and send out at first cytoplasmic processes.

The cells continue to multiply and grow out in the same direction, forming narrow columns of cells. The columns of cells tend to unite laterally so as to form loops. The cells in the columns and loops soon arrange themselves so as to inclose a lumen which extends out from the original capillary and brings blood to nourish the young cells. Later, many of these newly formed capillaries disappear. Others persist, and may develop into larger vessels, but never into well-formed arteries and veins.

Chondroblasts; Cartilage Cells.—Cartilage cells apparently have no power of regeneration, because, like the red blood-corpuscle and the polymorphonuclear leukocyte, they are an end-product of cell activity and are incapable of mitosis. The same holds true for bone cells.

Cartilage cells are newly formed from chondroblasts which are fibroblasts endowed with the property of secreting chondromucin. This accounts for the frequent presence of collagen and elastic fibrils in cartilage. Cartilage is always surrounded with a layer of these cells, known as the perichondrium.

Bone; Osteoblasts; Bone Cells.—Under normal conditions and even in the fetus, bone is being constantly torn down and built up. The ground substance is dissolved by osteoclasts and reformed by osteoblasts or by osteal fibroblasts. The osteoclast is a foreign body giant-cell, formed by fusion of endothelial leukocytes. The osteoblast is a modified osteal fibroblast and represents an intermediate stage between the fibroblast of the peri- and endosteum and the bone cell. This osteal fibroblast is endowed with the property of secreting osseomucin in addition to collagen and elastic fibrils. Osseomucin is a homogeneous ground substance which binds the collagen and elastic fibrils together and has the property of attracting lime salts. This homogeneous matrix in which the lime salts are to be deposited is known as osteoid material.

The osteal fibroblast also has inherent in it the property of producing chondromucin, and thus of becoming transformed into a cartilage cell, as sometimes occurs in the healing of fractures of bones.

Bone cells are an end-product, and have lost the power of proliferation so that they play no part in the regeneration of bone, which has to take place entirely from the osteal fibroblasts. These cells form a thin layer around all bone and are known collectively from their situation as the periosteum and endosteum.

The collagen and elastic fibrils in bone can be demonstrated by special staining methods. Under ordinary conditions they are masked by the homogeneous ground substance, osseomucin.

Neuroglia Cells.—They are capable of active regeneration. In many ways they resemble fibroblasts. Under certain conditions regeneration is active and mitotic figures numerous. The new-formed cells are usually large and have much cytoplasm. They produce neuroglia fibrils in abundance. Later, many of the cells may atrophy, but the fibrils persist.

Neuroglia cells regenerate only when neuroglia cells have been injured and destroyed, never simply because ganglion cells have atrophied and disappeared.

Smooth Muscle-cells.—They show little or no power of regeneration. In repair of smooth muscle no new smooth muscle-cells are formed. The connective-tissue cells injured at the same time proliferate and form scar tissue which fills in the space left by the necrotic muscle-cells.

On the other hand, smooth muscle-cells are capable of marked hypertrophy, as shown in the pregnant uterus and in the thickened wall of the hypertrophied urinary bladder.

Blood-corpuscles.—Extensive hemorrhage may lead to great loss of all the cellular elements of the blood. Infectious processes of different sorts often cause large increase in the numbers of certain leukocytes in the circulation, of polymorphonuclear leukocytes in suppurations, of eosinophiles in trichiniasis, of lymphocytes in whooping-cough, and to a less extent of endothelial leukocytes in typhoid fever. Many of these leukocytes emigrate into the tissues and are there destroyed. The normal cell equilibrium in the blood must be maintained by the formation of new cells.

Regeneration of the polymorphonuclear leukocyte, of the eosinophile and of the mastcell takes place in the bone marrow from the three types of myelocytes present there; namely, the neutrophilic, acidophilic, and the basophilic myelocytes.

The red blood-corpuscles are formed by the erythroblasts, and the proper proportion of blood platelets in the circulation is

maintained by the cytoplasmic disintegration of the megakaryocytes.

The endothelial leukocytes in the blood are regenerated chiefly from the endothelial cells lining the blood-vessels, possibly also to some extent from those lining lymph-vessels.

The lymphocytes are produced in lymphoid tissue everywhere, but chiefly in the lymph-nodules of the lymph-nodes, the spleen, and the gastro-intestinal tract.

Often, owing to the activity of regeneration of the various leukocytes, the red bone marrow spreads throughout the shafts of the long bones from which it is usually more or less completely absent in adult life. In like manner, when the production of lymphocytes is unusually active the lymphoid tissue, and especially the lymph-nodes, may increase considerably in size owing to the cellular hyperplasia.

Under certain conditions regeneration of some of the elements of the blood may occur in the circulation.

REGENERATION OF PARTS OF CELLS

Probably most cells are able to rebuild parts of their cytoplasm which have been destroyed or mechanically removed. In only two types of cells (nerve- and muscle-cells) is this form of regeneration of sufficient significance to deserve attention here. The new formation of the axis cylinder processes of nerve-cells is of the greatest importance clinically, while the regeneration of parts of muscle-fibers is of much less value, although histologically interesting.

Nerve-cells.—Nerve-cells do not regenerate. If they undergo necrosis, they are not replaced. If, however, the axis cylinder process of a nerve-cell is destroyed, the cell is able in time to reproduce or regenerate it.

The process of nerve regeneration is best studied experimentally in animals. The general results obtained by this method of study are borne out by the clinical results obtained in man.

The results obtained experimentally may be summarized briefly as follows:

If a porous foreign body is inserted into an incision in the brain thus injuring nerve tissue, both axis cylinder processes and neuroglia cells will grow into the cavity.

If peripheral nerves are sectioned, all of the peripheral part of every axis cylinder beyond the point of section degenerates quickly. On the proximal side of the cut each axis cylinder degenerates back at least to the first node of Ranvier, and sometimes as far as to the sixth.

Union of the cut ends of a nerve by means of suturing will

not, therefore, restore function by bringing about direct and immediate union of the severed ends of the axis cylinder processes. It only aids the slow process of regeneration by furnishing a favorable and direct path for the outgrowing nerves.

Following section of a nerve each axis cylinder process gradually regenerates by growing out from the proximal end and making connections, by means of new nerve terminations, with the cells it formerly supplied.

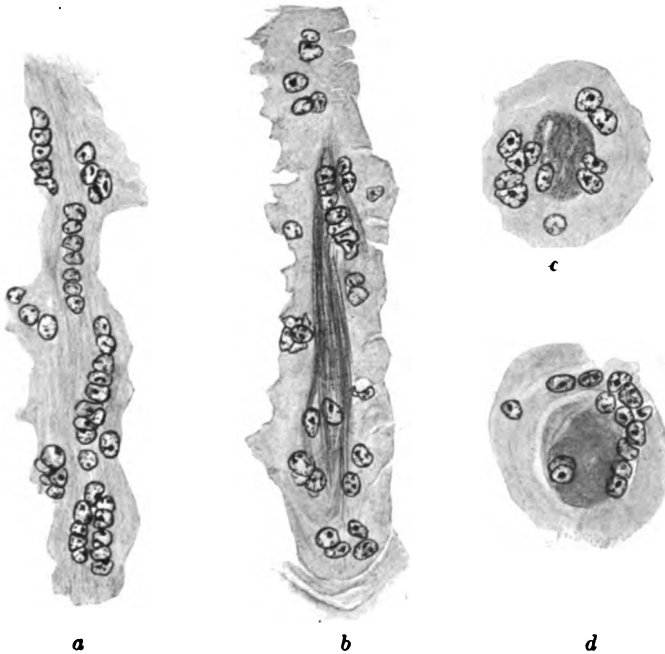


Fig. 19.—Regeneration of skeletal muscle-fibers. Multiplication of muscle nuclei by direct division; formation of new cytoplasm; migration of nuclei into it. *a* and *b*, longitudinal sections; *c* and *d*, cross-sections.

Following amputation of an extremity the cut nerves usually degenerate slowly back to their nerve-cells which degenerate and atrophy. Sometimes, however, following amputation the nerves, instead of degenerating at once, attempt to regenerate the part destroyed. As their extension is interfered with by the amputation scar they form a nodular mass of interlacing nerves which is usually (but incorrectly) called by the surgeon an amputation neuroma.

Muscle-fibers.—The striated skeletal muscle-fibers are not simple mononucleated cells, but spindle-shaped syncytial masses

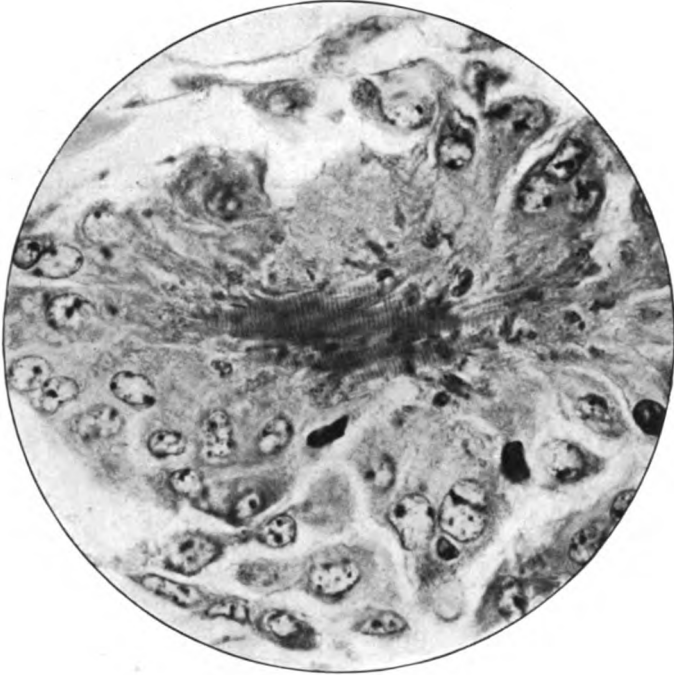


Fig. 20.—Repair. Regeneration of skeletal muscle-fiber. New cytoplasm forming around part of fiber not destroyed. M.

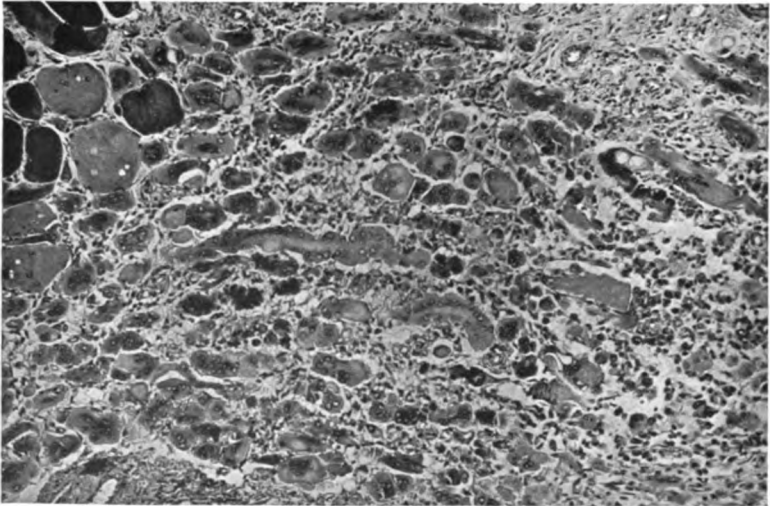


Fig. 21.—Repair. Regeneration of skeletal muscle-fibers following injury due to acute infection. M.

of highly differentiated cytoplasm containing numerous nuclei usually situated peripherally beneath the sarcolemma.

When the whole of a muscle-fiber is killed, it is not regenerated. When, however, only a part of one of these fibers is destroyed, active regeneration of the part which has undergone necrosis takes place from the part which remains uninjured. The intact nuclei undergo rapid direct division, and each forms several to a dozen separate nuclei. The division of the nuclei may take place at the

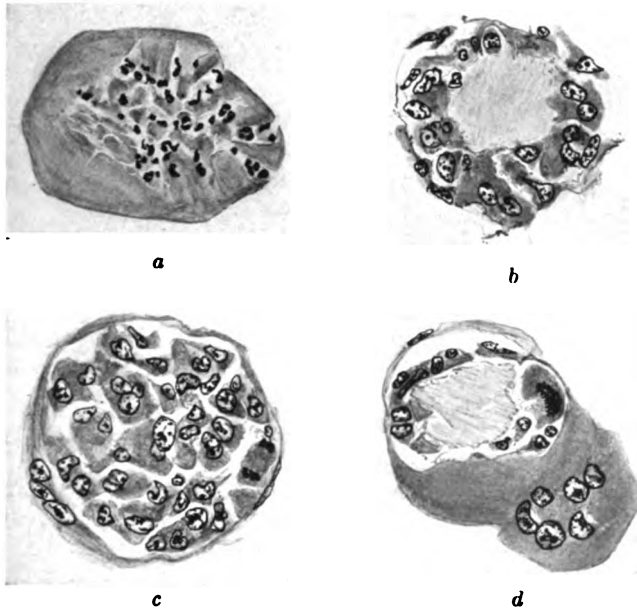


Fig. 22.—Necrosis of skeletal muscle-fibers. *a*, Necrotic muscle-fiber invaded by polymorphonuclear leukocytes; *b*, necrotic muscle-fiber surrounded by endothelial leukocytes; *c*, necrotic muscle-fiber entirely removed by action of endothelial leukocytes, one of which is in mitosis; *d*, portion of necrotic muscle-fiber being removed by endothelial leukocytes, one of which is in mitosis. Some proliferation of remaining muscle-nuclei by direct division.

periphery of the cell or in the center of its long axis. The new nuclei migrate to the periphery and to the destroyed end of the muscle-fiber. They are surrounded by young cytoplasm, which extends forward in the form of blunt processes, each of which contains a nucleus. In time, these cytoplasmic processes develop striations and fuse together to form a regenerated muscle-fiber. They do not separate from the old fiber to form new ones.

The process of regeneration of muscle-fibers is complicated

and made confusing by the presence of numerous leukocytes attracted by the injurious agent and by the injured tissue. Sometimes the necrotic muscle is removed through the action of polymorphonuclear leukocytes which usually invade the fibers; they are readily recognized, but at other times only endothelial leukocytes are present. They attack necrotic muscle substance from the periphery and gradually dissolve it, working slowly from without inward. Mitoses in these endothelial leukocytes are not infrequent. Occasionally, multiple mitoses occur from which multinucleated cells result. More often some of the endothelial leukocytes fuse to form foreign body giant-cells. Sometimes the two processes of regeneration and of removal of the necrotic muscle-tissue of the same muscle-fiber overlap and render the picture difficult to interpret. Each process must first be studied separately.

HEALING OF ORGAN AND TISSUE INJURIES

So far we have considered under repair the removal of foreign bodies of all sorts, the organization of fibrin, and the power of regeneration inherent in various kinds of cells. It is necessary now to make use of the knowledge thus obtained and apply it to the study of what takes place when definite masses of tissue have been injured and destroyed. In this way we can see how lesions are finally repaired by healing of the defects in the tissues. It is customary and easiest to begin with simple traumatic lesions, and to take up afterward those which are more complex.

Healing of Wounds.—The repair of wounds may be simple or complex, according to the number and variety of the cells injured or destroyed, the quantity of blood poured out, and the absence or presence of bacteria or other complicating injurious agents. It is customary to study wounds chiefly in sections prepared from experimental lesions produced in animals, although similar lesions can usually be obtained from man. The simplest incised wounds are produced in the cornea which, in consequence, is much employed for this purpose. Next in instructive value, perhaps, are incised wounds of the abdominal wall and of the intestine.

Clinically, the healing of wounds is of great importance, because on its quick and successful issue depends much of the value of surgery as a therapeutic measure.

Primary Healing (Healing by First Intention).—The term primary healing or healing by first intention is applied to the repair of simple incised wounds. The conditions for repair are usually most favorable. The injury is comparatively slight; there are few necrotic cells and little intercellular substance to be removed; hemorrhage is reduced to a minimum by ligature of

vessels; the cut surfaces are brought into the closest apposition by sutures and pressure; bacterial infection is prevented so far as possible by cleanliness or by antiseptics.

Following an incision (accidental or surgical) more or less serous and cellular exudation takes place; its functions are to counteract any injurious agents present including any antiseptic used; and to dissolve and remove all necrotic cells and fibrils and also any red blood-corpuscles which may be present owing to hemorrhage. At the same time proliferation begins in those types of cells which are capable of it to replace the cells which have been destroyed and thereby to bind together again the tissue walls separated by the incision. In incised wounds practically only three types of cells are of importance—fibroblasts, vascular endothelium, and epithelium. The fibroblasts and the vascular endothelium produce the connective tissue and blood-vessels to bind all wounds together. In certain non-vascular situations as in the cornea the fibroblast alone is sufficient. Surface epithelium quickly covers over any break in its continuity.

Any fibrin which is not digested and removed by the action of the leukocytes present is organized by fibroblasts. Ligatures and sutures, if not removed mechanically by the surgeon, are dissolved or encapsulated according to their nature. The same thing happens to other foreign bodies accidentally present, such as hairs or cotton fibers.

Secondary Healing (Healing by Granulation Tissue).—Secondary healing or healing by granulation tissue is the term applied to the repair of wounds where there is more or less loss of tissue, which has to be filled in by new formation of cells or where surfaces are kept apart by fluid or blood or by fibrin which has to be organized. Healing takes place by proliferation of fibroblasts and of vascular endothelium on a more or less extensive scale according to the extent of the injury. The young richly vascularized connective tissue formed in this way is called granulation tissue. Later, it contracts and persists indefinitely as scar tissue. At the same time that the granulation tissue is forming, the epithelium on any injured epithelial surface is rapidly proliferating to cover in the denuded surface.

Nature is able in time to fill in very extensive superficial lesions, such as ulcerations following burns of the skin or gaping wounds, where from the nature of the injury or operation the surfaces cannot be approximated.

Healing takes place through the action of these two types of cells simply because following tissue necrosis they are the only cells in most situations, outside of surface epithelium, which proliferate to replace cells of their own kind which have been

destroyed. In addition they possess the property of being able to organize fibrin. They seem, therefore, to take upon themselves the whole process of tissue repair, outside of the central nervous system, and in effect they do.

The difference between primary and secondary healing is essentially quantitative.

In primary healing the injury is slight and but few cells are destroyed. There is little in the way of foreign material of any sort to be removed. The amount of regeneration required of the tissue cells in order to effect union of the separated surfaces is reduced to a minimum. The cells which regenerate are the fibroblast and the vascular endothelium. In addition the epithelium of any involved epithelial surface, gland, or tubule proliferates to cover over any break in the surface where it belongs.

In secondary healing we have the other extreme. The injury is often excessive. Much foreign material has to be removed and frequently much fibrin organized. In addition fibroblasts and vascular endothelium must proliferate abundantly and often for a long period of time to replace the cells of their own type which have been destroyed. The result is the formation of much granulation tissue. The same excessive proliferation may be required of epithelium covering a surface, as, for example, of the epidermis.

The terms primary and secondary healing are applied to the two extremes of the process of healing tissue injuries. They are essentially one and the same process and all gradations between the two extremes occur.

Bacterial infection of a wound renders repair very much more complicated, so that even the simplest incised wounds can heal only by granulation tissue.

Granulation Tissue.—The term granulation tissue is clinical in origin, but very useful pathologically. It is applied to the young tissue composed of fibroblasts and vascular endothelium which are proliferating to replace destroyed blood-vessels and connective tissue, or which are growing into fibrin to organize it. The clinician employs the term for the red granular appearance presented by the healing ulcers and wounds as seen especially on the surface of the body. The pathologist applies the term to young vascularized connective tissue wherever found.

As just stated, the basis of granulation tissue is fibroblasts and vascular endothelium. Nothing else is essential; but, as a matter of fact, granulation tissue is practically always complicated by the presence of some of the elements of inflammatory exudation, owing to the action of foreign bodies such as necrotic cells, red blood-corpuscles, and fat, and of injurious agents such as bacteria, antiseptic dressings, air, etc. As a result of these various in-

fluences an acute serous or purulent exudation may continue to pass through the newly formed tissue from the vessels to the surface; endothelial leukocytes may collect in large numbers owing to the presence of fat or other foreign substances, while lymphocytes in small or large numbers may infiltrate the superficial and especially the deeper layers to counteract certain injurious substances which are being absorbed. Eosinophiles are usually present in small numbers but may be numerous. As the result of diapedesis granulation tissue often contains many red blood-corpuscles.

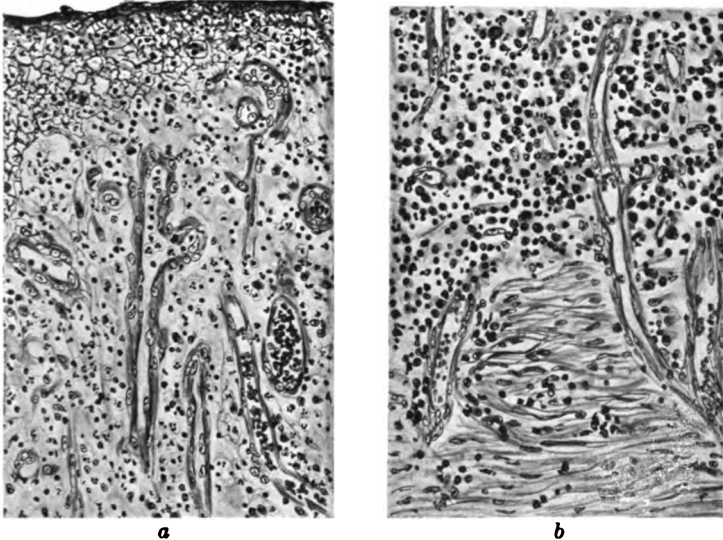


Fig. 23.—Granulation tissue. *a*, Surface portion, composed chiefly of newly formed blood-vessels; very few fibroblasts; many polymorphonuclear leukocytes between the vessels and in the fibrin on the surface; blood-vessels and leukocytes separated by serum. *b*, Deeper portion; many lymphocytes between blood-vessels; young fibroblasts growing in horizontal arrangement at base.

Granulation tissue is likely to be more abundant where there is plenty of fibrin than elsewhere because fibrin directly stimulates its growth. The lack of cicatricial contractions following typhoid fever and tuberculous ulcers of the intestine and of perforating ulcers of the stomach is probably due to the absence of fibrin, which if formed quickly undergoes maceration and disappears.

Abundant fibrin on a surface or between opposing edges favors the formation of granulation tissue. On this account a sodium citrate dressing is sometimes used clinically to prevent fibrin formation.

Lesions of all sorts involving destruction of tissue (necroses, infarctions, abscesses, diffuse suppurations, etc.) tend to heal after the manner of wounds. The underlying principles are the same. The cells which have undergone necrosis, together with their intercellular products, are gradually dissolved by the digestive action of the leukocytes and discharged on a free surface or absorbed. Fat, lime salts and certain other substances are removed largely through the agency of endothelial leukocytes. Fibrin when not dissolved becomes organized by fibroblasts with or without the help of vascular endothelium.

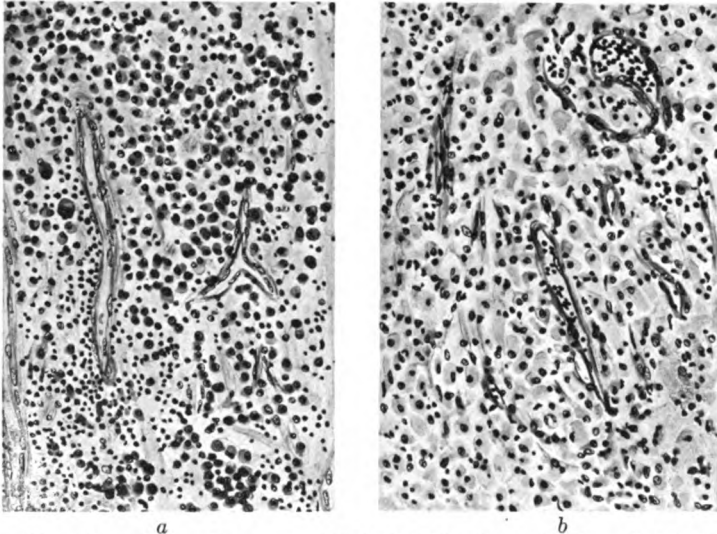


Fig. 24.—Granulation tissue. *a*, Marked infiltration with lymphocytes; *b*, infiltration with endothelial leukocytes.

At the same time regeneration of the necrotic cells takes place from adjoining cells of the same type, provided they are capable of it. Some are capable of it under certain conditions but not under others. Thus, when a single kind of parenchymatous cell, such as the liver cell, is destroyed even over considerable areas without injury to the intervening vascular and connective-tissue cells, the liver cells may be completely restored by regeneration. But when definite masses of liver tissue are completely destroyed, the liver cells do not regenerate, except possibly in small areas at the edge of the necrosis where the above favorable conditions hold. Under these latter conditions, however, the fibroblasts and the vascular endothelium proliferate and form granulation tissue which later contracts to scar tissue. These same con-

ditions hold good in the kidney, and probably in the other epithelial organs. In the heart the muscle-cells do not regenerate under any conditions.

Scar Tissue.—As granulation tissue ages the collagen fibrils increase in amount up to a certain degree. Then, many of the blood-vessels and of the fibroblasts disappear. The connective tissue thus formed gradually becomes denser. In this final stage it is called scar tissue. Scar tissue may also result from the proliferation of fibroblasts only. The term is applied in addition to the dense fibrous tissue which results from the contraction of the connective-tissue stroma of an organ in definite foci following necrosis and disappearance of the parenchymatous cells. Some of the areas of fibrous tissue in the heart arise in this way.

The term scar is usually applied to a surface appearance, either of the skin or of an organ produced by the formation of scar tissue with resulting contraction and usually depression below the surrounding surface.

Diffuse formation of scar tissue is variously named. Sclerosis or fibrosis of an organ is a good term to use when the pathologic process which caused the lesion is healed. Chronic nephritis and chronic hepatitis are proper terms only when a chronic process is present and persisting; otherwise we should speak of a sclerosed kidney or liver. The correct use of these terms would save much of the misunderstanding which often arises between clinician and pathologist.

REPAIR OF BONE

Introduction.—The repair of bone is analogous to repair of connective tissue, but differs from it in several very important points.

1. Any necrotic bone present is much more difficult to dissolve and remove than the necrotic cells and fibrils of other tissues, and hence persists often for a long time in the lesion and acts as an obnoxious foreign body, interfering with repair so long as it is not removed naturally or mechanically. It is dissolved very slowly through the action of endothelial leukocytes which for the most part are fused into foreign body giant-cells, ordinarily called osteoclasts on account of the function which they perform.

2. The fibroblasts available for producing the osteoid material in which the lime salts are to be deposited are limited to the cells covering bone, namely, to the periosteum and endosteum. The bone cells themselves are end-products and cannot produce other bone cells. Hence, the new cells required to seal together the ends of a fractured bone have to grow into the fracture from without.

3. The new bone is laid down not in a solid mass but in narrow connecting trabeculæ with richly vascularized connective tissue

between them. It is usually formed much in excess of eventual needs and occupies much more space than the original bone which it is to replace. Later the trabeculæ fuse more or less completely together, and in time those parts not required are removed by the erosive action of the osteoclasts. The new formed bone, whose functions are to unite the ends of the fracture and to hold the shaft rigid during repair, forms a kind of tumor mass, especially around the long bones, and is called a callus, which is sometimes distinguished as outer and inner callus according to its relation to the bone.

Simple Fracture.—A simple fracture of a bone with the ends held in proper apposition affords an example of bone repair which is easy to follow. In experimental lesions produced in animals the same result is reached by sawing or drilling into bones, instead of fracturing them, in order to maintain rigidity of bone during repair.

Ordinarily, the injury produced is slight; necrosis of a comparatively few bone cells adjoining the fracture and of a small number of bone marrow cells, possibly of a few muscle-cells outside of the bone. A little hemorrhage always occurs.

Following the injury a certain amount of exudation takes place but it is usually slight. The necrotic cells and fibrils and the red blood-corpuscles are readily dissolved and absorbed. Any free fat is taken up by endothelial leukocytes. All bone not under the control of living bone cells is dissolved slowly by osteoclasts. Experimental lesions produced by sawing and drilling are usually complicated by much bone dust which attracts endothelial leukocytes. Many of these leukocytes fuse to form foreign body giant-cells (osteoclasts). While these various processes are going on the fibroblasts of the periosteum and endosteum are actively proliferating and extending toward each other in between the ends of the fracture, where they soon meet and unite. At the same time they are piling up for a certain distance above and below the fracture on the outside and inside of the shaft. In this young and highly vascular connective tissue trabeculæ of osteoid material are soon formed extending out chiefly at right angles to the old bone. In time the osteoid trabeculæ thicken and fuse more or less intimately together and lime salts are deposited in them. The new bone formed between the ends of the fracture unites to the old bone and gradually seals the ends together. After complete solidification has taken place osteoclasts begin to dissolve those parts of the callus no longer required, and eventually the fractured and healed bone approaches more and more to its original size and shape.

The principle of repair of a comminuted fracture is the same as that of a simple fracture, and nature goes about it in the same way.

The danger of extensive necrosis of bone is greater. The amount of callus formed is usually more.

Complications.—Certain complications of fractures must be mentioned. Hemorrhage may sometimes be abundant, but is taken care of in the same way as in other tissues.

Occasionally, a great deal of fat is set free from the fat-cells in the bone marrow. If it happens to escape through a rupture into a vein, it may be carried all over the body, causing fat embolism from which death occasionally results.

Necrosis of bone may be extensive. This interferes greatly with repair because it is so difficult to dissolve. It forms a sequestrum, and unless removed mechanically becomes encapsulated by granulation, later scar tissue, and persists indefinitely.

When the fragments are widely displaced so that the alignment is poor, much more callus formation is required than in a simple fracture.

If fibrous or muscle-tissue is forced in between the ends of the fractured bone, it may prevent the ingrowth of the osteal fibroblasts capable of producing bone so that bony union cannot take place.

Compound Fracture.—A compound fracture is one in which the injury is opened to infection owing to the perforation of an overlying surface such as the epidermis, the intestine, an infected pleural cavity, etc. If it occurs, then the simple reparative process of the fracture is complicated with an acute infection. This almost invariably leads to more or less extensive necrosis of bone, which remains as a sequestrum after the infection is ended. Repair then has to attend to the damage done by the acute septic process, to the necrotic bone left behind, and to the original fracture.

Necrosis.—Necrosis of bone may occur from a variety of causes, such as direct injury, fracture, or infection. Repair is not easy and simple owing to the necrotic bone. It is dissolved with the greatest difficulty, as the action of the osteoclasts is exceedingly slow and ineffective. In time, however, the necrotic bone is separated from the living bone through their action and forms what is known as a sequestrum. Osteoclasts continue to work at it. It becomes surrounded or encapsulated by the granulation tissue of the general reparative process. Later, this contracts to scar tissue.

Perfect repair of bone is not possible so long as a sequestrum persists. It may be dissolved in time or it may be removed surgically.

As a result of necrosis of bone a certain amount of callus is always formed to strengthen the weakened bone. When this

callus forms from the periosteum, the resulting thickening of the bone is sometimes mistaken for a tumor, especially when there has been no history of previous fracture, injury or infection.

In infections involving bone the whole shaft may be destroyed and form the sequestrum. The periosteum always attempts to rebuild the bone destroyed. As a result, extensive callus may be formed. Treatment requires operative removal of the sequestrum. Then the periosteum if left behind uninjured, can readily reform the shaft.

REPAIR OF CARTILAGE

Injuries to cartilage are not nearly so frequent or important as to bone. They may be due to incisions, lacerations, or fractures (epiphyseal ends of bones).

Healing takes place as in other tissues through the formation of granulation tissue. In addition, however, the perichondrial cells proliferate like the osteal cells to produce new cartilage. Sometimes, however, they produce only connective tissue.

It is claimed by some that in repair of fractures through the epiphyseal cartilage the cartilage cells themselves undergo mitosis and form new cartilage, but the claim is open to doubt.

REPAIR OF MUSCLE

Repair of an incised wound of muscle takes place entirely by granulation and scar tissue formed from the fibroblasts and vascular endothelium adjoining the incision.

Injured muscle-cells undergo certain changes which are partly retrograde, partly regenerative of the cells injured, but no new separate muscle-fibers are formed.

The same statement is true in regard to other injuries to muscles due to infection or tumors; injured muscle-cells may regenerate the parts which have been destroyed, but no new muscle-fibers are formed to replace those which have been completely destroyed.

HEALING OF TISSUE DEFECTS IN THE CENTRAL NERVOUS SYSTEM

Neuroglia Cells.—In the central nervous system there is an additional cellular element besides the fibroblast and the vascular endothelium which enters into all processes of repair, namely, the neuroglia cell. It regenerates as actively as the fibroblast, and in many lesions plays a more active part. When a mass of tissue is destroyed, all three types of cells may regenerate. It is noticeable, however, that while fibrin stimulates the fibroblast it produces little effect on the neuroglia cell. It is probably on this account that the capsule of a solitary tubercle is always composed of connective tissue.

RETROGRADE PROCESSES

And the Substances Associated with Them

Introduction.—Every cell is a minute chemical manufactory. According to its inherited nature it converts the nutrition received from the circulation into various products, some for its own use in building itself into a fully differentiated cell of its own type and for purposes of multiplication; some into products which surround the cell as an intercellular substance, or which pass into the circulation to perform functions elsewhere. The grosser structural products within and without the cell we can recognize under the microscope; others we are made aware of only through functional performances and by means of chemical reactions.

Various injurious influences, such as toxins of many sorts, increase or lack of internal secretions which affect cells in other organs, and lack of nutrition, lead to interference with normal cell activity. They may stimulate or depress its activity or entirely alter its nature. If the toxins are strong or if nutrition is completely cut off, necrosis may occur. As a result of these injurious influences there occur a great variety of changes, chemical at basis, of which many can be recognized functionally and morphologically; only the morphologic changes concern us here.

Certain substances already in the cells in one form or another may be increased in visible number or in amount, such as albuminous granules, fluid, fat, glycogen, mucus. New substances may be formed within or without the cell, such as hyalin of many sorts, of which some, like amyloid and mucin, are characterized by more or less definite chemical reactions.

We speak of the changes which take place as retrograde processes due to disturbances of metabolism, but we are really concerned chiefly with the morphologic evidences of the changes, namely, with normal substances (serum, fat) accumulated in excess, or new substances (amyloid, hyalin) formed as the result of the abnormal processes. By observing and studying the accumulation and production of these various substances we attempt to understand the retrograde processes which gave rise to them.

Some of these various normal and abnormal substances are more or less closely related chemically or in origin (hemoglobin, hematin, bilirubin, hemosiderin, malarial pigment); others often follow in a certain sequence or are associated together ac-

ording to the degree of injury inflicted on the cells (hydrops, albuminous granules, fat-droplets, necrosis, lime salts). Some of the substances included under this heading are definitely characterized (fat, cholesterin, glycogen, mucin, amyloid), others are very indefinite (albuminous granules, hyalin, colloid), so that one name may cover a variety of pathologic products (hyalin).

Some of the substances (albuminous granules, fat) are entirely or chiefly intracellular, others (biurate of sodium crystals) are extracellular; some are associated with living cells (albuminous granules, glycogen), others with dead cells (lime salts, cholesterin crystals); some of the substances are of much importance (amyloid, biurate of sodium crystals), others are of little significance (albuminous granules).

POSTMORTEM CHANGES

The changes which occur in cells and intercellular substances postmortem are often marked. On this account it is important to know and to be able to recognize them so as not to mistake them for vital processes.

Tissues removed during life and fixed at once are always the best for study. Postmortem tissues fixed within one to two hours after death are fairly trustworthy, but after about that interval of time they slowly but steadily deteriorate. Tissues thoroughly chilled but not frozen may be preserved in fairly good condition for several days, but are far from ideal.

The degree of temperature at the time of death has an important bearing on postmortem material. If it is high (40° to 41° C.), as frequently happens in typhoid fever, lobar pneumonia and septicemias, for example, the high temperature will persist for some time and the postmortem changes are more rapid and marked than when the temperature is normal or below. For a similar reason tissues change more rapidly in hot weather than in cold.

Two other factors are of importance. If edema is present, or if the tissues are placed in contact with water, the cells and intercellular substances tend to imbibe fluid and swell and undergo other changes in consequence. If bacteria of any sort obtain entrance to the tissues after death or shortly before it, they are likely to multiply and ferments set free by them often produce noticeable alterations.

Postmortem changes tend to take place more quickly in some organs than in others owing to their exposure to putrefactive organisms (intestine) or to injurious chemical substances (the stomach and its secretion, hydrochloric acid, the pancreas and its ferments).

The changes which take place postmortem in cells and tissues are best studied by killing a normal animal, removing the heart, kidney and liver aseptically, and placing them in a covered dish in a thermostat at 37° C. Sections of the organs may be removed and studied or fixed at various intervals of time. Similar changes may be studied in human organs by noting the number of hours, postmortem, the tissues were placed in fixatives.

Within twenty-four hours or less many of the nuclei have shrunk a little and the chromatin has diffused through them so that they stain deeply and homogeneously. A later change is disappearance of the chromatin so that the nuclei do not stain

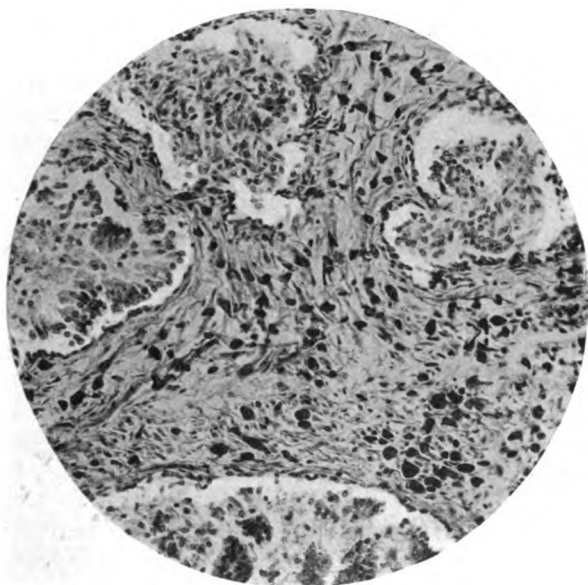


Fig. 25.—Prostate. Postmortem changes; desquamation of epithelial cells in the glands; hyaline changes in smooth muscle-cells. M.

at all. In human kidneys the nuclei of the convoluted tubules lose their ability to stain much sooner than those in the collecting tubules. The condition is often mistaken for necrosis during life.

In the liver of animals cytolysis usually occurs postmortem owing to the rapid growth of a bacterium which is a more or less normal inhabitant of that organ.

Myoglia, fibrogia and neuroglia fibrils lose rather quickly, postmortem, their peculiar chemical or physical properties on which a differential stain of them depends. Collagen and elastic fibrils preserve their characteristic staining properties much longer.

Smooth muscle-cells frequently swell up in the center, presenting a lumpy hyaline appearance, and stain deeply with eosin. This is a common postmortem change and is usually most prominent in the prostate.

The hemoglobin dissolves out of red blood-corpuscles quickly postmortem, especially if the tissues are edematous. It continues to dissolve out for some time even after the tissues have been placed in fixatives. On this account it is difficult to fix red blood-corpuscles in the spleen or liver except at the surface of the tissues, unless the sections are very thin (one to three mm.). For this reason it is possible to judge faithful tissue-fixation by the state of preservation of the red blood-corpuscles. Hemoglobin in solution is precipitated by formaldehyd in the form of black granules.

Certain other postmortem changes deserve mention.

In the liver the liver cells frequently separate from each other.

Not infrequently the endothelium strips off the walls of the blood-vessels and the renal epithelium slides down within tubules and doubles upon itself, so that the condition has been mistaken for adenoma-formation. The heart muscle-fibers may separate at the intercalated discs (segmentation). In perfectly fresh tissues these things do not occur.

Cardiac muscle-fibers are brittle and easily fractured even by the microtome knife, especially after postmortem changes have set in. The resulting condition of fragmentation is an artefact and, of course, of no pathologic significance.

The epithelial lining is very commonly found desquamated in the gall-bladder within a few hours postmortem. It macerates off in the urinary bladder and desquamates loosely in the glands of the prostate so that the cells lie free of one another.

Postmortem changes are very common in the pancreas. The condition is likely to occur in foci which spread until they coalesce. The nuclei lose their ability to stain and the cells usually shrink so that an increase of interglandular tissue is often suggested.

The epithelium lining the gastro-intestinal tract undergoes rapid changes: the nuclei along the surface lose the power to stain and the cells may desquamate.

ATROPHY

Atrophy of an organ or tissue, unlike atrophy of a cell, may be due to diminution in the size or the number of the cells composing it or to both causes. All three possibilities must be borne in mind. Atrophy of organs and tissues, and to some extent of cells, may be caused by normal physiologic changes, by lack of nourishment or of use, by trophic disturbances, or by toxic influences.

Physiologic atrophy is the term applied to the diminution in size which occurs in certain organs normally as the result of development and senescence. The thymus atrophies before puberty owing to disappearance of many of its cells, and the ovary by the time the climacteric is reached because the follicles have been used up. In old age, on the other hand, and in emaciation the atrophy seen in various organs and tissues is due to diminution in the size of the cells. In emaciation the fat and

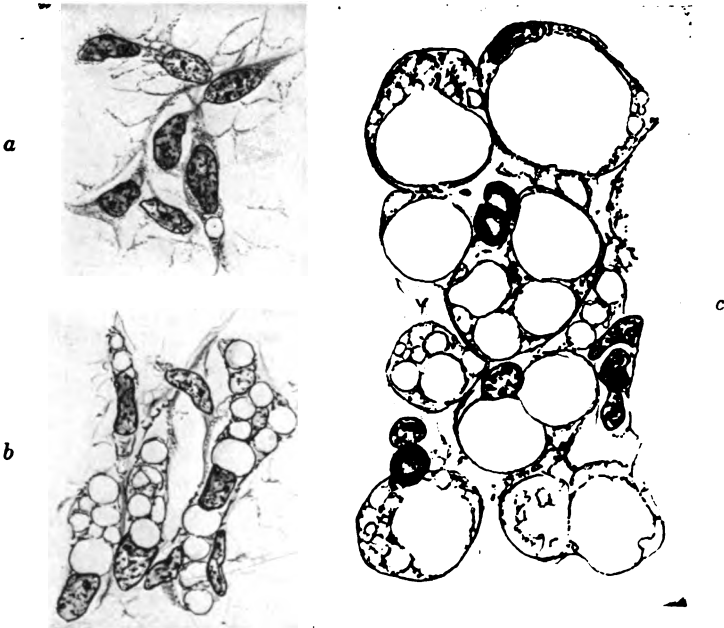


Fig. 26.—Fat-cells developing in human fetus. Three different stages shown.

muscle-tissues are those most affected, the central nervous system the least; even the heart may be diminished to half its normal weight.

Pressure atrophy may lead to disappearance of cells, as seen in the effect produced in bone by tumors and aneurysms; or to atrophy of cells, such as occurs in amyloid formation in the liver.

Atrophy of organs may be caused by toxins owing to destruction of cells. The best example is seen in the liver in acute yellow atrophy due to necrosis and disappearance of most of the liver cells. The organ may be reduced to one-half or even to one-third of its normal weight.

Atrophy from lack of use and from trophic disturbances is

best shown by the changes which take place in muscle and bone, chiefly as the result of atrophy and disappearance of cells.

The cells of certain organs become increasingly pigmented with age. The heart and liver afford the best examples. In

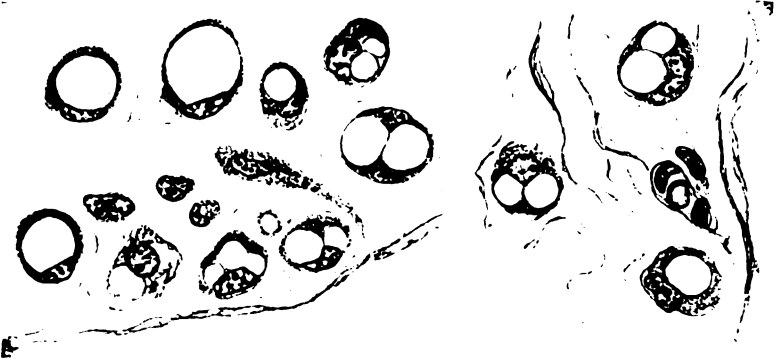

Fig. 27.—Atrophying fat-cells.

atrophy due to old age the amount of pigment in the cells is relatively increased owing to diminution in the size of the cells. To this condition the term brown atrophy is commonly applied, although the pigmentation has nothing to do with causing the atrophy.

Atrophy of Fat-Cells.—The fat-cell is a perfectly definite type of cell formed by differentiation from a mesenchymal cell. It is not a fibroblast, does not arise from one and when it undergoes

atrophy does not turn into one. It is characterized by the property of taking up and storing fat and by not producing any intercellular substance.

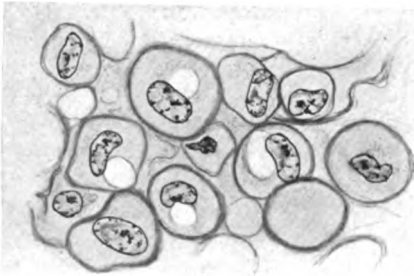


Fig. 28.—Atrophied fat-cells.

Fat-cells arise in sharply defined islands in various parts of the body. They appear at first as star- and spindle-shaped mesenchymal cells with finely granular cytoplasm.

Each group of cells is clustered around the end of a comparatively large supplying blood-vessel which sends numerous capillaries in between the cells.

As fat is deposited in these cells it appears at first as small droplets which soon fuse together. As the fat continues to

accumulate the cytoplasmic processes retract and the cell gradually assumes a spherical shape. After a time the fat fuses into one or more large drops so that the nucleus is pushed to the periphery of the cell and becomes flattened. The cytoplasm is thinned to the merest layer around the fat and apparently loses its granulations.

When fat tissue atrophies from inanition either in infancy or in old age, the fat-cells undergo much the same changes in reverse order until they become rounded or polygonal cells with dense, finely granular cytoplasm and look somewhat like enlarged endothelial leukocytes or like some form of epithelial cell. Sometimes the cells are relatively quite large, especially in emaciated infants, and resemble liver cells. Fat-

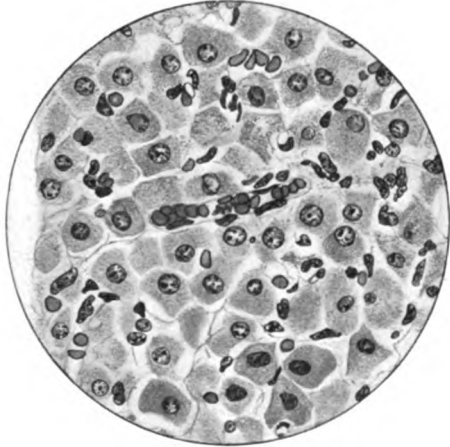


Fig. 29.—Fat-cells of the embryonic type from an emaciated infant.

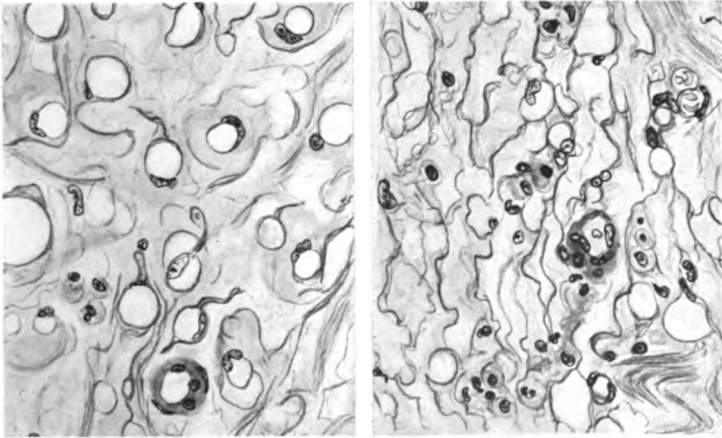


Fig. 30.—Epicardium. Atrophying fat-cells, edema of connective tissue.

cells in this condition, if their character is not recognized, may suggest some form of new-growth.

Ordinarily, fat-cells do not remain in the definite islands where

they first arise, but multiply and spread into the surrounding tissues, especially along the blood-vessels. Thus, in fat people they multiply in great numbers and may invade such organs as the pancreas and the heart. In emaciation as the fat is absorbed most of these cells disappear entirely. They may even disappear largely from the fat islands. As they disappear the fibroblasts often take on the appearance of mucous connective-tissue cells, due to the presence apparently, of mucin between the collagen fibrils, so that the epicardial tissue, for example, may resemble in texture and translucency the umbilical cord.

ALBUMINOUS GRANULES

Many normal cells contain in their cytoplasm, in addition to the microsomes, fine to coarse granules. Those which optically disappear on the addition of acetic acid but are not affected by chloroform or ether are regarded as albuminous in nature. To the apparent or real increase of these granules in the parenchymatous cells of three organs, the kidney, liver and heart and to a less extent in striated muscle, much attention has been directed in the past, entirely out of proportion to the slight significance of the condition.

As already stated under postmortem changes these granules should be studied in the fresh state, not after fixation, and as soon after death as possible. The results obtained in the fresh state may be compared with what is found in similar cells after fixation, but it must be remembered that most of the best fixatives precipitate soluble albumin in the form of granules, that the acetic acid test cannot be applied to the fixed granules and that many fixatives, as, for example, Zenker's fluid, contain acetic acid so that the albuminous granules have already been acted on by it.

On the other hand, we may compare sections of similar organs, both normal and abnormal, fixed under similar conditions and draw fairly reliable conclusions in regard to the number and size of the granules present, although it is probably not justifiable to regard them all as albuminous in nature. Their composition is, perhaps, as varied as the granules in leukocytes, but we lack at present reliable methods for demonstrating them.

Increase in the number of albuminous granules is supposed to be due either to substances in the cytoplasm becoming visible as granules, or to substances, taken in from without, being deposited as granules. Such an increase is held to indicate a lowering of the functional activity of the cell, but the disturbance is not severe and recovery from the condition may easily occur.

Variation and especially increase in the number of albuminous granules in the cytoplasm of cells is not easy to demonstrate in a satisfactory manner. It lacks definiteness. While it may exist

there seems to be no reliable way of proving it. The granules cannot be counted; they are too numerous and too minute. Consequently, they can be compared numerically only in a relative way and such a method is not very reliable. Moreover, increase or diminution in the number of granules is relative for each variety of cell, even in the same organ. Compare for instance in the normal kidney the number of granules in the cells lining the convoluted tubules with those in the cells of the collecting tubules.

It must be borne in mind that the cytoplasm of the cells lining the convoluted tubules of the kidney are normally very granular. The same condition holds in a less degree for the liver cells. On the other hand, the striated muscle-fibers of the heart contain only a few coarse granules adjoining the ends of the nuclei. They do not occur elsewhere in the cytoplasm between the striations.

The albuminous granules present in the cytoplasm of cells are studied in the fresh state by mounting scrapings from the cut surface of the organ to be examined in normal salt solution. The granules when very numerous may obscure the nucleus, but postmortem changes may cause the nucleus to appear faint. The addition of dilute acetic acid to the preparation will cause the optical disappearance of the albuminous granules, thus distinguishing them from fat-droplets, and at the same time will render the nuclei prominent. In fixed tissues the granules in the cytoplasm of cells are readily stained by eosin, acid fuchsin or phosphotungstic acid hematoxylin.

In necrotic cells the albuminous granules usually disappear quickly so that the cytoplasm presents a uniform hyaline appearance.

Increase in size and number of albuminous granules may occur focally at the advancing edge of acute lesions, such as liver necroses and abscesses. In these situations the number and size of the granules can be directly compared with those in the adjoining normal cells so that the differences noted have some value.

A few observations made in regard to cytoplasmic granules may be of interest.

In stained sections of heart muscle, fixed within one to two hours postmortem from cases of typhoid fever, lobar pneumonia and septicemia, no granules could be found. The various elements in the longitudinal striations were perfectly preserved and stained.

The number of granules in the cells lining the convoluted tubules in the kidney is very high normally; to detect an actual increase is not easy. On the other hand, the cells in the collecting tubules contain few granules and no marked increase occurs under any circumstances.

Sometimes the granules in groups of renal cells are increased

both in number and in size and stain deeply with acid dyes. As they continue to enlarge they become definitely hyaline (colloid), and usually stain lightly or not at all. This change may not be associated with any acute infectious process; for example, it often takes place in connection with amyloid formation in the kidney.

Sometimes the albuminous granules may be more or less completely absent from liver cells. Rarely, this absence may occur in foci up to one or more millimeters in diameter and be scattered throughout the organ. Such foci appear pale and are readily visible in the fresh condition and after hardening. The reason for the lack of granules is not evident, but may be due to some form of coagulation. The liver pictured in Fig. 47 came from a patient killed suddenly by being knocked down by an automobile.

Cloudy Swelling.—Cloudy swelling is a term applied by Virchow to the appearance presented postmortem by the liver, kidneys and heart in certain acute infectious processes, such as typhoid fever and lobar pneumonia. It is supposed to be due to increase in the number of the albuminous granules. The cut surface of the organs appears less translucent than normally; it is cloudy as if it had been dipped into boiling water. Often the organs are somewhat increased in size (an eighth to a quarter). It was on account of these two characteristics that the term cloudy swelling was applied. Sometimes the term albuminous degeneration is used. The increase in the size of the organs, when present, is probably due largely or entirely to increase of fluid. Whether the cloudiness is due to an antemortem increase in the number of albuminous granules or to postmortem changes in the cells as the result of high temperature is a moot question.

Cloudy swelling is a condition always readily recognized with great certainty, both in the fresh state and microscopically in fixed tissues by the beginner even in such an organ as the spleen, although amyloid and other important pathologic products may be as readily overlooked. To demonstrate to the student's satisfaction that he may be in error is not easy. It is the one lesion that most of them feel sure about, and the instructor often honestly doubtful or exceedingly sceptical.

FAT

Introduction.—Fat is present normally in visible form in certain tissues and organs (fat tissue, adrenal glands, sebaceous glands). It may be stored up in excess of normal needs in fat tissue and in the liver. It may make its appearance in all kinds of cells as a result of injury done them. On this account its presence in many kinds of cells, such as heart and skeletal muscle-fibers and renal

epithelium, furnishes most reliable evidence that the cells are injured, in some way or other, and that their functional activity is impaired. On this account the study of its normal distribution and of its appearance and significance under pathologic conditions is important.

Composition.—Fat as it exists in the human body is not a simple substance. It consists for the most part of neutral fats, the triglycerids of oleic, palmitic and stearic acids. In addition it contains small amounts of soaps. More complicated fatty combinations, such as lecithin, myelin and cholesterol, occur in certain locations, either alone or in connection with fat.

Characteristics.—Ordinary fat when in droplets is recognized microscopically by its refractiveness; by its solubility in alcohol, ether and chloroform, and its insolubility in acids and alkalis; by the property, possessed in highest degree by oleic fat, of reducing osmium peroxid to metallic osmium whereby it is stained black; and by the characteristic common to all three forms of fat of dissolving certain anilin dyes such as Scharlach R., in consequence of which they may be readily stained red and rendered prominent. These tests must be made on tissue which is fresh or fixed in formaldehyd. After they have been made, the osmium preparations may be preserved permanently in balsam, the Scharlach R. preparations in glycerin jelly. In sections of tissues fixed in other ways and carried through alcohol the fat is dissolved out so that only vacuoles remain.

Fat also exists in cells either so finely divided or in so close chemical combination that it cannot be demonstrated microscopically except by special technic. It has been found that dried cells may contain as much as 20 per cent. of so-called invisible fat.

Labile and Stable Fat.—In starvation fat stored up in fat-cells and, under certain conditions to be mentioned later, in the liver, is readily used up and disappears. On this account it is called labile fat. Under similar circumstances the invisible fat persists in the tissues; hence it is termed stabile fat.

Normal Distribution.—Visible fat occurs plentifully under normal conditions in the fat-cells of fat tissue all over the body, in the cortical cells of the adrenal glands and to a less degree in the epithelial cells of the sebaceous glands.

Increase of Fat Deposit.—Fat tissue is sometimes increased much beyond normal limits. The terms *adipositas* and *lipomatosis* are applied to the condition which may be general or local. As examples of the latter may be mentioned: (a) A marked increase in the fat capsule of the kidney. (b) An increase of fat tissue around the heart and often an ingrowth extending in

between the muscle-fibers as far as the endocardium, so that the function of the heart muscle is interfered with. (c) An ingrowth of fat tissue between and into the lobules of the pancreas.

The cause of such great increase of fat tissue seems to be chiefly excess of nutrition, but in some instances impaired metabolism combined with diminished oxidation may play a part.

Sometimes a growth of fat tissue occurs which seems to have a compensatory function only. Thus, in atrophy of the kidney the fat tissue around the pelvis of the kidney is often increased in amount, and in atrophy of skeletal muscles fat tissue may extend in abundantly between the remaining muscle-fibers (pseudomuscular hypertrophy). In healed sclerosed appendices fat tissue often makes its appearance in the submucosa.

Fatty Infiltration of the Liver.—Fat is often deposited in the liver cells, sometimes in large amounts. The condition is known




Fig. 31.—Fat. *a*, In epithelial cells lining tubules of kidney; *b* and *c*, in muscle-fibers of heart viewed longitudinally and in cross-section.

as fatty infiltration of the liver. If it is of moderate degree the fat is usually located in the cells at the periphery of the lobule around the portal vessels. In marked instances, however, every liver cell may contain a single large fat-drop which pushes the nucleus to the periphery of the cell and makes it look like a fat-cell.

Cell Degeneration Evidenced by the Presence of Fat; So-called Fatty Degeneration.—Under various pathologic conditions visible fat makes its appearance in cells which normally contain none. The presence of the fat is due to degeneration following injury or faulty nutrition. The degeneration causes impairment of cell function.

The fat usually appears in the form of minute to small droplets in the cytoplasm of the cells, but sometimes in the liver it occurs in large drops. This condition of cell degeneration associated with

the presence of fat is commonly called fatty degeneration. It is old usage based on the mistaken idea that the fat arises directly within the cell from a change of the proteid into fat. This view has been proved wrong. The term is, therefore, incorrect.

The chief source of the fat is that brought as nourishment to the cells through the blood and lymph and not utilized. It is thought that in addition some of the invisible fat in the cells may be set free and so become visible, and that sometimes complicated lipoids, such as lecithin, may break down and fat be formed from

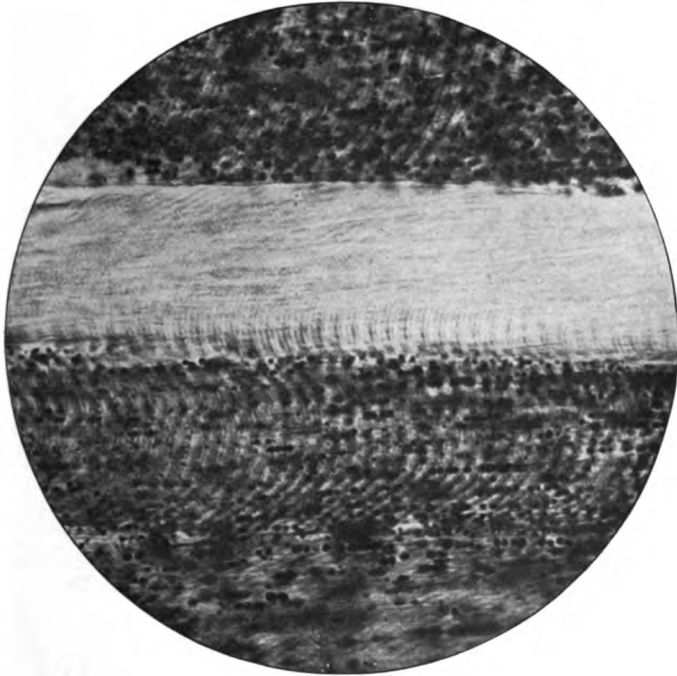


Fig. 32.—Fat in skeletal muscle-fibers (diphtheria). M. and W.

them. Certainly fat is often formed in abundance from myelin in the central nervous system.

In the adrenal glands fat due to cell injury is difficult to distinguish from the fat normally present and in the liver from fat due to fatty infiltration. The size of the fat-droplets will not definitely decide the matter, although in general fat due to infiltration in the liver occurs in large droplets and that due to cell degeneration in small droplets.

Cell degeneration associated with the presence of fat is caused largely or entirely in two ways, by a deficient supply of nourish-

ment including oxygen, and by the direct injurious action of toxins of many sorts.

In general anemia due to hemorrhage from a gastric ulcer or to any other cause much fat accumulates in the heart, kidneys and other organs. Local anemia due to interference with the blood supply by embolism, thrombosis, or narrowing of blood-vessel lumen likewise results in injury to cells and in the accumulation of fat within them. The condition is common at the edge of infarcts and in the cells situated a little away from the blood-vessels in rapidly growing tumors.

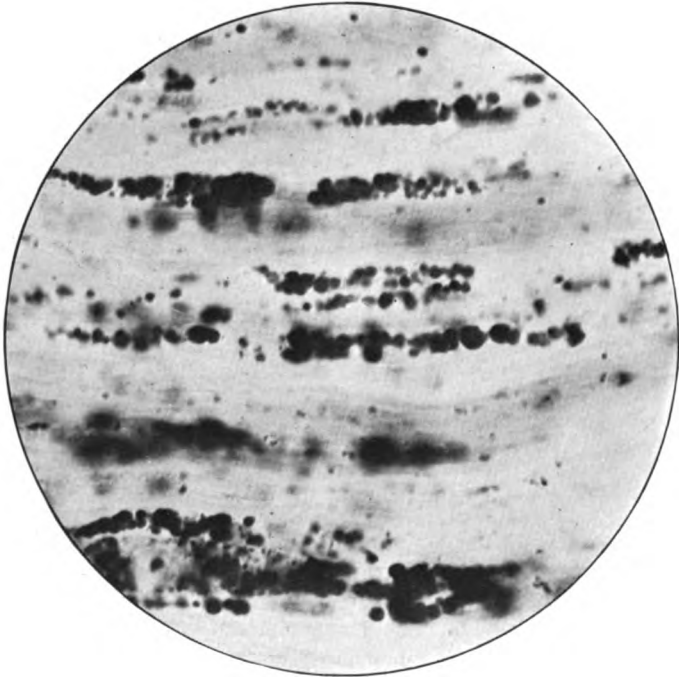


Fig. 33.—Fat in nerve-fibers (diphtheria). M. and W.

Many injurious agents injure cells and thus cause fat to accumulate in them. Phosphorus is a classical example. Chloroform affects particularly the cells in the center of every liver lobule. Diphtheria toxin often injures nerves and striated muscles and leads to the presence of fat.

Injured cells which contain but little fat may recover, but cells which contain much fat have been injured beyond recovery.

Fat in Endothelial Leukocytes.—Fat is often set free in the body by necrosis of cells. When this occurs, the fat is taken up

by endothelial leukocytes which dispose it in their cytoplasm in the form of small droplets of fairly uniform size. The leukocytes in this condition are sometimes called fat granule cells. After filling themselves with fat in this way the leukocytes tend to collect in the lymphatics around blood-vessels while they digest the fat and probably transform it into other compounds.

Endothelial leukocytes filled with fat are often numerous in the granulation tissue walls of old abscesses, in the inflamed mucous membrane of chronic salpingitis, in softened foci in the brain, in atheromatous patches in the aorta and other blood-vessels, and in all kinds of tumors.

Gross Appearances of Fat in Tissues.—Fat in tissues lends them a white to yellow color and a certain amount of opacity, most marked when the fat is in small droplets or crystallized, due

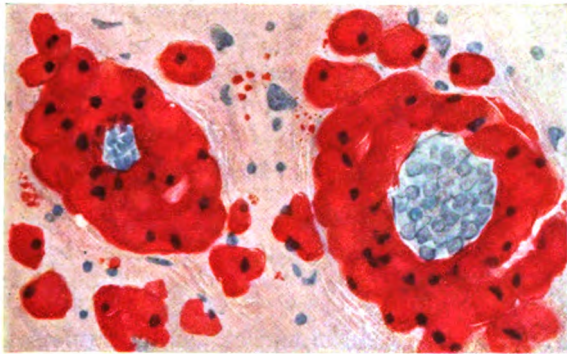


Fig. 34.—Spinal cord. Softening. Endothelial leukocytes filled with fat collected around blood-vessels.

to refraction of the light. It may be completely masked by injection of blood-vessels and may be simulated by anemia, by mucous connective tissue and by small hyperplastic masses of elastic tissue, such as often occur in scirrhous cancer of the breast. From these it may be distinguished in gross by its greasing the knife, and microscopically by its characteristic properties. When fat is present in the tissues in foci, as in the tiger lily heart, it stands out more prominently than when evenly distributed.

Cholesterin occurs normally in solution and in combination with fats and soaps in the bile, in nerve tissue, in the blood and, in slight amount, in nearly all tissues. In its crystalline form it is easily recognizable on account of its occurrence in characteristic rhomboid flakes, usually with a corner out. Treated with sulphuric acid it turns red, then violet. Iodin followed by sulphuric acid turns it blue.

Cholesterin crystals may be found wherever fatty degeneration and necrosis of cells have occurred; for example, in old abscesses, in old echinococcus cysts and hydrocele sacs, in atheromatous patches in the aorta. They also appear in connection with cornified epithelium, as, for example, in dermoid cysts, in wens, in cholesteatomas.

FLUID

Fluid often accumulates in cells and between them, and within cavities. Various terms are applied to the condition—hydrops, dropsy, edema, ascites, etc. Here we are concerned chiefly with collections of fluid within and between cells.

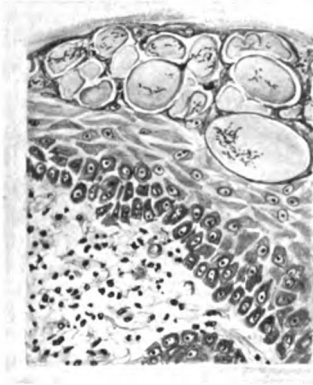

Fig. 35.—Hydrops of cells. Accumulation of serum in cornified cells of epidermis. Slight formation of fibrin.

The fluid is derived from the lymph, which in turn comes from the serum of the blood. Its composition evidently varies considerably, depending on the conditions under which it occurs; sometimes fibrin forms readily in it but at other times not.

Hydrops of the Cell.—The accumulation of fluid within a cell is sometimes termed hydropic degeneration or, better, hydrops of the cell. The condition occurs more often in the cytoplasm than in the nucleus, and may possess no great significance although the affected cells often present a striking appearance. The fluid may occur diffusely in the cell or collect within

one or more cavities in the cytoplasm. In fixed tissues only the cavities or vacuoles in which the fluid was contained appear. They may be empty or contain spherules, threads or networks of fibrin or occasionally hyaline material.

Fluid accumulates in cells most often in connection with inflammatory conditions of various sorts as the result of the exudation of serum. Thus, it is often found in and between the epithelial cells of the epidermis where large collections of fluid known as blisters are of common occurrence (eczema, urticaria, smallpox, varicella, anthrax pustule, etc.). It may also occur in a variety of cells as the result of excess of fluid in the tissues in consequence of general or local disturbances of the circulation, causing an abundant escape of lymph, for example, as the result of certain lesions of the heart or kidneys.

In the liver fluid often collects in small amounts in the cells around the central vein in the early stage of central necrosis. The cells show one to several vacuoles, in each of which is a small ball of fibrin. In the larger vacuoles the fibrin may appear as threads or as a network.

Fluid accumulates in striated muscle-fibers in a variety of infectious processes and particularly in the early stages of invasion with the *trichinella spiralis*. The longitudinal striations are usually pressed to the periphery, but may be separated into bundles by the formation of numerous vacuoles filled with fluid.

Fluid accumulation between cells and fibrils is generally termed edema. It is of common occurrence in inflammatory conditions and also as the result of

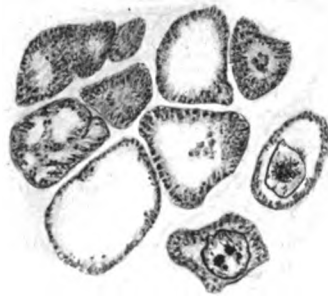

Fig. 36.—Hydrops of cardiac muscle-fibers.

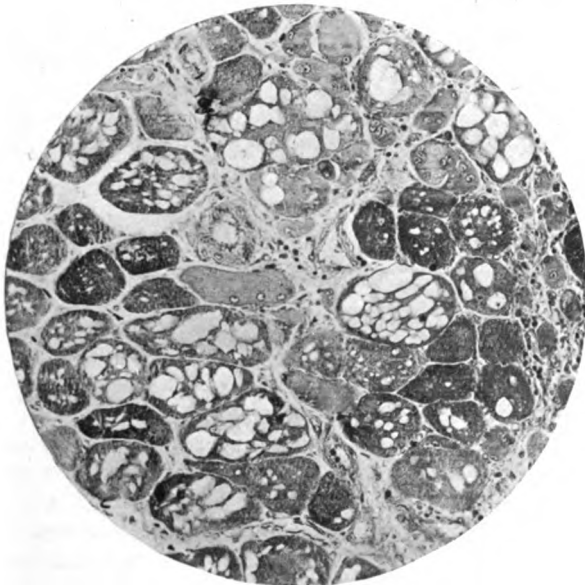

Fig. 37.—Hydrops of striated muscle-fibers. M.

transudation, due to general or local disturbances of circulation. Fluid often collects in tumors; for example, in fibromas causing

edema of them, and in the stroma of adenomas of the breast. It is not always easy to distinguish between simple edema and that secondary to the secretion of mucin by mucous connective-tissue cells.

The kidney under various conditions (glomerulonephritis, etc.) often shows fluid in the cells and tubules and in the interstitial tissue.

NECROSIS

Necrosis is the term applied to local death of cells, that is, to death of cells, singly or in groups, while surrounding cells continue living. Necrobiosis is a term sometimes applied to slow death of cells under similar circumstances.

Of the various retrograde processes necrosis is necessarily the most serious because it signifies the end of the life of the cells involved. It may affect normal cells or follow one or another of the forms of degeneration, especially that associated with the presence of fat in the cells. On this account it is impossible always to draw a sharp line between degeneration and necrosis.

As soon as necrosis occurs the cells involved become a foreign body,—that is, an injurious agent,—exciting an inflammatory reaction in part at least as the result of injurious substances emanating from it, and often stimulating regeneration by cells of the kind destroyed.

The causes of necrosis are almost as numerous as the causes of inflammation, and include many of the injurious agents in the mechanical, physical and chemical groups. In addition, however, a very important rôle is played by the cutting off of nutrition, including oxygen, from the tissues. This is effected by plugging the vessels on the inside by embolus or thrombus, or by constricting the vessels from without by compression.

Necrosis may affect single cells or small or large groups of them. It may involve only the parenchymatous cells in an organ (central necrosis of the liver), or all the cells in masses of tissue (infarction of kidney).

Cells killed suddenly often cannot be distinguished at first from living cells, but only after certain chemical and physical changes have taken place in them, as a result of being kept at body temperature and bathed in fluid. These changes affect both the nucleus and the cytoplasm and are characteristic of necrotic cells.

The chromatin of the nucleus may contract into a small, irregular, jagged mass and stain intensely (pyknosis), or divide into irregular masses which stain deeply (karyorrhexis), or gradually dissolve so that the nucleus stains less and less distinctly or not at all (karyolysis). These transformations are sometimes

simulated more or less closely by postmortem changes. Thus in the liver many of the nuclei often stain uniformly and intensely while the others appear normal, and in the convoluted tubules of the kidney the nuclei commonly fade away and refuse to stain after a certain number of hours.

The cytoplasm may become vacuolated from edema, hyaline from disappearance of its granules, coagulated and homogeneous so that it stains deeply with acid dyes, or dissolved by the action of ferments.

Certain types of necrosis have received special names.

Coagulation Necrosis.—Coagulation necrosis is a term applied originally by Weigert to the transformation assumed to take place in necrotic tissue in consequence of which, along with other changes, it swells slightly and becomes firmer than normal. It is supposed that the albumin of the cells, after the necrotic tissue has been permeated with fluid, undergoes some form of coagulation such as albumin does when acted on by formaldehyd, heat, alcohol, etc. Fibrin formation is not in the least essential to the process, although fibrin may be present in greater or less amount.

The classical example of coagulation necrosis is seen in an infarct of the kidney. Its gross characteristics are best studied there. Microscopically, the cells go through one or more of the changes peculiar to necrotic cells until finally they appear homogeneous and more or less fused with each other and with the surrounding blood-vessels and intercellular fibrils so that the whole forms a structureless mass.

The changes in the cells peculiar to coagulation necrosis may take place also in single cells and in groups of them. Thus, it is of frequent occurrence in the liver (focal necrosis), in striated skeletal muscle (Zenker's degeneration) and also in various infectious processes.

Caseation.—Caseation is a form of necrosis occurring especially in the lesions produced by the tubercle bacillus. It is due to the gradual necrosis (necrobiosis) of the leukocytes of the inflammatory reaction to the organism, and of any included tissue cells. As the cells are injured before they are killed they usually contain more or less fat.

The usual inflammatory reaction to the tubercle bacillus in blood-vessels consists of an accumulation of endothelial leukocytes. When, however, the organisms are in lymph-spaces and vessels or in epithelial-lined cavities, serum (much fibrin often forms from the serum) and a relatively small number of lymphocytes may be added to the leukocytes. The leukocytes, by occluding blood- and lymph-vessels, gradually cut off all nourishment. The tissue cells undergo necrosis first, because more delicate, and disappear; then

the leukocytes, beginning in the center of the lesion and extending peripherally, die off gradually in the same way. Caseation in tuberculous lesions consists chiefly, then, of necrotic endothelial leukocytes which have thoroughly infiltrated the tissue and destroyed most or all of its landmarks. Combined with the necrotic leukocytes there may be much fibrin of inflammatory origin.

Similar lesions may be produced by the oidium.

The caseation occurring in the lesions of syphilis is somewhat different. The reaction to the *treponema pallidum* consists of a moderate inflammatory exudation (usually endothelial leukocytes and lymphocytes, less often polymorphonuclear leukocytes) combined with reparative proliferation of fibroblasts. This process taking place in the walls of blood-vessels frequently leads to their occlusion and to necrosis of the tissue supplied by them. In these necrotic areas tissue landmarks such as blood-vessels, fat and fibrous tissues, and muscle can usually still be made out, although later they may disappear owing to the attraction often exerted by this necrotic tissue on endothelial and polymorphonuclear leukocytes. The necrosis in a gumma is, therefore, often much more like that in an infarct than in a tuberculous lesion.

Fat necrosis is a term applied to necrosis of multiple, disseminated, usually miliary but sometimes extensive, areas of fat tissue. The lesion occasionally occurs in the peritoneal cavity and is due to the action of digestive ferments which have escaped in some way from the pancreas. The pancreatic ferments act on the glycerids of the palmitic, stearic and oleic acids and splits them into free fatty acids and glycerin. The glycerin is absorbed and removed. The free fatty acids remain as needle-shaped crystals or unite with the calcium of the tissues to form an amorphous granular material. This causes the areas to have an opaque white appearance.

The necrotic areas at first attract polymorphonuclear leukocytes, but these are soon succeeded by endothelial leukocytes which surround and gradually absorb the fat products of the necrotic fat-cells. Occasionally, they fuse to form giant-cells.

Pancreatic tissue is often involved in the same way as the fat tissue and very rarely the ferments may extend to the muscles of the abdominal wall and cause extensive necrosis of them.

Colliquation or liquefaction necrosis is characterized by the fact that the necrotic tissue elements swell and dissolve in the tissue juices. The process is most common in the brain following ischemia. As the result of the softening cysts are formed.

Gangrene is a clinical term applied to two different conditions: (a) to necrotic tissue which is in such a location (toes, fingers) that when it undergoes infarction it may, under the influence of

the air, dry up (dry gangrene, mummification), or (b) to necrotic tissue anywhere (extremity, lung, appendix) which, under the influence of bacteria, undergoes putrefactive changes (moist, stinking gangrene, sphacelus).

Gangrene about the mouth has received the special name of noma. It is apparently due to the bacillus fusiformis acting alone or in conjunction with a spirillum.

Emphysematous gangrene is a condition of moist gangrene accompanied by the formation of gas. It is due in most instances to infection with the bacillus *aërogenes capsulatus*.

A line of demarcation due to acute inflammatory reaction is formed at the edge of gangrenous tissue just as around an infarction in the kidney or any other organ.

A marked inflammatory reaction takes place at the edge of necrotic tissue when the cells have been killed suddenly, as in a bland infarct of the kidney. This is due to toxins set free by the necrotic cells. On the other hand, there may be no reaction if necrosis comes on slowly as the result of gradual cutting off of the blood supply, because very little toxin is set free at any one time. The best examples are seen in tumors where the cells at a distance from the blood-vessels slowly die, dissolve and disappear without any inflammatory reaction being excited, leaving each vessel surrounded with a sheath of tumor cells and thereby suggesting a perithelial type of growth.

HYALINE SUBSTANCES

Numerous substances occurring in the body have the one common property of appearing transparent, like glass. These substances differ greatly in chemical composition. A few exhibit fairly definite chemical reactions; most of them do not. They will be considered under several different headings.

GLYCOGEN

Glycogen is a carbohydrate which easily changes into grape-sugar. It is a homogeneous hyaline substance which appears microscopically in the form of granules and small globules. It is the only one of the carbohydrates which is visible and demonstrable under the microscope.

Glycogen is fairly soluble in water and by this property is readily distinguishable from amyloid. In addition it is quickly changed to sugar by the action of saliva. Like amyloid it is stained brownish red by iodine. Stained with Best's carmin solution it appears red, while amyloid is colorless.

Glycogen when present occurs usually in the cytoplasm, but sometimes in diabetes is found also in the nuclei of the liver cells.

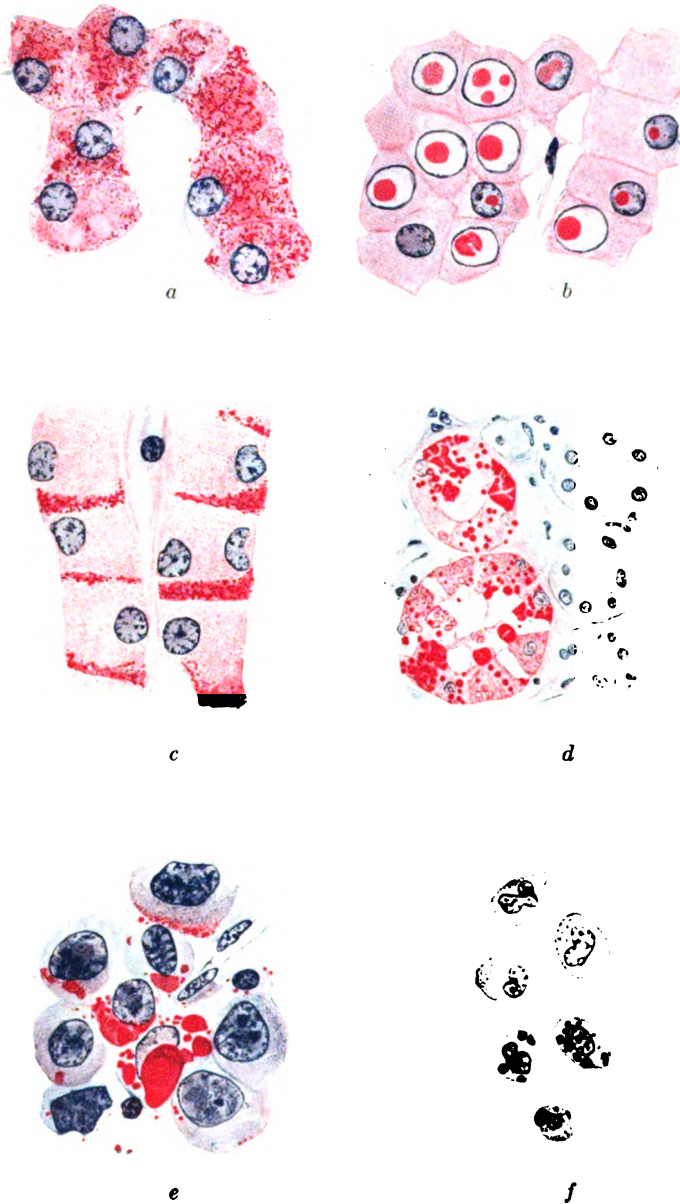


Fig. 38.—Glycogen in, *a*, liver cells; *b*, nuclei of liver cells; *c*, in liver cells (fixing reagent drives the glycogen to side of cell away from it); *d*, in kidney in diabetes; *e*, in an embryoma of the testicle; *f*, in polymorphonuclear and endothelial leukocytes.



Many cells under normal conditions contain glycogen permanently or temporarily. This is especially true of liver cells and striated muscle-fibers. It also occurs normally in cartilage cells.

Under pathologic conditions glycogen is frequently abundant. Thus, in inflammatory conditions it is common in the young fibroblasts and endothelial cells of granulation tissue. It is frequently contained also in epithelial cells. In persistent glycosuria and in diabetes glycogen occurs not only in the liver cells, but also in small to large globules in the epithelium of Henle's loops in the kidneys. It is also found in the cells of many tumors (adrenal cancers, chondromas).

MUCIN

Mucus is a hyaline slimy substance which occurs normally as a secretion of the epithelial (beaker) cells of the gastro-intestinal tract, as one of the homogeneous substances produced under certain conditions by the fibroblast (mucous connective-tissue cells of the umbilical cord), and in the fluids of joints, bursas and tendon sheaths.

Mucus is not a definite compound, but contains a group of nitrogenous, albuminous substances called mucins, which dissolve or swell up in water to form slimy stringy fluids. They are precipitated by acetic acid and by alcohol in the form of threads which are not dissolved by excess of the acid. They dissolve, however, after precipitation, in neutral salt solutions and in caustic alkalis.

In epithelial cells the mucus occurs as round, transparent masses which may be cast off as in ordinary beaker cells, or the drops of mucus may run together until the whole cell is transformed into a homogenous mass.

In mucous connective tissue the fibroblasts are more or less star-shaped, with branching cytoplasmic processes, and the mucus occurs between the collagen fibrils which are often widely separated. This type of tissue is widely distributed in the embryo, but is best exemplified in the umbilical cord (Wharton's jelly).

Under pathologic conditions the mucous secretion of epithelial cells may be much increased or the cells transformed into mucus. The cells of epithelial tumors arising from the gastro-intestinal tract often secrete mucus and sometimes masses of the tumor cells are gradually transformed into that homogeneous substance. Less often tumors arising in the mammary gland and in the ovary undergo mucous degeneration. The epithelial tumors arising from the ovary are more likely to contain pseudomucin, a homogeneous slimy substance which is precipitated by alcohol but not by acetic acid.

While mucus is not produced normally in the adult by fibroblasts, it occurs not infrequently in tumors of mesenchymal origin; for example, in fibroma, chondroma, osteoma and in the rapidly growing tumors composed of the same type of cell (myxosarcoma, etc.). It occurs also in mixed tumors of the parotid region, and not infrequently in the connective-tissue stroma of certain epithelial new-growths.

AMYLOID

Introduction.—Amyloid is a homogeneous, translucent, colorless, solid substance characterized by fairly definite chemical reactions which distinguish it from the other hyaline substances.

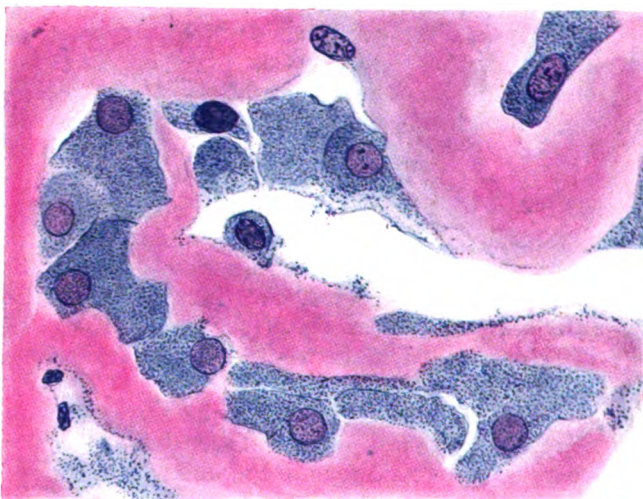


Fig. 39.—Amyloid formation in liver. Methyl-violet reaction for amyloid.

According to Krawkow it is a combination of an albuminous body with chondroitin sulphuric acid. The latter substance is found especially in cartilage and elastic tissue.

Amyloid is not a product of degeneration of cell or fibril, or something filtered out of the blood like serum. Instead it is a deposit in tissues manufactured out of normal constituents of the blood by cell activity, as will be explained farther on.

Properties.—Amyloid is insoluble in water and in alkalis, and dissolves with difficulty in strong acids. Treated with Lugol's solution, it stains mahogany brown while the surrounding tissue appears of a yellow color. On the addition of one per cent sulphuric acid the brown may turn to blue, violet or green; the reaction is not constant. Sections stained with methyl-violet followed by

dilute acetic acid show the amyloid rose red, the nuclei blue, and the other structures pale blue or colorless. Methyl-green and certain other anilin dyes give a similar metachromatic color reaction. The reaction with the anilin stains is considered more reliable than that with iodine.

Origin.—Amyloid does not exist as such in the blood. By some it is claimed that it is manufactured by cell activity out of a substance in the circulation. It seems to be generally assumed, owing to the deposition of amyloid to a large extent just outside of the endothelial cells lining blood-vessels, that they are the cells active in its production.

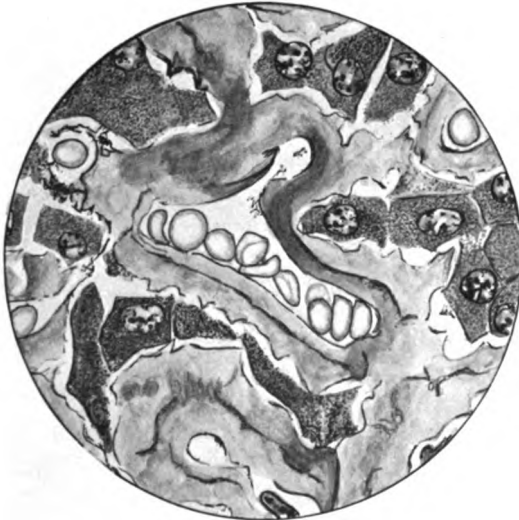

Fig. 40.—Liver. Amyloid formation. Pressure atrophy of liver cells.

It seems more reasonable to regard amyloid as an abnormal product of the fibroblast; in support of this view a certain amount of evidence can be brought forward. The ordinary fibroblast is capable of producing under different conditions a variety of fibrils and homogeneous substances (fibrogia, collagen and elastic fibrils; mucin, chondromucin and osseomucin). It seems more likely that the normal metabolism of the fibroblast should be so altered by functional disturbances as to produce an abnormal product, than that endothelial cells should develop the property of manufacturing such a substance.

The chemical composition of amyloid, namely, the presence of chondroitin sulphuric acid is in favor of the origin of amyloid

from fibroblasts because it is found in other products of these cells, namely, in elastic fibrils and in chondromucin.

The position of amyloid is around the fibroblasts, around and between the collagen fibrils. This is true not only in the walls of

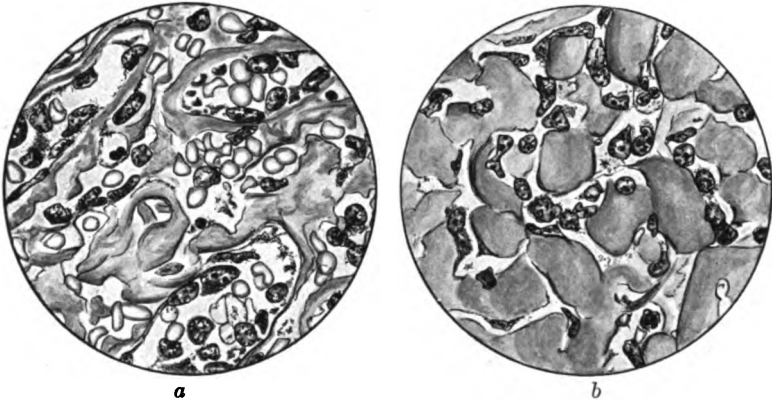


Fig. 41.—Amyloid formation in spleen. *a*, In pulp; *b*, in lymph-nodule.

the smaller blood-vessels just outside of the lining endothelium, but also around the tubules of the kidney, between the smooth

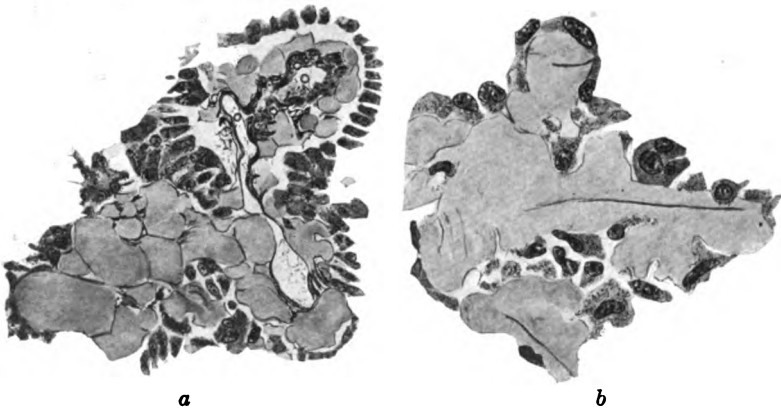


Fig. 42.—Tumor (lymphoblastoma ?) with extensive amyloid formation in stroma.

muscle-cells in the walls of arteries and in places where no endothelial cells are present.

Amyloid is manufactured chiefly in certain situations and usually close to blood-vessels; in the liver between the walls of

the sinusoids and the columns of liver cells, in the glomeruli of the kidneys, in the lymph-nodules of the spleen and lymph-nodes and around the reticulum of the spleen, in the islets of the pancreas.

The occurrence of local amyloid when there is no systemic disturbance of metabolism favors this view of the origin of amyloid, as well as the occurrence occasionally of amyloid in the stroma of tumors.

Fibroblasts often produce a hyaline substance resembling amyloid except in reaction.

Amyloid is formed in consequence of some disturbance of cell metabolism. This disturbance may be general or local. In general amyloid formation various organs may be affected; for example, the liver, spleen, kidneys, intestine, etc. In local amyloid formation the substance may be confined to a single site.

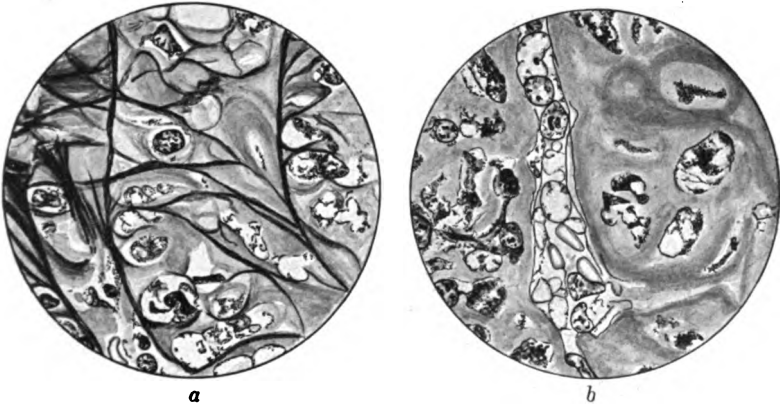


Fig. 43.—Amyloid formation in adrenal gland. *a*, Collagen fibrils still apparent in the midst of the amyloid; *b*, marked atrophy of adrenal cells.

General Amyloid Formation.—Amyloid occurs in a variety of cachectic conditions, especially when there has been much loss of albumin. Thus, it is found in cases of prolonged suppuration from any cause and in any location; but it also occurs under other conditions when there has been no pus formation. The following list is illustrative but by no means complete.

- A. Chronic ulcerative tuberculous lesions of lung, intestine or bone.
 - Actinomycosis.
 - Chronic dysentery.
 - Ulcerating new-growths (carcinoma of stomach, etc.).
- B. Chronic syphilis.
 - Chronic nephritis.

Malarial cachexia.**Chronic anemia.**

General amyloid formation may be produced experimentally in animals by causing prolonged suppuration, and occurs commonly in the rats and mice used for carcinoma propagation.

Local amyloid formation is rare. The amyloid may occur in tumor-like swellings at the base of the tongue, in the mucous membrane of the larynx, trachea and bronchi, in the eyelids and diffusely in the wall of the urinary bladder. It also occurs occasionally in the stroma of certain tumors without being present elsewhere in the body. The cause of its formation is unknown, but is probably due to some disturbance of metabolism in fibroblasts, as the result of local chemical action.

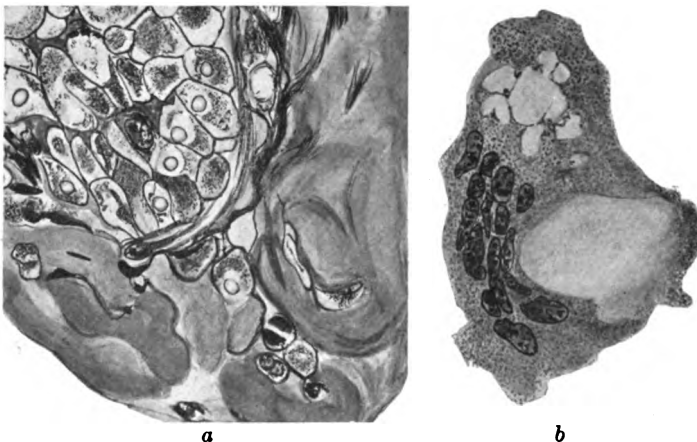


Fig. 44.—Urinary bladder. Amyloid formation. *a*, Atrophy of muscle-fibers from pressure by amyloid; *b*, amyloid taken up as a foreign body by a giant-cell.

As already stated, amyloid is always found in close relation to fibroblasts. It is deposited between the collagen fibrils which, at first, in properly stained sections stand out distinctly, but later disappear. Amyloid when first deposited is finely fibrillar, but soon becomes homogeneous. Amyloid, like the other products of the fibroblast, requires the care of the cell. When this is removed by the death of the cell the amyloid becomes a foreign body and is attacked and dissolved by the action of endothelial leukocytes which sometimes fuse to form giant-cells. Tumor cells may also attack the amyloid when it is formed in the stroma of the new-growth and utilize it as food.

Effect.—Amyloid exerts mechanical pressure; hence it causes gradual atrophy and disappearance of the important functioning or parenchymatous cells in the organs affected; for example, the liver cells in the liver, the lymphoblasts in lymph nodules of the spleen and lymph-nodes. It destroys the glomeruli in the kidneys, and hence leads to degeneration and atrophy of the tubular epithelium. The result is sclerosis of the kidney.

Gross Appearance.—Amyloid frequently leads to increase of size and consistence of the organ in which it is found. The kidney, however, in the late stage may be smaller than normal owing to atrophy and disappearance of many of the tubules. Amyloid organs are usually pale and translucent and have a dry appearance. Amyloid is evidently of a tough consistence because the walls of affected arteries never dilate or rupture.

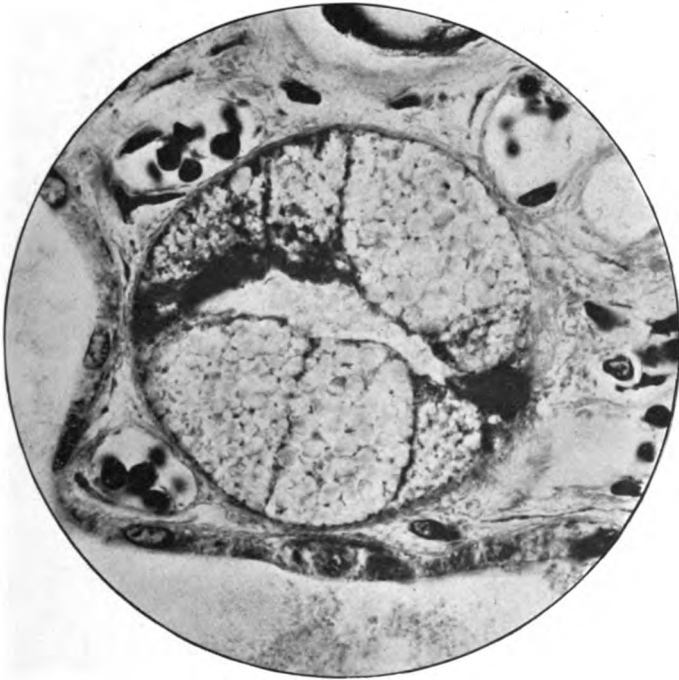

Fig. 45.—Colloid in epithelial cells lining a tubule in the kidney. M.

COLLOID

The term colloid is applied to the transparent, semisolid secretion of the thyroid gland. Unlike mucus it remains homogeneous after treatment with alcohol or acetic acid. It is characterized chemically by containing iodine in the form of iodothyron. The acid dyes tend to stain it rather deeply.

The term colloid is also applied to other homogeneous substances of epithelial origin which in appearance and consistence resemble the colloid of the thyroid gland, although chemically they may differ markedly from it. This is especially true of certain hyaline substances appearing as droplets in the renal cells and as casts in the tubules of the kidney.

The colloid material derived from the epithelial cells in the glands of the prostate usually takes the form of rounded concentrically layered masses called corpora amylacea, because in the early days of pathology they were incorrectly supposed, on the basis of a single chemical reaction, to be related to starch. Similar bodies sometimes occur in the alveoli of the lung and may be formed in large numbers in cysts of the kidney. Similar bodies, usually smaller in size, are sometimes formed in large numbers in the central nervous system, especially beneath the pia, when retrograde changes are in progress.

FIBRIN

Fibrin is usually fairly definitely characterized by its appearance in the form of delicate to coarse anastomosing threads and by its staining reactions. But it may also appear as a coarse hyaline reticulum (diphtheritic membrane) and as hyaline spherules (in liver cells in beginning central necrosis). Necrotic cells and fibrils and red blood-corpuscles bathed in serum frequently undergo a hyaline change due to the formation of fibrin. In this way hyaline masses of various sizes and shapes may be formed in blood-vessels (hyaline thrombi) and in the tissues.

HYALIN

Hyalin in the Liver.—In alcoholic cirrhosis the liver cells undergo a peculiar and apparently characteristic type of hyaline change preceding necrosis. The cells swell somewhat and in the cytoplasm appears a coarse hyaline meshwork which tends to stain deeply with eosin and methylene-blue and with phosphotungstic acid hematoxylin.

In a normal individual in whom violent injury caused sudden death the liver was studded with small, sharply defined, light colored areas, up to several millimeters in diameter. Microscopically the liver cells in these areas are homogeneous and hyaline, but do not tend to stain deeply with eosin; all the granules have disappeared from the cytoplasm. The nuclei stain about normally. Possibly the appearance is due to beginning coagulation necrosis following concussion, and is analogous to the hyaline change which takes place in striated muscle after rupture and other injuries.

Hyalin in Plasma Cells.—It is not uncommon for hyaline droplets of various sizes to develop in the cytoplasm of plasma cells. They stain faintly to deeply with acid dyes and are brought

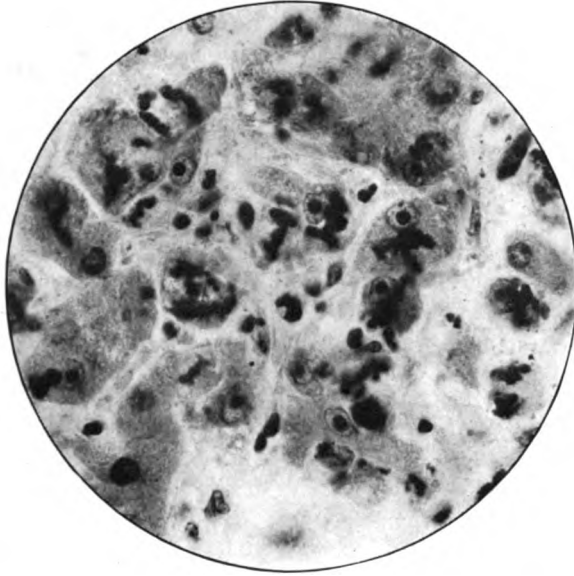

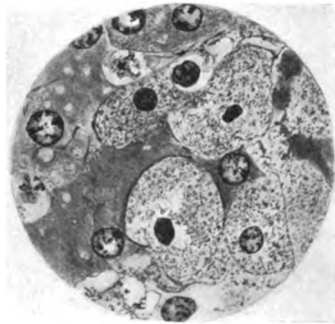


Fig. 46.—Liver. Alcoholic cirrhosis. Hyaline material in cytoplasm of liver cells. M. and W.



a



b

Fig. 47.—Liver. Sudden death from violence. Hyaline areas apparently due to coagulation and loss of cell granulations.

out prominently by the fuchsin in the tubercle bacillus stain. After death of the cell these hyaline droplets may persist for some time in the tissues. They were once claimed to be parasites and

the cause of cancer. As a result of this notoriety they are still often called "Russell's fuchsin bodies."

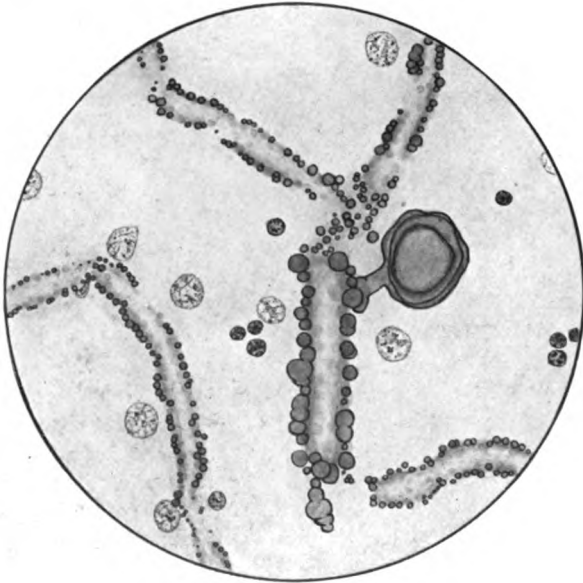


Fig. 48.—Hyaline material forming in and on the walls of capillaries in the cerebellum.

Hyalin in Blood-vessels.—In the blood-vessels of the brain in general, but especially in the cerebellum, hyalin occasionally occurs in the form of multiple small droplets which gradually enlarge and fuse together so as to form homogeneous hyaline walls to the vessels. Sometimes all the capillaries over considerable areas are sheathed in this way. Concentric masses of various sizes are also frequently formed outside of the vessels. As a result of the hyaline deposit, thickening and fusing, the intervening cells atrophy and disappear, so that large masses of hyalin may be formed. Lime salts are usually deposited in this hyalin. As a result calcareous masses of considerable size and rigid blood-vessels are sometimes formed. Later, the calcified masses may become ossified owing to organization by fibroblasts.

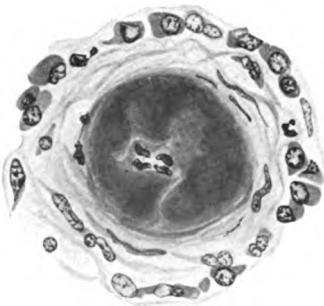


Fig. 49.—Artery. Arteriosclerosis. Hyaline formation with narrowing of lumen.

In various acute infectious diseases the arteries in the spleen show another type of hyaline change. The walls appear hyaline and very noticeably swollen so that the lumen is encroached on. A Scharlach R. stain always shows much fat present. A similar appearance is presented by lesions of a chronic type appearing in the condition known as arteriosclerosis.

Hyalin in Smooth Muscle-cells.—The central portion of smooth muscle-cells often presents a thickened hyaline appearance and stains deeply with eosin. This is a postmortem change. It is especially common in the muscle-cells of the prostate, but may occur in smooth muscle anywhere.

Zenker's Degeneration.—Necrotic striated muscle undergoes usually a change, called coagulation necrosis, as a result of which the striations disappear and the cytoplasm becomes homogeneous. To this form of hyaline change in striated muscle the term Zenker's degeneration is applied because the process was first described by him. Sometimes this hyaline change fails to

take place and the striations persist until the necrotic muscle is entirely dissolved by the action of leukocytes.

Hyaline Connective Tissue.—The collagen fibrils of connective tissue are often, under certain conditions, rendered invisible, as they usually are in cartilage and bone, and probably in the same way, by the deposition of a homogeneous substance between them, which binds them intimately together. Thus, hyaline connective tissue is frequently found in the lymph-nodules of lymph-nodes and of the spleen following inflammatory changes; in old healed tuberculous lesions; in sclerosed glomeruli.




Fig. 50.—Necrosis and hyaline transformation of skeletal muscle-fibers (Zenker's degeneration).

PIGMENTS

Certain substances possess more or less color. The formation or deposition of such substances in the body is called pigmentation, and the colored materials themselves are spoken of as pigments. Pigments may appear in homogeneous, granular or crystalline form. They are divided according to their origin into two classes: endogenous, those which originate within the body and exogenous, those which enter the body from without. The endogenous

pigments are further divided into two groups: autogenous, those formed by the cells themselves; hemoglobinogenous, those derived directly or indirectly from the hemoglobin of the blood.

A. AUTOGENOUS PIGMENTS

There are several kinds of pigment produced by cell metabolism of which the most important is melanin.

1. **Melanin** is the pigment which gives the color to the skin, hair and eyes. It occurs within cells in the form of brown to black granules. Its chemical nature has not been definitely determined, but it does not seem to be due to blood pigment.

In the skin melanin is found in the deepest layers of epithelial cells and also in the melanoblasts or pigment cells of mesenchymal origin which occur in the corium. It seems probable that the epithelial cells of the epidermis do not produce the pigment themselves, but that it is transferred to them from the melanoblasts, the only cells which produce this pigment. This view is favored by the fact that the cells of epidermoid cancers, even in a negro, never produce pigment.

Melanoblasts occur also in the choroid and iris and in the pia, especially over the medulla. Abnormal collections of them often develop in the skin soon after birth, and are known as pigment nevi. From the melanoblasts in any of these locations melanoblastomas may arise. The pigment produced by them is sometimes so abundant that it is excreted by the kidneys and appears in the urine.

In the symptom complex known as Addison's disease a brown granular pigment, apparently similar in nature to melanin, is deposited in the epithelial cells of the skin and in the mucous membrane of the mouth. It is probably produced by the melanoblasts.

2. **Lutein** is a soluble coloring matter found in fat-cells and in the corpus luteum. It occurs in fat tissue, in lipomas and in the collections of cells to which the name xanthoma has been applied.

The nature of the green color occurring in the tumor nodules of myeloblastoma, which under this condition is called chloroma on account of its color, is not known. It fades quickly on exposure to air but can be restored, temporarily at least, by treatment with peroxide of hydrogen and also with other chemical reagents.

3. **Lipochrome** is a pigment which, with advancing age, collects in the muscle-fibers of the heart, in liver cells, in the zona pigmentosa of the adrenal, in certain ganglion-cells, in the smooth muscle-cells of the intestine and seminal vesicles, and often abundantly in the epithelial cells of the same vesicles. This pigment reduces osmium tetroxide and stains with Scharlach R.

B. HEMOGLOBINOGENOUS PIGMENTS

Hemoglobin is the normal coloring matter of the blood. It is manufactured by the erythroblasts and remains as the characteristic feature of the red blood-corpuscles after disappearance of the nuclei. It contains iron but does not give the iron reactions, owing to close chemical union with other substances. Hemoglobin may be set free in the tissues and in body cavities by diffusion or in consequence of disintegration of the red blood-corpuscles following hemorrhage, or it may escape into the serum of the circulating blood (hemoglobinemia) as the result of injury to the corpuscles by toxins. If it escapes into the serum in large amount it is excreted by the kidneys (hemoglobinuria) and may be deposited in the renal tubules as brown masses and color the papillæ a dirty brownish red (hemoglobin infarct).

Hemoglobin in solution is precipitated by formaldehyd in the form of black granules which often collect in clumps. This pigment formation is common in tissues which have been placed some hours postmortem or after removal from the body in fixatives containing formaldehyd. The pigment is an artefact and must be recognized as such.

Hemoglobin as the result of chemical change gives rise to two pigments known as hematoidin and hemosiderin.

1. **Hematoidin** is an iron-free pigment occurring as granules and crystals which vary in color from yellow to red. It arises from hemoglobin in solution and does not owe its origin like hemosiderin to vital activity. After formation, however, hematoidin may be taken up by endothelial leukocytes.

Feathery yellow crystals of hematoidin arranged in radiate form often occur in infarcts of the spleen, especially at the periphery of the lesion, and are frequently within endothelial leukocytes and foreign body giant-cells.

2. **Hemosiderin** is a collective term for yellow to brown pigments which are derived from hemoglobin and give the iron reaction. They occur as granules and small masses. They may arise directly from hemoglobin still attached to red blood-corpuscles or from hemoglobin in solution. They require vital activity for their formation. Ordinarily endothelial leukocytes transform red blood-corpuscles directly into hemosiderin, and they can perform the same function for hemoglobin in solution. It seems probable, however, that hemoglobin in solution can also be transformed into hemosiderin by vital activity without being taken up by cells, probably through the action of chemical substances derived from the cells.

Hemosiderin is found very commonly following hemorrhage;

in the corpus hemorrhagicum as it undergoes repair; in the lungs following hemorrhages as the result of chronic passive congestion; in the meninges owing to chronic internal hemorrhagic pachymeningitis; in the brain following cerebral hemorrhage. In all of these situations the hemosiderin occurs for the most part within endothelial leukocytes. In the lungs these leukocytes are usually known as heart failure cells. If they contain carbon, as they often do, the hemosiderin is deposited around it.

All hemosiderin is very gradually decolorized and disintegrated by the leukocytes containing it and returned in some other form to the circulation.

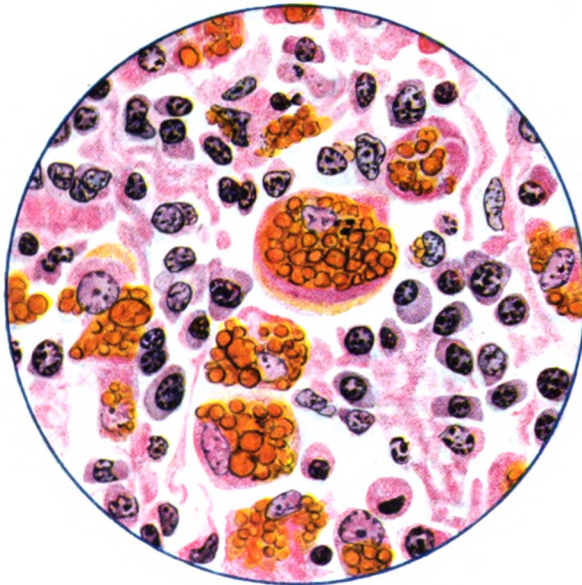


Fig. 51.—Blood pigment in endothelial leukocytes in spleen following typhoid fever.

In typhoid fever and some other infectious diseases endothelial leukocytes, filled with red blood-corpuscles, often collect in small to large numbers in the spleen and to a less extent in the bone marrow, and gradually transform the hemoglobin into hemosiderin.

When hemoglobin is set free slowly and continuously for a long time in the serum, as in pernicious anemia and in certain forms of chronic poisoning, the epithelial and endothelial cells in many organs—liver, spleen, bone marrow, kidneys, heart, pancreas—take up the pigment and store it in the form of yellowish

brown granules which may be readily distinguished from any lipochrome pigment present by means of the iron reactions. When the hemosiderin deposit is extensive the organs may appear of a rusty brown color.

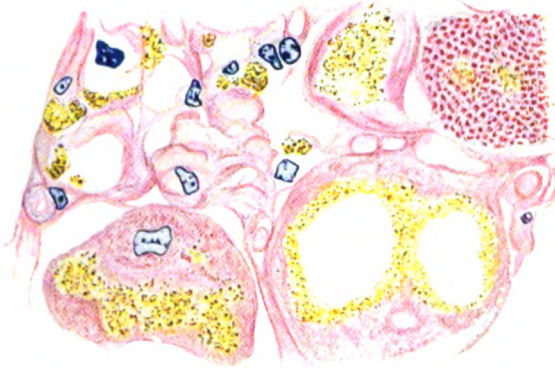
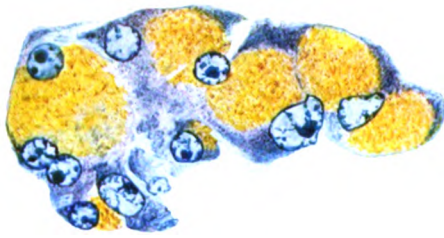
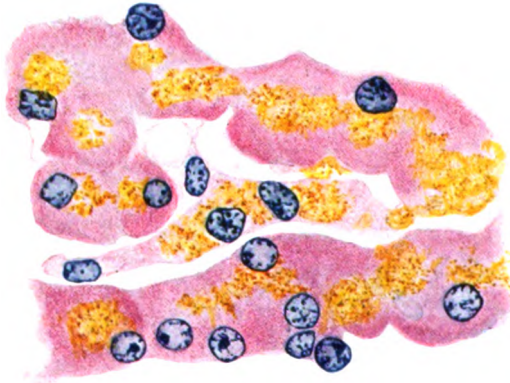


Fig. 52.—Hemochromatosis. Pigment in muscle-fibers of heart. Following necrosis of the muscle-fibers the pigment is taken up by endothelial leukocytes.

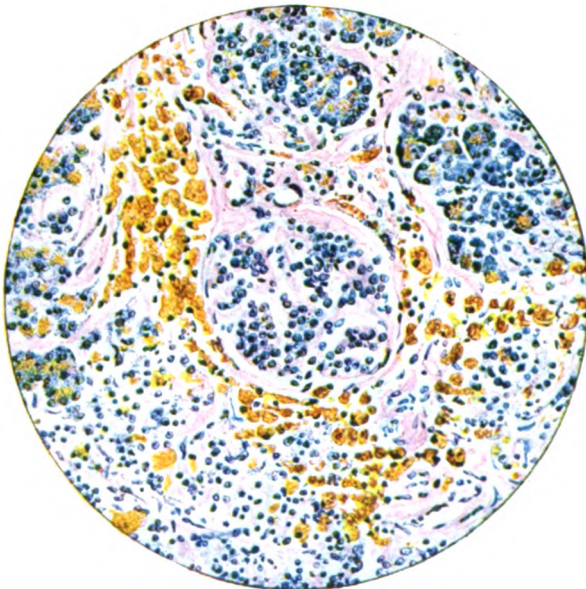
In a rare symptom complex known as **hemochromatosis**, because the pigmentation in the liver and some other organs is the most conspicuous feature, hemosiderin is formed in large amounts and is found in various cells, such as the epithelium of the kidneys,



a



b



c

Fig. 53.—Hemochromatosis. *a* and *c*, Pigment in pancreas; *b*, pigment in liver cells.

liver and pancreas, the muscle-fibers of the heart, the endothelial cells of various organs, but most abundantly in endothelial leukocytes which often collect in great numbers in the liver and to a less extent in the spleen, lymph-nodes, pancreas, etc.

The hemosiderin is apparently deposited in such large amounts in some of the parenchymatous cells of the heart, pancreas and especially of the liver, that it leads to their destruction. The pigment set free in this way by necrosis of the affected cells attracts endothelial leukocytes. As a result of this process there often occur in the liver extensive lesions, forming one type of cirrhosis with increase in size, owing to the extensive infiltration with endothelial leukocytes. Similar lesions, but on a smaller scale, occur in the pancreas (resulting in so-called bronze diabetes) and in the heart.

Pigmentation is of common occurrence in the liver, spleen and bone marrow in malaria. The pigment occurs in endothelial cells and leukocytes and is of two sorts; hemosiderin derived from hemoglobin and a black pigment of unknown composition which is formed in some way in the red corpuscles by the activity of the malarial organisms, but whether from hemoglobin or from other substances is not known.

3. Bile Pigment.—Bilirubin, the coloring matter of the bile, is chemically identical with hematoidin. It is a product of the liver cells, being formed by them from hemoglobin.

Bile sometimes escapes into the circulation either as the result of bile stasis or in consequence of necrosis of liver cells, and diffuses into the organs and tissues, staining them a yellow to green color. The resulting condition is known clinically as icterus or jaundice.

Bile stasis is caused throughout the liver by obstruction of the bile duct or the common duct, usually by gall-stone or tumor, or focally by obstruction of the smaller bile vessels by inflammatory exudation, by sclerosis, or by pressure from an infiltrating tumor. Bile stasis results in dilatation of the bile capillaries, most marked around the hepatic vein in each lobule. The bile often breaks through the wall of liver cells and escapes into the lymph-space between the cells and the walls of the sinusoids. Here the inspissated masses are incorporated and gradually digested by endothelial leukocytes. The fluid bile apparently passes directly into the circulation through the endothelium lining the sinusoids and is carried all over the body. It stains nearly all tissues yellow. If the icterus is persistent the color may turn to green.

When the liver is severely injured by toxic and infectious processes (phosphorus poisoning, acute yellow atrophy, sepsis) bile escapes into the circulation. This is due in some instances at least to necrosis and dissolution of the liver cells allowing the bile to escape from the bile capillaries.

Icterus is always of hepatogenous origin. This is shown by the constant presence in the blood of bile acids, which can arise only in the liver. Enough hematoidin (chemically identical with bilirubin) is never set free by diffusion from hemorrhage, or by breaking down of the corpuscles within the circulation to cause icterus.

Bile pigment usually diffuses and simply stains most cells and intercellular substances, but the central nervous system is never colored in the adult and rarely in children. Necrotic tissue, on the other hand, is readily stained as shown by the classical examples, the sloughs in the intestine in typhoid fever and the caseous tubercles involving the bile ducts in the liver.

Sometimes the bile pigment is deposited in granules which are usually yellowish but may be greenish if old. They occur most commonly in the liver cells, in the endothelial cells lining sinusoids and capillaries, in renal epithelium, etc. The pigment itself does not seem to be injurious to cells, but the accompanying invisible bile acids and other substances may do damage.

Bile pigment is very rarely found in crystalline form in the adult as a result of postmortem changes; in the macerated fetus its occurrence is more common.

C. EXOGENOUS PIGMENTS

Several pigments which frequently or occasionally occur in the body are derived from outside sources, for example, carbon and lead. They may be taken into the body in granular form as pigments (carbon), or be formed after ingestion from colorless compounds in solution (nitrate of silver). The most common pigments of extraneous origin are carbon and the various colors used in tattooing; of rarer occurrence but greater clinical interest are lead and silver.

1. **Carbon** enters the body through the respiratory tract. It often collects in considerable quantities in the alveoli of the lung, where it appears as greenish black to black granules. Much of it is expectorated. The rest of it is slowly taken up by endothelial leukocytes, which migrate with it into the lymph-spaces in the walls of the alveoli, which, in consequence, may be much thickened. Many of the leukocytes filled with carbon collect in the lymphatics around the blood-vessels and bronchi. Still others are carried by the lymph to the peribronchial lymph-nodes where they infiltrate the lymphoid tissue and lead to its disappearance. Occasionally they are transported to the spleen or liver. Very rarely carbon gets into the circulation in considerable quantities through some infectious process which causes softening of lung or lymph-node tissue containing carbon; the softened focus may rupture

into a blood-vessel or the thoracic duct. Carbon may then be carried in considerable quantities to the spleen, liver and bone marrow and there be deposited.

If hemoglobin is taken up by leukocytes already containing carbon, it is transformed and deposited as hemosiderin around the carbon.

Carbon in the tissues is indestructible. It persists indefinitely in the endothelial leukocytes unless involved in a tuberculous or other infectious lesion which causes destruction of the cells. After repair of the lesion the carbon may be found in scattered granules in the scar tissue instead of in the masses due to its collection within leukocytes.

2. Various pigments (vermilion, charcoal, etc.) are introduced into the skin in the process of **tattooing**. Some of them are carried to the adjoining lymph-nodes where they remain stored in endothelial leukocytes in the same way that carbon does. The rest of them persist in the corium.

3. **Lead** in the form of soluble salts is often taken into the body by men working in certain trades, painting for example. It is sometimes deposited as brownish black granules of lead sulphid in the subepithelial tissue of the gums, owing to chemical action following lack of cleanliness of teeth and mouth.

4. **Silver** under rare conditions is precipitated in certain tissues and causes a brownish discoloration of the skin known as **argyria**. The condition follows the long-continued ingestion of silver salts, usually the nitrate, as a medicament. The silver is precipitated from its solution by certain cells, especially the fibroblasts in the medulla of the kidney and by the smooth muscle-cells connected with the hairs and around the coil glands in the skin.

In one instance where much colargol was injected into the substance of a kidney, on the supposition that a cyst was present, silver was found precipitated most extensively in brown and black granules in multiple foci throughout the organ.

PETRIFICATION

Petrification is a general term applied to the deposit of certain solid, crystalline, granular or amorphous salts in the tissues, vessels and cavities of the body. The deposit may consist of lime salts, uric acid salts, bile pigments, or cholesterin crystals.

LIME SALTS

Two different terms are applied to depositions of lime salts according as the salts are in relation to bone cells or to other cells and substances.

1. **Ossification**.—Lime salts in the forms chiefly of phosphate

and carbonate of lime are present in all normal tissues and fluids. Under ordinary conditions they are attracted and deposited in granular form only in the homogeneous ground substance, osseomucin, of bone. This is termed ossification. The lime is deposited around living cells, the bone cells, whose function it is to protect and care for the intercellular substances and the lime deposited in them. The same deposition of lime salts takes place also in the osteoid substance of the callus formed in the repair of injuries of bone and in the tumors arising from osteal fibroblasts (osteoma, etc.).

2. **Calcification.**—Under pathologic conditions other substances than osseomucin may attract lime salts. Thus with advancing age they are frequently deposited in chondromucin, the ground substance of cartilage. It may almost be regarded

as a physiologic process. Here, although the cells are living, the process is called calcification because the cartilage cells are not transformed into bone cells. In a similar way, but less often, lime salts may be deposited in the intercellular substance of connective tissue especially if hyaline (blood-vessels, kidneys).

The lime salts deposited in calcification are in about the same proportion as in normal bone; and that is about the same as the normal proportion in the body fluids, namely,

calcium phosphate over 80 per cent., while the rest consists of chlorids, carbonates, fluorids and sulphates of calcium, sodium, potassium and magnesium.

Frequently substances not connected with living cells attract lime salts; to this condition the term calcification is also applied. Thus necrotic ganglion-cells in the brain, necrotic smooth muscle-cells in the aorta and arteries and necrotic tissue anywhere may become calcified. A classical example is the lithopedion due to the deposition of lime salts in a dead fetus carried for years in the abdominal cavity. Calcification is common in the caseous material of old tuberculous lesions, in necrotic retained placentas and especially perhaps in necrotic portions of tumors (leiomyomas).

Lime salts are very commonly deposited in various homogeneous substances, the products of secretion and degeneration;

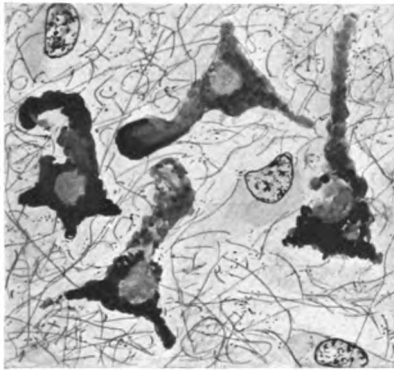


Fig. 54.—Calcified ganglion-cells in brain.

thus in concretions in the prostate, in the pineal gland, in the choroid plexus, in hyaline vessels of the brain, in casts in the renal tubules, in dural endotheliomas, in so-called psammomas of various origins. If the lime salts are dissolved out by means of nitric

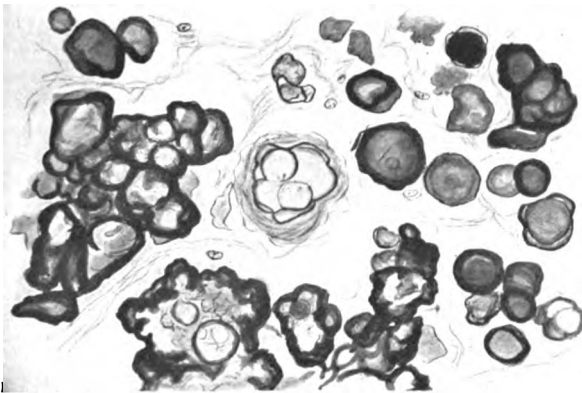


Fig. 55.—Calcified corpora amylacea in pineal gland.

acid the homogeneous base in which they were deposited is easily rendered visible.

Fibrin or substances in it frequently attract lime salts; the commonest examples occur in old fibrinous deposits in the pleural

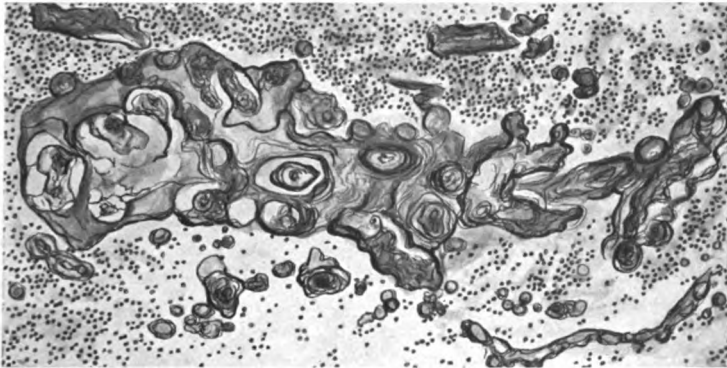

Fig. 56.—Calcified hyaline capillaries and corpora amylacea in cerebellum.

cavity, in thrombi in veins (phleboliths), in hemorrhages (eyeball), in endocarditis.

Fat products seem unquestionably to play some part in the deposition of lime salts. The aorta and other blood-vessels afford

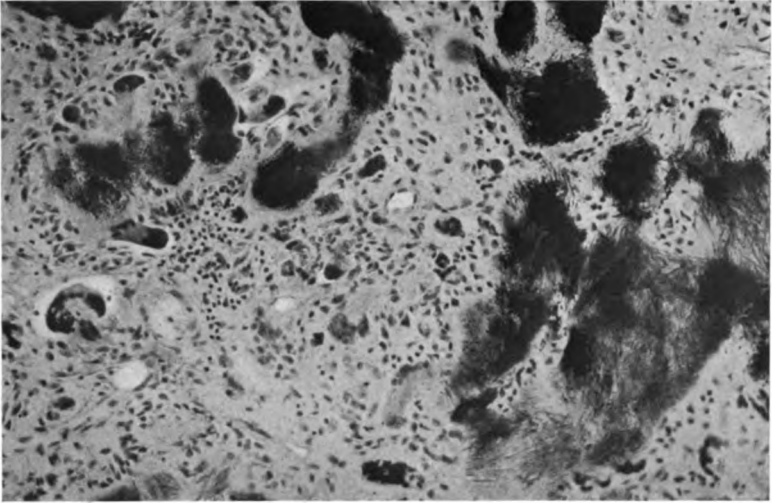


Fig. 57.—Gout. Granulation tissue containing masses of biurate of sodium crystals and also numerous giant-cells. M.



Fig. 58.—Gout. Tophi in ear. O.

numerous examples. For this reason probably caseation often attracts lime-salts, while gummas and infarctions rarely do. Lime is also very commonly deposited in the capsules of encysted trichinae.

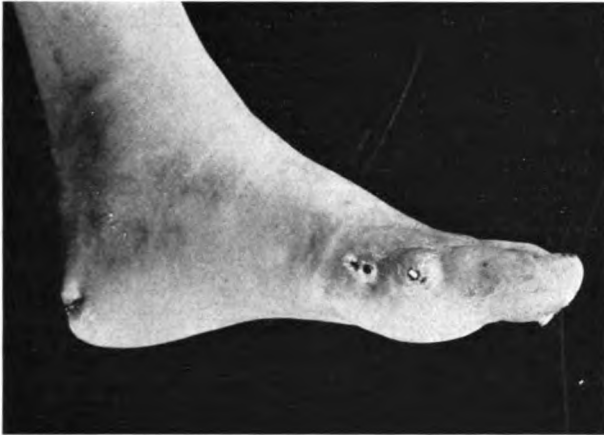

Fig. 59.—Gout. Tophi in foot. One mass of crystals protrudes through base of ulcer. O.

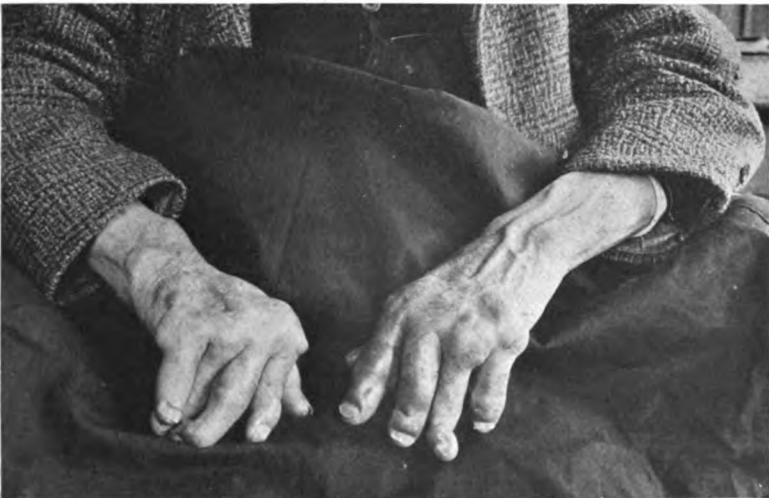

Fig. 60.—Gout. Tophi in subcutaneous tissue of hands. O.

The ordinary fibroblast is apparently incapable of producing osseomucin, attracting lime salts and converting itself into a bone cell. But if free lime salts are deposited in its immediate territory they have the property of stimulating that fibroblast so that it

grows into a true bone cell. This is what regularly happens to the fibroblasts which organize the fibrin due to a hemorrhage into the eyeball. The same transformation of an ordinary fibroblast into a bone cell is of common occurrence in blood-vessels and also happens elsewhere, as in a glioma of the brain for instance.

URIC ACID AND ITS SALTS

Under normal conditions urates are present in solution in the circulation and by excretion through the kidneys are kept below any injurious percentage in the blood.

In new-born infants dying within the first few days or weeks after birth it is common to find yellow to yellowish-red streaks in the papillæ of the pyramids.

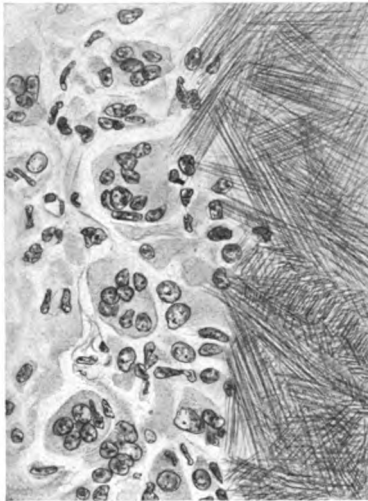


Fig. 61. — Gout. Endothelial leukocytes and giant-cells adjoining biurate of sodium crystals.

They are due to a precipitate of uric acid and ammonium urate crystals in the tubules. Microscopically these salts appear in the form of fine and coarse crystalline masses. Evidently they are due to a precipitation from the urine during its excretion. The appearances above described are called uric acid infarcts, but are neither the cause nor the result of local injury. Probably they are due to altered metabolism and a concentrated urine.

Under abnormal conditions uric acid and its salts may accumulate in the circulation beyond the normal amount. In the pathologic condition known as gout they are deposited in the

tissues as biurate of sodium in the form of bundles of delicate needle-shaped crystals which often coalesce into solid, mortar-like nodules known as tophi.

The biurate of sodium crystals are deposited most frequently in the lobe of the ear, in the cartilages and capsules of joints and in the surrounding connective tissue, but they may occur anywhere in the subcutaneous tissue. They act as an injurious agent, whose effect is probably mechanical, and cause necrosis and acute inflammatory reaction. In the granulation tissue formed around the crystals foreign body giant-cells are usually numerous.

The cause of the deposit of the biurate of sodium crystals is not definitely known.

PATHOLOGIC CORNIFICATION

The cells of the epidermis pass through certain characteristic changes before they become cornified. They develop epithelial fibrils and kerato-hyalin and eleidin granules and, finally, are transformed into the keratin of the cornified layer. These same characteristics are present under pathologic conditions and frequently one or another of them is magnified. Thus cornification may be increased in hyperkeratosis and ichthyosis. In psoriasis it is said to be diminished.

Cornification may occur in situations where it does not appear under normal conditions, as on the tongue (hairy tongue), in the vagina, esophagus, urinary bladder, pelvis of kidney, gall-bladder, bile ducts, usually as the result of chronic irritation of some sort or other causing change in the type of growth of the cells (metaplasia).

Occasionally in the middle ear cornified epithelium is found accumulated in a mass completely filling the cavity. Similar masses sometimes of large size occur not infrequently in simple or multiple form in connection with the central nervous system, usually in the meninges, and are known as cholesteatomas. They are abnormalities due to desquamation and accumulation of dead cornified epithelial cells over the surface of clumps of epidermal cells displaced from their normal surroundings at the time of the formation of the neural canal. The material of similar appearance in the middle ear may be of similar origin or due to metaplasia of the lining epithelium.

Cornification is common in epidermoid carcinomas and is sometimes very conspicuous, even when this type of tumor arises in a location where normally no epidermis exists.

SPECIAL INJURIOUS AGENTS AND THE LESIONS THEY PRODUCE

STAPHYLOCOCCUS PYOGENES AUREUS

Of the several varieties of pathogenic staphylococci the aureus, from the pathologic point of view, is by far the most important and is the only one which will be considered here. What is said of it in the following pages is applicable, however, although in a decidedly minor degree, to the albus and citreus.

The staphylococcus aureus causes a great variety of lesions no one of which is produced by this organism alone and is, therefore, pathognomonic of it. On this account the lesions due to the aureus, are generally classified from the anatomic point of view as abscess, suppuration, osteomyelitis, etc., with the name of the active agent sometimes added, as aureus abscess. Two of the lesions, however, are produced so much more commonly by the aureus than by any other organism that they are regarded as fairly peculiar to this bacterium, namely, furunculosis and osteomyelitis.

The aureus varies greatly in the pathologic effects which it produces owing to great differences in the virulence of the organisms coming from different sources, and in the susceptibility of the host. Both of these variable factors must be kept in mind.

The lesions are usually acute but may be chronic and are, as a rule, sharply circumscribed.

Micro-organism.—The aureus tends to grow in a compact clump or colony wherever it lodges in solid tissue as in the kidney. Later, after solution of the surrounding tissue has occurred, the organisms are dispersed more or less evenly in the pus, probably largely as a result of the ameboid movements of the leukocytes. In loose tissue such as the meninges and in the alveoli of the lung the cocci are usually scattered in the exudation more or less uniformly from the first. In acute endocarditis due to the aureus, the organisms grow in large solid masses on the surface of the valve, just as on a culture-medium in a test-tube.

The aureus is easily rendered prominent in the lesions which it causes by means of the Gram-Weigert staining method.

Toxin.—The staphylococcus aureus produces a strong toxin which acts chiefly locally and possesses apparently only moderate diffusibility. A certain amount is absorbed by the surrounding lymphatics and carried to neighboring lymph-nodes where it

causes cellular hyperplasia. There is little or no evidence of the elimination of any toxin through the kidneys; at least no inflammatory changes are produced there, such as so often occur as the result of infection with the streptococcus pyogenes or the pneumococcus. On the other hand, central necrosis of the liver lobules occurs occasionally and may be directly due to the toxin.

Besides toxin the aureus produces one or more ferment-like substances which exert a solvent action on certain bodies, such as gelatin and perhaps fibrin.

Injury.—The characteristic injury produced by the toxin of the staphylococcus aureus is necrosis which ordinarily occurs quickly for a definite area surrounding the organisms and spreads peripherally if the micrococci continue to develop. The production of necrosis is best studied in solid organs such as the kidney, where the toxin from the organisms has little opportunity to diffuse. In loose-meshed tissues such as the meninges and when the cocci are within the alveoli of the lung the toxin may be so quickly diluted by an abundant exudation of serum that necrosis may be lacking.

Reaction.—The injury and reaction caused by the staphylococcus aureus can best be studied by injecting suspensions of the cocci into the ear veins of rabbits and, later, fixing the tissues, especially the kidneys and heart, at various intervals of time from six to forty-eight hours. The organism must be one of just the right degree of virulence, which can be ascertained only by trial, or the animals may be quickly killed as the result of toxemia, or septic infarcts be produced instead of miliary lesions. Occasionally similar early lesions can be obtained in man as the result of an aureus septicemia.

Early lesions, of twelve to eighteen hours' duration, show in the kidney only a clump of cocci surrounded by a zone of necrosis. The toxin and the necrosis soon induce, however, an abundant exudation of polymorphonuclear leukocytes and more or less serum from the surrounding blood-vessels. As a rule, little fibrin is formed and that soon disappears, dissolved, perhaps, by substances eliminated by the organisms. Under the action of the leukocytes the necrotic tissue is digested and softened so that an abscess is formed. In cellular organs like the kidney this process of abscess-formation requires but twenty-four to forty-eight hours. In tough fibrous tissues like the skin it often requires seven to ten days or more to liquefy the dense and tough masses of collagen and elastic fibrils of the corium, so as to form pus which may be discharged through an opening in the skin. Following necrosis of bone it may require months or years to soften down the necrotic bone (sequestrum) formed.

Many of the leukocytes attracted by the aureus toxin are destroyed in the same way that the tissue cells are.

As soon as the necrotic tissue is liquefied the ameboid movements of the leukocytes tend to break up the colony arrangement of the micrococci, which quickly become dispersed among the leukocytes and to some extent incorporated in them.

The tendency of focal lesions is to extend peripherally until the contents of the abscess are discharged externally or into some natural cavity. In some tissues, however, such as muscle, the necrosis and inflammatory reaction often spread rapidly and extensively along the lines of least resistance, so that the result is a diffuse suppurative process.

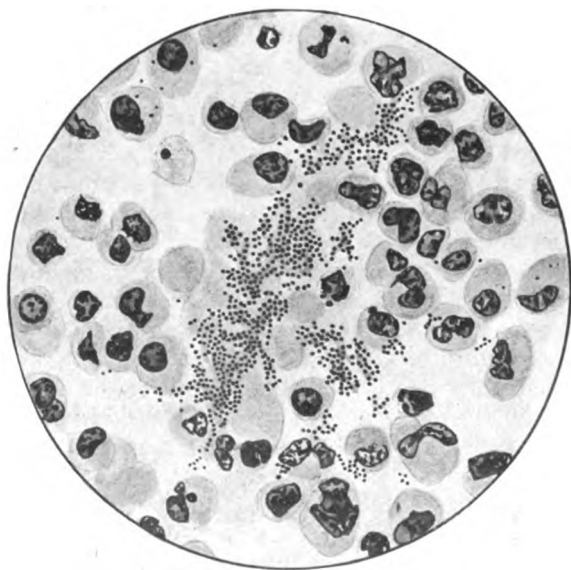


Fig. 62.—*Staphylococcus pyogenes aureus* in abscess in muscle.

Termination of Lesion.—The body shows considerable ability to counteract, by means of the production of an antitoxin, the toxins secreted by the *staphylococcus aureus* and to destroy the organism. It is greatly aided in the process of repair by the tendency of the lesion to remain focal and of the necrotic tissue to undergo complete solution, because the process frequently extends to a surface or natural cavity, and the pus with most of the organisms contained in it is discharged; the cocci remaining behind are easily destroyed.

As soon as necrosis ceases to extend peripherally the surrounding fibroblasts and capillary endothelium rapidly start regenerating

and soon form a wall of granulation tissue which on account of its better vascularization is more resistant than normal tissue to the action of the organisms and tends to prevent their further extension. After the discharge of the contents of an abscess the inflammatory edema of the adjoining tissues quickly subsides, the connective tissue contracts, and the contracted abscess cavity is soon filled with granulation tissue which in time changes to a small amount of scar tissue.

Special Forms of Lesions.—The most common primary lesions caused by the staphylococcus aureus are the following: furuncle and carbuncle; bronchopneumonia and abscess of the lung; abscess of tonsil; infection of wounds of all sorts.

The commonest secondary lesions are: septicemia from which multiple abscesses of the kidneys, heart, muscles, etc., are likely to follow; lymphangitis and abscesses of the lymph-nodes; osteomyelitis. The primary focus from which the secondary lesions arise is often not recognized. This is especially true of osteomyelitis.

Furuncle and Carbuncle.—Infection of the intact skin by the staphylococcus aureus often takes place by direct invasion and growth in a hair follicle or sebaceous gland. The toxins secreted cause necrosis of the epithelial cells and an inflammatory exudation. The organisms soon extend to the corium and cause more or less necrosis which is followed by a marked inflammatory exudation and much congestion and edema. Softening of the tough fibrous tissue of the corium usually requires from seven to ten days before it can be discharged in the pus through an opening in the skin at the original site of infection. Such a lesion as this is called a furuncle. If the infection in the corium is extensive and spreads laterally it is likely to reach the surface at a number of points by extending up through the fat columns. Such a lesion discharging pus at a number of separate openings in the skin is called a carbuncle. It sometimes reaches a diameter of ten centimeters and over.

Lesions corresponding in every way to the furuncle may be caused by infection of a wound of the skin such as a scratch, cut or prick.

The organisms discharged from a furuncle are very likely to be deposited elsewhere on the body, infect other hair follicles and cause new lesions. On this account furuncles are likely to follow one another and to be multiple. In fact it is often very difficult when a furuncle exists to prevent others from forming. Hence the very prevalent idea that the blood must be "out of order."

Following the discharge of pus spontaneously or as the result of an incision the swelling of a furuncle quickly subsides, the

walls of the cavity collapse and the wound quickly heals, especially if the pus was discharged spontaneously. An incision hastens the discharge of pus and relieves the tension, but delays the healing of the wound. Nature's opening is often preferable.

Osteomyelitis.—Another very characteristic lesion produced by the staphylococcus aureus is osteomyelitis. Infection occurs

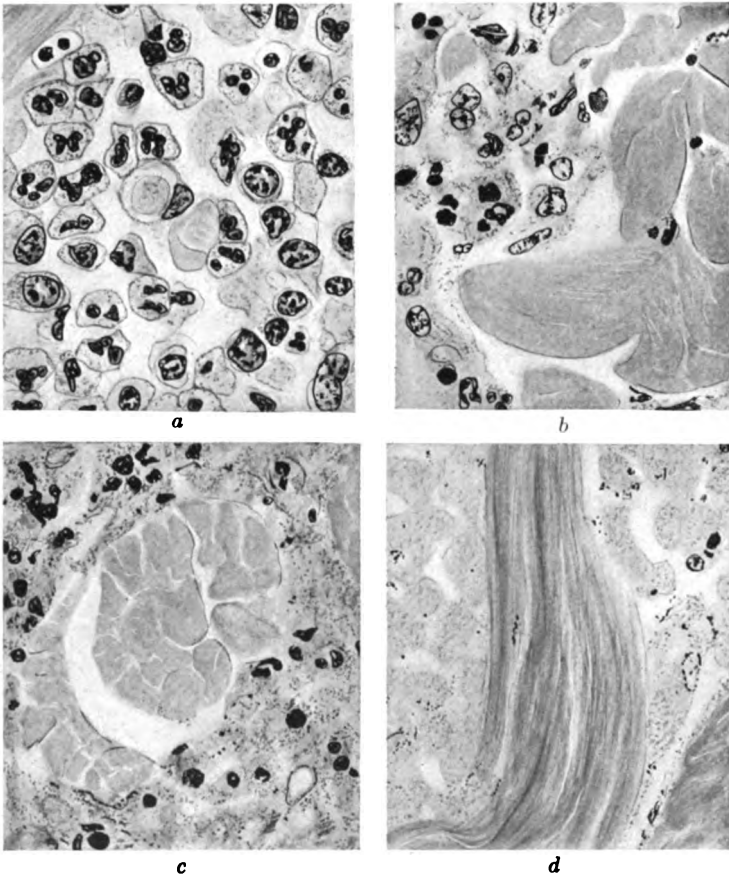


Fig. 63.—Four separate fields from furuncle produced by staphylococcus pyogenes aureus.

by way of the circulation and causes necrosis of the bone marrow and particularly of the bone tissue. Suppuration occurs as in other lesions, but the bone is exceedingly difficult to soften down. It persists as a foreign body which must be got rid of and nature's powers of handling it, although persistent, are very limited.

Months and years may be spent on the operation and then prove ineffective.

The necrotic bone is called a sequestrum. The process of repair surrounds it with granulation tissue. It also forms new bone from the endosteum or periosteum, according to the location of the sequestrum, to strengthen the living bone tissue left. If a whole shaft is necrotic a new shell of bone, called involucrum, is formed around it by the periosteum. If by a surgical operation this involucrum or the periosteum alone is stripped back and the sequestrum is removed the periosteum will form an entire new shaft.

Septicemia.—The staphylococcus aureus is more likely to spread by the blood than by the lymph-vessels. It frequently gains entrance to the circulation from some focal lesion and usually causes multiple abscesses in the kidneys and heart, less often in the muscles, lungs, bone marrow and spleen. Sometimes it gives rise to other lesions such as endocarditis, meningitis, etc.

Under certain conditions the organism becomes attenuated and persists in the blood for a long time, for months at any rate, as shown by repeated blood cultures. The patient may finally recover and return to a perfectly normal condition.

STREPTOCOCCUS PYOGENES

The streptococcus pyogenes is one of the most common and important of the organisms which infect the human body. It causes a great variety of lesions of which erysipelas is the only one wholly peculiar to it. Its virulence varies within very wide limits, as a result of which numerous attempts have been made to distinguish several different strains of the organism. Occasionally very virulent strains arise and may do great harm, especially if they happen to be spread broadcast in milk, as has sometimes happened.

The streptococcus is very commonly present in nature and on this account is a frequent secondary invader, when the body is weakened by infection with some other organism, as in diphtheria, scarlet-fever, and small-pox for example.

Septicemia is of frequent occurrence and is often followed by endocarditis and by infection of multiple joints.

The elimination of the toxin from the body is a common cause of lesions, especially of the glomerular type, in the kidney.

Central necrosis of the lobules of the liver is due to the toxin of the streptococcus pyogenes more often than to that of any other organism.

Micro-organism.—The streptococcus is usually fairly abundant in the lesions which it causes and is sometimes very numerous.

It appears in the form of chains, occasionally of great length, which run in various directions and which, when within lymphatics or small blood-vessels, may more or less completely fill the lumina. In streptococcus septicemia chains of the organism are often found in the vessels of the liver and spleen. Sometimes they occlude the capillaries in the glomerular tufts of the kidneys.

In endocarditis they are often so numerous as to form solid masses on the surface of the valves, and occasionally in small-pox they are present in great numbers in the corium, with little or no inflammatory reaction around them.

By the Gram-Weigert staining method the streptococcus is readily and strikingly demonstrated in the lesions which it causes. As the organism may multiply to some extent postmortem it is not always possible to say just how abundant it was in the tissues before death.

Toxin.—The toxin secreted by the streptococcus is fairly strong and calls out a well-marked inflammatory reaction. The toxin is also quite diffusible; hence local necrosis and abscess formation are not of so common occurrence as with the staphylococcus aureus, and bronchopneumonia due to the streptococcus does not ordinarily terminate in abscess formation. The toxin is freely absorbed along the lymphatics and usually causes marked swelling of the regional lymph-nodes, due largely to hyperplasia of the lymphocytes.

The streptococcus toxin is readily taken up by the circulating blood and may cause necrosis of liver cells, hyperplasia of the endothelial cells in the lymph-nodules of the spleen and other organs and, by elimination through the kidney, acute nephritis usually of the glomerular type.

Occasionally the streptococcus is very virulent and its toxin strong so that extensive necrosis, especially of muscle tissue, is produced, and death occurs so quickly that little inflammatory exudation is called out.

Injury.—As a rule the streptococcus does not produce extensive necrosis with solution of the tissue and abscess formation as the aureus does. In the characteristic lesion, erysipelas, there is little or none, only inflammatory exudation. On the other hand, in the severer lesion known as phlegmon extensive sloughing may occur; and as already mentioned streptococcus infection of muscle may cause necrosis often combined with hemorrhage.

The lesions due to the streptococcus are usually not sharply circumscribed; they tend to spread owing to the readiness with which the organisms invade the lymphatics and extend along them, causing a lymphangitis.

Reaction.—The inflammatory reaction to the streptococcus

consists of an exudation of serum and polymorphonuclear leukocytes; considerable fibrin is usually formed. The cocci are often taken up by the leukocytes so that they may present the appearance of gonococci, but they stain positively by the Gram method. Sometimes the serous exudation is very abundant and causes marked swelling of the tissues as in the early stage of a phlegmon.

Occasionally the streptococcus persists for a long time in an attenuated form in the circulation and causes abscesses in first one location and then another. The cellular reaction under these conditions often consists largely of endothelial leukocytes.

Termination of Lesions.—The streptococcus may die out in the lesion which it causes. This is the usual termination in erysipelas, and the same result may happen with bronchopneu-

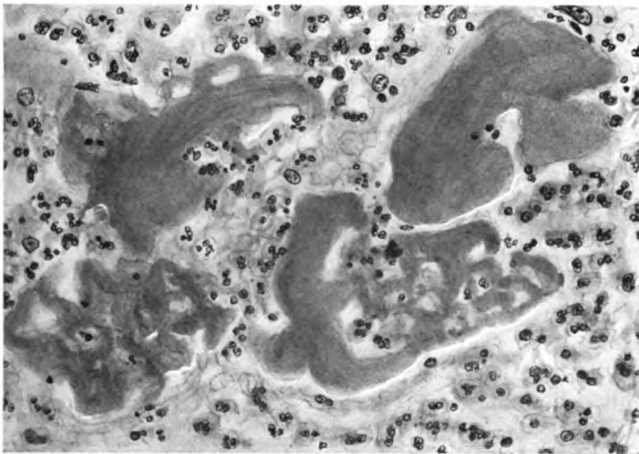


Fig. 64.—Necrosis of skeletal muscle-fibers due to the streptococcus pyogenes. Exudation consists chiefly of polymorphonuclear leukocytes.

monia, pleuritis, infections of the skin, etc. The exudation quickly disappears and the tissues return to a normal condition. Abscess formation followed by discharge of its contents and the cocci is not common as in aureus infections. On this account the streptococcus is not easily got rid of. It is very persistent especially in wound infections. The lesions tend to light up repeatedly. Hence a streptococcus infection is always to be regarded as dangerous. The organism is treacherous.

Special Types of Lesions.—Several forms of lesions due to the streptococcus deserve brief mention.

Erysipelas is a spreading lesion of the skin due to a mild streptococcus extending through the lymph-spaces. Little or

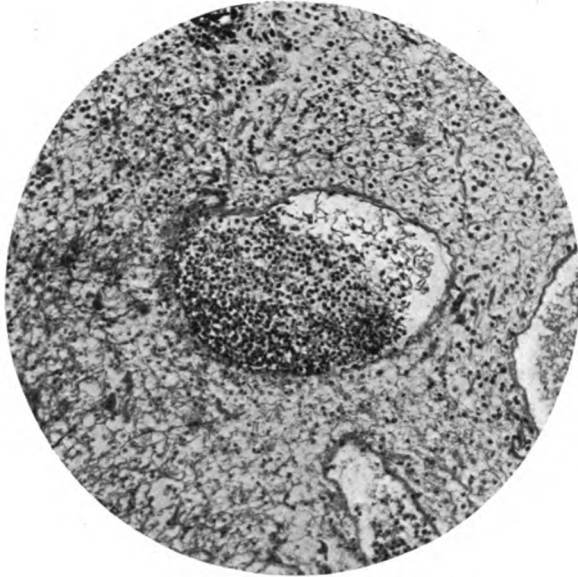

Fig. 65.—Phlegmonous inflammation of the pharynx due to the streptococcus pyogenes. The lymphatic in the center is distended and filled with serum and leukocytes. M.

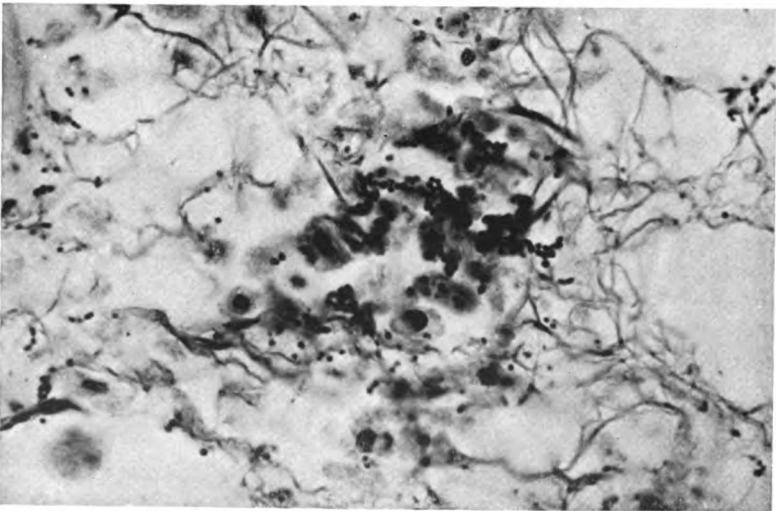


Fig. 66.—Pharynx. Phlegmonous pharyngitis. The streptococcus pyogenes present in abundance in the serofibrinous exudation. M.

no necrosis is produced. There is congestion and a moderate inflammatory exudation. The infection runs a fairly typical clinical course and tends to terminate in complete recovery, but the streptococcus may extend along the lymphatics or obtain entrance to the circulation and cause a variety of other lesions which may prove fatal.

Phlegmon and phlegmonous inflammation are terms applied to a severer type of spreading inflammation of the skin, pharynx, stomach, etc., in which the exudation and consequent swelling are much more marked and extensive necrosis may occur.

Tonsilitis is a fairly frequent primary lesion due to the streptococcus, and often complicates scarlet fever. It is dangerous in

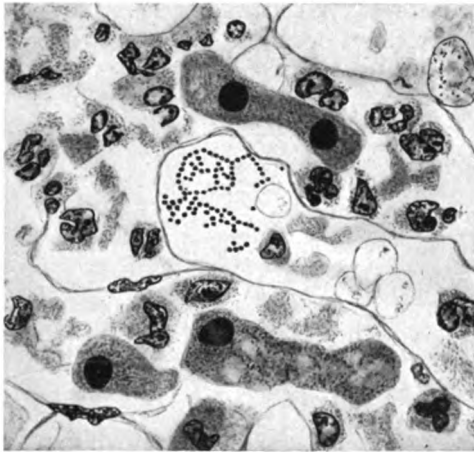

Fig. 67.—*Streptococcus pyogenes* septicemia. Necrosis of liver cells. Emigration of polymorphonuclear leukocytes.

itself and also because a septicemia is liable to occur and be followed by endocarditis and infection of various joints. Infection of the tonsil may cause superficial necrosis and membrane formation resembling perfectly that due to the diphtheria bacillus, or it may lead to extensive necrosis and abscess formation.

Bronchopneumonia is often due to the streptococcus. Abscess of the lungs is more likely to occur when the organisms are brought there by the circulation. Pleuritis is frequently caused by extension of the organisms to the pleural cavity.

Septicemia is fairly frequent and always exceedingly dangerous. It may give rise to multiple abscesses, to multiple infectious lesions of blood-vessels, to acute endocarditis, to infection of joints, to meningitis, etc. The character of the lesions depends

on the virulence of the infecting organism and this may vary within very wide limits. When it is virulent elimination of toxins through the kidneys may cause acute glomerular lesions.

Endocarditis is quite often due to the streptococcus and may appear as the primary lesion. The organisms grow in solid masses forming minute to large vegetations which show live organisms at the surface and masses of dead ones beneath. The inflammatory reaction around them may be marked or surprisingly slight.

DIPLOCOCCUS LANCEOLATUS (PNEUMOCOCCUS)

The diplococcus lanceolatus occurs widely in nature and is a common inhabitant of the mouth. It causes a variety of lesions of which lobar pneumonia is the most important and characteristic, although this disease may be caused occasionally by other organisms. Other lesions of frequent occurrence due to the pneumococcus are bronchopneumonia, meningitis, endocarditis and septicemia. Pneumococcus meningitis apparently always terminates fatally, but recovery from some of the other lesions is of frequent occurrence.

A characteristic of the inflammatory exudation is the formation of much fibrin and it is noticeable that the blood clots postmortem more extensively than is usual.

Micro-organism.—The pneumococcus appears singly, in pairs and in chains in the lesions which it produces. Sometimes it is very abundant, at other times so scarce that it is difficult to demonstrate its presence microscopically. It is usually most numerous in the early stages of the lesions, at which time it multiplies and spreads rapidly. In lobar pneumonia it is present in great numbers at the beginning in the stage of edema. After the leukocytes appear the organisms usually rapidly vanish partly as the result of phagocytosis.

The diplococcus lanceolatus is readily stained in sections by the Gram-Weigert method.

Toxin.—The pneumococcus produces a toxin which is of considerable strength and more or less diffusible. In the immediate neighborhood of the organisms it leads to a marked inflammatory reaction, but necrosis is rarely conspicuous. The elimination of the toxin through the kidneys frequently leads to acute glomerulonephritis, usually of the intracapillary type, if the infection persists more than two or three weeks.

Injury.—In the ordinary lesions due to the pneumococcus it is not easy to demonstrate any marked injury caused by the toxin. It does not usually cause necrosis, at least in the lungs and meninges. Occasionally, however, necrosis of the alveolar walls and abscess formation occur in the lung, apparently entirely as the result of the action of this organism.

In septicemia due to the pneumococcus hemorrhage is of frequent occurrence as the result of injury to the walls of the blood-vessels.

Reaction.—The reaction to the pneumococcus and its toxin takes the form of an acute exudation in which serum in abundance is the first element to appear. Polymorphonuclear leukocytes soon follow and much fibrin is formed from the serum. Endothelial leukocytes as a rule do not play an important part, except during the stage of resolution. The exudation is often complicated by more or less hemorrhage.

The fibrin is delicate at first and in the lung often begins forming near the alveolar walls; later it usually fills the air-sacs and often also the bronchioles and gradually becomes thicker.

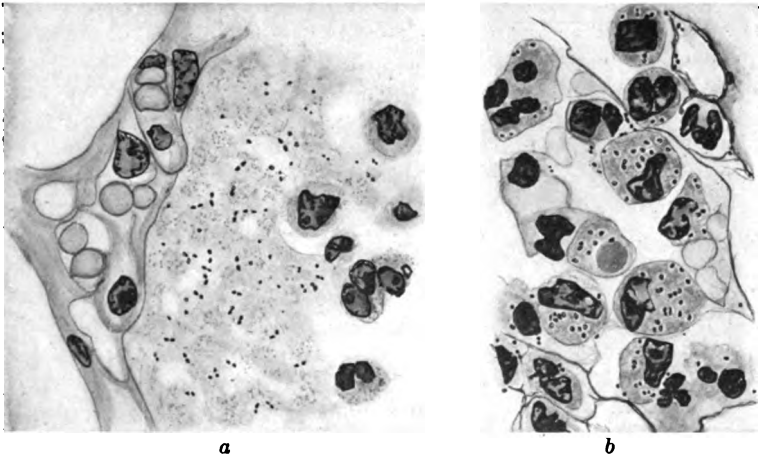


Fig. 68.—*Micrococcus lanceolatus*. Acute lobar pneumonia. *a*, Cocci free in serum in alveolus; *b*, cocci within polymorphonuclear leukocytes.

Termination.—The diplococcus *lanceolatus* tends to disappear early from its lesions. In lobar pneumonia the toxin seems to become neutralized, since the temperature drops suddenly by crisis and recovery is rapid. Under the action of the polymorphonuclear leukocytes the fibrin is dissolved, at least in part, and is either removed through the natural passages or becomes organized and replaced by fibrous tissue.

Septicemia.—The pneumococcus frequently gains access to the circulation, especially in cases of lobar pneumonia. The resulting septicemia is not necessarily fatal. Sometimes the smaller blood-vessels are injured by the toxin and multiple petechial hemorrhages result.

Special Types of Lesions.—The most common primary lesions due to the diplococcus lanceolatus are lobar and lobular pneumonia; the secondary lesions are pleuritis, pericarditis, septicemia, endocarditis, meningitis, etc.

Lobar pneumonia is almost always due to the diplococcus lanceolatus. Infection occurs through the air passages. The lesion often affects one or more lobes more or less completely, but it is never confined entirely to that location. The organisms always extend to the pleural cavity and occasionally to the tissue outside of it, causing an exudation in the intercostal muscles, in the mediastinum and even extending into the neck. Secondary infection of the pericardial and peritoneal cavities is also of frequent occurrence.

Lobar pneumonia usually terminates in resolution, but occasionally the fibrin in the exudation is not dissolved. It, therefore, attracts blood-vessels and fibroblasts which replace or organize it. The same process takes place with the fibrin on the pleural surface, resulting in dense fibrous adhesions which bind the visceral and parietal surfaces intimately together and often obliterate the pleural cavity entirely.

Lobular pneumonia is more often due to the pneumococcus than to any other organism. The inflammatory exudation is exactly the same as in lobar pneumonia. The two types of lesions sometimes occur in the same lung. The cause of the distribution of the lesion in lobular pneumonia has never been satisfactorily explained. Possibly the abundant serous exudation in the early stage causing rapid distribution of the organisms has something to do with it.

Lobular pneumonia usually terminates in resolution, but occasionally organization takes place.

MICROCOCCUS INTRACELLULARIS MENINGITIDIS (MENINGOCOCCUS)

The micrococcus intracellularis meningitidis produces the disease known as epidemic cerebrospinal meningitis. About two-thirds of all cases of meningitis are of this type. The organism is probably transferred directly from one person to another. The path of entry is supposed to be through the lymphatics from the nasal cavity where the meningococcus has been repeatedly demonstrated by means of cultural methods.

This form of meningitis usually occurs epidemically but also occasionally sporadically. It is not necessarily fatal. Some patients recover completely, others with loss of sight or of hearing, or with mental deficiencies. Some patients recover temporarily only to die later from internal hydrocephalus.

The infection is usually acute but sometimes runs a chronic course, persisting for many weeks with remissions and exacerbations. The meningitis is occasionally complicated by lobular pneumonia due to the same organism.

The diagnosis of epidemic cerebrospinal meningitis is readily made apart from the clinical history, by obtaining some of the exudation by spinal puncture, demonstrating the characteristic Gram-negative organism within polymorphonuclear leukocytes, and growing it on blood serum or other suitable medium.

Micro-organism.—The meningococcus is often present in large numbers at the beginning of the infection. It dies out, however, in the older part of the exudation within a very few days.




Fig. 69.—Acute meningitis due to the micrococcus intracellularis meningitidis.

On this account it is always most numerous at the advancing edge of the process and within the ventricles, on the surface of the spinal cord and along the nerves. In the later stages of the disease it may be impossible to demonstrate any organisms.

The meningococcus occurs almost entirely within the cytoplasm of polymorphonuclear leukocytes and is often found there in large numbers. In this peculiarity and in its morphology and staining reactions it closely resembles the gonococcus, but its cultural characteristics are entirely different.

Toxin.—The meningococcus evidently produces a fairly strong toxin, judging from the quick inflammatory reaction which it calls out and the severe symptoms which the infection causes.

The toxin acts for the most part locally but is also absorbed and diffused throughout the body causing slight to severe retrograde changes.

Injury.—Little or no evidence of direct injury to the cells in the meninges produced by the toxin of the meningococcus can be found. On the other hand, the ganglion cells of the cortex sometimes show slight to severe retrograde changes, and rarely in circumscribed foci may undergo necrosis, either as the result of toxin diffusing from the meninges or owing to organisms invading the brain tissue. The neuroglia cells frequently show active pro-

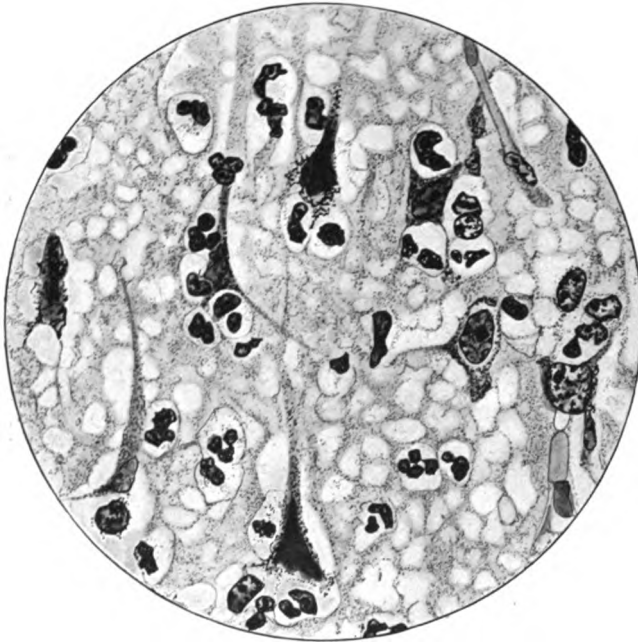


Fig. 70.—Cerebrum. Epidemic cerebrospinal meningitis. Polymorphonuclear leukocytes around ganglion cells in cortex.

liferation which is probably of a reparative nature secondary to injury of these cells.

Fat can usually be demonstrated in ganglion cells and especially in nerve-fibers, both in the brain and cord and in the peripheral nerves, in those cases in which the infection has lasted for a number of days.

Reaction.—In the meninges the meningococcus causes an acute inflammatory exudation consisting of serum and polymorphonuclear leukocytes. Fibrin forms to some extent, but is usually

not very abundant, at least early in the process. The exudation is slight at first, but rapidly increases in amount. After the exudation has existed for several days, endothelial leukocytes begin to make their appearance in considerable numbers and incorporate many of the polymorphonuclear leukocytes. Lymphocytes also accumulate, particularly around the blood-vessels, as the neutrophilic leukocytes disappear.

In the cortex of the brain polymorphonuclear leukocytes often appear around the vessels; they have evidently been led to emigrate by the toxin diffusing from the organisms in the meninges. The surface of the cortex also becomes edematous owing to an exudation of serum.

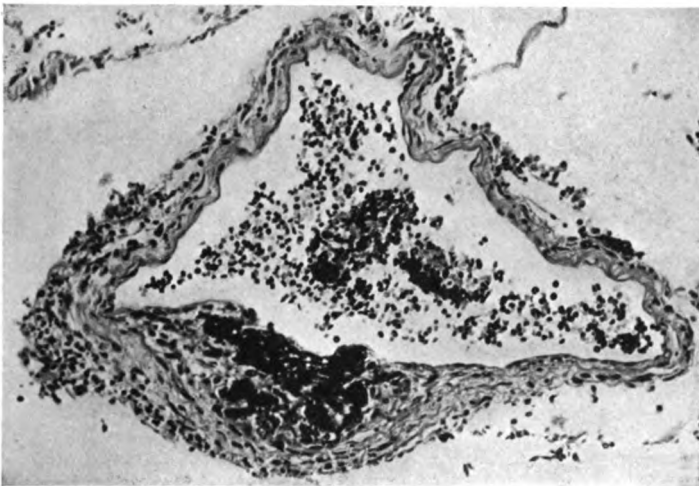


Fig. 71.—Spinal cord. Epidemic cerebrospinal meningitis. Lesion in wall of vein with fibrin formation and beginning organization. M.

Gross Appearances.—The inflammatory process in epidemic cerebrospinal meningitis is usually most marked at the base of the brain; it is less over the parietal and occipital lobes. The meninges of the cerebellum are always involved.

In the earliest stage of the process there is intense congestion. Later, the exudation appears as yellowish lines along the blood-vessels. At the base of the brain it often appears distinctly purulent at first; later more fibrin may be formed. The exudation here may be a centimeter or even more in thickness.

The spinal cord is always involved and presents much the same appearance as the brain. Occasionally the exudation over the cord is more abundant than that over the brain. The posterior sur-

face of the cord is always covered with a greater amount of exudation than the anterior, owing to the normal reclining position of the patient. For the same reason the posterior horns of the lateral ventricles almost always contain a little thick, purulent exudation.

Termination.—If the patient survives for two or more weeks the polymorphonuclear and endothelial leukocytes gradually undergo necrosis and disappear, and the fibrin which is not dissolved by ferments becomes organized. As a result, at this stage, the meninges appear thickened and edematous or gelatinous, and white streaks are present alongside the blood-vessels. Small yellowish patches occur here and there, particularly over the sulci, where the thicker masses of fibrin are being organized. At the base of the brain organization of the abundant fibrin often present may lead to occlusion of the foramen of Magendie as a result of

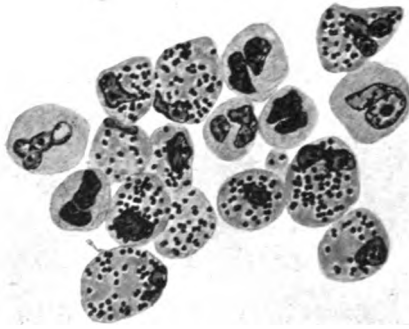

Fig. 72.—Focal pneumonia due to the diplococcus intracellularis meningitidis.

which the ventricles may become greatly distended (internal hydrocephalus) and contain a hundred cubic centimeters or even more of fluid.

In the acute stage of meningitis the meninges are easily stripped off from the cerebrum; after repair has taken place they are usually more or less adherent and tear away small bits of brain tissue when forcibly removed.

The active proliferation of neuroglia cells along the surface of the cortex has already been mentioned. Occasionally mitotic figures are fairly numerous and clumps of several neuroglia cells in close contact are frequent. In the severe or prolonged cases the neuroglia fibrils produced by these cells cause a certain amount of sclerosis. Similar changes result in the formation of numerous minute granules on the surface of the ventricles.

Complications.—The meningococcus shows quite a tendency

to extend along certain nerves, especially the optic, auditory and fifth, and sometimes it produces inflammation of the eye or of the orbit, or destroys the internal auditory apparatus, or the nerve-cells and fibers of the Gasserian ganglion.

As in other infectious processes the walls of some of the blood-vessels, especially veins, in the meninges are injured. As a result thrombi may be formed within them and, later, undergo organization. Occasionally the lining endothelium of an artery is elevated by an accumulation of polymorphonuclear leukocytes beneath it.

Lobular Pneumonia.—Occasionally a more or less extensive lobular pneumonia is produced by the meningococcus. Infection probably takes place from the nares, not embolically from the meninges, because a septicemia with this organism has never been demonstrated. The exudation in the lungs consists almost wholly of polymorphonuclear leukocytes which often contain the meningococcus in very large numbers.

DIPLOCOCCUS GONORRHOÆ (GONOCOCCUS)

The gonococcus is a common and dangerous infectious agent. It causes acute lesions which tend to become chronic and persist indefinitely. Its normal habitat is the genital tract in human beings. In the male infection spreads from the urethra to the prostate and epididymis; in the female from the vagina through the uterus to the oviducts where the greatest damage (salpingitis) is generally produced.

Infection often spreads to the urinary tract and rarely in the female to the peritoneal cavity. Septicemia is an occasional complication and may lead to arthritis and endocarditis.

Infection ordinarily takes place through the act of sexual intercourse. Occasionally, however, the organism is transferred from the genitals to the eyes by the fingers in adults, or at the time of birth in infants, causing ophthalmia of a dangerous type. Small children, especially females, are not infrequently directly infected through personal contact with their parents, owing to deplorable lack of cleanliness. Ophthalmia and more often vaginitis acquired in this way are sometimes passed from child to child in institutions, constituting an epidemic difficult to control.

Micro-organism.—The gonococcus usually occurs in diplococcus form with the adjacent surfaces characteristically flattened. It is found most frequently in the cytoplasm of polymorphonuclear leukocytes and often in large numbers in the cells which contain any at all, indicating that it multiplies freely within the cells which incorporated it.

The gonococcus is Gram-negative. It is stained readily,

however, by the ordinary basic dyes. The best results with sections are obtained by the eosin-methylene-blue method after Zenker fixation.

Toxin and Injury.—The gonococcus evidently produces a more or less strong toxin. This is shown not so much by any direct injury as by an active inflammatory reaction. Infection takes place and spreads, as a rule, along epithelial-lined surfaces. The epithelium usually does not undergo necrosis. When it does the infection quickly extends to the underlying tissue where abscess formation may follow necrosis and softening.

Reaction.—The exudation consists chiefly of serum and polymorphonuclear leukocytes. Little or no fibrin is formed. Endothelial leukocytes are usually inconspicuous, except in chronic lesions, as in the oviduct for instance, where they may be attracted

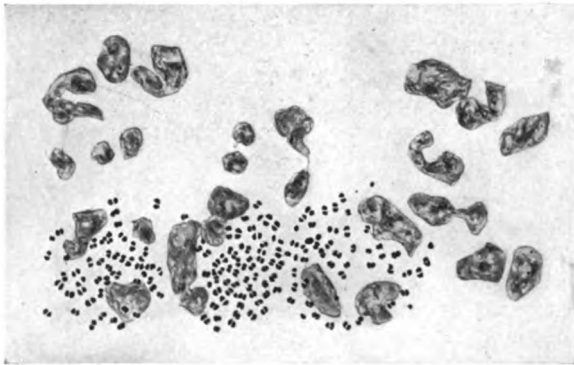


Fig. 73.—Smear made from urethral discharge. Micrococcus gonorrhœæ present in large numbers in the cytoplasm of many of the polymorphonuclear leukocytes.

by fat accumulated from necrotic polymorphonuclear leukocytes in the lumen. They take up the fat and collect in the subepithelial tissues where they may appear to the naked eye as a narrow, opaque yellowish zone.

In the more chronic lesions lymphocytes often infiltrate the submucous tissue in large numbers and eosinophiles may be fairly numerous.

Termination.—The lesions due to the gonococcus are acute to start with, but instead of healing spontaneously they tend to become less active and to persist in a chronic form for years. These chronic lesions are characterized by the formation of much scar tissue due in part to direct injury, as when the organism invades the submucous tissue and causes suppuration or abscess formation, in part apparently to diffusion of toxin through the lymph-

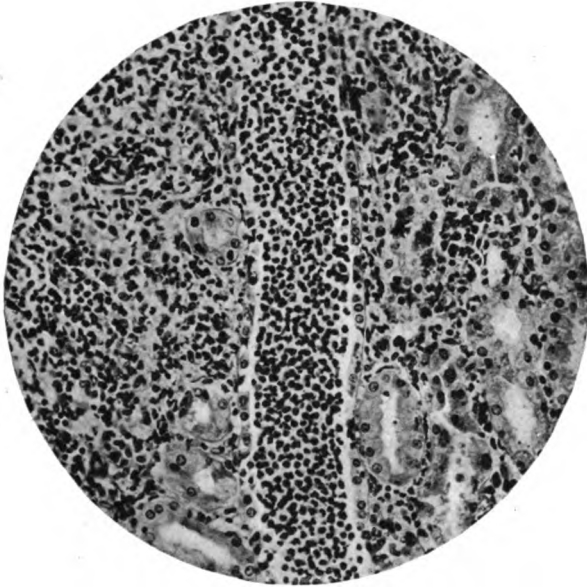


Fig. 74.—Kidney. Chronic infectious (pyelo) nephritis due to the gonococcus. M.

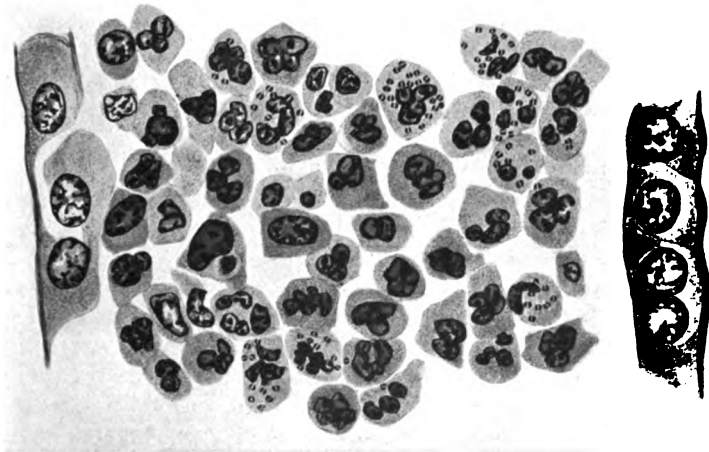


Fig. 75.—Kidney. Chronic pyelonephritis due to the gonococcus. Part of a tubule distended with polymorphonuclear leukocytes, some of which contain numerous gonococci.

spaces. The uninjured fibroblasts regenerate and produce much collagen which later contracts. This contraction frequently leads in the male to stricture of the urethra with consequent interference with the outflow of urine. Similar lesions in the epididymis often result in occlusion of the ducts and consequent sterility.

Salpingitis in the female results in accumulation of exudation within the tube (pus tube), more or less thickening of the wall and in adhesions to the ovary and surrounding organs, with occlusion of the fimbriated end and consequent sterility.

Special Pathology.—The various lesions due to the gonococcus can be summarized briefly. In the male, urethritis, prostatitis, infection of the seminal vesicles, extension along the vas deferens, epididymitis, rarely invasion of the testicle and abscess formation.

In the female, vaginitis, endocervicitis and metritis, salpingitis, abscess of ovary, peritonitis.

Infection of the bladder seems to be fairly frequent but not very serious. In extremely rare instances the organism may extend to the kidney and cause a chronic pyelonephritis.

Proctitis and stomatitis are not common in civilized communities.

Septicemia occurs not infrequently and may be followed by arthritis, which is often of a severe and chronic type, and less often by endocarditis.

Ophthalmia is due to direct transference from the genital tract, and often results in loss of vision.

The inguinal lymph-nodes are occasionally swollen secondarily to gonorrhoeal urethritis. The buboes resulting from the acute inflammation seems to be due, at least in the majority of instances, to absorption of toxins rather than to the immediate presence of the gonococcus.

BACILLUS DIPHThERIE

The diphtheria bacillus ordinarily infects only the air passages of which the different parts are affected in the following order of frequency, pharynx (tonsils), larynx, nares, and lungs. Rarely infection may begin in the conjunctiva. From these primary foci the pathologic process often extends; from the tonsils to the uvula, the pillars of the fauces, and the posterior wall of the pharynx; from the larynx to the trachea and lungs; or from the nares to the accessory sinuses of the nose. More rarely it extends from the primary foci to the esophagus, tongue, or skin around the nose and mouth, or to the middle and external ear through the Eustachian tube and a perforated membrana tympani. Still more rarely, diphtheria bacilli which have been swallowed cause lesions in the stomach, or are conveyed to the genitals

(vulva, vagina, penis) by the fingers and give rise to membrane formation there.

The diphtheria bacillus secretes a strong toxin which usually causes intense local injury and an active inflammatory reaction. The reaction appears prominently in the form of an adherent layer of fibrin, commonly called a membrane. Some of the toxin, absorbed and distributed in dilute form, causes retrograde changes in various cells throughout the body and also a well-marked reaction in the various lymph-nodes.

In some respects the diphtheria bacillus resembles the pneumococcus, in others it differs from it. Of the two it is the more virulent, and the injury produced, necrosis, is usually more evi-

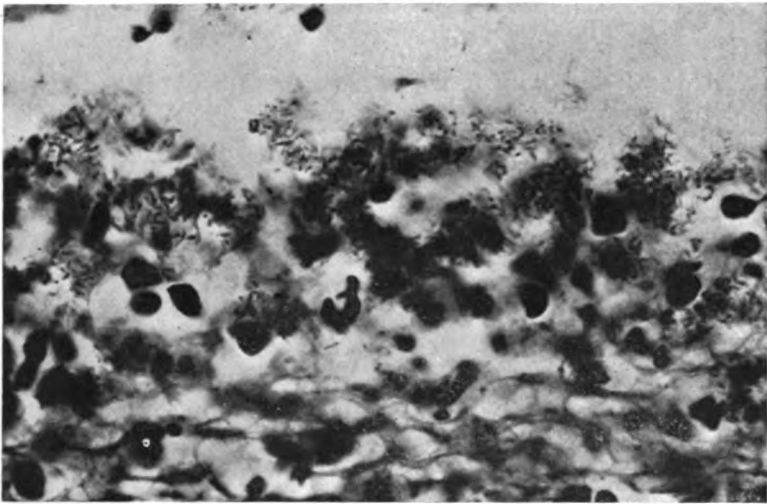


Fig. 76.—Diphtheria. Fibrinous tracheitis. Masses of diphtheria bacilli on the surface of the membrane. M.

dent. They both produce an acute inflammatory exudation in which polymorphonuclear leukocytes and especially fibrin play a conspicuous part. The diphtheria bacillus infects the large air passages, the pneumococcus, the small terminal vesicles. The bronchi are more or less common territory. The fibrinous layer produced by the action of the diphtheria bacillus is usually called a membrane, but that due to the pneumococcus (fibrinous pleuritis), although of the same nature, is not.

Micro-organism.—The diphtheria bacillus does not ordinarily form a conspicuous feature microscopically in the lesions which it causes, although sometimes it is present in abundance in the trachea and may form large masses in the smaller bronchi of the

lungs. On the other hand, its presence can almost always be demonstrated in early lesions when a definite membrane is present. The organisms occur in clumps of various sizes, chiefly on the surface of the membrane, but also in the underlying necrotic tissue. They are not found in living tissue, or on the surface of normal epithelium, or even in those places where there are, in the epithelium, degenerative changes which can be regarded as the primary injury of the disease. It seems probable that the beginning of the lesion is due to the toxic action of bacilli growing in the fluids of the mouth or throat. When necrosis is once produced the necrotic tissue and the membrane deposited on its surface form a suitable culture medium. In the accessory sinuses of the nose and in the middle ear the diphtheria bacilli so frequently present often produce only a mucoid or purulent secretion.

In a certain number of cases the cervical lymph-nodes become infected with diphtheria bacilli from the local lesions in the throat, and the bronchial nodes from lesions in the lungs without the bacilli reaching the circulation. In many fatal cases, however, the bacilli get into the blood and can be obtained in cultures from various organs. The order of relative frequency is as follows, liver, kidneys, spleen, heart's blood, and very rarely the brain. The highest percentage of septicemias recorded is fifty, but in general it does not exceed twenty per cent.

Toxin.—The diphtheria bacillus secretes a strong toxin which acts energetically locally. The toxin is also diffusible and being absorbed to a considerable extent, it circulates in the lymph- and blood-vessels to act injuriously, although in a much more dilute form, throughout the body. The diphtheria toxin is frequently contaminated and complicated by toxins derived from the streptococcus pyogenes and other secondarily infecting organisms.

Injury.—The injury produced by the diphtheria bacillus depends on the strength of its toxin acting in any given location. It may vary from slight retrograde changes to complete necrosis of the tissue cells. Frequently in the primary local lesions the cells are found in all stages of degeneration so that the term necrobiosis is sometimes applied to the condition.

In the epithelium the most noticeable degenerative changes are enlargement and lobulation of the nuclei, or multiplication of them by direct division, vacuolation of the cytoplasm by inhibition of serum, and necrosis of the cells with disintegration of the cytoplasm and fragmentation of the nuclei, or with hyaline transformation. In the trachea the necrotic cells quickly desquamate, but on surfaces covered with stratified epithelium they usually persist in or beneath the membrane.

The injury involves not only the surface epithelium but often

extends also to the underlying tissues, which may likewise degenerate or undergo necrosis.

Reaction.—The reaction to the toxin secreted by the diphtheria bacillus and to the injury caused by it is an active and usually abundant exudation, which consists chiefly of serum and polymorphonuclear leukocytes. Endothelial leukocytes and lymphocytes play a minor rôle. From the serum much fibrin is formed. It is deposited chiefly on the epithelial surfaces in successive layers which are parallel with the surface. The fibrin threads at first are fine and delicate; later, owing to gradual

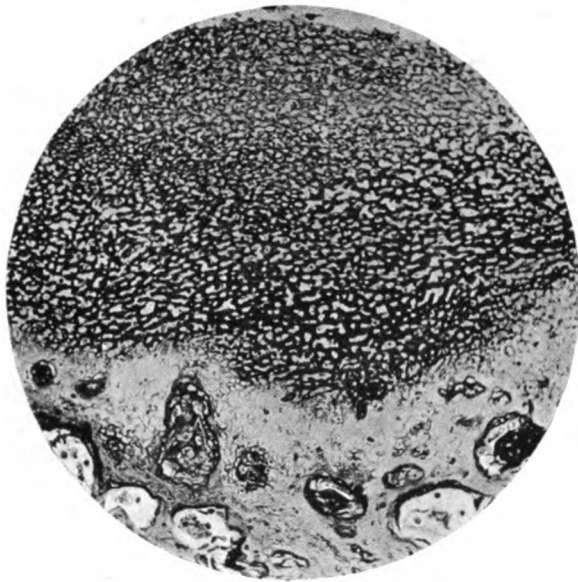


Fig. 77.—Hyaline membrane in pharynx. The reticulum is coarse, the spaces small and rounded; they contain few cells. In the submucosa the walls of the blood- and lymph-vessels show marked hyaline fibrinoid changes. M. and W.

fusion and from continual accretions, they become thick and the membrane is often spoken of as hyaline, in contradistinction to its fibrinous appearance in the early stages of the process. The hyaline membrane is formed where the fibrin gets a strong hold on the surface and persists a long time. On this account it is common over stratified epithelium and very rare in the trachea and bronchi, where the membrane readily strips off because the epithelial cells desquamate. At the same time the basement membrane, which is particularly thick in the trachea, forms more or less of a pro-

tection for the adjoining tissue so that it does not often undergo necrosis.

When the subepithelial tissues become necrotic they are often transformed, by chemical changes taking place in the serum bathing them, into hyaline structures which give the fibrin reaction. The transformation is sometimes called fibrinoid degeneration.

The polymorphonuclear leukocytes pass for the most part through the membrane on to the free surface, but some lodge in the meshes of the membrane and may be killed like the tissue cells by the action of the toxin. The endothelial leukocytes do not migrate to the surface so freely.

Gross Characteristics of Membrane.—The membrane varies greatly in appearance. It may appear white, dirty white, brownish, grayish brown, or almost black in color. It may form a thin pellicle which is easily removed, leaving a smooth surface, or a thick, tough layer which is stripped off with difficulty from the ragged, injected tissue beneath. It may be soft and granular, breaking into small fragments, or tough and elastic, and removable in large patches. The membrane is always more easily removable from the trachea than from any other part.

Lungs.—The diphtheria bacillus may cause extensive membrane formation in the bronchi similar to that in the trachea. In addition it may alone, or combined with other organisms such as the streptococcus pyogenes or the staphylococcus aureus cause a bronchopneumonia. Occasionally the diphtheria bacillus is present in masses in these lesions.

Systemic Lesions.—The diphtheria toxin is absorbed in strongest solution through the lymphatics connected with the local lesions and may cause severe injury in the neighboring lymph-nodes, especially the cervical and submaxillary. Hemorrhage and diffuse and circumscribed necrosis are of frequent occurrence as the result of the action of the strong toxin.

Toxin absorbed and diffused throughout the body in more dilute form causes proliferation of the endothelial cells lining the reticulum in the center of the lymph-nodules of many of the lymph-nodes, of the spleen, and of the gastro-intestinal tract. The endothelial cells proliferate and incorporate and gradually digest the surrounding lymphocytes, in some instances so extensively that only a few are left at the periphery of the lymph-nodule. The resulting lesion sometimes closely resembles an early miliary tubercle. Necrosis, hemorrhage, and fibrin formation also often occur in the lymph-nodules. This reaction on the part of the endothelial cells probably is connected with the manufacture of an antitoxin. The endothelial cells are the active agents, the lymphocytes serve as nutritive material.

The termination of this lesion is the disappearance of the endothelial cells and the contraction of the stroma into a small mass of hyaline connective tissue.

The toxin leads to various degenerative changes all over the body. Fat appears in small droplets in the heart, liver, kidneys, striated muscle-fibers, ganglion cells, nerves, etc. Necrosis is caused not only in the epithelium and underlying tissues in the local lesions and in the neighboring lymph-nodes, but also in foci or diffusely in the heart (toxic myocarditis) and kidney (toxic nephritis), and centrally or focally in the lobules of the liver. Wherever necrosis occurs there is an inflammatory reaction to the necrotic material in addition to the general reaction to the absorbed diphtheria toxin.

Besides the lesions already described as occurring in the lymph-nodules, the pulp of the spleen shows an increase in the number of lymphocytes, especially of the plasma cell type. They may be present in large numbers diffusely and in masses in cases which have lasted for some time. Occasionally lymphocytes collect in considerable numbers beneath the lining endothelium of veins. Eosinophiles are sometimes numerous in the pulp.

BACILLUS ANTHRACIS

Infection with the anthrax bacillus occurs occasionally in man in this country and is frequently but not necessarily fatal. It takes place by means of anthrax spores, carried in the wool and on the hides brought from countries where the disease anthrax is endemic among sheep and cattle.

Infection in man takes place commonly by direct inoculation through abrasions of the skin (neck, face, hands, arms); less frequently in the intestinal tract as the result of swallowing the spores; or rarely, in the lungs in consequence of inhaling them.

The organisms usually multiply rapidly, the local lesions develop quickly, a septicemia is common, and secondary lesions such as a meningitis may arise.

A diagnosis in the case of the lesions of the skin is commonly made from the characteristic gross appearances, and the finding of bacilli with the characteristic morphology and staining reactions of the anthrax bacilli, in cover-slip preparations made of the serum obtained from the vesicles and underlying tissue.

Micro-organism.—The anthrax bacillus is usually prominent histologically in the lesions which it causes. Sometimes it is present in great numbers. In the skin lesions it is most numerous usually just beneath the epidermis. Occasionally in patients who are recovering spontaneously the organisms may be few in number and difficult to find.

The large size and staining properties of the anthrax bacillus enable it to be demonstrated readily in sections. A Gram-Weigert stain combined with a carmine red in the nuclei furnishes the best contrast and most striking picture.

Toxin, Injury. Reaction.—The anthrax bacillus produces a fairly strong toxin. This is evidenced by marked inflammatory reaction rather than by extensive injury in its immediate vicinity. Necrosis is not a marked feature, as, for example, around the staphylococcus aureus. On the other hand, the blood-vessels are

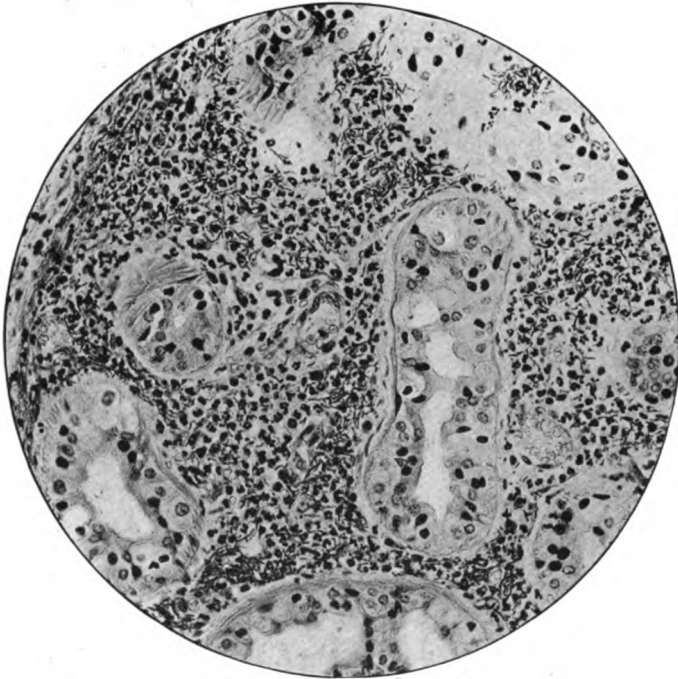

Fig. 78.—Anthrax pustule of the skin. Many anthrax bacilli and polymorphonuclear leukocytes in the tissue around a coil gland. M.

congested and the exudation of serum is abundant; much fibrin forms in it. The cellular exudation consists chiefly of polymorphonuclear leukocytes which often collect in large numbers. Hemorrhage is a common complication and seems to be due to injury of the vessel walls, caused by toxin derived from the organisms. The necrosis which usually slowly occurs and spreads seems to be due, in part at least, to obstruction of the blood-vessels by the exudation around them. Owing to the large amount of

fibrin present in the exudation, softening and suppuration are not common features.

Lesion.—The characteristic and most common lesion caused in man by the anthrax bacillus is that known clinically as malignant pustule or anthrax carbuncle. It starts as an infection of an abrasion or minute injury of the skin. The resulting focal lesion, composed of inflammatory exudation which causes marked swelling, rapidly enlarges. Some of the exuded serum escaping into the skin forms small vesicles. As the lesion spreads the vesicles increase in number peripherally. In the center of the lesion they usually become ruptured early and the serum oozing dries to form

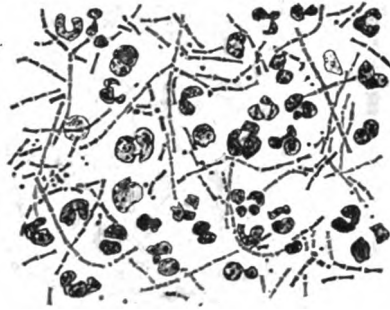

Fig. 79.—Anthrax bacillus. Exudation consists of polymorphonuclear leukocytes.

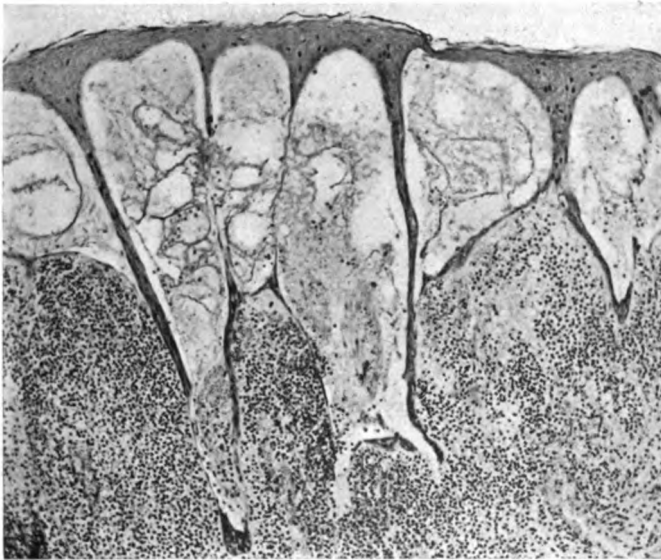

Fig. 80.—Vesicles on surface of pustule due to the anthrax bacillus. M.

a scab. The congested vessels color the lesion red, but usually the center of it early becomes cyanotic from stasis and hemorrhage.

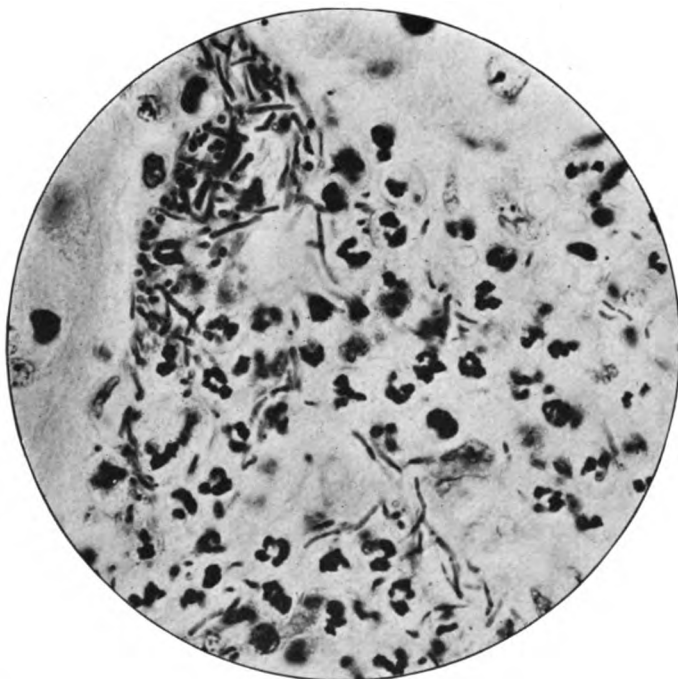


Fig. 81.—Anthrax pustule of skin. Anthrax bacilli and exudation of polymorphonuclear leukocytes produced by them. M.

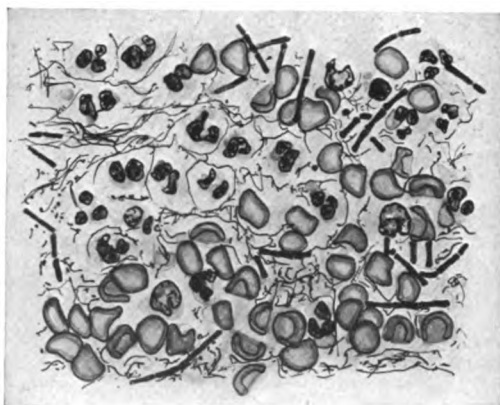

Fig. 82.—Anthrax bacillus. Acute meningitis. Hemorrhagic type of exudation.

Occasionally the lesion in the skin appears in the form of an extensive diffuse edematous process.

Gastro-intestinal Tract.—The gastro-intestinal tract may be infected primarily by ingestion of anthrax spores, or secondarily by conveyance of bacilli to the mouth from a lesion of the skin. It is also believed that lesions arise in this situation as a result of anthrax septicemia. The facts are not easy of proof. The lesions are usually focal and marked by swelling, congestion, and usually by hemorrhage. The center of a lesion may undergo necrosis with the formation of a slough. Rarely the lesions in the intestinal tract take the form of a diffuse edematous process with hemorrhage and necrosis.

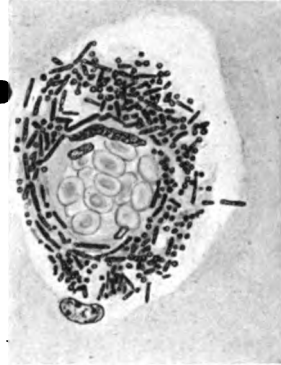

Fig. 83.—Anthrax bacilli growing in the wall of a blood-vessel in the brain.

Lungs.—Primary infection of the lungs is rare and occurs usually among rag pickers. The infection results in a bronchopneumonia with extension to the

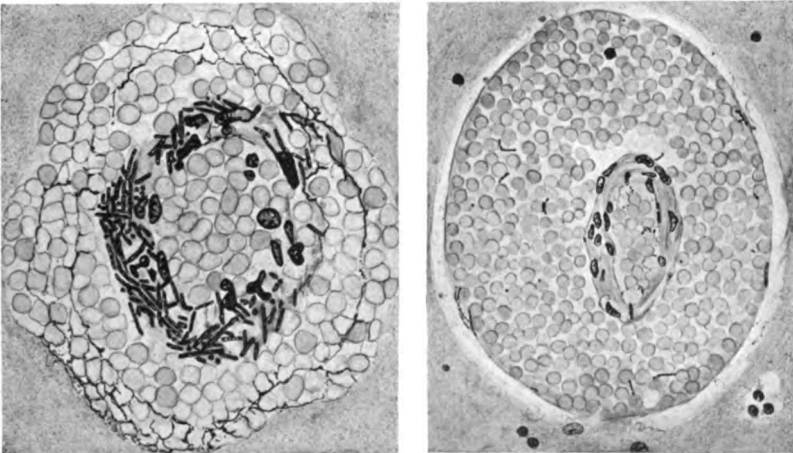


Fig. 84.—Anthrax bacillus in walls of blood-vessels in cerebrum and hemorrhages caused by it.

lymphatics and involvement of the pleura and sometimes of the mediastinum.

Septicemia.—Anthrax septicemia is a frequent and dangerous complication of the primary focal infection, but is not necessarily

always fatal. The number of organisms circulating in the blood is never enormous, as it often is just before death in inoculated animals. Still they can usually be demonstrated by cultures and found microscopically in sections. The organisms carried to all parts of the body may set up lesions in various organs. The lesions most commonly caused are bronchopneumonia and meningitis.

As the result of the septicemia the spleen is enlarged, usually to more than twice the normal size.

Meningitis.—Anthrax meningitis is usually characterized by much hemorrhage. The abundant exudation consists of serum and polymorphonuclear leukocytes. Much fibrin forms, especially around the blood-vessels. The bacilli are usually present in large numbers. The process frequently extends along the blood-vessels from the pia into the brain substance and hemorrhage often occurs around the vessels.

BACILLUS MUCOSUS CAPSULATUS

The bacillus mucosus capsulatus or Friedländer's bacillus was held originally to be the cause of lobar pneumonia. It does produce that lesion occasionally as well as lobular pneumonia,

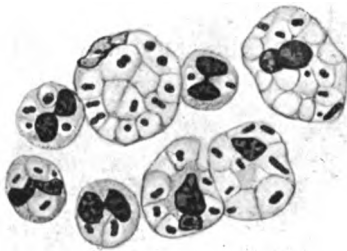


Fig. 85.—Lobar pneumonia due to the bacillus mucosus capsulatus. The bacilli are within polymorphonuclear leukocytes.

but from a pathologic point of view it is a much less important organism than the micrococcus lanceolatus. Its name covers a group of Gram-negative capsulated bacilli which differ in minor characteristics.

Micro-organism.—The bacillus is usually very numerous in the lesions which it produces; in fact, it is often more abundant than the exudation itself.

In this respect it resembles the plague bacillus. A diagnosis of the organism can often be made with more or less certainty, on gross examination of the lesions it produces, from the slimy appearance and feel of the exudation due to the presence of the numerous bacilli with their mucoid capsules.

The organisms occur free in the exudation and also enclosed in polymorphonuclear leukocytes.

Toxin, Injury and Reaction.—The toxin secreted seems relatively mild, although it sometimes produces necrosis, so that

softening of the tissue and abscess formation occur. The exudation is composed of serum and polymorphonuclear leukocytes. Fibrin may be small in amount or abundant. Endothelial leukocytes are usually few in number; they often incorporate both bacilli and polymorphonuclear leukocytes.

Occurrence.—Friedländer's bacillus occurs occasionally in lobar, more often in lobular pneumonia. From these lesions it may extend and produce a pleuritis or pericarditis. It sometimes enters the circulation causing a septicemia and giving rise to multiple abscesses in the kidneys and elsewhere. Meningitis may be produced in the same way.

In one instance a septicemia persisted for weeks at least. If the patient bruised himself anywhere an abscess resulted. The day he was discharged from the hospital as cured blood cultures were taken and numerous colonies developed, showing that the septicemia still persisted.

BACILLUS OF RHINOSCLEROMA

This organism is closely related to bacillus mucosus capsulatus and evidently belongs in the same group, but it is less toxic. It gives rise to a chronic indurative process affecting the respiratory

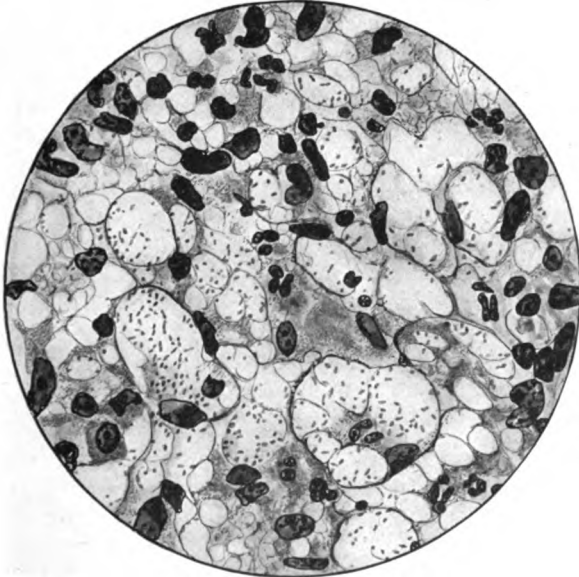


Fig. 86.—Rhinoscleroma. The bacilli are within endothelial leukocytes.

tract. The bacillus occurs in the nasal secretion of infected patients and is evidently conveyed from them to others. The lesion

starts in the mucous membrane of the nose causing thickening and induration, and extends along the respiratory tract into the trachea and bronchi gradually narrowing the lumina and eventually producing death. The lesion frequently extends out on to the external nares, less often to the upper lip, causing smooth, hard, nodular swellings. It is these visible lesions which have given the name to the infection and enable it to be recognized during life.

Histologically the lesion consists of masses of endothelial leukocytes filled with capsulated bacilli. That is the essential part of the lesion, the inflammatory reaction to the mildly injurious agent. In addition there is some increase of fibroblasts and usually considerable infiltration with lymphocytes.

• BACILLUS MALLEI

The bacillus mallei produces in man a primary, and usually multiple secondary, acute to chronic exudative lesions which are all included under the term glanders, a disease occasionally acquired by man from horses.

Micro-organism.—The glanders bacillus occurs in small to large numbers in the lesions which it produces. It usually lies free between the exudative cells, but often occurs in large numbers within endothelial leukocytes. Rarely it may be found within polymorphonuclear leukocytes. It stains very lightly and appears as a short to sometimes quite long, delicate, vacuolated rod which it requires a little practice to recognize readily in sections.

Toxin and Injury.—The glanders bacillus produces a strong toxin which acts locally and produces necrosis. Its toxic effect is best studied when the lesion occurs in muscle-tissue, because the degenerative changes in the muscle-fibers are marked and easily seen.

Reaction.—The reaction to the glanders bacillus is intense, exudative in type, and consists of serum, fibrin, and polymorphonuclear and endothelial leukocytes in varying proportions. The necrotic tissue quickly liquefies and the fibrin dissolves and disappears, so that abscesses are formed. Striated muscle-fibers become hyaline, vacuolated, invaded by polymorphonuclear leukocytes and digested. The exudative cells are quickly injured by the toxin and undergo degenerative changes so that their true nature is often difficult to recognize, except in the earliest lesions or at the periphery of an older lesion.

Many of the endothelial leukocytes undergo a peculiar and fairly characteristic degenerative change. The nucleus enlarges, becomes multilobulated and often by direct division multinucleated, so that a kind of giant-cell is formed. This is especially the case when the endothelial leukocytes, as phagocytes, have taken up

polymorphonuclear leukocytes and increased much in size. These large, lobulated and multiple nuclei generally stain intensely for a while and then fade away as the cells undergo necrosis.

The lesion produced by the glanders bacillus tends to spread peripherally, especially along the lines of least resistance, as, for example, in the connective-tissue septa of fat and muscle-tissues,

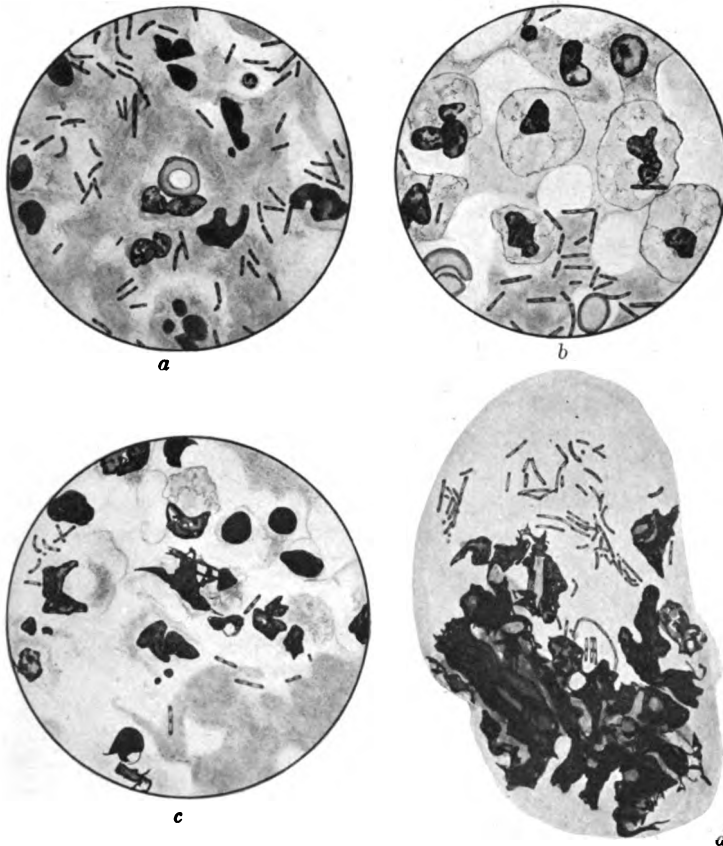


Fig. 87.—Focal pneumonia due to the glanders bacillus. Detail drawings showing bacilli and character of exudation. In *d*, one of the characteristic large cells.

along the sheaths of nerves and around blood-vessels. Still more characteristic is a marked tendency to invade blood-vessels, especially veins, and spread along them. Here a thrombus of fibrin, polymorphonuclear and endothelial leukocytes is quickly formed. Later, the fibrin in the center of the thrombus softens and disappears, the cells degenerate, and the characteristic large, lobulated

and multiple nuclei may form within endothelial leukocytes before they undergo necrosis. From these softened thrombi the glanders bacilli unquestionably escape readily into the circulation and are carried all over the body. This thrombus formation is common in the veins of the subcutaneous and muscle-tissues, and especially in the lungs, where the only lesions may consist of the thrombi within the pulmonary veins and arteries. In this latter condition it must be assumed that the organisms brought to the lung by the circulation have remained within the blood-vessels and produced lesions there only. The thrombi in the blood-vessels in other situations may owe their origin at times to a similar method of starting.

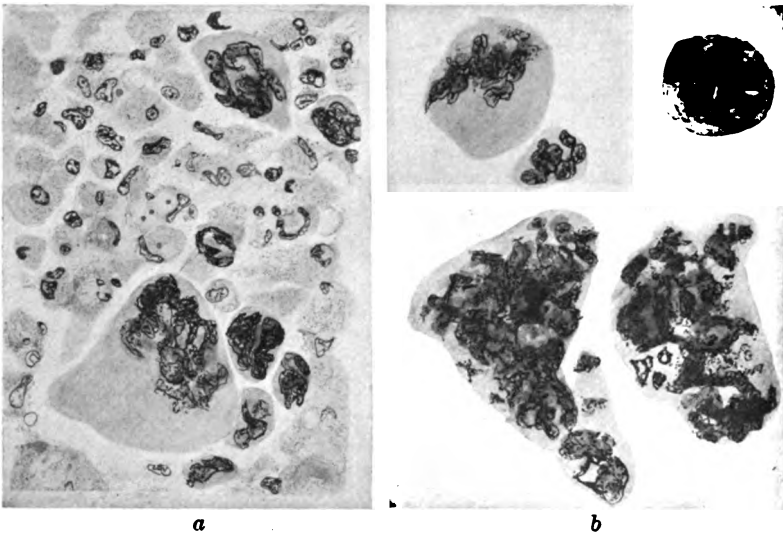


Fig. 88.—Glanders bacillus. Focal pneumonia. The large cells with large lobulated nuclei are fairly characteristic of this infectious agent.

Primary Lesions.—In man infection usually occurs through a scratch or other injury of the skin, much less often through the digestive or respiratory tract. In the skin a suppurative lesion is produced which may be quite extensive and more or less chronic in type. It does not differ particularly, however, from infectious lesions due to other organisms.

Secondary Lesions.—The secondary lesions in glanders are due to the bacilli obtaining entrance to the circulation and being carried all over the body. They produce focal lesions, usually acute in character, in the skin and subcutaneous tissues, less often

in muscle, and very commonly in the lungs, liver, spleen, and central nervous system, and in the mucous membranes.

Skin.—When the lesion in the skin is near the external surface, serum, and later, polymorphonuclear leukocytes due to the inflammatory reaction, escape into the epidermis, separate the cells and lead to the formation of a vesicle which gradually changes to a pustule.

Lung.—In the lungs the organisms brought by the blood usually gain access to the alveoli and produce a miliary bronchopneumonia with serum, fibrin, polymorphonuclear and endothelial leukocytes in the exudation. Soon the alveolar walls involved undergo necrosis, the fibrin dissolves and abscesses are formed and may gradually increase in size.

Sometimes the organisms remain within the pulmonary vessels and give rise to thrombi composed of polymorphonuclear and endothelial leukocytes and fibrin. Later the thrombi soften down.

Liver, Spleen, Brain, Etc.—The lesions in the other organs do not require special mention. They are all of the type of acute abscesses, in which the organism is the most important element. Still the type of the histologic changes in the lesions is often so characteristic, owing especially to the formation of the large lobulated and multinucleated endothelial leukocytes, that the nature of the etiologic factor may often be shrewdly guessed.

BACILLUS AÉROGENES CAPSULATUS

The bacillus *aërogenes capsulatus* is of interest from two points of view, first, because it is a dangerous invader of wounds, often causing death; second, because it sometimes produces gas in the human body, occasionally during life, more often postmortem. The organism is widely distributed in nature. It is found, for example, in the soil and occurs also quite commonly in the intestinal tract of man. It is, therefore, frequently in a position to infect wounds or to obtain entrance to the body through ulcerated surfaces.

The bacillus occasionally infects wounds of the extremities, especially compound fractures, and causes rapidly spreading necrosis which is complicated by the presence of bubbles of gas, largely hydrogen, produced by the organism. Owing to this peculiarity the condition is commonly known as emphysematous gangrene. The gas which is formed in different organs, as the result of a septicemia, gives rise to conditions known as gas cysts, foamy liver, etc.

Micro-organism.—The bacillus appears as a straight rod not unlike the anthrax bacillus, but somewhat thicker and more variable in length. Occasionally in a septicemia it will be found growing in chains. It is Gram-positive and stains readily also by

the ordinary methods. It multiplies rapidly and may be very numerous in the lesions it produces. If the multiplication is largely or entirely postmortem there is no evidence of inflammatory reaction around the bacilli which are sometimes exceedingly numerous in the walls of the gas cysts.

Toxin, Injury and Reaction.—The bacillus *aërogenes* produces substances which cause necrosis of cells, dissolve chromatin, hemolyze the blood and dissolve the tissues. The toxin is strong and produces rapid and often extensive necrosis. When muscle-tissue is affected the fibers may become hyaline or be digested, so that each fiber is separated into discs or the sarcous elements are set free. Under this condition these elements may be taken up in large numbers by the polymorphonuclear leukocytes.

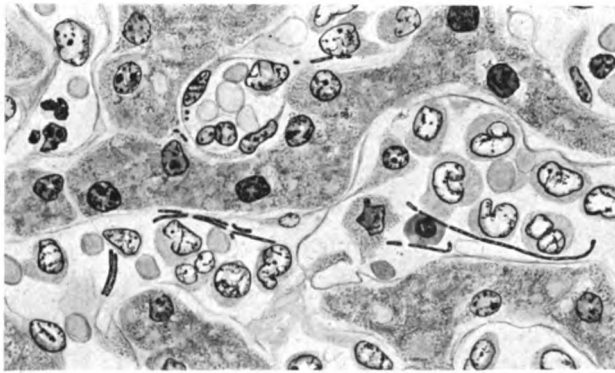


Fig. 89.—Liver from a case of septicemia due to the bacillus *aërogenes capsulatus*. Many endothelial leukocytes in the blood.

The inflammatory reaction varies considerably. There may be considerable serum and many polymorphonuclear leukocytes. More or less fibrin may be formed. At other times the exudation is slight in amount.

Septicemia frequently follows infection with the bacillus *aërogenes*. As a result the organisms are carried to all parts of the body. Whether they give rise to gas formation antemortem or not is an unsettled question. Occasionally they seem to, but in most instances the gas is evidently produced after death. Cysts are formed most frequently in the liver, intestine and brain.

BACILLUS TYPHOSUS

Introduction.—The typhoid bacillus ordinarily produces a definite series of lesions characteristic of the disease known as typhoid fever. These lesions will be considered first. Certain

other lesions which sometimes occur and usually, perhaps always, accompany or follow an attack of typhoid fever will be taken up briefly later.

Typhoid fever is an acute, self-limited disease which may recur after a very short interval. If the patient recovers he has practically acquired immunity from further attacks.

The site of infection and the nature of the lesions in typhoid fever are always the same; they vary only in intensity.

Micro-organism.—The typhoid bacillus obtains entrance to the human body through the gastro-intestinal tract and by that way only. It multiplies usually in the lower end of the ileum; sometimes in the ileum and colon; rarely most abundantly in the

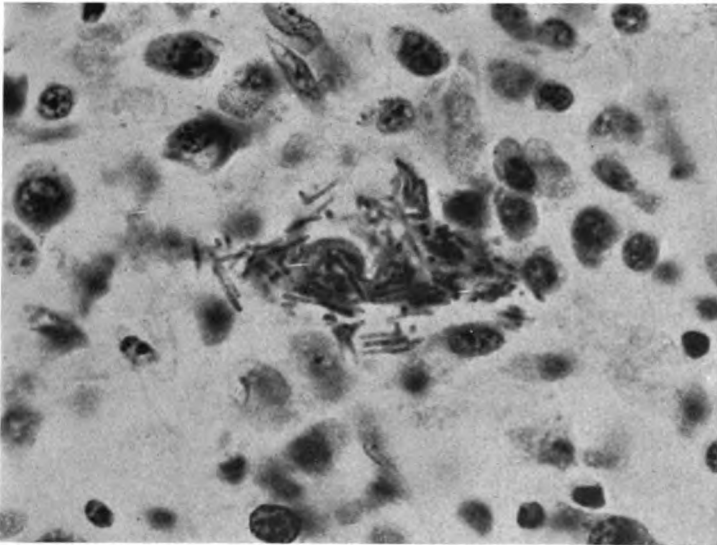


Fig. 90.—Typhoid fever. Intestine. Characteristic clump of bacilli. M.

colon. It sometimes enters the appendix. Early in the infection it invades the intestinal wall and gains access to the blood-current, giving rise to a septicemia.

The typhoid bacillus is not conspicuous in the lesions to which it gives rise. In tissues fixed soon after death, or at operations for intestinal perforation, the organisms are few, scattered, and difficult to find, and not to be distinguished with certainty morphologically from the colon bacillus. When tissues are fixed in preservatives a number of hours after death bacilli, as a result of post-mortem growth, are frequently found in small and large colonies in the intestinal wall, mesenteric lymph-nodes, liver, and spleen.

These organisms have generally been regarded as characteristic typhoid bacilli, but are necessarily open to some doubt; they might be colon bacilli.

Toxin.—There is rarely the intimate relation between the typhoid bacillus and the lesion produced by it, which obtains, for example, between the tubercle bacillus and the reaction around it. This lack of relation is probably more apparent than real and is due to the fact that the typhoid toxin appears to be not a secretion of the living organism, but a product of the disintegration of its dead body; hence the relation is between the products of disintegration, which cannot be demonstrated, and the lesion.

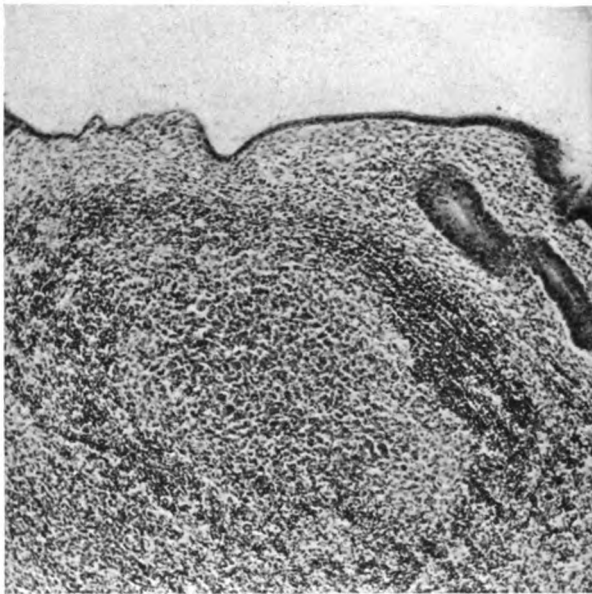


Fig. 91.—Typhoid fever. Lymph-nodule in a Peyer's patch largely replaced by phagocytic endothelial leukocytes. M.

The toxin is apparently soluble and diffusible, extending for a certain distance peripherally around a dissolving bacterium and being absorbed and carried in the lymph and blood streams. Judging from the character and distribution of the lesions in the intestine, much toxin is also absorbed from the intestinal tract where the typhoid bacilli are at first located.

Injury.—The typhoid bacillus under ordinary conditions does not produce necrosis of the cells with which it comes in contact. In fact it does not seem to produce any direct injury. The

necrosis which occurs in the later stages of typhoid fever is of secondary origin, due to the cellular reaction to the organism.

Reaction.—The inflammatory exudation in typhoid fever is the result of the reaction against the typhoid bacillus and its toxin; it does not take place in consequence of any injury of tissue cells produced by the organism.

The typhoid bacillus produces a mild type of inflammatory reaction consisting almost entirely of endothelial leukocytes which accumulate in large numbers where the typhoid toxin is strongest and thus form the lesions characteristic of typhoid fever. These endothelial leukocytes are strongly phagocytic for other cells,

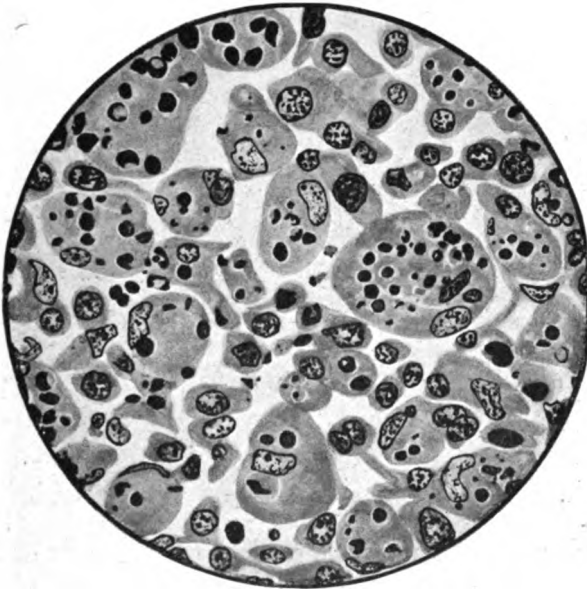


Fig. 92.—Typhoid fever. Phagocytic endothelial leukocytes in lymph-nodule in a Peyer's patch.

incorporating and digesting large numbers of them. In the intestinal lesions they take up chiefly lymphocytes, in the spleen red blood-corpuscles, and in the blood-vessels, especially of the portal circulation, polymorphonuclear leukocytes and red blood-corpuscles. The morphologic evidence strongly favors the view that the endothelial leukocytes take up and digest these various cells, not because the latter have been injured by toxins, but because they are needed for nutritive purposes by the endothelial leukocytes in the preparation of an antitoxin to neutralize the typhoid toxin.

As a result of the typhoid toxin in the tissues and in the blood- and lymph-vessels, which only endothelial leukocytes seem able to combat, the endothelial cells lining the blood- and lymph-vessels and the reticulum of the lymphoid tissue, proliferate rapidly and desquamate or are set free as endothelial leukocytes. These leukocytes are capable of emigrating, migrating, and proliferating. They accumulate in large numbers in the lymphoid tissue, lymphatics and lymph-spaces, and blood-vessels wherever the typhoid toxin is present.

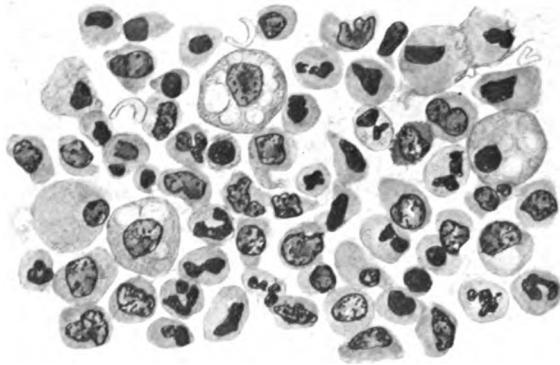


Fig. 93.—Typhoid fever. Phagocytic endothelial leukocytes present in small numbers in clot from heart.

The endothelial leukocytes attracted by the typhoid toxin sometimes have associated with them a varying number of lymphocytes, especially within the lymphatics, and more or less fibrin; these two elements seem to be secondary rather to degenerative changes in the endothelial leukocytes and other cells, than directly to the typhoid toxin.

In order to understand the gross lesions produced by the typhoid bacillus, which under ordinary conditions leads chiefly or exclusively to an accumulation of endothelial leukocytes, it is necessary to take up these lesions in detail.

Distribution of Lesions.—The chief and characteristic lesions of typhoid fever are distributed along the path of absorption of the typhoid toxin from the intestinal tract, namely, in the lymphatic apparatus of the intestinal wall and in the mesenteric lymph-nodes. In addition, the toxin in the blood-vessels leads to changes in the character and relative proportions of the blood elements and to the accumulation of endothelial leukocytes, especially in the

spleen, bone marrow, and portal circulation. These lesions are all more or less diffuse in character. They are complicated by focal lesions due to the attraction of endothelial leukocytes around dead, disintegrating typhoid bacilli. These focal lesions are best

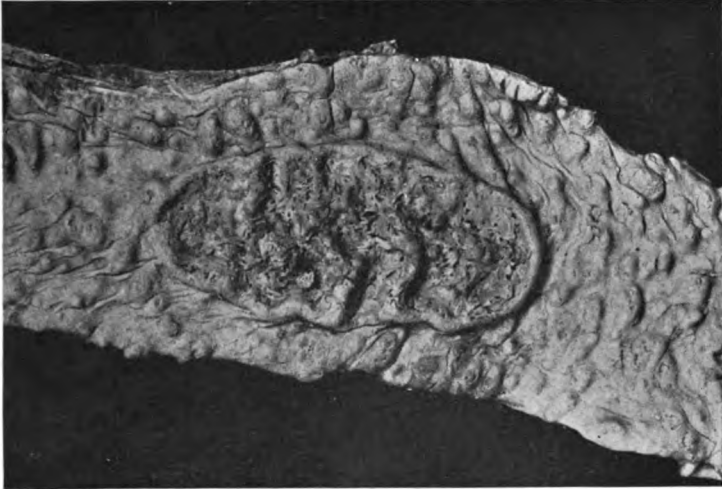


Fig. 94.—Typhoid fever. Intestine showing marked swelling of a Peyer's patch and of numerous solitary lymph-nodules.




Fig. 95.—Typhoid fever. Ileocecal valve, appendix and lower end of ileum. Marked swelling of a Peyer's patch and of numerous solitary lymph-nodules. Necrosis and beginning ulceration of surface of many of them.

seen in the liver, the bone marrow, and the spleen; in the intestine and mesenteric lymph-nodes they are largely or entirely masked by the more prominent diffuse lesions.

Intestine.—The lesions of the intestine in typhoid fever are usually most prominent in the Peyer's patches and in the solitary and agminated lymph-nodules of the ileum. They are severest just above the ileocecal valve and diminish in intensity from this point upwards. If they were due entirely to the presence of bacilli,

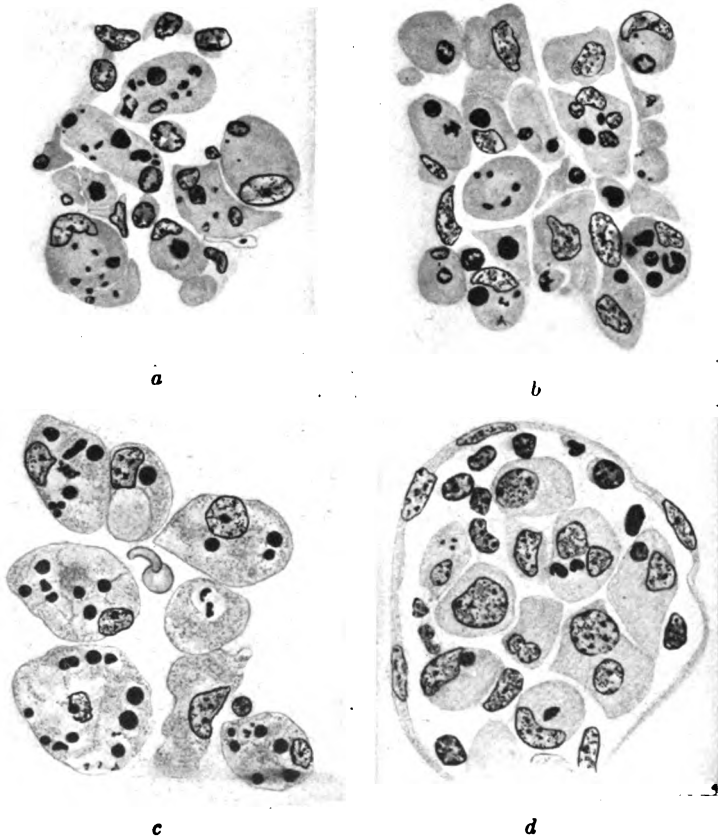


Fig. 96.—Typhoid fever. Phagocytic endothelial leukocytes. *a*, *b*, and *c*, In a lymph-nodule in a Peyer's patch; *d*, in a lacteal in the mucous membrane.

as in tuberculous lesions, instead of largely to the absorption of typhoid toxin from the intestinal canal, this gradual diminution in the severity of the lesion upward would not hold. Frequently, in the lower part of the ileum the lesions also involve the mucous membrane between the patches of lymphoid tissue. Occasionally

many of the lymph-nodules in the colon are involved, and rarely, the lesions are more prominent in this portion of the intestine. When the appendix is affected the lesion corresponds to that in the ileum.

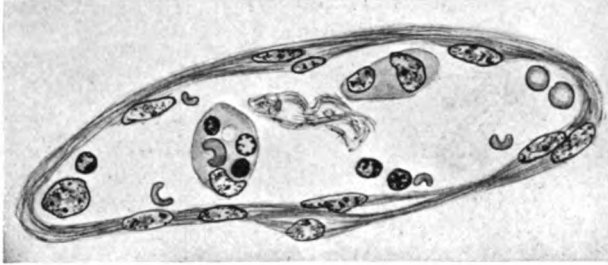


Fig. 97.—Typhoid fever. Phagocytic endothelial leukocytes in blood-vessel in wall of intestine.

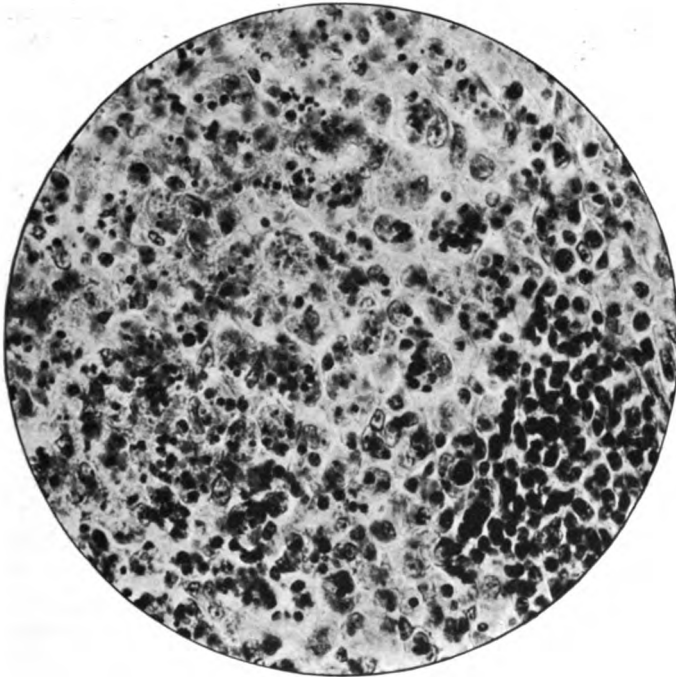


Fig. 98.—Typhoid fever. Part of a lymph-nodule in a Peyer's patch; largely replaced by phagocytic endothelial leukocytes. M.

The lesion for the first seven to ten days consists only of a thickening or swelling of the lymphoid tissue and in severe cases also of the adjoining mucous membranes. The thickening may

reach four to six or even, rarely, eight or ten millimeters. It is due to the accumulation of large numbers of endothelial leukocytes in and around the lymph-nodules, in the mucous membrane, in the submucosa and frequently, also, in the muscle coats. They are present in abundance in the lacteals and in all the lymphatics, but especially in the submucosa. Occasionally the subperitoneal

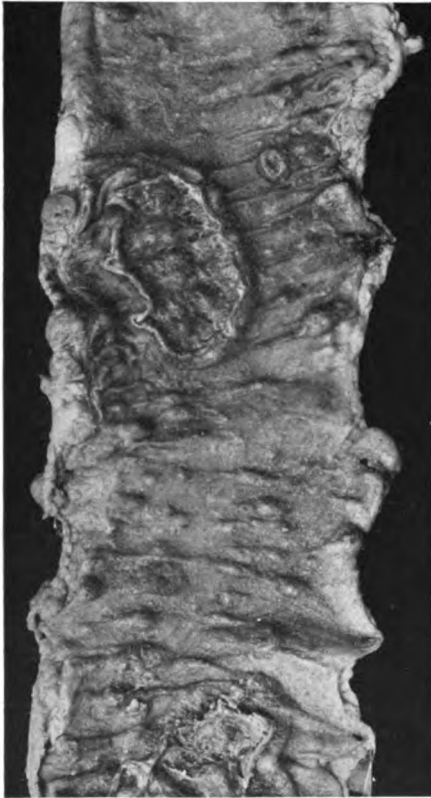

Fig. 99.—Typhoid fever. Intestine with large sloughs still attached in the Peyer's patches.

lymphatics may be so distended with cells that they stand out prominently as white lines. The capillaries, and especially the veins of the intestine, contain numerous endothelial leukocytes, while polymorphonuclear leukocytes are to a large extent or entirely absent. In all these situations the endothelial cells and leukocytes may be found occasionally, sometimes frequently, in mitosis.

In the lymphoid tissue the lesion is sometimes most marked within the lymph-nodules which may be entirely occupied, except for a narrow rim at the periphery, by endothelial leukocytes filled with the more or less digested remains of the lymphocytes which have been incorporated. In other instances the endothelial leukocytes are more abundant around and between the lymph-nodules.

In the lacteals and lymphatics the endothelial leukocytes usually have associated with them a varying number of lymphocytes, and more or less serum and fibrin.

In mild cases of typhoid infection the development of the lesion in the intestine may cease at this point, owing to the formation of enough antitoxin to counteract the injurious effect of the bacteria. The endothelial leukocytes then quickly undergo degeneration

and disappear. In the severe cases, however, the accumulation of endothelial leukocytes continues and leads frequently to occlusion of the smaller blood-vessels here and there, usually near the surface in the swollen lymphoid tissue. The occlusion seems to be due partly to external pressure on the vessels by the accumulated cells, partly to obstruction by cells collected within the vessels. This is caused, in part at least, by cells accumulating beneath the lining endothelium where they often undergo necrosis and lead to the formation of fibrin thrombi. Owing to obstruction of the blood-vessels and the resulting interference with nutrition the cells begin to undergo necrosis. The necrosis may be slight and superficial if the occluded vessels are small; occasionally, however, the obstructed vessel is large; then the area of necrosis is large. As soon as necrosis of the surface epithelium occurs the way is open to infection by various bacteria which may themselves cause more extensive necrosis. This infected necrotic tissue leads to an active inflammatory exudation of polymorphonuclear leukocytes all along the edge where it abuts on living tissue.

The necrotic tissue macerates and disintegrates along its inner surface. The main mass, however, which appears as the slough on gross examination, is finally set free by the digestive action of the polymorphonuclear leukocytes along its border. When it separates it may leave behind one or more eroded vessels which give rise to intestinal hemorrhage, or the necrosis may have extended so deep that perforation of the intestinal wall occurs.

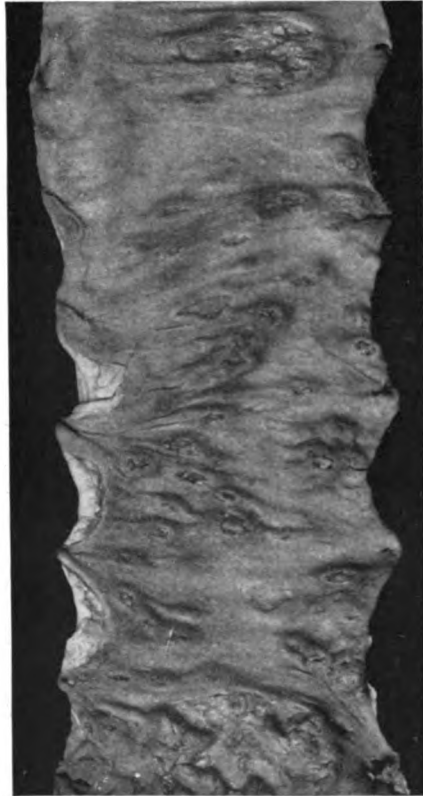

Fig. 100.—Typhoid fever. Intestine showing sloughs and ulcerations.

In the repair of the ulcerations occurring in typhoid fever there is no cicatricial contraction. This is due probably to two causes. The lesion is of brief duration, especially the stage of necrosis which alone affects the connective tissue. In other words, the injury done the fibroblasts is short and sharp; it is not prolonged. Secondly, the slough is soon cast off; there is no necrotic tissue or

fibrin left on the surface to stimulate proliferation of fibroblasts or require organization.

Mesenteric Lymph-nodes.—The lesions in the mesenteric lymph-nodes correspond closely to those in the intestine except in one particular; they are rarely exposed like the latter to the complication of secondary infection.

The toxin reaches the lymph-nodes from the intestine by way of the lymphatics; both those entering and those leaving the lymph-nodes are usually distended with serum, endothelial leukocytes and lymphocytes. The peripheral and other sinuses within the nodes show the same contents. In the lymphoid tissue the endothelial leukocytes may be scattered diffusely or they may be

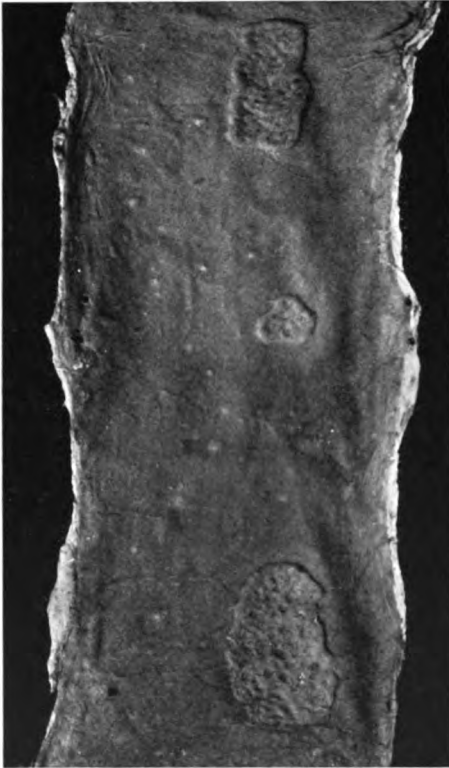


Fig. 101.—Typhoid fever. Intestine showing ulcerations.

more or less focally grouped. As a rule, they are less abundant within the lymph-nodules than elsewhere.

As the process advances the sinuses often become occluded by the masses of cells fused together in a fibrinous mesh-work. Fibrinous thrombi frequently form in the walls of the veins and may lead to occlusion of them. More or less extensive necrosis often occurs and may involve an entire lymph-node. Such a lymph-node on section appears yellow and caseous, suggesting a tuberculous process. Sometimes hemorrhage takes place.

The accumulation of endothelial leukocytes is not limited to the lymph-node. They often infiltrate in large numbers the capsule and fat tissue outside of the nodes and probably show the distance to which the typhoid toxin diffuses and, therefore, exerts its chemotactic influence.

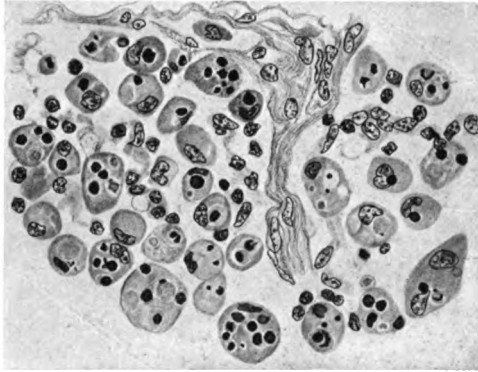


Fig. 102.—Typhoid fever. Phagocytic endothelial leukocytes in the peripheral lymph-sinus of a mesenteric lymph-node.

Liver.—Two types of lesions are present in the liver, the one focal, the other diffuse. In addition, the sinusoids in the early stage of the disease contain large numbers of phagocytic endothelial leukocytes filled with red blood-corpuscles and occasional lympho-

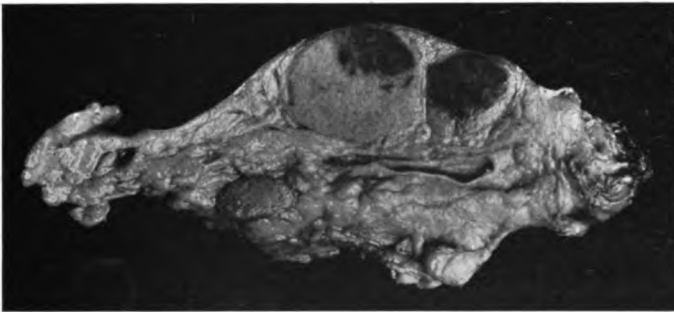


Fig. 103.—Typhoid fever. Swollen mesenteric lymph-nodes with hemorrhage.

cytes and polymorphonuclear leukocytes. The endothelial cells lining the sinusoids frequently contain cellular inclusions and rarely may be found in mitosis.

The focal lesions closely resemble miliary tubercles in size, shape and distribution. They are composed of accumulations of

endothelial leukocytes which block up the sinusoids and lead to necrosis of the included liver cells and sometimes, also, of the leukocytes centrally situated in consequence of nutrition being cut off. After necrosis has begun, more or less fibrin is usually formed, and a few lymphocytes may be attracted to the nodules.

These focal lesions have been explained as miliary infarcts due to occlusion of the sinusoids by the large phagocytic endothelial leukocytes. Two points may be urged against this explanation. The leukocytes in the nodules are usually less phagocytic than

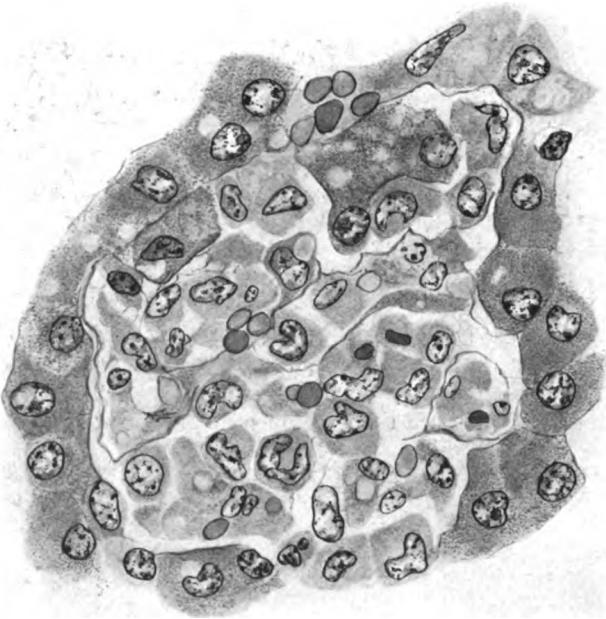


Fig. 104.—Typhoid fever. Focal lesion in liver composed of endothelial leukocytes.

elsewhere and hence not so large. Secondly, if a lesion forms near a large vein, endothelial leukocytes will collect on the inner wall of the vein adjoining the nodule and form a sort of endothelial leukocyte thrombus, similar to a blood platelet thrombus. This observation shows that the leukocytes are attracted into the nodules, not pushed there by the blood current.

The study of the early stage of the miliary tubercle in the liver shows that it is formed, exactly like the typhoid nodule, of an accumulation of endothelial leukocytes, and when it adjoins a

vein, endothelial leukocytes in the blood stream are attracted to the wall over the tubercle. By proper staining methods it is possible to demonstrate one or more tubercle bacilli in the center of each tubercle. It seems reasonable to explain the typhoid nodules in the same way; each is an accumulation of endothelial leukocytes attracted around a typhoid bacillus, not living, but dead and disintegrating (probably within an endothelial cell lining a sinusoid), thus setting free the toxin which attracts these leukocytes to neutralize and counteract it.

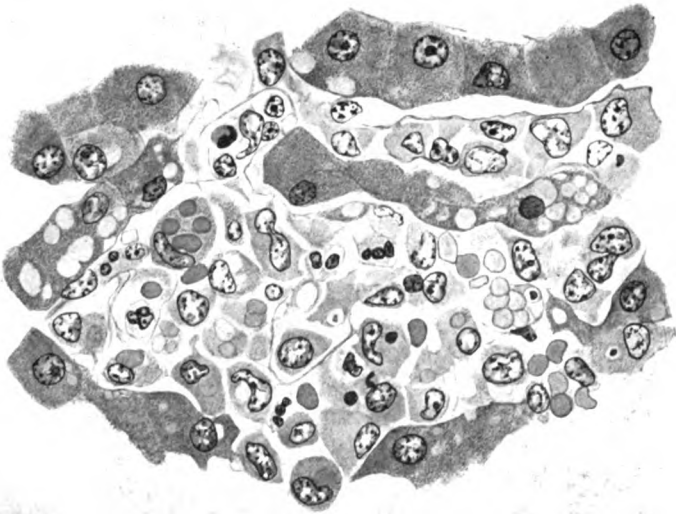


Fig. 105.—Typhoid fever. Focal lesion in liver composed of endothelial leukocytes. Some of them contain red blood-corpuscles and portions of other leukocytes.

Repair of these focal lesions may result in small foci of scar tissue.

The diffuse lesion consists of endothelial leukocytes along the line of lymphatic absorption, namely, in and around the lymphatics which accompany the portal vessels. As a rule, they are not numerous, but occasionally the lymphatics are distended with leukocytes. Rarely they fuse in this location to form an occasional giant-cell.

Spleen.—The terminal veins of the spleen are greatly distended and filled with numerous endothelial leukocytes which are full of red blood-corpuscles, and occasionally of polymorphonuclear leukocytes and lymphocytes. Sometimes the vessels are occluded

with a thrombus composed of these phagocytic leukocytes held together by a reticulum of fibrin. These thrombi may belong with focal lesions occurring here and there in the spleen, which are evidently of the same nature as those in the liver. These typhoid nodules sometimes encroach on the lymph-nodules which otherwise usually show no change. The phagocytic cells occur also in the tissue between the veins.

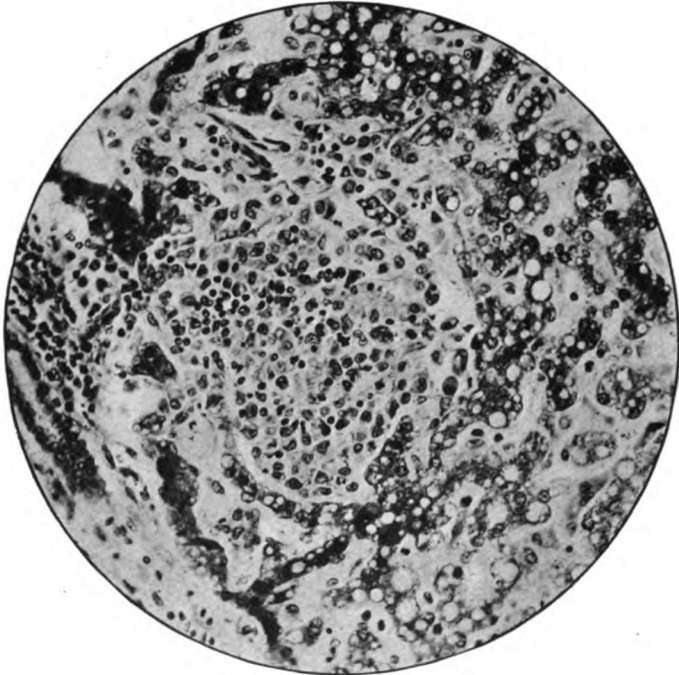


Fig. 106.—Typhoid fever. Focal lesion in liver. Consists chiefly of endothelial leukocytes some of which are phagocytic. M.

Occasionally endothelial leukocytes may be found in considerable numbers beneath the lining endothelium of the larger veins.

This great accumulation of endothelial leukocytes in the spleen leads to considerable increase in its size, and in the early stage of the disease to a marked increase of consistence. Later, the consistence becomes soft and flabby.

If recovery takes place the hemoglobin of the red corpuscles within the endothelial leukocytes is gradually changed to hemosiderin which is slowly dissolved, so that during the process the spleen contains large numbers of pigmented cells.

Bone Marrow.—The blood-vessels of the bone marrow contain numerous endothelial leukocytes filled with red corpuscles, and occasional lymphocytes and polymorphonuclear leukocytes. The characteristic lesion is, however, the typhoid nodule which corresponds in every way to that found in the liver and unquestionably is formed in the same way. As these lesions get older and some of

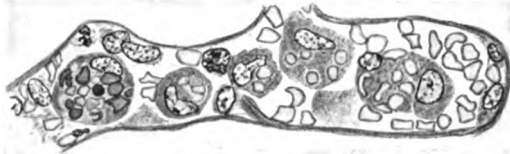

Fig. 107.—Typhoid fever. Spleen. Phagocytic endothelial leukocytes containing red blood-corpuscles in blood-sinus.

the cells undergo necrosis more or less fibrin is formed and this masks the true character of the cell reaction.

Owing to the cell activity in the bone marrow as the result of the typhoid lesions, the fat tissue in the long bones is more or less encroached upon by erythroblasts and myelocytes and becomes red.

In addition to the tissues already described, numerous endothelial leukocytes are frequently found in various lymphatics, for example, those of the heart. Occasionally focal lesions (typhoid nodules) occur also in other organs; for instance, they have been found in the kidney, adrenal gland, pancreas, and testicle.

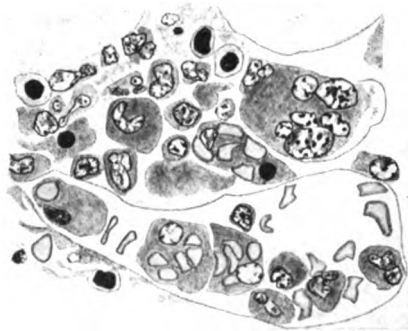

Fig. 108.—Typhoid fever. Phagocytic endothelial leukocytes in and between blood-sinuses of spleen.

Lung.—Besides the typical lesions thus far described the typhoid bacillus occasionally gives rise to others. Thus, typhoid fever may be complicated by a lobar pneumonia in which the typhoid bacilli seem to play a more or less important part; at least they occur in the alveolar exudation which contains large numbers of phagocytic endothelial leukocytes, suggesting a reaction similar to that in the intestine.

Meningitis.—Rarely an acute meningitis supervenes in which

the only organism demonstrable is the typhoid bacillus. The cellular exudation consists of numerous endothelial and polymorphonuclear leukocytes and more or less serum and fibrin.

Gall-bladder.—Although the typhoid bacillus is commonly found to be present in the gall-bladder, it produces no lesion of the wall. In like manner it may be present and persist for months in the urinary bladder without producing any lesion. In both situations it may, however, serve as a nucleus for the formation of calculi.

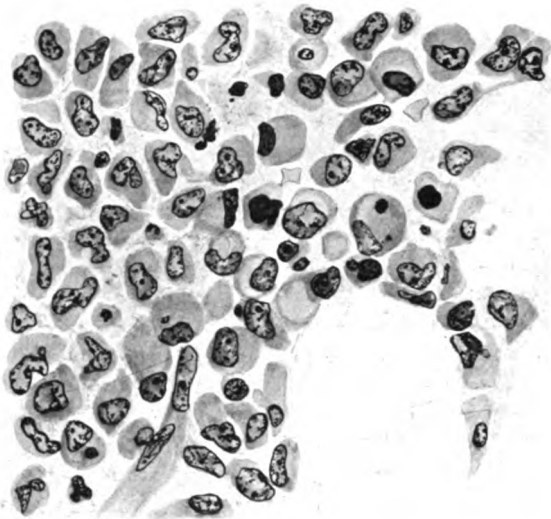

Fig. 109.—Bone marrow from typhoid fever patient. Part of focal lesion containing numerous endothelial leukocytes.

Abscesses.—Abscesses are sometimes produced by the typhoid bacillus. They occur in the spleen, in muscles, and especially in bones, sometimes months or even years after an attack of typhoid fever. The lesion is so different from that ordinarily caused by this organism that it is difficult to explain. A mixed infection has been suggested as the reason. It seems more likely that, under certain rare conditions, the typhoid bacillus multiplies in large numbers in certain favorable foci in the body and then acts possibly by reason of a much more concentrated toxin than under usual conditions. This strong toxin produces necrosis and attracts polymorphonuclear leukocytes just as the tubercle bacillus sometimes does.

BACILLUS COLI COMMUNIS

The colon bacillus is a constant inhabitant of the intestinal tract. Postmortem it is often found widely distributed in the body, probably as the result of a terminal septicemia due to invasion of the circulation shortly before death. It is also found in certain lesions of which it is unquestionably the cause. First in order are the lesions of the urinary tract, namely, of the bladder, ureter, renal pelvis and kidney; second, those of the gall-bladder,




Fig. 110.—Kidney. Acute infectious nephritis (pyelonephritis) due to the colon bacillus. The inflammatory exudation consists largely of endothelial leukocytes. M.

bile ducts and liver; and third, of the pancreas and its ducts. To all these organs the bacillus obtains entrance through natural passages into which it is ordinarily unable to penetrate. Hematogenous infection of these organs in the human being with the colon bacillus is always to be regarded as extremely doubtful, although often strongly claimed. Other less common lesions are peritonitis, abscesses and septicemia.

The lesions produced by the colon bacillus may be very acute

and intense and cause death. In general, however, they are mild and tend to become chronic, especially in the kidney. Frequently the micro-organism dies out and the lesions undergo repair. On this account, especially, it is important to recognize the type of lesions produced by the colon bacillus and their usual distribution, because without an exact knowledge of them the origin of the resulting sclerosis, when recovery and repair have taken place, might not be suspected.

Micro-organism.—The colon bacillus often occurs in large numbers in the lesions which it produces, for example, in the kidney. When it is found in clumps of considerable size a post-mortem growth in the tissues is presumable just as occurs with the typhoid bacillus. At other times it may be difficult to demonstrate the organism microscopically in sections of lesions. Often it is found for the most part only within polymorphonuclear leukocytes of which an occasional one may contain one to a dozen bacilli.

Toxin.—The injurious substance derived from the colon bacillus is apparently an endotoxin, not a soluble diffusible toxin. It varies much in strength, and as a result, the injury and reaction likewise vary greatly. The toxin exerts its effect chiefly or entirely locally.

Injury.—The toxin may cause necrosis of all of the cells in its immediate neighborhood, or only of those which are more highly differentiated. Thus, in the kidney the tubular epithelium is often destroyed, in part or entirely, while the surrounding fibroblasts and the vascular endothelium are left intact. Necrotic cells and mitotic figures may be present in the same tubule. Such lesions tend to be diffuse and in the end to undergo repair because the toxin is not strong and the organism usually dies out. In other instances all the various types of cells are destroyed and abscesses result.

In the liver the epithelium lining the bile ducts is more resistant than the liver cells, probably because the cells are less highly differentiated. In like manner the acinar cells in the pancreas are more easily injured than the duct and possibly the islet cells.

Reaction.—The inflammatory reaction to the colon bacillus may be acute and intense, consisting chiefly of an exudation of serum and of polymorphonuclear leukocytes. This type of reaction commonly terminates in abscess formation as a result of the extensive necrosis. Fibrin is sometimes abundant. Endothelial leukocytes, lymphocytes and eosinophiles may also be present in varying numbers. The blood-vessels in and around the infected areas are usually intensely congested and hemorrhage is a frequent complication. Lesions of this type are fairly common in the kidney and occur occasionally also in the liver. If recovery

takes place they terminate in scar formation. The so-called surgical kidney is usually the result of a chronic infection of this type due to the colon bacillus.

At other times the injury is slight and the reaction of a mild type, consisting largely or chiefly of endothelial leukocytes, while the other exudative elements appear in smaller proportions. The result is a diffuse inflammatory process without extensive necrosis and without abscess formation. Such a lesion terminates in sclerosis of the organ affected.

Urinary Tract.—The colon bacillus is a frequent cause of a cystitis which is usually mild and chronic in type. The infection may ascend through the ureter and involve the kidney. Sometimes the organism produces little or no disturbance in the bladder while the lesion in one or both kidneys may be marked.

The lesions in the kidney vary greatly. The bacillus invades the tubules in the pyramids and ascends towards the cortex. Owing to the way the tubules branch, the affected areas broaden as they approach the capsule. If the organism is very virulent the result is necrosis, acute inflammatory exudation and abscess formation. The process may become chronic and form the so-called surgical kidney.

If the organism is mildly virulent, only the epithelium lining the tubules is destroyed and it may regenerate. The tubules are distended with polymorphonuclear and endothelial leukocytes. One type or the other may predominate. Fibrin is often present. The intertubular tissue is usually infiltrated with numerous lymphocytes and often with many eosinophiles. The fibroblasts, as a rule, show more or less proliferative activity. The colon bacillus toxin produces some evident effect upon them.

The termination of these lesions, if recovery takes place, is to leave behind more or less wedge-shaped areas of sclerosis in the cortex. The tubules may be partly or entirely destroyed, or only compressed by the contracting connective tissue and atrophied. The glomeruli are often sclerosed and hyaline, but they contain living cells. In this way they may be readily distinguished from the glomeruli in a partially organized infarct.

Gall-bladder and Liver.—Cholecystitis, usually chronic in type, is often caused by the colon bacillus. Less often the micro-organism invades the bile ducts of the liver. If it is very virulent the result is an acute inflammatory exudation of serum and polymorphonuclear leukocytes in and around the bile ducts, associated with more or less extensive necrosis and abscess formation. If the organism is only mildly virulent the ducts may contain chiefly or entirely endothelial leukocytes, while the surrounding tissue is infiltrated with similar leukocytes and occasional lymphocytes.

The fibroblasts show increase in numbers. This type of infection may terminate in sclerosis (cirrhosis) which is characterized by being confined to the periphery of the lobules.

Pancreas.—Infection of the pancreas by the colon bacillus is probably more frequent than generally suspected. Acute cases with hemorrhagic type of exudation and with abscess formation have been reported. The more or less extensive sclerosis of the pancreas occasionally found at autopsy is probably, judging from similar lesions in the kidney and liver, often of infectious origin and due to the colon bacillus.

BACILLUS PERTUSSIS

Micro-organism.—The whooping-cough bacillus, discovered in 1900 by Bordet and Gengou, but not obtained in pure culture until 1906, is a minute, ovoid, Gram-negative cocco-bacillus which

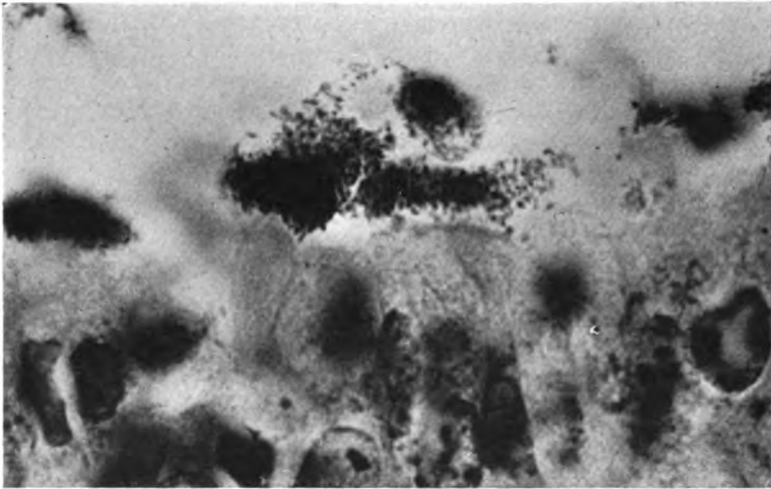

Fig. 111.—Pertussis. *Bacillus pertussis* present in large numbers between the cilia of many of the epithelial cells lining the trachea. M.

stains lightly by ordinary methods. In the disease caused by it the organism occurs in large numbers in a location which is characteristic for it, namely, between the cilia of the epithelial cells lining the trachea and bronchi, and probably also the nares. This last point has not yet been determined for human beings. The bacilli also occur to some extent free and enclosed in polymorphonuclear leukocytes in the secretion in the air passages. The organisms are most abundant during the first two or three weeks

of the disease and then gradually diminish in number, disappearing usually after six to eight weeks or more.

Toxin.—The toxin produced by the bacillus is evidently mild. Its presence is indicated in three ways: (a) by a moderate inflammatory exudate in the walls of the trachea and bronchi; (b) by a lymphocytosis; and (c) by the production of an antibody in the patient's blood, demonstrable by the complement-fixation test.

Injury and Reaction.—The injury produced is apparently largely or entirely mechanical. The action of the cilia is interfered with so that they are unable to remove secretion and inhaled foreign material, as under normal conditions. The bacilli thus act as a continual local irritant, inciting coughing which in typical instances, terminates in the characteristic whoop.

No necrosis of the lining epithelium is produced. The inflammatory reaction is probably largely or entirely due to the mild toxin derived from the organisms. It consists of an emigration of polymorphonuclear and less often of endothelial leukocytes which pass through the epithelium to the free surface. In addition, lymphocytes accumulate to some extent in the tissues around the trachea and bronchi.

As a result of the absorption of toxin the endothelial cells in the lymph-nodules of the lymph-nodes, spleen and gastro-intestinal tract proliferate as in diphtheria, scarlet fever and certain other infectious diseases, but to a much less extent, and incorporate some of the adjacent lymphocytes. The increase in the number of lymphocytes in the circulation and of the endothelial cells in the lymph-nodules indicates, probably, the cells most available in the formation of an anti-toxin to counteract the toxin produced by the bacillus and absorbed into the body.

Bronchopneumonia.—The bronchopneumonia which frequently complicates whooping-cough is probably due to contaminating bacteria. So far no evidence has been found that the bacillus pertussis causes it.

The bacillus bronchisepticus, which causes distemper in dogs, rabbits and other domestic animals, is found in the same location in these animals as the bacillus pertussis is in man, namely, between the cilia of the epithelial cells lining the nares, trachea and bronchi. Histologically in sections the lesions cannot be told apart and the bacilli are practically identical in size, shape, and staining reactions. On this account all experimental work where the bacillus pertussis is inoculated into the ordinary laboratory animals is open to doubt, and must be rigidly controlled bacteriologically, as the two organisms differ in motility and in alkali production in litmus milk.

BACILLUS TUBERCULOSIS

Introduction.—Several strains of the tubercle bacillus exist in nature; only two of them concern us here, the human and the bovine varieties. The human strain of tubercle bacillus is a very common injurious agent affecting man. Usually infection takes place indirectly from man to man. Occasionally the bovine type of the organism, common in cattle, gains access through ingested milk or its products and causes lesions which apparently correspond closely to those produced by the human variety.

The tubercle bacillus causes a great variety of lesions, usually chronic in character, but often acute. The lesions are all included under the general term tuberculosis, but the lesions in certain organs are often prominent and give rise to characteristic clinical symptoms which have long been known under special names and have been regarded and treated as separate diseases; for example, chronic tuberculosis of the lungs has been known as consumption, tuberculosis of the spine as Pott's disease, tuberculosis of the skin as lupus, tuberculosis of the cervical lymph-nodes as scrofula.

Infection takes place usually through the respiratory, less often through the digestive tract, rarely through injuries to the skin. The primary lesions tend to progress; the infecting organism spreads readily through the lymphatic apparatus, the blood-vessels, and various epithelial-lined cavities, ducts, and glands of the body such as the pleural cavities, the bronchi and alveoli of the lungs, the tubules of the kidney, and of the epididymis and testicle.

The lesions produced by the tubercle bacillus appear in a great variety of forms, due less to variations in the character of the inflammatory reaction than to differences in the structure of the organs in which the lesions are situated. In order clearly and fully to understand the reaction of the tissues to the tubercle bacillus it is important to have the organisms stained in the sections studied.

The organs and tissues most commonly infected are the lungs, lymph-nodes, intestine, liver, spleen, meninges of the brain and cord, genito-urinary apparatus, bones and joints, pleural and other mesothelial-lined cavities, skin.

The lesions produced by the tubercle bacillus are not self-limited, but are steadily progressive, although they vary greatly in rate of development. Sometimes they are very acute, at other times exceedingly chronic, persisting a long life time. They may heal in one place and spread in another.

No complete local or general immunity is produced, except under favorable conditions. Therefore, to combat the organism

successfully the best of hygienic surroundings are necessary; fresh air and nourishing food are the chief requirements.

Tuberculosis is rarely inherited, but it is difficult for children to avoid infection if one of the parents has the disease, or if they are exposed to infection through people, local surroundings, air, or food, because the human being is naturally very susceptible to the tubercle bacillus.

Micro-organism.—The tubercle bacillus occurs in widely varying numbers in the lesions which it produces. In some lesions it is almost impossible to demonstrate its presence except by inoculating some of the tissue into a susceptible animal. In other lesions it may be present in great numbers. It is usually contained within

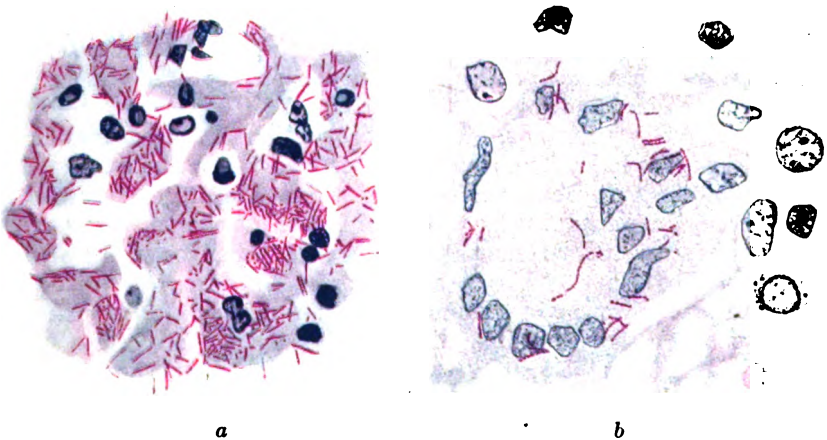


Fig. 112.—Tubercle bacilli. *a*, In inflammatory exudate in alveolus of lung; *b*, in giant-cell.

endothelial leukocytes and giant-cells; less commonly within polymorphonuclear leukocytes. As the result of necrosis and subsequent softening of lesions it is often left free outside of cells. Sometimes in necrotic material, in fibrin thrombi, and within cavities it may grow in solid masses like cultures on media in the test-tube. Apparently it may also grow free in serous fluids and in the urine.

The tubercle bacillus is non-motile. By the rupture of softened tuberculous cavities into blood- and lymph-vessels the organisms, often in large numbers, are carried by the blood and lymph currents to various parts of the body. They seem to spread to some extent within the lesions produced by direct growth from cell to

cell. More commonly, however, they are slowly distributed by the ameboid movements of endothelial leukocytes carrying them into and along blood- and lymph-vessels and epithelial-lined spaces. Occasionally polymorphonuclear leukocytes play the part of distributing agents.

Toxins.—The tubercle bacillus produces mild toxins, partly during the life of the organism, partly by disintegration of its body after death. These toxins cause lesions locally, that is, in their immediate presence; not at a distance by diffusion of the toxins. At least the kidneys never show any effect which could be ascribed to the elimination of a tuberculous toxin through them.

The amount of toxicity apparently varies considerably with different strains of the organism. On the other hand, the reaction of the host is not always the same. It is, therefore, difficult to decide from the morphologic picture alone the degree of toxicity. That is a problem for animal experimentation to decide in the case of each individual strain of organism.

Early Miliary Lesions.—The primary lesion produced around the first tubercle bacillus which gains entrance to a human body has of necessity probably never been seen. We are dependent, therefore, for our knowledge of the origin and development of the minute, early, miliary lesions in man on the changes which are produced by single tubercle bacilli, or small clumps of them, carried chiefly by the blood and lymph streams to different parts of the body. The best material is furnished by early cases of so-called acute miliary tuberculosis. Here an old tuberculous lesion or thrombus softens and discharges large numbers of tubercle bacilli into the circulation. As the discharge once started is often continuous, in appropriate cases all stages in the development of the miliary lesions may be present. Such lesions are best found and studied in the liver, lung, and spleen.

Injury.—It is difficult to demonstrate any direct injury done to the tissue cells by the immediate presence of the tubercle bacillus and its toxins, even when the organisms are present in large numbers, as, for instance, in a capillary of the tuft of a glomerulus. The lesion does not start with necrosis as is usually the case with the staphylococcus pyogenes aureus for example.

Reaction.—Wherever the tubercle bacillus lodges in the human body it ordinarily brings about an accumulation of endothelial leukocytes around it, due to the reparative effort of nature to neutralize the toxins produced by the organism and thus to counteract its injurious effect. Rarely the endothelial leukocyte is replaced in part or largely by the polymorphonuclear leukocyte. This happens only when the tubercle bacilli are very numerous.

The leukocytes incorporate the organisms which continue to multiply readily within the cells.

Tubercle bacilli may lodge in blood- or lymph-vessels or in spaces lined with epithelium. The further reaction to them, other than the accumulation of endothelial, rarely of polymorphonuclear leukocytes around them, depends on their location. When they are located outside of the circulation the other elements occurring in acute inflammatory reactions may be added to the leukocytes already mentioned, namely, serum (from which much fibrin may be formed), lymphocytes, and occasionally eosinophiles. The reaction to the tubercle bacillus when outside the circulation is, therefore, to be classed as exudative in character. The reaction is usually of a mild type.

The earliest tuberculous lesions begin, as a rule, either in the capillary blood-vessels or in the minute lymph-spaces of organs and tissues; but they may begin in large blood-vessels, in lymphatic spaces or sinuses, or in epithelial-lined spaces such as the alveoli of the lung. These early discrete lesions produced by the tubercle bacillus receive different names according to their location.

When the lesions start in the minute blood- or lymph-vessels of an organ or tissue and involve the surrounding parenchymatous cells, they are called miliary tubercles. Their development can best be followed, perhaps, in the liver.

When the organisms are located in sizable blood-vessels the accumulations of endothelial leukocytes within the vessels and around the organisms may be regarded as cell thrombi. Such lesions may best be studied in the terminal veins of the spleen.

If the bacilli obtain access to lymphatic vessels, to loose-meshed tissues like the meninges, or to spaces lined with epithelium, they lead to what is generally recognized as an inflammatory exudation of a type known as tuberculous. The lung furnishes the commonest examples of this latter type of lesion.

The important point to bear in mind is that the reaction to the tubercle bacillus is essentially the same under all conditions. It appears to differ at times only on account of the situation of the organism in the tissues.

The endothelial leukocytes in tuberculous lesions are mainly derived from blood- and lymph-vessels by chemotaxis, but occasionally mitosis of an endothelial leukocyte within a miliary lesion may be observed.

Giant-cells.—Usually but not always some of the endothelial leukocytes of the early tuberculous lesions exhibit a marked tendency to fuse together to form multinucleated or so-called giant-cells. These giant-cells form a striking and characteristic but by no means diagnostic feature of tuberculous lesions. As

a rule, only one giant-cell is formed within a single miliary lesion, but often two or more giant-cells are present. Rarely, all or nearly all of the endothelial leukocytes fuse together to form one large or several to many smaller giant-cells. In lesions starting in lymphatics and in epithelial-lined spaces giant-cells are usually lacking, but they may be formed, as, for instance, in the alveoli of the lung.

When the tubercle bacilli are numerous and the cellular reac-

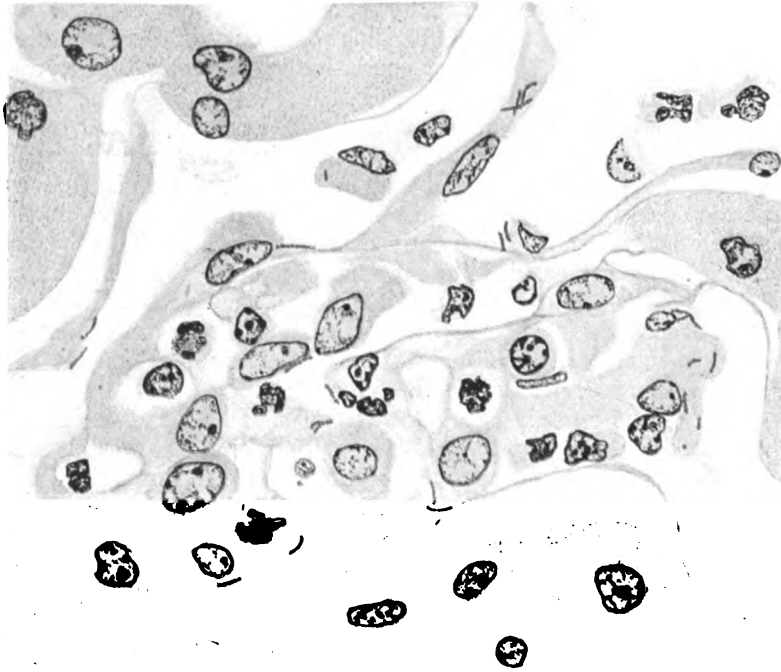


Fig. 113.—Liver. Early miliary tubercle consisting of an accumulation of endothelial leukocytes, some of which contain tubercle bacilli.

tion consists largely of polymorphonuclear leukocytes, giant-cells are usually not formed.

The giant-cells in tuberculous lesions are probably all to be classed as of the nature of foreign body giant-cells. The foreign body may be the fats or other derivatives of dead tubercle bacilli, or the live bacilli themselves. The nuclei of tuberculous giant-cells are usually characteristically arranged at the periphery of the cell; sometimes a more or less bipolar arrangement is evident.

The cytoplasm in the center of the giant-cell is as a rule finely reticular and contains numerous centrosomes.

The giant-cells are generally irregularly spherical in shape. At the periphery of a cell the cytoplasm may be sharply limited, stopping abruptly just beyond the nuclei, or it may send out cytoplasmic processes in one or many directions, probably into the larger lymph-spaces towards sources of nutrition.

The different forms under which the early reaction to the tubercle bacillus appears can be best understood, perhaps, by describing one or more specific examples of each.

Miliary Tubercle; Liver.—Tubercle bacilli brought by the circulating blood to the liver are taken up by the endothelial cells lining the sinusoids. Each one of the endothelial cells containing one or more tubercle bacilli attracts endothelial leukocytes around it. The leukocytes pack and occlude the sinusoids around the cell just infected, and by pressure and by obstructing the circulation soon lead to necrosis of the included liver cells which rapidly disintegrate and disappear.

Some of the endothelial leukocytes usually fuse to form one or more giant-cells which occupy a more or less central position among the remaining leukocytes. When the miliary tubercle reaches a certain size, necrosis of fibroblasts, of the blood-vessel endothelium, and of the endothelial leukocytes, begins in the center of the lesion and spreads peripherally. The giant-cells are also gradually involved in the necrosis.

Necrosis.—The necrosis in a miliary tubercle is due to the endothelial leukocytes accumulating in the blood-vessels and lymph-spaces to such an extent as to occlude the vessels and thereby cut off nutrition. The process is perfectly analogous to what often takes place in typhoid lesions, but is continuous and progressive instead of ceasing abruptly. This is because no immunity occurs as in typhoid fever.

It is claimed by some that the necrosis in tuberculosis is the direct result of toxins derived from the tubercle bacillus. If this were so then the endothelial leukocytes and the giant-cells containing the bacilli ought to be destroyed first in the reaction. This does not occur.

It is noticeable that the nuclei both in the endothelial leukocytes and in the giant-cells tend to arrange themselves in that part of their cytoplasm farthest removed from the advancing necrosis.

Regeneration of Fibroblasts.—If the tuberculous process and the necrosis advance rapidly enough peripherally, no regeneration on the part of the surrounding connective-tissue cells is possible. They are destroyed along with the other cells. Ordinarily, how-

ever, as soon as necrosis takes place and fibroblasts are destroyed along with the other cells, proliferation of the surrounding connective-tissue cells takes place, that, is, fibroblasts regenerate because of injury to fibroblasts, and tend to surround and infiltrate the miliary tubercle to take the place of those destroyed. They extend in between the endothelial leukocytes and invade and gradually organize the necrotic material in the center of the tubercle. Perhaps the stimulating influence of the fibrin in the tubercle plays some part in organization. The tubercle bacilli die out, the endothelial leukocytes disappear, and the site of the tubercle is occupied by a spherical mass of connective tissue. The new collagen fibrils become fused together and often hyaline in appearance. The lesion may be regarded as healed.

Regeneration of Connective Tissue.—The new-formed connective tissue forms a wall of secondary defense around the lesion and is, apparently, often useful in limiting the spread of the tubercle bacilli when they are not destroyed as the result of the inflammatory exudation.

The regenerative activity on the part of the fibroblasts is rarely so active in man as in cattle; in these animals in certain situations, as in the peritoneal cavity, it often leads to such overgrowth of the connective tissue that the tubercles are raised above the surface on papillary stalks.

Apparently no regeneration of blood-vessels occurs; on the other hand, the capillaries around a tubercle are often prominent owing to congestion.

In the liver the miliary tubercles do not tend ordinarily to progress; the same is often true in lymph-nodes and in some of the other organs. The tubercle bacilli are in some way or other prevented from multiplying and spreading.

Lymphocytes.—Cells of the lymphocyte series are attracted around tubercles and sometimes into them in varying numbers. The attractive force seems to come from disintegrating cells rather than from any chemotaxis on the part of the tubercle bacillus. Eosinophiles and mastcells play a very slight rôle.

Miliary Tubercle.—The size of a miliary tubercle represents the extent to which the toxins exert their chemotactic attraction for endothelial leukocytes. Bacilli carried to the periphery of a tubercle by direct growth or by the migratory actions of endothelial leukocytes containing them, become new centers of attraction and thus lead to the formation of other spherical accumulations of endothelial leukocytes. If the centers of attraction start in the periphery of the first tubercle, they necessarily become crescent-shaped accretions on the surface. This is the way in which the small, so-called conglomerate tubercles arise, more

often than from the fusion of several separate and distinct miliary tubercles.

It is customary to apply the term epithelioid cells to the cells composing the miliary tubercles.

The epithelioid cells in a young tubercle are endothelial leukocytes: in a late tubercle where the connective tissue is actively regenerating they are partly or largely fibroblasts. These two types of cells should be recognized and named accordingly, and the indefinite term epithelioid cell should be given up so far as possible.

After necrosis has started in a tubercle other endothelial leukocytes are attracted and invade the necrotic material; they often appear at the edge of the necrosis with their nuclei radially arranged, pointing towards the center.

Sometimes the necrosis in tuberculosis is so slow in formation and the cells destroyed are so quickly removed that the condition is scarcely evident or may be absent. This condition is sometimes found in lymph-nodes.

Thrombi of Endothelial Leukocytes.—In the spleen miliary tubercles similar in appearance to those in the liver and lungs are often formed in great numbers. They involve the small blood-vessels and the intervening splenic tissue. Occasionally, however, lesions of another sort are evident. The tubercle bacilli carried by endothelial leukocytes to the larger terminal veins, attract large numbers of other endothelial leukocytes around them within the vein, so that the lumen may be filled and occluded by them. As the leukocytes remain within the vein and closely compacted together it seems best to regard them as a thrombus formation, analogous to the kind frequently formed by the conglutination of blood platelets. These collections of endothelial leukocytes within veins may be focal or diffuse in character.

Lymphatics.—Tubercle bacilli carried along lymphatics into lymph-nodes may be taken up by the lining endothelial cells, or be carried into the parenchyma and give rise to focal lesions, or they may remain within endothelial leukocytes in the sinuses and lead to large focal, or more often diffuse, collections of other endothelial leukocytes. Associated with the leukocytes are usually considerable serum, much fibrin, and a varying number of lymphocytes. Lesions of this type are frequent in the lymph sinuses of lymph-nodes and in the lymphatics of the intestine.

Tuberculous Inflammation.—Sometimes the tubercle bacilli are spread rapidly and diffusely through the smaller lymph-spaces, probably largely or entirely by the activity of endothelial and polymorphonuclear leukocytes, and give rise to a very diffuse type of tuberculous lesion. The most marked example of this type of lesion occurs, perhaps, in the meninges, where we may get an acute

diffuse inflammatory exudation consisting of serum, fibrin, endothelial and polymorphonuclear leukocytes and lymphocytes in varying proportions. More or less definite miliary tubercles may be combined with this diffuse process. Occasionally in miliary tuberculosis of the liver a diffuse infiltration of the periportal connective tissue with endothelial leukocytes containing tubercle bacilli may occur. A similar acute diffuse process may occur in the hyperemic tissue surrounding an old tuberculous lesion.

In the lung the development of the miliary tubercle is not so readily followed as in the liver. The bacilli are taken up by endothelial cells in the capillaries of the walls of the alveoli and lead to a focal collection of endothelial leukocytes. These leukocytes and, therefore, the whole lesion may remain in the wall between adjoining alveoli and cause great thickening of it; but often in adults and usually in children some of the micro-organisms, as they multiply, reach the alveolar spaces on each side of the wall and cause an exudation within these cavities. The lesion, therefore, takes on partly or largely the character of a miliary tuberculous pneumonia and the reaction is readily recognized as exudative. Serum and fibrin appear in addition to the endothelial leukocytes, and lymphocytes also are usually present.

Tubercle bacilli frequently obtain entrance to other epithelial cavities (including those lined with mesothelium) besides those in the lungs, such as the tubules and pelvis of the kidney, the glands of the prostate, the oviduct, etc. In all these situations it gives rise to an inflammatory exudation similar in character to that already described.

Resemblance of the Lesions to Those Produced by the Typhoid Bacillus.—The lesions of tuberculosis in their early stages may closely resemble those produced in typhoid fever in the same organs, particularly in the mesenteric lymph-nodes, liver and spleen. The cellular reaction consisting chiefly or entirely of an accumulation of endothelial leukocytes is much the same. The tuberculous lesions tend to be more focal in character; they are usually characterized by the presence of giant-cells which are very rare in typhoid-fever; they tend to progress and spread indefinitely and to undergo necrosis, while the typhoid process ceases abruptly after a definite period, and necrosis is not so definitely associated with it. In typhoid fever an antitoxin is as a rule quickly produced and neutralizes the injurious action of the typhoid bacilli. In tuberculosis the same cells at work are unable to counteract the toxins of the tubercle bacilli.

Chronic Tuberculosis.—So far we have discussed the early, beginning lesions produced by the tubercle bacillus in various situations; in capillaries and larger blood-vessels, in lymph-spaces

and vessels, and in epithelial-lined cavities, and have shown that the reaction consists chiefly of an accumulation of endothelial leukocytes around the bacillus. As a rule, a number of these leukocytes fuse together to form one or more giant-cells. Under certain rather rare conditions the polymorphonuclear leukocyte plays the more important rôle. In addition to these leukocytes, serum, fibrin, lymphocytes, and eosinophiles may be added in varying proportions, according to the location of the organisms. It is necessary now to follow the changes which occur when the duration of the injurious action of the tubercle bacillus is not for days and weeks but for months and years; in other words, when the tuberculous process is chronic.

Conglomerate Tubercle.—The typical miliary tubercle is spherical in shape and represents the limit of attraction for leukocytes exerted by a single tubercle bacillus, or by a small group of them. A miliary tubercle does not enlarge perfectly uniformly because the bacilli in it do not extend evenly in all directions towards the periphery in consequence of more favorable conditions of nutrition at one point than at another; more often they are carried out by endothelial leukocytes. Whenever they reach the surface or approach it they become new centers of attraction. In this way crescent-shaped portions of new tubercles are formed on the surface of the old miliary tubercle so that there develops first a small and then a large conglomerate tubercle. The necrosis which started in the center of the miliary tubercle extends peripherally with the enlargement of the conglomerate tubercle.

Solitary Tubercle.—The conglomerate tubercle rarely continues to develop evenly and to retain its more or less spherical shape. The reason for this lack of symmetric growth is to be found chiefly in the anatomic structure of the tissues in which the tubercles develop. In most of the tissues large lymph- and blood-vessels and epithelial-lined spaces exist. These are quickly invaded by the tubercle bacilli and then the pathologic process caused by them usually spreads rapidly and irregularly. In the brain, however, a lesion started by a single tubercle bacillus frequently has the opportunity to reach its full and perfect development. This is owing to the fact that large portions of this organ are uniformly solid and possess only small blood- and lymph-vessels. Lesions starting in these portions frequently develop into the large rounded masses known as solitary tubercles. They consist for the most part of necrotic material surrounded by a narrow zone of tuberculous tissue composed of imperfect miliary tubercles, and are limited by a connective-tissue capsule. This capsule is being constantly invaded by tubercle bacilli conveyed to it from within, probably by the migratory activity of endothelial leukocytes, so that new tubercles

are as constantly developing within it. Rarely the new tubercles start at the outside of the connective-tissue capsule in the adjoining brain tissue. The surrounding blood- and lymph-vessels are so small that the tuberculous process rarely invades and extends along them. But if a solitary tubercle finally reaches a ventricle or the meninges, then a very active and extensive tuberculous process may start up and quickly cause death.

Very rarely favorable conditions allow the development of solitary tubercles in other organs than the brain, as, for example, in the liver.

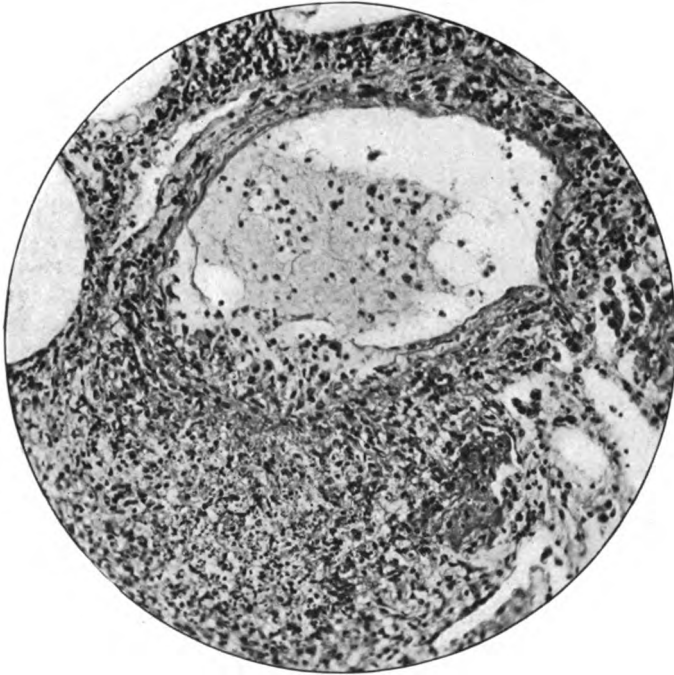


Fig. 114.—Tuberculosis of lung. Process extending into a vein. M.

Thrombus Formation.—A miliary tubercle in the wall of a blood-vessel or a tuberculous lesion on the outside of the vessel, which involves the wall and leads to necrosis, may bring about the formation of a fibrinous thrombus inside of the vessel. In such a thrombus tubercle bacilli sometimes multiply in great numbers. They may attract many polymorphonuclear leukocytes which digest and soften the thrombus. In this way the bacilli may be set free and cause acute miliary tuberculosis. This is a common way for this form of lesion to arise.

Caseation.—Attention has been called to the fact that as the miliary tubercle enlarges the tissue cells, and later the leukocytes in the center of it, undergo necrosis. In the lesions starting in the larger blood- and lymph-vessels and in epithelial-lined cavities the necrosis at first involves only the leukocytes, but the surrounding tissue cells are affected later.

The necrosis in tuberculosis seems to be due chiefly or entirely to the endothelial leukocytes plugging the blood- and lymph-vessels and cutting off nutrition. The necrosis as a rule spreads gradually

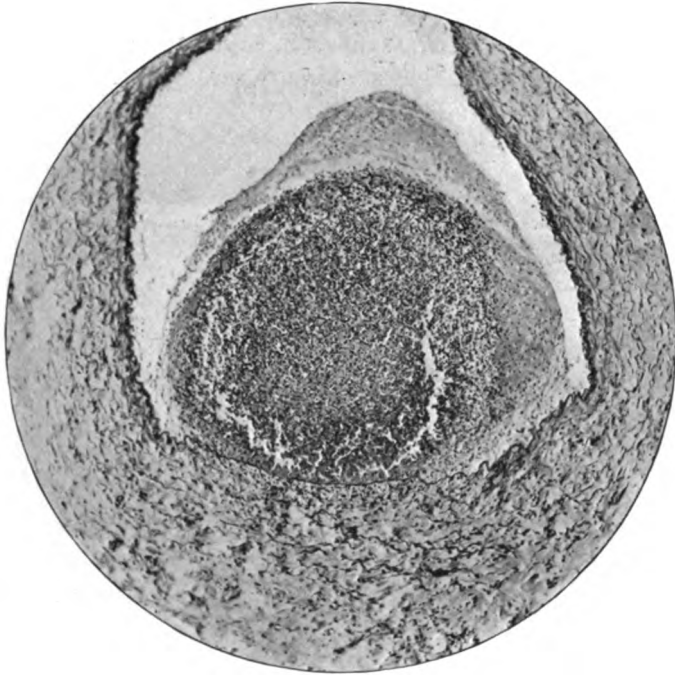

Fig. 115.—Tuberculous thrombus in blood-vessel in lung. M.

and uniformly peripherally. It takes place in tissue so infiltrated with endothelial leukocytes that the parenchymatous cells and other tissue markings (blood-vessels, fat-cells, etc.) have usually disappeared and can rarely be made out in the necrotic areas.

In certain situations, however, some of the tissue markings are often well preserved for a certain length of time, as, for example, in the lung in caseous pneumonia. The walls of the alveoli are usually perfectly evident microscopically for some time after the exudative and the tissue cells have been destroyed. The collagen

and elastic fibrils persist for a long time and can readily be demonstrated by the special staining methods used for them.

There is nothing peculiar in the necrosis of tuberculosis beyond the fact that it consists chiefly or entirely of necrotic endothelial leukocytes, that it usually but not necessarily contains much fibrin, and that ordinarily it does not undergo softening. Usually more or less fat is present because the cells die slowly (necrobiosis) and hence accumulate a certain amount of fat before they become necrotic. The term caseation is applied to it because of the homogeneous, opaque white to yellow appearance which it presents on gross examination, but much the same appearance is presented by the necrotic material in a gumma or in an infarct, or in necrosis of portions of a tumor.

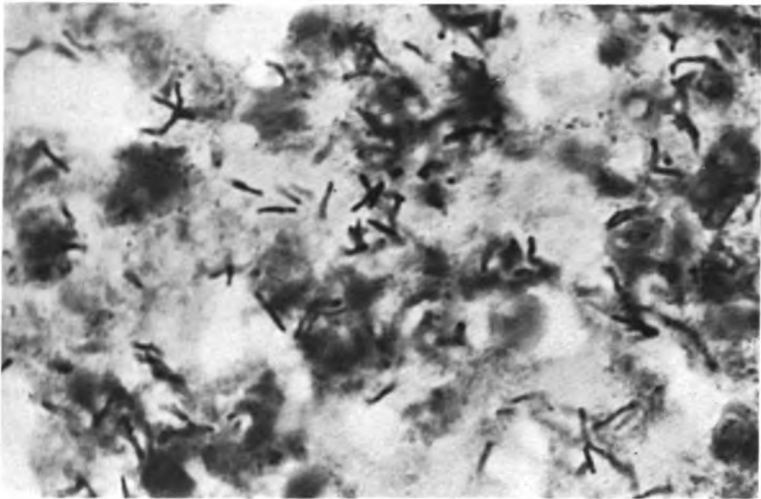


Fig. 116.—Tubercle bacilli in thrombus in blood-vessel in lung. M.

Caseation is most marked in tuberculous lesions of the lymph-nodes and lungs, and in solitary tubercles of the brain.

Caseous material may persist almost indefinitely in the human body, but it tends gradually to undergo one of three changes which will now be considered, namely, calcification, softening including ulceration, and organization.

Calcification.—The necrotic tissue in tuberculous lesions frequently attracts lime salts and leads to their deposit. Probably the fat present in the caseous material as the result of necrobiosis plays an important part in the process.

Calcification is more common in some organs than in others;

thus it is of frequent occurrence in the peribronchial and cervical lymph-nodes, in the lung and in the spleen, but rare elsewhere.

Occasionally the fibroblasts adjoining these deposits of lime salts are stimulated in some way so that they invade them, organize them, and become transformed into true bone cells.

Softening, Abscess.—Under certain conditions and in certain situations the caseous material in tuberculous lesions undergoes softening and abscess formation. Apparently the softening is always due to the attraction of many polymorphonuclear leukocytes into the caseous material which they dissolve through the action of the ferments they secrete. Sometimes at least the leukocytes are attracted by a very active multiplication of the tubercle bacilli. It is from the rupture of such abscesses into blood- and lymph-channels that cases of acute miliary tuberculosis frequently arise.

At other times the caseous material itself attracts leukocytes in sufficient numbers just as occurs in softening of bland parietal thrombi of the heart. This happens most frequently in tuberculosis of the bones, especially of the bodies of the vertebræ (Pott's disease of the spine).

Softening occurs most often in lymph-nodes, in the lungs, and in the genito-urinary apparatus. Apparently in some situations it does not take place, for example, in solitary tubercles of the brain.

Sometimes the softening in tuberculous lesions is due to secondary invasion with the common pyogenic organisms. Naturally such invasion is more likely to occur in the lung and in certain other organs than in lymph-nodes or in the brain. In one instance large sloughs in a tuberculous abscess of the lung were due to the complicating action of the staphylococcus pyogenes aureus; both organisms were present in masses.

Ulceration.—Ulceration of tuberculous lesions is common in all situations when they adjoin a surface or originate there. As the lesion develops and the necrosis extends the protecting covering cells of the surface are destroyed and the necrotic material is thereby exposed to the macerating effect of fluids and, in many instances, to invasion by a variety of organisms. Such ulcerations are most common in the intestine, the urinary bladder, and the trachea and bronchi. When they occur in a blood-vessel, as, for example, in the wall of the aorta, they may result in the formation of a tuberculous aneurysm from which many tubercle bacilli may be discharged into the circulation and thus cause acute generalized miliary tuberculosis.

Regeneration of Fibroblasts.—In chronic tuberculous lesions, regeneration of connective-tissue cells is constantly going on as a result of destruction of fibroblasts. As soon as necrosis begins in a

miliary tubercle the surrounding fibroblasts begin to proliferate, provided the tuberculous process does not extend so rapidly as to destroy them. The new-formed connective-tissue cells grow in between the endothelial leukocytes at the periphery of the tubercle and gradually invade and replace the necrotic tissue. The endothelial leukocytes disappear and the bacilli are apparently destroyed. In many instances, for example in the liver and in lymph-nodes, this process results in complete repair of the lesion which is replaced by dense fibrous, usually hyaline, connective tissue. In chronic lesions a similar process is going on all the time; in some places it is successful; in others it is not. There is another cause, however, in chronic tuberculous lesions which often results in a more active proliferation of fibroblasts and that is fibrin.

Organization of Fibrin.—Much fibrin is usually formed as a result of the inflammatory reaction to the tubercle bacillus when situated outside of blood-vessels. It is often evident even in miliary tubercles where occasionally it may be so abundant as to form a hyaline reticulum similar to that seen in a diphtheritic membrane. It is especially abundant in lesions involving, for example, the pleural and pericardial cavities, the lungs, the meninges, the lymph sinuses of lymph-nodes. Wherever it appears fibrin stimulates organization by blood-vessel endothelium and by fibroblasts, or by fibroblasts alone.

Organization of the fibrin formed in tuberculous lesions differs from that occurring elsewhere only in the peculiarity that wherever a tubercle bacillus is caught and retained in the advancing granulation tissue it becomes the focus of a new tuberculous lesion. This is well known in the case of tuberculous pleuritis and pericarditis, but not so generally recognized in the case of tuberculous pneumonia and some other lesions. Much of the dense fibrous tissue formed in the lungs in tuberculosis is the result of the organization of fibrin.

In consequence of regeneration of connective tissue and of organization of necrotic material and especially of fibrin, much fibrous tissue is in time formed as the result of tuberculous lesions, especially in the lungs.

Perhaps the reason so little connective tissue is formed in connection with tuberculous ulcers of the intestine and of some other locations is that, owing to maceration and sloughing off of the necrotic material and of any fibrin formed, there is little stimulation of the fibroblasts to proliferate.

So far the lesions produced by the tubercle bacillus have been described almost entirely from the general point of view. Fully to appreciate them, however, it is necessary to describe the lesions briefly as they affect the more important organs and tissues of the body.

Two or three preliminary statements are perhaps necessary.

Acute Miliary Tuberculosis.—Acute generalized miliary tuberculosis is due to the sudden or continuous discharge of many tubercle bacilli into the circulation. It usually happens from one of the following causes:

1. Softening and rupture of a tuberculous thrombus in a blood-vessel;
2. Softening of a tuberculous lesion with rupture into a blood-vessel;
3. Tuberculous ulcer or aneurysm of the aorta or other blood-vessel;
4. Tuberculosis of the thoracic duct.

If there is a single active focus of tuberculosis anywhere in the body, bacilli are likely to be carried occasionally from it into the circulation by endothelial leukocytes and they may then give rise to miliary tubercles elsewhere in the body. The bacilli are most apt to lodge in the liver or spleen.

A single bacillus carried to the meninges, to the peritoneal or other mesothelial cavity, or to a lymph-node may result in miliary tuberculosis in those situations owing to rapid multiplication and distribution of the organisms.

Chronic Tuberculosis.—The character and extent of the chronic lesions produced by the tubercle bacillus depend largely on the location of the primary lesions. They are simplest when the tissue surrounding them is compact and lacking in large blood- and lymph-vessels and in cavities lined with epithelium; they are most complex when all these anatomic structures are present. For this reason the solitary tubercle of the brain represents the simplest type of chronic lesion, tuberculosis of the lungs perhaps the most complex type.

A single tuberculous lung may show miliary tubercles arising from bacilli distributed through blood- and lymph-vessels; miliary tuberculous pneumonia; extensive caseous pneumonia; softening and cavity-formation; calcification; regeneration of connective tissue; organization of fibrinous exudate with reinfection with the tubercle bacillus; tuberculous-thrombus formation in one or more blood-vessels; ulceration of bronchi.

Liver.—Infection occurs almost invariably through the blood, usually through the hepatic artery, less often through the portal vein. Infection by direct extension or through lymphatics is very rare.

The following types of lesion are recognized.

1. *Acute Miliary Tuberculosis.*—The lesions may be located in any part of the lobule, but are commonest in the neighborhood of the portal vessels.

An occasional miliary tubercle is likely to be found in the liver if any active tuberculous lesion exists in the body. The liver acts as a filter and catches and retains them. Miliary tubercles of the liver tend to remain quiescent after reaching a certain size. They become encapsulated and heal. The development of the miliary tubercle in the liver has already been described. Giant-cells are usually prominent, but sometimes rare or absent.

2. *Bile Duct Tuberculosis*.—Rarely the tubercle bacillus invades the periportal connective tissue and produces a diffuse inflammatory reaction, consisting chiefly of endothelial leukocytes. Giant-cells are sometimes formed. This diffuse process may become chronic, undergo caseation, involve the bile ducts, and lead to escape of bile which colors the caseous material.

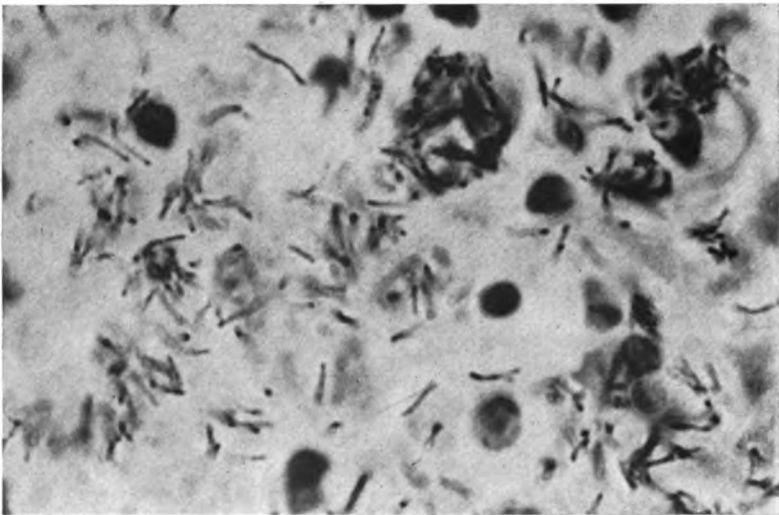


Fig. 117.—Tubercle bacilli in miliary tubercle of spleen. M.

3. *Solitary Tubercle*.—This lesion is uncommon but has been described. It must be carefully differentiated from gumma by demonstrating the presence of the tubercle bacillus in the lesion.

Spleen.—Infection occurs through the blood.

1. *Acute Miliary Tuberculosis*.—It is a common lesion and occurs whenever there is generalized miliary tuberculosis.

2. *Miliary Thrombi of Endothelial Leukocytes*.—Occasionally the terminal veins are distended by endothelial leukocytes attracted by the tubercle bacilli. This lesion closely resembles that which occurs in the spleen in typhoid fever. It has already been described.

3. *Conglomerate Tubercles*.—They are usually small, and often

calcified, but on occasion the spleen is much enlarged and shot through with conglomerate tubercles of all sizes.

Lymph-node.—The lymph-nodes most commonly infected are the cervical, peribronchial, and mesenteric.

Infection usually takes place through the lymphatics, rarely through the blood. The tubercle bacilli may be distributed quite rapidly and evenly throughout the node by the ameboid action of the endothelial leukocytes carrying them, in the same way that carbon is carried to the node and distributed. The organisms transported into the pulp give rise to miliary tubercles; those which remain in the sinuses cause an accumulation of endothelial leukocytes which fill and distend the vessels for a certain distance. In addition to the leukocytes, lymphocytes, serum and fibrin in varying proportions are usually present. A lesion in the pulp may extend to a sinus and infect it, or the reverse may occur. Both types of lesions are commonly found if the tuberculous process is not too far advanced. At a later stage the two types are generally more or less combined and fused. An early extensive tuberculous lesion in the lymph sinuses may closely resemble that occurring in typhoid infection.

The miliary lesions gradually spread, and if multiple, fuse, so that in time the entire node may be transformed into a caseous mass with all its landmarks destroyed. It is limited peripherally by a fibrous capsule, just inside of which endothelial leukocytes and giant-cells are commonly present to some extent and indicate the nature of the pathologic process.

Softening and calcification are two processes which caseous lymph-nodes not infrequently undergo.

These acute and chronic lesions are those ordinarily found. Two other types, however, occasionally occur.

Sometimes the reaction in a lymph-node is very slow. The cells and leukocytes are dissolved and removed as fast as they undergo necrosis, so that no caseation is evident and no giant-cells are formed. The fibroblasts regenerate more or less actively. As a result the entire node is replaced by focal areas of endothelial leukocytes and fibroblasts which suggest miliary tubercles somewhat by their arrangement. The organisms are so few that it usually requires animal inoculation to demonstrate the nature of the lesion.

Still more rarely each miliary tubercle as formed is rapidly replaced by active regeneration of fibroblasts, so that it is transformed into a miliary mass of fibrous tissue which in time often becomes hyaline in appearance.

Lungs.—Infection may occur through the blood, the respiratory tract, and possibly the lymphatics.

It is simplest to divide the lesions first into two groups, acute and chronic.

1. *Acute Miliary Tuberculosis*.—The tubercle bacilli reach the lung through the blood-vessels. Miliary tubercles may develop in the walls of the alveoli and remain confined to them. Frequently, however, in adults and always in children, the bacilli reach the alveoli on each side of the alveolar wall and produce what anatomically is a miliary tuberculous pneumonia. This has already been described under the miliary lesions.

2. *Chronic Tuberculosis*.—The first lesion may arise from a bacillus brought by the blood or through the air passages; perhaps occasionally through the lymphatic system. As the lesion enlarges and spreads it is almost sure to involve all three of these tracts and to extend along all of them. It is likely to extend quickest and most extensively through the alveoli and bronchi setting up numerous other foci of infection; the lymphatics are more often involved than the blood-vessels.

The gross pictures presented by chronic tuberculosis of the lungs vary greatly. They are built up out of the following elementary lesions and processes which have already been to some extent described.

1. *Miliary Tubercles*.—They are constantly developing wherever bacilli are carried from the existing lesions. The miliary lesions in chronic tuberculosis arise chiefly from bacilli carried along the lymphatics, but also from organisms distributed through the alveoli and bronchi and carried into the walls by endothelial leukocytes. Possibly a few bacilli are carried through the blood-vessels.

From the miliary tubercles develop conglomerate tubercles which may reach a considerable size.

Necrosis regularly occurs when the tubercles reach a certain size. Calcification of the necrotic material sometimes takes place.

2. *Tuberculous Pneumonia*.—The lesions may be miliary in size or very extensive. The miliary lesions are due to single bacilli distributed here and there, chiefly through the air cavities. The extensive areas are usually due to numerous bacilli being discharged into a bronchus from an old tuberculous cavity in the lung.

Many miliary and conglomerate tubercles are surrounded by a tuberculous exudate in the alveoli.

When the bacilli are few and the fibrin in the exudate abundant in tuberculous pneumonia organization frequently takes place. More often, however, the exudate and the alveolar walls gradually undergo necrosis. It is to this picture, when at all extensive, that the term caseous pneumonia is applied.

Sometimes the process is limited almost entirely to the bronchi which become occluded by caseous material.

Many apparently miliary and conglomerate tubercles are really a combination of tuberculous pneumonia, organization of fibrin, and tubercle formation.

3. *Softening; Abscess Formation; Cavity Formation.*—Softening of tuberculous lesions is fairly common in the lung. Sometimes it is due to invasion of the necrotic material by pus producing organisms, but this does not appear to be the rule. The softened area or abscess may discharge into a bronchus and give rise to extensive caseous pneumonia, or into a blood-vessel and cause acute generalized miliary tuberculosis.

In other instances the discharged material is mostly coughed up. Large blood-vessels and bronchi often persist as trabeculæ in the cavities thus formed. If a blood-vessel is eroded, more or less extensive and even fatal hemorrhage may occur.

4. *Regeneration of connective tissue* is usually in evidence around miliary and conglomerate tubercles and may become quite abundant, especially when these lesions cease to progress and the necrotic material becomes organized. Much of the connective tissue, however, perhaps the greater part of it, is due to organization of the fibrin produced as a result of the inflammatory exudate into the air-sacs. From both these causes, extensive fibrosis is sometimes produced in very chronic tuberculosis of the lungs, and by contracting leads to shrinkage of the lung and to deformity of the chest.

5. *Tuberculous lymphangitis* in the peribronchial lymphatics is not uncommon. The exudate gradually undergoes caseation in the same manner as the exudate in the air-sacs.

6. *Fibrin thrombi* occasionally form in the pulmonary vessels and may partially to completely occlude them. They usually form when a tuberculous lesion adjoins and invades a vessel. Tubercle bacilli sometimes grow luxuriantly in these thrombi and subsequent softening and rupture of the mass may discharge great numbers of tubercle bacilli into the circulation and give rise to acute generalized miliary tuberculosis.

7. *Tuberculous ulcerations* of the bronchi sometimes occur and may be fairly extensive.

8. *Secondary infections* especially with the streptococcus pyogenes and the staphylococcus pyogenes aureus are not infrequent; they necessarily complicate and may even obscure the tuberculous process.

BACILLUS LEPRÆ

Introduction.—The leprosy bacillus causes a variety of lesions which since ancient times have all been grouped together under

the general term leprosy. The lesions develop slowly and tend to persist indefinitely. They may affect any part of the body, but occur most commonly in the skin of the face and extremities and in the nasal mucous membrane. They are disfiguring in character and often produce marked deformity. Largely on this account, because the lesions affect the most conspicuous parts of the body, infection with the leprosy bacillus is universally feared and dreaded; yet long experience has demonstrated that the disease is very slightly contagious.

The lesions of leprosy tend to progress steadily like those of tuberculosis. There never occurs any general immunity as in typhoid fever or any local immunity as in syphilis.

Clinically two types of the disease are recognized, the nodular and the anæsthetic. This is an artificial distinction depending on whether the nerves are involved or not. The two types often co-exist.

Micro-organism.—The leprosy bacillus with its characteristic morphology and staining reaction, in both of which it closely resembles the tubercle bacillus, is usually easily demonstrable in the lesions produced by it. It may be overlooked, however, owing to the readiness with which the stain is extracted from the organisms in dehydrating and clearing the sections. The lesion itself is fortunately, as a rule, fairly characteristic.

From the pathologic point of view the leprosy bacillus is a very innocuous parasite which grows fairly slowly and must be present in large numbers in order to produce any noticeable reaction and macroscopic lesion. The micro-organisms do not occur free in the tissues, but are almost invariably contained within cells, chiefly within endothelial leukocytes, much less commonly within epithelial cells, and only occasionally inside of polymorphonuclear leukocytes. They are present in these cells, especially in the endothelial leukocytes, usually in large numbers, from dozens to hundreds. This is particularly true of the leukocytes in the more acute lesions. But in old lesions when the endothelial leukocytes are often large and vacuolated, the bacilli may be few in number, lying in the cytoplasm between the vacuoles.

In the more acute lesions the bacilli may be diffusely scattered in the cytoplasm of the endothelial leukocytes, but more often they are grouped in clumps in solid rounded and elongated masses of which one to several or many may occur in a single leukocyte.

Toxin.—The toxins produced by the leprosy bacillus are exceedingly mild. Possibly they consist only of the fat produced within the body of the organism. This fat may be readily demonstrated by staining with Scharlach R, or with osmic acid. After the latter stain the separate bacilli can be readily seen under the

oil immersion. No matter how many bacilli are present in a cell, and they often number hundreds, they never cause necrosis of that cell. Death of the cells results only secondarily from obliteration of blood-vessels and consequent cutting off of nutrition.

No secondary lesions are produced in the kidneys or in any other organs by elimination of any toxin derived from the organisms.

Injury.—No direct injury to the tissues due to a toxin derived from the leprosy bacillus is demonstrable. The injury occasioned is secondary in origin, due to the inflammatory exudation.

Reaction.—The reaction to the leprosy bacillus is of the mildest type; it consists only of an accumulation of endothelial leukocytes

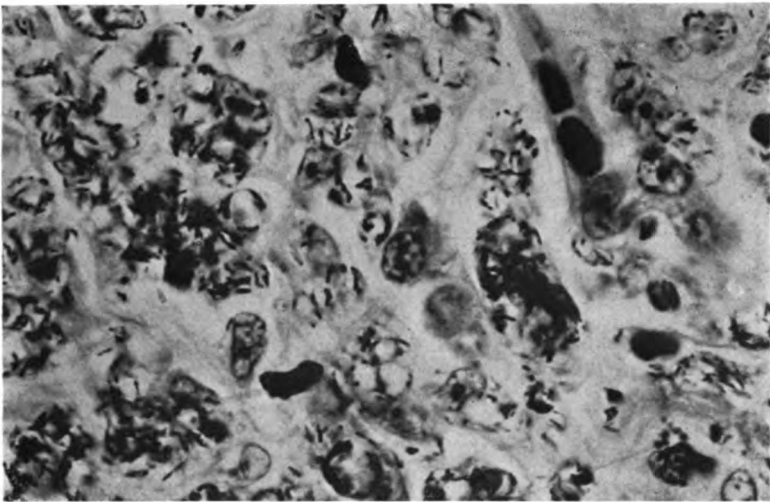


Fig. 118.—Leprosy nodule of skin. Bacilli within endothelial leukocytes. M.

without other evidence of inflammatory exudation. The leukocytes collect together practically only so fast as they are needed to contain the leprosy bacilli. Apparently there is little or no need of them to counteract any diffusible toxin as in the lesions of typhoid fever and of tuberculosis.

The endothelial leukocytes containing bacilli gradually infiltrate the normal tissues in great numbers and distend them. In this way they lead to nodule formation. The leukocytes are derived partly by emigration from the vessels, partly by mitosis of the newly emigrated leukocytes. In recent lesions mitotic figures are not infrequent, but apparently they never occur in leukocytes containing bacilli.

From any focus of infection endothelial leukocytes containing

leprosy bacilli gradually spread and infiltrate the surrounding tissues, such as fat and muscle-tissues, nerves, and walls of blood-vessels. They cause atrophy of the more highly differentiated cells as a result of the pressure exerted, and a moderate amount of proliferative activity on the part of fibroblasts. As a result

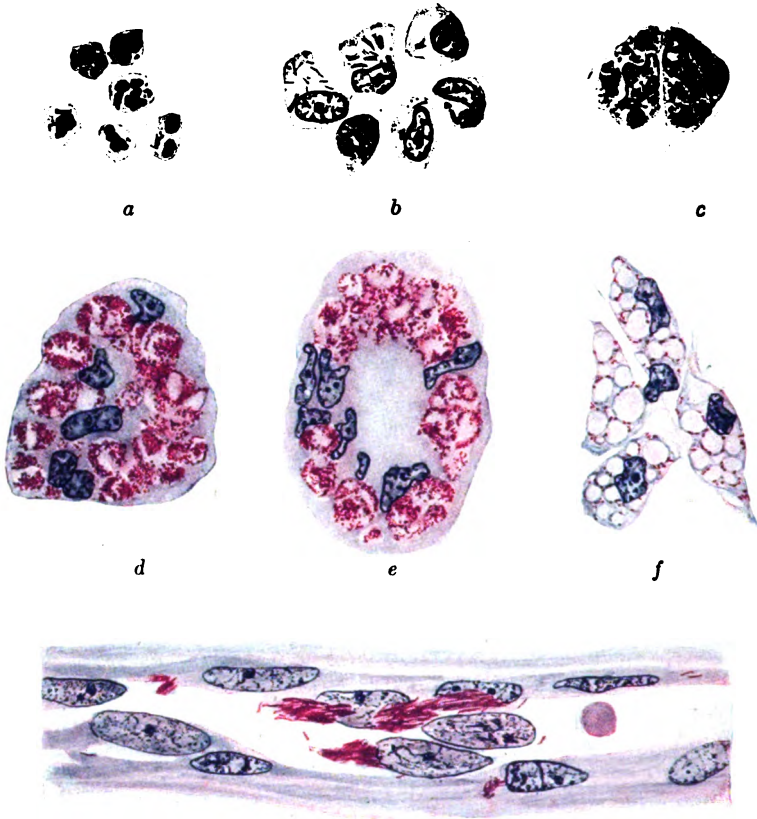


Fig. 119.—Leprosy bacilli. *a*, In polymorphonuclear leukocytes; *b* and *c*, in endothelial leukocytes; *d* and *e*, in giant-cells formed from endothelial leukocytes; *f*, in endothelial leukocytes containing vacuoles; *g*, in endothelial cells lining a capillary.

smooth and striated muscle-cells, fat-cells, and nerve-fibers disappear, and connective tissue increases moderately in amount. The whole process is so slow that visible necrosis of cells as a result of the infiltration with the endothelial leukocytes, such as commonly occurs in tuberculosis, is not evident. On the other hand,

the infiltration of the walls of blood-vessels, especially of arteries, leads to their thickening, often to a marked degree, and to the occlusion of the lumen, so that in this manner necrosis of tissue may occur. In this way retrogressive changes in the nodular lesions arise, and probably the gradual destruction and loss of the smaller extremities.

The endothelial leukocyte undergoes considerable change as the result of the multiplication of leprosy bacilli within its cytoplasm. It gradually enlarges, sometimes to a very great size. Occasionally the leukocytes contain two or more nuclei and rarely they form giant-cells similar to those in tuberculosis. The bacilli usually occur in the cytoplasm in masses probably as the product of centers of proliferation. As the cells get older many of the bacilli die and they and their fat products are gradually digested and removed. As a result the leukocytes in time become vacuolated and many contain several small or one or more large vacuoles. Within these vacuoles fat derived from the organisms may be present.

The leprosy bacilli may in time become very few in number and lie scattered in the cytoplasm between the vacuoles. These large vacuolated endothelial leukocytes are especially characteristic of leprosy. When they are present in fat-tissue they sometimes closely resemble young developing fat-cells. In the liver and spleen and in lymph-nodes these vacuolated cells form a very characteristic picture.

The leprosy bacillus does not lead to the emigration of the polymorphonuclear leukocytes. On the other hand, if necrosis occurs from occlusion of blood-vessels, or if through mechanical injury or secondary infection, polymorphonuclear leukocytes are attracted into tissue containing leprosy bacilli, the latter may be taken up to some extent by these leukocytes, but such inclusion is not of frequent occurrence.

Leprosy bacilli not infrequently infect the endothelial cells lining blood-vessels, especially those in the larger capillaries and in arteries. They may occur in masses in separate cells here and there, but more usually all the cells over a given stretch are affected. This infection of the endothelial cells lining blood-

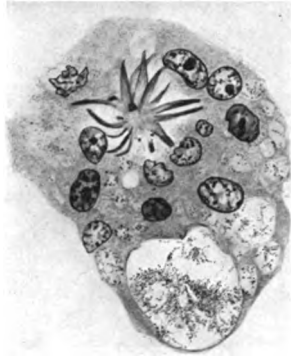

Fig. 120.—Leprosy. Giant-cell containing a spiculated body and also numerous leprosy bacilli.

vessels leads to no proliferative or exudative reaction. On the other hand it is, of course, a common source of infection of the wall of the blood-vessel and of the surrounding tissues.

Leprosy bacilli also infect epithelial cells. They are found most often in the epithelium lining the coil glands which are of necessity so often involved in the leprosy lesions of the skin. The

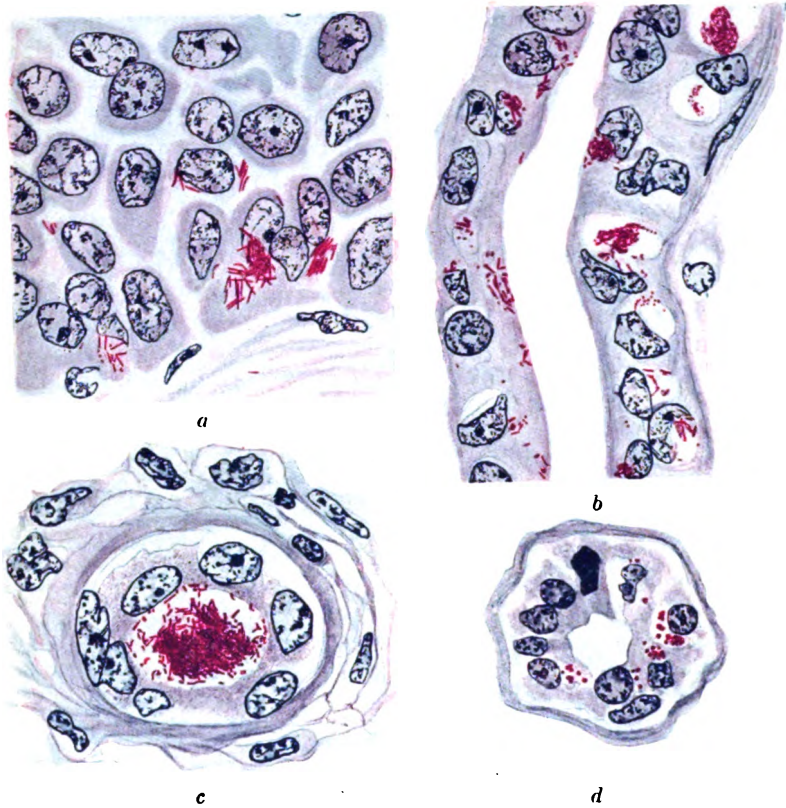


Fig. 121.—Leprosy bacilli. *a*, In epithelial cells of epidermis; *b*, in epithelial cells lining coil gland; *c*, in lumen of coil gland; *d*, fat-droplets in epithelial cells of coil gland.

bacilli occur in small clumps, and do not lead to marked enlargement of the cells as in the case of the endothelial leukocytes. The bacilli are easily distinguished from the larger, round masses of hyaline, perhaps fatty, material which occurs in the epithelial cells of the coil glands and stains differentially, like the tubercle bacillus. The leprosy bacilli may be found not only in the deeper portions of the coil gland, but also in the part running through the

epidermis and even in the cornified layer on the outer surface. Occasionally the bacilli lie free within the lumen of a coil gland and may be present there in such large numbers as to dilate it considerably. A patient thus affected is capable of "sweating" leprosy bacilli.

The leprosy bacillus is sometimes present in considerable numbers in the epithelial cells of the epidermis. This occurs most commonly by extension of the infection from the epithelial cells in the coil glands at the points where they pass through the epidermis. Sometimes all the epithelial cells over a given area will be filled with the bacilli which give rise to no reaction of any sort around them.

Very rarely the epidermis of a hair follicle is invaded by the leprosy bacillus which, by growth and extension of the hair shaft, may reach the surface of the body in the same way that it does through the coil glands.

The leprosy bacillus probably spreads from one cell to another by direct extension, growing out of one cell and into another or being incorporated by the latter. This view is especially favored by the location and spread of the organism in contiguous epithelial and endothelial cells. The same method of extension probably holds good for the endothelial leukocytes. Certainly, there is no evidence in the ordinary uncomplicated lesions that the organisms are set free by necrosis of cells containing them so that other cells can take them up.

Cells of the lymphocyte series frequently infiltrate and surround the more acute leprosy lesions. They are probably attracted, not by any toxin from the leprosy bacilli, but by products set free by the atrophy and disintegration of the more highly differentiated tissue-cells.

ACTINOMYCES

The actinomyces produces progressive lesions of a chronic type, which are all included under the term actinomycosis. Infection with the organism is common in cattle in whom the disease is known as lump jaw; it is comparatively rare in man. Infection occurs most frequently by way of the gastro-intestinal tract, particularly in the mouth where the opportunities for invasion are greatest, but it sometimes starts in the lungs, or in the skin. In the mouth, and especially about the lower jaw, the lesions begin as hard nodules which soften and rupture so that discharging sinuses are formed. In the lung the actinomyces produces lobular pneumonia and abscesses from which cavities may arise. Here the process may strongly suggest tuberculosis. The lesions of the lungs show a marked tendency to involve adjoining structures by

direct extension, for example, the liver and particularly the ribs and vertebræ.

The organism occasionally obtains entrance to the circulation and produces multiple abscesses in various parts of the body, such as the skin, muscles, kidneys and brain.

Infection occurs, not by transference from an infected case, but through the agency of grain and hay on which the organism seems to occur normally.

Histologically the actinomyces usually forms a conspicuous and characteristic feature in the lesions which it produces, and has perhaps naturally attracted more attention than the inflammatory reaction caused by it.

Micro-organism.—The actinomyces appears in the lesions to which it gives rise as branching filaments, as bacilli, sometimes in still shorter forms resembling cocci. Still more characteristically,

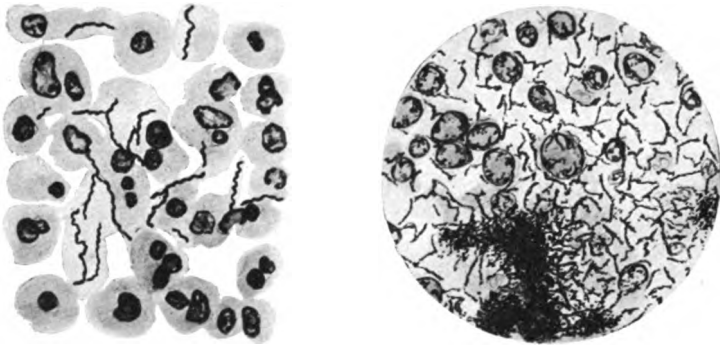


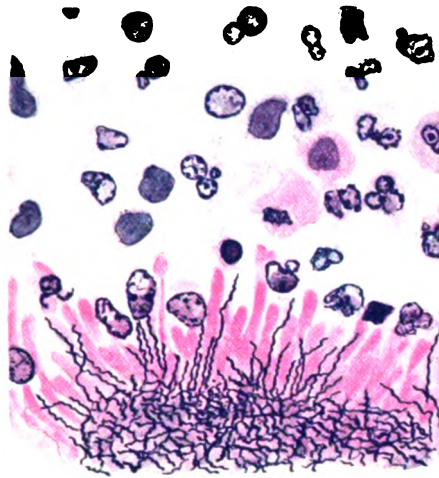
Fig. 122.—Actinomycetes growing diffusely in exudation.

it often appears in the form of small and large colonies frequently surrounded by a striated hyaline zone, the separate elements of which are spoken of as clubs. In human beings the resistance to the growth of the micro-organism is active but not very effective; the parasite, therefore, multiplies rapidly and numerous filaments occurring singly, in loose tangles, and in colonies, are often abundant. The hyaline clubs are usually rare and often entirely wanting. They probably represent a protective secretion of the marginal filaments.

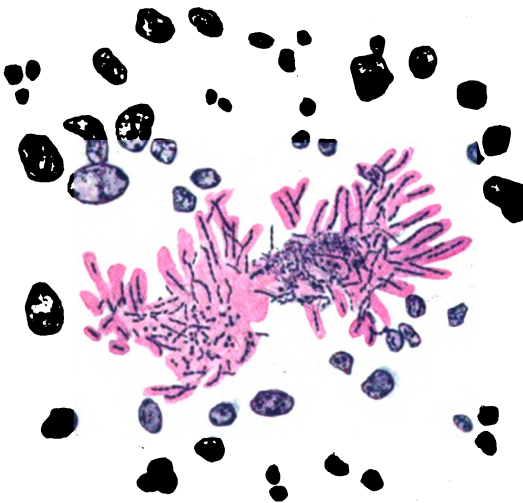
The colonies are readily visible to the naked eye as grayish or grayish-white granules.

In cattle the growth of the organism is usually less active and more chronic, and the actinomycetes appear for the most part as colonies surrounded by a well developed layer of clubs.

The organisms extend from the original focus partly by direct



a



b

Fig. 123.—Actinomycosis. *a*, Edge of colony showing filaments and clubs. *b*, small colony showing filaments within clubs.

growth, partly by being transferred by leukocytes which have incorporated them. Sometimes a lesion extends into a blood-vessel; in this way the organisms may be distributed all over the body.

The actinomyces colonies measure up to one and even two millimeters in diameter. The fully developed ones usually form somewhat flattened ovoid masses with an opening on one side communicating with the interior. They show up well even in sections stained with hematoxylin and eosin, but are made to stand out most strikingly by a deep eosin stain followed by the Gram-Weigert methyl-violet method.

Toxin, Injury and Reaction.—The organism produces a toxin of considerable strength so that more or less extensive necrosis is

always produced. The exudate consists chiefly of serum and polymorphonuclear leukocytes. When the growth of the organism is less active endothelial leukocytes may be more or less numerous. Rarely foreign body giant-cells are formed. The abscesses resemble those caused by the staphylococcus aureus and other pus organisms, but are not so rapidly formed.

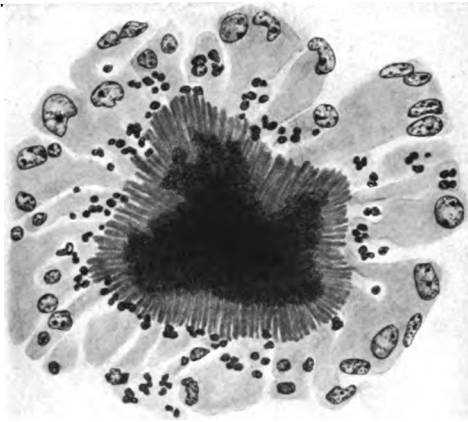


Fig. 124.—Actinomycosis bovis. Colony with clubs surrounded by polymorphonuclear and endothelial leukocytes.

Repair.—The reparative activity around the lesions of

actinomycosis, particularly when they are at all chronic, is usually strikingly characteristic. The separate colonies or groups of colonies are surrounded by granulation tissue and outside of this there is often much fibrous tissue.

It is not easy to determine just how the organisms spread from such encapsulated lesions, but it is probably in two ways; by direct invasion of the capsule in places so that necrosis and softening are produced and further extension rendered possible, and possibly by organisms being carried to other parts by endothelial leukocytes in which they are often found.

In cattle, in which the growth of the organism is usually much less active, the lesion is characterized by the production of masses

of fibrous tissue in which are minute softened areas containing the colonies of the organism, surrounded by a broad zone of clubs. The inflammatory reaction is composed of a few polymorpho-nuclear and often also of endothelial leukocytes. Sometimes it consists of the latter leukocytes alone. Occasionally single clubs or small clumps of clubs can be found within endothelial leukocytes.

Diagnosis.—The gross lesion produced by the actinomyces is often more or less characteristic, but the diagnosis is made by finding the colonies in the pus from the abscesses or sinuses. They should be sought and identified microscopically both fresh on a slide with a cover-slip dropped gently on the material, and also in fixed preparations stained by Gram's method.

Special Pathology.—In the gastro-intestinal tract, but particularly in the mouth and intestine, the lesions appear for the most part as chronic suppurating sinuses lined with granulation tissue and with much fibrous tissue outside of them. The lesions exhibit a strong tendency to spread.

In the lungs the organisms are readily distributed through the bronchi. They produce lobular pneumonia and also abscesses from which cavities arise. Frequently much fibrin is formed in the exudation and may undergo organization, so that considerable fibrous tissue may arise in this way.

In the liver the infection may spread rapidly causing extensive necrosis and a diffuse suppurative process, or slowly so that much fibrous tissue is formed in which are numerous large and small pockets of pus.

Infection of bone causes a chronic inflammatory process. The cells of the connective tissue produced from the osteal cells as a result of repair tend to differentiate into bone cells; as a result the lesions tend to exhibit the production of much bone.

In the other organs, kidneys, brain, muscle, etc., the lesions usually take the form of abscesses of comparatively slow formation, so-called cold abscesses.

TREPONEMA PALLIDUM

Introduction.—The treponema pallidum is the cause of various lesions which are all included under the term syphilis. Infection with it may be acquired or congenital.

In acquired syphilis infection takes place almost invariably on a cutaneous or mucous surface and leads to the formation of a primary lesion. Later, the micro-organism, like many other infectious agents, gives rise to a septicemia and causes multiple usually slight lesions which are most evident in the skin and visible mucous membranes. These lesions may soon disappear, or persist for a long time, or develop into larger lesions. Still other

lesions may develop anywhere in the body in the succeeding months and years.

Syphilis is peculiar in several ways. The lesions develop very slowly. Under natural conditions a septicemia apparently always follows the primary lesion. The lesions, unlike those due to the tubercle bacillus and many other infectious agents, do not tend to spread indefinitely. After a variable length of time they retrogress and undergo repair, although new lesions may start up in other locations. Evidently both local and general acquired immunity plays an active part in limiting the growth of the organisms and the development of the lesions.

For the sake of convenience three stages in the development of the lesions in acquired syphilis have long been recognized clinically. The first includes the development of the primary lesion; the second the lesions immediately following the septicemia; the third all the later lesions due to the immediate presence of the *treponema pallidum*, whether they develop out of the secondary lesions or arise independently after them.

It is difficult to determine how soon the septicemia takes place. We know, however, that the *treponema* spreads very early from the site of primary infection through the lymph-vessels to the adjoining lymph-nodes. Moreover experiments have shown that excision of infected skin a few hours after inoculation will not prevent the development of the disease. Judging from the length of time elapsing between the infection and the first appearance of the primary lesion, a general septicemia exists at least three to four weeks before the secondary lesions appear.

Acquired Syphilis.—*Primary Stage.*—The early course of the infection in acquired syphilis is much alike in all cases. There is a primary lesion which is often multiple and which, in about ninety to ninety-two per cent of the cases, starts on the genitals, in the other eight to ten per cent on the tonsils, lips, tongue, skin, etc. The primary lesion, known clinically also as chancre or hard chancre, develops slowly at the site of infection. It starts as a papule which becomes evident at about the twenty-first to twenty-eighth day after the date of infection, and which quickly or from the beginning exhibits erosion of its surface. The underlying tissue becomes thickened and indurated. At the same time the regional lymph-nodes enlarge considerably and become distinctly harder.

The first stage of syphilitic infection usually lasts until about six weeks after the time the primary lesion first appeared.

Secondary Stage.—This begins with the development of the multiple cutaneous lesions as the result of the general systemic infection with the *treponema pallidum*. It usually occurs at about

the forty-second day after the first appearance of the primary lesion, but often later. Various lesions generally but not always manifest themselves; a variety of cutaneous lesions called syphilides (macular, papular, pustular, squamous); mucous patches, condylomas, iritis. Lesions of a similar inflammatory nature probably occur in the internal organs and tissues, but are not within reach of observation.

The duration of the second stage is variable, from weeks to months.

Tertiary Stage.—All the later manifestations of infection with the *treponema pallidum* are included in the tertiary stage which has no limit of time but lasts till the patient dies. They may

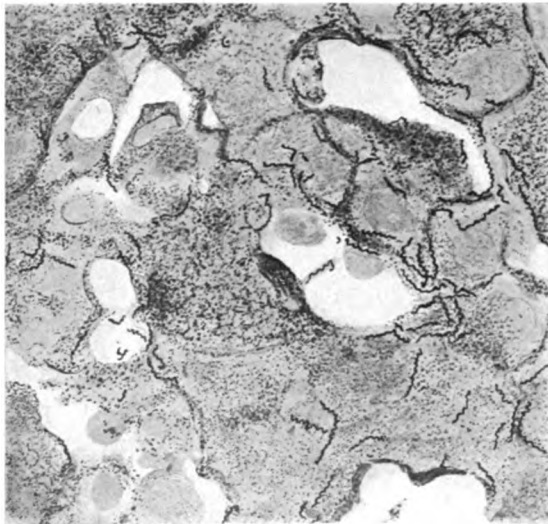


Fig. 125.—Syphilis, congenital. Liver. *Treponemata pallida* between the liver cells and around the sinusoids.

occur in the skin as the so-called later syphilides and in the various organs and tissues (liver, testicles, muscle, brain and meninges, bones) as diffuse and focal inflammatory processes. Infection of the blood-vessels, chiefly the arteries, causes thickening of their walls and frequently leads to partial or complete occlusion of the lumen. When more or less extensive necrosis is present, chiefly or entirely as the result of obliteration of blood-vessels, the lesion is called a gumma.

Syphilis is very commonly complicated by amyloid formation in various organs.

Congenital Syphilis.—In congenital syphilis infection occurs

in utero. No primary external lesion is formed. The disease may be said to start at the secondary stage. All the various lesions which develop in acquired syphilis may be duplicated in congenital syphilis with the exception of the primary sore or chancre. As a rule, however, the lesions are of a milder type and more extensively distributed. The inflammatory reaction is usually slight and gummas are of rare occurrence. On the other hand, abundant production of connective tissue as the result of regenerative proliferation of fibroblasts is a usual and prominent feature in various organs, but especially so in the liver. Occasionally the reaction is more or less intense and all the secondary and tertiary lesions of acquired syphilis may be present in the congenital form.

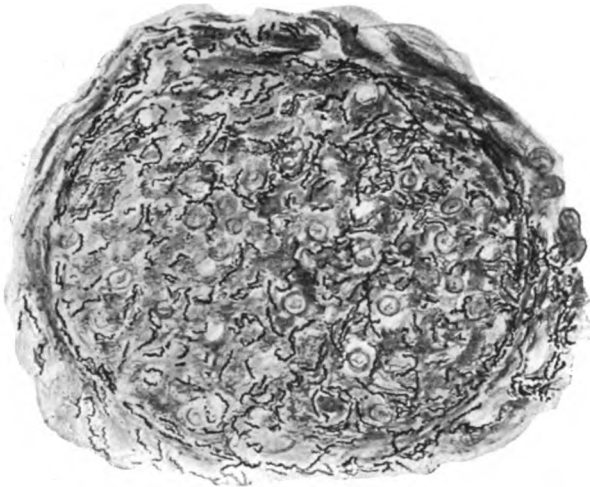

Fig. 126.—Syphilis, congenital. Heart. *Treponemata pallida* present in large numbers in nerve and its sheath.

Micro-organism.—The *treponema pallidum* is a very delicate, cork-screw-like micro-organism with one or more cilia at each end. It is stained faintly in cover-slip preparations by Giemsa's and Wright's methods. For demonstrating it in sections only Levaditi's method is at present available. The method is unsatisfactory for two reasons: it deposits a precipitate on the surface of the organisms making them appear larger than they really are; and it is very unreliable, often failing to stain the treponemas even when they are present in large numbers. It also renders necessary for the study of syphilitic lesions a parallel series of sections; one set stained for organisms, the other for cell changes.

The *treponema pallidum* is often present in enormous numbers in the lesions which it produces, in primary lesions, mucous patches, condylomas and especially in the liver and other organs in congenital syphilis. At other times it is very difficult to find any at all. This absence of organisms may be due to the acquisition of local immunity or to antisyphilitic treatment.

Location of *Treponema Pallidum*.—The *treponema* is found chiefly in two situations, between the epithelial cells of the epidermis, and most often and abundantly in connective tissue wherever it occurs, as subcutaneously, in various organs and tissues, and in blood-vessels and nerves. It lies in the minute lymph-spaces between the cells and the various fibrils, and especially between the collagen fibrils. When it is found in the lumina of blood-vessels, bile-ducts, etc., and in epithelial cells it has probably



Fig. 127.—Syphilis, congenital. Heart. *Treponemata pallida* in connective tissue and between muscle-fibers.

invaded them postmortem as the organisms are very actively motile. The organism sometimes occurs within giant-cells and may possibly be taken up by endothelial leukocytes.

Toxin.—The *treponema pallidum* produces a very mild toxin which is locally diffusible and is absorbed along the lymph-spaces and vessels. Apparently it requires numerous organisms and some time (days to weeks) to produce enough toxin to injure the fixed tissue-cells and to attract leukocytes.

Injury.—It is important in studying the lesions produced in syphilis to distinguish between the primary injury due to the direct action of the toxin and that secondary to obstruction of blood-vessels. The primary injury is difficult to demonstrate. The organisms may be present in large numbers without evidence of injury or reaction around them. In time, however, the epidermis over a chancre or a mucous patch disappears, evidently as

the result of necrosis slowly produced. In like manner in connective tissue the fibroblasts gradually begin to proliferate (regenerate) to replace those adjoining fibroblasts which have been destroyed. The cells have been killed slowly and diffusely here and there, not in large visible areas. Hence the regeneration is diffuse. In like manner fat-cells and smooth and striated muscle-cells may be gradually destroyed.

In the late lesions of syphilis necrosis is common and often extensive. It is due largely, perhaps entirely, to obstruction of blood-vessels and cutting off of the blood supply.

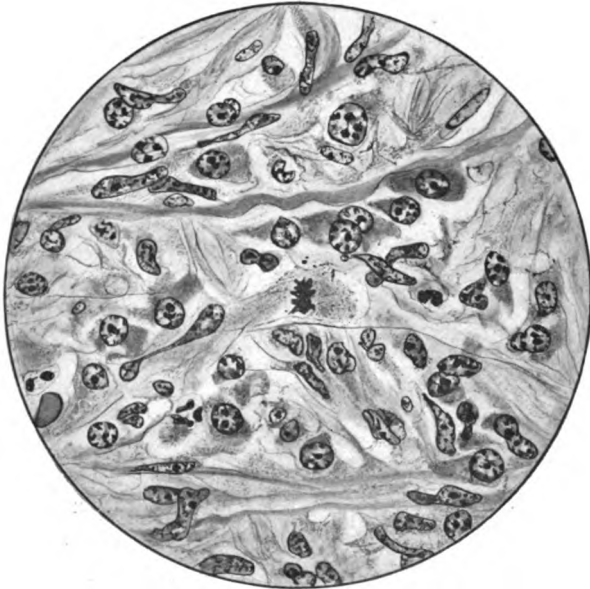
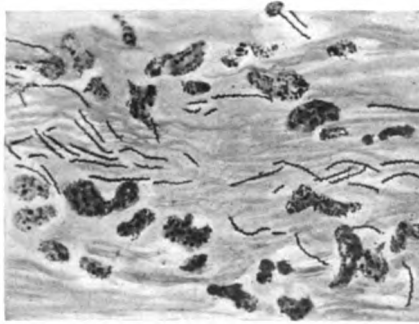


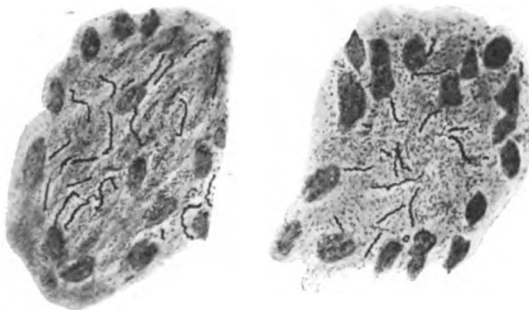
Fig. 128.—Syphilis. Primary lesion. Tissue infiltrated with numerous endothelial leukocytes; one of them is in mitosis.

Reaction.—The inflammatory reaction in syphilis takes place slowly. It consists of serum, endothelial and polymorphonuclear leukocytes, of lymphocytes and occasionally of eosinophiles. The numbers in which the cellular elements are present and the proportion in which they are combined vary greatly. Polymorphonuclear leukocytes may be entirely absent, or be present more numerous than any other cell of exudative origin. Lymphocytes, often in the form known as plasma cells, may be abundant or few. Mitosis of endothelial leukocytes, fibroblasts and lymphocytes is fairly frequent.

It is difficult to determine how much of the reaction is due to the *treponema pallidum* and its toxin and how much is due to the necrotic cells and the injurious products derived from them, but the latter elements certainly play an important part. Thus endothelial leukocytes often accumulate in large numbers around arteries, especially when the smooth muscle-cells are undergoing necrosis, and also around fat-cells when they have been destroyed. Fat and its products attract them strongly.



a



b

Fig. 129.—Syphilis, acquired. Primary lesion. *Treponemata pallida* in (a) connective tissue and (b) giant-cells.

Giant-cells occur rarely in chancres, frequently in gummas. They are probably all of the foreign body giant-cell type, due to fusion of endothelial leukocytes. The inclusions which they are attempting to digest vary; elastic or collagen fibrils; masses of fibrin; most often fat and its products. They may also form under certain conditions within blood-vessels, apparently around

treponemas, and in this location possibly from endothelial cells instead of leukocytes.

The inflammatory reaction in the different lesions due to the *treponema pallidum* is essentially the same although the gross and clinical manifestations vary greatly.

Repair.—The lesions due to the *treponema pallidum*, unlike those caused by the tubercle bacillus and many other infectious agents, tend in time to heal instead of spreading indefinitely, because the organisms, after a varying length of time, die out locally, apparently as the result of acquired immunity in the affected area.

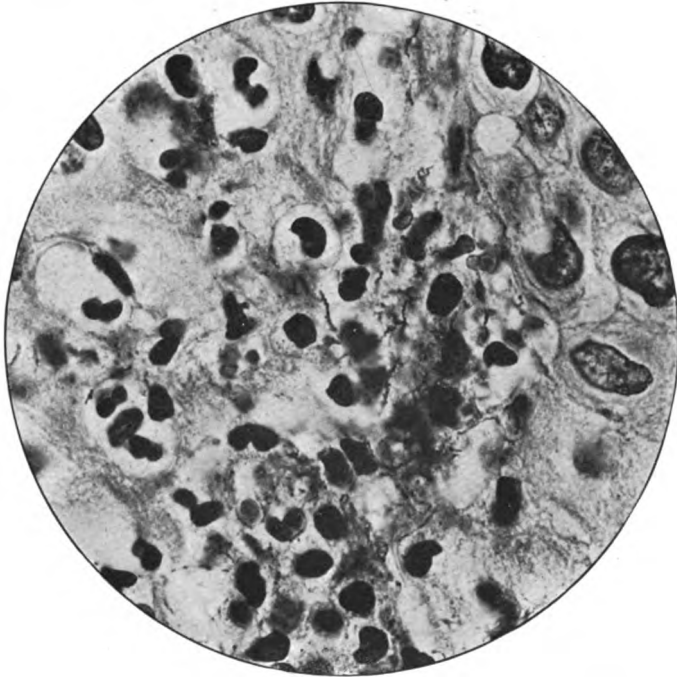


Fig. 130.—Syphilis. Primary lesion. *Treponemata pallida* in epidermis. M.

The local immunity is, perhaps, due to substances produced by the leukocytes attracted around the organisms.

The development of syphilitic lesions may also be stopped at any moment by appropriate treatment.

Repair of the simple lesions, those in which no extensive necrosis has occurred, takes place by destruction of the treponemas, gradual disappearance of the leukocytes and diminution in the number of fibroblasts with contraction of the collagen fibrils. The lymphocytes persist longest in and around the affected area. The ulcer-

ated surface of a chancre heals in the same way as an ordinary surface wound, by the formation of granulation tissue which is gradually covered over with epidermis. Where extensive necrosis has occurred as in gummas, the necrotic tissue is slowly dissolved and absorbed by the action of leukocytes and an ingrowth of granulation tissue. In time its place is taken by scar tissue. The most extensive scars resulting in this way are, perhaps, found in the liver which may be deeply clefted and extensively lobed as the result of necrosis followed by repair.

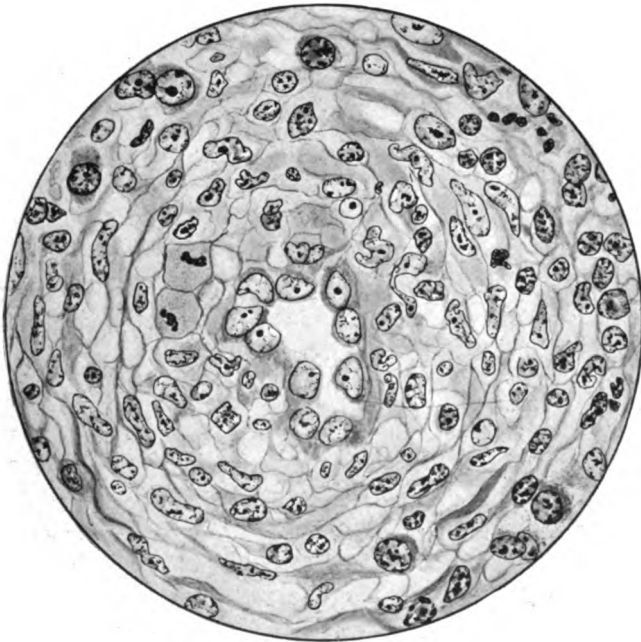

Fig. 131.—Syphilis. Primary lesion. Wall of blood-vessel infiltrated with many endothelial leukocytes; mitosis of one of them (diaster).

Pathologic Histology.—*Primary Lesion, Chancre, Hard Chancre.*—The primary lesion of syphilis starts on an epithelial surface. It is the first lesion produced by the *treponema pallidum* just as a furuncle often is with the *staphylococcus aureus*, the malignant pustule with the *anthrax bacillus*, etc. The *treponema* almost always infects the epidermis first and multiplies there between the cells and then, later, invades the lymph-spaces and vessels of the corium. It is usually present in large numbers. The injury produced is slight and diffuse. A cell here and there is destroyed and disappears. The result is the loss of the epidermis over a certain

area and slight to moderate erosion of the corium. The inflammatory reaction is mild. It consists of a moderate infiltration of the affected area with endothelial leukocytes and of a marked accumulation of lymphocytes, chiefly in the form of plasma cells, more abundantly at the periphery of the lesion and in the walls of the blood-vessels than in the lesion itself. The endothelial leukocytes are sometimes fairly abundant and polymorphonuclear leukocytes may be added to them in variable numbers. Giant-cells are rare. Regenerative proliferation of fibroblasts is fairly active. Exu-

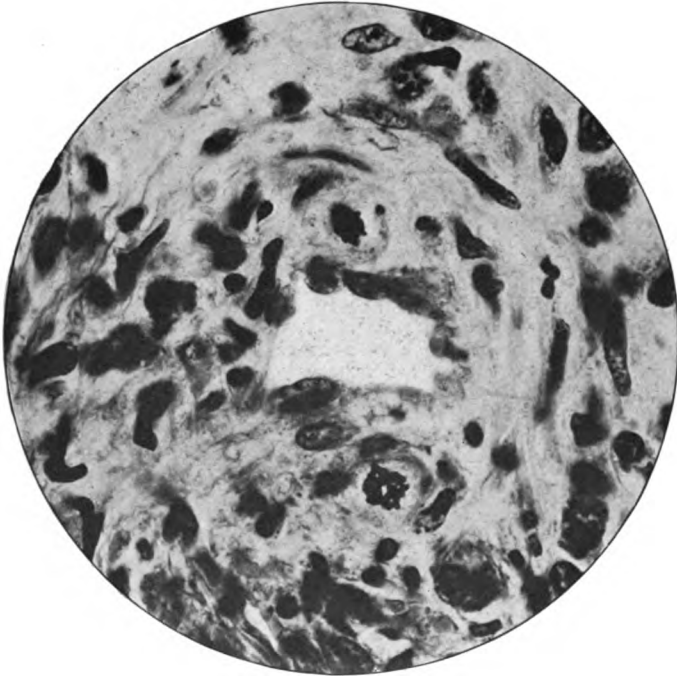


Fig. 132.—Syphilis. Primary lesion. Two mitoses in wall of blood-vessel. M.

dation and regeneration take place in the corium not only between the blood-vessels, but often also around and within them, leading to narrowing and occasionally to obliteration of them.

The primary lesion starts as a papule which is soon transformed into an erosion with thick indurated base. The hardness of the chancre seems to be due rather more to the proliferation of fibroblasts than to the leukocytic and lymphocytic infiltration.

The size of the primary lesion varies considerably, from a few millimeters to four centimeters or over in diameter. It is regularly

accompanied by swelling and induration of the regional lymph-nodes (syphilitic bubo) which, in uncomplicated cases, show little or nothing beyond hyperplasia of the lymphocytes.

Secondary Lesions.—They represent the reaction to the treponemas distributed all over the body as the result of the septicemia and are most conspicuous in the skin. The condylomas are often removed, but the other lesions are rarely obtained for histologic examination. The gross manifestations are much more striking than the microscopic changes which simply show various combinations of exudation and repair.

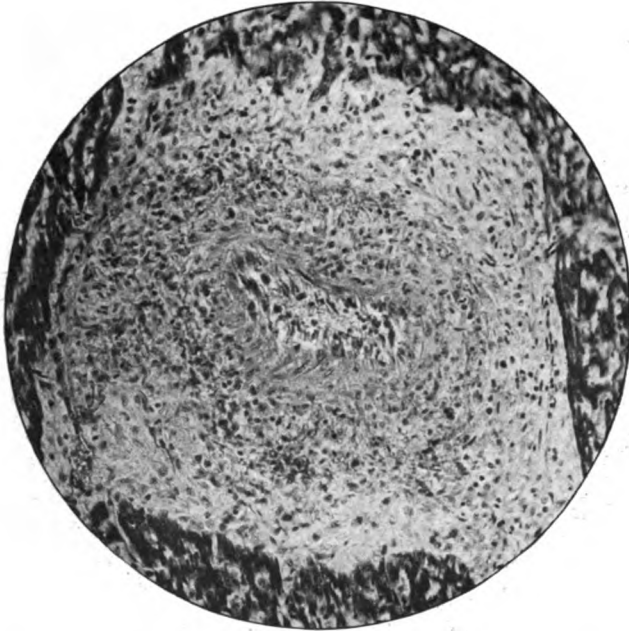


Fig. 133.—Syphilis, congenital. Heart. Artery. Adventitia infiltrated with numerous endothelial leukocytes. M.

The lesions are multiple, slight and superficial. They heal without leaving any scars. Evidently more or less general acquired immunity prevents their development beyond a certain moderate degree, except in rare instances.

Tertiary Lesions.—The histologic changes in the tertiary lesions have been practically covered under injury and reaction. Here it is needful only to emphasize the two following points.

1. The tertiary lesion represents an inflammatory reaction to a mild form of injury and reparative proliferation of the fibroblasts plays a prominent part in the lesion.




Fig. 134.—Syphilis, acquired. Brain. Syphilitic endarteritis. Vessel almost occluded, chiefly by infiltration with endothelial leukocytes. Many others together with polymorphonuclear leukocytes outside of the vessel. Fibrin at the periphery.

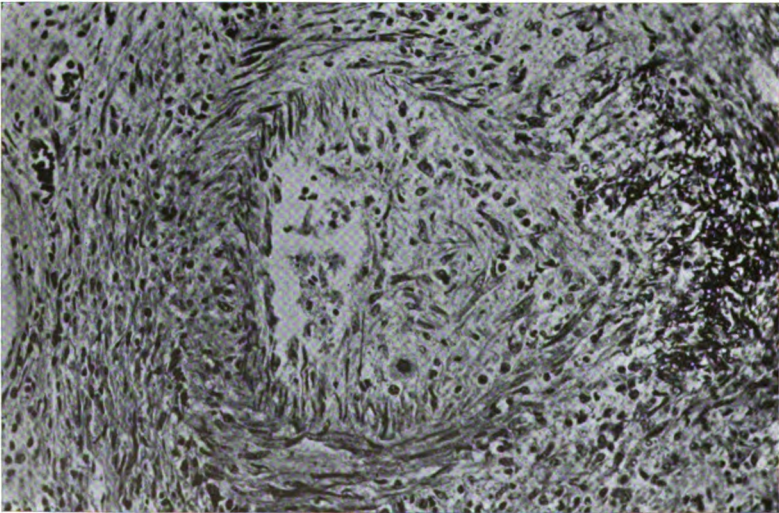


Fig. 135.—Syphilis, acquired. Liver. Syphilitic endarteritis. Mitosis of one cell. M.

2. This inflammatory lesion is often complicated by more or less extensive necrosis, due to obliteration of one or more blood-vessels (usually arteries) in or adjoining the lesion, owing to occlusion of their lumina by the same inflammatory process taking place in the intima. The term *gumma* is practically restricted to those tertiary lesions in which necrosis has taken place. The other lesions are classed as inflammatory (periostitis, meningitis, endarteritis, etc.).

It is important to cover briefly the tertiary lesions in the principal tissues and organs of the body so that some connected

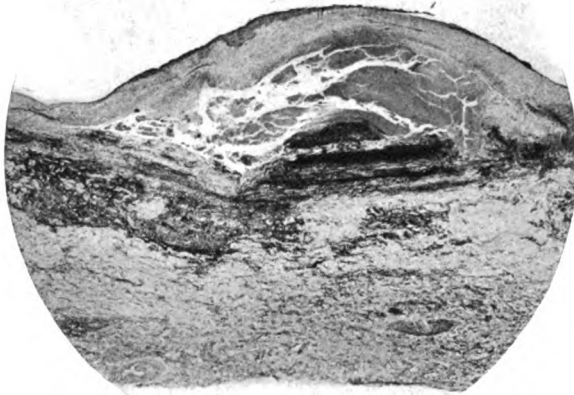

Fig. 136.—Aorta. Syphilis. Elastic tissue stain. Necrosis extending into media. Thickening of intima. M.

idea of the *treponema pallidum* and the pathologic disturbances which it may cause may be obtained. First in importance, owing to their wide distribution and their relation to all syphilitic lesions and especially to *gummas*, are the blood-vessels.

Blood-vessels.—Syphilitic lesions of the blood-vessels are of frequent occurrence and of great importance. The *treponemas* are present more often in the adventitia than in the intima, but both locations are frequently infected at the same time. The media may thus be involved from either or both sides. The intima at one point or all around may rapidly thicken up and cause **narrowing** or complete occlusion of the lumen. The thickening is

due to an infiltration with endothelial leukocytes often combined with lymphocytes and occasionally with polymorphonuclear leukocytes. In addition the fibroblasts proliferate. The cell changes correspond with those produced elsewhere by the treponema. - As soon as the blood-supply is cut off completely, necrosis occurs and more or less fibrin is formed.

In the adventitia much the same reaction takes place. As soon as necrosis occurs, probably as the result of occlusion of blood-vessels, numerous endothelial or polymorphonuclear leukocytes

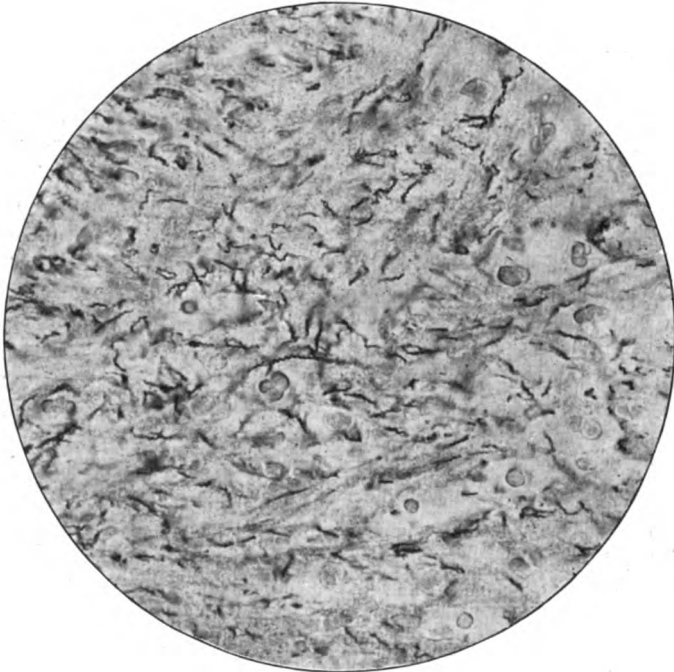

Fig. 137.—Syphilis. Aorta. Syphilitic endarteritis. Many treponemata pallida in lesion. M.

or both are attracted by the products of the disintegrating cells. Occasionally some of the endothelial leukocytes fuse around substances hard to dissolve, such as elastic fibrils, masses of fibrin, or fat and its products and form foreign body giant-cells.

As already stated necrosis occurs in tuberculous lesions, usually owing to complete infiltration of the tissues with endothelial leukocytes which block all the smaller vessels and thus cause necrosis and disappearance of the tissue cells before they themselves undergo necrosis. Consequently all the landmarks have been

obliterated. In syphilis, on the contrary, the necrosis results largely or entirely from the obliteration of blood-vessels and the tissue which undergoes necrosis may show only moderate inflammatory infiltration and proliferation of fibroblasts, or none at all.

Syphilitic lesions of the aorta have always attracted much attention and excited a great deal of discussion, but the demonstration of treponemas in them often in great numbers has decided in favor of their actual occurrence. The organisms may invade the aorta from without or through the nutrient vessels of the wall, but certainly in many and perhaps in most instances they infect the vessel from the intimal side. The lesions often extend deeply into the wall causing necrosis and softening with subsequent repair

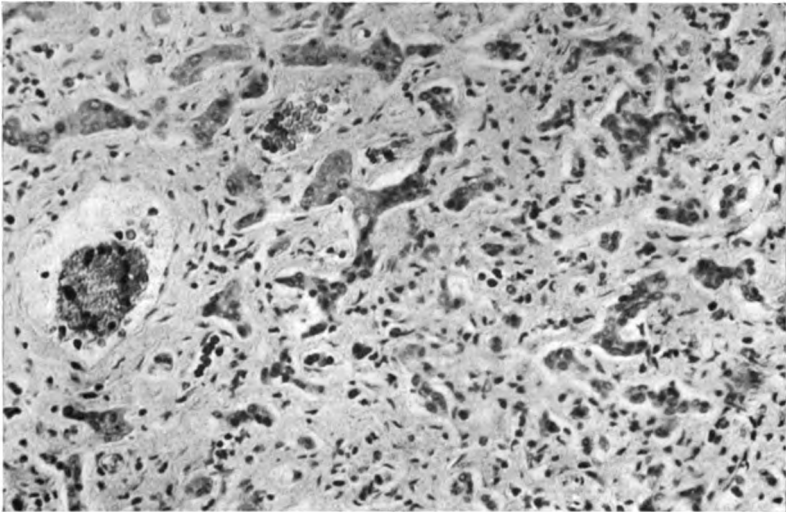


Fig. 138.—Liver. Syphilitic cirrhosis, acquired. Liver cells atrophied; marked increase of connective tissue. M. and B.

and scar formation, or yielding of the wall in the form of aneurysms. Fibrin often forms in abundance and later undergoes more or less extensive organization.

Syphilitic lesions of the aorta most commonly involve the arch, especially its ascending portion, and may extend to the aortic valve; but they may occur in any part of the aorta. In a case of congenital syphilis in a girl of sixteen extensive lesions were present only in the abdominal portion of the aorta.

Liver.—The early lesion in the liver is a diffuse inflammatory process which results in more or less of an exudation of endothelial or polymorphonuclear leukocytes, or of both between the liver cells

and the walls of the sinusoids. The fibroblasts gradually proliferate and lead to much increase of the connective tissue. Contraction of the connective tissue causes atrophy of the liver cells. This inflammatory process may be present throughout the liver, but it is usually focal and statistics show that it is more common in the region of the suspensory ligament, and in the left lobe than in the right.

Frequently the treponemas invade the blood-vessels, especially the arteries, and produce the same type of lesion there, with resulting thickening of the intima and partial to complete occlusion of the lumen, so that the circulation is interfered with and necrosis (gumma formation) occurs. Repair of the necrosis by granulation tissue leads in time to scar formation and often to marked lobulation of the liver. Repair of the diffuse inflammatory lesion when necrosis has not taken place results in sclerosis.

Central Nervous System.—Syphilitic infection of the central nervous system may be confined to the meninges or to the nervous tissue or involve both synchronously.

Syphilis of the meninges may affect chiefly the blood-vessels or the tissue around them, or more commonly both at the same time. The process is usually complicated by necrosis (miliary and large gummas) owing to obstruction of small and large arteries by endarteritis. The diffuse process in the meninges consists of an inflammatory exudation of endothelial and polymorphonuclear leukocytes and of the formation or more or less fibrin. Giant-cells may be few or numerous. Usually there is a well marked infiltration with lymphocytes. Treponemas may be present in small or large numbers.

Syphilitic infection of the brain appears under two forms. The first is gumma formation and is usually, but not necessarily, due to extension of the process from the meninges. Single or multiple gummas of small or large size may be formed. The neuroglia cells are usually stimulated to proliferative activity and often surround and digest masses of fibrin formed in their neighborhood.

The second type of infection is caused by a diffuse infiltration of the grey matter, especially of the cerebrum, with treponemas, which cause little injury or inflammatory reaction around them, but gradually bring about more or less proliferation of the neuroglia cells, as a result of which a certain degree of sclerosis is produced. In time many of the ganglion cells atrophy and disappear (general paresis). Until the recent discoveries of Noguchi this type of lesion was supposed to be of toxic origin and not due to the immediate presence of the treponemas.

Bone.—The treponema may affect bone on the inside or the

outside. A lesion starts as an inflammatory process of mild type. The fibroblasts which proliferate in the process of repair tend to produce bone because they are derived from the osteal cells. The result is sclerosis of bone within, periosteal thickening without. The lesions may be complicated by necrosis owing to obliteration of blood-vessels. The necrotic tissue has to be softened and removed. The result is erosion of bone; but where necrosis has not occurred bone continues to be formed. This combination of erosion and new-formation of bone is fairly characteristic of syphilitic lesions of the skeleton.

The lesions in the bones in congenital syphilis are wide-spread and fairly constant and characteristic. The treponemas develop readily along the line of ossification where the vascular supply is abundant. Their presence causes delayed ossification, so that the normal narrow straight line, where the cartilage is replaced by

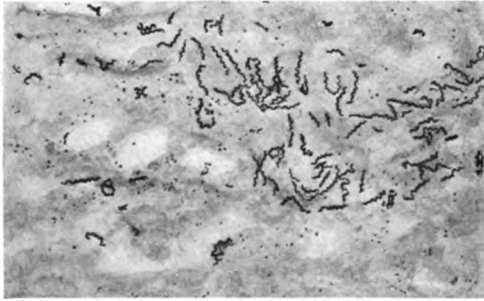


Fig. 139.—Syphilis, acquired. *Treponemata pallida* in gumma of optic nerve.

bone, becomes a broad yellowish white zone which fades out on the side away from the cartilage. In addition the organisms often cause an increase of the connective tissue around the vessels which send tongue-shaped processes into the cartilage, so that the upper edge of the line of ossification appears jagged.

Other Organs.—Syphilis affects many other organs and tissues (testicle, muscle, skin, etc.). The lesions formed are comparable in every way with those already described.

If the principles of the pathologic process caused by the *treponema pallidum* are fully grasped the lesions in the various organs can be readily understood.

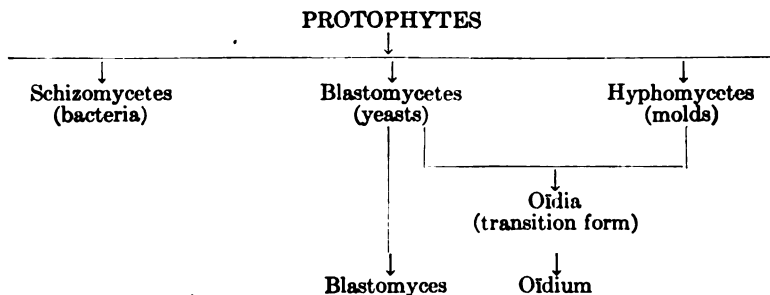
Amyloid.—Syphilitic infection of long duration is often complicated by amyloid formation, probably as the result of some toxic substance acting on the fibroblasts. Amyloid is formed in the liver, kidney and spleen; less often in the adrenal glands and in a few other situations. Excessive amyloid formation in the

kidney may bring about chronic nephritis owing to the mechanical injury it exerts by its presence in the glomerular tufts, the blood-vessels, and sometimes around the tubules. It interferes with the action of the glomeruli and causes atrophy of the tubules. Elimination of waste products in the circulation is thereby prevented to a less or greater extent and they, acting as injurious agents, are perhaps the direct cause of the nephritis.

BLASTOMYCES AND OIDIUM

Most infectious diseases due to vegetable parasites are caused by bacteria, but a few owe their origin to micro-organisms of a higher type, namely, to the yeasts and molds. Two of the infectious processes caused by yeasts, although comparatively rare, deserve brief consideration. Both the organisms and the lesions they produce microscopically and in gross resemble each other more or less closely. For this reason they were for a long time confused with each other, but the differential characteristics are now fairly generally recognized.

The relation of the yeasts or blastomyces to the bacteria and the molds is shown in the following diagram.



True yeasts grow by budding; they rarely form mycelia; under favorable conditions of growth they may form endospores.

Oidia grow by budding and as mycelia with spore formation.

Hyphomycetes grow as mycelia with spore formation of asexual or sexual origin.

All authorities seem agreed that there is no sharp line of demarcation between the blastomycetes and the hyphomycetes, and most of them place the oidia as a transition form.

Blastomycosis is the term applied to the lesions produced by a blastomyces. A variety of organisms have been cultivated from the lesions and different names have been assigned to them. Whether they are distinct entities or only strains of a single organ-

ism has not yet been definitely decided. Therefore, at present, it seems best to use simply the general term blastomyces.

Blastomycosis has been recognized and studied more thoroughly in and around Chicago than anywhere else in this country. Infection begins practically always in the skin and may remain localized there. Occasionally, however, the organism invades the circulation and causes lesions in all parts of the body.

Micro-organism.—The blastomycetes occur in human tissues only in the blastomycetoid form, that is, as small round bodies

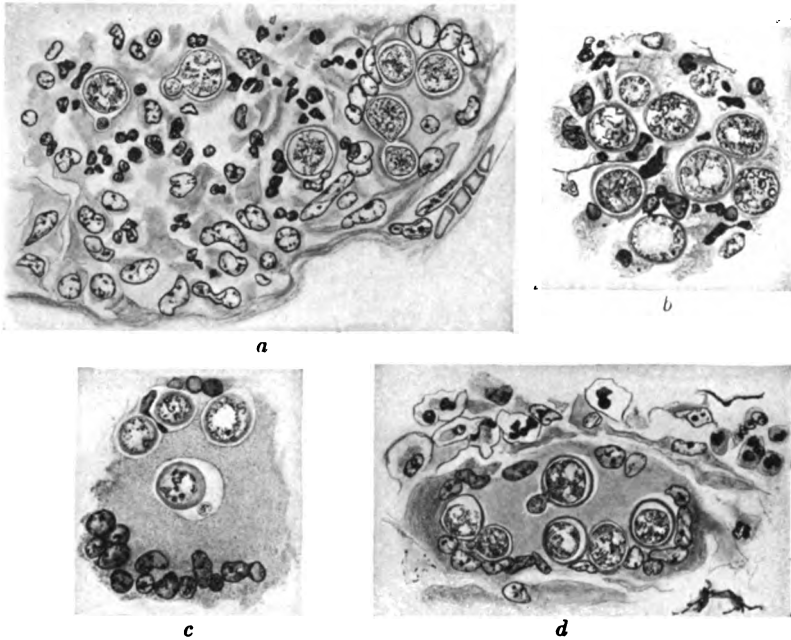


Fig. 140.—Blastomycosis. Focal pneumonia due to the blastomyces. Exudation consists of polymorphonuclear and endothelial leukocytes. Some of latter fused to form giant-cells which contain many organisms. *a*, Part of an alveolus; *b*, *c*, and *d*, details from exudation.

with granular protoplasm, and with thick hyaline capsules. They multiply by budding only. In cultures they may develop mycelia or grow by budding, or in both ways. They may be numerous in the lesions which they produce, or few and hard to find.

Toxin, Injury and Reaction.—The blastomyces produces a fairly strong toxin which acts locally, frequently causes necrosis, and excites a well marked inflammatory reaction. The exudation consists of serum and polymorphonuclear and endothelial

leukocytes. Much fibrin is sometimes formed. Many of the blastomyces are enclosed in endothelial leukocytes and in giant-cells due to fusion of these latter cells.

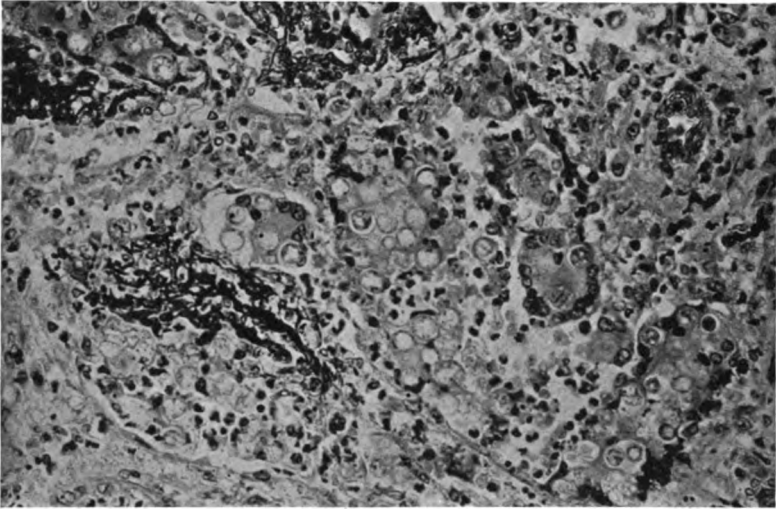


Fig. 141.—Blastomycosis. Focal pneumonia due to the blastomyces. M.

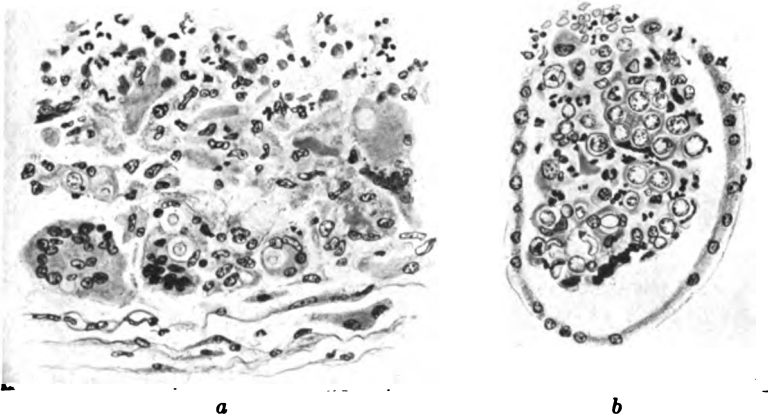


Fig. 142.—Blastomycosis. Focal pneumonia due to the blastomyces. Numerous organisms present. Exudation in *b*, consists of polymorphonuclear leukocytes. Several giant-cells in *a*.

Following necrosis of the tissue cells the lesion may present the appearance of caseation, but as a rule it tends to undergo soften-

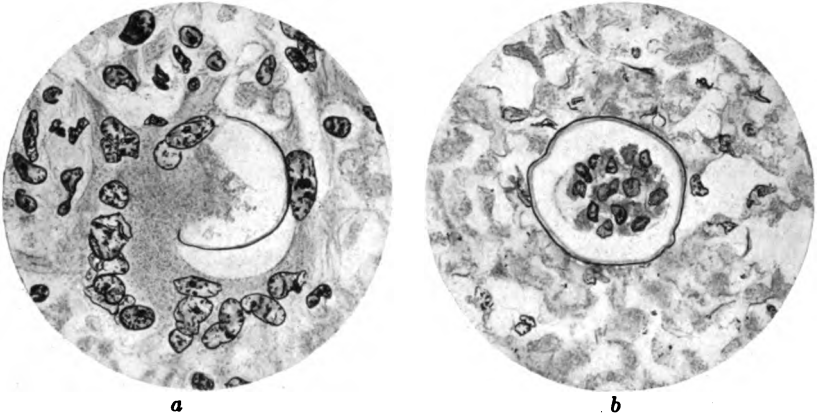


Fig. 143.—Oidiomyces. *a*, Ruptured capsule partially surrounded by a foreign body giant-cell; *b*, empty capsule invaded by leukocytes.

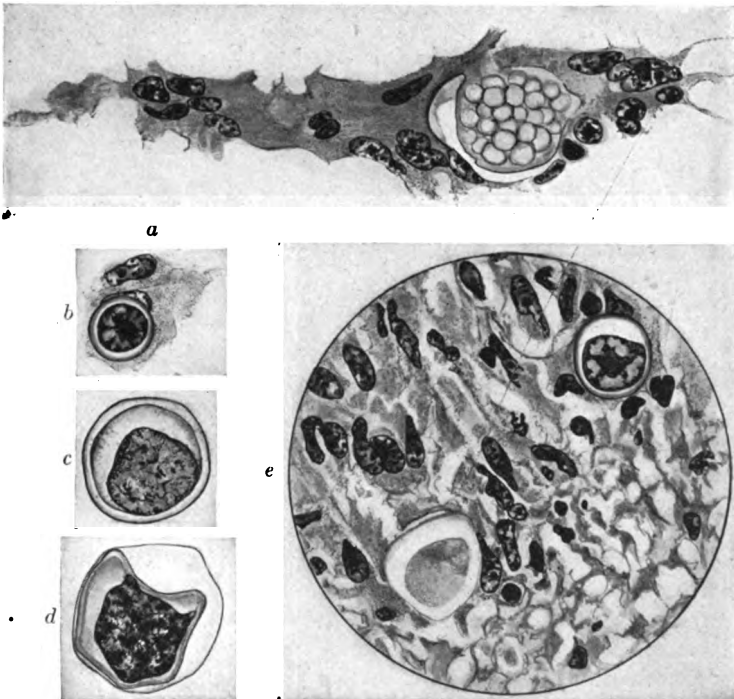


Fig. 144.—Oidiomyces. *b*, *c* and *d*, Show structure of organism; *a*, organism filled with spores in a giant-cell; *e*, two organisms and the characteristic cellular reaction which they produce.

ing and transformation into an abscess or an ulcer according to its location.

In the skin the blastomyces produces chronic lesions of a combined nodular and ulcerative type.

In the lungs the lesion resembles a lobular pneumonia and affects large and small groups of air-sacs. Fibrin often forms in abundance from the exudation and may undergo organization. In other foci abscesses result from necrosis and softening of the alveolar walls.

Multiple lesions may form in various other organs, such as lymph-nodes, spleen, liver, kidneys, bone, etc. They may be small or large, few or many.

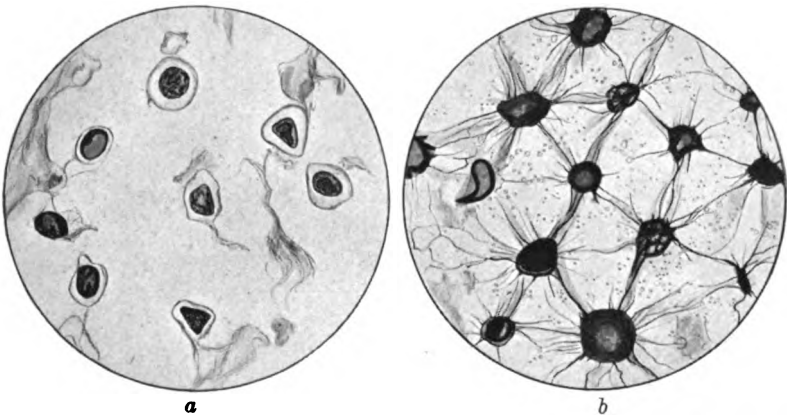


Fig. 145.—Oidiomyces. Organisms in alveoli of lung. In *a*, distinctly visible; in *b*, surrounded by deeply stained mucinous secretion.

Oidiomyces (*granuloma coccidioides*) is the term applied to the lesions produced by an oïdium variously named in the past *immitis*, *coccidioides*, etc., but not yet definitely classified by the botanists. Infection with this organism is rare and is confined almost exclusively to California. The disease is practically fatal.

The oïdium occurs in human lesions in the form of spherical bodies which may reach a size of thirty microns. They consist of an irregularly staining mass of protoplasm enclosed within a double contoured capsule which is occasionally covered with prickles, or even long spines. The organisms multiply in tissues only by endosporulation, never by budding. The spores may number as high as a hundred or more. They are liberated by the bursting of the capsule. The number of parasites in the lesions varies. They may be many or few and hard to find. In cultures the oïdium

grows as long septate branching hyphæ. In time spores develop in the ends of the hyphæ and are infectious if inoculated into animals; the hyphæ themselves are not.

Toxin, Injury and Reaction.—The lesions produced by the oïdium often bear a close resemblance to those caused by the tubercle bacillus, and have probably been mistaken for them more than once on histologic examination. If the organisms are few in number typical caseation may be produced as the result of a gradual infiltration of the tissues with endothelial leukocytes.

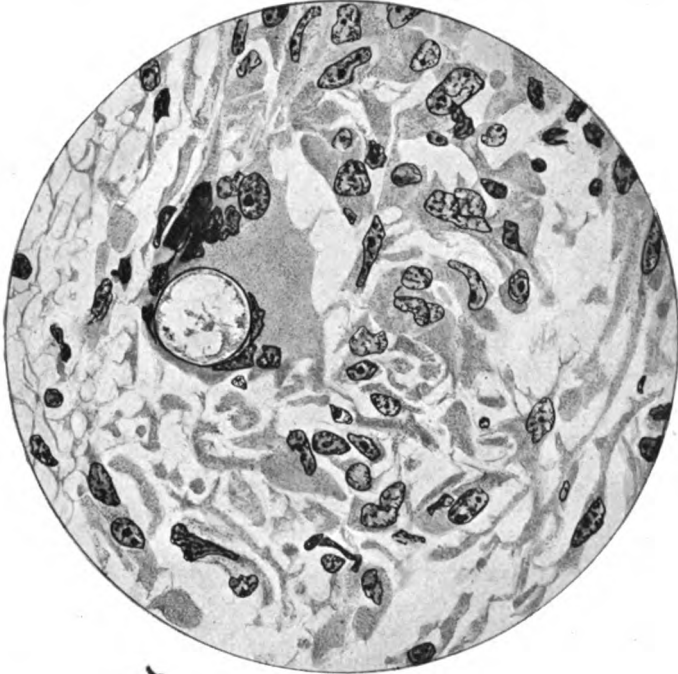


Fig. 146.—Oïdiomycosis. Organism in a giant-cell. Inflammatory exudation consists chiefly of endothelial leukocytes.

If they are numerous suppuration, often in the form of abscesses and ulcers, is more likely to occur. Giant-cells are of frequent formation and often contain oïdia. The lesions may be infiltrated with numerous eosinophiles.

The oïdium tends to spread by the blood and lymph streams so that the lesions, as a rule, are widely distributed. The primary focus is as likely to be within the body as in the skin. The lesions not only closely resemble those caused by the tubercle bacillus, both histologically and in gross, but they tend to involve much

the same organs, the lungs, lymph-nodes, adrenal glands, meninges, seminal vesicles, etc.

In the skin the lesions are chronic in type and consist of nodules, abscesses and ulcerations.

ENTAMEBA HISTOLYTICA

The *entameba histolytica* causes a primary chronic ulcerative process in the large intestine, so-called amebic dysentery. The organisms are frequently carried to the liver by the portal circulation and give rise to abscesses which may attain a large size and may extend to a pleural cavity or to a lung. Rarely, metastatic lesions are produced in the lungs and brain.

Amebic dysentery is a common infection in the tropics, but occurs also more or less frequently in the temperate zones.

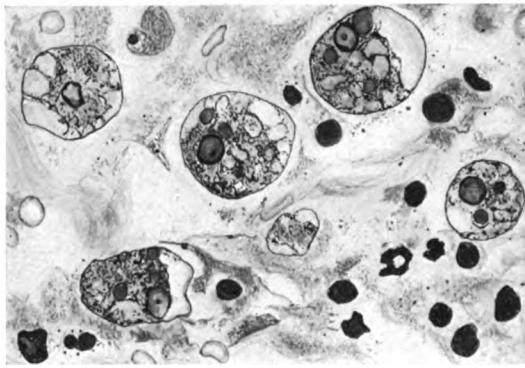


Fig. 147.—Amebic dysentery. *Amebæ histolyticæ* in submucosa of intestine.

Micro-organism.—The *entameba histolytica* measures fifteen to twenty-five microns in diameter. It contains a small round vesicular nucleus which stains but poorly with the ordinary basic dyes and with alum hematoxylin. The nucleus contains a minute nucleolus. The cytoplasm around the nucleus is finely granular and is surrounded by an outer zone or ectosarc which is transparent and refractive, and which sharply defines the outer limits of the organism.

The *entameba histolytica* is commonly sought in preparations made from the fresh stools and examined on a warm stage, in order to detect the characteristic movements; but it is readily identified in properly fixed tissues owing to its characteristic morphology.

The organism is quite phagocytic and frequently contains red blood-corpuses, bacteria, or cellular débris. It is able to penetrate fibrous and other tissues and is frequently found in the walls of blood-vessels and inside of them.

Toxin, Injury and Reaction.—The *entameba histolytica* evidently secretes a mild toxin which slowly produces necrosis of the

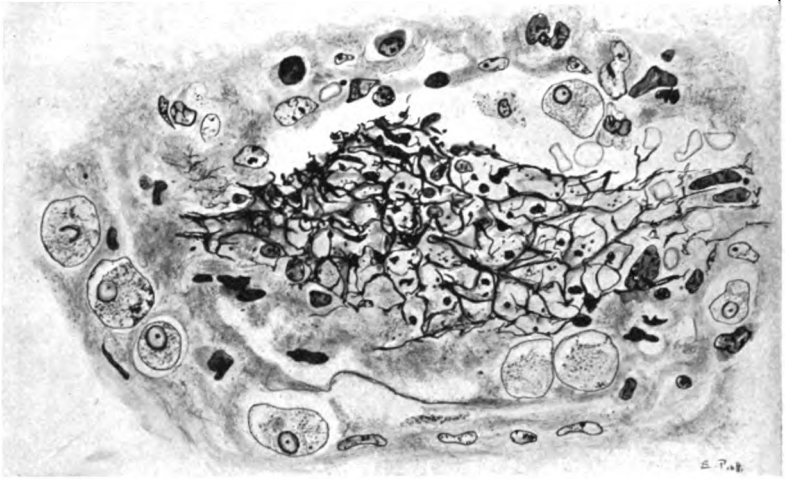


Fig. 148.—Amebic dysentery. *Amebæ histolyticæ* in wall of vein in intestine, several also within lumen of vessel.

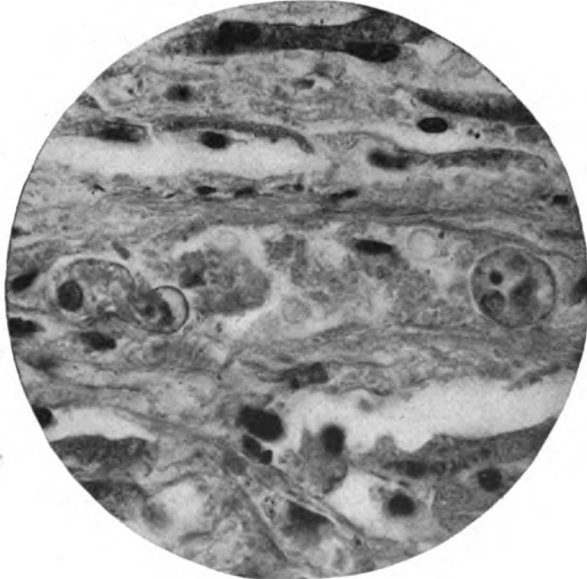


Fig. 149.—Liver. *Ameba histolytica*. Two amebæ in small blood-vessel. M. cells in its neighborhood and also gradually dissolves them. It does not, as a rule, cause an active acute inflammatory reaction.

Frequently the amebæ are found in considerable numbers in tissues which otherwise appear normal. In other fields the nuclei are fading out and in still other places there is more or less of an inflammatory exudation; chiefly polymorphonuclear leukocytes and fibrin. Sometimes lymphocytes are fairly numerous.

Intestine.—Infection begins in the mucosa where there is formed a small ulcer which gradually spreads more or less extensively in the submucosa, undermining the mucosa. The tissue

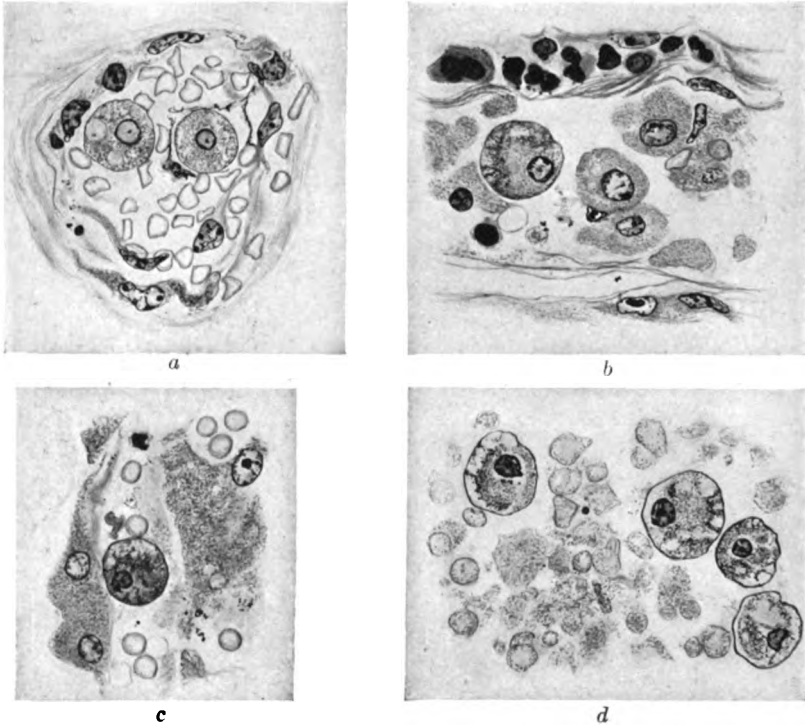


Fig. 150.—*Ameba histolytica* in the liver. *a*, *b*, and *c*, Within veins and capillaries; *d*, in an abscess.

gradually undergoes necrosis. The blood-vessels persist longest, but usually in the end become thrombosed and then are quickly destroyed. The amebæ are often very numerous in the necrotic tissue. Polymorphonuclear leukocytes may be present in numbers in the exudation, but tend to undergo necrosis like the other cells. Fibrin is sometimes abundant, especially upon the wall of the ulcer.

The gross lesions of the intestines are more or less character-

istic. The ulcerations extend widely beneath the mucosa, undermining it in all directions, so that they are often connected by sinuous passages. The edges of the ulcers are swollen and gelatinous owing to the serous and cellular exudation in them.

Liver.—In the liver the amebæ can sometimes be found in the sinusoids in places where the liver tissue appears perfectly normal. Gradually, however, the tissue undergoes necrosis and then solution. Leukocytes may not be very abundant. Fibrin often forms on the walls of the abscesses. That is about the extent of the process but it keeps spreading. There is little or no evidence of repair. The amebæ invade the living tissue peripherally and the necrosis and softening follow them.

BALANTIDIUM COLI

The balantidium coli is an infusorium of oval shape measuring about 0.1 by 0.07 mm. It is surrounded by cilia which are most developed in the funnel-shaped opening at one end, called the peristome. It has a bean-shaped macronucleus and a spherical micronucleus. In the tissues the organisms frequently exhibit changes of form due to ameboid motion, as in penetrating the epithelial lining of the intestinal glands.

This organism is a common inhabitant of the intestine of the hog where it causes no lesion. On rare occasions it is apparently transferred to man and gives rise to more or less extensive ulcerations in the large intestine (rarely in the lower end of the small intestine) accompanied usually with persistent diarrhoea which may terminate fatally. Many balantidia may be found in the stools.

Occurrence.—The balantidium coli is found occasionally in the lumen of an intestinal gland. More often it penetrates the epithelial lining and lies along side of a gland or at its base. Many enter the lacteals and occasionally they collect in numbers in the lymph-nodules, lying among the lymphocytes. The lymph-vessels of the submucosa may be greatly distended and filled with them. They are found also in the veins, but in smaller numbers. In addition they occur in the lymph-vessels and veins, both in the muscle coats and subperitoneally.

It would seem as if the balantidia would be transported from these situations to all parts of the body, but so far as known they

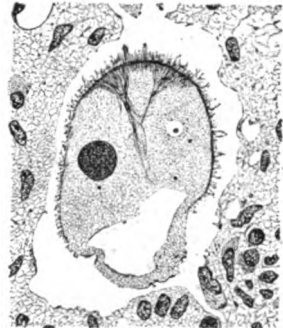

Fig. 151.—Balantidium coli in lymph-vessel in intestine.

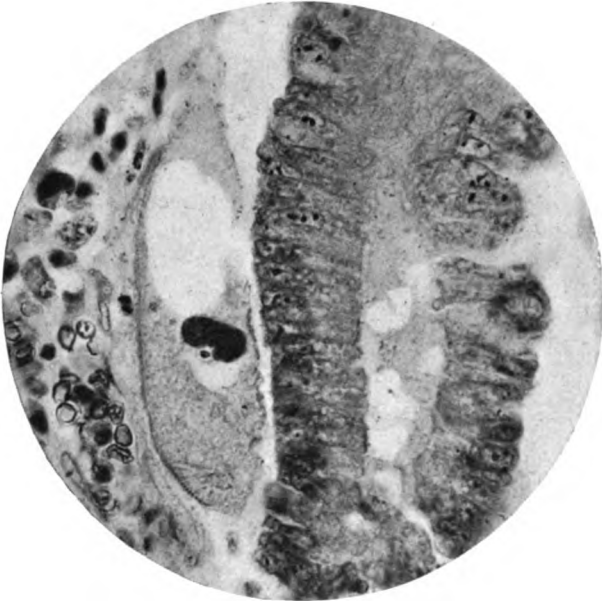

Fig. 152.—*Balantidium coli* outside of gland in mucous membrane of intestine. M.

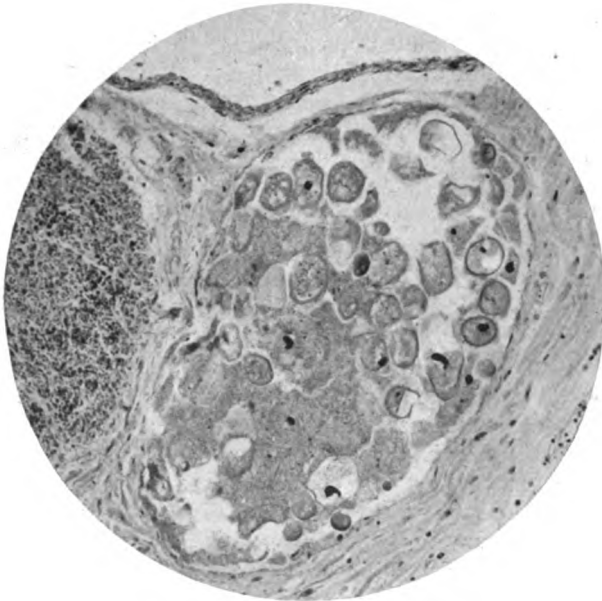


Fig. 153.—The *balantidium coli* present in numbers in a dilated lymphatic in the submucosa of the intestine. M.

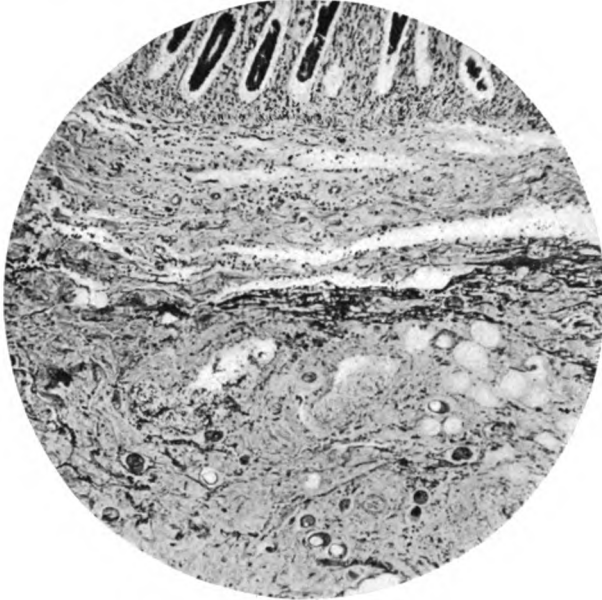


Fig. 154.—Balantidia coli in submucosa of intestine. M.

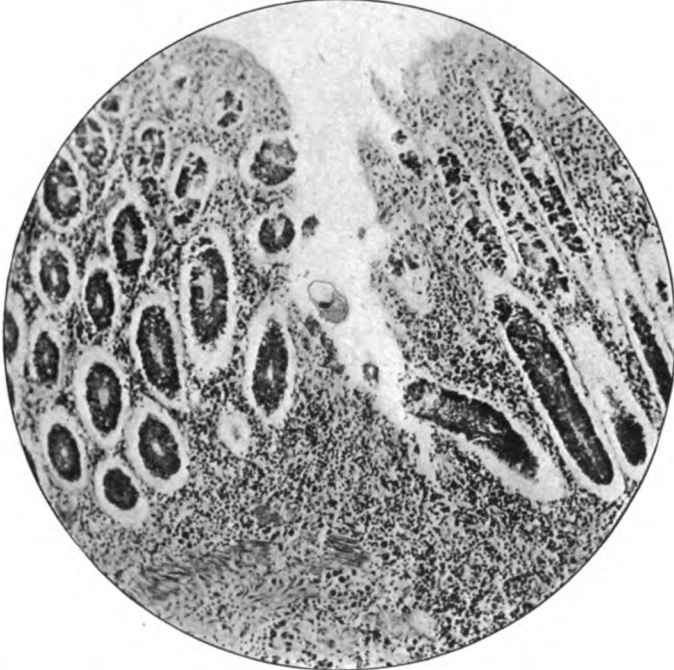


Fig. 155.—A balantidium coli in a slit-like ulceration in the mucosa of the intestine. M.

have been found, outside of the intestinal wall, only in the mesenteric lymph-nodes and in the liver.

The balantidium occurs also in large numbers in the pus and in the walls of the ulcers and fistulous tracts.

Injury.—The balantidium coli seems to produce mechanical injury only. This view is favored by the frequent lack of any inflammatory reaction around it in the various situations in which it is found outside of the ulcers. As a rule the mechanical injury does little harm. Occasionally, however, the paths opened up in

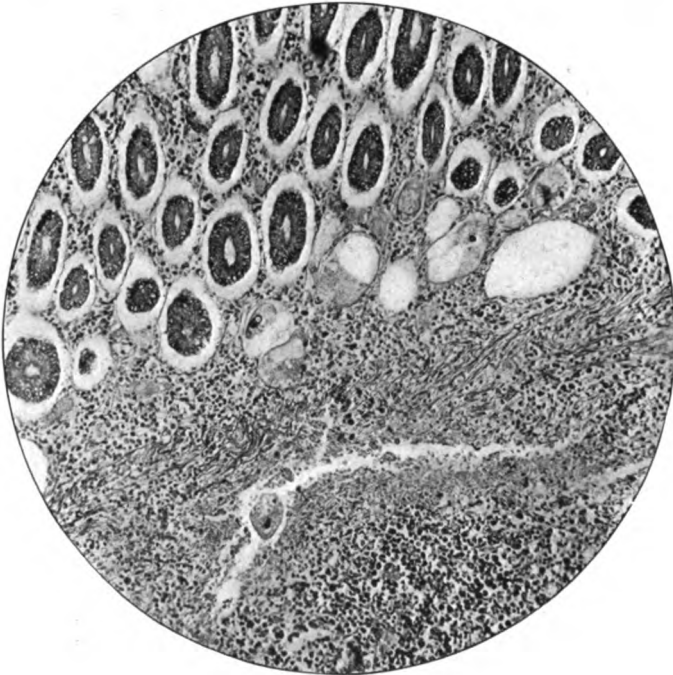


Fig. 156.—A balantidium coli in a fistulous tract in the submucosa of the intestine. Several also at the base of the glands. M.

this way become infected with bacteria and a fistulous tract is formed, in which balantidia congregate and which they aid in enlarging, so that eventually extensive ulcers with more or less undermined edges are formed. Around these ulcers the walls are infiltrated with numerous polymorphonuclear leukocytes, lymphocytes, eosinophiles and mastcells, in varying numbers. Sometimes the intestinal wall is much thickened. In general the ulcerations occurring in connection with the balantidium coli resemble those produced by the entameba histolytica.

TRICHINELLA SPIRALIS

Introduction.—The trichinella spiralis is a nematode which occurs frequently under ordinary conditions in the hog and the rat, and occasionally, as a result of the ingestion of uncooked, infected pork, in man. The encysted trichinæ escape as the muscle containing them is digested and develop and differentiate in the stomach and small intestine into male and female round worms of minute size. The female measures 3 mm., the male 1.5 mm. in length. With a little practice they can be recognized with the

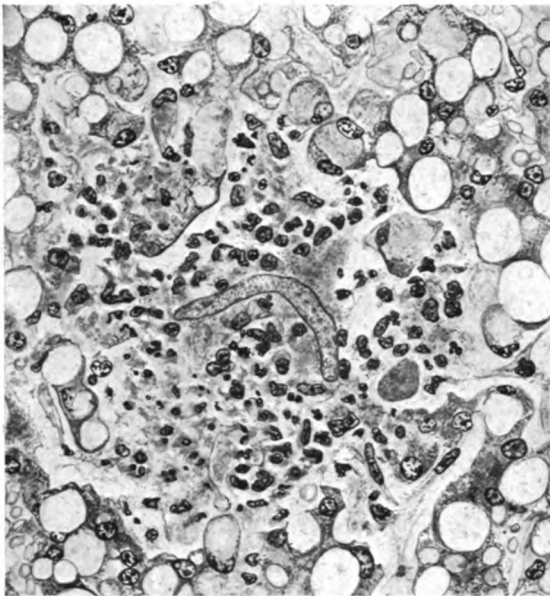


Fig. 157.—Trichiniasis. Liver. Embryo of trichinella spiralis surrounded by acute inflammatory exudation.

naked eye in the intestinal contents. The female, after fertilization, ploughs her way just beneath the epithelium of the duodenum and jejunum (rarely as low as the cecum) and deposits in successive batches her numerous embryos, when ripe, here and there in the mucous membrane. The embryos quickly gain entrance by their own activity to the lymphatics and are carried to the mesenteric lymph-nodes where, in the early stages of infection, they may often be found in the lymph sinuses. From the lymph-nodes they pass by way of the thoracic duct to the blood stream and by it are distributed all over the body. By means of centri-

fugalization they have been demonstrated in large numbers in the circulating blood (up to 100 in 1 c.cm.). Within ten days to three weeks after ingestion of infected pork trichinæ may be found in all

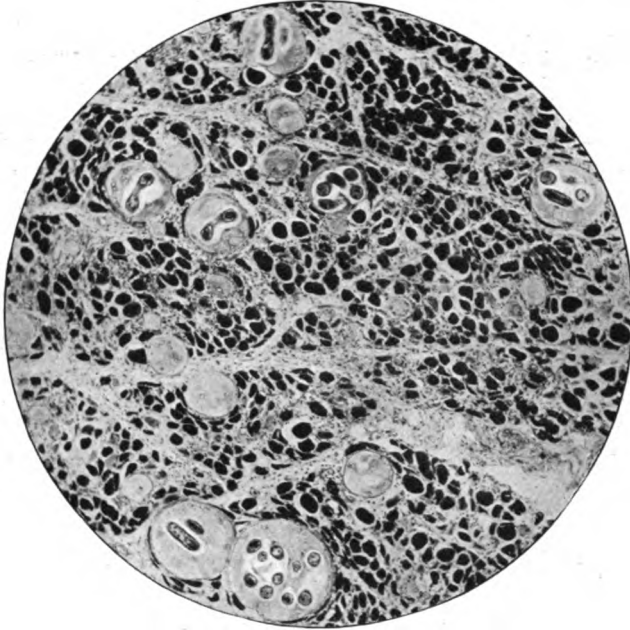


Fig. 158.—Trichiniasis. Many trichinellæ spirales within muscle-fibers. M.

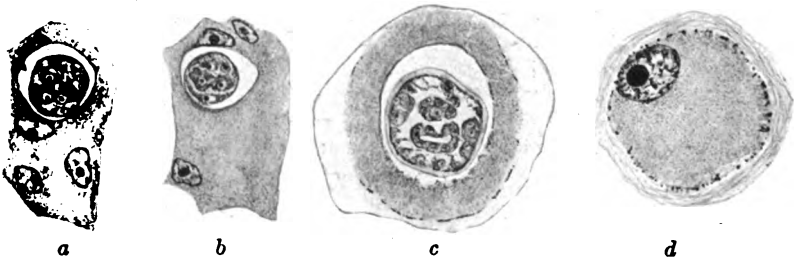


Fig. 159.—Trichiniasis. Successful invasion of muscle-fibers by the trichinella spiralis. *a* and *b*, In a rabbit; *c* and *d*, in human muscle-tissue. Organisms present in *a*, *b*, and *c*, but not in *d*. Longitudinal striations left only at periphery of fiber in *c* and *d*.

the muscles of the body. It is thought by some that trichinæ may occasionally reach the blood more directly by penetrating the blood-vessels in the intestines, but no positive evidence has been offered.

The development and spread of trichinæ in the host are best followed in animals fed with infected muscle, but most if not all steps of the process have been traced in man.




Fig. 160.—Trichiniasis. Two trichinellæ spirales within one muscle-fiber. M.

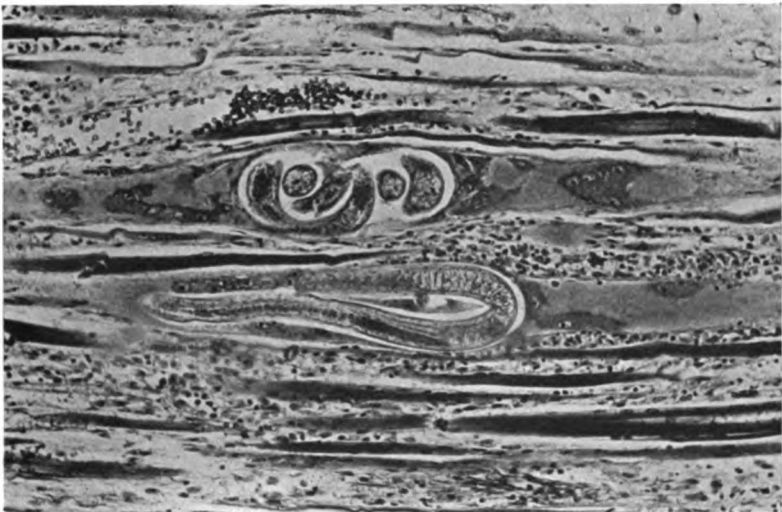

Fig. 161.—Trichiniasis. Two trichinellæ spirales in muscle-fibers. Little inflammatory reaction around them. M.

When trichinæ are carried all over the body by the blood stream they emigrate from the vessels situated not only in muscle-tissue, but in various other locations. Thus they have been found in

numbers in the heart, and occasionally in the liver, pancreas, and brain; further search would probably show them in other organs and tissues. It is only in striated, skeletal muscle-fibers, however, that they find conditions favorable for further development. In other locations, as well as frequently in skeletal muscle, they die or are killed, and each organism becomes surrounded by a focus of acute inflammatory reaction.

Embryo trichinæ emigrating from blood-vessels running through muscle-tissue attempt to penetrate into muscle-fibers. A successful embryo at first lies stretched out straight in the center of the fiber and grows. After reaching its full size in a very few days it curls up in its characteristic spiral attitude, becomes ap-

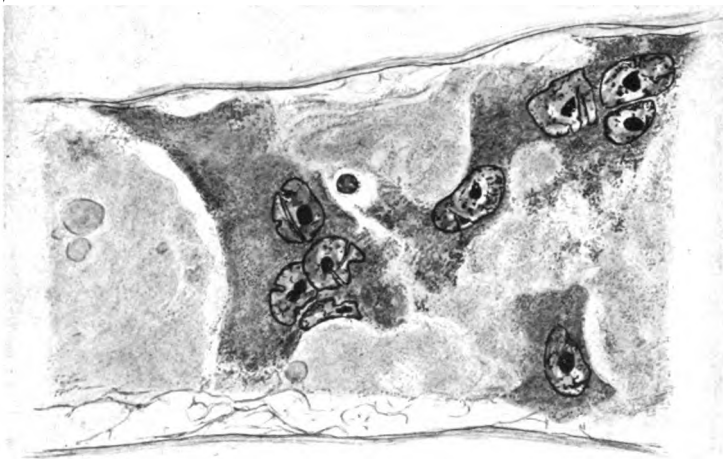


Fig. 162.—Trichiniasis. Part of a muscle-fiber showing portions necrotic and other portions beginning to regenerate.

parently innocuous, and may persist in this condition for years (twenty or more) until death of its host and ingestion of the infected muscle by another host sets it free to continue the cycle of development.

Injury.—The usual effect of an embryo trichina on the muscle-fiber which it has invaded is to cause more or less degeneration. The mere mechanical invasion seems to do little harm. The injury is apparently produced by a soluble toxin eliminated by the embryo trichina during its stage of development. The invaded fiber may become edematous, as shown by hollowing out of its center, or by the formation of numerous vacuoles. The striations may disappear diffusely, or over considerable areas. Sometimes only a

single row is left at the periphery of the fiber. Sometimes the fiber undergoes more or less extensive necrosis either centrally or in scattered patches, or over long stretches. If the whole fiber, or the part in which the embryo lies, becomes necrotic the trichina dies or is killed. Apparently after it reaches a certain size it is too large to invade another fiber.

Regeneration.—As soon as any portion of an invaded muscle-fiber is destroyed the adjoining nuclei in the remaining portion are stimulated to regeneration. They multiply by direct division and extend towards the part destroyed. Even if only a single nucleus with a little cytoplasm is left intact it attempts regeneration. How far the process will progress towards the formation of a whole fiber cannot be determined. The active regeneration occurs not only immediately around the included trichina, but also throughout the fiber wherever injury has been done by the action of the diffusible toxin. Sometimes as the result of the necrosis of a large part of a muscle-fiber several minute fibers, each with one to several nuclei, may be formed to take its place.

Exudation.—A muscle-fiber seems to be the only structure in the body capable of furnishing an asylum of rest and protection to a trichina. Elsewhere it is quickly surrounded by a focus of acute inflammatory exudation and destroyed. The cells of the exudation consist of polymorphonuclear leukocytes, endothelial leukocytes, lymphocytes, and eosinophiles; the latter are sometimes very numerous. Occasionally some of the endothelial leukocytes fuse together around parts of the trichina to form foreign body giant-cells.

Invaded muscle-fibers which are not necrotic usually have little or no inflammatory reaction around them. When, however, as frequently occurs, the fiber is destroyed, the reaction is usually intense. The necrotic muscle is removed by the action of endothelial leukocytes, but the trichina is surrounded and acted upon by the variety of leukocytes mentioned above. Whether the exudation is called out by disintegration of a dead trichina, or is

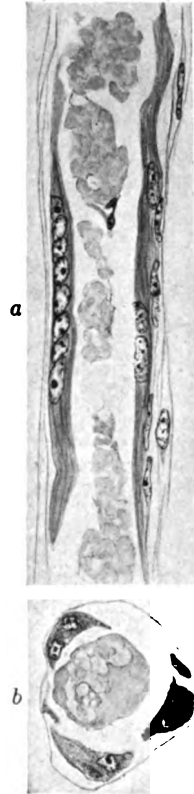

Fig. 163.—Trichiniasis. Regeneration of parts of muscle-fiber not killed. Viewed in *a* lengthwise; in *b* in cross-section. Necrotic portion of fiber still persistent.

attracted by a living trichina whose death it strives to cause, is difficult to determine, but the latter view seems the more probable one.

Capsule.—Soon after a muscle-fiber is invaded by a trichina the connective-tissue cells immediately around that fiber are stimulated to produce an increased number of collagen fibrils.

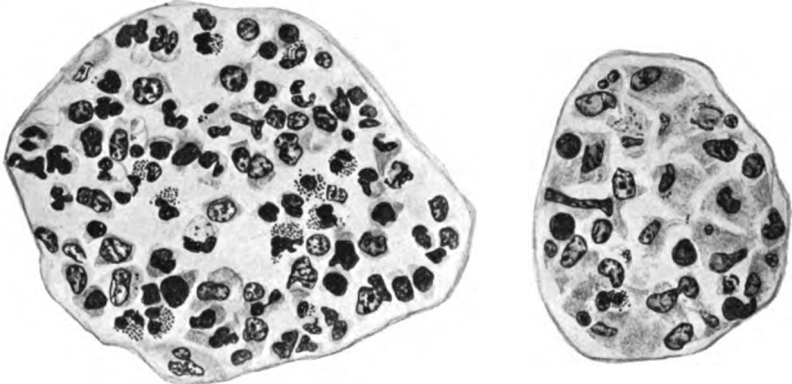


Fig. 164.—Trichiniasis. Inflammatory reaction to necrotic muscle-fibers which have been dissolved and removed. In *a*, it consists chiefly of polymorphonuclear leukocytes and eosinophiles; in *b*, of endothelial leukocytes with a few eosinophiles. The invading trichinellæ are not visible.

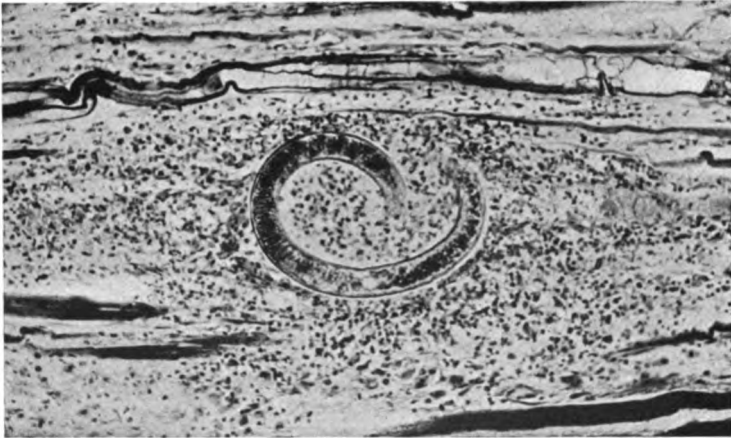


Fig. 165.—Trichiniasis. Acute inflammatory reaction around a trichinella spiralis which killed the muscle-fiber it invaded. M.

Possibly the fibroblasts proliferate to some slight extent. In this way a capsule is formed which gradually thickens and contracts, and usually becomes hyaline. Eventually it may become calcified. This capsule serves as a further protection for the included trichina, but occasionally it is invaded by leukocytes either be-

cause the organism has died, or because they have been attracted by some toxin emanating from it.

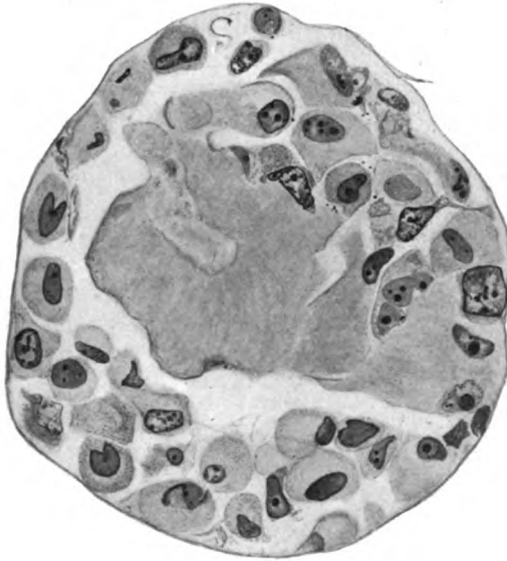


Fig. 166.—Trichiniasis. Muscle-fiber, killed by action of *trichinella spiralis*, being dissolved by endothelial leukocytes.

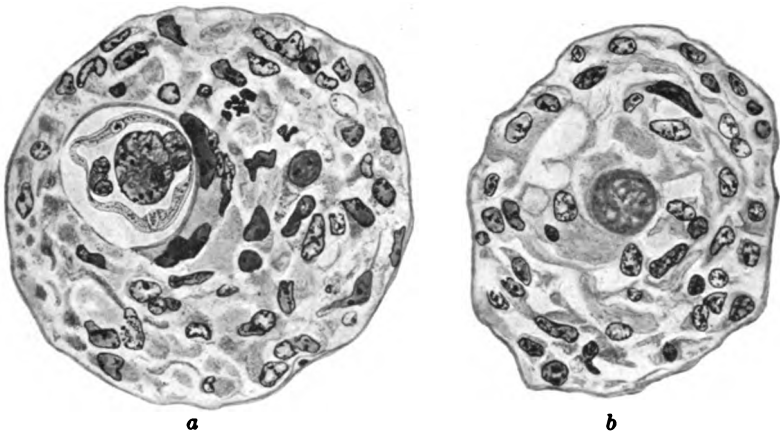


Fig. 167.—Trichiniasis. *a*, *Trichinella spiralis* surrounded by endothelial leukocytes in space previously occupied by a muscle-fiber; *b*, dead *trichinella spiralis* in similar location.

In the heart, brain, and other organs the trichinæ invariably die or are killed, and give rise to small foci of acute inflammatory

exudation. The organisms are gradually dissolved and removed; the exudation disappears, and only small foci of fibrosis or gliosis are left as marks of the lesions to which they owe their origin.

Gross Appearance.—Infection of muscle with trichinæ cannot be detected in the early stages with the naked eye. The embryos are grey and translucent. What one sees and recognizes later on are the whitish connective-tissue capsules around the encysted trichinæ. If these capsules become calcified they are rendered still more prominent.

End Results.—If the body is overwhelmed with embryos, death ensues probably as a result of destruction not only of great numbers of muscle-fibers, but of small foci of tissue in many other

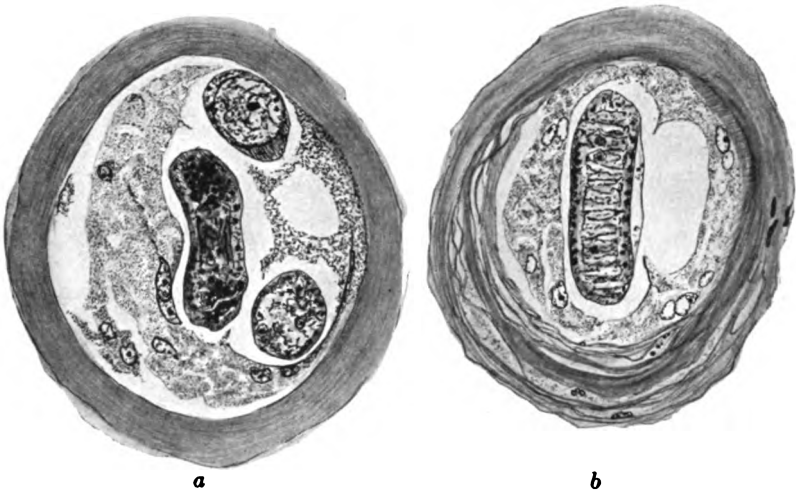


Fig. 168.—Trichiniasis. *Trichinellæ spirales* within thick connective-tissue capsules.

organs, such as the heart, brain, pancreas, etc. In addition, toxins derived from the trichinæ and from the necrotic cells of different kinds must produce some injurious effect. We have some evidence of this in the leukocytosis which accompanies infection, and especially in the eosinophilia which is characteristic and usually amounts to twenty to forty per cent and has run as high as sixty per cent.

Diagnosis.—The only way to make a positive diagnosis of trichiniasis in suspected cases is by demonstrating the embryos, by means of centrifugalization, in the circulating blood, or by cutting out a bit of muscle, usually from the calf of the leg, and demonstrating trichinæ in the muscle-fibers. The adult trichinæ do not appear in the feces; apparently they are destroyed before reaching the rectum.

TUMORS

Introduction.—Tumors play a very important part in pathology and occupy a distinct field by themselves. They occur in great variety; may be inconvenient, disfiguring, or dangerous from size or location; are frequently destructive to the tissues in which they are situated; and often cause death of the individual afflicted with them.

We know a great deal about the gross and microscopic appearance of tumors and in regard to their classification, but nothing in regard to their cause, and little in regard to their origin. Much still remains to be learned. Experimental work on animals is throwing light on certain points, but continued observation and study of tumors occurring in man is likely in the end to be the more profitable line of investigation.

In a way tumors form a class of injurious agents; the tissues involved may react to them as they do to certain kinds of foreign bodies. This statement is particularly true of certain forms of cancer. Yet tumors, with perhaps one exception, the chorion-epithelioma, originate from the host himself, although they may lead to his destruction.

In some respects tumors bear a close relation to abnormalities from which certain new growths unquestionably arise, especially from small persisting and displaced groups of cells known as fetal rests and displacements.

Tumors act as parasites. They draw nourishment and support from the tissue in which they occur and are often hindered in their growth by lack of these factors. But in many ways they are independent of normal tissues, especially in the possession of a greater vitality such as few normal cells can withstand, of continuous growth without physiologic limitation, and of autonomous growth independent of body control.

Definition.—Before taking up the subject of tumors it is necessary to have as exact and comprehensive a definition as possible of what a tumor is, in order to be able to distinguish it from enlargements due to various conditions, such as hyperplasia (lymph-nodes); hypertrophy (prostate, thyroid); exercise of function (lactating breast); regeneration (end of cut nerve); repair (callus); excess of process of repair (keloid); normal growth and development of displaced cells (adrenal displacements, chole-

teatoma); dilatation of obstructed ducts (wen) and of persisting fetal cavities (simple dermoids of neck and over coccyx); infectious tissue formation (verruca).

It is difficult to frame a definition and to make general statements which will apply to all types of tumors.

The term tumor is used in two senses, first, in a general way to mean swelling, its original signification, as when in discussing acute inflammation we speak of the four cardinal symptoms as rubor, tumor, calor, dolor, or of an enlarged spleen of septic origin as acute splenic tumor; second, specifically as a new formation of tissue, a new-growth, or as is often said a true tumor.

In this specific use of the term a tumor is a new formation (usually a more or less circumscribed collection) of cells which proliferate continuously and without control; tend to differentiate as the cells from which they arose would do under normal conditions; serve no useful function; lack an orderly structural arrangement; and have, at least at the present time, no assignable cause for their existence.

TUMOR CHARACTERISTICS

Autonomy.—The most striking of these characteristics of a tumor is its autonomy or independence of growth. It is unlimited and uncontrolled except when its nutrition is interfered with so that necrosis results or, as sometimes happens, especially in cancer, the active stroma by its contraction retards the extension of the tumor.

Normal cells are under control in some way or other. They cease to proliferate after a certain limit of size of organ or need of secretion is reached. The same limited growth of cells and tissues, due probably to a control of chemical nature, becomes evident under various inflammatory conditions, including those of regeneration and repair.

Vitality.—In some respects tumor cells seem to possess greater vitality than normal cells, at least they are able to obtain nutrition and multiply while at the same time the normal cells which are interfered with, atrophy and disappear. Thus, on the one hand a tumor may grow rapidly while the patient is wasting away, or it may infiltrate and destroy an organ.

On the other hand, some tumors at least are more susceptible to x-rays and radium emanations and disappear under their influence while the normal cells persist.

Morphology.—A tumor is an attempt at the formation of a tissue or organ (the simple tumor), or more or less of an entire fetus (the mixed tumor). The results are sometimes very close copies in detail, that is, in the construction of single cells and in

the grouping of cells in acini, but never in gross. In general it may be said that the more the cells differ from the normal in structure and arrangement, the more likely is the tumor composed of them to be malignant.

Function.—So far as physiologic function is concerned a tumor is useless and may even be dangerous. The smooth and striated muscle-cells do not fit into the plan and architecture of the body and cannot be utilized. The bile secreted by a liver cell cancer has no way of getting into the intestinal tract. The colloid material of a thyroid tumor or the internal product of an adrenal tumor needs no duct and can be directly absorbed, but it may prove injurious, or in case of destruction of the organ itself, useful.

Cause.—In the lesions of typhoid fever and usually of tuberculosis, for example, we have a marked diffuse or focal accumulation of endothelial leukocytes which arise largely by proliferation, as is shown by the presence of numerous mitotic figures. This accumulation and multiplication of cells is due to definite causes, the toxins arising from the typhoid and tubercle bacilli. The cells are needed to produce antitoxins to combat the toxins. In the case of the typhoid bacillus the reaction is sharp and quick; it is over in two to three weeks and, if the patient recovers, the endothelial leukocytes disappear quickly because they are no longer needed. In the case of the tubercle bacillus the reaction is usually continuous because not effective.

In like manner we frequently get a proliferation of fibroblasts from at least two definite causes; injury to other fibroblasts (regeneration of connective tissue), and the presence of fibrin (organization of thrombi, etc.). For tumors no such definite cause of proliferation can at present be advanced.

In the past all sorts of causes have been assigned; injury, long continued irritation, bacteria, protozoa. They have all been urged at least for certain types of tumors, and have all been discarded until recently. In the past few years, however, injury, severe or long continued, has come to the front again as a frequent cause of certain types of cancer and possibly of some other varieties of tumors. This change of view is due to the repeated occurrence of carcinoma following excessive exposure to x-rays and radium. A similar formation of carcinoma following exposure to ordinary sunlight occurs rarely in a few very susceptible individuals (melanoderma). The exact manner in which the cancer arises has not been fully determined, but it seems to be due, not to direct stimulation of the epithelium, but to injury done the connective tissue and blood-vessels as a result of which excessive regenerative efforts on the part of the epithelium are called forth. Other

injurious agents may possibly act occasionally in some similar way.

Evidently something starts the cell, which produces a tumor, to proliferate just as a spermatozoön influences an ovum, or as recent experimental work has shown conclusively various chemical reagents may do. Perhaps the solution of the cause of cancer lies along this same line.

Origin.—We know more in regard to the origin of tumors in general than we do in regard to their cause. Many of them unquestionably arise from cells which have become displaced from

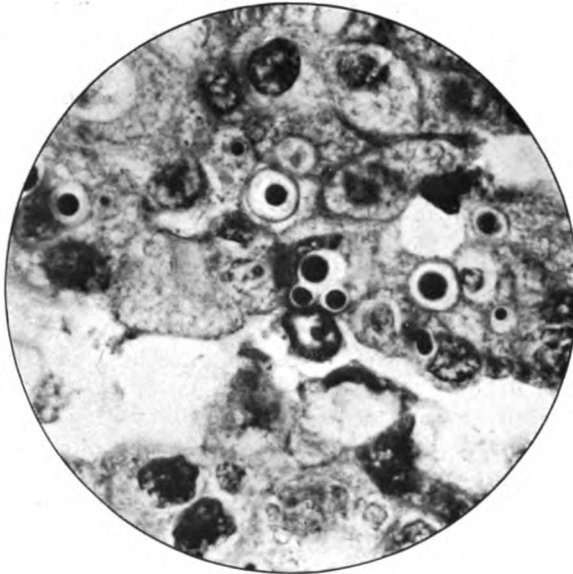


Fig. 169.—Carcinoma of mammary gland. The hyaline bodies are products of secretion or degeneration and were formerly exploited as parasites and the cause of cancer. M. and W.

their normal relations during fetal and postembryonic development, or have persisted into adult life when they should have disappeared after their function in the fetus had been performed.

Still others arise from local tissue abnormalities of various sorts and from fetal inclusions. We can often find examples of fetal rests, displacements, and local tissue abnormalities. The fetal inclusions we assume with confidence because we have, as good evidence, the occurrence of occasional monstrosities in the same locations where the mixed tumors most often arise. These four definite sources of origin of tumors will be taken up separately.

Many of the remaining tumors may arise from the same or similar abnormalities, but at present we are unable to demonstrate them.

Fetal Rests.—Certain structures formed during early embryonic life give rise to various organs and tissues. After they have served their purpose these structures usually disappear entirely or in part. If separate cells or cell groups belonging to these structures persist they are called fetal rests. Various examples may be mentioned: remains of the neural canal over the coccyx, of the branchial clefts in the neck, of the Müllerian and Wolffian ducts in the oviduct and broad ligament, of the notochord at the base of the skull.

A knowledge of fetal rests is important on several accounts. While the majority of them cause no trouble, some of them unquestionably give rise to tumors. They explain the presence of certain types of tumors in situations where they apparently have no right to be, for example, gliomas over the coccyx and at the base of the nose from remains of the neural canal. If the fetal rests are of early embryonic development the cells may differentiate in several ways and give rise to mixed tumors; if, however, the fetal rests were formed at a late stage of development they are capable of giving rise only to simple tumors.

Fetal Displacements.—During fetal development cells or groups of cells are often displaced from their normal relations. Such displacements are especially liable to occur in those places where developmental conditions are complicated and where considerable movement of cell masses normally occurs. A remarkable example of such a condition is presented in the formation of the organs of the abdominal cavity.

Displaced cells tend to develop in exactly the same way as they would have done if they had remained in their normal environments. If the resulting cell masses are small, they are called fetal displacements; if large, they often form secondary organs. Thus we may have accessory spleens, or an accessory pancreas in the wall of the stomach or elsewhere.

The following examples will serve to show the variety of fetal displacements. Displaced adrenal cells are common, not only in the capsule of the adrenal and in the surrounding fat tissue, but also in the kidney and its capsule, along the ureter, the epididymis and elsewhere. Epithelial cells which would normally give rise to epidermis are sometimes displaced into close association with the central nervous system. The desquamated product of their growth forms rounded pearly masses of cornified epithelium, which have been regarded as tumors (cholesteatomas). Fat-cells also are sometimes displaced into the cerebrospinal canal. The result of the normal development of such a fat-cell is not a lipoma

but a fetal displacement. Cartilage cells are sometimes displaced in postembryonic time as the result of rickets and may continue to grow as they would have done under normal conditions. The result is an abnormality (*exostosis cartilaginea*), not a tumor.

Displaced cells cannot always be found or seen: because of later occurrences we judge them to have taken place. For example, an osteosarcoma of the breast is probably due to displaced periosteal cells from an underlying rib.

Local Tissue Abnormalities.—This term includes both fetal rests and displacements, but is applied here to such minor deviations as result, for example, from excess of fetal development of some particular kind of cell. Thus we have congenital nevi due to overgrowth of vascular endothelium or of chromatophores, and

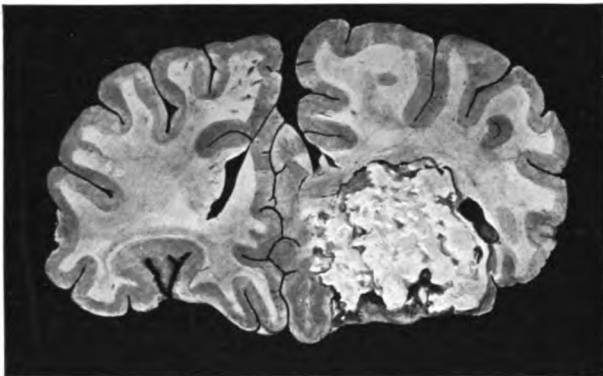


Fig. 170.—Cholesteatoma. A mass of cornified epithelial-cells which has been slowly formed and pressed into the brain.

molluscum fibrosum from excessive growth of fibroblasts in the corium.

From the congenital vascular nevi the different forms of hemangio-endothelio-blastoma usually, in fact apparently always, arise while the melano-blastoma frequently has its origin in a congenital pigmented mole.

Fetal Inclusions.—The occurrence of teratomas in certain situations can be explained only on the assumption that within one fetus there has been included a cell which could have formed another fetus. This view is favored by the occurrence of monstrosities frequently in the same situations, as over the coccyx, for example.

Tumor-like Formations.—A variety of tumor-like formations occur which must be carefully distinguished from the tumors.

To do so with certainty is not always easy. A few illustrative examples are given.

From Fetal Rests.—A branchial cleft of the neck persisting as a sinus is an abnormality. If both ends of the sinus are closed the cavity may be dilated into a cyst by the accumulation of secretions. In this way there is formed a *simple dermoid cyst* which is not at all a true tumor. Simple dermoid cysts may be formed in a similar way in other parts of the body where epithelial-lined surfaces are united during fetal development; for example, over the coccyx, in the orbit, etc.

Simple cysts may be formed by dilatation of remains of the Müllerian, Wolffian and other ducts.

From Fetal Displacements.—Displacement of epidermal cells into close relation with the central nervous system, and their development as if they had remained in their normal location, leads occasionally to the formation of single and multiple pearl-like bodies due to the piling up of cornified epithelial cells. These bodies are termed *cholesteatomas* and were long regarded as true tumors. From such a cell-displacement an epidermoid carcinoma might arise; that would be a true tumor.

Displaced adrenal cell masses, if of considerable size, are sometimes regarded as adenomas. It is not always easy to decide on their exact nature.

From Pathologic Processes.—Obstruction of the mouth of the duct of a sebaceous gland often leads to marked dilatation of the duct. The result is a cyst lined with epidermis and known clinically as a wen. Wens like simple dermoids are sometimes mistaken for true tumors. They have no relation to the true teratomatous dermoid cysts occurring in the ovary, testicle, and occasionally elsewhere.

Organization of a fibrinous exudate in the peritoneal cavity sometimes results in a multiple cystic formation which has been mistaken for a tumor (endo- or mesothelioma). The cysts are lined with mesothelium derived from mesothelial cells which had not been destroyed: these cells have proliferated and lined the serum-filled spaces present in the fibrin while it was undergoing organization by fibroblasts.

Regenerative efforts on the part of a severed nerve lead to a tumor-like formation often called an amputation neuroma.

The lesion underlying a hypertrophied prostate may be interpreted as an adenoma or as glandular hyperplasia often combined with more or less dilatation of the lumina of the acini.

The tissue masses formed as the result of the reaction to the *treponema pallidum* and the tubercle bacillus, for examples, may occasionally be easily mistaken for true tumors on gross examina-

tion. The terms syphiloma and tuberculous granuloma are occasionally applied to such lesions.

The infectious lesion of the skin called molluscum contagiosum resembles to some extent an epidermoid cancer, and the coccidium oviforme produces in the bile ducts of the rabbit's liver the typical structure of a papillary cystoma.

Manner of Growth.—Tumors grow entirely by multiplication of their own cells, not by the transformation of normal cells into tumor cells. In the past the exact nature and diagnosis of many a tumor has been based on the statement that it has been possible to trace every gradation from normal cells to tumor cells. This

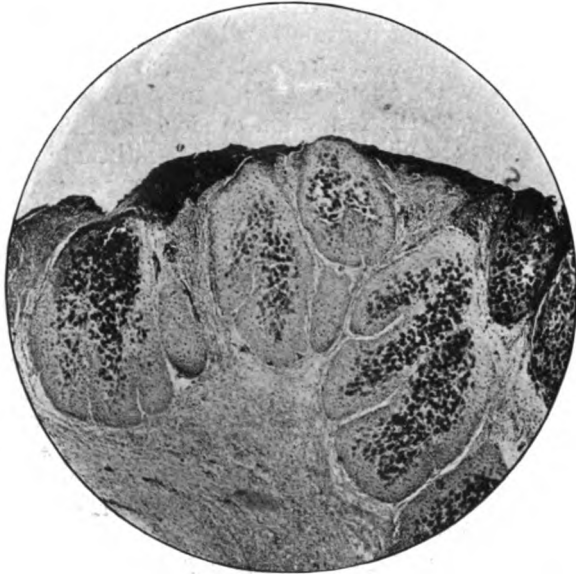

Fig. 171.—Molluscum contagiosum. M. and W.

claim has been made especially for new-growths of the uterus in the attempt to demonstrate that certain rapidly-growing, infiltrative, spindle-cell tumors were rapidly-growing leiomyomas as they probably were. The arguments, however, were founded on incorrect observation, interpretation and deduction; they should have been based on cell differentiation.

So far as exact observation goes at the present time all active tumor cells multiply entirely by indirect division, that is by mitosis. This statement does not deny that degenerating tumor cells may not occasionally divide directly by amitosis.

Tumors grow in two ways: by expansion and by infiltration; the two types of growth are often combined.

In growth by expansion the tumor cells are said to grow in a solid mass shoving the normal cells before them. This statement is not entirely true because blood-vessels and more or less connective tissue, enough to furnish a blood supply and physical support for the cells, always remain in the tumor and develop with it. But the other cells are pushed back and the parenchymal cells (liver- and muscle-cells for instance) are compressed so that they atrophy and disappear. The connective-tissue cells, however, persist as a fibrous capsule around the tumor and may even increase in number. This type of growth is characteristic of benign tumors (lipoma, fibroma, etc.).

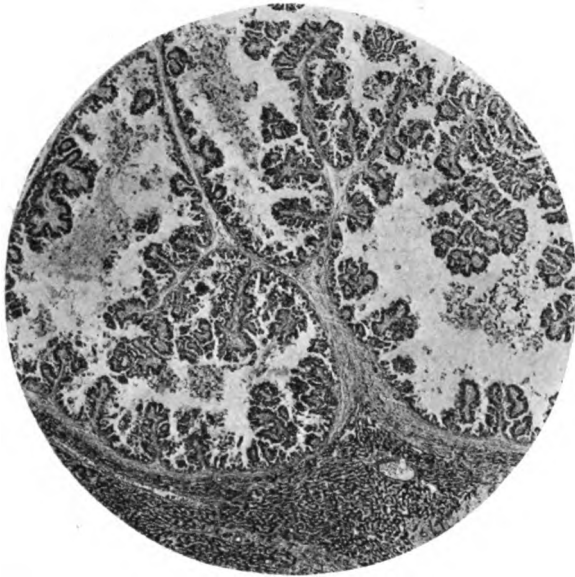

Fig. 172.—*Coccidium oviforme* in bile duct of rabbit's liver, causing the formation of papilliferous cyst. M. and W.

In growth by infiltration the tumor cells penetrate between the cells of the tissue in which they arise. As a rule, owing to their greater vitality, by pressure and by using up the nutrition, they lead to necrosis or atrophy and disappearance of the parenchymatous cells; only the connective-tissue cells and the blood-vessels ordinarily persist in the end.

When tumor cells grow in between the tissue cells they lie in the lymph-spaces which surround all cells. The tumor cells may extend in this way so gradually and uniformly that the tumor is sharply defined and looks as if it were growing by expansion.

In other instances a tumor will spread out very extensively and diffusely, or will extend very rapidly in one or another kind of tissue and present little of the appearance we ordinarily associate with a new-growth. Thus in one instance a glioma of the lumbar cord reaching the pia spread in it the entire length of the cord and over the brain, presenting an appearance which was at first mistaken for an organizing or a tuberculous meningitis. In other instances tumors will grow into cavities (alveoli of lung, uterus), and ducts (mammary gland), or into lymphatics and blood-vessels, and extend along them, adapting themselves more or less perfectly to the natural cavities. Tumors may thus branch in various

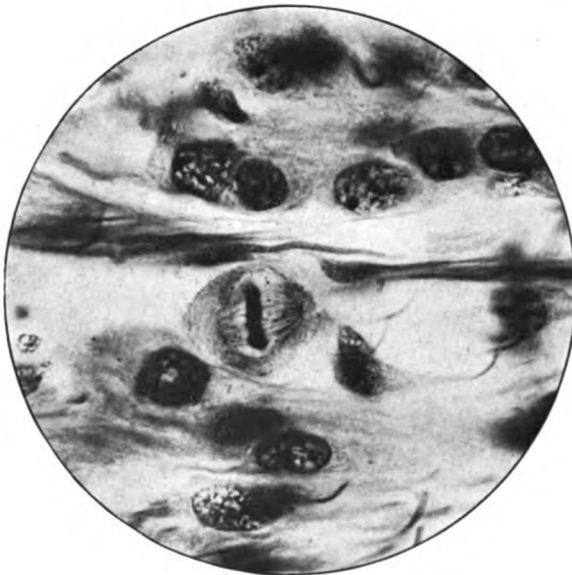

Fig. 173.—Glioma over coccyx. Mitotic figure. M. and W.

directions and extend over a large amount of space and yet the cells may all remain in direct continuity, a part of the original primary tumor (cavernous hemangio-endothelioma).

Structure.—All tumors consist of two parts: of the tumor cells and their products, and of the stroma. The tumor cells form the parenchyma and as distinguished from the stroma are the true essential part. The stroma is entirely secondary and is furnished by the surrounding tissue. It is common to all tumors. Its cells are not tumor cells although it is sometimes difficult to distinguish them everywhere from the tumor cells, especially in a fibroma or fibrosarcoma because the nature of the two kinds of cells is identical.

On the other hand, it is easy in the case of a glioma, especially of the dense slow-growing type, because by special staining methods it is possible to make the different types of cells and their fibrils stand out in marked contrast.

Tumor Cells.—The true tumor cells tend to differentiate in exactly the same way as do the normal cells to which they correspond. In slow-growing tumors the differentiation may be perfect. In rapidly-growing tumors the cells may depart so widely from the model that it cannot be recognized. The nuclei often show much variation in size and are often larger than in the normal

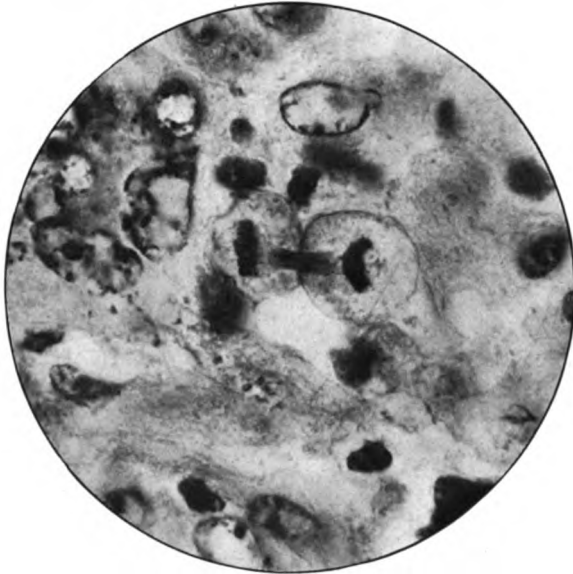


Fig. 174.—Carcinoma of mammary gland. Mitotic figure in last stage of division. M. and W.

cells. The tumor cells themselves frequently exhibit marked differences both in size and in shape.

Mitosis.—Rapidly-growing tumor tissue offers very favorable material for the study of cell proliferation because the mitotic figures are often exceedingly numerous, and the tissue can usually be obtained in a perfectly fresh condition at the operating table and placed at once in thin sections in any fixative desired.

Multiple mitoses are not infrequent: two, three or four spindles are common and they may number dozens or even run up to a hundred or more, giving rise to giant-cells of various sizes with few to many nuclei. Such true tumor giant-cells have been found,

for example, in the following types of tumor: fibrosarcoma, glioma, lymphoblastoma, carcinoma.

Multiple mitoses are not necessarily diagnostic of tumor growth because they occur as well in various inflammatory and reparative processes.

Stroma.—The stroma of tumors ordinarily consists, like that of the glandular organs, of connective tissue and blood-vessels. It may be newly formed or consist of the existing stroma of the organ or tissue in which the tumor is situated, or it may be a combination of the two. The amount of stroma varies greatly in dif-

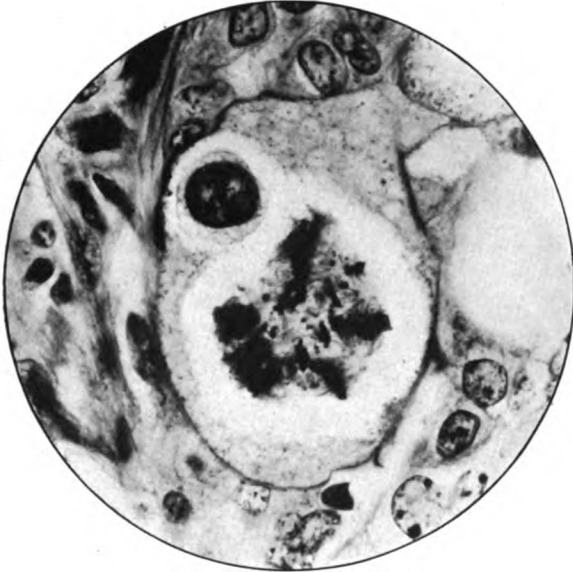

Fig. 175.—Carcinoma of mammary gland. Multiple mitosis. A lymphocyte is included within the cell. M. and W.

ferent tumors. It may be slight and scarcely demonstrable or more abundant than the tumor tissue itself.

We can best assure ourselves that the blood-vessels and connective tissue are newly formed in the case of encapsulated tumors and of those which grow above surfaces and into ducts. When a tumor infiltrates, the preëxisting vessels and connective tissue may be all-sufficient and no new ones may be formed, or they may be stimulated to active proliferation.

The nature of the stroma, its arrangement and structure, depend to a considerable extent on the tumor cells. Wherever a breast cancer metastasis takes place (lymph-node, bone marrow)

the stroma formed is usually abundant and often resembles that seen in the healing of wounds. Wherever the cells of a lymphoblastoma are carried, a connective-tissue reticulum is usually formed for them. The slow-growing varieties, however, often lead to the production of abundant fibrous connective tissue.

Tumor cells seem unquestionably to incite in some way a proliferative activity on the part of the fibroblasts. Some kinds of cells exert a greater influence than others. In general it may be said that tumor cells obtain about the same amount of connective tissue as subtends normal cells of the same kind. For example, in the epithelial tumors, the epithelium of the mammary glands and ducts are subtended by a large amount of connective tissue. The epithelial tumors of the breast cause an abundant connective-tissue stroma to be formed. This is best seen when metastases of cancer take place into the axillary lymph-nodes or into the bone marrow. On the other hand, the adrenal contains very little connective tissue and tumors of the adrenal cause the production of very little connective tissue. The same is true of the chorion-epithelioma.

Of course rapidity of growth plays some part. The connective tissue is always better developed in the slower growing tumors of any given type. In the ordinary leiomyoma every muscle-cell is surrounded by collagen fibrils produced by fibroblasts which accompany the blood-vessels and spread between the muscle-cells. To a considerable extent the collagen fibrils are the cause of the denseness and toughness of these tumors. In those which grow rapidly little or no stroma is formed and the tumor is soft and easily teased apart.

While the connective tissue of the stroma is usually fibrous in character, occasionally it is mucous. Rarely in tumors involving bone the fibroblasts of endosteal and periosteal origin are osteoplastic, that is, produce bone owing to some chemical effect of the tumor cells upon them.

If the tumor grows slowly the blood-vessels are well formed, with muscle-cells and fibroblasts to strengthen the walls of the larger vessels. If growth is rapid the vessels may consist of only a single layer of endothelial cells and be so thin and delicate that hemorrhages followed by necrosis take place readily. The blood-vessels may vary greatly in number and in size. For example, a rapidly-growing leiomyoma of the uterus was like a coarse sponge in structure owing to the large size and number of the blood-vessels, and collapsed to half its volume when cut into. Such a tumor is not an angioleiomyoma but simply a very vascular rapidly-growing leiomyoma.

The stroma of a cancer, especially of the breast, often suggests

scar tissue, as if it had resulted from an inflammatory reaction. When an epidermoid carcinoma of the skin first starts there is usually marked inflammatory reaction adjoining it: infiltration with lymphocytes and plasma cells occurs, occasionally a few eosinophiles are present and there may be active proliferation of fibroblasts which are sometimes to be found in mitosis.

Retrograde Metamorphoses.—Tumors are subject to many of the retrograde changes which affect normal tissues, such as necrosis, the accumulation of fat in the cells and intercellular substances, calcification, hemorrhage, pigmentation and hyaline change of the connective-tissue stroma. To these changes they react as do the normal tissues: necrosis may call out an inflammatory exudation; fat often leads to the emigration of large numbers of endothelial leukocytes which take up the fat in their cytoplasm. Sometimes the stroma is packed with these cells. At other times mastcells are present (leiomyoma of uterus) and eosinophiles sometimes occur in great numbers (carcinoma of cervix uteri, scirrhus type of lymphoblastoma).

Following hemorrhage the red blood-corpuscles are taken up by endothelial leukocytes and transformed into hemosiderin, causing a type of pigmentation sometimes called false melanosis.

When a tumor adjoins a surface, necrosis often results in extensive ulceration. This condition is seen most often in carcinoma involving the gastro-intestinal tract.

Tumors are frequently exposed to bacterial invasion. They react just as do the normal tissues. The blood-vessels and their contents and the stroma are similar in the two kinds of tissues. The tumor cells may undergo necrosis, but they do not interfere with an inflammatory exudation taking place.

Gross Characteristics.—In describing the gross appearances of tumors it is customary to consider size, shape, color and consistence. Of these qualities, color and consistence alone are more or less characteristic in the case of certain tumors. Thus black is fairly diagnostic of a melanoma, green of myeloblastoma nodules, red to purple of a hemangio-endothelioma, and the consistence of a chondroma or of an osteoma is quite characteristic.

The gross appearance of a tumor, while often very suggestive, should never be considered as absolutely diagnostic. The diagnosis should always be based on cell differentiation and cell arrangement as seen under the microscope.

Size.—Tumors vary greatly in size, from microscopic collections of cells to masses weighing more than the individuals possessing them. Large tumors are not so common nowadays as formerly because people are recognizing more and more the importance of having them removed early.

The size of tumors depends in general on two factors, namely, on rapidity and on duration of growth. Sometimes, as in the case of a scirrhus carcinoma, they represent an actual loss of substance owing to infiltration and destruction of the normal tissue, followed by contraction of the stroma. Necrosis and ulceration may likewise lead to much loss of the normal tissue as well as of the tumor.

Shape.—The shape of tumors in general tends to be spherical, especially when they grow expansively (fibroma, lipoma), but also often when they infiltrate (cancer, glioma). Many other forms occur, however, and various descriptive terms, most of which are self-explanatory, have been applied, such as the following: nodular, lobulated, tuberous, polypoid, papillary, racemose, fungoid, cauliflower-like. The different forms depend to some extent on the vascular supply, on the presence of obstructions which prevent growth in certain directions, and on the tendency of all tumors to adapt themselves more or less to the form of pre-existing cavities (ducts, blood-vessels, spinal canal, etc.).

Color.—The color of tumors, like that of normal tissues, depends on microscopic conditions. Cells massed together are in general gray and translucent. This condition, best seen in a fibrosarcoma, is generally compared to fish flesh. It may be altered in various ways.

Fat present in the form of small droplets in the cells reflects light in all directions; as a result the tissue appears opaque white to yellow. Fat is commonly present here and there in many tumors, but especially in cancer, owing to interference with the nutrition of the cells.

Necrotic cells appear opaque white to yellow owing to some chemical change. As a rule they also contain fat.

Elastic fibrils are sometimes present in masses in cancer of the breast and appear to the naked eye as small yellow areas.

If a tumor is vascular and the vessels congested the blood may so mask the tissue that its real nature will be overlooked; for example, a vascular lipoma may be mistaken by the surgeon for a sarcoma. Blood escaping from the vessels may cause a variety of colors, red, brown, or black, and give rise to a false melanosis which can be demonstrated by the reaction for iron.

Edema, if the fluid is amber colored, may cause a fibroma to look like a lipoma, but the knife cutting it is not greased.

The green color of myeloblastoma nodules fades rapidly on exposure to air but may be restored quickly, but only temporarily, by treatment with peroxide of hydrogen.

Cancer nodules in the liver are sometimes stained greenish by bile.

Melanin, the pigment of the melanoma, is a product of meta-

bolism of the chromatophores and appears microscopically in the form of minute brownish granules.

Consistence.—The consistence of some tumors depends on the amount and character of the intercellular substance produced by the tumor cells (fibroma, glioma, osteoma); of others on the amount and character of the stroma (carcinoma, leiomyoma, lymphoblastoma). It varies within wide limits, from the delicacy of a rapidly-growing sarcoma to the ivory-like density of an osteoma durum.

Recurrence.—When there is failure to remove all of a tumor the part left behind, if it be only a single cell, will continue to multiply until another tumor mass is formed. This is termed a recurrence. The danger of recurrence is so well recognized nowadays that surgeons usually remove a wide margin of apparently normal tissue around a tumor to avoid any risk. This is particularly true of cancer because it infiltrates the surrounding tissue so far, and so readily invades and extends along lymphatics. However, the surgeons not infrequently fail either because the original tumor has infiltrated farther than they suspected, or because they were unable or unwilling to remove as large a zone of normal tissue as was desirable. Occasionally a malignant tumor shells out so easily that infiltration of the surrounding tissue is not suspected. In the older days it was not uncommon to cut into the tumor during the operation and so inoculate the wound. Finally an apparent recurrence may be due to metastasis in the immediate neighborhood of the original tumor.

Under this same heading must be mentioned the apparent recurrence of keloid after removal. This is a tumor-like growth due to excessive proliferation of connective tissue, usually, perhaps always, associated with repair of the corium following injury. Removal of the tumor repeats the injury and leads to a like formation. In one case removal of the apparent recurrence led to a second return and probably the process could have been repeated indefinitely.

Metastases.—When tumors grow from the beginning within vessels or cavities or invade them, cells or masses of cells may be set free and be carried to other points within the vessels or cavities and there continue to grow and to proliferate. A secondary growth arising in this way, entirely apart physically from the original or primary tumor, is called a metastasis. Metastases occur most commonly by way of the lymphatics, less frequently through the blood-vessels, and only to a comparatively moderate extent within cavities lined with epithelium. Some tumors metastasize most often by way of the lymphatics (carcinoma, lymphoblastoma); others by the blood-vessels (myeloblastoma, melanoma); a few

in all three ways. Some tumors metastasize so quickly and early that they are often claimed to be of multiple origin (myeloma, lymphoblastoma).

The cells of a tumor may get into blood or lymph-vessels or into epithelial lined cavities in several ways:

(a) By direct migration of the tumor cells into vessels (lymphoblastoma, myeloblastoma).

(b) By the growth of the tumor into vessels or cavities whereby cells or groups of cells may be set free (cancer, melanoma).

(c) By rupture of a tumor growing within a cavity (papillary adenocystoma).

(d) By cells being set free or transplanted (inoculated) at a surgical operation.

Cells set free within blood-vessels are usually carried along by the circulation until they block a capillary or a small artery. Within veins they may be stopped by valves. Then if conditions are favorable they proliferate and form secondary nodules. Metastases develop much more often in some organs and tissues than in others. Conditions of a chemical nature probably play an important part.

Cells within lymphatics are likewise carried along until they meet with obstruction, usually within lymph-nodes.

If tumor cells enter the blood stream, metastases are most likely to form in the liver and lungs; but cancers of the prostate and breast are prone to have metastases develop in the bone marrow. A melanoma is likely to give rise to secondary nodules in many organs and tissues, including heart, skin and gall-bladder.

Metastases by way of the lymphatics are naturally of most common occurrence in lymph-nodes, although sometimes they develop extensively within the lymph-vessels themselves, as in the lungs, for example.

Metastases by transplantation within an epithelial-lined cavity are most common in the peritoneal cavity. Apparently the cells simply plant themselves on the surface and develop; later a stroma is furnished them from the underlying tissues.

Metastases usually occur in the direction of the current of blood- and lymph-vessels; rarely in a retrograde direction; for examples; in lymph-vessels from the breast to the axillary lymph-nodes; from over the sacrum to the inguinal lymph-nodes; and from the abdominal cavity by way of the thoracic duct to the blood stream and into the lungs.

Metastases by way of the blood follow the peculiarities of the circulation; from the stomach and much of the intestinal tract to the liver; but from the rectum as well as from the uterus to the lungs.

From primary metastases in the lungs, cells may be set free and form secondary metastases in various parts of the body.

Tumor cells may pass through the capillaries of the lungs and develop elsewhere in the arterial circulation; or develop in the same way after passing through an open foramen ovale.

While metastases usually develop rapidly cases are on record where they were not evident until after many years.

The stroma of a metastasis is furnished entirely by the tissue in which the tumor cells proliferate.

Malignancy.—A tumor is often said to be malignant or benign according as it endangers or not the life of the individual possessing it. There is a clinical as well as a pathologic use of these descriptive terms and the two forms of usage do not entirely harmonize.

Clinically any tumor is malignant which destroys life whether it grows rapidly or slowly, and whether it infiltrates surrounding tissue and gives rise to metastases or not. From this point of view certain kinds of tumors are invariably malignant because they are destructive of important organs (most types of cancer); others are so usually (dural endothelioma); or only occasionally (fibroma of epiglottis, or nasopharynx) owing to the location in which they grow.

From the pathologic point of view the term malignancy is not easy to define in exact terms. The usual characteristics assigned are rapidity of growth, infiltration (and consequently destruction) of surrounding tissues and the formation of metastases. Some malignant tumors possess all these characteristics; others only one or two of them.

Rapidity of growth is a common but not necessary characteristic. Some cancers grow with marked slowness, yet infiltrate and give rise to metastases, and eventually, after many years, cause death. On the other hand, some tumors cause death in months or even weeks.

Infiltration of surrounding tissues is usually regarded as a sure sign of malignancy, yet one type of tumor, the hemangio-endothelioma, always infiltrates (fat- and muscle-tissues and nerves especially) and yet is not ordinarily regarded as malignant, and almost never gives rise to metastases.

The formation of metastases is, perhaps, the most important evidence of malignancy, although rarely or never exhibited by certain types of tumors. For example, glioma of the central nervous system is an infiltrative, malignant tumor which sometimes spreads far by direct extension, but only one case of metastasis is on record. On the other hand, a glioma arising over the coccyx from fetal remains of the neural canal gave rise to metastases in the lymph-nodes of both groins.

Slow-growing chondromas occasionally invade blood-vessels and give rise to metastases. Likewise a slow-growing leiomyoma may metastasize.

Tumor cells are not in themselves malignant. They possess in some respects greater vitality than many normal tissue cells and usurp their nutrition; in this way and by pressure due to more rapid growth they destroy the normal cells, but biologically they are of the same nature.

Multiplicity.—Some tumors are not infrequently multiple at the start. There may be dozens of them, rarely hundreds to thousands.

Leiomyomas of the uterus are often multiple, several to a dozen or more. Rarely they occur in large numbers in the skin.

Fibromas, usually of congenital origin, sometimes number hundreds to thousands in the skin and along the peripheral nerves.

Lipomas are sometimes multiple.

Some tumors metastasize so early that they appear to be of multiple origin (myeloma, lymphoblastoma).

A cavernous hemangio-endothelioma may apparently be multiple owing to its forming a number of nodules, but the nodules always appear in chronologic order and are really all connected together by direct extension of the tumor through blood-vessels. The nodules represent simply local developments of the primary tumor itself.

A few tumors of congenital origin are often or usually double; neuroblastoma of the eye; mixed tumor of the kidney.

Heterogeneous Tumors.—Occasionally an individual will have at the same time two or more tumors of different character, for example, coincident leiomyoma and carcinoma of the uterus, or two different types of carcinoma. Two unusual cases, seen personally, are worth citing.

1. 05.150. Male, aged fifty-one years; death from rupture of esophageal vein secondary to cirrhosis of the liver. Carcinoma (malignant adenoma) of colon. Papillary adrenal tumor of kidney. Adenoma of kidney.

2. 04.41. Female, aged seventy; death from bronchopneumonia. Adenoma of left adrenal gland. Leiomyoma of uterus. Fibroma of ovary. Rapidly-growing leiomyoma of broad ligament. Adenomas of liver. So-called cavernomas of liver.

Differentiation of Normal Cells.—In order to understand something about the different varieties of tumors and how they may be distinguished more or less positively from one another, it is necessary to know as much as possible of the development and differentiation of normal cells.

As is well known, every individual higher organism starts

from a single cell, the fertilized ovum. This cell multiplies by mitosis and gives rise to three layers of cells known as the epiblast, the mesoblast and the hypoblast. The cells of these three layers undergo further multiplication. They also undergo a process of development or, better, of differentiation in consequence of which various types of cells are produced according to the function they are to perform later. These different types of cells can be distinguished from one another by the possession of certain characteristic morphologic features. One cell is characterized by the development of peculiar structures within its cytoplasm (striated muscle-cell, eosinophile); another cell produces fibrils possessing peculiar staining properties (neuroglia cell); another cell secretes and surrounds itself with an intercellular substance which distinguishes it from all other cells (fibroblast, cartilage cell). But once a cell has reached a certain degree of development it cannot retrogress and give rise to cells of other types, derived from cells which have differentiated in other ways.

This can be stated in another way by saying that after the three germ layers are formed, the cells of one layer cannot give rise to the differentiated cells produced by the other two layers; for example, the cells of the mesoblast cannot produce the neuroglia cells derived from the epiblast.

Type Cells.—There occur in the human body some fifteen different distinct varieties of cells, giving rise to tumors, which may be denominated type cells. Some of these cells are very sharply characterized so that they are readily recognized (fibroblast, neuroglia cell); others are recognized with more or less difficulty (endothelial cell, lymphocyte). Some of these cells occur in more than one form and stage of development (endothelial cell, endothelial leukocyte; lymphoblast, lymphocyte, plasma cell; myeloblast, myelocyte, neutrophile, eosinophile, etc.). There are other type cells which seem not to give rise to tumors (erythroblast, megakaryocyte).

Each of these fifteen type cells gives rise to a series of tumors which grow at various rates of speed. All gradations occur between the slowest and fastest growing. With some of the tumors the two extremes in rate of speed of growth are recognized by different names assigned accordingly (fibroma, spindle-cell sarcoma); with other tumors one name usually includes all rates of speed (glioma, lipoma, melanoma, neuroblastoma).

The list of type cells and of the tumors arising from them follows.

SIMPLE TUMORS

<i>Type cell</i>	<i>Name of tumor and what it includes</i>
1. Fibroblast (connective-tissue cell).	Fibroblastoma (fibroma, fibrosarcoma).
2. Myxoblast (mucous connective-tissue cell).	Myxoblastoma (myxoma, myxosarcoma).
3. Chondroblast (cartilage cell).	Chondroblastoma (chondroma, chondrosarcoma).
4. Osteoblast (bone cell).	Osteoblastoma (osteoma, osteosarcoma).
5. Lipoblast (fat-cell).	Lipoblastoma (lipoma).
6. Leiomyoblast (smooth muscle-cell).	Leiomyoblastoma (leiomyoma, leiomyosarcoma).
7. Endothelioblast	Endothelioblastoma.
(a. blood-vessel endothelium.)	(a) hemangio-endothelio-blastoma (hemangioma, angioma).
(b. lymph-vessel endothelium.)	(b) lymphangio-endothelio-blastoma (lymphangioma).
(c. dural endothelium.)	(c) dural endothelio-blastoma (dural endothelioma).
8. Lymphoblast (lymphocyte).	Lymphoblastoma (lymphosarcoma, malignant lymphoma, lymphatic leukemia).
9. Myeloblast (myelocyte).	Myeloblastoma (myelogenous leukemia, chloroma).
10. (myeloma).
11. Melanoblast (pigment cell).	Melanoblastoma (melanotic sarcoma, melanoma).
12. Rhabdomyoblast (striated muscle-cell).	Rhabdomyoblastoma (rhabdomyoma, rhabdomyosarcoma).
13. Glioblast (neuroglia cell).	Glioblastoma (glioma, gliosarcoma).
14. Neuroblast (nerve-cell).	Neuroblastoma (neuroma).
15. Epithelioblast (epithelial cell).	Epithelio-blastoma (adenoma, papilloma, carcinoma).

Differentiation of Tumor Cells.—Tumor cells tend to differentiate as the cells from which they arise would do under normal conditions. For example, a leiomyoma, a smooth muscle tumor, arises from the proliferation of a smooth muscle-cell or of a cell which, under normal conditions, would have produced smooth muscle-cells.

If the growth of the tumor is slow the differentiation of the cells may be as perfect as in normal tissues although as a rule it is not. When the cell multiplication is rapid the differentiation of the cells is less marked and may be entirely wanting except, perhaps, in some part where nutrition is less favorable and growth is less rapid.

The study and recognition of the differentiation of tumor cells are exceedingly important, for on the differentiation depends the exact diagnosis of the various kinds of tumors. At present certain

loose indefinite terms such as *spindle-cell sarcoma*, *round-cell sarcoma*, *perithelial angiosarcoma* are much in use; they should be given up so far as possible. The use of them indicates lack of exact knowledge. Such general terms are permissible only when the rate of growth is so rapid that cell differentiation does not take place and an exact diagnosis is impossible. Such a condition rarely obtains. These terms signify only shape of cell or type of growth, features which are not characteristic of any one type of tumors. For example, a tumor with spindle-shaped cells may prove, on careful examination, to be any one of the following new-growths: fibrosarcoma, chondrosarcoma, osteosarcoma, melanoma, leiomyoma, glioma, rhabdomyoma, hemangio-endothelioma or neuroblastoma.

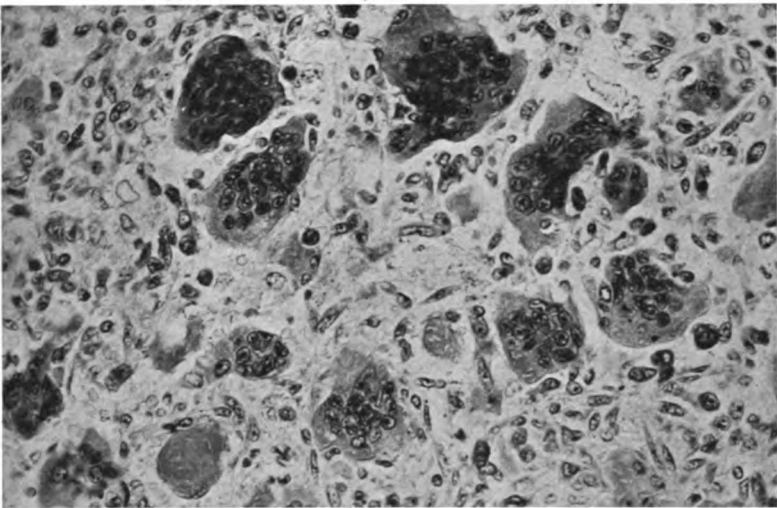


Fig. 176.—Fibrosarcoma of bone containing numerous foreign body giant-cells.
M.

Similarly a tumor with round cells may be demonstrated to be a lymphoblastoma, melanoma, myeloblastoma, myeloma, neuroblastoma, osteosarcoma, chondrosarcoma or leiomyoma.

A perithelial angiosarcoma is not a peculiar type of tumor, but a form of growth dependent on malnutrition. Cells at a distance from blood-vessels receive less nutrition and readily undergo necrosis, dissolution and absorption. Owing also to lack of nutrition no exudative or reparative processes occur. The vessels are thus set free from each other with only a sheath of tumor cells around them. In consequence they often may be drawn out in threads like the tubules of the normal testicle of the

adult. Such a type of growth is not infrequent in any of the following tumors: melanoma, neuroblastoma (of the retina) and fibrosarcoma, and may occur in glioma and carcinoma (breast, skin).

Psammoma is a term often applied to tumors containing calcified hyaline concretions. Such sand-like material may occur in a variety of tumors: for example, dural endothelioma, carcinoma of ovary, carcinoma of antrum of Highmore. Such tumors should be classified according to the type of cell composing them, not named from some accidental calcified product of secretion or retrograde process.

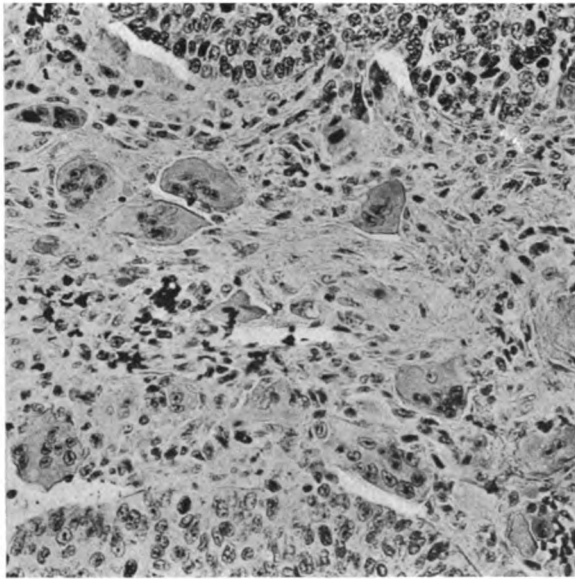


Fig. 177.—Foreign body giant-cells formed in stroma of metastatic cancer in bone marrow. M.

Giant-cell sarcoma is another term which is misleading and should be abolished. At least two types of giant-cells occur in tumors. One type results from multiple mitoses and signifies rapid growth. It is a true tumor cell with characteristics like the other cells in the tumor in which it is present. This kind of giant-cell occurs in a variety of rapidly-growing tumors, such, for example, as fibrosarcoma, glioma, lymphoblastoma, carcinoma. Its origin is plainly evidenced by the presence of numerous multiple mitoses. Oddly enough tumors containing this type of giant-cell are rarely called giant-cell sarcomas, etc.

Giant-cells of the second type are found most commonly in new-growths involving bone. They occur both in rapidly-growing and in slow-growing tumors. There are no multiple mitoses to explain their origin.

Giant-cells of this type produce no fibrils. They are foreign body giant-cells, similar to the osteoclasts of normal bone and are due to the fusion of endothelial leukocytes attracted into the tumor by the presence chiefly of lime salts which they dissolve and remove. They signify usually disintegration of bone, rarely the presence of fat and fat crystals. Sometimes they are present in great numbers in epidermoid carcinomas, attracted by the cornified epithelium which they digest and remove. They occur most

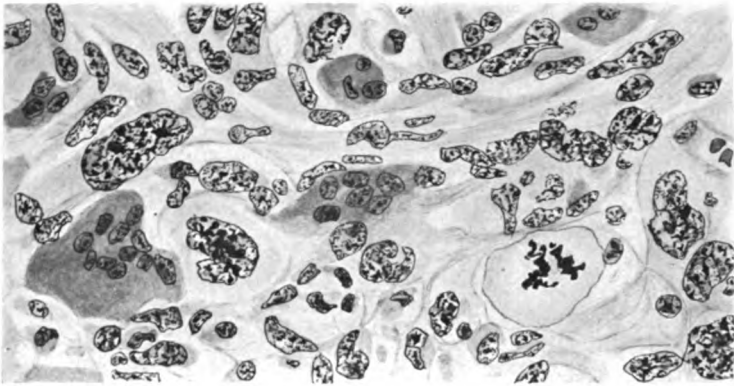


Fig. 178.—Fibrosarcoma of bone containing true tumor giant-cells, due to multiple mitoses (one of which is present), and foreign body giant-cells (with dark cytoplasm) due to fusion of endothelial leukocytes around particles of lime-salts which attracted them into the tumor.

commonly in fibroma and fibrosarcoma involving bone; in the stroma of cancer metastases in bone; in osteosarcoma.

Rarely a rapidly-growing fibrosarcoma involving bone may contain both types of giant-cells. The tumor containing foreign body giant-cells should be classified according to the nature of the other cells present in the tumor; the foreign body giant-cells should be disregarded. They do not signify either rapid growth or malignancy.

Classification.—Tumors are classified like normal tissues on a histologic basis; that is, on the differentiation of the cells composing them. When the differentiation of the cells is marked, as it ordinarily is in slow-growing tumors, a diagnosis of the nature of the tumor is usually easy. When growth is rapid, however, the differentiation is slight and may be entirely wanting. In the

latter case we may be able only to guess at the probable diagnosis from the situation in which the tumor grows, or from having for comparison with it a series of tumors of the same nature growing at all rates of speed. Sometimes, too, in a part of the tumor the cells may grow slowly so that more or less differentiation of them has had time to take place; and from them the character of the growth can be ascertained.

In the classification of tumors a knowledge of the embryologic development and appearance of the normal tissue cells is important for two reasons.

If a tumor grows rapidly its cells do not have time to differentiate to any extent; they remain of an embryonic type which must be recognized (nerve-cells and striated muscle-cells, for example).

Embryology is useful in explaining the occurrence of certain tumors in certain situations; for instance, a glioma in the nasal sinuses or over the coccyx; adrenal cell tumors in the kidney and liver; a chordoma at the base of the skull; an epidermoid carcinoma deep in the neck not connected with the skin.

Under every recognized variety of tumor should be grouped both the slowly-growing and the rapidly-growing tumors built up by the multiplication of the same type cell. In no other way is it possible fully to understand each variety of tumor and find out its characteristics. The type cell is the one important element in every tumor. From it the tumor should be named, not from some peculiarity of minor importance, such as method of growth, or arrangement of cells, or form of retrograde change.

Besides the fifteen varieties of simple tumors, there are other tumors due to the proliferation of cells of an earlier embryonic type which are capable of differentiation into two or more of the simple adult type cells. These tumors are called mixed tumors. Several varieties occur, some very simple, others more complex in structure. The most complex tumors arise from cells capable of developing into a fetus.

Nomenclature.—The nomenclature of tumors is very unsatisfactory. Most names were applied long ago when much less was known about tumors than now. Consequently they have become heirlooms which are not easily cast off. Many improvements in names have been suggested and a few have been generally accepted.

The use of some names has been restricted. The term carcinoma was formerly applied to all malignant tumors. It is now confined to malignant new-growths of an epithelial nature. The term sarcoma has long been applied to all malignant tumors of a non-epithelial nature. The tendency now is to restrict its use

to the four types of rapidly-growing tumors derived from the fibroblast (fibrosarcoma, myxosarcoma, chondrosarcoma and osteosarcoma). Perhaps it would be advisable to retain it in the broader meaning of signifying rapid growth, but such terms as gliosarcoma and rhabdomyosarcoma offend some people strangely. On the other hand, it would enable us to avoid the use of the clinical phrases, such as malignant leiomyoma, etc.

One good suggestion is being followed more and more, to join the ending blastoma to the name of each kind of cell of a distinct type and have the term apply to all the tumors arising from that type of cell; a few examples are given: fibroblastoma (includes fibroma and fibrosarcoma); osteoblastoma (includes osteoma and osteosarcoma); glioblastoma (includes glioma and gliosarcoma?); epithelioblastoma (includes adenoma and carcinoma); embryoblastoma (includes embryoma and teratoma).

SIMPLE TUMORS

INTRODUCTION TO THE FOUR CONNECTIVE-TISSUE TUMORS

The first four types of tumors (fibroblastoma, myxoblastoma, chondroblastoma, osteoblastoma) are very closely related, just as are the normal tissues to which they correspond. They are sometimes included under the term "the connective-tissue tumors."

The ordinary connective-tissue cell, the fibroblast, produces fibroglia and collagen fibrils. It has inherent in it, however, the property of being able to manufacture certain other substances. Thus in many situations, as in the walls of blood-vessels, it also produces elastic fibrils. In other situations and also under certain pathologic conditions the fibroblast may produce, in addition to the three kinds of fibrils already mentioned, three different kinds of homogeneous substances, namely, mucin, chondromucin and osseomucin.

The tumors in which the fibroblast produces only fibrils are included under the term fibroblastoma which covers both fibroma and fibrosarcoma.

If the fibroblast produces, in addition to the fibrils, a gelatinous homogeneous intercellular substance known as mucin, the cell is spoken of as a mucous connective-tissue cell, and the tumors to which it gives rise are included under the term myxoblastoma, or more commonly myxoma or myxosarcoma, according to their rate of growth.

If the fibroblast produces a solid homogeneous intercellular substance known as chondromucin, it is called a cartilage cell and the tumors are included under the term chondroblastoma, or

chondroma or chondrosarcoma, according to rate of growth. Three varieties of cartilage cells are recognized, namely, hyaline, fibrous and elastic, according to the amount of chondromucin secreted and the number of collagen and elastic fibrils present.

If the fibroblast produces in addition to the fibrils a dense homogeneous intercellular substance, known as osseomucin in which lime-salts tend to be deposited, it is called a bone cell. Tumors of which the cells tend to differentiate into bone cells are included under the term osteoblastoma or commonly osteoma or osteosarcoma, according to rate of growth. Bone cells may arise directly from fibroblasts or from an intermediate cell known as an osteoblast.

Cartilage and bone cells are end products. They do not rejuvenate and by mitosis give rise to other cartilage and bone cells. They all arise from less differentiated cells, the fibroblasts of the perichondrium and peri- and endosteum, which have inherent in them the property of producing homogeneous intercellular substances in addition to various fibrils.

Owing to the intimate relation between the four types of connective tissue, all of which arise in fact from the fibroblast, it is easy to understand how tumors frequently occur in which various combinations and proportions of the fibrils and intercellular substances which can be produced by it are present. The origin of an osteo-chondro-myxofibroma thus becomes readily comprehensible.

1. FIBROBLASTOMA (FIBROMA, FIBROSARCOMA)

Definition.—A group of tumors of mesenchymal origin of which the cells tend to produce fibroglia and collagen fibrils, less often elastic fibrils.

Type Cell.—The type cell from which this group of tumors arises is the ordinary connective-tissue cell or fibroblast, a cell which is characterized by producing regularly two kinds of fibrils named respectively, fibroglia and collagen fibrils. In addition it may give rise to elastic fibrils, but it does not do so under all conditions. These three kinds of fibrils can be readily differentiated from each other by several different staining methods.

The fibroblast is in general a flat elongated cell with one or more cytoplasmic processes at each end. Its nucleus is flat and oval in shape and vesicular in character. The fibroglia fibrils are straight or gently curved; they run along the surface of the cytoplasm and follow its prolongations. The collagen fibrils are intercellular, lying free between the cells, are more delicate in structure than the fibroglia fibrils, and run parallel in wavy bundles of larger and smaller size. The elastic fibrils vary from fine to coarse and form an interlacing network.

The fibroblast forms a great variety of tissues in the body, aponeuroses, tendons, supporting and binding tissues of all sorts. It varies in size and shape and in the amount and arrangement of the collagen and elastic fibrils it produces in these different tissues in accordance with the function it has to perform. In the cornea the fibrils are abundant and run in thin, closely compacted layers. In the corium the bundles of collagen fibrils are loosely bound together. In the cortex of the ovary the fibrils are few in number and the cells are more or less spindle-shaped. It is not surprising, therefore, that the tumors arising from fibroblasts in different parts of the body should vary much in appearance, structure, and texture.




Fig. 179.—Fibroma. Few cells, many collagen fibrils.

Rate of Growth.—Tumors arising from fibroblasts grow at all rates of speed. One on a big toe was thirteen years in reaching a diameter of five cm. Others grow with great rapidity, forming large tumors in a few months. To the slower-growing tumors the term *fibroma* is applied, while those which grow rapidly are classed under the term *fibrosarcoma*. The dividing line is not always easy to determine, but, for practical purposes if mitotic figures are present the tumor should be regarded as a fibrosarcoma. When the cells divide by mitosis it is always transversely, across the long axis of the cell.

Histologic Structure.—The cells of tumors arising from fibroblasts tend to differentiate like the normal cells. They are flat

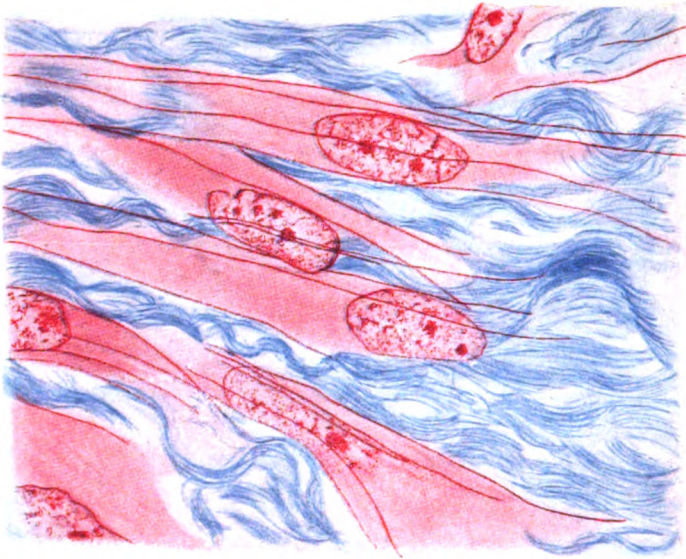


Fig. 180.—Fibrosarcoma. Cells viewed flatwise; fibroglia fibrils red, collagen fibrils blue.




Fig. 181.—Fibrosarcoma. Cells viewed sidewise.

cells with oval nuclei and produce fibroglia and collagen fibrils, and occasionally elastic fibrils. The collagen fibrils are always the more abundant and the more easily stained and recognized. They surround in equal amount all cells growing at the same rate of speed. In fibromas the fibroglia fibrils, like the cells themselves, are few in number. The tumors are composed chiefly of interlacing bundles of collagen fibrils. In the more slowly-growing fibrosarcomas the fibroglia fibrils are more prominent, but in those in which the cell proliferation is very rapid both kinds of fibrils are so delicate that they are seen with difficulty except when deeply stained or when viewed on end.

Giant-cells.—Occasionally, especially in the more rapidly-growing fibroblastomas, numerous multiple mitoses and multinucleated cells arising from them are present. Some of the cells may contain dozens of nuclei. These giant-cells are true tumor

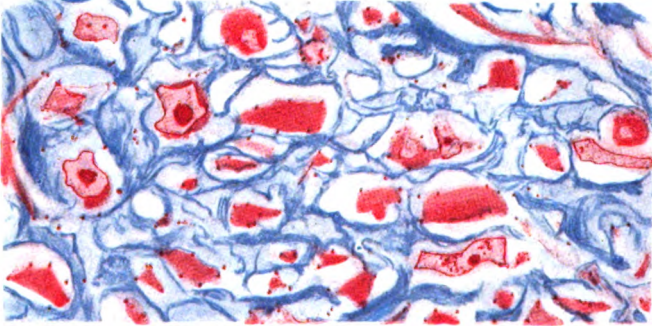


Fig. 182.—Fibrosarcoma. Cells viewed in cross-section.

cells and produce fibrils like the other cells. They indicate abundant nutrition and usually rapid growth.

More often giant-cells of another type are present. They are foreign body giant-cells due to fusion of endothelial leukocytes which have been attracted into the tumor by foreign bodies of some sort or other, usually fat crystals or lime-salts, and have fused around them. On this account this type of giant-cell is common in fibroblastomas involving bone.

Stroma.—The stroma of fibroblastomas consists of blood-vessels and connective tissue derived from the surrounding tissue. They run in the centers of the strands of tumor cells which run parallel with them. The most active proliferation and the youngest tumor cells always adjoin the vessels. In the most rapidly-growing tumors the stroma consists for the most part only of blood-vessels lined with a single layer of endothelium. In the more slowly-growing tumors the vessels are accompanied by a

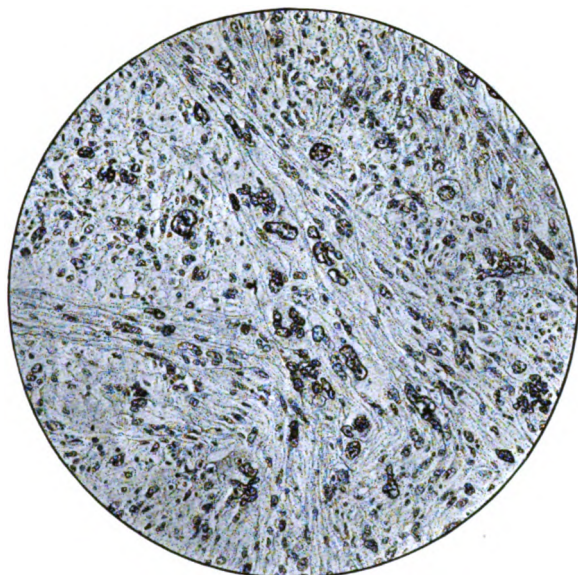


Fig. 183.—Fibrosarcoma containing multiple mitoses and true tumor giant-cells.

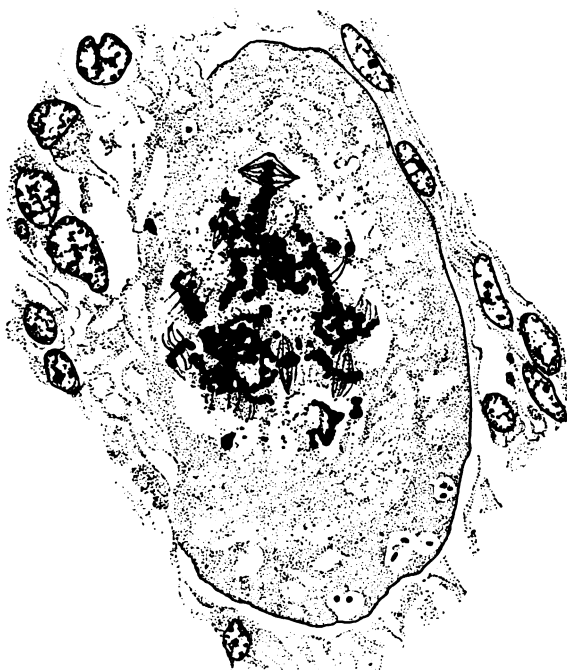

Fig. 184.—Fibrosarcoma. Multiple mitosis.

varying amount of connective tissue which cannot always be readily distinguished from the tumor tissue.

Fibroma.—While there is no sharp line separating the slowly and rapidly-growing fibroblastomas from each other, because all gradations in rate of growth occur, it is advisable to discuss separately and briefly the two extremes of growth recognized by the terms fibroma and fibrosarcoma.

Histologically the cells and fibrils of a fibroma are joined together sometimes in large bundles which run in different directions,

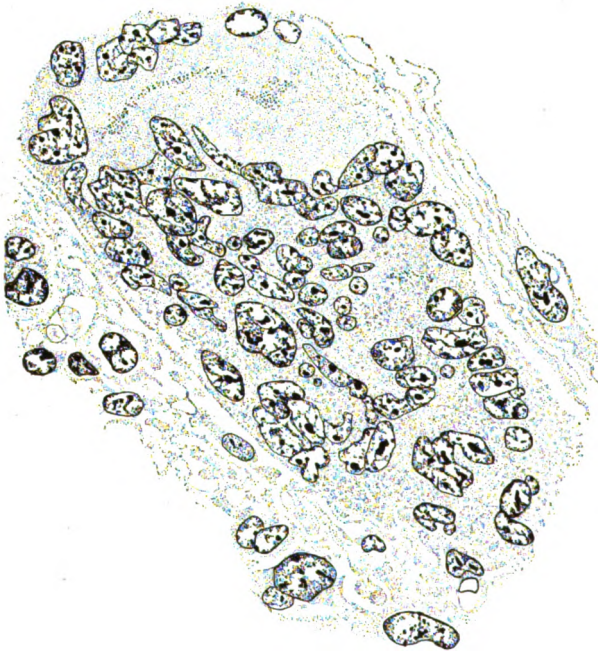


Fig. 185.—Fibrosarcoma. True tumor giant-cell. Many nuclei and centrosomes present.

sometimes in small strands which twist and twine in every way. If the bundles and strands are closely woven the result is a compact, hard tumor, fibroma durum; if loosely woven, a flabby, shapeless, tough mass, fibroma molle. Sometimes edema has the same effect on a fibroma causing it to be flabby, tough, and on section moist.

Fibromas usually grow expansively and form spherical or rounded nodular masses. As a rule, they are surrounded by a fibrous capsule and are dangerous clinically only from size, location, or pressure exerted. Occasionally they grow diffusely and

tend to infiltrate. Frequently they are multiple, occurring sometimes in great numbers in the skin and along nerves. Rarely they




Fig. 186.—Fibroma. Cells few in number. Collagen fibrils form wavy bundles. M.

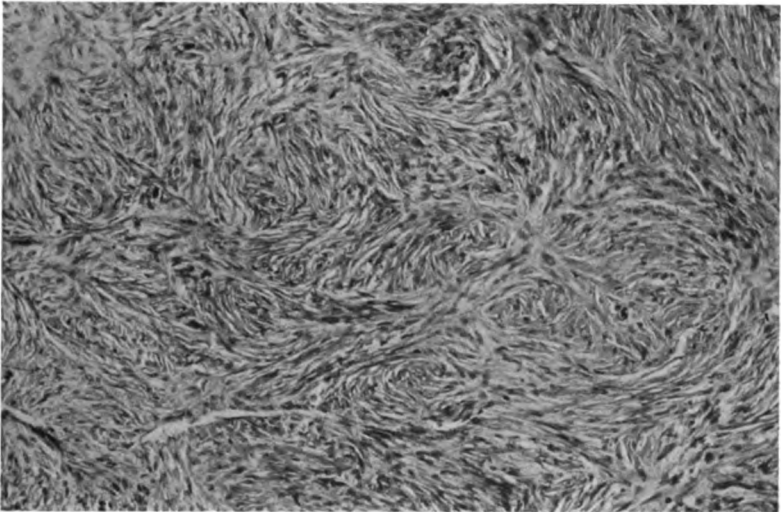


Fig. 187.—Fibroma. Cells and fibrils in small bundles which run in every direction. M.

present a plexiform appearance possibly owing to extension along or around nerves or other structures. They originate most com-

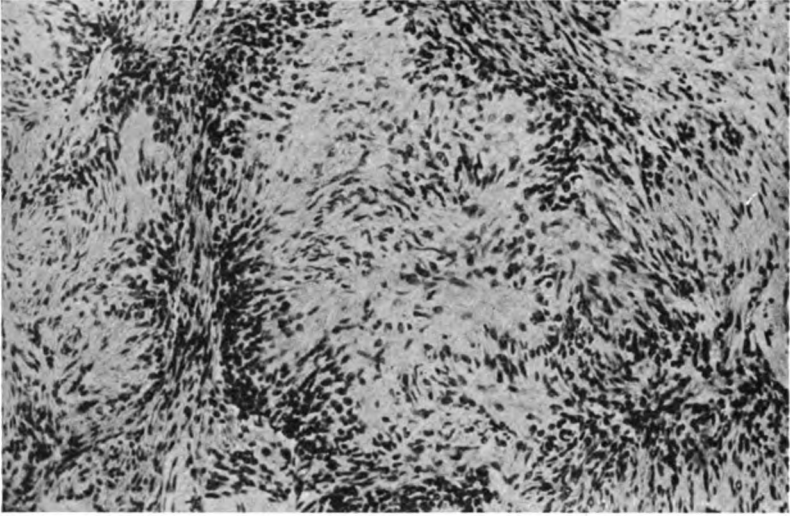


Fig. 188.—Fibroma developing from sheath of nerve. Nuclei tend to occur in groups, close together; hence the clear areas where only cytoplasm and collagen fibrils are present. M.

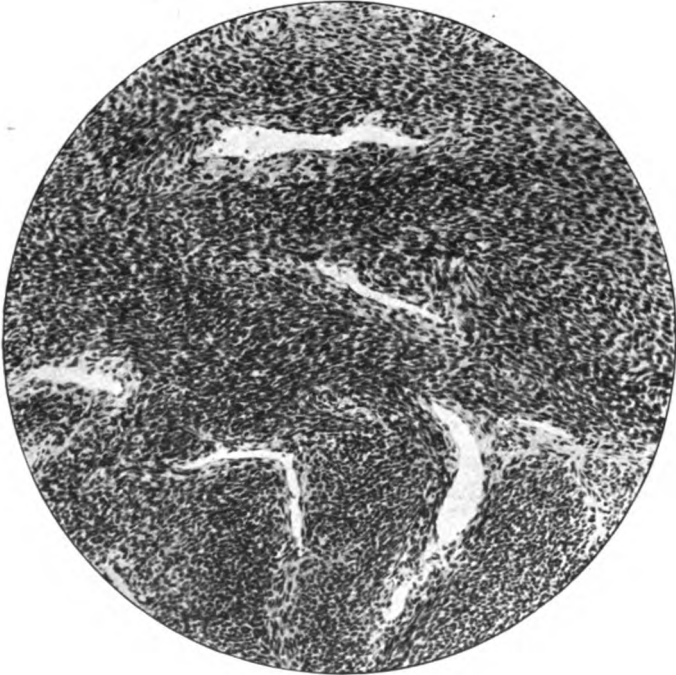

Fig. 189.—Fibrosarcoma. M.

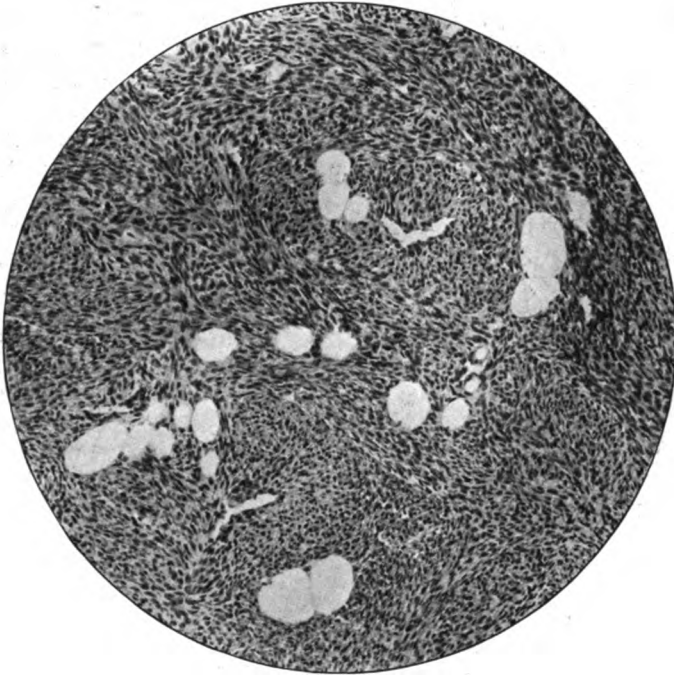


Fig. 190.—Fibrosarcoma invading fat-tissue. M.

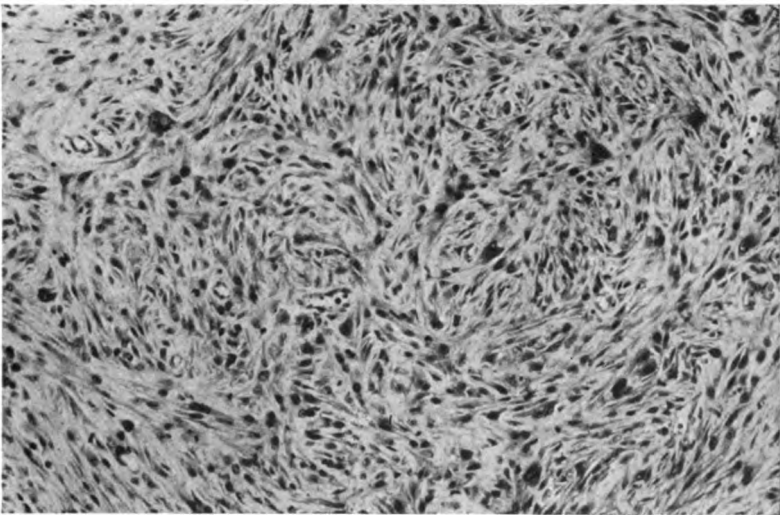


Fig. 191.—Fibrosarcoma. Cells and fibrils in small bundles which run in various directions. M.

monly in the skin, muscles, fasciæ, tendons, periosteum, ovaries and uterus. On section the hard varieties are white and glistening when the bundles of cells and fibrils run horizontally, and of various shades of grey when the bundles are cut obliquely and transversely. The flabby varieties are light grey and if edematous are translucent. Rarely the serum in an edematous fibroma may color it yellow like fat.

Fibrosarcoma.—The rapidly growing tumors, the fibrosarcomas, tend to infiltrate the tissues in which they grow and to give rise to metastases, especially by way of the blood stream, to the lungs, liver and other organs. The cells are almost always spindle-shaped and may be large or small. Occasionally they are oval, round or polymorphous. On section the cut surface is even,

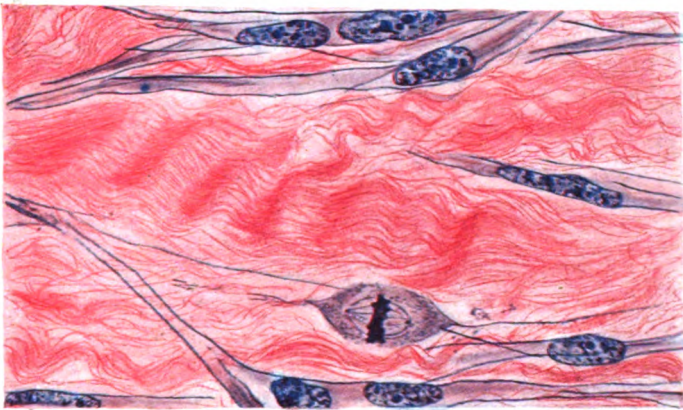


Fig. 192.—Fibrosarcoma of breast. Numerous collagen fibrils. One mitotic figure. Fibroglia fibrils blue.

translucent and resembles fish flesh. As a rule the cells are readily teased apart. The fibrosarcomas originate in much the same locations as the fibromas, but are never multiple except by metastasis.

Keloid.—Keloid is a term applied to certain tumor-like structures composed of dense fibrous tissue which occur in the skin in certain peculiarly constituted people. Keloids usually follow an injury (cut, blow, burn), but occasionally they appear to arise spontaneously. The fibroblasts of which they are composed are distributed in thin sheets between thick layers of collagen fibrils which are more or less fused together and usually appear hyaline. The cells and fibrils run in various directions. The tissue resembles scar tissue.

When a keloid is removed, a similar growth arises to take its

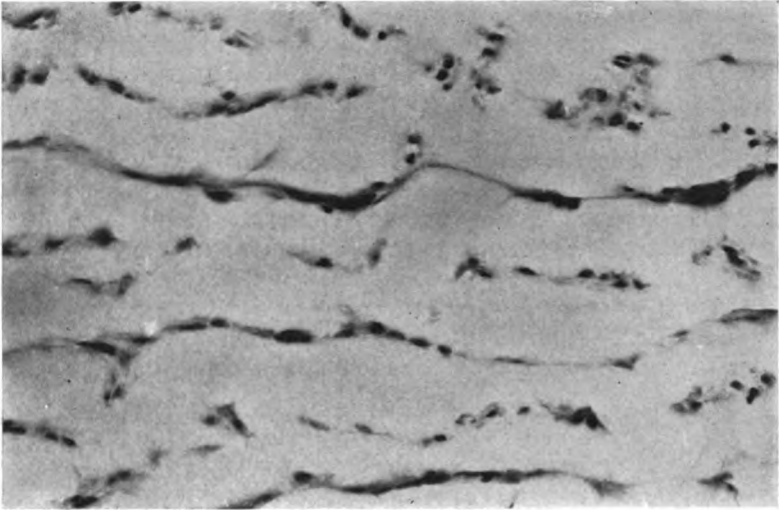


Fig. 193.—Keloid. The collagen fibrils form thick hyaline layers, with the cells in thin sheets between them. M.

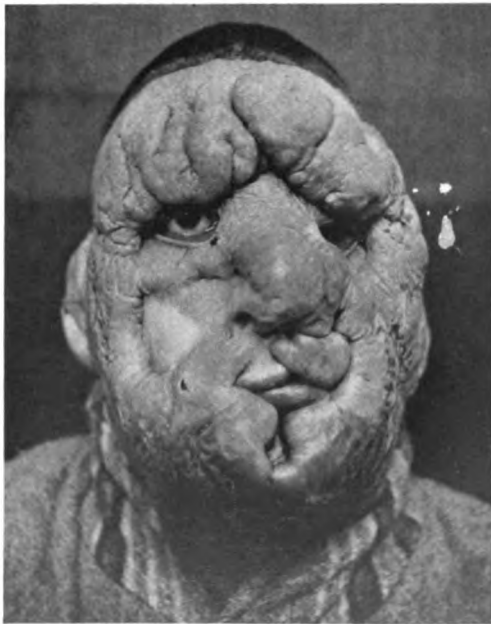

Fig. 194.—Keloid of face following a burn.

place and is often incorrectly regarded as a recurrence. If the second mass is removed a third will take its place, because the injury is the same each time. In other words a keloid is the result of over-activity on the part of the regenerative powers of the fibroblasts and represents a hypertrophied scar.

A keloid in the active stage of formation closely resembles histologically a fibrosarcoma, because the fibroblasts play a much more active part than the vascular endothelium and there is little or no leukocytic or lymphocytic infiltration:

2. MYXOBLASTOMA (MYXOMA, MYXOSARCOMA)

Definition.—A tumor of mesenchymal origin of which the cells tend to produce mucin in addition to fibroglia, collagen, and elastic fibrils.

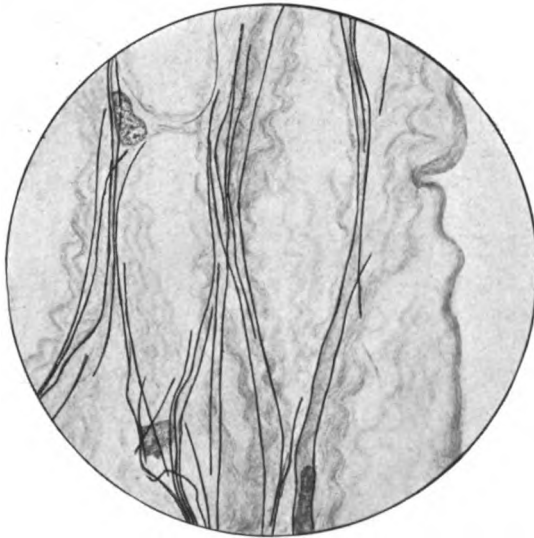

Fig. 195.—Umbilical cord at term. Mucous connective-tissue cells with fibroglia and collagen fibrils.

Introduction.—The myxoblastoma is a comparatively rare tumor and, therefore, clinically of minor importance. It is characterized by its translucency and in well-marked examples by its sliminess. It is questionable whether it deserves recognition as an entity. It often differs so little from the fibroblastoma that it could well be included under that tumor. Moreover, all the tumor cells do not secrete mucin; many produce only the fibrils and hence cannot be distinguished from the ordinary fibroblast. On the other hand, the cells which do secrete mucin show how all

the cells tend to differentiate and may be said to characterize this tumor, just as the production of chondromucin distinguishes the chondroblastoma.

Type Cells.—The type cell is the mucous connective-tissue cell as found in the early embryo, but restricted at the time of birth almost exclusively to the umbilical cord. It is a fibroblast which secretes, in addition to the three kinds of fibrils, a homogeneous semifluid intercellular substance called mucin. The mucin occurs between the collagen fibrils. Sometimes it is much more abundant

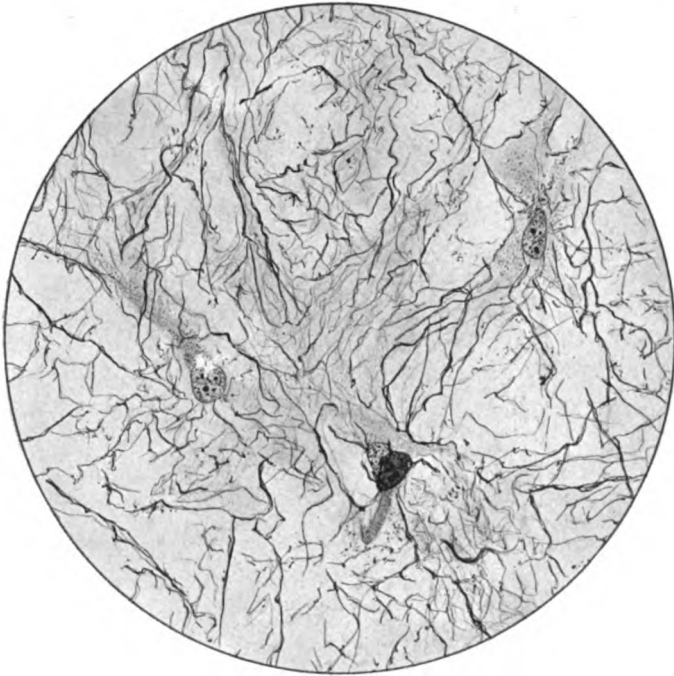


Fig. 196.—Myxoma. The cells and their fibrils are separated by fluid containing mucin.

in some situations than in others, filling small cavities between strands of fibrils.

Rate of Growth.—The myxoblastomas grow at various rates of speed. The term myxoma is applied to one which grows slowly, myxosarcoma to one which grows rapidly. The absence or presence of mitotic figures determines the heading under which a given tumor should be grouped.

Histologic Appearance.—The cells of a myxoblastoma tend to differentiate into mucous connective-tissue cells. Owing to the

presence of the mucinous fluid the fibrils are more or less widely separated from each other and the cells often present a stellate appearance with long branching cytoplasmic processes, because they are not packed tightly together as in a fibroblastoma. Rarely some of the cells contain multiple nuclei; they are true tumor giant-cells derived from multiple mitoses. In a myxosarcoma many of the cells are likely to be of the spindle type.

Myxoblastomas have a slight stroma containing fairly numerous blood-vessels and a small amount of connective tissue.

Gross Characteristics.—Myxoblastomas may attain a considerable size, one or more kilos. They usually form lobulated or polypoid masses which may or may not be sharply limited and encapsulated. On section they often appear translucent, gela-

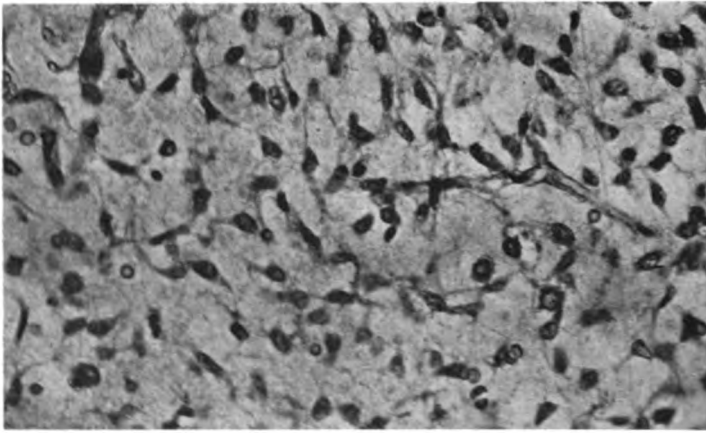


Fig. 197.—Myxoma. The cells and their processes are separated by fluid containing mucin. M

tinous, and colorless, but are sometimes grayish, yellowish or whitish, at least in part, and if the vessels in the stroma are numerous and injected they may be colored light to dark red. Naturally, they are not rigid and dense to the touch, but the myxomas are tough like the umbilical cord owing to the presence of numerous collagen fibrils. The myxosarcomas are delicate and easily teased apart. Both forms of growth on section often feel slimy to the fingers, owing to the presence of much mucin.

Myxoblastomas occur most often in the soft parts of the extremities, especially in the fat-tissue; along the course of nerve bundles; in the neighborhood of joints; retroperitoneally; in the umbilicus; in the periosteum; and rarely in the endocardium of the heart.

The myxoma is benign, is occasionally multiple, and sometimes congenital.

The myxoblastoma may be closely simulated by an edematous fibroblastoma. The presence or absence of mucin on test is the deciding point. Myxomatous tissue is often present in some of

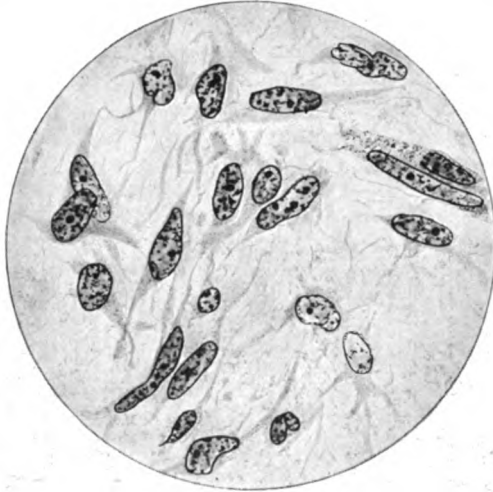

Fig. 198.—Myxosarcoma.

the mixed tumors, especially in those derived from the fibroblast and in the mixed tumors of the parotid region. Myxomatous-like tissue is often formed in the stroma of certain tumors, especially in adenomas of the mammary gland and in hair matrix cancers of the skin.

3. CHONDROBLASTOMA (CHONDROMA, CHONDROSARCOMA)

Definition.—A tumor of mesenchymal origin of which the cells tend to differentiate into cartilage cells.

Type Cells.—The type cell is the cartilage cell which ordinarily arises from the perichondrium. This structure consists of fibroblasts which produce fibroglia, collagen, and elastic fibrils. In addition they are able to secrete a dense homogeneous intercellular substance known as chondromucin, which more or less obscures the fibrils unless they are rendered prominent by special staining methods. In transforming itself into a cartilage cell, a fibroblast alters its shape, becomes spherical or more or less flattened, and apparently loses its fibroglia fibrils. The cartilage cells, at least in hyaline cartilage, do not retain cytoplasmic connection with each other. The homogeneous substance is sometimes deposited

in lighter and denser layers around individual cells and small groups of them so as to appear in the form of hyaline capsules.

When the homogeneous intercellular substance is abundant, the hyaline type of cartilage is formed. When it is slighter in amount and the collagen or elastic fibrils predominate, fibrous (white) or elastic (yellow) cartilage results. So far as known cartilage cells are an end product; they do not give rise to other cartilage cells, but all arise from the less differentiated fibroblast of the perichondrium, or from other fibroblasts such as those composing the periosteum, for example.

Rate of Growth.—Tumors composed of cartilage cells grow at all rates of speed. The term chondroma is applied to those which

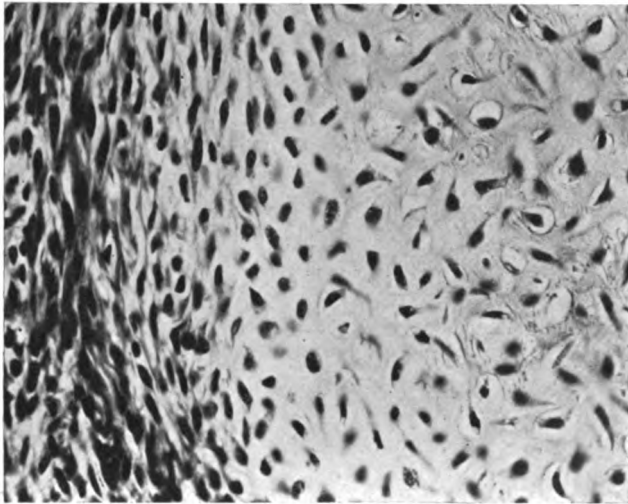


Fig. 199.—Normal cartilage in a fetus. The fibroblasts of the perichondrium are undergoing a gradual transformation into cartilage cells. M.

grow slowly, chondrosarcoma to those which grow rapidly. There is no sharp dividing line between the two, but the absence or presence of mitotic figures may be used as the surest guide.

Histologic Appearance.—The cells of a chondroblastoma tend to differentiate into cartilage cells and in a given tumor may form any one of the three varieties—hyaline, fibrous or elastic. Combinations of all these types may occur. The tumor cells vary considerably in size and shape in different instances. In some tumors they are large and polymorphous; in others they may be small and spindle-shaped.

The stroma of a chondroblastoma consists of blood-vessels

accompanied by connective tissue usually in small amount. The actively proliferating tumor cells adjoin the stroma and in a chon-

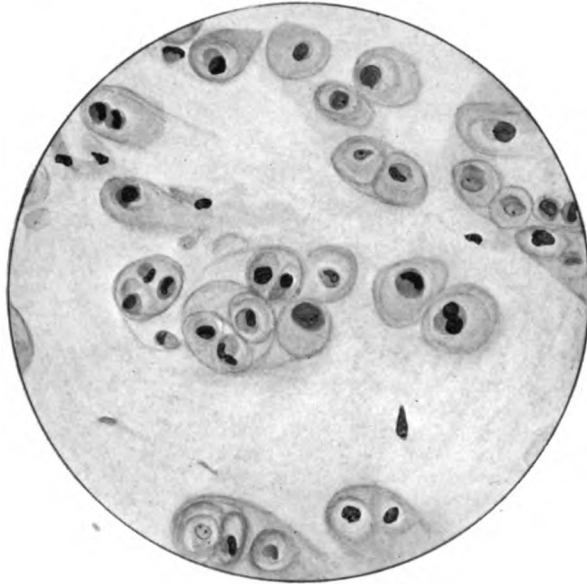


Fig. 200.—Chondroma.

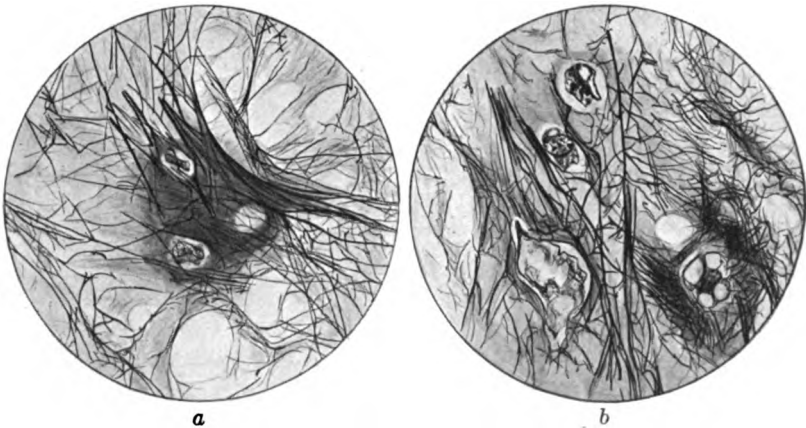


Fig. 201.—Chondroma. Elastic tissue stain.

droma form the perichondrium from which growth takes place. As the tumor masses enlarge peripherally the stroma is stretched

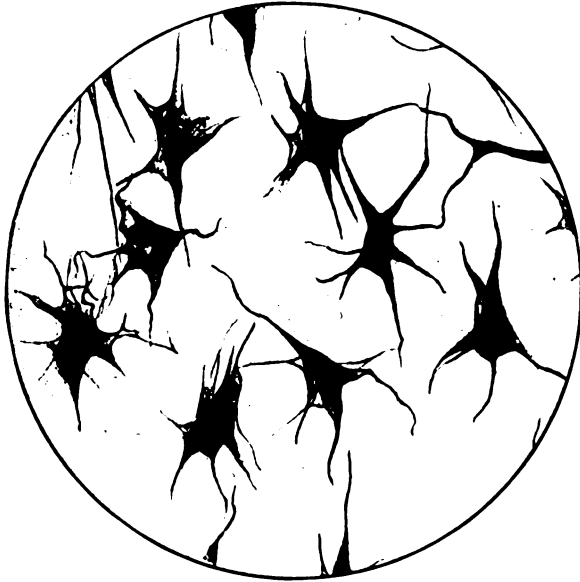


Fig. 202.—Chondroma. An area where the intercellular substance is soft and the cells have cytoplasmic processes, like mucous connective-tissue cells.

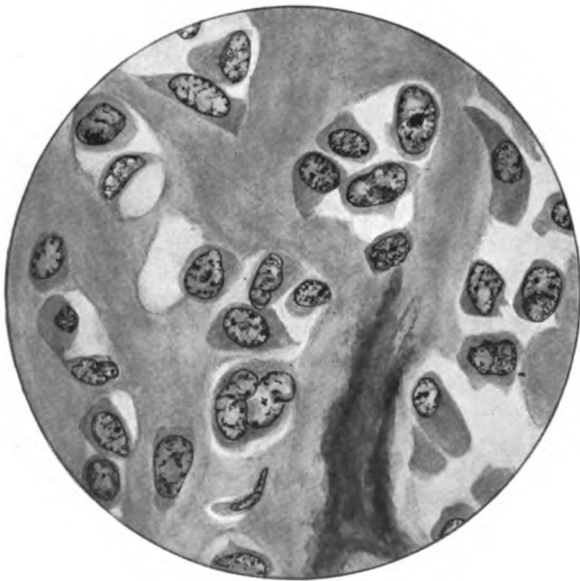

Fig. 203.—Chondrosarcoma.

and its meshes surrounding the tumor as a whole and extending in between the tumor cell masses become more and more distended. As a result of this manner of growth the tumor cells farthest removed from the stroma get less and less nutrition by imbibition, and are likely to undergo retrograde changes, such as mucoid softening, calcification, or necrosis.

In chondrosarcomas the blood-vessels are usually large and numerous and little or no connective tissue is present. The tumor cells immediately adjoin the vessels and proliferation is most marked in this situation. Farther away from the vessels the cells undergo differentiation and form cartilage cells.

Gross Characteristics.—Chondroblastomas may attain a large size, sometimes weighing many kilos. They are usually lobulated or nodular, and on section of a translucent pale bluish or opalescent white color. As a rule they are hard and dense to the touch.

Chondromas grow expansively, are limited by a definite capsule and are in general benign, but occasionally they invade lymphatics and veins and extend along them. They may give rise to metastases but this occurrence is much more likely to happen with the chondrosarcomas which tend to infiltrate the tissues around them.

Chondroblastomas arise usually from perichondrium and periosteum, but occasionally originate in the soft tissues and in internal organs. They are found most often, therefore, in connection with the skeleton.

Chondromas are sometimes multiple and occasionally congenital.

4. OSTEOLASTOMA (OSTEOMA, OSTEOSARCOMA)

Definition.—A tumor of mesenchymal origin of which the cells tend to differentiate into bone cells.

Type Cell.—The type cell of the osteoblastoma is the bone cell.

Under normal conditions bone cells arise from fibroblasts either directly or through an intermediate form of it called the osteoblast. The fibroblasts which produce bone cells are known as periosteal and endosteal cells. They produce fibroglia, collagen and elastic fibrils. In addition they are capable of secreting a dense homogeneous intercellular substance called osseomucin, which binds the fibrils together, rendering them more or less invisible, and attracts lime-salts. While this substance is being deposited the fibroblast contracts and alters its shape. The cell finally comes to occupy a cavity called a lacuna, surrounded by the homogeneous substance in which the lime-salts are deposited. From the cell cytoplasmic processes and perhaps fibroglia fibrils

extend in all directions through canaliculi to connect with other cells. Bone cells are formed in this way in the skull, etc. In other places the fibroblasts change first into polymorphous osteoblasts, often with numerous fine granules in their cytoplasm.

So far as is now known bone does not arise from cartilage but may substitute itself for it. On the other hand, cartilage often becomes calcified but the cartilage cells do not change into true bone cells.

Bone cells always arise from fibroblasts and osteoblasts. They are an end product. They do not rejuvenate and by mitosis give rise to other bone cells.

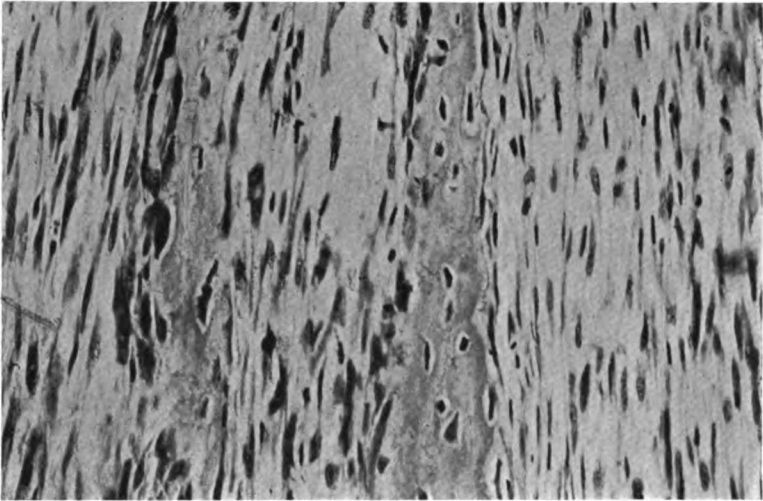


FIG. 204.—Osteosarcoma arising from periosteum of femur. The tumor consists largely of rapidly proliferating fibroblasts which in places differentiate into bone-cells arranged in trabeculae. M.

When a bone cell undergoes necrosis, the intercellular substance and especially the lime-salts under its control are removed by the action of foreign body giant-cells formed from fused endothelial leukocytes attracted to the site. The giant-cells are known as osteoclasts.

Rate of Growth.—Bone tumors grow at all rates of speed. Some require many years to reach a size attained by others in weeks or months. Those which grow slowly are classed under osteoma; those which increase in size rapidly are grouped under osteosarcoma; there is no sharp dividing line; many are on the border line. It is sometimes difficult to decide in which group to place a given tumor.

The rapidly-growing tumors are the more interesting to study because all stages in the development of bone cells are present.

Histologic Appearance.—Bone cells in osteblastomas arise in the same manner as in normal bones from fibroblasts and osteoblasts. In the rapidly-growing tumors of this type all stages in the transformation of fibroblasts into bone cells can be readily followed. Some of the tumors grow as fibrosarcomas, but here

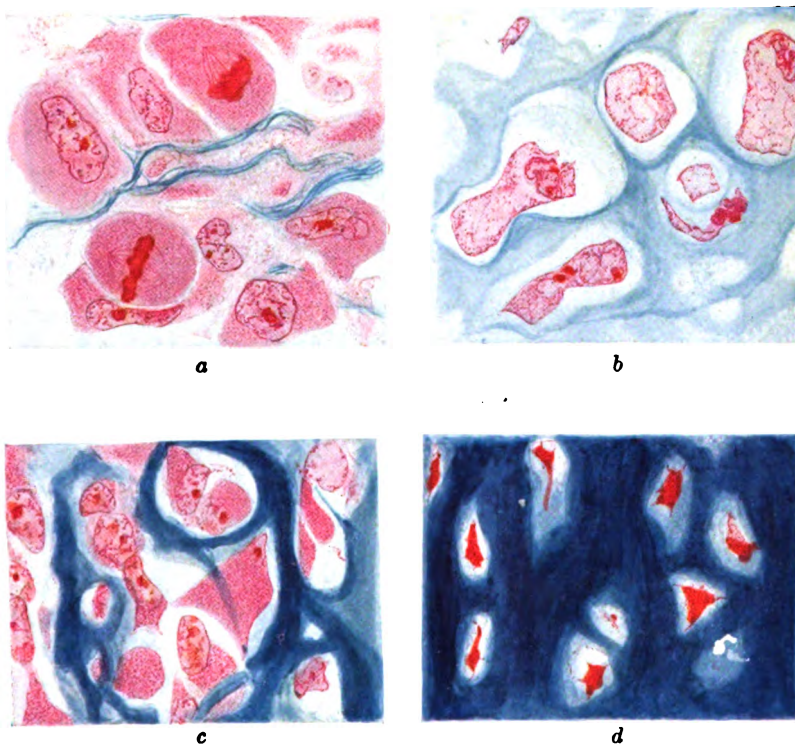


Fig. 205.—Osteosarcoma. Four views from same tumor showing different rates of growth and differentiation.

and there groups of the cells cease to proliferate, secrete osseomucin between the fibrils and attract lime-salts; in other words, they differentiate into bone cells. Other cells adjacent to these groups of cells join them so that the differentiating foci spread and coalesce, thus forming the bony trabeculae of the tumors.

In other osteblastomas the rapidly-growing cells may be spindle-shaped or round, but, instead of forming fibrils, at least to any extent, they deposit directly large amounts of homogeneous

intercellular substance in the form of anastomosing trabeculæ. In consequence of the prominence of this deposit of osteoid material these tumors have received the distinctive name of osteoid sarcomas. Occasionally osteblastomas occur in which both the fibrous and osteoid types of growth are present and they may be very intimately combined, showing that there is no essential difference in the cells. Possibly the cells in the osteoid tumors correspond to the cell intermediate between the fibroblast and the bone cell in certain situations, namely, to the so-called osteoblast.

When an osteblastoma gets to growing rapidly the cells in some parts of it may not differentiate in the slightest. Under these conditions they may appear spindle-shaped or spherical.

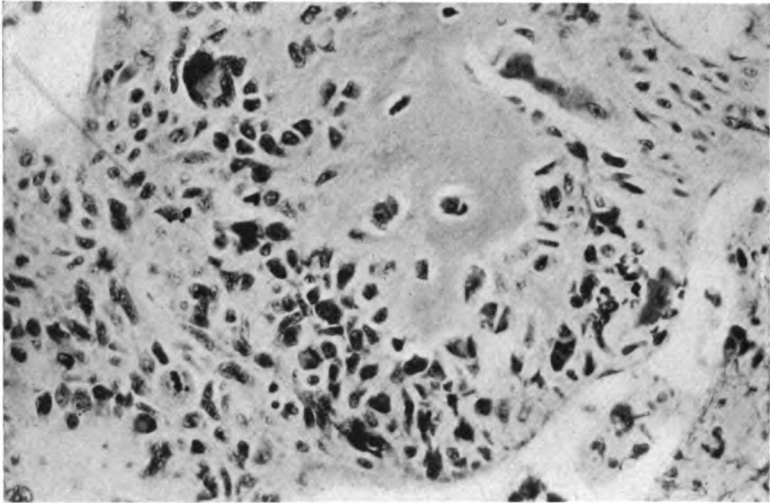


Fig. 206.—Osteosarcoma. The cells adjoining the blood-vessels are the least differentiated. M.

Their true nature can be recognized only by the differentiation of the cells in other parts of the tumor when they are proliferating less rapidly.

In osteomas the cell changes may be so slow that they cannot be directly followed.

In all osteblastomas, just as in normal bone, there is a continual removal of the older tissue going on. Whether it is due to atrophy and disappearance or to necrosis of the bone cells cannot be determined, but the intercellular substance, be it calcified or not, is immediately attacked by foreign body giant-cells (osteoclasts) formed by the fusion of endothelial leukocytes attracted to the spot. They gradually erode, digest and remove all inter-

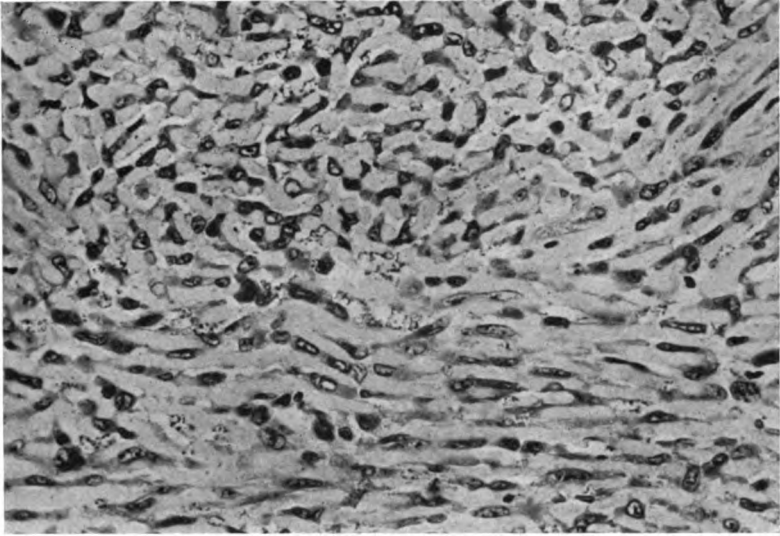


Fig. 207.—Osteoid sarcoma. The intercellular substance appears as hyaline trabeculae. M.

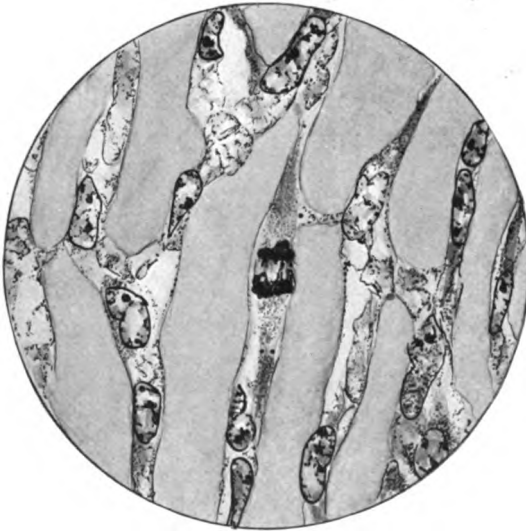


Fig. 208.—Osteoid sarcoma. One cell in mitosis.

cellular substance not under the immediate care of living bone cells. Sometimes the retrograde processes are very active, so that the number of foreign body giant-cells is in excess of the tumor cells. The term giant-cell sarcoma is often incorrectly applied to such a new-growth.

Gross Characteristics.—Osteoblastomas may attain a very large size. This statement was particularly true in the old days when tumors were allowed to attain their natural development without operative interference. They form spherical or tuberosous tumors, often of great hardness. The osteomas are sometimes divided on the basis of hardness into *osteoma durum* (compact, ivory-like) and *osteoma spongiosum* (porous, sponge-like). The osteomas appear white to yellowish like bone, but the osteosarcomas are often grayish to white, and sometimes reddish brown

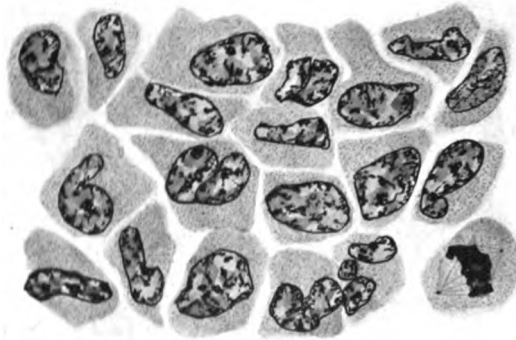


Fig. 200.—Osteoid sarcoma. From an area where no differentiation has taken place.

as the result of hemorrhage. Occasionally, they are hollow and cystic as the result of necrosis, softening and absorption. When they start in the periosteum the new trabeculae of bone extend out for the most part at right angles to the shaft.

True osteomas are rare, especially out of connection with the skeleton, but they have been found, for example, in the lung, brain and elsewhere. They grow slowly and expansively. Sometimes it is difficult to distinguish between them and tumor-like growths of inflammatory origin.

The osteosarcoma is a more common and important tumor than the osteoma. It invades and destroys bones, especially when it arises within one and often extends to muscle and other neighboring tissues. Metastases occur most often by way of the blood stream.

5. LIPOBLASTOMA (LIPOMA)

Definition.—A tumor of mesenchymal origin of which the cells tend to differentiate into fat-cells.

Type Cell.—The type cell is the fat-cell found in various places throughout the body. In the embryo the fat-cells are early differentiated as a definite cell entity from the other mesenchymal cells. They appear in small clumps in the subcutaneous tissue and elsewhere, and have a stroma consisting of numerous capillaries and a slight amount of connective tissue. The fat-cell is not a fibroblast, is not derived from one, and in emaciation does not return into one.

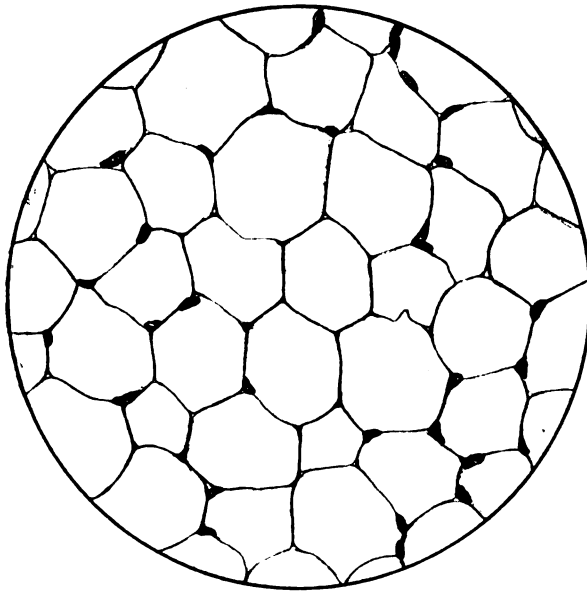


Fig. 210.—Lipoma.

A fat-cell at first resembles to some extent a small liver cell. The nucleus is centrally located; the cytoplasm is abundant, finely granular, and sharply limited although it does not seem to possess a cuticle. In emaciated infants, especially soon after birth, the fat-cells often increase considerably in size, although containing no fat, and may so resemble large epithelial cells as to be mistaken for some form of tumor.

At a later stage in the development of fat-cells minute droplets of fat appear more or less evenly distributed in the cytoplasm. By coalescence larger drops are formed, but the nucleus remains

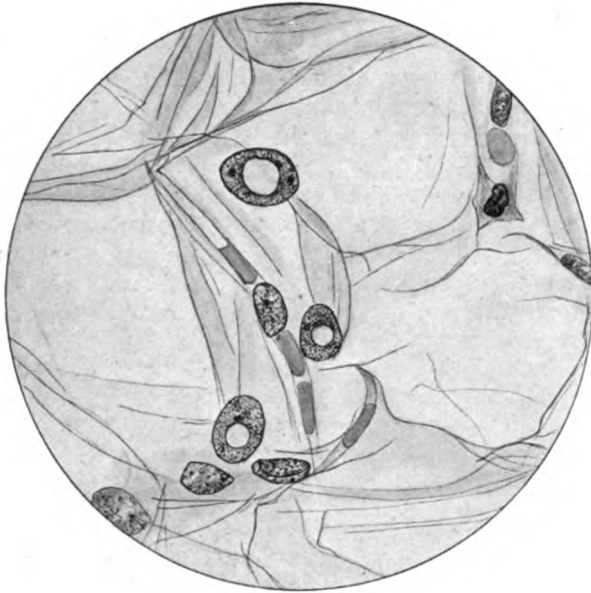

Fig. 211.—Lipoma. Detail showing character of nuclei.

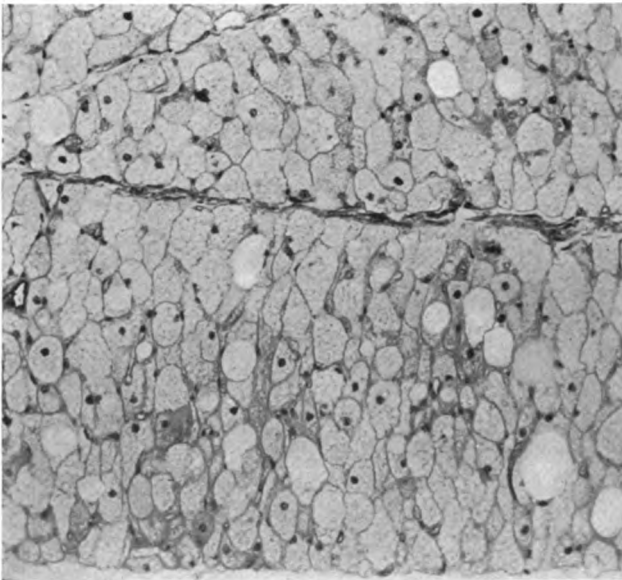


Fig. 212.—Lipoblastoma in which most of the fat-cells are of the embryonic type. M.

in the center of the cell. Fat-cells of this type are not infrequently found in the adult, especially retroperitoneally. They are common in many of the lower animals, such as monkeys, mice, etc.

The adult type of fat-cell ordinarily contains one large globule of fat around which its cytoplasm is distended into a thin envelope. The nucleus is flattened and pushed to the periphery of the cell. Within the nucleus is often a small opening (vacuole).

Rate of Growth.—The lipoblastoma is a tumor of comparatively slow growth and is ordinarily called a lipoma. If rapidly-growing forms occur their true nature has not been recognized.

Histologic Appearance.—The cells of a lipoblastoma tend to differentiate into fat-cells usually of the adult type, but occasionally of the embryonic type. They are held together by a small amount of connective tissue and are provided with blood-vessels, mostly of the capillary form.

The fat-cells of a lipoblastoma are usually thought to be a little larger than the normal size, but in a lipoma from an infant they were unquestionably smaller. A rapidly-growing lipoma from the back of a nurse was composed almost entirely of fat-cells of the embryonic type and they were considerably above the normal size. The cytoplasm

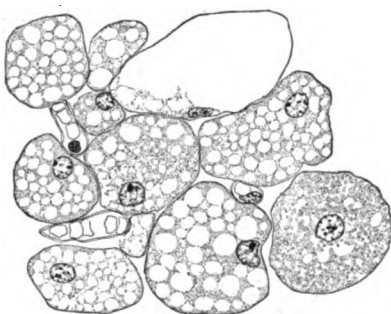


Fig. 213.—Lipoma of fetal fat-cell type.

of the cells was decidedly granular and some of them contained no fat. At the periphery of the tumor the cells were invading the surrounding fat and muscle-tissue. The growth must therefore be regarded as possessing some of the properties of malignancy.

Gross Characteristics.—Lipomas usually grow slowly and expansively. They are lobed or lobulated and are surrounded by a connective-tissue capsule in consequence of which they can usually be easily shelled out of the tissue in which they have developed. They may reach a large size and from size or pressure prove dangerous clinically. In other respects they rank among the most benign of tumors. Occasionally, they undergo retrograde changes, such as necrosis, cyst formation, or calcification. Rarely they become ossified.

Lipomas occur most frequently subcutaneously, intramuscularly and subserously. They have also been found in the kidney, orbit, uterus, and skull cavity. Sometimes they are multiple and symmetrically distributed. On section they resemble ordi-

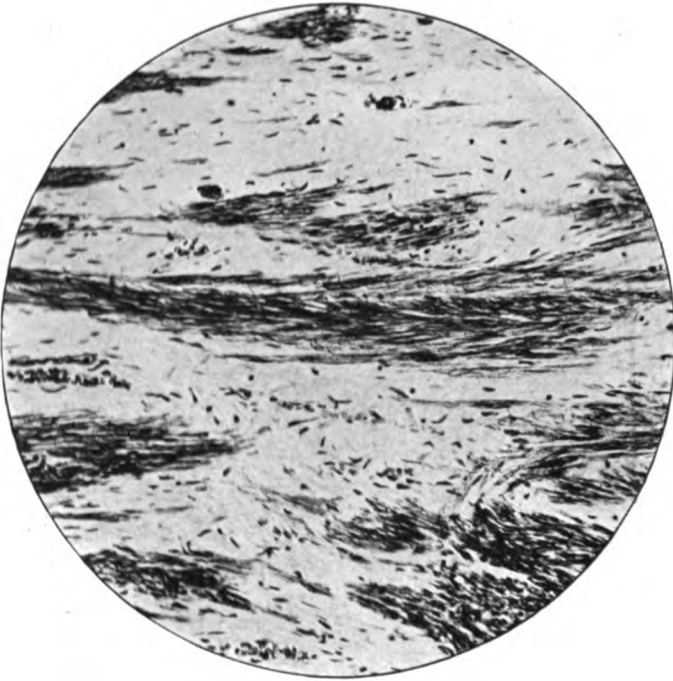


Fig. 214.—Leiomyoma. Smooth muscle-cells with their myoglia fibrils appear black. Fibroblasts with their collagen fibrils appear light. M.

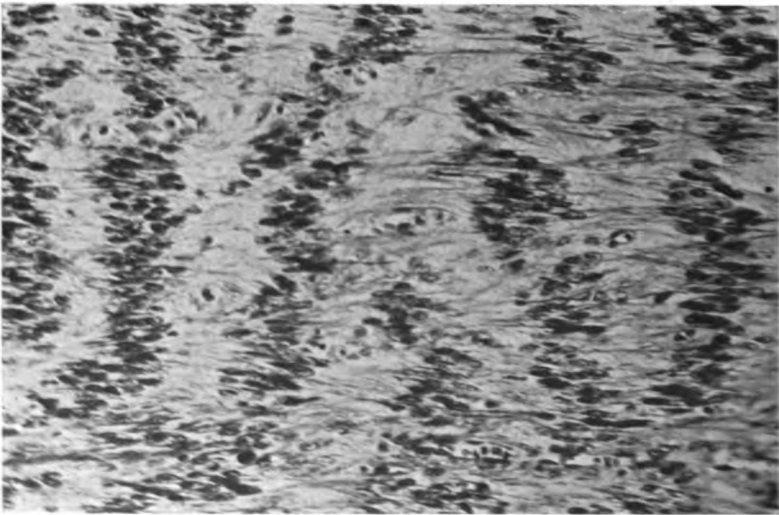


Fig. 215.—Leiomyoma. Nuclei grouped in regular rows like columns of infantry. M.

nary fat-tissue. The rapidly-growing one from a nurse's back was reddish yellow in color and very vascular.

The consistence of a lipoma depends largely on the amount of connective tissue present.

6. LEIOMYOBlastOMA (LEIOMYOMA)

Definition.—A tumor of mesenchymal origin of which the cells tend to differentiate into smooth muscle-cells.

Type Cell.—The type cell is the smooth muscle-cell of mesenchymal origin which occurs in the uterus, gastro-intestinal tract, blood-vessels, and elsewhere.

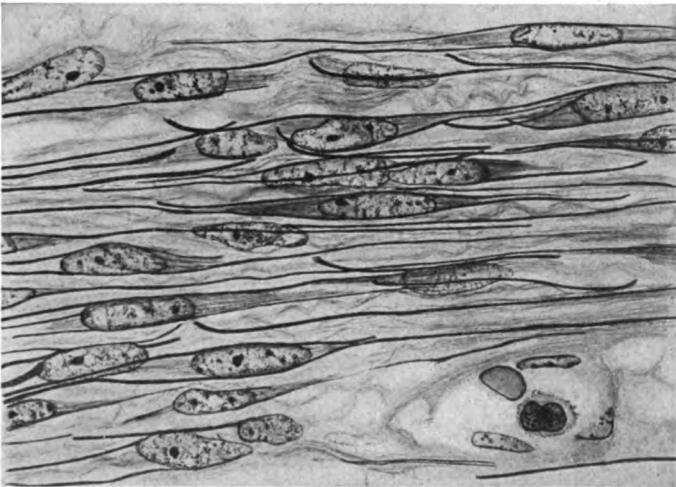


Fig. 216.—Leiomyoma. Myofibrils relatively coarse.

The type cell is long and spindle-shaped with a rod-shaped nucleus and dense acidophilic cytoplasm. The cell is characterized by having in the cuticle of the cytoplasm longitudinal striations, known as myofibrils which can be stained differentially and which have much to do with the deep acidophilic staining of the smooth muscle-cell cytoplasm. These fibrils are fine and separate except at the ends of the cells where they fuse more or less together to form coarse fibrils which terminate the cell. Owing to this condition smooth muscle-cells show when properly stained both fine and coarse fibrils and in this respect differ from a fibroblast.

Smooth muscle-cells vary considerably in size and in the development of fibrils in different parts of the body. The cells

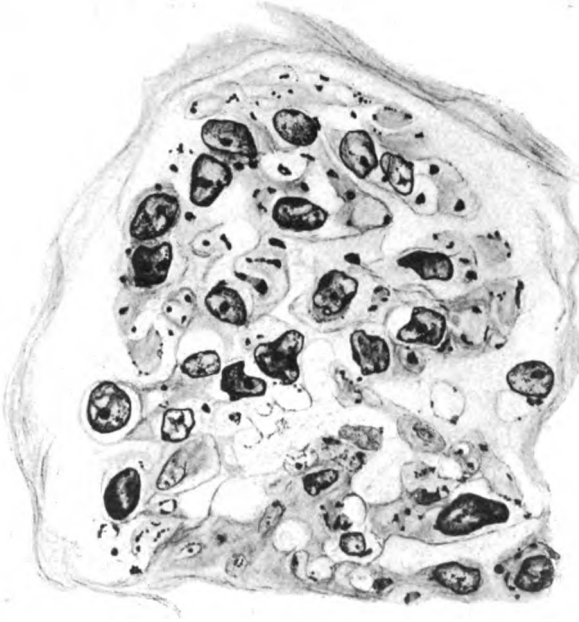


Fig. 217.—Leiomyoma. Cells and fibrils viewed in cross-section.

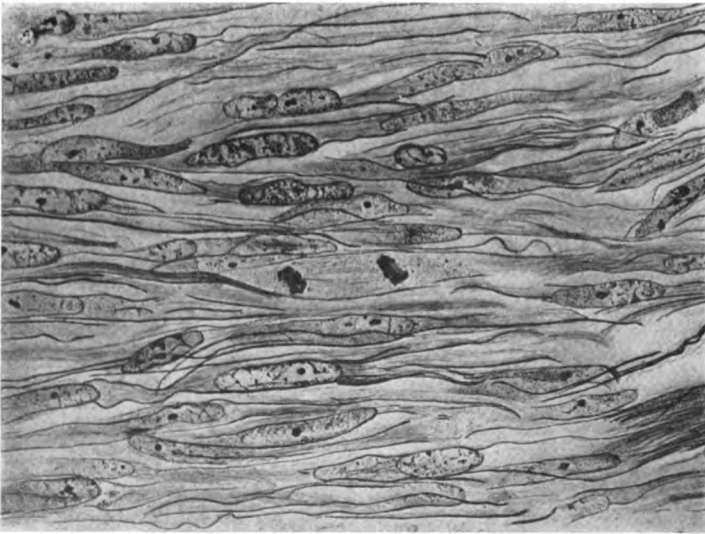


Fig. 218.—Leiomyosarcoma. Myofibrils well developed. One mitotic figure present.

are largest in the vas deferens, the prostate, and the pregnant uterus.

Smooth muscle-cells are always surrounded by numerous collagen fibrils which bind them together and which appear to be largely responsible for the density and toughness of smooth muscle tissue. The collagen fibrils are not produced by the muscle-cells but by fibroblasts which occur in moderate numbers between them.

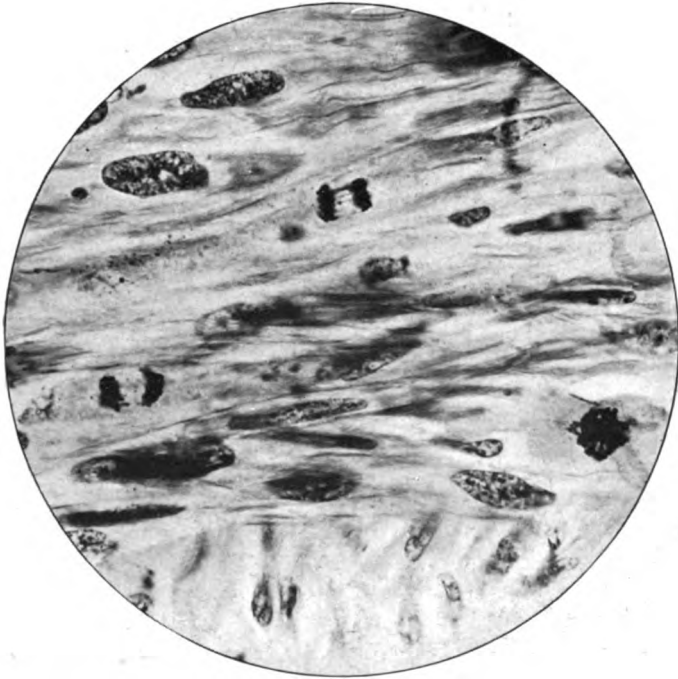

Fig. 219.—Leiomyosarcoma. Three mitotic figures present. M.

Rate of Growth.—Leiomyoblastomas grow at various rates of speed, although generally regarded as of slow growth. They are commonly called leiomyomas, or fibroids by the clinician, and have received no special designation when growing rapidly except that of malignant leiomyoma. The term leiomyosarcoma has been used, but the general feeling is that the use of the word sarcoma should be restricted to the four connective-tissue tumors.

When mitotic figures are present in a leiomyoblastoma the tumor is to be regarded as capable of infiltration and of giving rise to metastases and, therefore, as clinically malignant.

Histologic Appearance.—The cells of a leiomyoblastoma tend to differentiate into smooth muscle-cells. In the slowly growing

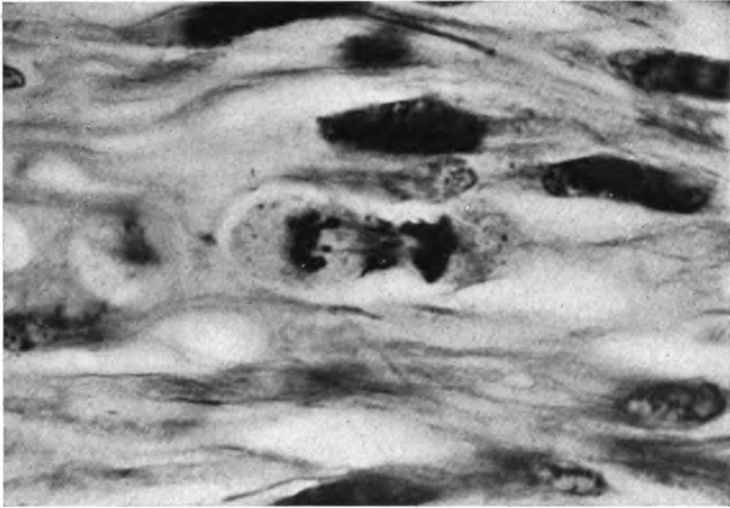


Fig. 220.—Leiomyosarcoma. One cell in mitosis. From spindle-cell portion of tumor. M. and W.

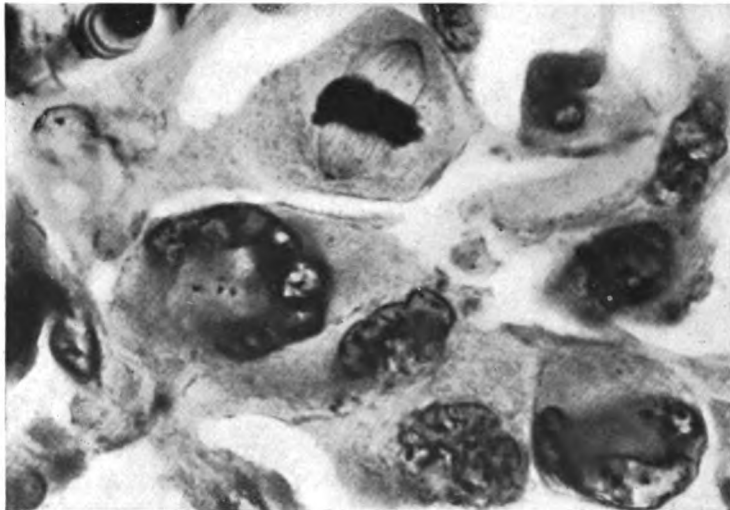


Fig. 221.—Leiomyosarcoma. One cell in mitosis. From round-cell portion of tumor. M. and W.

tumors this readily takes place, but in those which proliferate rapidly the fibrils may be formed only to a slight extent or not at

all and the cells, instead of preserving a spindle shape, may become spherical and sometimes multinucleated.

The stroma of a leiomyoblastoma consists of blood-vessels and of connective tissue. The tumor cells seem able to make large demands on the fibroblasts since these deposit numerous collagen fibrils around every muscle-cell. In time many of the smooth muscle-cells disappear owing to interference with nutrition while the hardier fibroblasts persist. As a result a leiomyoblastoma may come in time to contain more fibroblasts than smooth muscle-cells. It has reached the condition of many a scirrhus cancer.

Gross Characteristics.—Leiomyoblastomas usually form spherical or lobulated tumors, occasionally of large size, and of a reddish gray to white color, and of fairly dense consistence; the greater the amount of stroma present, the whiter the color and the denser the consistence. Beginning necrosis of a leiomyoblastoma in consequence of obstruction of blood-vessels often results in a light to dark reddish coloration. The cut surface of a leiomyoblastoma offers a play of shades, owing to the various angles at which the intertwining strands of cells are cut.

Leiomyoblastomas are of common occurrence, and are frequently multiple, most often in the uterus, occasionally in the skin and elsewhere. They are usually sharply defined and definitely encapsulated so that it is easy to shell them out, but occasionally they infiltrate the surrounding tissue. This is especially true of the more rapidly growing forms which often give rise to metastases. These malignant leiomyoblastomas originate most often in the uterus, but have been found also in the subcutaneous tissue, the kidney, and in other locations. Owing to the elongated spindle shape of their cells they may easily be mistaken for fibrosarcomas.

7. ENDOTHELIOBLASTOMA

(*Angioma, hemangioma, hemangio-endothelioma, endothelioma, lymphangioma, lymphangio-endothelioma, dural endothelioma*)

Definition.—A tumor of mesenchymal origin of which the cells tend to differentiate into flat endothelial cells and to line vessels, cavities and surfaces.

Type Cells.—Three different type cells are recognized under this tumor heading.

1. Endothelial cells lining blood-vessels.
2. Endothelial cells lining lymph-vessels.
3. Endothelial cells lining the arachnoid or subdural space.

The endothelial cells lining the heart and the blood- and lymph-vessels have a common origin and may be considered identical in all respects. The cells lining the subdural space are derived from the mesenchyma at a considerably later period of embryonic

life. They differ in some respects from the other endothelial cells and are usually referred to as dural endothelium, but it is convenient to treat them along with the other types of endotheliomas because they have certain features in common.

The endothelial cell is not morphologically a highly differentiated cell. On this very account, however, it stands out in marked contrast with those cells which are thus characterized when all are properly fixed and stained. It is a large flat cell with a flat oval nucleus surrounded by a moderate amount of delicate cytoplasm. It gives rise to no intercellular substance and its free border develops no cuticular surface. Its function is to cover surfaces. Under normal conditions the endothelial cells lining blood- and lymph-vessels possess marked phagocytic properties and they may desquamate and give rise to endothelial leukocytes, but these characteristics play no part in tumors originating from them.

The three different types of endothelioblastoma will be taken up separately.

HEMANGIO-ENDOTHELIOBLASTOMA

Histologic Structure.—The endothelial cells of a hemangio-endothelioma tend to form blood-vessels as they do under normal conditions. These vessels are backed ordinarily by a slight amount of connective tissue which forms a stroma and binds them together. Sometimes this stroma is quite abundant so that the tumor appears more or less scirrhous in type. The vessels of the tumor carry blood unless something arises to prevent.

The vessels of the tumors may be capillary in type or cavernous, or of any gradation between these two extremes.

The capillary hemangio-endothelioblastoma is relatively common, often congenital, and frequently grows with considerable rapidity. Mitotic figures may be numerous in it. It is always infiltrative in growth. In the skin it surrounds the coil glands and ducts and invades especially lobules of fat-tissue, nerves and muscle tissue. In one instance one of these tumors was confined to a nerve of the wrist; the infiltrated and enlarged nerve was excised on the supposition that it was a tuberculous tendon.

Certain peculiarities of growth occasionally occur in angiomas which it is important to understand:

(a) In the larger vessels the endothelial cells sometimes thicken up into two or more layers. In angiomas with vessel lumina of larger size this piling up of the cells in several layers is occasionally quite a prominent feature. It may affect all the vessels and cause a distinct perithelial type of growth. Mitosis may take place in the cells in any of the layers. In time some of the fibro-

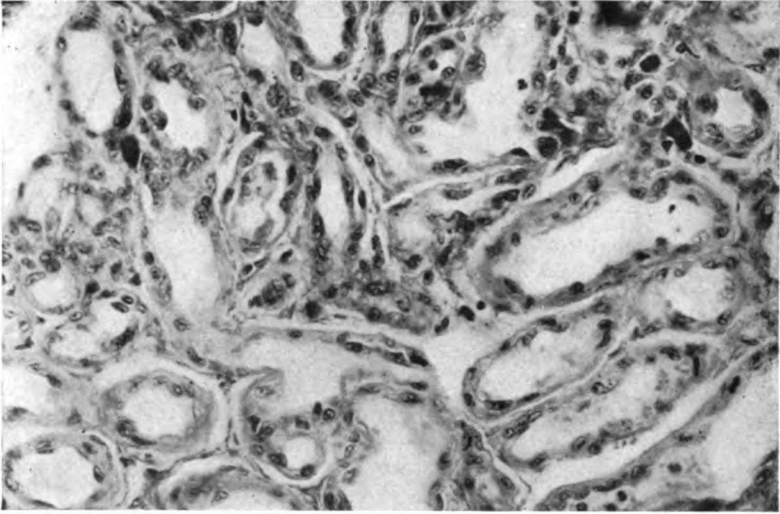


Fig. 222.—Capillary hemangioma of skin. M.

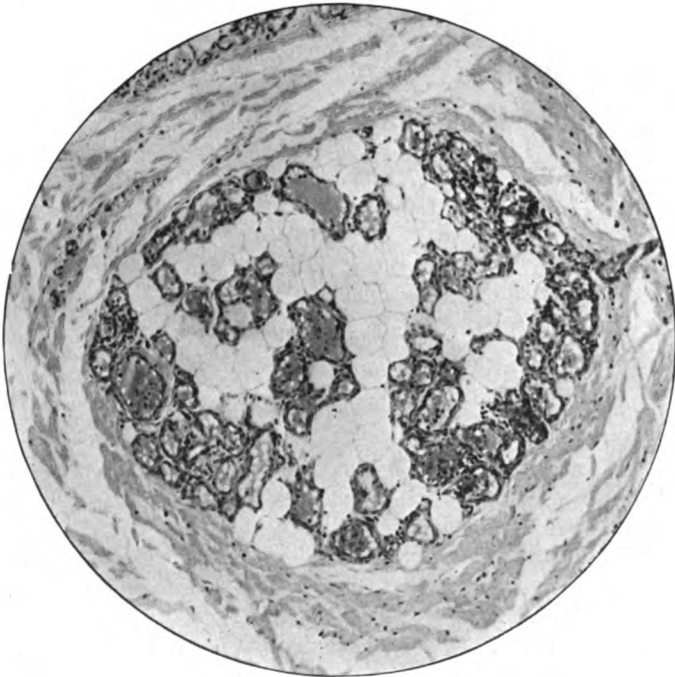


Fig. 223.—Capillary hemangioma invading fat-tissue. M.

blasts around the vessels grow in and deposit collagen fibrils between the endothelial cells.

(b) Rarely, the endothelial cells grow out into the lumina of the vessels in the form of papillary projections in which the endothelial cells sometimes accumulate in concentrically arranged masses or whorls. One tumor of this type started from a vascular nevus of the eyelid, invaded the orbit and destroyed the eyeball. Another, reported by Borrmann, recurred repeatedly at its site of origin beneath the breast after excision, and finally gave rise

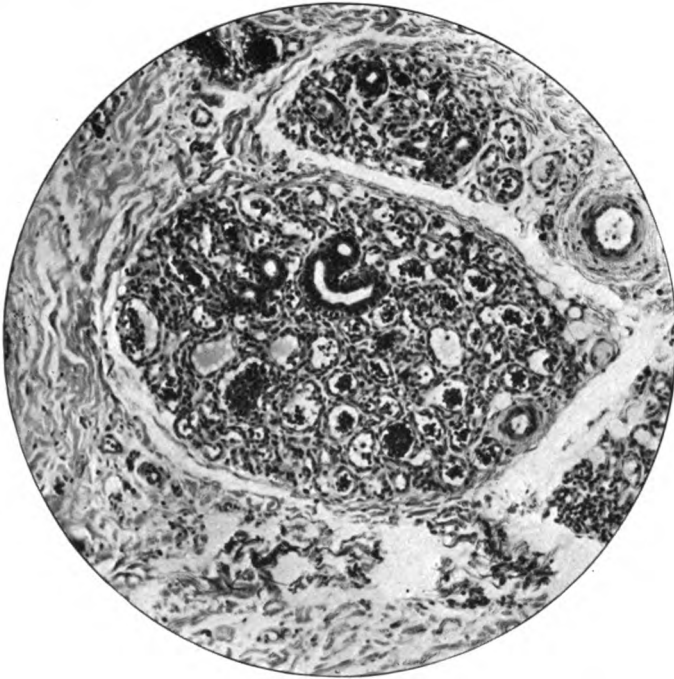


Fig. 224.—Capillary hemangioma invading fat-tissue around a coil gland. M.

to multiple metastases in the lungs. In a third tumor, showing marked perithelial type of growth and forming painful nodules around the ankle, both arteries and especially veins had been invaded; the latter were much distended in consequence of the growth and extension of the tumor within them.

(c) If the capillary vessels are occluded or injured in any way so that blood ceases to circulate in them the endothelial cells continue to proliferate, but as they are no longer connected with the blood stream they do not form vessels. Instead, the cells

collect in rows, groups, and especially in concentric masses or whorls. These collections of cells are gradually invaded by fibroblasts which deposit collagen fibrils between the endothelial cells. They do this probably in response to some influence emanating from the tumor cells, in the same way that a stroma of blood-vessels and connective tissue is furnished to other kinds of tumors. An angioma which has undergone the changes described here may closely resemble a fibrosarcoma, but the endothelial cells possess no fibroglia fibrils. The true nature of the growth is sometimes

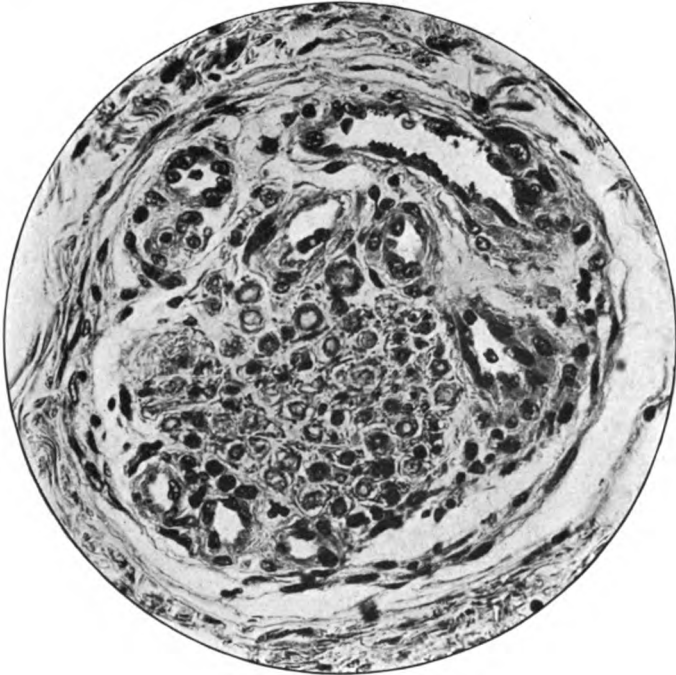


Fig. 225.—Capillary hemangioma invading a nerve. M. and W.

to be recognized only by finding areas at the periphery or in the surrounding fat-tissue where the tumor vessels are intact.

(d) Much fibrous tissue sometimes develops in angiomas so that they may present a scirrhous type of growth. Whether this results from gradual atrophy and disappearance of many of the tumor vessels or whether it is a consequence of some of the changes already described cannot be made out with certainty.

(e) Rarely, after the vessels have become occluded the endothelial cells accumulate fat, and sometimes also blood pigment

from the red blood-corpuscles left within the lumina, and present in gross a yellowish appearance, in consequence of which they have sometimes been called xanthomas.

(f) Very rarely, when the endothelial cells of the vessels thicken up to several layers, those on the outside continue to proliferate and invade the surrounding tissues to a slight extent. Small tumors of this type occur most often in the bend of the elbow.

The cavernous type of hemangio-endothelioma is rare. It is doubtful if the so-called cavernomas of the liver are to be re-

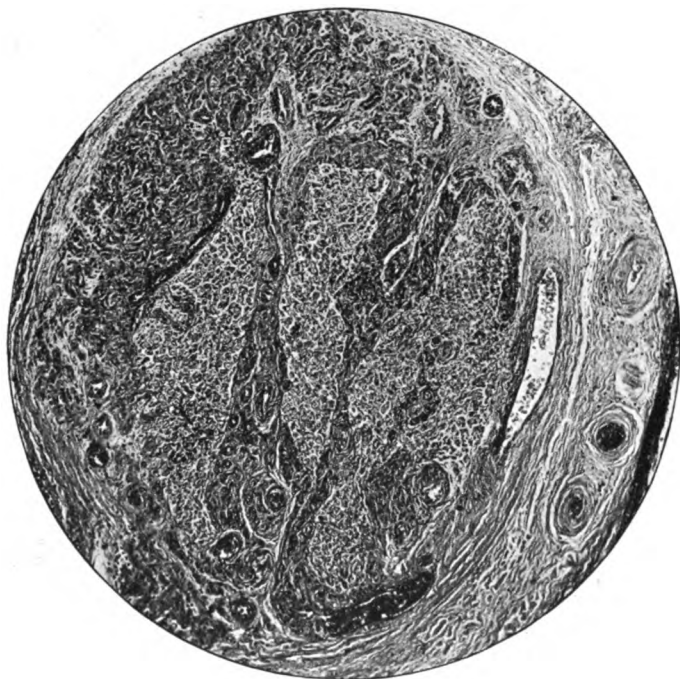

Fig. 226.—Capillary hemangioma invading a nerve. All the darker portions are tumor. M. and W.

garded as true tumors. Those ordinarily found certainly show no evidence of advancing growth. They suggest rather an abnormality of the blood-vessels similar to a vascular nevus of the skin.

The true cavernous tumors consist of large irregular cavities separated by thin non-vascular walls of connective tissue lined on each side with endothelial cells. These partitions have just the structure of the valves in veins. All three of the tumors of this type obtained for study showed the same structure and the

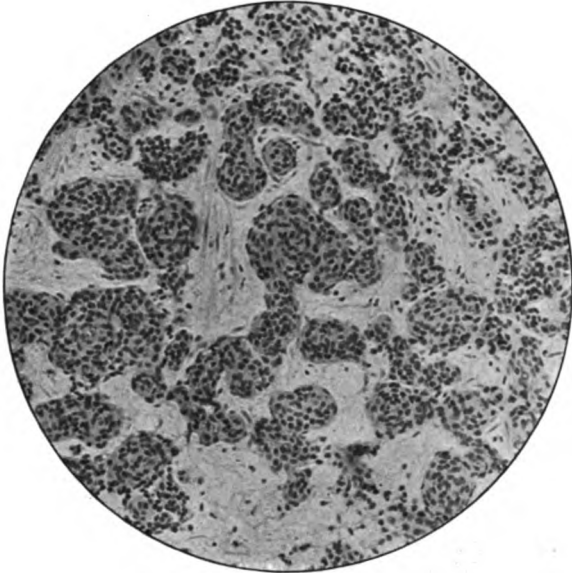


Fig. 227.—Hemangioma of leg. Cells several layers thick in walls of vessels. M. and W.

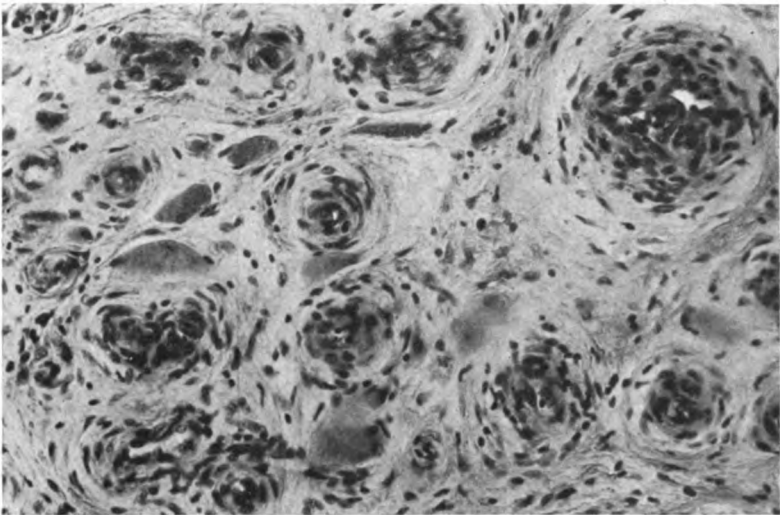


Fig. 228.—Hemangioma of orbit. The endothelial cells tend to form several layers in the walls of the vessels. M. and W.

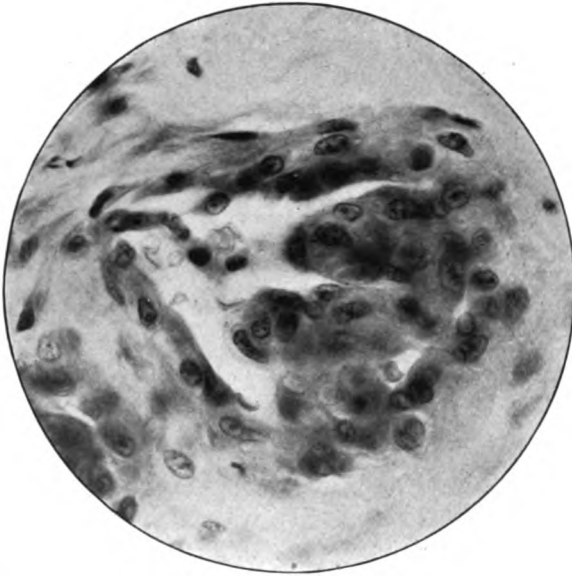


Fig. 229.—Hemangioma of orbit. Papillary masses of endothelial cells project into lumen of vessel. M. and W.

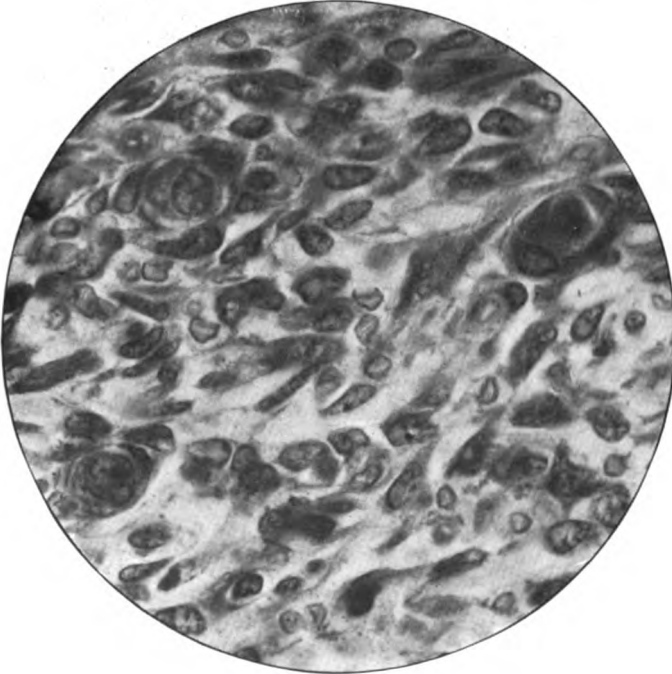


Fig. 230.—Capillary hemangioma growing without lumen formation. Three whorls of cells present. M. and W.

same peculiarities. They were found to be growing and extending within blood-vessels, chiefly the veins. Here and there the tumor leads to great dilatation of the vessels and may break through the wall and invade the surrounding tissue. In this way new secondary nodules may arise at a distance from the primary growth, not by metastasis but by direct extension.

Without much question this form of tumor starts within the larger blood-vessels—that is, veins not capillaries—and grows and extends intravascularly in the form of thin connective-tissue membranes covered with endothelial cells. The starting point of new membranes may occasionally be found; also whorls of

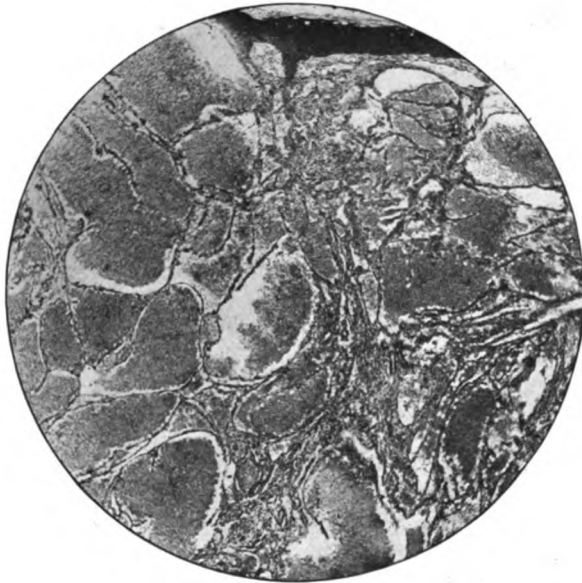


Fig. 231.—Cavernous hemangioma of skin. M. and W.

endothelial cells such as occur in the capillary form of endothelioma when the lumen of a vessel becomes obliterated. When the endothelial cells under either of these conditions form more than one layer, collagen fibrils extend in between the endothelial cells and form a support for them.

Thrombi are of frequent occurrence in this type of tumor. They may become calcified and form phleboliths, or they may become organized. Those found in the late stages of the process of organization may consist entirely of fibroblasts surrounded by fibroglia and collagen fibrils.

Occurrence, etc.—The hemangio-endothelioblastomas are often

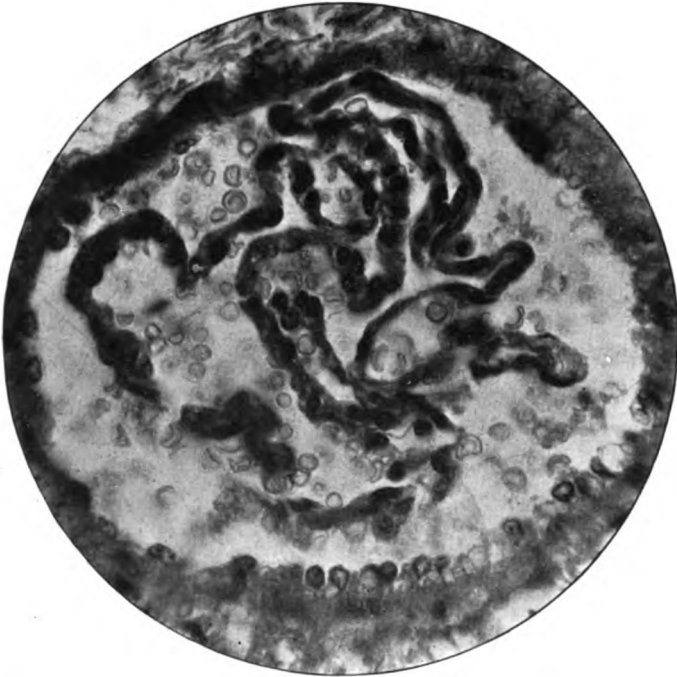


Fig. 232.—Cavernous hemangioma extending within a vein. M. and W.

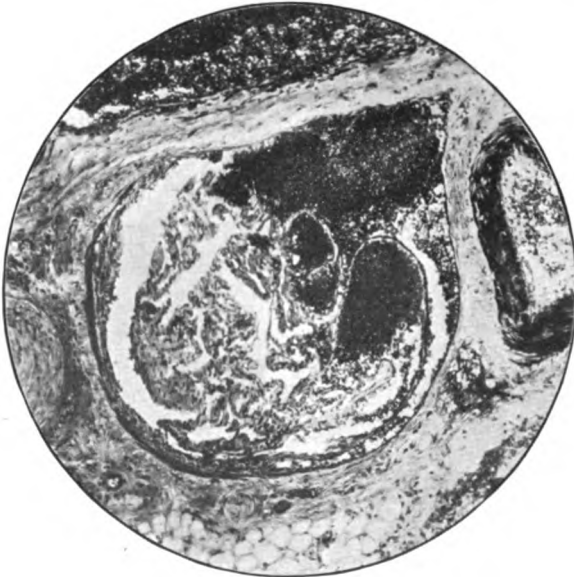

Fig. 233.—Cavernous hemangioma extending within a vein. M. and W.

congenital and frequently, perhaps always, arise from abnormalities of the blood-vessels, especially from vascular nevi. They occur most often in the skin and subcutaneous tissue, but may originate also in muscles, nerves, the liver, spleen, brain, bone marrow, etc. They are to be regarded on the whole as benign growths, although locally destructive, because their manner of extension is by infiltration of surrounding tissues and by growth within and along blood-vessels. Apparently but one case of metastasis is on record.

Gross Characteristics.—The hemangio-endothelioblastoma presents marked variations in size. In one instance a rapidly-growing tumor of the capillary type involved the lower half of the face, while

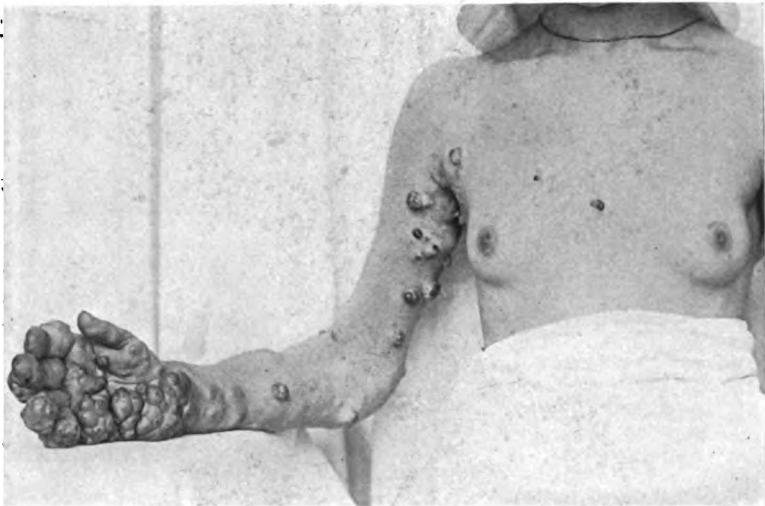


Fig. 234.—Cavernous hemangioma in a girl fourteen years old.

the cavernous example pictured here extended from the axilla, where it started, to the hand and also on to the front of the chest.

The tumor may be level with the surface or form one to many nodular projections. The color varies from light red to the deepest purple. On pressure the nodules are comparatively soft and the blood can usually be forced temporarily out of them.

LYMPHANGIO-ENDOTHELIOBLASTOMA

The cells of a lymphangio-endothelioblastoma tend to form lymph-vessels. True tumors arising from the endothelium lining lymph-vessels are rare and the means of recognizing them are not so sure and reliable as in the case of the hemangio-endotheliomas.

Dilatation of pre-existing lymph-vessels does not constitute a true tumor formation.

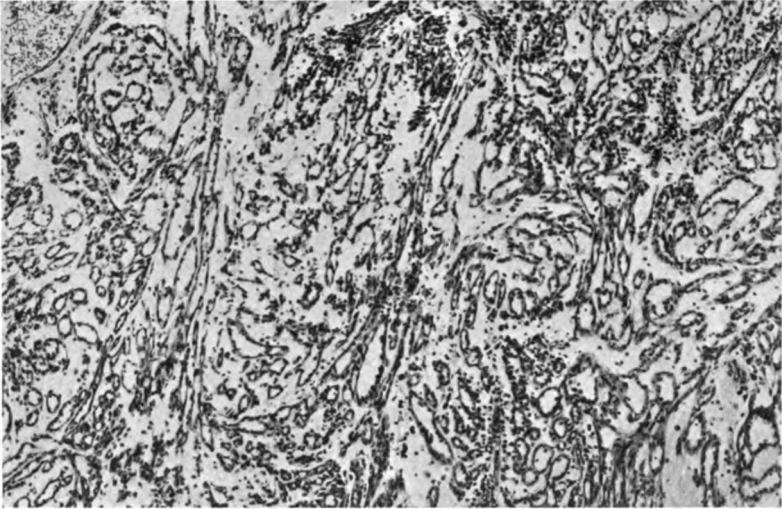


Fig. 235.—Lymphangio-endothelioblastoma (lymphangioma). M. and W.

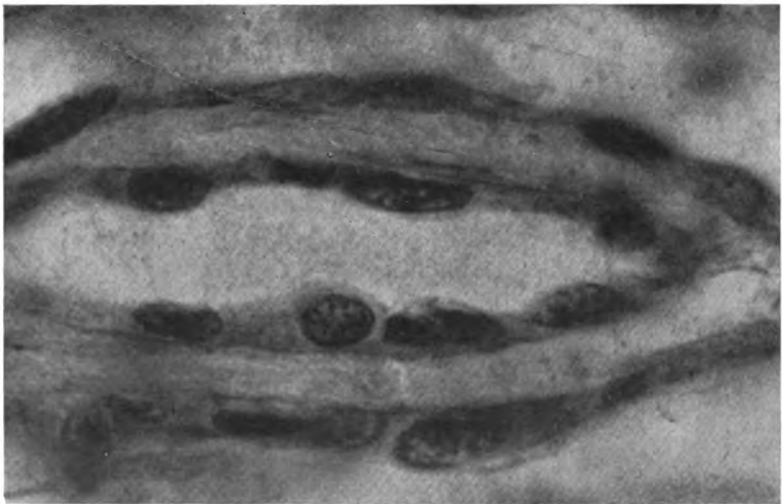


Fig. 236.—Lymphangio-endothelioblastoma (lymphangioma). M. and W.

Lymphangio-endotheliomas are composed of irregular cavities of various sizes communicating with each other and lined with

flat endothelial cells. The cavities contain a serous secretion. Two tumors of this type, one occurring retroperitoneally and the other in the wall of the uterus, both showed areas of a more solid appearance where spherical cells were becoming hollowed out. The vacuoles thus formed coalesced into lumina, while the cells flattened out and formed a wall for them.

True lymph-vessel tumors are rare. They occur in the skin, in the connective tissue in various locations, and very rarely in the different organs, such as the spleen, uterus, etc. Organization of a peritoneal exudate with cyst formation by mesothelial cells which have not been destroyed has unquestionably been mistaken more than once for a lymphangioma. In a similar manner marked dilatation of the lymph-vessels of the intestinal wall may suggest tumor formation.

Gross Characteristics.—They may form very definite tumor nodules, sometimes of large size, which on section are gray, translucent, sometimes of a spongy appearance and very moist owing to the escape of the serous contents of the vessels and cysts.

DURAL ENDOTHELIOBLASTOMA

The type cell of a dural endothelioblastoma varies considerably in the different tumors. It may be very large and thin, or more compressed and thick, even approaching sometimes a cubical epithelial cell in form. Occasionally, the cytoplasm shows a very finely fibrillar structure.

The tumor cells are ordinarily grouped in small or large masses with a slight connective-tissue stroma containing blood-vessels between them, an alveolar arrangement; but sometimes the tumor and its stroma are intimately blended together so as to present the appearance of a fibrosarcoma. This blending occurs when growth is slow and the fibroblasts have time to grow in between the tumor cells and deposit collagen fibrils as a backing for them.

The cells of a dural endothelioblastoma tend to cover a surface. Under various pathologic conditions, aside from tumor formation, the dural endothelial cells often proliferate, thicken up into layers, and form small and large concentric masses of cells. Such cell accumulations are not uncommon around the pituitary body and may often be found scattered over the surface of the pia. A similar tendency in the manner of growth is often exhibited by the cells in a dural endothelioma and is fairly characteristic. The cells incline to wrap around each other so as to form single and multiple, small and large concentric masses or whorls. These whorls may be exceedingly numerous or entirely absent. The cause of their formation is not evident. Cells simply apply themselves to the surface of one or more other cells which form the center.

When a dural endothelioma invades the dura, as not infrequently happens, the tumor cells sometimes apply themselves to the surface of strands of collagen fibrils, especially when the fibroblasts caring for them have undergone necrosis. Under these conditions the whorls may be of various shapes, spherical, elongated, irregular. The centers of them may contain one or several masses of collagen fibrils which gradually undergo a hyaline transformation. These two types of whorls may occur together.

A third type of whorl also occurs. This is due to a commingling of dural endothelial cells and of fibroblasts either as the result of



Fig. 237.—Dura of spinal cord in five months' fetus. Dural endothelium at bottom not yet split into two layers.

invasion of connective tissue by the tumor-cells or the ingrowth of the fibroblasts into the tumor cell masses. Both processes occur. In this third type the center of the whorl is formed by one or more endothelial cells around which one or more fibroblasts deposit a spherical shell or capsule of collagen fibrils. Compound whorls also occur owing to several centers of whorls starting close together in contact with the same clump of fibroblasts. After a certain length of time the endothelial cells in the center of these whorls may undergo necrosis and disappear.

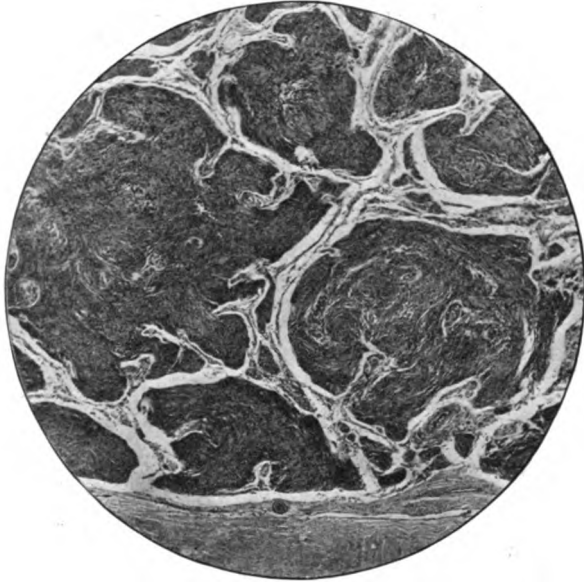

Fig. 238.—Dural endothelioma. Cells form large whorls. Dura at base of picture. M. and W.

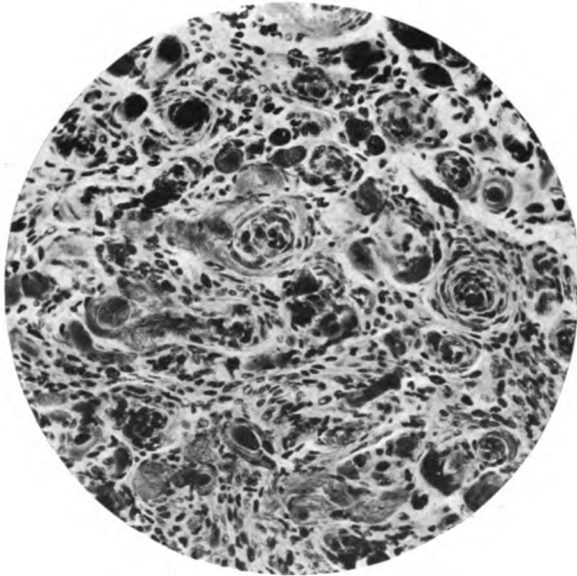

Fig. 239.—Dural endothelioma containing numerous whorls formed around hyaline masses of collagen fibrils. M.

One other feature more or less characteristic of dural endotheliomas is a gradual hyaline transformation of many of the concentric whorls of cells. This feature is sometimes especially prominent when the dura is invaded because, as already mentioned, the strands of connective tissue surrounded by the tumor cells are often the first to undergo necrosis and hyaline transformation. As a result hyaline beams and irregular masses of various shapes may be formed as well as the ordinary spherical balls. Rarely, the walls of small blood-vessels thicken up and are transformed in the same way into hyaline material.

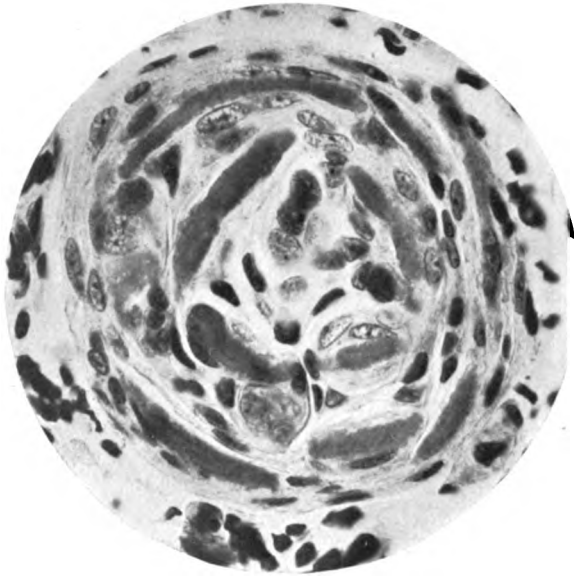


Fig. 240.—Dural endothelioma. A whorl of cells enclosing hyaline masses of collagen fibrils. M.

Lime-salts may be deposited in these hyaline masses so that the tumor on section feels sandy to the touch.

This form of tumor, although usually regarded as benign, shows a marked tendency to invade the dura and infiltrate it more or less extensively. Instances have been reported of extension through the skull. On the other hand, although it exerts a good deal of pressure internally as it grows, and causes atrophy of the nervous tissue on which it presses, it very rarely shows any tendency to invade the pia. While invasion of the dura indicates a slight degree of malignancy, metastases apparently never occur.

The tumors grow at various rates of speed. Occasionally,

mitotic figures are fairly numerous, but most of the tumors are of slow growth.

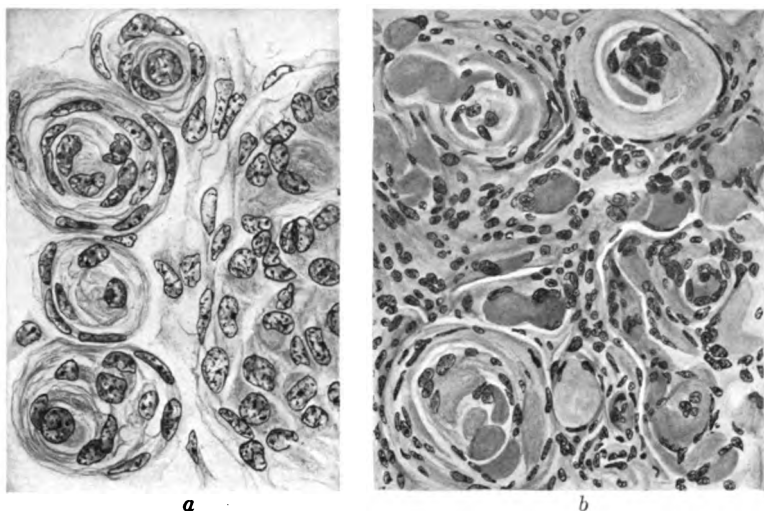


Fig. 241.—Dural endothelioma. *a*. Whorls of endothelial cells and fibroblasts; *b*, whorls of endothelial cells around (necrotic) hyaline masses of collagen fibrils.

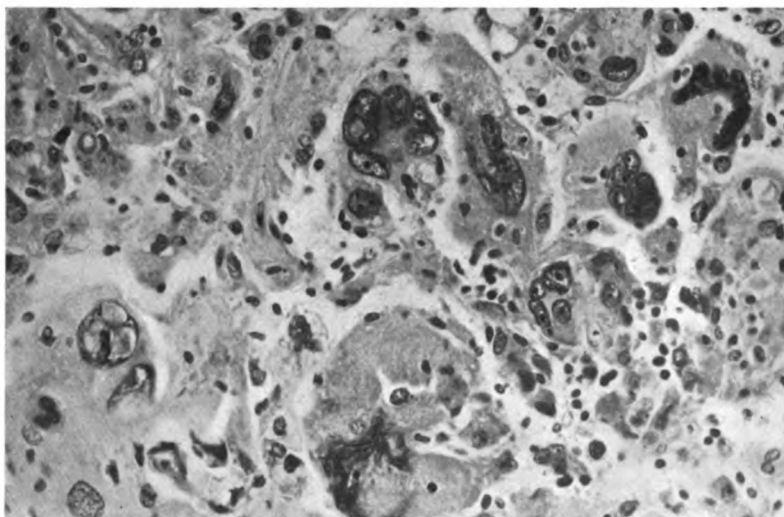


Fig. 242.—Dural endothelioma. Several true tumor giant-cells present. M.

The dural endothelioma is necessarily limited in its site of origin. Usually it arises from the endothelium lining the dura

but occasionally from the endothelium covering the pia arachnoid. The tumor is much more common within the skull than in the spinal canal.

It occurs most commonly in the vault of the skull, but may arise also anywhere at the base.

Gross Characteristics.—Dural endotheliomas are usually small, a few centimeters in diameter, but occasionally they reach a large size; thus, for example, one weighed a little over 200 grams; another in the right occipital lobe measured 8.5 by 6 by 6 cm. Occasionally, they are multiple.

They tend to be spherical in shape but sometimes are irregular or lobed; if they are attached to the dura, they are more or less flattened on one side and sometimes hemispherical.

In color they vary from reddish gray to gray or white according to their vascularity.

Some are soft in consistence and easily teased apart; others tough or firm.

When the hyaline concentric masses are calcified, the tumors feel sandy or gritty. On this account they have sometimes been called psammomas. This term is inexact and inadvisable, however, because it simply has reference to a physical condition which may occur also in tumors of other nature.

8. LYMPHOBLASTOMA

(*Lymphocytoma, lymphoma, lymphosarcoma, pseudoleukemia, lymphatic leukemia, Hodgkin's disease*)

Definition.—A tumor of mesenchymal origin of which the cells tend to differentiate into lymphocytes, that is, into cells of the lymphocyte series.

Type Cell.—The type cell is the lymphoblast. It occurs abundantly in the germinative centers in the lymph nodules of the lymph-nodes, the tonsils, the gastro-intestinal tract and the spleen.

The lymphoblast under normal conditions passes by slight degrees of differentiation of nucleus and cytoplasm through intermediate stages, to which the term lymphocyte is applied, to the end product known as the lymphoid cell. In the mucous membrane of the intestine it appears in another form called the plasma cell. Under pathologic conditions plasma cells may be formed in large numbers anywhere from lymphocytes and even rarely from lymphoblasts.

The various forms of cells derived from the lymphoblast are sometimes all classed together as lymphocytes or are spoken of as cells of the lymphocyte series.

The different cells of the lymphocyte series vary considerably

in size and in other features. In general they are comparatively small round cells. The lymphoid cell is the smallest of the series and represents the end product of differentiation. It is probably incapable of undergoing mitosis. All the lymphocytes possess the power of ameboid motion, but they are never phagocytic for foreign particles of any sort or for other cells.

The nuclei are round, relatively large, and contain rather coarse chromatic granules, located for the most part at the periphery. As a rule, the nucleus lies a little eccentric in the cytoplasm.

The cytoplasm tends to be basophilic. This property is especially prominent in the plasma cell. Near the nucleus on

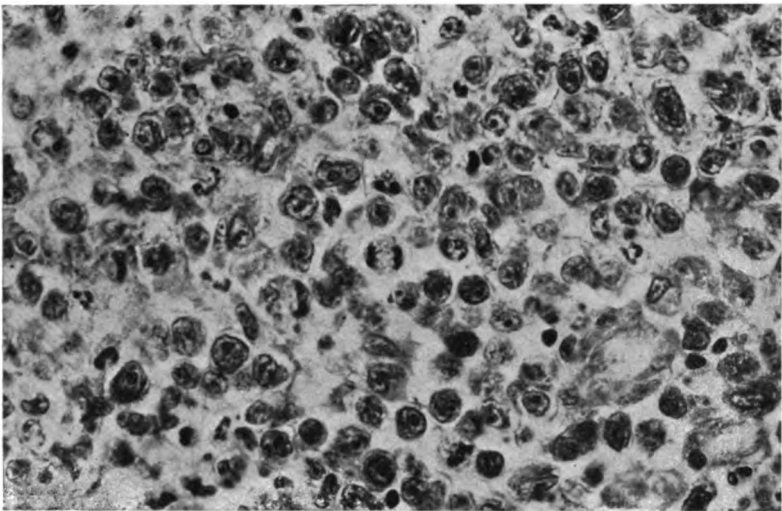


Fig. 243.—Lymphoblastoma growing rapidly. M.

the side where the cytoplasm is most abundant is a small crescent-shaped, acidophilic area in which the centrosomes lie. Under normal conditions certain minute, rod-shaped granules, stainable by special methods, can be demonstrated in the cytoplasm near the nucleus (Schridde). They do not appear, however, in tumor cells derived from the lymphoblast, hence they do not possess diagnostic value.

It is evident that the characteristics of the cells of the lymphocyte series are not particularly striking even under normal conditions. They are even less so in the tumors originating from lymphoblasts because the cell differentiation is rarely perfect.

Histologic Appearance.—The cells of a lymphoblastoma tend

to differentiate into cells of the lymphocyte series, but so far as known they never form plasma cells. They may come very close, morphologically, to the pre-lymphocytes, lymphocytes and lymphoid cells or depart widely from them, but it seems probable

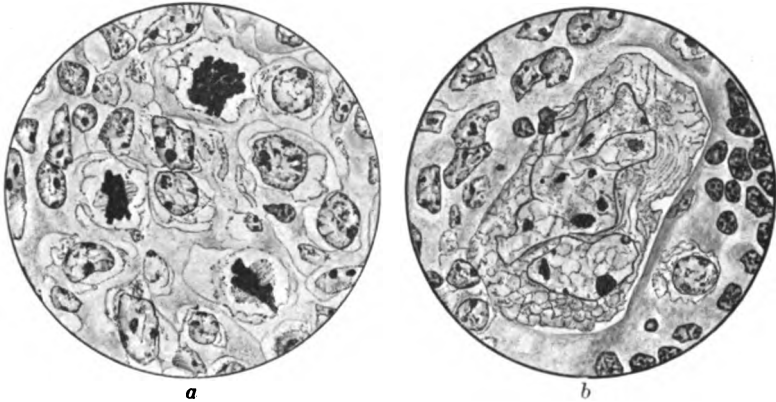


Fig. 244.—Lymphoblastoma growing rapidly. *a*, Three mitotic figures present; *b*, large lobulated tumor-cell.

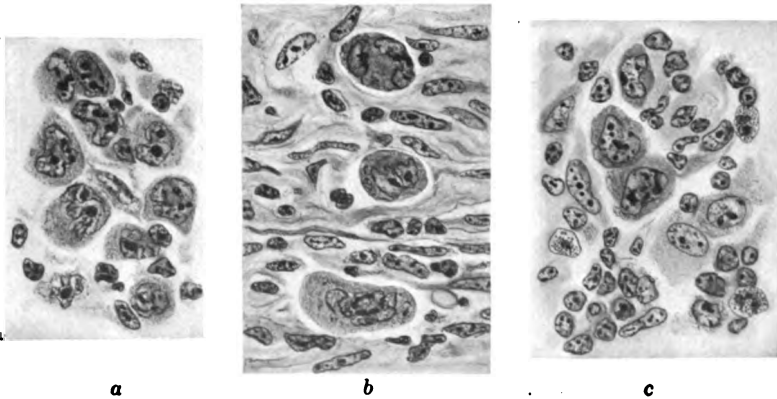


Fig. 245.—Lymphoblastoma, scirrhus type. Often called Hodgkin's disease and regarded as an infectious process.

that they always retain their physiologic property of ameboid motion.

In some of the tumors, cells of large size, with large lobulated or multiple nuclei, often occur. They arise by mitosis which is frequently multiple, and, although they sometimes resemble to some extent the endothelial cells occurring in normal lymphoid

tissue, are unquestionably true tumor cells of lymphoblastic origin. On the other hand, endothelial cells are commonly present, as in normal lymphoid tissue, and often exhibit marked phagocytic properties, incorporating and digesting numerous tumor cells.

The lymphoblastoma is an infiltrative tumor, therefore its stroma is furnished by the organ or tissue it invades. In some tumors the stroma is of the slightest, consisting chiefly of capillary blood-vessels accompanied by a minimum of connective tissue, usually in the form of a reticulum. As the invaded organs enlarge the stroma may be increased by proliferation of fibroblasts and probably by the formation of new blood-vessels.

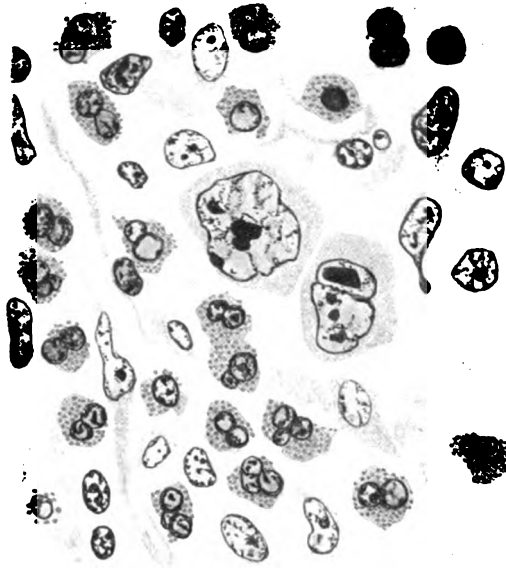


Fig. 246.—Lymphoblastoma. Scirrhus type of tumor; only two tumor-cells present; numerous eosinophiles.

Sometimes the tumor cells arouse marked reaction on the part of the fibroblasts, so that the latter multiply exceedingly just as they often do in certain forms of carcinoma. This noticeable increase of connective tissue is most common in the slowly-growing scirrhus type of lymphoblastoma. At the same time there is often an abundant inflammatory infiltration with eosinophiles and plasma cells. This type of tumor may sometimes so closely resemble inflammatory tissue that it is often regarded as a chronic infectious process. Its distinguishing feature is the presence of

tumor cells, often in very small numbers, which are different from any cell found in chronic inflammatory processes.

Origin and Occurrence.—The lymphoblastoma probably originates from a single cell, a lymphoblast. Cells of this type occur in nearly all parts of the body, but are most common in the various lymph-nodes and in the lymph-nodules of the gastro-intestinal tract and spleen. On this account the lymphoblastoma may originate in various localities wherever lymphoid tissue exists, as, for example, in the cecum or spleen, but it starts most commonly in lymph-nodes, especially in those in the cervical, axillary and inguinal regions and in the mediastinum.

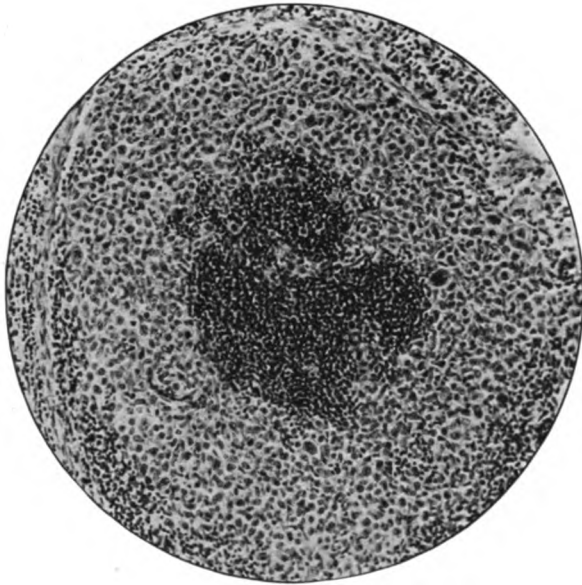


Fig. 247.—Lymphoblastoma of lymph-node invading and destroying a lymph-nodule. M. and W.

The tumor cells spread rapidly from one node to another so that all in a given region often seem to be involved at once, but careful study of early cases shows that the tumor spreads from one point, probably from a single cell or perhaps from a small group of them, just as a cancer does. The tumor cells infiltrate the parenchyma and the lymph sinuses of the lymph-nodes and very quickly destroy all landmarks. Sometimes it is possible to discover the advancing edge of infiltration within a node and observe how it spreads. As a rule, a lymphoblastoma remains within the capsule of the lymph-node but it may infiltrate it and spread to

the surrounding fat and muscle-tissues. It extends to other lymph-nodes chiefly through the lymphatics.

Rate of Growth.—Some lymphoblastomas grow very rapidly; others very slowly; all variations in rate of growth between the two extremes occur. The rapidly-growing tumors are readily recognized as such. Those which grow slowly are sometimes mistaken for a chronic inflammatory process and have been regarded as of infectious origin. The reason for the error is the comparatively small number of tumor cells often present and the marked inflammatory reaction which they induce.

Gross Characteristics.—When a lymphoblastoma involves a group of lymph-nodes it leads to marked enlargement of them. The packet of nodes formed is frequently the size of the fist, or larger. The separate nodes are often distinct but may be obscured by tumor infiltration of the surrounding tissues. On section, the tissue usually appears gray and translucent and more or less friable, but may be tough and fibrous owing to the formation of much dense connective tissue.

Retrograde Changes.—It is not uncommon for foci of necrosis to occur in the lymphoblastoma. They are probably due to obstruction of the small blood-vessels either by pressure or by tumor thrombus formation within them. These foci of necrosis, especially when they are present in the slowly-growing tumors, sometimes suggest gummas.

Diagnosis.—The diagnosis of a lymphoblastoma must be based, just as with other varieties of tumors, on the character of the tumor cells, not on that of its stroma or on the kind of cellular exudation which it sometimes calls forth.

Metastasis.—The cells of the lymphocyte series normally migrate into the lymph-vessels and in this way, and probably also to some extent by direct ameboid action, gain entrance to the blood stream. It is not surprising, therefore, that the cells of a lymphoblastoma quickly invade the lymph-vessels of the organ, usually a lymph-node, in which it starts. It is in consequence of quick and early metastasis of the cells from one lymph-node to another that the tumor so commonly involves a whole chain of lymph-nodes and suggests thereby a multiple origin in a given region; but the same rapid spread may be observed when another group of lymph-nodes becomes involved.

Tumor cells in the lymphatics are often carried into the blood stream and in this medium are transported all over the body. They may emigrate at any point from the vessels into the tissues and in this way form metastases in various organs, but especially in the spleen, liver, kidneys and bone marrow. They may give rise to diffuse infiltrations or to more or less discrete tumor nodules.

Not infrequently, however, many of the cells, finding conditions favorable for growth in the blood, remain there and multiply. With other tumor cells, except those derived from myeloblasts, this does not occur. Neither does it always occur with the lymphoblastoma. Apparently those tumor cells succeed best which are nearest in character to the normal lymphocytes. This condition of the growth of the cells of a lymphoblastoma in the circulating blood is commonly called lymphatic leukemia. It is really a circulating tumor metastasis.

The cells of a lymphoblastoma causing lymphatic leukemia may gain access to the blood through the lymphatics by way of

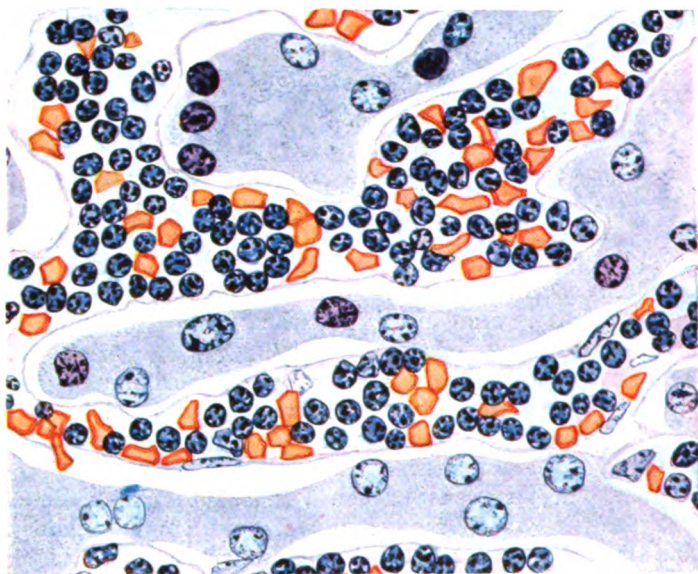


Fig. 248.—Lymphoblastoma (lymphatic leukemia). Tumor-cells in blood-sinuses of liver.

the thoracic duct, by immigration into the blood-vessels, or by direct growth of the tumor through the vessel wall into a vein or artery. From a tumor thrombus formed in this manner the cells readily escape, often in large numbers, into the blood stream. Clinical observations have shown that the tumor cells sometimes make their appearance in the blood in successive crops.

Sometimes a lymphoblastoma seems to start from the beginning in the circulation as a lymphatic leukemia; at least in certain instances no tumor mass can be found anywhere as a starting point.

Lymphatic leukemia occasionally runs a very rapid course

of only a few weeks' duration and may in this way simulate an acute infectious process.

The lymphoblastoma appears under various forms and is known by a number of different names, such as lymphoblastoma, lymphoma, lymphocytoma, lymphosarcoma, small round cell sarcoma, pseudoleukemia, lymphatic leukemia, Hodgkin's disease. This variety of names is partly the result of the different clinical pictures presented by the tumor as the consequence of location, rapidity of growth and manner of spreading, and partly the result of the lack of distinctive peculiarities which would render the exact nature of the tumor recognizable under all conditions.

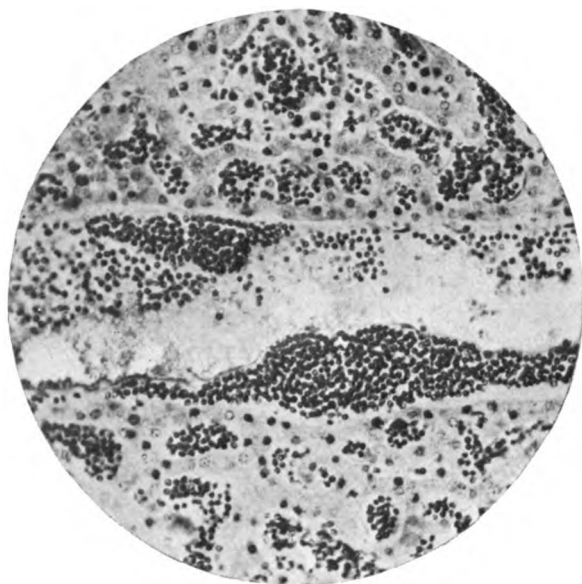


Fig. 249.—Liver. Lymphatic leukemia. Masses of lymphocytes beneath lining endothelium of a central vein. M.

Hodgkin's disease is a term of clinical origin applied to a certain symptom complex or syndrome, namely, to a marked chronic enlargement of the lymph-nodes of the neck.

The nature of the affection is various. The quickest, and in fact the only, reliable way in which to make an exact diagnosis is to excise a lymph-node in each individual instance and make a microscopic examination. Sometimes it is advisable to inoculate a guinea pig with some of the tissue at the same time.

The diagnosis frequently turns out to be tuberculosis; rarely it is due to metastasis from an unrecognized tumor in the im-

mediate neighborhood (thyroid, esophagus, carcinoma of branchial cleft origin) or at a distance; most often it is a lymphoblastoma, usually of the slowly-growing scirrhus type. Tuberculosis and lymphoblastoma may occur in the same lymph-nodes.

The scirrhus type of lymphoblastoma is regarded by many as a chronic infectious process and not as a new-growth. It is also regarded as the typical lesion of Hodgkin's disease. Therefore the term Hodgkin's disease is extended and sometimes applied to this type of lesion wherever it occurs; for example, primary Hodgkin's disease of the spleen.

The term Hodgkin's disease is inexact and should not be used. It always covers ignorance of the true nature of the lesion.

9. MYELOBLASTOMA (MYELOGENOUS LEUKEMIA; CHLOROMA)

Introduction.—The myeloblastoma is a fairly common and very important tumor which has been generally recognized as such only within recent years. The usual form under which it appears is as myelogenous leukemia. Rarely, it occurs in another form known as chloroma, the green-colored tumor.

Type Cell.—The type cell of the myeloblastoma is the myeloblast of the bone marrow and its derivatives. In its undifferentiated form this cell is not sharply characterized morphologically. It resembles a large lymphocyte. From it by multiplication and differentiation arise first the three types of myelocytes with acidophilic, basophilic or neutrophilic granular cytoplasm, and later the three forms of polymorphonuclear leukocytes (eosinophile, mast-cell, and polymorphonuclear leukocyte or neutrophile).

The cells of a myeloblastoma tend to differentiate in the same way as do the cells derived from the myeloblast under normal conditions. If the tumor grows slowly the differentiation is more or less perfect, but if the cell multiplication is rapid the characteristic granules in the cytoplasm may be only partially formed. Under this condition the recognition of the tumor by morphologic characteristics only may be difficult or open to doubt. Fortunately, there are two reactions of a biologic or chemical nature which aid in the recognition of the myeloblast and its derivatives.

These cells develop and contain in their cytoplasm an oxidizing substance. This oxidase can be demonstrated most satisfactorily by the indophenol synthesis test, which stains blue the cells containing it. Lymphocytes and most other cells do not give the reaction.

The myeloblast also shows, when properly tested, the presence of a proteid splitting enzyme which acts in an alkaline medium. Lymphocytes tested in this way are always negative.

Origin.—The myeloblastoma probably always starts in the

bone marrow, although it is theoretically conceivable that the cell from which the tumor originates might be circulating in the blood and the tumor start wherever the cell happens to be, as occasionally occurs in the case of the chorionepithelioma and possibly of some other types of tumor.

The early beginning tumor in a bone is not exposed to examination and it produces no physical symptoms which call attention to its location. Moreover, owing to the rapidity with which the cells of a myeloblastoma enter the circulation and are carried all over the body, and the readiness with which they infiltrate the

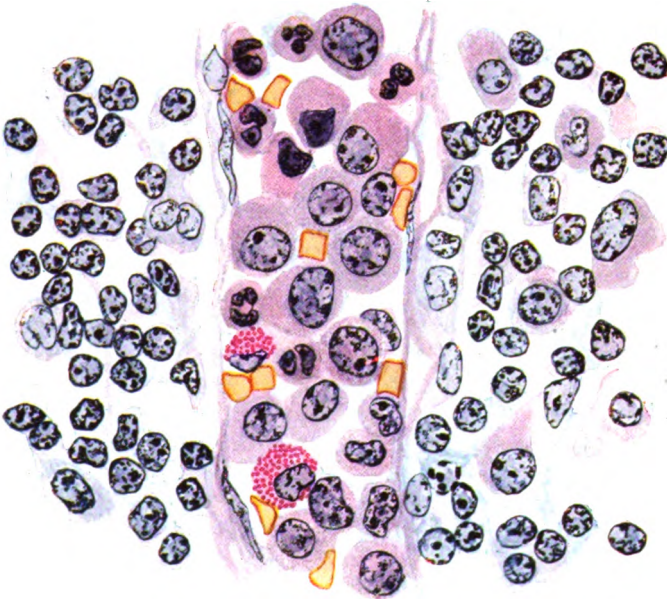


Fig. 250.—Myeloblastoma (myelogenous leukemia). Tumor-cells in blood-vessel in bone marrow.

bone marrow everywhere and develop there, it is probably impossible ever in any given instance to state in the marrow of which bone the tumor started.

Metastases.—As already stated the cells of a myeloblastoma quickly invade the blood and, owing to the nature of their origin, find conditions there favorable for further development. In other words, they become a circulating metastasis of which the cells continue to multiply in the blood. No other cell except the lymphocyte is capable, so far as we yet know, of developing under

similar conditions. The cells of other tumors get into the blood, but they do not continue to proliferate and circulate there.

The circulation of the cells of a myeloblastoma in the blood naturally causes great increase in the number of white corpuscles, so that they run up from the normal proportions of 8,000 to 12,000 per cubic millimeter into the hundreds of thousands and even into the millions, equaling or exceeding the number of red blood-corpuscles. The condition has long been known as *myelogenous leukemia*. If the cells of the tumor are proliferating slowly many of them have the opportunity to differentiate into fully developed leukocytes. The proportions of the three types vary greatly in different instances.

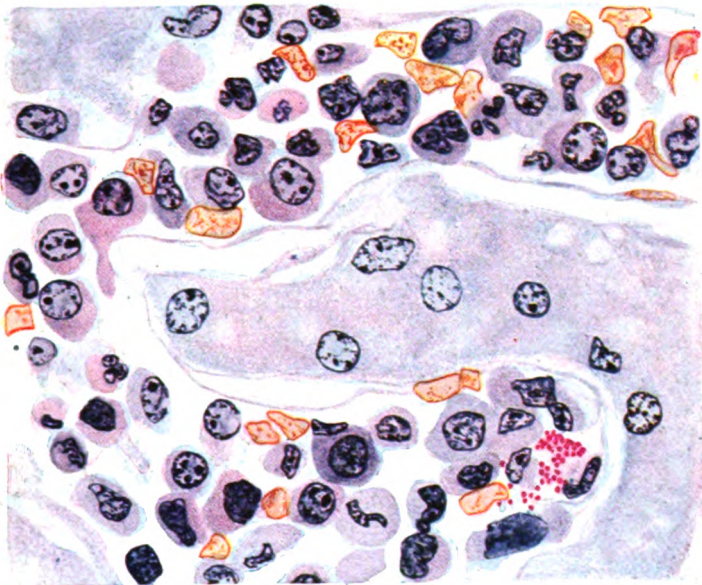


Fig. 251.—Myeloblastoma (myelogenous leukemia). Tumor-cells in blood-sinuses of liver.

When the tumor is growing rapidly the cell differentiation may be slight. Cases with cells of this type have unquestionably been regarded as lymphatic leukemia with cells of a large size.

From the circulating metastasis in the blood the tumor cells may invade various organs in the body. Thus they quickly infiltrate the marrow of all the bones and thereby suggest a primary disease of the blood-producing tissues, the view formerly held. Probably the invasion is always very uniform, but it may not be. Careful examination of many bones in cases coming to autopsy at an early stage of the process might throw light on this point.

In the spleen the infiltration is often very extensive and apparently always uniformly distributed. If the cells were only in the blood stream the spleen would be no larger than in congestion. Instead it often reaches a large size and weighs many kilos (one to eight). The tumor cells emigrate from the blood-vessels, infiltrate the tissues between them and multiply there in great numbers. The increase in weight of the spleen represents simply tumor growth. When the spleen is much enlarged the clinicians often apply the term splenic myelogenous leukemia to the case.

The liver also often attains a large size and may weigh five or six kilos. Here again the increase in weight represents tumor

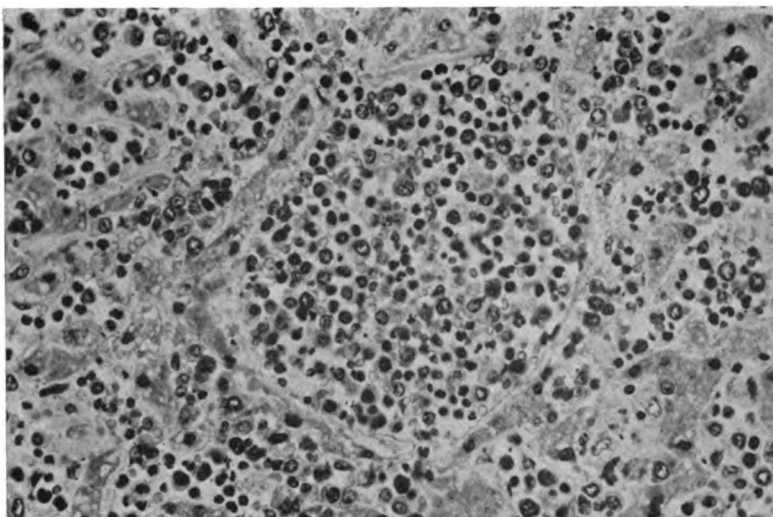


Fig. 252.—Myeloblastoma (myelogenous leukemia). Tumor cells in the blood in the central vein and adjoining sinusoids of a lobule of the liver. M.

growth. The cells infiltrate, especially throughout the periportal connective tissue.

Besides the metastases in the blood, bone marrow, spleen, and liver, certain other organs, such as the lymph-nodes and the kidneys, may be invaded and the cells may even extend from a lymph-node into the surrounding fat-tissue.

As a rule, the myeloblastoma is a slow-growing tumor and the cells tend to differentiate more or less perfectly into myelocytes and the various polymorphonuclear leukocytes. Occasionally, however, the tumor develops rapidly and the cells differentiate but little. They resemble large lymphocytes and have un-

questionably been mistaken for them. The cells also act more like other tumor cells and may give rise to multiple tumor nodules in various parts of the body; for example, in the kidneys, lungs, brain, within the dura, etc. They also commonly form masses along the vertebral column, sternum and other bones, apparently owing to direct extension from the bone marrow into the periosteum which is elevated and infiltrated.

In connection with the rapidly-growing myeloblastoma one point not yet touched on must be taken up and that is the color of myeloblasts when massed together. If the blood from a case of so-called myelogenous leukemia is rapidly centrifugalized after withdrawal, with as little exposure to the air as possible, it will be found that the layer of leukocytes presents a greenish yellow color; the greater the proportion of undifferentiated myeloblasts, the greener the color.

In the cases of rapidly-growing myeloblastoma the tumor masses and the areas of infiltration usually appear light to dark green, owing to the presence of numerous undifferentiated myeloblasts. The color is readily masked by blood; on this account the bone marrow often shows no evidence of a green color. The presence of much connective-tissue stroma appears to have a similar effect.

Tumor nodules presenting a greenish color have been termed *chloroma*, and regarded as a definite pathologic entity. It is only within a few years that their relation to myelogenous leukemia has been recognized.

The green color is very evanescent. It disappears in about ten minutes on exposure to the air. If the tissue is treated with peroxid of hydrogen the color will return almost immediately, but soon fades again. The test works also on tissue long preserved in formaldehyd.

Diagnosis.—The presence of a myeloblastoma is recognized by the examination of the blood. The circulating metastasis (the leukemia) has always and necessarily attracted more attention than the primary tumor. Enlargement of the spleen and liver naturally throw much light on the spread and development of the pathologic process. The condition known as chloroma should be suspected if the symptoms are acute and the blood examination shows many undifferentiated myeloblasts. The diagnosis of chloroma during life has been made from the presence of green nodules in the skin or elsewhere.

10. MYELOMA

Definition.—A tumor, undoubtedly of mesenchymal origin, which arises only within the bone marrow and which is peculiarly characterized by causing the presence of albumose in the urine.

Type Cell.—The type cell of this tumor has not yet been determined. Evidently it does not belong to the myeloblast series of cells because it does not differentiate like them. Moreover, the myeloma is never associated with myelogenous leukemia.

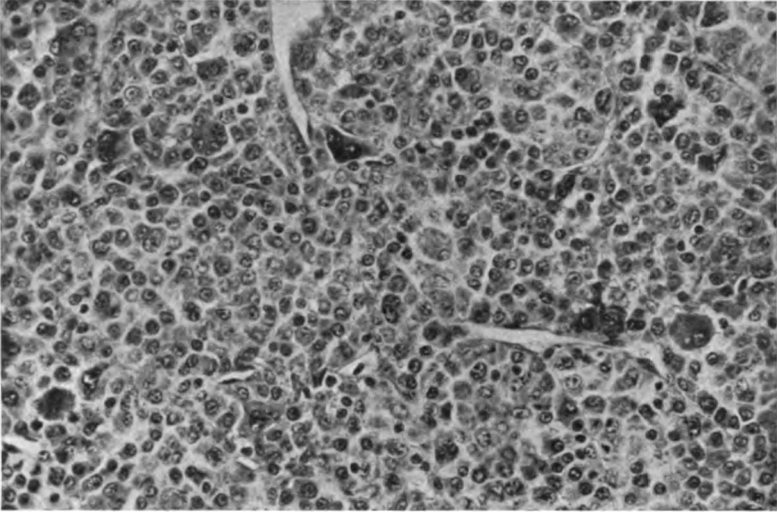


Fig. 253.—Myeloma. M.

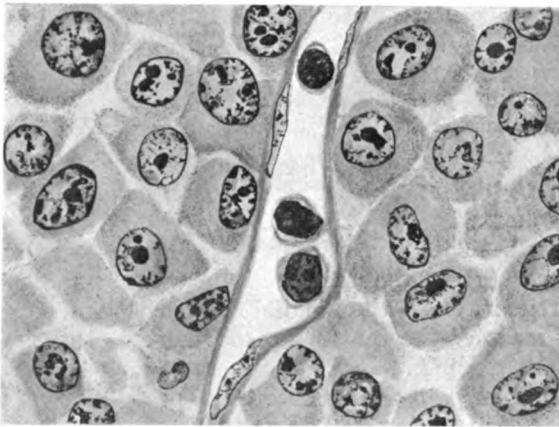


Fig. 254.—Myeloma.

The only other cells peculiar to the bone marrow are the erythroblast and the megakaryocyte. Possibly it arises from one of these cells. It is claimed by some writers that there exists in the bone marrow another peculiar kind of cell which they call the

bone marrow plasma cell and that from it this tumor arises. Time alone will tell.

Histologic Structure.—The cells of a myeloma sometimes closely resemble plasma cells, but in other instances they do not, at least at all closely. They are of medium size and irregularly spherical. Usually they are compressed so that in sections they often appear more or less polygonal. The nuclei vary from round to oval. The chromatin granules are coarse and show a tendency to mural arrangement. Usually there is a distinct nucleolus. As a rule, the nucleus lies a little eccentric. Sometimes a cell contains two or three nuclei or a large, irregular nucleus.

The outline of the cytoplasm is distinct but there is no cell membrane. The cytoplasm is apparently composed of a fine, thick reticulum which contains no granules and has been compared to ground glass. It tends to stain rather deeply, but not so intensely as in plasma cells which these cells resemble to some extent in size, shape and staining reactions. The cytoplasm is usually said to be basophilic. By the eosin methylene-blue method after fixation in Zenker's fluid it is rather neutrophilic and some of the cells are distinctly acidophilic. There is no light space in the cytoplasm near the nucleus as in plasma cells.

The stroma consists of delicate blood-vessels along with which runs a very slight connective-tissue reticulum which spreads in between the tumor cells and supports them.

The tumor occurs in various bones, is often multiple, and forms nodules and diffuse infiltrations. The bones may become eroded so that fractures occur and the periosteum may be infiltrated.

11. MELANOBLASTOMA (MELANOMA, MELANOTIC SARCOMA)

Definition.—A tumor of mesenchymal origin, of which the cells tend to differentiate into pigment cells or melanoblasts (chromatophores).

Type Cell.—The type cell is the melanoblast or pigment cell which occurs (a) in the skin and in the mucous membranes derived from it, (b) in the iris and choroid of the eye, and (c) in the membranes of the central nervous system, especially in the pia over the medulla. It is a perfectly definite type of cell of mesenchymal origin, characterized by production of pigment, and by lack of any intercellular substance.

Pigment cells are relatively large and have considerable cytoplasm. They may be spindle-shaped or irregularly round with long cytoplasmic processes. The pigment is iron-free and contains sulphur. It is a direct product of the cells and occurs as brown granules; some cells contain many of them, others few. The normal pigment cells are best studied by stripping the pia

from the medulla, preferably of a dark complexioned or colored person, and mounting it flat on a slide in water or glycerin. Permanent mounts can also be readily prepared. The cells with their long pigmented cytoplasmic processes stand out in their entirety.

Abnormal collections of pigment cells occur as soft congenital warts (pigmented nevi) in the skin. The cells are polymorphous, varying considerably in shape. Collagen fibrils from the surrounding fibroblasts often, but not always, extend in between the individual pigment cells. Where they do not the cells present more or less of an alveolar arrangement. As a rule, many of the cells in these nevi are comparatively small and contain no pigment. They are regarded as undeveloped melanoblasts. Others are deeply pigmented and may have cytoplasmic processes.

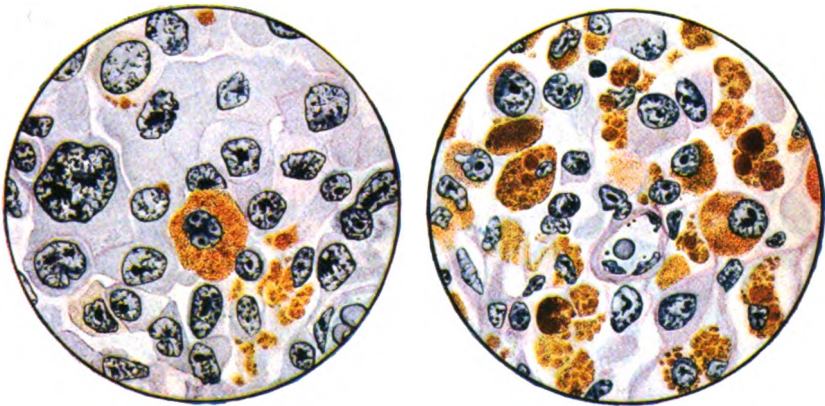


Fig. 255.—Melanoblastoma. Some cells contain much pigment, others none at all.

Histologic Appearances.—The cells of a melanoblastoma tend to differentiate into pigment cells or melanoblasts. They vary much in size, pigmentation and arrangement, depending on the amount of differentiation the cells have undergone and to some extent on the source of origin of the tumors. They may be large or small; and spindle-shaped, round or polymorphous. In a given tumor the cells may all be of the same shape or combinations of forms may occur. The amount of pigment likewise varies greatly. Some of the cells may be deeply pigmented, containing numerous dark brown granules which hide the nucleus, while others contain none at all, and all gradations between the extremes occur. Multinucleated cells due to multiple mitoses are not infrequent, especially in those tumors in which the cells are large and round.

The stroma consists of blood-vessels and of more or less con-

nective tissue. It is never very abundant, as so frequently happens in cancers, but in some of the tumors divides the cells into masses, forming a distinct alveolar arrangement. This type of growth is noticeable when the cells are round or oval, rarely when they approach a spindle shape.

Gross Characteristics.—The melanoblastoma is a fairly common tumor of striking and usually characteristic gross appearance. It occurs most frequently in the skin, occasionally in the eye, and very rarely in connection with the central nervous system. In the tumors originating in the eye the cells are usually spindle-shaped, but cells of the same form may occur in melanoblastomas arising

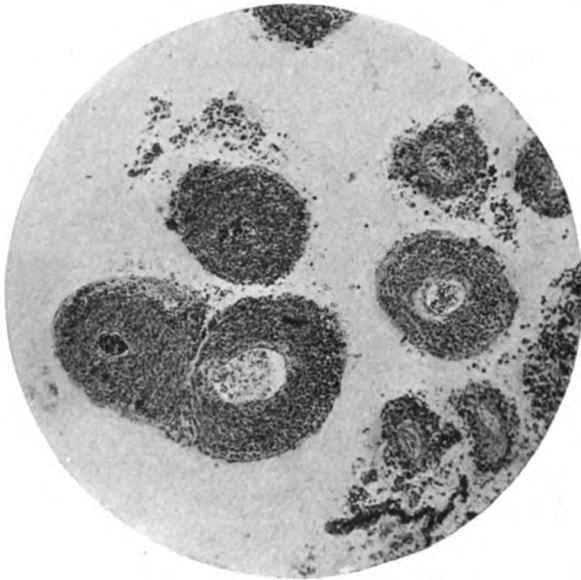


Fig. 256.—Melanotic sarcoma showing perithelial type of growth. M. and W.

in the skin. More frequently, however, the cells of the tumors starting in the skin are polymorphous and often exhibit a well marked alveolar arrangement. They are believed to arise almost always from the pigmented nevi occurring there.

Melanoblastomas form flat to spherical, often lobulated, masses and may attain a considerable size. The color varies from a light to dark brown and sometimes approaches an almost dead black. It is not always uniformly distributed. Frequently in metastases brown and black nodules will adjoin others which contain no pigment at all. The consistence varies considerably, depending chiefly on rate of growth.

So far as known the melanoblastoma is always malignant and usually gives rise to metastases by way of the blood and lymph streams; frequently these take place before the original tumor has reached any size or aroused any alarm.

The melanoblastoma frequently exhibits a perithelial type of growth owing to necrosis of the tumor cells at a distance from the source of nutrition and the persistence of a sheath of them around all the blood-vessels. When the necrotic cells have undergone liquefaction and absorption the vessels with their sheaths of tumor cells can be pulled out in threads like the tubules of a testicle.

12. RHABDOMYOBLASTOMA (RHABDOMYOMA)

Definition.—A tumor of mesenchymal or mesodermal origin of which the cells tend to differentiate into striated cardiac or skeletal muscle-cells.

Type Cells.—The type cells are of two sorts, the cardiac muscle-cell, which is of mesenchymal origin, and the skeletal muscle-cell, which is derived from the mesodermal epithelium. Both types of cells are characterized by longitudinal and cross striations in their cytoplasm, due to the presence and orderly arrangement of contractile fibrils composed chiefly of anisotropic and isotropic segments.

Cardiac muscle-cells are not separate and distinct cells, but form a syncytium, being united end to end into branching and anastomosing fibers. The nuclei are round or oval, possess a distinct chromatin network, and are situated in about the middle of the fibers.

Skeletal muscle-cells are long, multinucleated cells known as muscle-fibers. In the embryo the fibers are narrow and the nuclei lie between the contractile fibrils; in the adult the fibers are thicker and the nuclei lie, for the most part, just beneath the surface.

A. RHABDOMYOBLASTOMA OF CARDIAC MUSCLE-CELL TYPE

Histologic Appearance.—The tumor cells tend to differentiate into striated muscle-cells or fibers similar to those in the heart. As a rule, however, they differ markedly from them. They are usually very large and may be spherical, elongated, or branching and contain one to several nuclei. The cytoplasm of the cells is often coarsely vacuolated, a characteristic which has attracted much attention in the past. The contractile fibrils in the cytoplasm may be well defined, just forming, or even in some cells entirely wanting. The tumor contains blood-vessels, a slight stroma of connective tissue, and in the case pictured is sharply limited by a fibrous capsule.

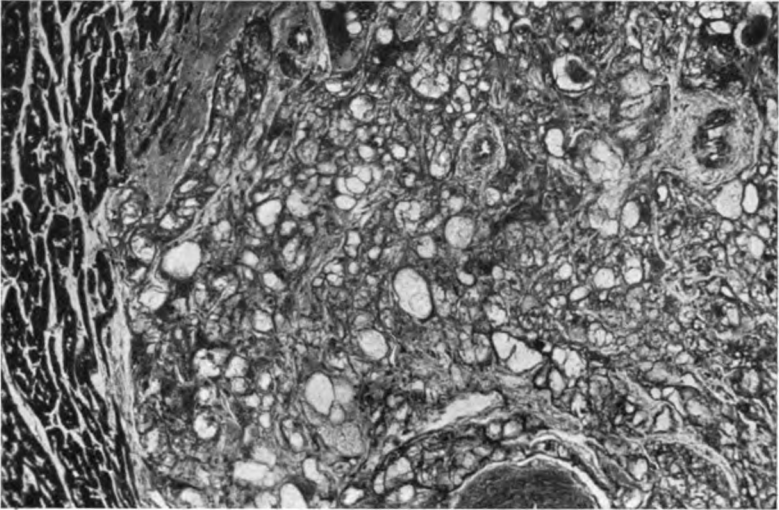


Fig. 257.—Rhabdomyoma of heart. Normal heart muscle on left. W.

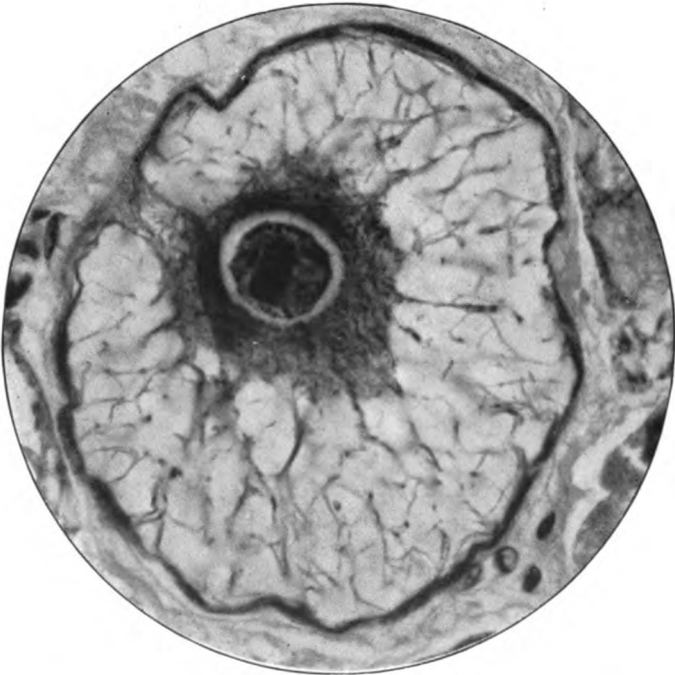

Fig. 258.—Rhabdomyoma of heart. A single edematous cell. W.

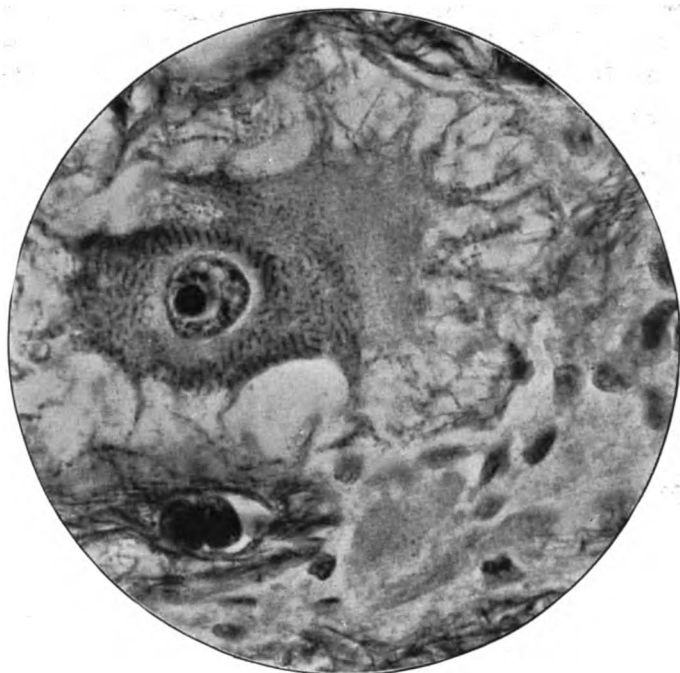

Fig. 259.—Rhabdomyoma of heart. Cross striations distinct in cytoplasm. W.

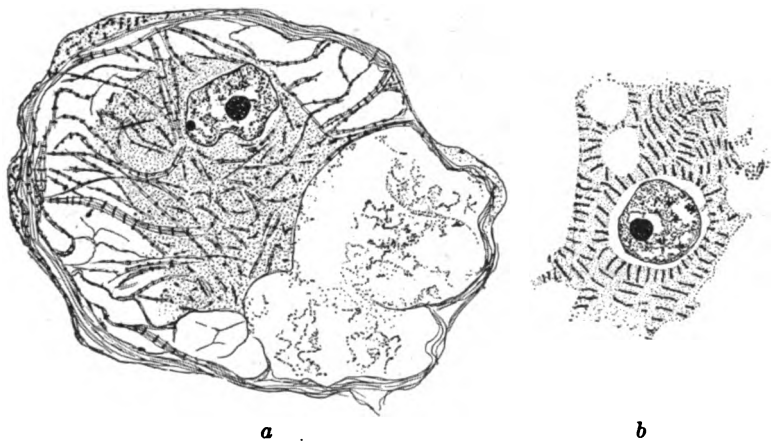


Fig. 260.—Rhabdomyoma of heart. *a*, Longitudinal fibrils and cross striations both distinct, but in *b* only cross striations evident.

Gross Characteristics.—This type of rhabdomyoblastoma is very rare (only about twelve cases are on record) and occurs only in the heart. It is always congenital, often multiple, and does not infiltrate or give rise to metastases. It is, perhaps, always as-

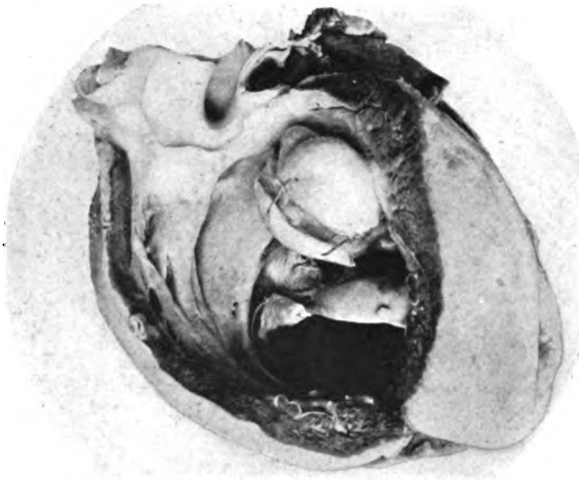


Fig. 261.—Rhabdomyoma of heart. W.

sociated with abnormalities of the central nervous system, usually diffuse scleroses of the cerebral cortex. It forms rounded, firm, elastic tumor nodules of a reddish gray color.

B. RHABDOMYOBLASTOMA OF SKELETAL MUSCLE-CELL TYPE

Histologic Appearance.—The tumor cells tend to differentiate into striated muscle-cells or fibers of the skeletal type, but they never get beyond the embryonic stage of development with the nuclei centrally located between the contractile fibrils. In the slowly-growing tumors fully developed muscle-fibers of the embryonic type are formed, but in the rapidly-growing ones the cells are spindle-shaped and each contains a single nucleus. Often only a few of the cells are sufficiently differentiated to produce the contractile fibrils which alone render the true character of the tumor recognizable.

Gross Characteristics.—This type of rhabdomyoblastoma is rarely found outside of the genito-urinary tract (kidney, testicle,

uterus, urinary bladder, prostate) although it has been reported as occurring in the orbit, the wall of the esophagus, and elsewhere in the skeletal muscles. It may grow slowly and be benign, but more commonly it grows rapidly, infiltrates, and gives rise to metastases. In gross appearances it resembles a fibrosarcoma.

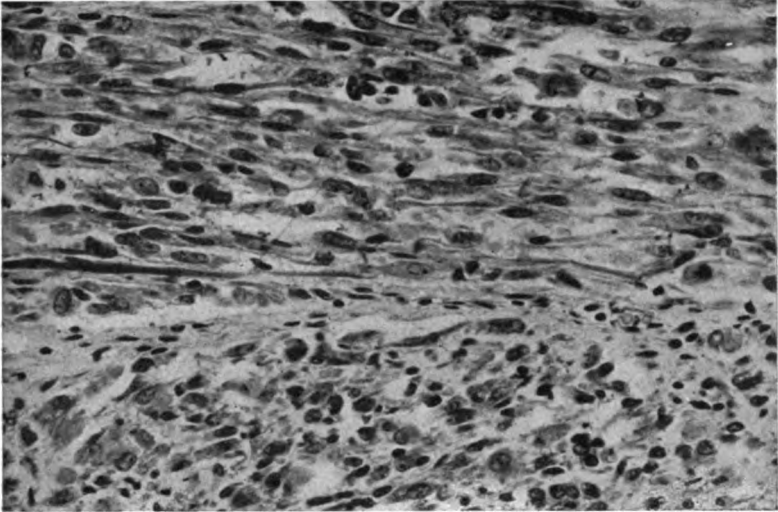


Fig. 262.—Rhabdomyosarcoma of testicle. M.

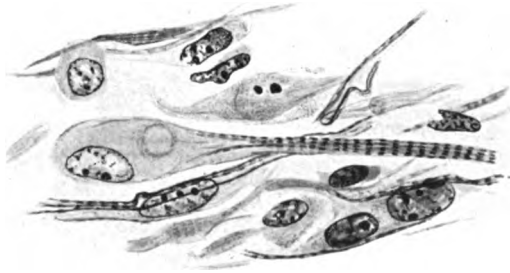


Fig. 263.—Rhabdomyosarcoma of testicle.

Striated cells and fibrils of skeletal muscle type of tumor origin are found not only in rhabdomyoblastomas, but even more often, perhaps, in the mixed tumors which occur in the genitourinary tract.

13. GLIOBLASTOMA (GLIOMA)

Definition.—A tumor of epiblastic origin of which the cells tend to differentiate into neuroglia cells.

Type Cell.—The type cell is the neuroglia cell. It is characterized by the production of only one kind of fibril, the neuroglia fibril, which can be stained sharply and characteristically by special staining methods.

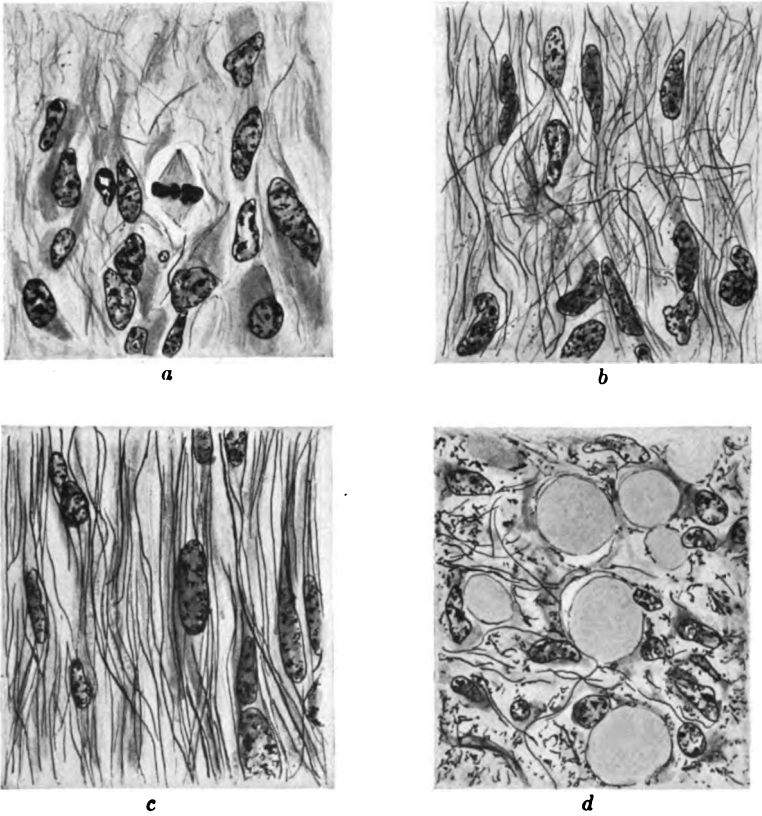


Fig. 264.—Glioma. Four views from different parts of the same tumor.

The normal neuroglia cells are derived originally from the ependymal cells lining the neural canal and are, therefore, epiblastic in origin. The exact relation between the ependymal cells and the neuroglia cells in post-embryonic tissue is undetermined. It is impossible to state whether the ependymal cells produce neuroglia fibrils or not; those covering the choroid plexuses certainly do not, but elsewhere they seem to do so.

Normal neuroglia cells vary considerably in size from small to large. In shape they run from spherical to spindle. As a rule the cytoplasm is small in amount.

The neuroglia fibrils do not start from the cell, but course along the surface of the cytoplasm with which they are in intimate contact and extend away from the cell in two directions. Every cell is surrounded by perhaps one to two dozen fibrils of undetermined length. Around the spherical cells they run in all directions; around the spindle-shaped cells they run parallel to the long axis of each.

The neuroglia cells and their fibrils form the more abundant and chief supporting tissue of the central nervous system. Connective tissue is present also in small amounts, for the most part along the course of the blood-vessels, but plays normally, and usually also pathologically, a subordinate rôle.

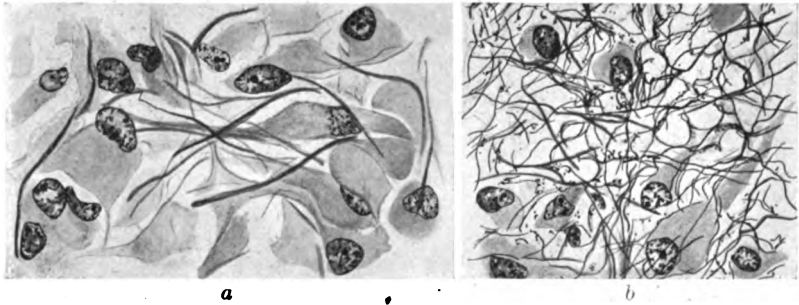


Fig. 265.—Glioma of brain. Large cell type. Few neuroglia fibrils in *a*, many in *b*.

In inflammatory lesions of various sorts in the central nervous system neuroglia cells react much as fibroblasts do in the other organs and tissues of the body. They often proliferate, and the cells may enlarge and the cytoplasm become abundant. The nucleus usually lies eccentric and the fibrils may become very coarse. The cells under these conditions are sometimes spoken of as spider cells. Similar large neuroglia cells appear in various degenerative lesions of the central nervous system.

Histologic Structure.—The cells of a glioblastoma tend to differentiate into neuroglia cells, that is, into cells which form neuroglia fibrils. Whether they do this or not depends much on the rate of growth of the tumor. If the cells proliferate slowly, neuroglia fibrils may be formed in large numbers; if they multiply rapidly, few or no fibrils may be produced. Complete lack of fibril formation necessarily renders a diagnosis doubtful.

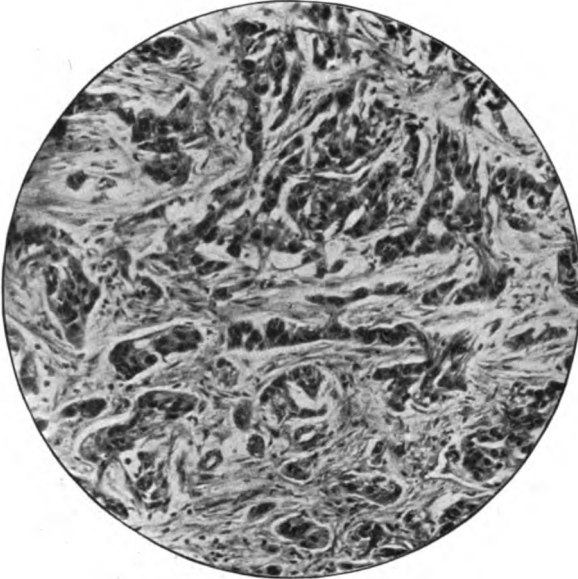

Fig. 266.—Glioma over coccyx. Cells arranged in alveoli like a carcinoma. Stroma abundant. M. and W.



Fig. 267.—Glioma over coccyx. Many neuroglia fibrils present between cells. M. and W.

Structurally, a glioblastoma, or glioma as it is more commonly called, consists of masses of neuroglia cells through which runs a delicate stroma of blood-vessels accompanied by a slight amount of connective tissue. Rarely, the connective tissue is abundant so that the tumor cells present an alveolar arrangement just as they do in a carcinoma.

The tumor cells vary much in size and shape. They may be large or small and round, oval or spindle in form. As a rule all the cells of a given tumor are more or less of the same type and size. The neuroglia fibrils also vary considerably in thickness

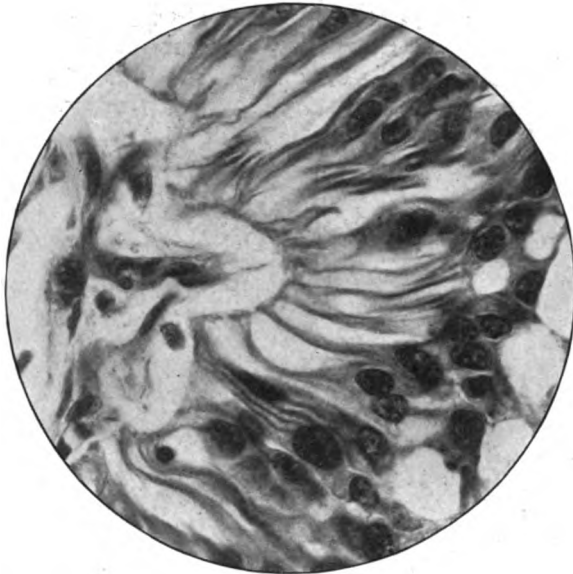

Fig. 268.—Glioma over coccyx. Neuroglia fibrils abutting on stroma. M. and W.

and in number. They may be very fine or decidedly coarse and few in number or very abundant.

Gliomas grow at all rates of speed, but the terms glioblastoma and glioma are applied indiscriminately to them all. Mitotic figures may be very numerous and in some instances multiple so that large multinucleated cells which are true tumor giant-cells result.

Occasionally gliomas occur in which there are present gland and cyst-like cavities lined with ependymal cells. The presence of these structures suggests that these particular tumors at least arose from some abnormality of the central canal, such as displacement

of a group of ependymal cells in early embryonic life. Such displacements are not infrequently found when otherwise normal brains and cords are systematically searched for them.

Origin and Occurrence.—A glioblastoma originates only from neuroglia cells or from cells of the neural canal from which they are derived in the first place. It follows from this that gliomas occur only within the central nervous system and its outgrowths, and from remains of the neural canal. These remains are apparently found only at the ends of the canal, over the coccyx and at the base of the nose where closure of the canal takes place and

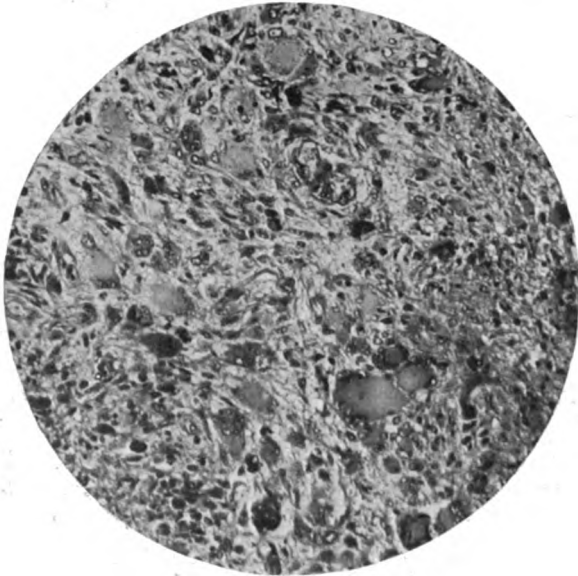


Fig. 269.—Glioma of brain. True tumor giant-cells present due to multiple mitoses. M.

where atrophy and disappearance of the ependymal cells are often incomplete.

It is easy to demonstrate these remains of the canal persisting in the form of glands over the coccyx in embryos a few months old. Probably the same could be done for the upper end of the neural canal.

These persisting cells have inherent in them the capability of forming neuroglia cells with their fibrils. Occasionally they give rise in both these regions (over the coccyx and in the nose and orbital sinuses) to perfectly typical gliomas.

In the brain and cord the tumors may lie within the solid

nervous tissue or project into a ventricle. It is possible that they may occur in the eye because the retina is an outgrowth of the brain and contains neuroglia tissue, but the tumor of the eye commonly called a glioma is a neuroblastoma.

Malignancy.—Gliomas are necessarily almost always dangerous owing to their common location in the central nervous system. In addition, however, they are dangerous owing to their manner of growth. They are often sharply defined, but in other instances are so intimately fused with the surrounding tissue that their limits cannot be clearly made out. While some of them seem to grow expansively only, it is probable that they are all infiltrative by nature. This is clearly shown in some instances by invasion

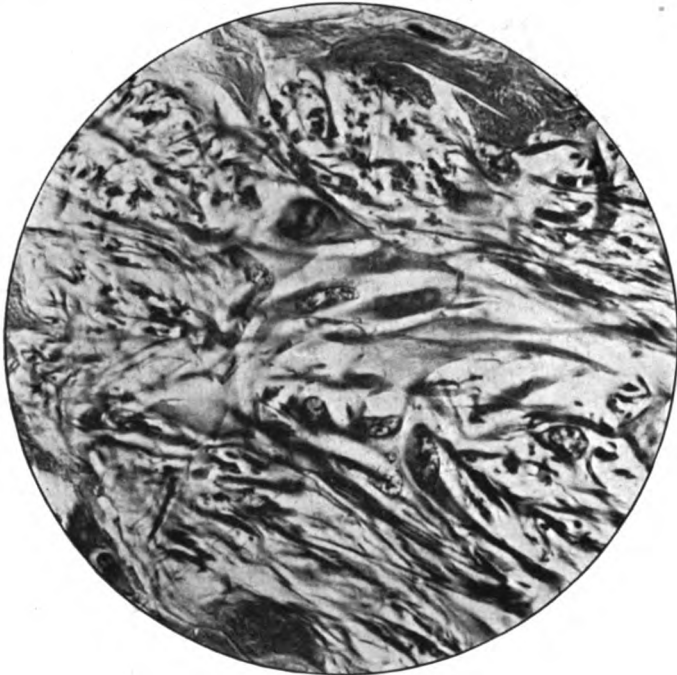

Fig. 270.—From a second case of glioma over the coccyx. One alveolus of neuroglia cells and their fibrils. M.

not only of brain tissue but of the pia, and by extension in one or two cases directly across the longitudinal fissure. A remarkable example occurred in a child, in whom a glioma of the lumbar enlargement invaded the pia and then extended through the meninges the entire length of the cord and over the cerebellum and cerebrum, invading these structures at many points. The tumor was mistaken at autopsy for an organizing meningitis.

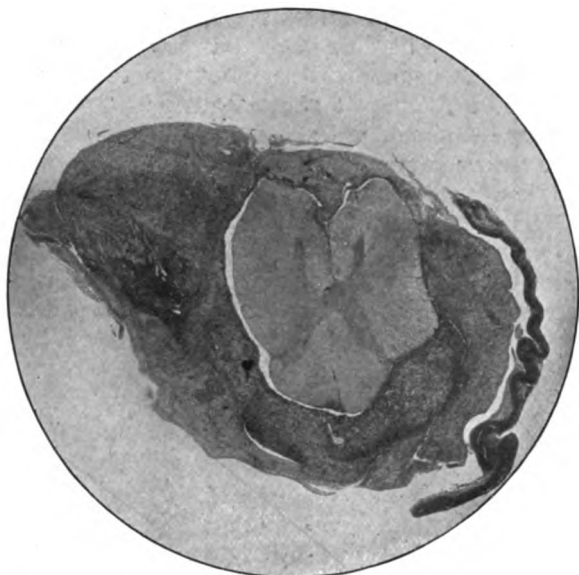

Fig. 271.—Glioma of lumbar cord extending up around the cervical cord through the meninges. M. and W.




Fig. 272.—Glioma of cord extending through meninges and invading cerebellum. M. and W.

Metastasis.—Although glioblastomas often show a marked tendency to infiltrate the tissue surrounding them, they apparently do not invade blood-vessels and in that way give rise to metastases in other parts of the body. At least no instance of a glioma of the brain or cord giving rise to metastases outside of the central nervous system is on record, so far as known. On the other hand, a typical glioma over the coccyx in a woman of forty-two recurred after removal and gave rise to metastases in the lymph-nodes in both groins.

Capsule.—The neuroglia tissue surrounding a glioma, especially when it is growing slowly and expansively, often thickens up as a gliosis and forms a sort of capsule. Sometimes this capsule is very definite and easily distinguishable from the tumor, but at other times it is difficult to tell tumor and gliosis apart. Occasionally a glioma so closely resembles a diffuse gliosis that its exact nature is difficult to determine.

Gross Characteristics.—A glioma may be as hard as a dense fibroma or as soft as the most delicate sarcoma. In size it may range from a millimeter to five or six centimeters or more in diameter. The color may be glistening white, gray and translucent, or reddish gray. The shape is usually more or less spherical in the brain, and rod-shaped in the cord owing to confinement within a narrow canal.

Retrograde Changes.—Various retrograde changes are common in gliomas. The most frequent is necrosis from which, by liquefaction and absorption, cysts may be formed. Hemorrhage may bring about the same result and is sometimes so extensive that only a rim of tumor tissue is left at the periphery, and that may be overlooked at examination unless the possibility of its presence is appreciated. Necrotic tissue, instead of undergoing softening, may become calcified and later any fibroblasts which are engaged in organizing the necrotic tissue may be transformed into bone cells (ossification).

In one instance fibrin formed in ependymal-lined cavities of a glioma of the cord. The fibrin attracted the neighboring fibroblasts which organized the fibrin. In this way the ependymal-lined cavities came to hold masses of fibrous tissue.

14. NEUROBLASTOMA (NEUROCYTOMA, NEUROMA)

Definition.—A tumor, of epiblastic origin, of which the cells tend to differentiate into nerve-cells.

Type Cell.—The type cell is the nerve-cell. In the central nervous system and its outgrowths, the eye, ear, and nose, and in the sympathetic nervous system, nerve-cells occur in great variety, differing much in size, shape, and function, but all charac-

terized by one common feature, the prolongation of the cytoplasm at some point into an axis cylinder process or nerve-fiber. The cells of neuroblastomas arising in different parts of the body may be expected, therefore, to vary considerably in appearance.

Histologic Appearance.—The cells of a neuroblastoma tend to differentiate into nerve-cells of the same type as those which would have developed under normal conditions from the cell giving origin to the tumor. The result is considerable variation in the histologic appearance of different examples of this tumor.

The tumors arising outside of the central nervous system usually show a more or less well marked alveolar arrangement of the tumor cells with respect to the stroma, which is often fairly

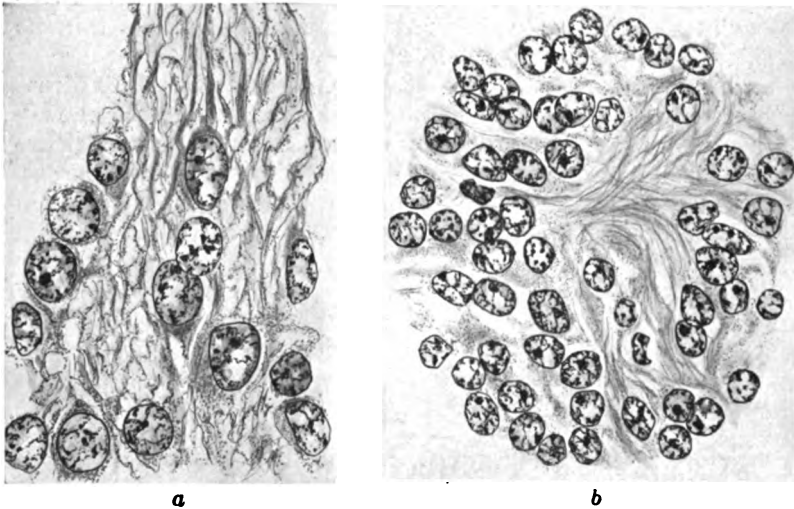


Fig. 273.—Neuroblastoma of the adrenal gland showing bundles of nerve fibrils.

abundant. When the tumor growth is rapid the cells show little or no differentiation although they may vary considerably in size and shape. As a rule, however, the nuclei are small, spherical and rich in chromatin, with little cytoplasm around them. When more or less cell differentiation has occurred, delicate fibrils are associated with the cells. These fibrils do not give the characteristic reactions of neuroglia, fibroglia, and collagen fibrils, but react to the various differential staining methods as nerve-fibrils do.

The fibrils of the tumor cells are usually arranged in one of two ways: either parallel to one another in bundles or woven in small spherical masses around which are grouped the cell nuclei. These masses form balls which on section show a circle of nuclei sur-

rounding a network of delicate fibrils, an appearance to which the term rosette has sometimes been applied.

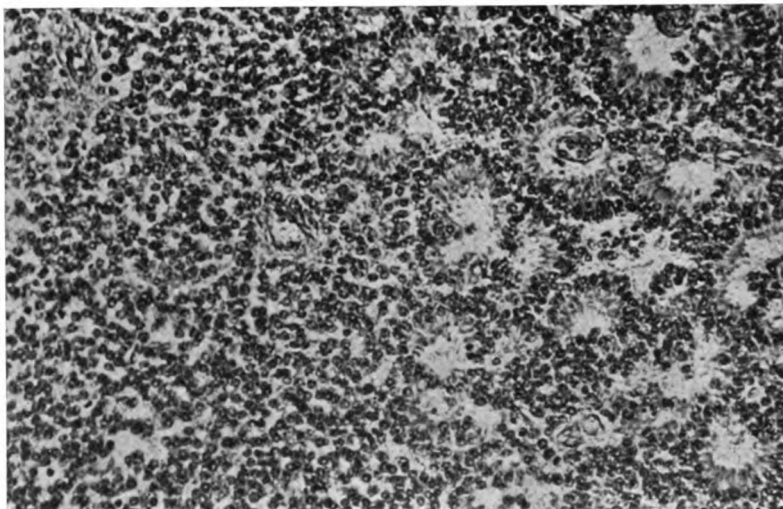


Fig. 274.—Neuroblastoma of eye. Cells on right differentiated and arranged around small lumina. M. and W.

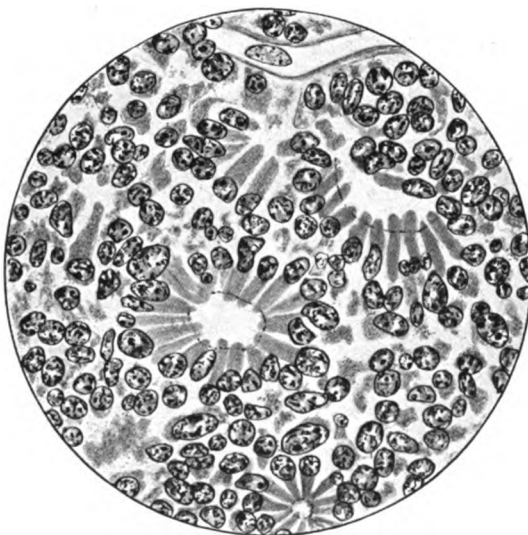


Fig. 275.—Neuroblastoma of eye. Gland-like cavities formed where the cells have differentiated and attempted to produce rods and cones.

Fibril formation may occur only in a few places or not at all, so that the positive recognition of a tumor of this type may some-

times be difficult or even impossible. In other instances the fibril formation may be abundant even in the metastases.

A distinct and well known variety of this type of tumor occurs in the retina where it has usually incorrectly been called a glioma. It is always congenital and often bilateral. It destroys the eye-ball and may invade the brain. When the tumor grows slowly its structure can readily be made out. It forms small, gland-like cavities lined by cells which produce more or less perfect rods and cones. These structures project through a limiting membrane just as in the normal retina. From the other end of each cell projects an axis cylinder process. When the cells proliferate rapidly the gland-like cavities cease to be formed although the

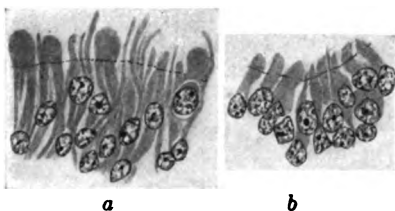


Fig. 276.—*a*, Rods and cones from the normal retina; *b*, rods and cones formed in neuroblastoma from same eye.

axis cylinder processes may still be. With more rapid growth, cell differentiation ceases and the tumor passes into that ill-defined group, the so-called small round-cell sarcoma. Owing to necrosis and absorption, a perithelial arrangement of the tumor cells around the blood-vessels is frequent.

Neuroblastomas originate most commonly in the adrenal glands, less often in the brain, lung, and other organs. They occur most often in infants but occasionally in adults. Those arising in the adrenals are frequently congenital and bilateral.

This type of tumor is probably not so rare as is usually supposed. The rapidly-growing forms are the more important and are distinctly malignant, infiltrating the surrounding tissues and giving rise to numerous metastases. Neuroblastomas containing nerve-cells of the large type with dendritic processes and tigroid bodies are rare.

15. EPITHELIOBLASTOMA (PAPILLOMA, ADENOMA, CARCINOMA)

Introduction.—The epithelial new-growths form the largest and most important group of the simple tumors. The type cells from which they are built up are the epithelial cells which occur normally in great variety. The different epithelial cells have no one striking morphologic characteristic which distinguishes them from all other cells. In general they cover surfaces or line cavities, but they may grow in solid masses (pituitary gland, adrenal gland).

On the other hand, the various epithelial cells differ among themselves in many ways. Some are ciliated, others contain

characteristic granules, still others undergo peculiar retrograde changes. These morphologic variations are not surprising when it is remembered that epithelial cells arise from all three embryonic layers, form a multitude of organs and tissues, and perform a great variety of functions.

The tumors arising from epithelial cells have some characteristics in common, but more that are peculiar to the variety of type cell from which they arise. It is necessary, therefore, to state the characteristics which are common to all the epithelial tumors and then to group under each variety of type cell all the tumors, whether they are benign or malignant, which arise from it and study these separate sub-groups by themselves. In no other way is it possible to obtain a comprehensive knowledge of the epithelial tumors.

Types of Growth.—The cells of epithelial tumors cover surfaces or grow in solid cords and masses. The surfaces may be elevated in finger-like processes or in ridges, or they may be depressed in pockets and folds. In these three different ways of growth the epithelial cells are supported and nourished by a stroma composed of connective tissue and blood-vessels.

In some tumors the epithelial cells are all arranged after a single type of growth; in others they may grow in two or even in all three of the ways mentioned.

Nomenclature.—Various names have been applied to epithelial tumors. These names are based partly on the histologic structure of the tumors, partly on whether clinically they are benign or malignant. The following three terms are the most important; the first two characterize type of growth; the third malignancy.

Papilloma.—An epithelial tumor in which the cells cover finger-like processes or ridges of stroma.

Adenoma.—An epithelial tumor in which the cells line gland-like depressions or cavities in the stroma. Dilatation of the glands of an adenoma by secretion leads to cyst formation.

Combinations of these two types of growth are common (intracanalicular papillary adenoma of the breast, papillary adenocystoma of the ovary). These two terms are commonly restricted to tumors which do not invade and hence are not malignant.

Carcinoma.—An epithelial tumor which infiltrates and which may give rise to metastases. It is the term applied to all epithelial tumors which pathologically invade and which clinically are malignant.

It is important to realize that a carcinoma may grow in any one of the three ways described, as a papilloma (penis, bladder), as an adenoma (rectum, uterus), or more commonly and characteristically with its cells in solid cords and masses (carcinoma of

breast). Hence in a narrow sense carcinoma is often used to signify this type of growth of the tumor cells in solid masses, without lumen formation, as is evidenced by the term adenocarcinoma used for a tumor containing epithelium grouped both in gland-form and in solid masses.

For a papilloma which infiltrates, the term papillary carcinoma is often employed. For an adenoma which invades the clinical term malignant adenoma is in common use; infiltrating would be better; still better in all these instances is the simple term car-

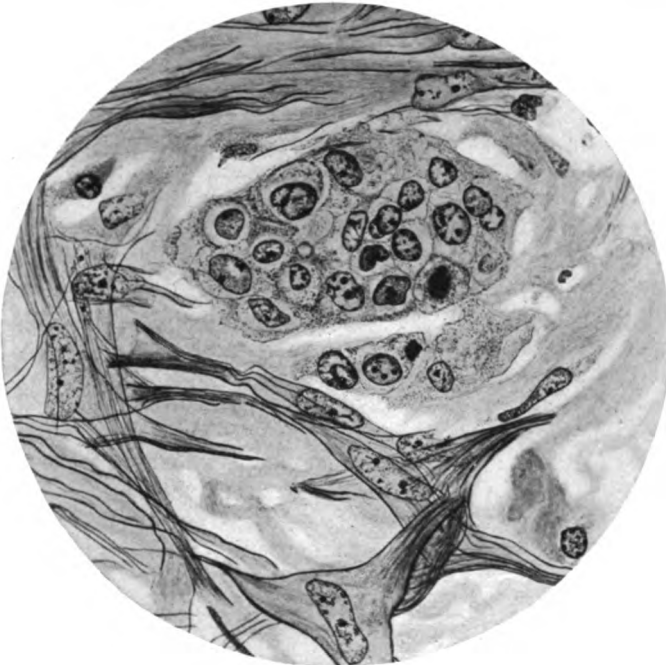

Fig. 277.—Carcinoma of breast. Alveolus of epithelial cells surrounded by abundant stroma of fibroblasts.

cinoma. The type of growth matters little; all three types may be combined in one tumor. The one essential point is the invasion of the surrounding tissue.

A papilloma is to be regarded as benign when it shows no evidence of invasion and gives rise to no metastases.

An adenoma is benign which grows expansively only, without invasion of the surrounding tissue and without formation of metastases.

Another way of making these statements is as follows: A

carcinoma is always malignant; a papilloma or an adenoma may be; if it is, it is best then to call it a carcinoma.

A non-infiltrating (benign) tumor without lumen formation, arising from epithelium which grows in solid masses (pituitary gland, cortex of adrenal gland) is usually classed as an adenoma.

Papillomas growing in certain situations are always to be regarded with great suspicion. This is particularly true of the urinary bladder, for clinical experience favors the view that in the end they are always malignant owing to invasion at the base of the tumor.

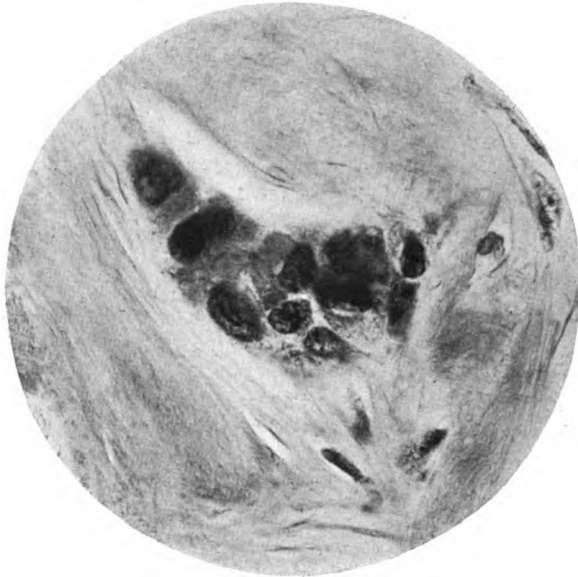

Fig. 278.—Scirrhous carcinoma of breast. An alveolus of epithelial cells surrounded by abundant stroma. M. and W.

Stroma.—In epithelial tumors which grow above a surface or expansively within an organ or tissue, the stroma is all new formed. In tumors which infiltrate the stroma consists of the original stroma of the organ, usually more or less increased in amount.

The stroma of normal epithelial organs varies greatly in amount. It is slight, for example, in the liver, kidney, and adrenal gland. In the tumors arising from these organs the stroma is usually slight in amount. In the mammary gland and in the skin the epithelial cells are subtended by a very large amount of stroma. In the epithelial tumors arising from these structures the stroma is usually very abundant. In the ordinary adenomas of the breast

it forms such a conspicuous feature that some pathologists regard these tumors as fibromas and others as an example of a mixed tumor, an adenofibroma. In carcinomas of the breast the stroma is usually a prominent feature, and on this account the alveolar arrangement of the cells with reference to the stroma, at least as seen in sections, is almost always conspicuous.

Metastases from the infiltrating (malignant) tumors in these different regions lead to the production of a stroma corresponding more or less closely in amount to that in the original tumor. Thus, a metastasis of a cancer of the breast leads to abundant stroma formation even in a tissue containing as little connective tissue as the bone marrow. This matter of production of more or less stroma favors the view that the epithelial cells, both in the normal organs and in the tumors arising from them, directly influence and determine the amount of the stroma; in other words, that epithelial cells, chemically or otherwise, can cause proliferation of fibroblasts.

Papilloma.—The epithelial cells of a papilloma may be in the form of an epidermis, of a stratified epithelium, or of a single layer which may or may not be ciliated. The arrangement of the cells depends on the location of the tumor, that is, on the nature of the epithelium from which it starts.

A true papilloma is a benign growth, but its recognition is not easy. Many carcinomas grow, especially at first, in papillary form; for instance, in the urinary bladder, on the penis, and in the ducts of the mammary gland. Papillomatous formations may arise as the result of chronic irritation or stimulation of various sorts (verruca, condyloma accuminatum, the papilliferous cysts in the bile ducts of the rabbit due to the coccidium oviforme), but they are largely or entirely infectious in nature and are not true tumors.

Adenoma.—Adenomas may occur in many situations. They are common in the breast where they are usually attended by a large amount of stroma, often have papillary projections into the glands, and may attain a large size. They arise also in the mucous membrane of the stomach and intestine, and in the kidney, liver, skin, sebaceous glands, thyroid, etc. The true benign adenoma grows expansively.

The adenomas in certain situations, as, for instance, in the breast, are almost always benign, although malignant tumors may occasionally start from them, thus a carcinoma from the epithelium, a fibrosarcoma from the stroma; but adenomas in many other situations, such as the uterus or rectum, are always to be regarded with suspicion.

Some or all of the glands in an adenoma may be dilated into cysts. This is the common condition in the adenocystoma of the

ovary. This tumor is ordinarily regarded as benign and yet it is open to a certain amount of suspicion. When it contains papillary projections it is generally regarded as more or less malignant, that is, as a carcinoma. Experience shows that those in which the cells are ciliated are especially prone to infiltrate. They may give rise to metastases in the peritoneal cavity and elsewhere.

Carcinoma.—A carcinoma is an epithelial new formation which tends to invade the lymph-spaces of the connective tissue adjoining it. When it starts it may at first only replace the epithe-

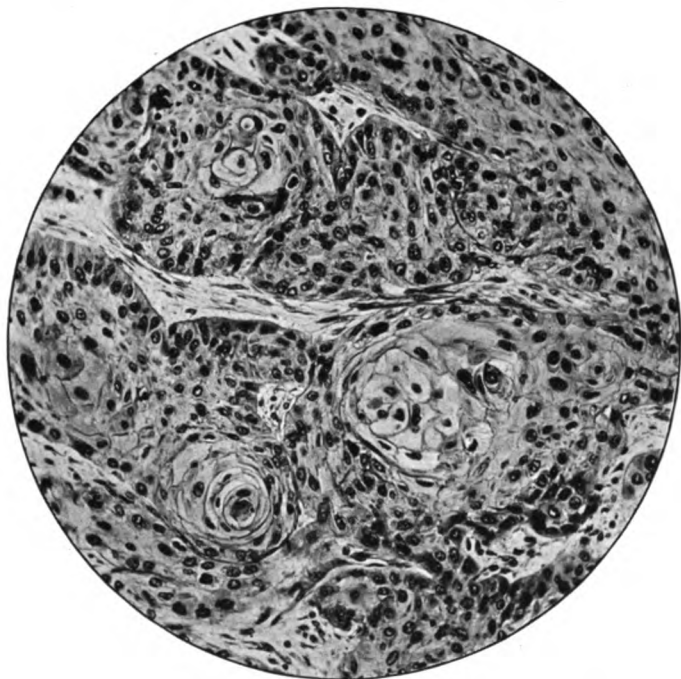


Fig. 279.—Epidermoid carcinoma. Epithelial pearls in early stage of formation. M.

lium lining a duct, gland or surface, or grow between it and the connective-tissue wall and usurp its nutrition. At this stage it may resemble a benign adenoma or papilloma or grow in solid masses in ducts and glands. But sooner or later it invades the surrounding lymph-spaces between the cells, fibrils and blood-vessels of the normal stroma. From here it frequently grows into the lymph-vessels, giving rise to metastases along the paths of absorption, and occasionally invades the blood-vessels and causes secondary growths in various parts of the body.

A carcinoma may grow in any one of several different forms or in various combinations of them; thus it may grow with the cells arranged in solid masses (carcinoma simplex), in the form of glands (malignant adenoma), or in the form of papillary projections (papillary carcinoma). Some of the combinations are expressed in the following terms: adenocarcinoma, papillary adenocystoma.

Epidermoid Carcinoma.—The epidermoid carcinoma forms one special variety of malignant epithelial tumors. It deserves separate mention in consequence of the characteristic changes which

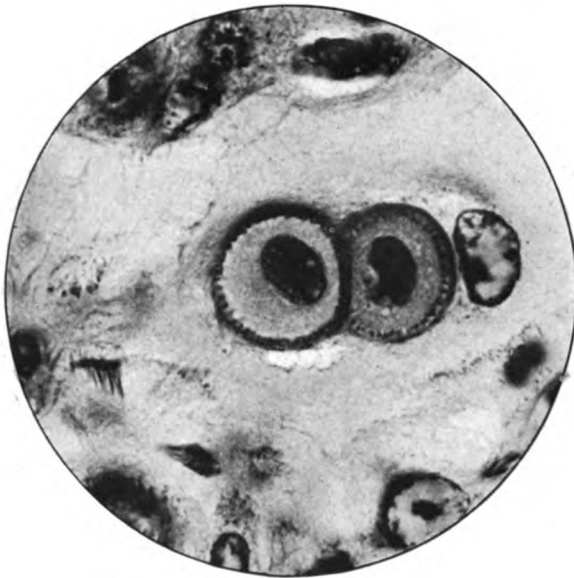

Fig. 280.—Epidermoid carcinoma. Two cells just beginning to undergo cornification. Epithelial fibrils still evident. M. and W.

its cells undergo. It is so named because the tumor cells tend to differentiate in the same way that the cells of the epidermis do, that is, they tend to form prickle cells and to undergo cornification. It is one of the commonest forms of cancer. It occurs most frequently in the skin (lips, penis, etc.), but also in numerous other situations where an epidermis is present normally, and occasionally where it is not, thus, in the tongue, pharynx, larynx, esophagus, cervix uteri, urinary bladder, gall-bladder, neck (from remains of a branchial cyst).

In an epidermoid carcinoma the cornified epithelial cells cannot, as a rule, reach the surface. As a result they are not washed

off, as happens with the cornified epithelium of the skin, but gradually accumulate. New cells at the periphery are added to the old cells at the center. In this way layered, often concentric, masses of cornified epithelial cells are formed, which are frequently more or less spherical in shape although they may assume various other forms. Owing to their striking appearance in stained preparations these cornified masses have received the name of epithelial pearls. As a rule the pearls are very compact, but sometimes the cells forming them do not contract and weld together well.

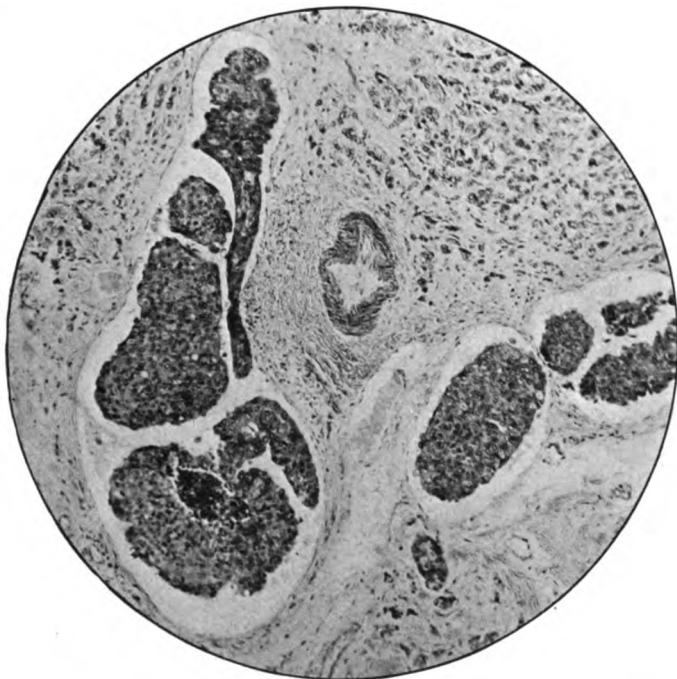

Fig. 281.—Carcinoma of mammary gland. Scirrhous in type until it invaded the lymph-vessels, where it is growing rapidly and forming large masses of cells. M.

Progressive Changes.—The rate of growth in cancer varies greatly, depending in part at least on the location of the cells. If they are within lymph-spaces surrounded by much connective tissue they may grow very slowly; often in single rows of cells (scirrhous carcinoma). But once these same cells obtain entrance to a lymphatic vessel and receive plentiful nutrition, they multiply and spread rapidly. Frequently the two types of growth can be found side by side in the same tumor.

In other instances the tumor cells multiply rapidly. Mitotic figures may be very numerous and often they are multiple. Occasionally multinucleated giant-cells are formed in this way, just as in other rapidly-growing tumors.

Metastases usually take place by way of the lymph-vessels because cancer so commonly gets into them. Ordinarily the tumor extends in the direction of the lymph current, either by direct growth or in consequence of cells being carried along by the lymph. Occasionally, however, the tumor extends in the opposite direction, against the current, and certainly as a rule by direct growth.

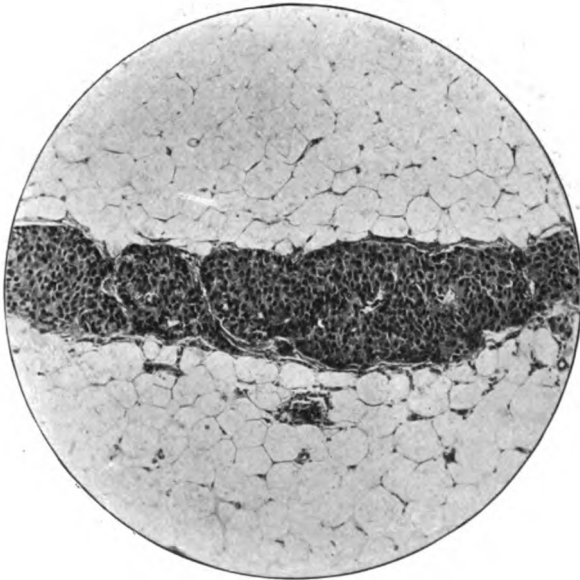


Fig. 282.—Carcinoma of mammary gland. Extension of tumor through a lymphatic in fat tissue. M. and W.

Metastases often occur also by way of the blood, following invasion of a vessel at some point or other and the formation of a cancer thrombus. Cells set free are carried all over the body and in favorable locations cause secondary nodules, especially in the liver, lungs, and bone marrow.

Metastases usually grow much faster than the original tumor, sometimes very much more rapidly.

Cancer of the breast not infrequently invades the ducts and grows beneath the lining epithelium. Sometimes it fills the ducts completely and extends along them. It also invades nerves and

very commonly infiltrates the underlying muscle tissue. Sometimes it seems to occupy the spaces formerly filled by the muscle-fibers themselves.

The growth of the stroma in epithelial tumors, and especially in carcinomas, is at times so active that it is not unusual to find fibroblasts in mitosis. In cancers of the breast the stroma often seems to be actively stimulated in some way, perhaps chemically, by the tumor cells. The fibroblasts proliferate actively and produce many collagen fibrils. In addition, the production of elastic fibrils is also often stimulated. Large masses of fine and

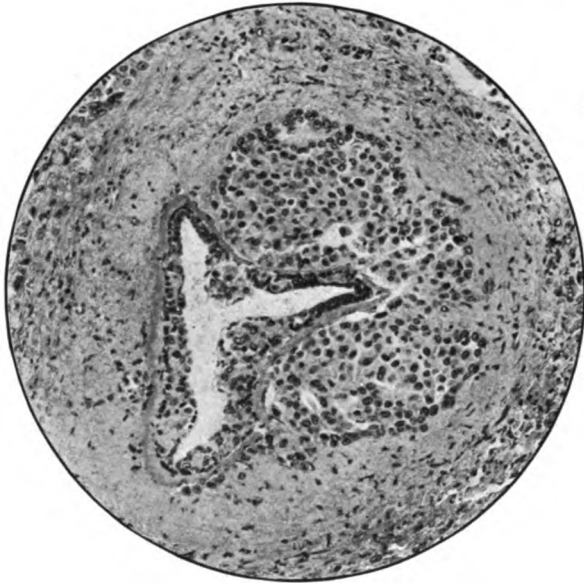

Fig. 283.—Carcinoma of mammary gland growing around and invading a duct. M. and W.

coarse fibrils are often formed around the ducts and vessels and may be visible to the naked eye on fresh section.

Rarely a cell in the stroma of an adenoma or cancer may take on malignant properties and grow independently, producing a fibrosarcoma.

Retrograde Changes.—Retrograde changes are rare in the benign epithelial tumors, but common in those which are malignant.

Fat often accumulates in consequence of impaired metabolism in those cells of a cancer which are farthest from the blood supply. Groups of such cells present a white or yellowish white opaque

appearance on fresh section. Sometimes the fat is taken up by endothelial leukocytes which may later accumulate in numbers in the stroma while digesting the fat. Necrosis often occurs as a result of local interference with the circulation within a tumor, as by pressure or hemorrhage. Rarely in small areas all cells die except for a sheath of them around the vessels. In this way a perithelial arrangement of cells is produced, but is much less common than with some other types of tumors.

In epidermoid carcinomas the cornified material in the epithelial pearls often attracts numbers of endothelial leukocytes. Many of the leukocytes may fuse to form foreign body giant-cells

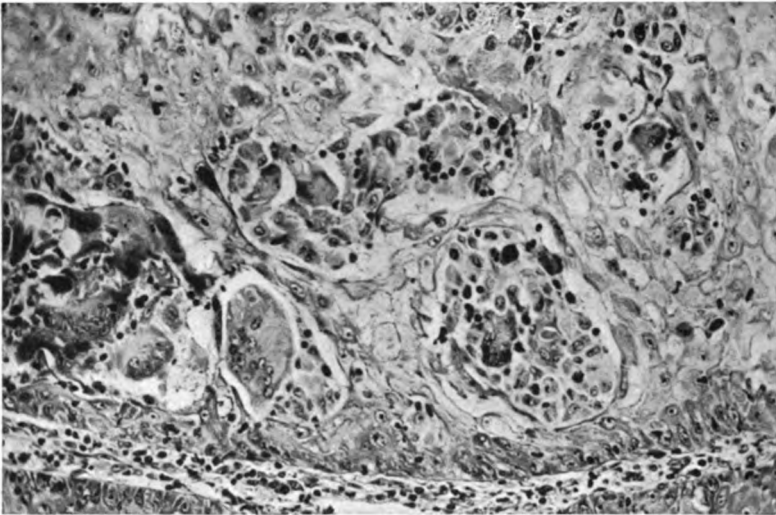


Fig. 284.—Epidermoid carcinoma of tongue. Numerous endothelial leukocytes attracted into it by cornified epithelium. Many have fused to form foreign body giant-cells. M.

and gradually digest the cornified cells. Polymorphonuclear leukocytes are sometimes attracted into the epithelial pearls, but this is usually where they are near an exposed surface and is probably the result of some bacterial infection.

The cells of some epithelial tumors secrete mucus, of others a mucoid material. In still other tumors many of the epithelial cells gradually undergo a transformation into a hyaline gelatinous substance (colloid carcinoma).

Sometimes the stroma of some of the epithelial tumors becomes markedly edematous, so that the collagen fibrils are all separate and distinct and the cells assume more or less of a stellate appearance. The presence of mucus is often strongly suggested

by the staining reaction. Edema is frequent in adenomas of the breast, and in certain tumors of the skin, probably derived from the coil glands.

EPITHELIAL TUMORS OF THE SKIN

In order to understand the different epithelial tumors of the skin it is important to bear in mind that four different epithelial structures are present in it:

1. The covering epidermis.
2. The hair matrix, follicle, and shaft.
3. The sebaceous gland.
4. The coil gland, and its amplified derivative.
5. The mammary gland.

The epithelial cells of each one of these structures have their own peculiar form of differentiation. Hence the epithelial tumors arising from them tend likewise to differentiate in the same four ways. The tumors will accordingly be taken up under these separate headings.

1. EPIDERMIS

The cells of the epidermis are characterized by the formation of numerous short fibrils, which bind the cells together and are known as intercellular bridges. Longer fibrils are sometimes present which are known as epithelial fibrils. The exact relation of these two kinds of fibrils to each other and to the cell is not fully determined. They seem to be due, for the most part at least, to a differentiation of the cuticle of the cell, and not to be an intercellular substance. The cells of the epidermis are further characterized by retrograde changes involving the formation of eleidin and keratohyalin and ending in cornification. In tumors derived from epidermis the cells tend to undergo these same changes and the resulting cornified epithelial cells collecting in masses are termed epithelial pearls. The mitoses occur entirely in cells corresponding in development to the lowest layer, the rete Malpighii; but even in this layer the surface of the cells usually shows the characteristic surface fibrillation which becomes more prominent in the prickle cell layer.

Papilloma.—The true benign papilloma is not very common. It must not be confused with the common hard wart, verruca, which is often multiple, and is probably infectious because there is good evidence that it is communicable; or with condyloma acuminatum which occurs frequently on the genitals and in that neighborhood.

In a papilloma the cornified cells buried deep between the papillæ often cannot escape but instead accumulate and form

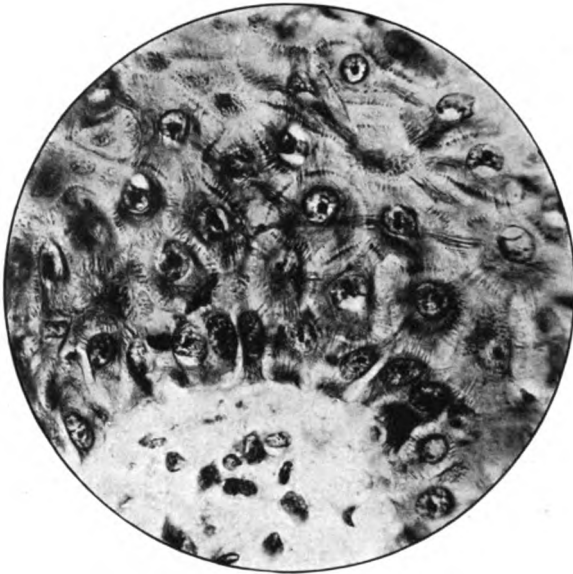


Fig. 285.—Normal epidermis. Epithelial fibrils are formed even by the cells in the lowest layer. M.

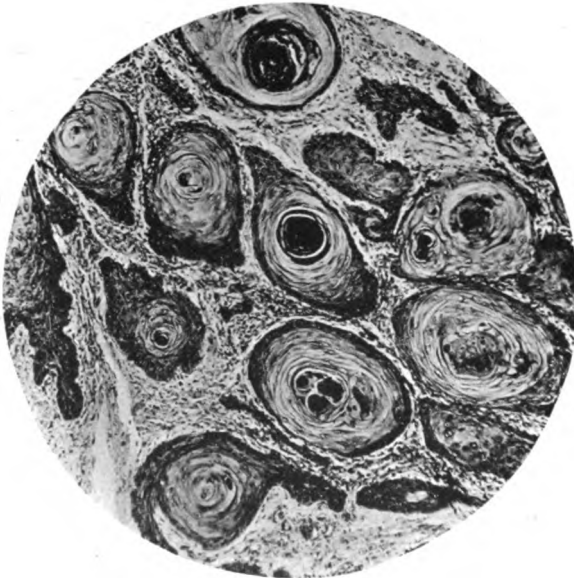

Fig. 286.—Epidermoid carcinoma. Numerous pearls present, owing to slow growth of tumor and marked differentiation of cells. M.

epithelial pearls just as in an epidermoid carcinoma. The important point to bear in mind is that an epithelial pearl does not assert anything with regard to malignancy, although often associated with that condition.

The epidermoid carcinoma has already been described in part histologically. It only remains to add certain additional features. Occasionally the epithelial fibrils are much more numerous and apparently also longer than in the normal epidermis.

When an epidermoid carcinoma starts in the skin there usually occurs a marked inflammatory reaction in the underlying corium. The fibroblasts proliferate actively so that mitotic figures are not infrequently found in them, and a marked infiltration with lymphocytes takes place.

Sometimes an epidermoid carcinoma grows so rapidly that little differentiation of the cells occurs; there is no time for it. In other instances the tumor consists largely of cornified epithelium; there is little in the way of actively proliferating cells.

All proliferation of an epidermoid carcinoma starts from the lowest layer of cells, the rete Malpighii, and occurs in cells of that undifferentiated stage. The idea which has been advanced, and which has obtained wide notoriety, that a carcinoma starting from the rete Malpighii does not undergo cornification is absurd. There are better explanations for the origin of the tumor to which the term carcinoma basocellulare has been applied.

The gross appearances of an epidermoid carcinoma vary greatly. At its inception it may present only a small nodule of thickening and induration. As it enlarges its surface may show numerous short projections so that it resembles a verruca. Later it may ulcerate; the surface may be eroded while the edges remain elevated and indurated. It may be confused with hard chancre. The latter has been excised more than once for an epidermoid carcinoma, to the later surprise and chagrin of the surgeon.

Metastases to the regional lymph-nodes commonly occur and often at an early stage of the lesion.

2. HAIR MATRIX

The cells which arise from a hair matrix and form the hair and its sheath do not differentiate, except to a slight degree, in the way that the cells of the epidermis do. The hair is composed of cells which develop large numbers of delicate fibrils. These fibrils bind the cells closely together. The cells of the sheath, on the other hand, undergo cornification to a slight extent.

Carcinoma.—Tumors arise not infrequently from hair matrices; the cells composing them tend to differentiate in the same way as

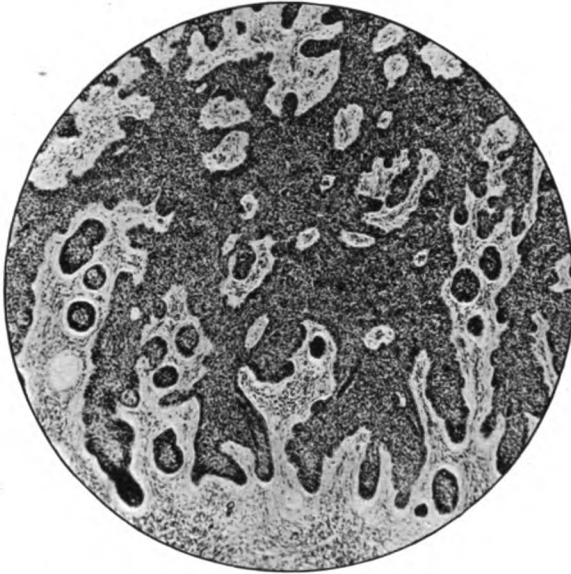

Fig. 287.—Hair matrix carcinoma. M.

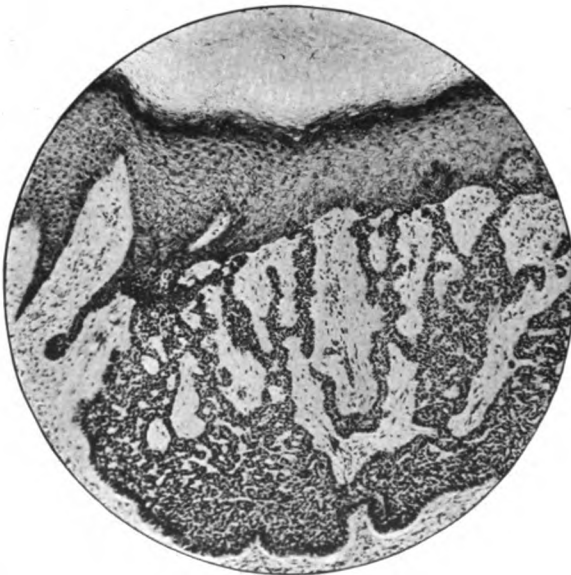


Fig. 288.—Hair matrix carcinoma forming connections with epidermis. M.

do the cells normally arising from these structures. The cells may occur as large masses of spindle-shaped cells running in bundles so that seen by themselves they suggest a spindle-cell sarcoma: they also occur in broad and narrow connecting bands. The cells are characterized by their cubical, cylindric or spindle shape, their small amount of cytoplasm, and their intimate relation to each other. In addition they frequently produce numerous long fine and coarse fibrils running in the direction of the long axis of the cells. Rarely, there is a hint of the formation of intercellular bridges and small epithelial pearls are occasionally present.

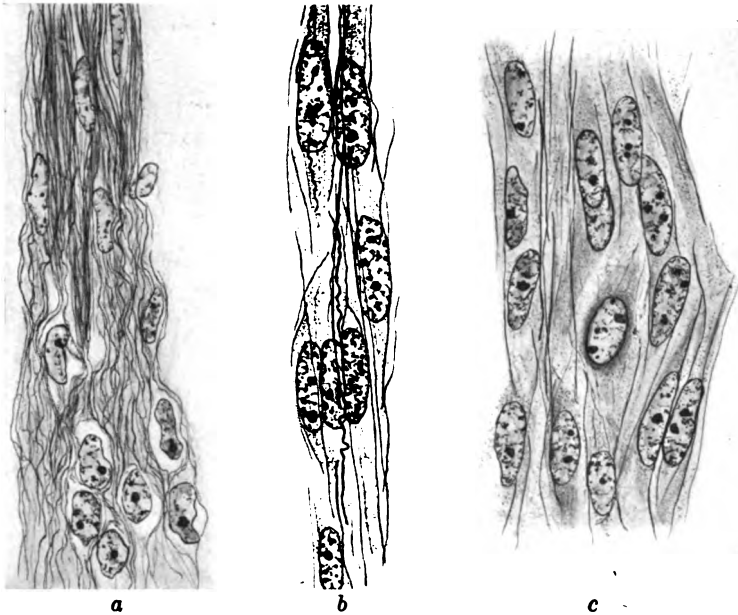


Fig. 289.—Hair matrix carcinoma. *a*, Cells and fibrils in normal hair shaft in fetus; *b*, *c*, cells and fibrils from hair matrix carcinoma.

The tumor in question usually grows slowly: it may spread widely in the corium and form connection with the overlying epidermis at many points. It rarely invades the deeper tissues or gives rise to metastases. While locally destructive it can hardly be considered clinically very malignant. It is usually but not always the lesion which is known clinically to the dermatologists as rodent ulcer. It has been very unfortunately named and elaborately classified into numerous varieties by Krompecher on the theory that it is derived only from the rete Malpighii of the epidermis and that, therefore, the cells do not undergo the usual transformation into prickle cells and cornified epithelium.

3. SEBACEOUS GLAND

The basal cells of sebaceous glands gradually accumulate fat in the form of small droplets in the cytoplasm which in this way becomes distended. The nucleus is gradually compressed and finally the cell is desquamated. The cells of a sebaceous gland may be said to be sharply characterized, although they undergo no differentiation.

Tumors of the characteristics of the sebaceous gland are rare. The example pictured is from an adenocystoma definitely encapsulated and larger than one's fist removed from a man's neck.

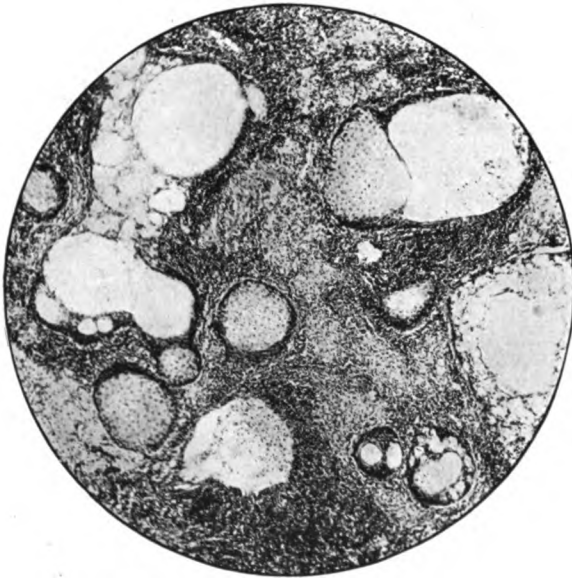

Fig. 290.—Adenocystoma of sebaceous gland origin. M.

The changes in the cells are perfectly characteristic. The numerous cysts present were filled with clear oil which on cooling and solidifying was of the color and consistence of butter.

Cancers arising from sebaceous glands are said to be of frequent occurrence in some animals.

4. COIL GLAND

The coil glands are lined by a single layer of cubical to columnar epithelial cells outside of which is a thin layer of slender rod-shaped fibrillated cells of epithelial origin running longitudinally. These two layers of cells characterize the coil gland.

Adenomas and adenocystomas of small size are sometimes derived from the coil gland; possibly also certain forms of cancer. It is not easy to say positively, because the characteristic fibrillated cells are not produced in malignant tumors.

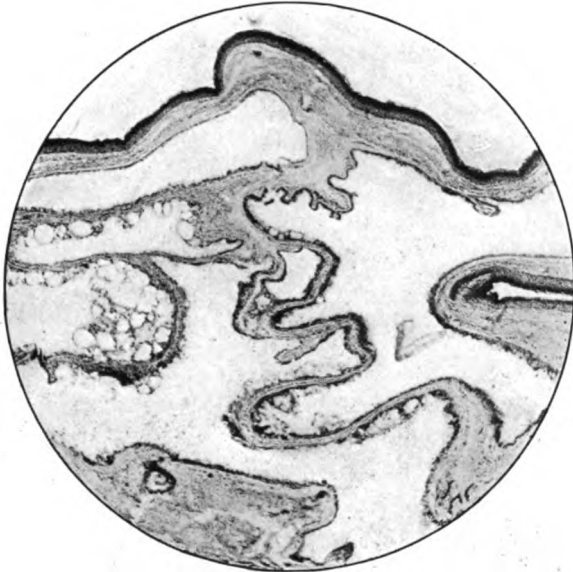

Fig. 291.—Adenocystoma of coil gland origin. M.

5. THE MAMMARY GLAND

The mammary ducts and glands are composed histologically of the same elements as the coil glands. They are lined with epithelial cells backed by a layer of slender fibrillated cells. These cells are usually called smooth muscle-cells, although of epithelial origin, and probably possess the power of contraction. In all benign epithelial tumors of the breast, both adenomas and papillomas, the epithelial cells lining the glands, cysts and papillæ are backed by these same fibrillated cells; but when the epithelial cells begin to proliferate in masses within the ducts there is no corresponding proliferation of the long cells. In like manner when the epithelial cells invade the stroma they are not accompanied by these characteristic cells. However, the epithelial fibrils occurring in cancers of the breast may owe their origin to these cells. It is fair to state, therefore, that there is not any striking peculiarity by which the cells of a carcinoma starting in the breast can be positively identified.

Several varieties of epithelial tumors arise in the breast. Some are distinctly benign, while others apparently from the beginning tend to invade and to give rise to metastases. Still others are

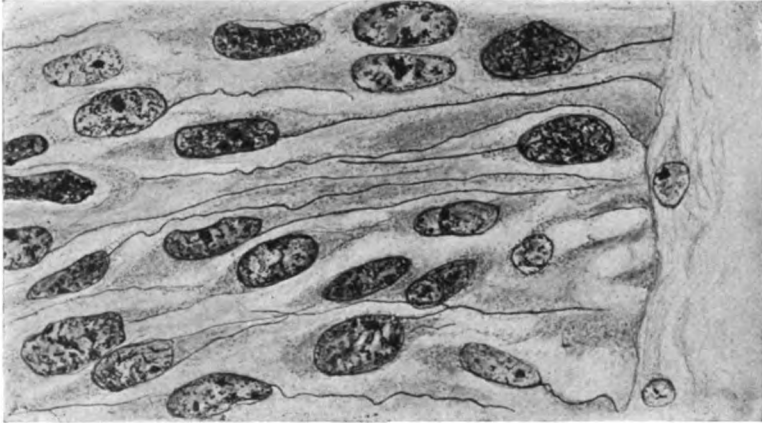


Fig. 292.—Carcinoma of breast. Epithelial fibrils within an alveolus.

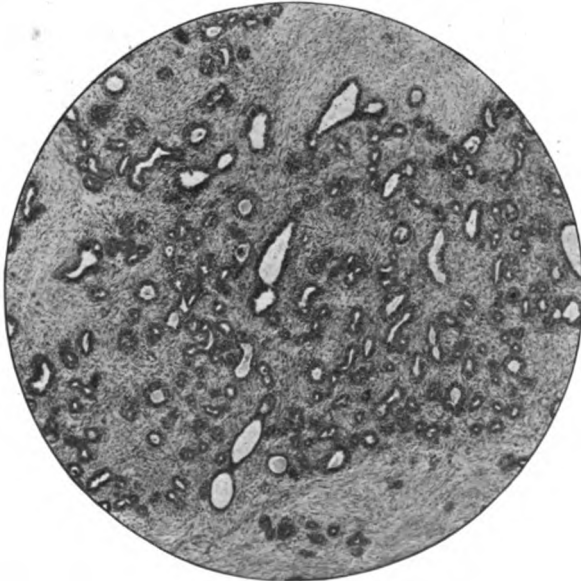


Fig. 293.—Adenoma of mammary gland. M. and W.

on the border line. They start like benign growths but are open to suspicion. Sooner or later they are almost sure to take on malignant properties and invade the surrounding stroma.

Epithelial tumors of the breast are very common. On this account and owing to the variety of them, they have been more studied than the new-growths from almost any other organ or tissue in the body.

Adenoma.—The adenomas vary considerably in histologic appearance. In some the glands are numerous and closely packed together; the stroma is moderate in amount. In others the stroma is very abundant and much the more prominent feature. All gradations between these two extremes occur.

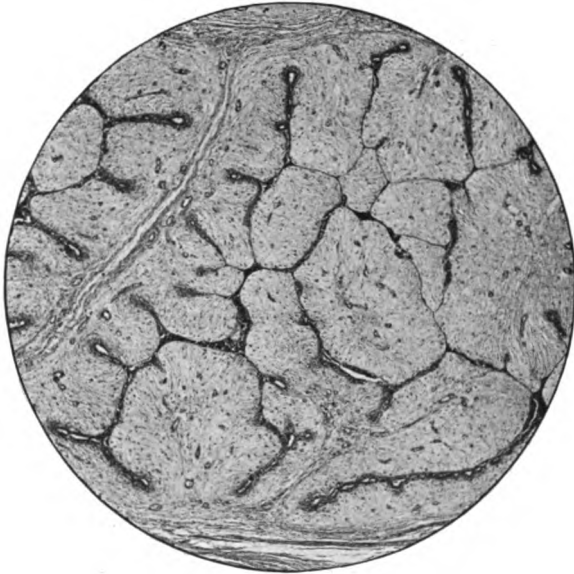

Fig. 294.—Adenoma of mammary gland, growing in intracanalicular papillary form. M. and W.

In some adenomas papillary projections extend into the gland lumina and distend them. The projections may be few in number or form a large part of the tumor. On section of one of these tumors in the fresh state the dilated glands and the papillary projections into them are often easily demonstrable by expanding the cut surface.

The adenoma is a common tumor of the breast in females between the ages of fifteen and forty-five years and occurs occasionally also in males. It grows expansively, is usually more or less spherical in shape, is encapsulated and may attain a large size. Sometimes it is multiple.

The stroma varies considerably in appearance. It may be

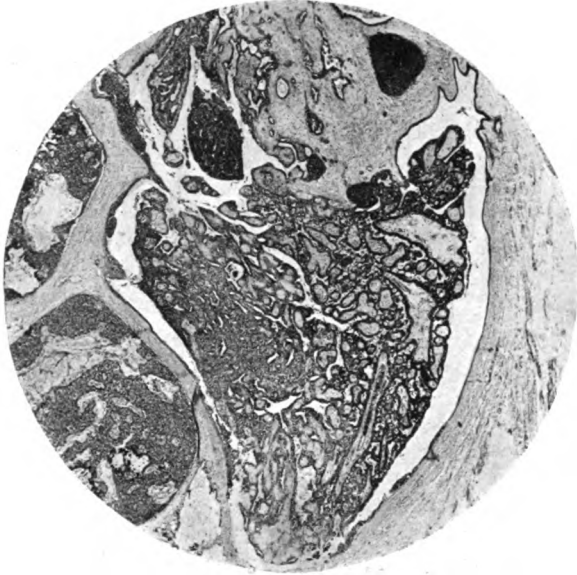


Fig. 295.—Epithelial tumor in ducts of mammary gland; is growing in papillary and gland form and in solid masses; has not yet invaded the normal stroma at any point, hence is in the pre-cancerous stage. M.

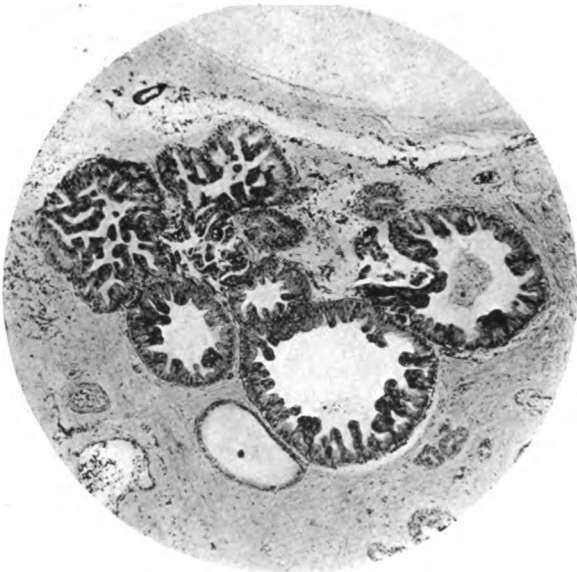


Fig. 296.—Mammary gland. Chronic mastitis. Proliferation of the epithelium in some of the glands; papillary masses of it project into the lumina. M.

dense and fibrous, edematous, or composed of mucous connective tissue, and occasionally is quite cellular so that it suggests a fibrosarcoma.

Papilloma.—Papillomas occur in the ducts of the mammary gland, especially near the nipple. They may dilate the duct so as to form a papilliferous cyst of considerable size. Usually they grow slowly, but occasionally with much rapidity. They are always to be regarded with more suspicion than the adenomas. Sometimes the epithelium grows into many of the ducts and glands and finally extends out into the surrounding connective tissue, showing that the tumor was from the beginning a carcinoma.

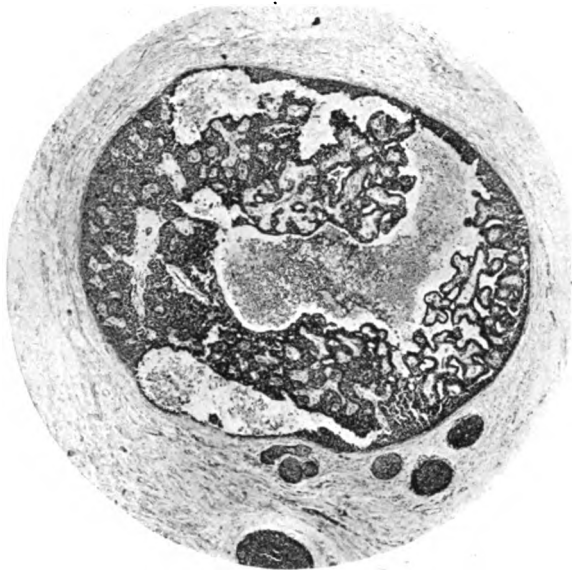


Fig. 297.—Epithelial tumor in duct of mammary gland; is growing in papillary and gland form and in solid masses. M.

Carcinoma.—It is a common experience to find in breasts removed for chronic mastitis small areas where the epithelium lining one or more glands or ducts is different in type from that occurring elsewhere. The cells are large and often form small projections into the lumen. Sometimes they fill the lumen completely. Occasionally these cells spread along ducts and glands, either replacing the lining epithelium or growing between it and the lining layer of elongated cells. In one instance practically every duct and gland in the breast was filled and often distended

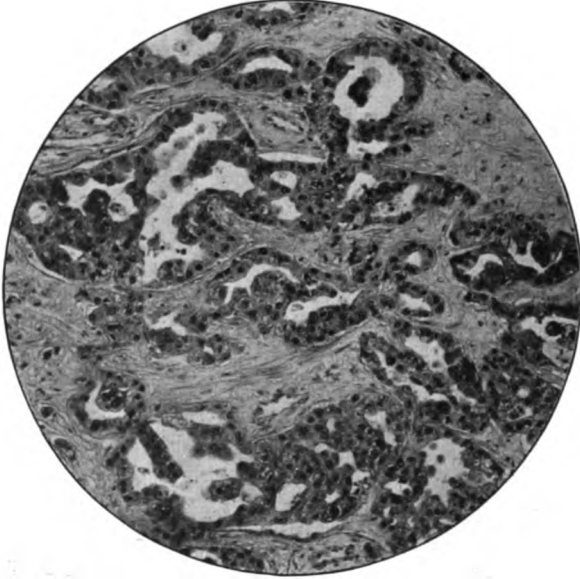

Fig. 298.—Carcinoma of mammary gland. Papillary adenomatous type of growth. M. and W.

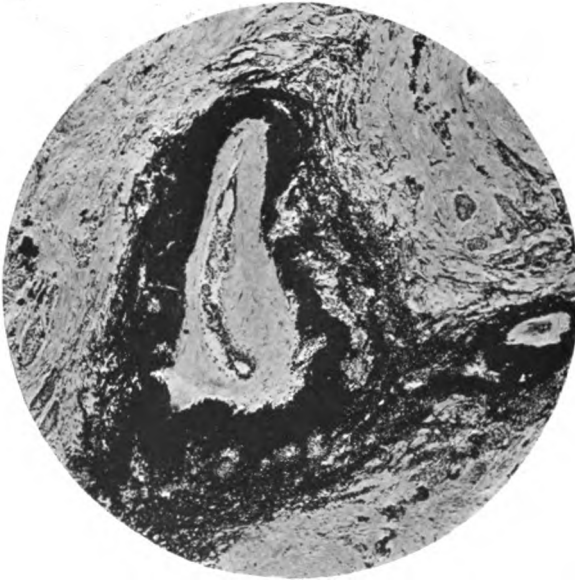

Fig. 299.—Carcinoma of breast. Excessive production of elastic tissue around duct. M. and W.

with cells in this way. Yet at no point had the cells invaded the adjoining stroma outside.

All these conditions are to be regarded with great suspicion; they show a marked tendency on the part of the epithelium towards malignancy. The condition has sometimes been called the pre-cancerous stage. Whether all cancers of the breast start in this way or not cannot be stated.

Cancers of the breast grow most often with the cells packed in solid masses, which in sections appear to be arranged in alveoli, but are really all more or less intimately connected together. The

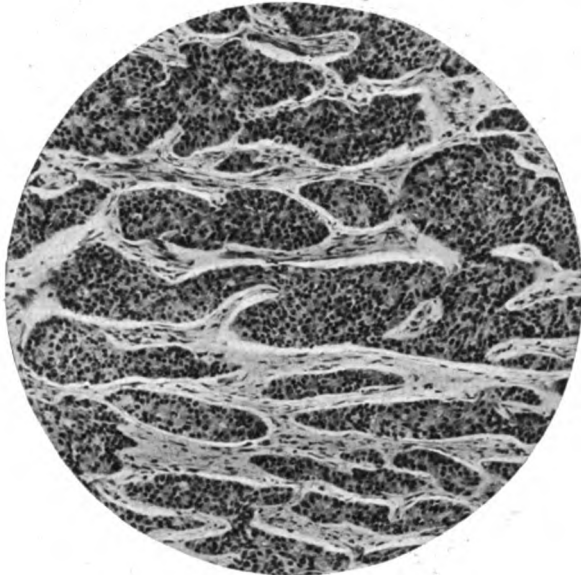


Fig. 300.—Carcinoma of mammary gland. Medullary type of growth. Slight tendency to the formation of gland lumina. M.

cell masses may be large or small and surrounded by little or much stroma.

Sometimes the cells of a cancer are arranged in gland form and still less often the glands are somewhat dilated and have small papillary projections into them.

Occasionally the cells of a cancer of the breast may in part at least produce hyaline material in the cytoplasm and thus form what is known as colloid carcinoma.

The stroma varies greatly in character, often within the same cancer. In some places it is dense and hyaline; in other places actively growing and very cellular. The reason for the differences

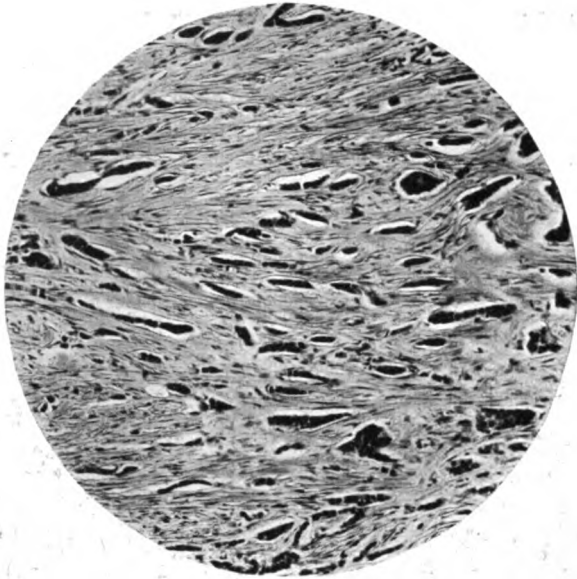


Fig. 301.—Scirrhous carcinoma of breast. Alveoli of epithelial cells small; stroma abundant. M.

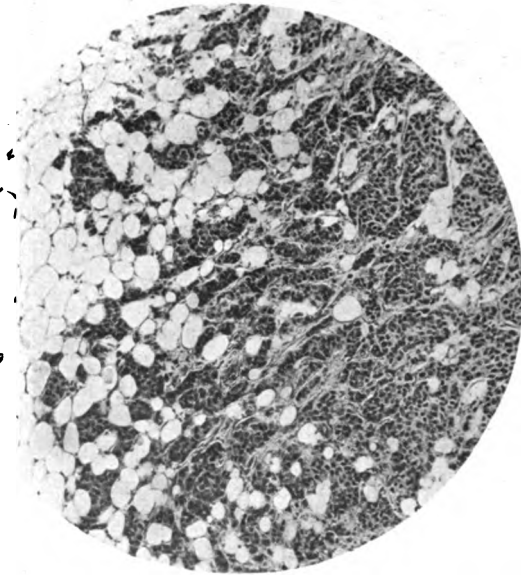


Fig. 302.—Carcinoma of mammary gland invading fat tissue. M. and W.

is not evident. Frequently the elastic tissue, especially around the blood-vessels, is greatly increased in amount. It would seem as if some chemical substance from the epithelium of the cancer frequently exerted a stimulating effect on the fibroblasts of the stroma. The methyl-violet stain for amyloid often gives a strong positive reaction with parts of the stroma, suggesting an abnormal product of some of the fibroblasts.

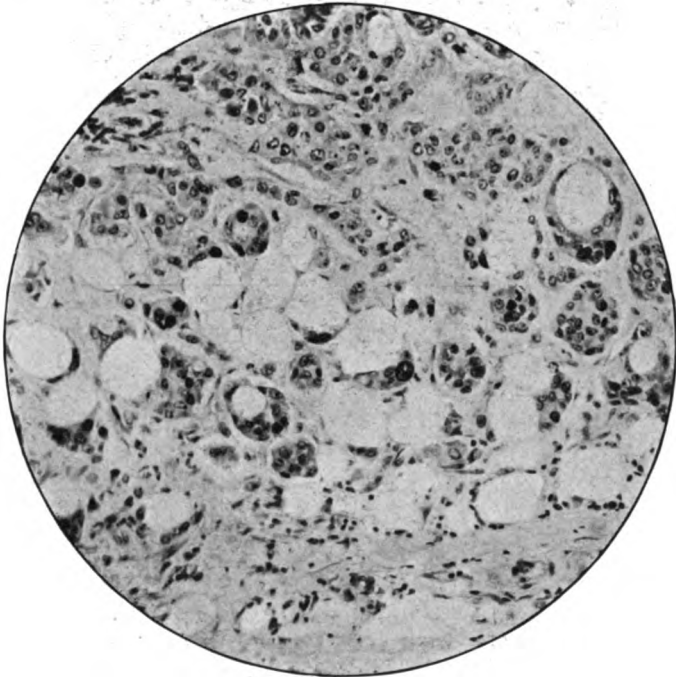


Fig. 303.—Carcinoma invading fat tissue, destroying fat-cells, and apparently utilizing the fat as nutrition. M.

Carcinoma of the breast occurs most commonly in the fourth and fifth decades. It may grow rapidly and form a large, more or less soft tumor mass (medullary cancer), or grow slowly and form a small dense nodule (scirrhous cancer). All possible intermediate gradations are found. The tumor may be fairly discrete and sharply limited or spread diffusely. It may invade and thicken the overlying skin or extend to the underlying pectoral muscles, or to the surrounding fat tissue. Metastases to the axillary lymph-nodes usually occur fairly early.

Cancer of the nipple is rare. It may start from the cylindric epithelium deep in a duct or from the squamous epithelium near

its mouth. In one instance a cylindric cell carcinoma of the duct, not over one centimeter in diameter, had given rise to metastases in the axillary lymph-nodes.

Epidermoid cancer of the duct tends to invade and replace the epidermis around the nipple, thereby causing a peculiar clinical picture which has received the name of Paget's disease of the breast.

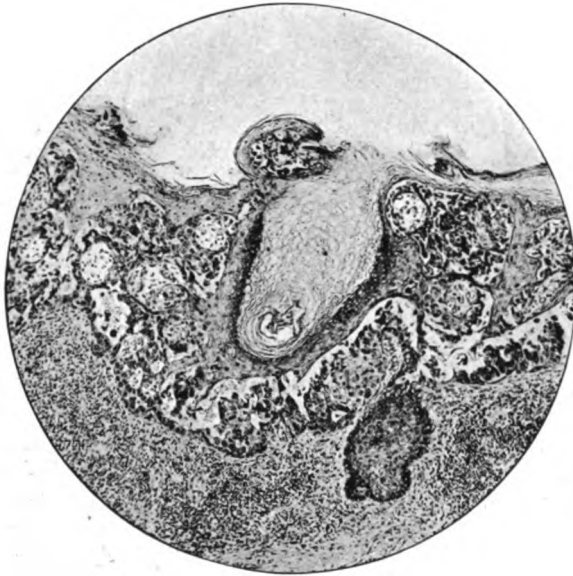

Fig. 304.—Epidermoid carcinoma of duct of mammary gland invading and growing in epidermis of nipple (Paget's disease of the breast.) M.

THE ENAMEL ORGAN

The cells of the enamel organ are of epiblastic origin, but do not undergo cornification. The cells of the outer layer are cuboidal in shape, those of the inner cylindrical. The cells between these two layers form the enamel pulp, and correspond to the prickle cells of the epidermis: they become more or less separated from each other by vacuolization, but remain connected by cell processes so that they resemble to some extent mucous connective-tissue cells. The nuclei in the cylindrical cells of the inner layer are situated away from the underlying connective tissue instead of close to it, as is usual in most other epithelial lined surfaces. It is these cylindrical cells which lead to the formation of enamel, and hence are known as adamantoblasts.

The dentin is formed by specialized fibroblasts known as odontoblasts. Still other fibroblasts form a periosteum and deposit a layer of true bone called cementum outside of the dentin.

The cells of tumors which arise from adamantoblasts tend to differentiate in the same way as the normal adamantoblasts do and they also tend to produce the effect of the normal cells on the adjoining fibroblasts, that is, they sometimes convert them into odontoblasts.

Three types of tumors are recognized as arising from the enamel organ.

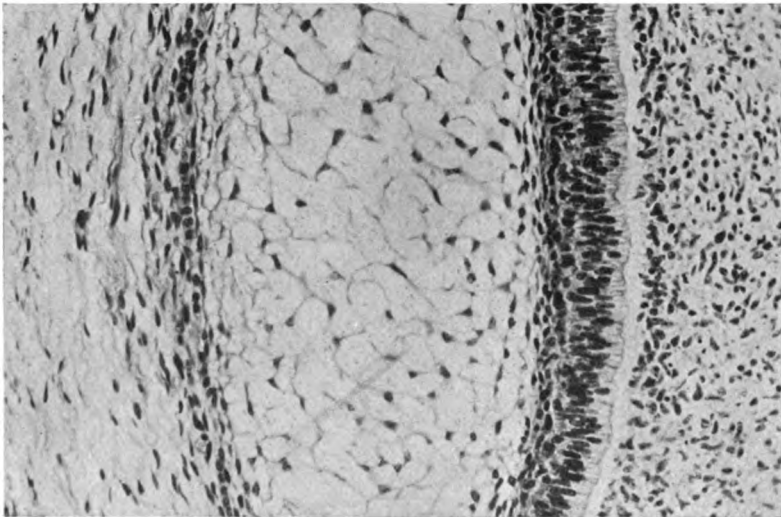


Fig. 305.—Enamel organ from fetus. Pulp cells of epithelial origin in center. The nuclei in the adamantoblasts on the right are situated away from the stroma. M.

1. The *follicular* cyst is the simplest. It consists of a cyst lined with pavement epithelium. The inner wall of the cyst often bears a single, rarely several to many teeth.

2. The *adamantinoma* grows as branching masses of epithelial cells of which those adjoining the stroma correspond to adamantoblasts while the others form the enamel pulp. Cysts often form owing to distension and coalescence of the vacuoles lying between the cells corresponding to those in the enamel pulp. Other cysts which may be more numerous and larger often occur in the connective tissue of the stroma as the result of focal collections of fluid. Blood-vessels will always be found running through this second form of cyst. Rarely the cells cor-

responding to those in the enamel pulp assume a concentric arrangement and suggest or may even form definite epithelial pearls.

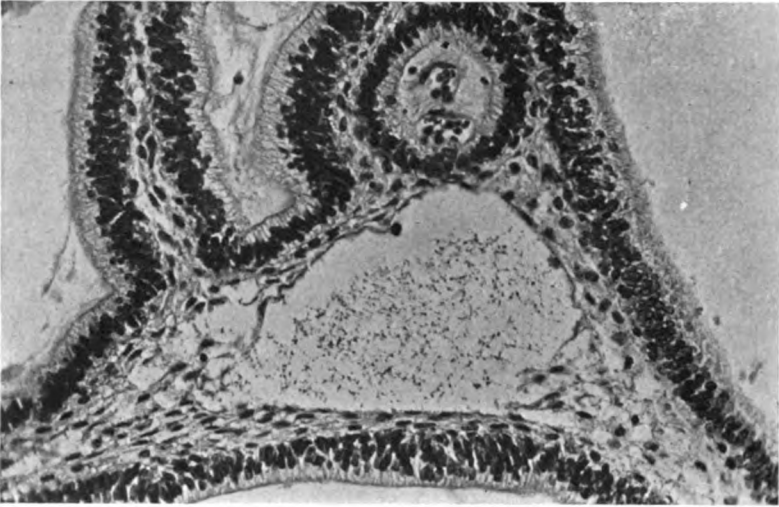


Fig. 306.—Adamantoblastoma. Cyst forming between the pulp cells. M.

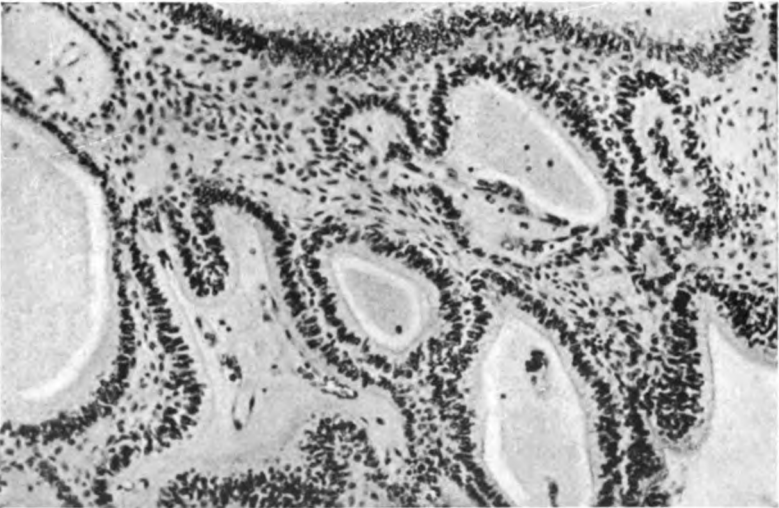


Fig. 307.—Adamantoblastoma. Cysts forming in stroma around blood-vessels. The nuclei in the epithelial cells are situated away from the stroma and hence from the cysts. M.

This result is not surprising considering the origin of the enamel organ.

The adamantinoma grows expansively only and produces no metastases. Owing to its location and the size it sometimes reaches it may cause clinically much local disturbance.

3. Occasionally the adamantinoma produces typical enamel. More often it converts adjoining fibroblasts into odontoblasts. When this happens separate teeth or fused masses of them (odontoblastoma) of various sizes may be produced. Cementum may also sometimes be formed.

EPITHELIAL TUMORS OF THE GASTRO-INTESTINAL TRACT

Esophagus.—The esophagus is lined with stratified pavement epithelium and is furnished with two varieties of glands, neither of which is particularly characteristic. Epithelial tumors may be derived from the surface epithelium or from that of the glands.

Adenomas and papillomas, the latter occasionally multiple, have been reported but are rare.

Carcinoma is much more common. As a rule it is of the epidermoid type, but malignant adenomas sometimes also occur. Combinations of the two types have been reported; also very rarely carcinomas with ciliated cells.

Stomach.—The glands of the stomach are characterized by the presence of acidophilic parietal cells in varying numbers. In addition there are two other varieties of epithelial cells; one kind in the body of the gland contains relatively large zymogen granules, the other kind in the neck of the gland secretes mucus. In the epithelial tumors arising from the stomach the acidophilic parietal cells and the cells containing zymogen granules apparently do not appear.

Adenoma sometimes occurs; it forms a polypoid mass and may be multiple. It is always to be regarded with suspicion.

Carcinoma of the stomach may grow in gland form (malignant adenoma), but the cells more often occur in solid masses. The cells of either type of growth may undergo a hyaline change so that the tumor is variously called hyaline, mucous, gelatinous or colloid carcinoma.

The gross appearances of cancer of the stomach vary greatly. If the tumor grows rapidly (medullary carcinoma), it may form a large, soft, cauliflower-like mass which histologically is usually of the gland type. Necrosis may lead to more or less extensive ulceration.

If the tumor grows slowly (scirrhous carcinoma) it tends to infiltrate the wall of the stomach widely, occasionally involving its entire extent. The surface is almost invariably ulcerated. Histologically the cells are grouped in small, solid masses.

The colloid cancer is usually scirrhous in its type of growth

and tends to infiltrate extensively. Rarely it may lead to marked uniform thickening and hyaline transformation of the entire stomach wall.

Rarer forms of cancer of the stomach are the epidermoid and the ciliated.

Intestine.—The epithelial cells lining the intestinal tract are of the tall columnar type. They are all capable of being transformed into goblet cells by the production of mucus. At the bottom of the crypts of Lieberkühn in the small intestine the cells often contain numerous zymogen granules. The cells of Brunner's glands in the duodenum secrete mucus.

Adenomas of the intestine occur in the form of polypi of which the surface may be smooth or papillary. They are often elevated, each on a slender stalk which may reach a length of a centimeter or more. The polypi are often multiple and occasionally very numerous, especially in the large intestine. As a rule, the epithelium lining them is of a different character from that present elsewhere in the intestinal tract. The significance of these polypi is in dispute. They may belong among the malformations. Certain it is that cancer may, at least occasionally, arise from them.

It is even more difficult to decide the exact nature of certain small tumor-like collections of epithelial cells occurring occasionally in the appendix, but also more rarely in the small intestine. They resemble a carcinoma in structure and are found most often in young people. The cells are small, are grouped in gland form or in solid masses, and may occur not only in the mucosa but also in the muscle coats and subperitoneally. In the appendix they often look as if they had started from the mucosa and more or less completely destroyed it, and then infiltrated the surrounding muscle and fibrous tissue. On the other hand they show little or no activity of growth and there is no evidence of reaction on the part of the tissue around them. They are regarded by some as a local tissue abnormality comparable to the congenital nevi of the skin.

True cancers occur most often in the rectum; less commonly in the ileocecal region, in the duodenum, and elsewhere. They are of much the same character as those found in the stomach. The malignant adenoma and the adenocarcinoma are the most frequent, but colloid and scirrhous forms also occur. They often completely encircle the intestinal wall, thus presenting an annular form, and may lead to complete stenosis of the lumen. Sometimes they extend directly to the surrounding organs, especially in the pelvis. Metastases are frequent, most often to the liver where they may cause great enlargement (over fifteen kilos in one instance).

Carcinoma of the papilla of the common bile duct occurs occasionally and is clinically of great importance, although it may not exceed one centimeter in diameter, because it usually leads to complete bile stasis.

Liver.—Two different types of epithelium occur in the liver; the liver cells and the bile duct epithelium.

The liver cells are characterized by their size and shape, by the secretion of bile, and by their arrangement in cords or trabeculæ around minute canals, the bile capillaries.

The bile ducts are lined by low and high columnar epithelial cells which are not in any way peculiar.

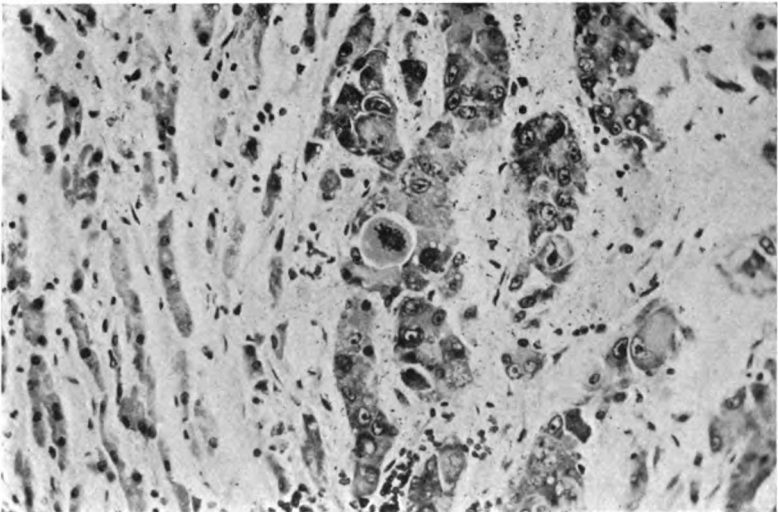


Fig. 308.—Liver. Liver-cell carcinoma on right. One mitotic figure present. M.

Adenoma.—Two different types of adenomas occur in the liver, derived from the two different kinds of epithelial cells.

The *liver cell adenoma* is the more common of the two. It is sometimes more easily recognized by the naked eye than microscopically, and may be difficult to distinguish from the local hyperplasia of liver cells which sometimes occur in chronic inflammatory processes. In a true liver cell adenoma bile ducts are not present. The tumor grows expansively and exerts pressure on the surrounding cells so that they are flattened. The structure of the liver cells and especially the formation of bile capillaries and the secretion of bile positively identify the nature of the new-growth.

Bile duct adenomas are less common and have no particular characteristics beyond forming a mass of glands and ducts more or less closely resembling bile ducts.

A third kind of adenoma sometimes occurs and must be carefully distinguished from the liver cell adenoma. It arises from displaced adrenal cells, grows without any kind of lumen formation, and of course lacks the characteristic bile capillaries of the other type of adenoma.

Primary *carcinoma* of the liver is rare. It may arise from liver cells, under which circumstances the tumor cells may closely resemble the liver cells, but are usually larger. They may secrete bile and form bile capillaries even when growing fairly rapidly.

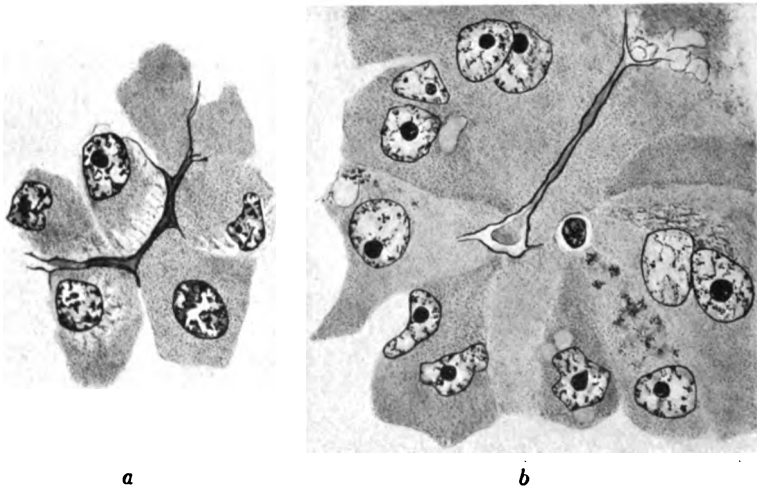


Fig. 309.—Liver-cell carcinoma. Bile capillaries present; the one in *b* contains inspissated bile.

The same characteristics may be shown by the metastases in other parts of the body.

Carcinoma may also arise from the bile ducts. This form sometimes spreads diffusely along the portal vessels. When this happens it is often extremely difficult to tell the normal bile ducts from the tubules produced by the tumor. In one instance the problem was made easier because the tumor cells were to a large extent ciliated.

Cancer may also arise from adrenal rests, and present the same peculiarities as that form of tumor does elsewhere.

When a cancer of the liver grows without any differentiation of the cells, that is, in solid masses and usually rapidly, the exact

nature of the cells from which it started often cannot be determined with any degree of certainty.

Cancer of the liver may form one large primary nodule with or without smaller secondary nodules around it, or occur as a diffuse infiltration with much connective-tissue formation so that the sclerosed liver is easily mistaken for some form of cirrhosis of inflammatory origin. Various gradations between these two extremes may also occur.

Gall-bladder.—The gall-bladder is lined with columnar epithelium of the same character as that in the bile ducts.

Papillomas occur but are very rare.

Carcinoma is relatively frequent and is found almost exclusively in gall-bladders which have contained gall-stones. It starts in the wall, usually infiltrates, and often invades the liver; rarely it projects in papillary form into the gall-bladder. The cancer is generally of the cylindrical cell type and sometimes undergoes the colloid change. Rarely it is a typical epidermoid carcinoma, starting probably from a pavement epithelium which has arisen metaplastically from the cylindrical epithelium as the result of chronic irritation. Such irritation is due most often to gall-stones.

Pancreas.—Three types of epithelium occur in the pancreas. The gland cells are characterized by the production of coarse zymogen granules in the cytoplasm adjoining the lumen, and by the basophilic staining properties of the basal homogeneous portion. The ducts are lined with a simple columnar epithelium. The islets contain epithelial cells of a smaller type and of two varieties named A and B; each is characterized by the presence of fine granules of peculiar chemical and staining properties.

Adenomas of the structure of the islets occur rarely; also adenocystomas apparently of the type of the duct epithelium.

Cancer is somewhat more common: it is usually scirrhus in type, but may grow rapidly or undergo hyaline change. As a rule cancer starts in the head of the pancreas. In one instance the tumor was glandular in type and the cells ciliated.

RESPIRATORY TRACT

The larynx is lined in part with stratified squamous epithelium which passes over into the pseudo-stratified ciliated columnar epithelium lining the trachea and bronchi. Numerous mucous glands pour their secretion into these air passages. The alveoli are lined with flattened epithelium. The several forms of epithelial cells present no striking peculiarities.

Papilloma is the commonest tumor affecting the larynx: it is usually located on the vocal cords and may more or less occlude the lumen.

Carcinoma usually of the epidermoid type also occurs and as a rule starts on the vocal cords.

Carcinoma of the lung is rare although the commonest primary tumor of this organ. It usually arises from bronchial epithelium.

THE GENITO-URINARY TRACT

Kidney.—The renal epithelium lining the tubules is derived from two sources: the uriniferous tubules originate in the nephrogenic tissues; the ducts of the kidney, from the papillary ducts to the collecting tubules of the medullary rays, arise from the epithelial buds which develop from the side of the Wolffian ducts. The cells lining the uriniferous tubules are, for the most part, more highly differentiated than those lining the ducts.

Small adenomatous structures occur in the kidney, usually in the cortex, and may have papillary projections into them. The lining cells are columnar in type and suggest renal epithelium. These structures usually show no evidence of exerting pressure on the adjoining tubules; they may be irregular in form and enclose glomeruli and tubules. They are probably to be regarded as abnormalities. Rarely, however, expansively growing adenomas do occur, which apparently are of renal-cell origin.

Adrenal rests of various sizes may occur in the kidney, usually in the cortex or in the capsule. They also are to be looked upon as congenital abnormalities.

Cancer of the kidney is relatively frequent. Most of the tumors are composed of cells of the adrenal type and are probably derived from adrenal rests. They grow often with great rapidity, invade the renal vein or its branches and give rise to multiple metastases in the lungs and elsewhere. Less often they extend into the pelvis of the kidney. The cells of these tumors frequently vary in shape and structure in different areas.

Cancer of renal-cell origin is much less common. The cells may grow in solid or gland form and form nodular masses or infiltrate diffusely.

Pelvis of Kidney and Ureter.—They are lined with stratified epithelium of the same origin as that lining the renal ducts.

Papillomas are of rare occurrence.

Urinary Bladder.—The urinary bladder is lined with stratified epithelium of the same origin as that in the ureter and in the pelvis of the kidney.

Papillomas of the bladder are not infrequent and although many of them are regarded as benign they should always be looked upon with suspicion. The almost invariable termination is infiltration of the bladder wall at the base of the tumor. The papillary projections are often long and delicate and covered with

a stratified epithelium. Epithelial fibrils are often demonstrable in and between the cells.

Typical epidermoid carcinomas containing numerous epithelial pearls sometimes occur: less often adenomas (derived, perhaps, from the prostate). Some forms of cancer may undergo hyaline change.

Prostate.—The alveoli of the prostate are lined with simple columnar epithelium. The cytoplasm of the cells often contains acidophilic granules on the side adjoining the lumen. The ducts are also lined with columnar epithelium, except near their terminations where its place may be taken by a stratified epithelium.

Hyperplasia and dilatation of the preëxisting glands and ducts of the prostate are common in old age and are often looked upon, but probably incorrectly, as adenomas. True benign adenomas may occur but they are certainly rare, and reported cases are doubtful. They ought to grow expansively, shoving back the part of the prostate surrounding them, not extending diffusely throughout the organ.

Cancer of the prostate is fairly frequent in old men and the cells are usually of small size and grow in solid masses or gland form. They are supposed to arise from the epithelium lining the glands. The tumor may grow in nodular form, or so diffusely infiltrate the prostate as not to be recognized, aside from the resulting hypertrophy, except on microscopic examination.

A frequent peculiarity of cancer of the prostate is to give rise to metastases in the bone marrow and to cause a marked reaction on the part of the peri- and endosteal cells so that much, often dense, osteoplastic stroma is produced. Metastases also take place retroperitoneally, into the lungs and elsewhere.

Uterus.—The mucosa of the body of the uterus and of the cervix is lined with a single layer of columnar ciliated epithelium, but the cells lining the glands of the cervix are tall, cylindrical and secrete mucus.

Adenomas in the form of mucous polyps are not infrequent. The epithelium lining them corresponds in type to that part of the mucosa from which they spring. The stroma varies in amount, is often abundant and sometimes edematous.

Cancer of the uterus is very common. In the fundus it may grow in solid alveolar or in gland form. It may remain sharply localized in the mucous membrane, but invade deeply in the underlying muscle-wall. More often it spreads gradually through the entire mucosa and infiltrates the muscle everywhere.

Cancer of the cervix starts most often from the stratified epithelium covering it externally and extending a varying distance through the external os into the cervical canal. On this account

cancer of the cervix is usually of the epidermoid type. Sometimes it is infiltrated with great numbers of eosinophiles. Frequently it presents a cauliflower-like appearance.

Ovary.—The ovary is almost entirely covered with mesothelial cells which here are cubical to cylindric in shape and are known as the germinal epithelium. From them are derived the primary egg tubes of Pfüger, which form the ova and the cubical follicular cells surrounding them. The stroma is cellular and abundant.

The epithelial tumors of the ovary are numerous and important. The simple cysts of various sizes and origin probably do not belong in this category.

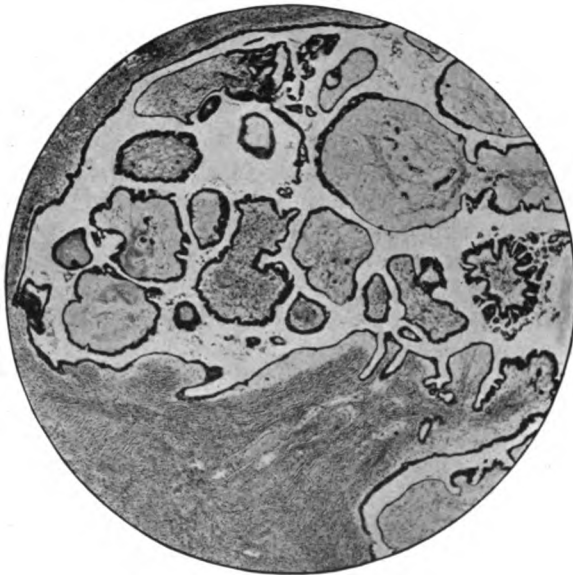

Fig. 310.—Ciliated papillary adenocystoma of ovary. M.

The adenomas of other organs are replaced here by adenocystomas. Two types are recognized; the simple and the papillary.

The simple adenocystoma is a multilocular tumor often of large size. It is composed of glands and cysts lined with tall cylindric epithelial cells which produce a mucoid secretion. The cysts are filled with this pseudomucin which varies greatly in consistence and in color. The inner surface of the cysts is smooth.

The papillary adenocystoma differs from the simple adenocystoma chiefly in having papillary projections from the walls. This condition indicates greater activity on the part of the epi-

thelium. These projections may be located in one small area or be more or less extensive, in some instances covering the wall of all the cysts and sometimes more or less completely filling them. Apparently all gradations between the simple and the papillary adenocystoma may occur. On the other hand the cells lining some of the papillary adenocystomas are ciliated. This condition would seem to indicate a possible difference in origin for at least some of them.

Sometimes either by direct growth through the wall or by rupture of a cyst, a papillary adenocystoma grows on the surface of an ovary largely in the form of a papilloma.

These epithelial tumors of the ovary vary from benign to malignant. To draw a sharp line of division is impossible. The papillary adenocystoma is always to be regarded with more suspicion (especially if its cells are ciliated) than the simple adenocystoma. If the epithelial cells form a single orderly arranged layer and are multiplying so slowly that no mitotic figures can be found, the tumor may be looked upon as benign and classed with the adenomas of other organs; but if the cells tend to pile up into two or more layers and cell proliferation is rapid, the tumor should be regarded as a carcinoma.

The opportunity for one of these tumors to invade is not great because the ovary is, to a large extent, free from actual contact with other tissues. On the other hand, the ovary itself is often entirely invaded and destroyed.

If one of the cysts of a papillary adenocystoma ruptures so that its contents escape into the peritoneal cavity multiple surface implantations of freed tumor cells often take place. This form of metastasis indicates at least a mild degree of malignancy. In occasional instances, however, metastases have taken place also apparently through the lymphatics into the thoracic cavity.

While these two forms of adenocystoma, and especially the papillary type, are not infrequently malignant and, therefore, to be classed as carcinoma, that term is usually reserved for the malignant epithelial tumors of the ovary which grow in solid form, that is, in which cysts are not present. The cells may grow in the form of glands or they may be massed together. The stroma is often excessively abundant. Occasionally multiple concretions appear and become calcified (psammo-carcinoma). The tumors form solid masses the size of the fist or larger and sometimes possess a peculiar yellow color.

The accidental finding of a small, infiltrating, ciliated, papillary adenocystoma in the broad ligament suggests that tumors of this type may arise from remains of the Wolffian tubes in the ligament. Similar ducts and glands lined with ciliated epithelium

and surrounded by smooth muscle frequently occur in the uterine tube. It is the ciliated papillary adenocystomas which prove clinically to be especially malignant. It seems much more probable that they are derived from the ciliated remains of the Wolffian and perhaps Müllerian ducts than from displaced intestinal epithelium as suggested by Ribbert.

What is needed is the careful study of early cases before the ovaries are infiltrated and destroyed and all relations lost. The finding of small solid masses of squamous epithelium in the outer wall of two different normal uterine tubes, and the occurrence of a thick layer of squamous epithelium lining one fold of the tubal mucosa while the rest was perfectly ciliated, suggests the possible origin of epidermoid carcinomas in this region.

ADRENAL GLAND

The cortex of the adrenal gland consists of epithelial cells arranged in three zones. The cells are characterized by the presence of numerous fat-droplets in many of them (chiefly in the

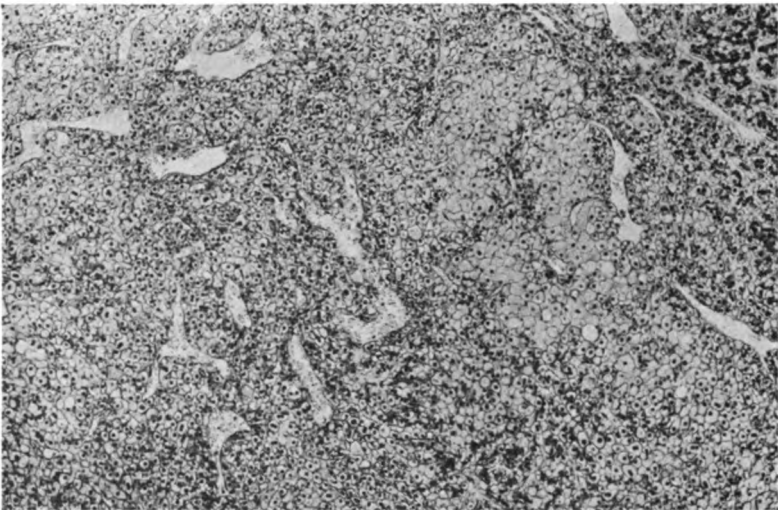


Fig. 311.—Adrenal carcinoma. M. and W.

two outer, glomerular and fascicular zones), and of pigment granules in some of them (in the innermost reticular or pigmented zone). The medulla is composed largely of chromatin cells derived from the sympathetic nervous system. These cells are smaller than those in the cortex and contain granules which are stained brown by chromic acid and its salts. Numerous ganglion cells and their nerve fibrils are also present.

The connective-tissue stroma of the adrenal is slight in amount, especially in the cortex. The blood-vessels are largely of the capillary type.

Adenomas of the adrenal gland are common and vary much in size. They arise most commonly in the cortex, but also occasionally in the medulla and in the capsule from displaced cortical cells. As a rule, the tumor cells are characterized by the presence of numerous fat-droplets which cause the new-growth to have the characteristic yellow color of the adrenal cortex. Occasionally

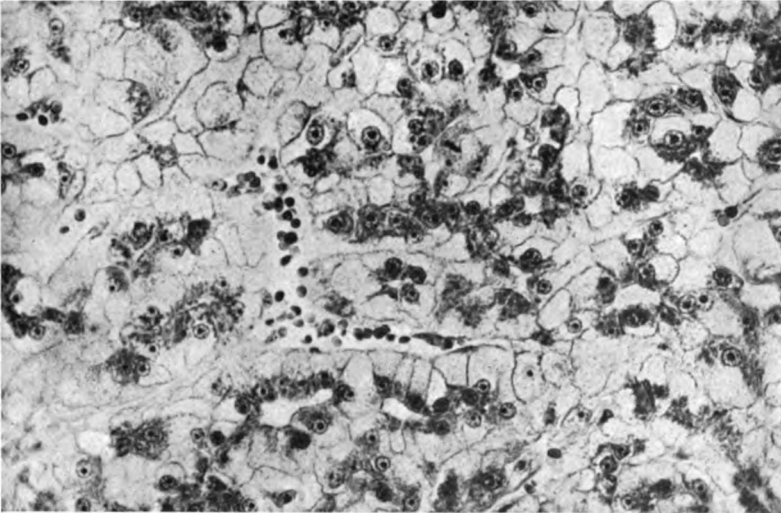


Fig. 312.—Adrenal carcinoma; actively growing part. One mitotic figure present. M.

adenomas occur adjoining the medulla, in which the tumor cells are pigmented and thus correspond in their differentiation to the pigmented zone.

The stroma of connective tissue and blood-vessels of the adenomas usually corresponds in character to that of the normal adrenal gland.

Carcinoma of the adrenal gland is of less common occurrence than adrenal cancer of the kidney. The tumor cells usually differentiate like the cells of the adrenal cortex and contain numerous fat-droplets.

THYROID GLAND

The thyroid gland is composed of cubical epithelial cells arranged in non-communicating acini of various sizes grouped in lobules. The cells secrete a hyaline substance called colloid or colloid

material. The colloid is characterized by the presence of iodine in combination with protein. The characteristic feature of the epithelial cells lies in the secretion which they produce.

Under various pathologic conditions the acini may become dilated with colloid material or they may increase greatly in number and contain little or no secretion. These changes may take place diffusely or in foci.

The connective-tissue stroma of the thyroid is fairly abundant and the blood-vessels numerous.

Adenomas of the thyroid are not infrequent, but it is often difficult to recognize them with certainty, at least when one has to decide from material removed surgically. A microscopic slide

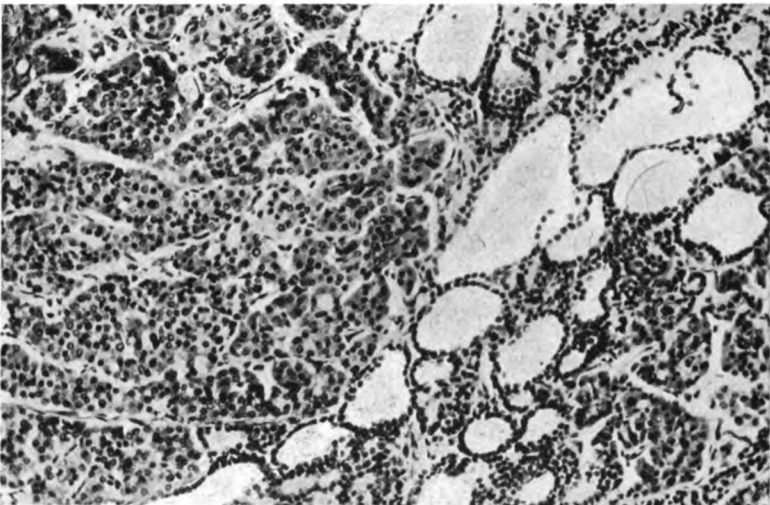


Fig. 313.—Thyroid gland. Carcinoma growing in solid form and gradually invading it. M.

preparation will not, as a rule, settle the question because there is nothing distinctive about an adenoma of the thyroid. What one really requires, or perhaps would like to have, is the whole thyroid gland with the tumor nodule in place.

An adenoma must be distinguished first from normal or abnormal thyroid tissue, and then from focal collections of colloid material in dilated glands and from focal hyperplasia of acini. It is claimed that in adenomas, inasmuch as the growth is expansive and the stroma new formed, no elastic tissue is present except along the blood-vessels. In other words elastic fibrils cease at the capsule of the tumor. This point may be of some diagnostic value.

With carcinoma of the thyroid gland much the same difficulty

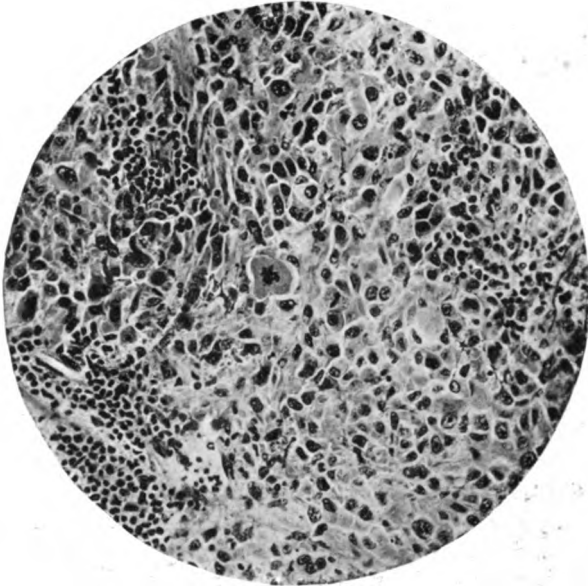


Fig. 314.—Thyroid gland. Rapidly growing carcinoma. Two mitotic figures in center of field. M.

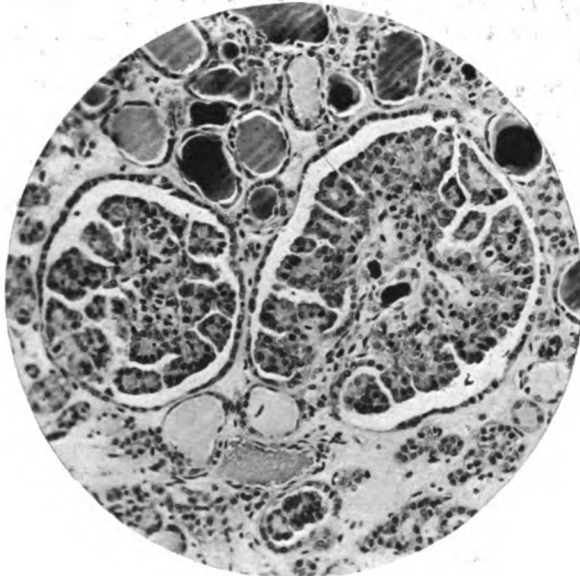


Fig. 315.—Thyroid. Illustration shows two small masses of a papillary epithelial tumor. A mitotic figure present in lowest clump of tumor cells in right hand mass. M.

in the way of making a positive diagnosis is sometimes presented. The cancer may grow with the cells arranged in solid masses in a well developed stroma. Here the atypical cell arrangement is sufficient, as it is also in the rare cases when the cancer grows in the form of a papillary adenoma.

In other instances, however, the cancer corresponds in every way to normal thyroid tissue and even in its metastases in the liver, lung, bone marrow, etc., produces typical colloid material containing iodine. Cases have even been reported where metastases of this structure were present in various organs when the thyroid gland itself was apparently normal in every respect with no evidence of any tumor being present.

HYPHYSIS

The hypophysis contains in the glandular or anterior lobe alveoli filled with two varieties of epithelial cells; chromophilic cells in whose cytoplasm are numerous coarse granules which stain deeply with acid dyes, and basophilic cells which are more numerous and contain fine granules with a strong affinity for the basic stains. Chiefly adjoining the posterior lobe occur epithelial lined acini which are similar to those in the thyroid gland and usually contain colloid material.

Adenomas consisting of either chromophilic or basophilic cells are said to occur, especially after the age of forty. They may be found on microscopic examination.

Carcinoma is also said to occur. It may extend through the capsule and invade the adjoining bone or brain tissue. The tumors containing acidophilic cells are the more important as they may be associated with symptoms of acromegaly.

Very rarely epithelial tumors arise from the colloid secreting glands.

Epiphysis.—The pineal gland contains follicles lined and sometimes entirely filled with epithelial cells. Some of the follicles contain round and irregular concretions known as brain sand.

Very rarely carcinomatous tumors arise from the epiphysis.

CHORDOBLASTOMA (CHORDOMA)

Definition.—A tumor of entodermal origin of which the cells tend to differentiate into cells like those forming the notochord.

The notochord is a rod of entodermal cells forming the axis around which the bodies of the vertebræ are laid down. It disappears for the most part from the body of each vertebra during fetal development, its tissue being forced into the intervertebral disk where it develops into the nucleus pulposus.

The notochordal tissue starts as epithelial cells which develop vacuoles containing mucin. Later, the cell walls disappear and the cytoplasm fuses to form a syncytium which resembles fetal mucous connective tissue. The mucin escaping from the vacuoles in part remains in the cytoplasmic mesh, in part collects around the notochord, forming an inner sheath. A still later change is the formation of more or less definite cells or cell-like structures in the syncytium, each of which contains one to three large vacuoles filled with serum. These peculiar vacuolated cells are characteristic of adult notochordal tissue. They occur in rows and clumps of various sizes, separate and surrounded by more or less mucin which acts as an intercellular substance, and usually held some-

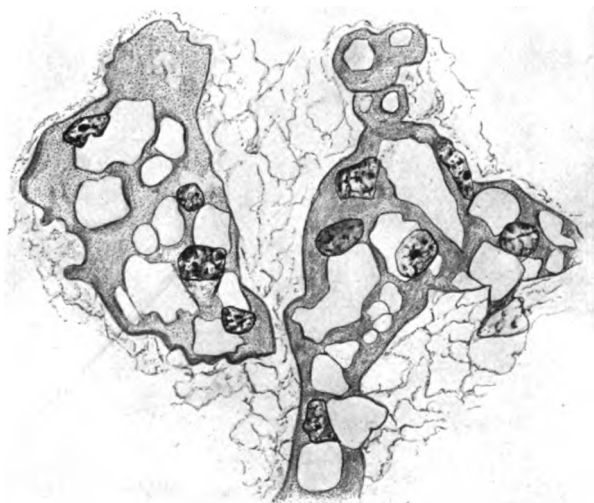


Fig. 316.—Notochord tissue from base of skull. Numerous cysts present in cytoplasm of syncytial cell masses.

what intimately together by a small amount of syncytial cytoplasm.

The cells of a chordoblastoma tend to differentiate into the vacuolated cells which are characteristic of adult notochordal tissue. In the one rapidly-growing malignant tumor of this nature reported, situated on the upper surface of the basi-occipital bone, all types of notochordal cells were present, the fetal as well as the adult.

The chordoma is of much theoretical interest, but has little practical significance as but one other instance of a real tumor of this kind, besides the one mentioned above, is as yet on record.

The illustrations are from a third case, not yet reported, in which the tumor started over the coccyx in an elderly person and recurred twice within two years after removal.

On the other hand, very small masses of notochordal tissue are found not infrequently in certain definite locations and their nature should be recognized. They occur most often upon the dorsum sellæ, less frequently in the hypophysial fossa and at the spheno-occipital junction, rarely elsewhere (anterior surface of the cervical vertebræ and on the sacrum). Although commonly

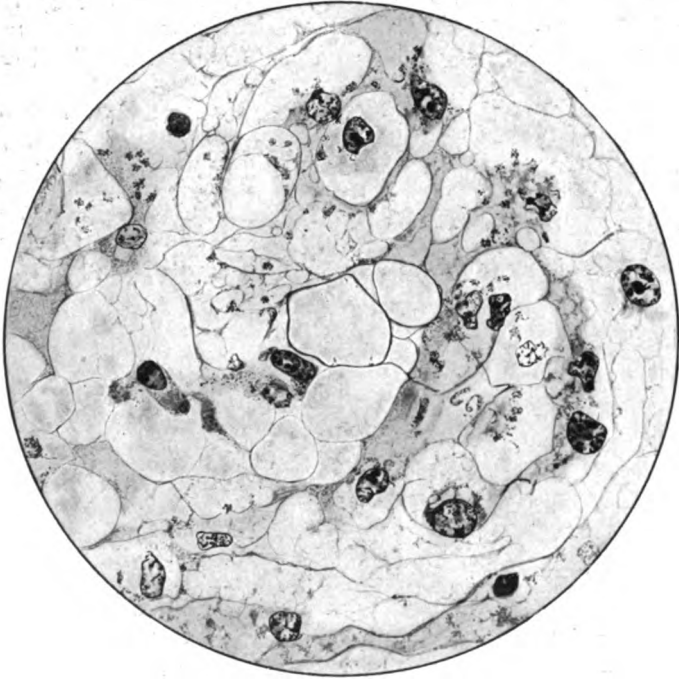


Fig. 317.—Chordoblastoma. Numerous vacuoles present, some with well defined walls.

called chordomas these small masses are probably only the result of the normal development of notochordal tissue forced out of the bone at the base of the skull during fetal development. They are analogous to the frequent displacements of adrenal cells.

These cell-masses are soft, of glass-like transparency, and may reach the size of a small pea. Ribbert has shown that those occurring on the dorsum sellæ are connected by a slender stalk extending through a small hole in the dura with similar tissue embedded in the underlying bone.

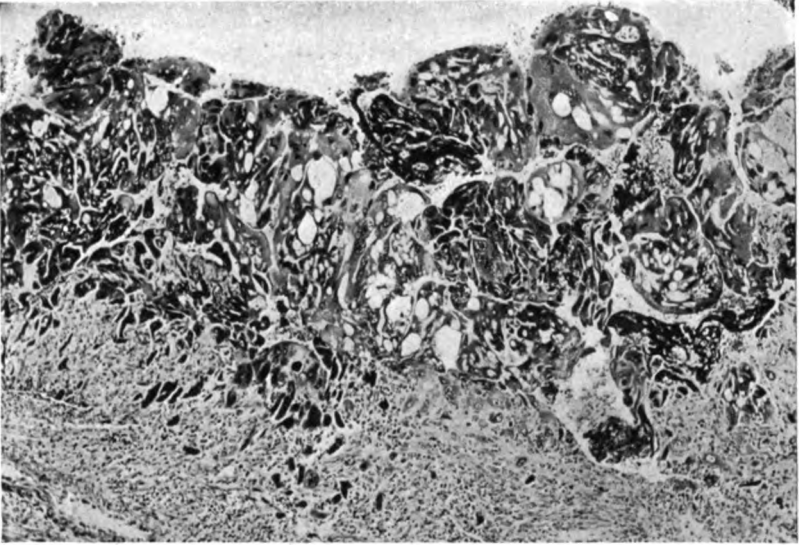


Fig. 318.—Chorionepithelioblastoma in uterus. M. and W.

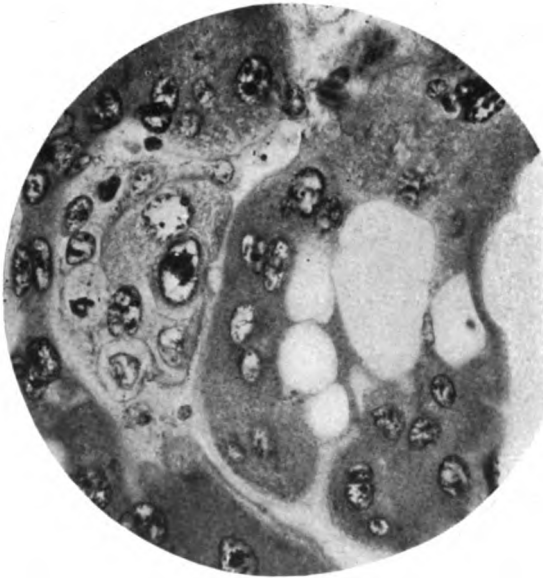


Fig. 319.—Chorionepithelioblastoma of the uterus. M. and W.

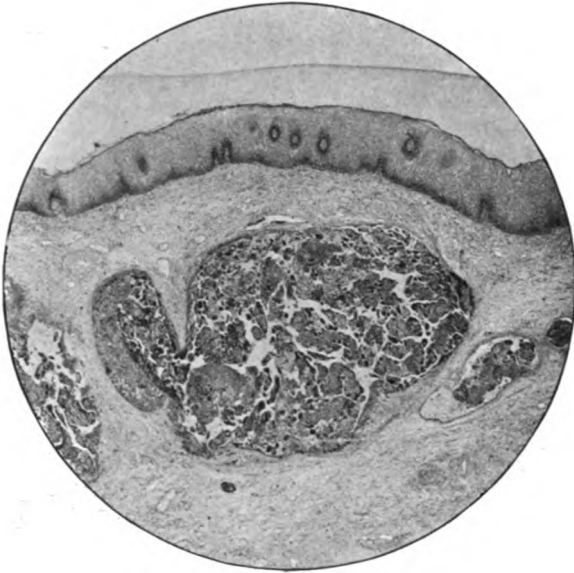


Fig. 320.—Chorionepithelioblastoma. Metastasis growing in vein in wall of vagina. M.

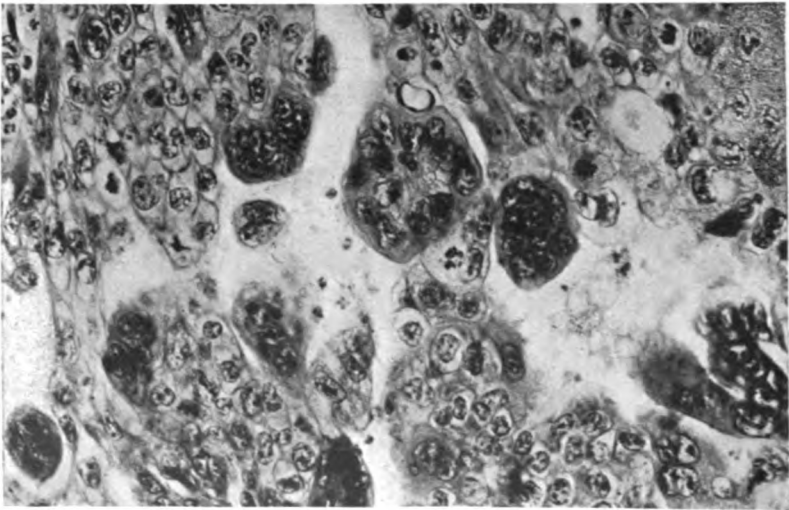


Fig. 321.—Chorionepithelioblastoma. From metastasis in wall of vagina. M.

CHORIONEPITHELIOMA

The chorionic villi are covered with two layers of epithelial cells; the inner or so-called layer of Langhans is composed of separate cells which are sharply defined and cubical in shape; the outer so-called syncytial layer is derived from the inner and is composed of flat connecting masses of cytoplasm containing numerous nuclei.

The tumor arising from the epithelial cells covering the villi is called a *chorionepithelioma*. It is an epithelial tumor of fetal origin and its cells tend to differentiate as do those covering the

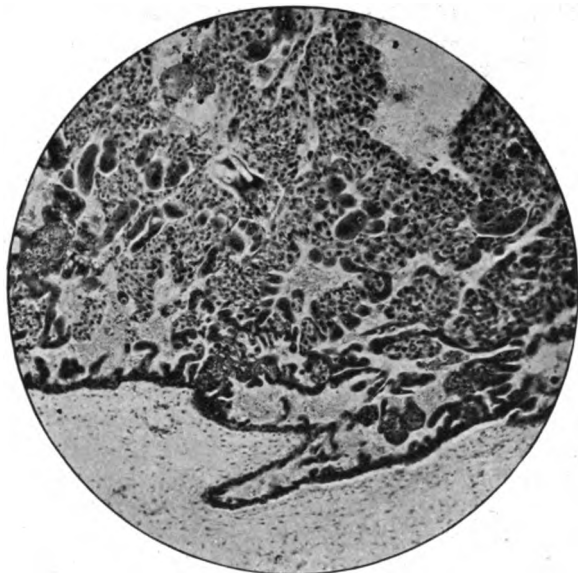

Fig. 322.—Hydatidiform mole. Marked hyperplasia of chorionepithelium covering a villus. M.

chorionic villi. It is usually, therefore, sharply differentiated from other forms of carcinoma by the presence of two kinds of cells; separate cells which undergo mitosis and which correspond to the layer of Langhans, and large multinucleated cells which correspond to the syncytial layer.

The tumor causes little or no reaction on the part of surrounding fibroblasts; that is, it does not lead to active stroma formation. Instead, the tumor cells tend, as do the normal cells of the same type, to invade blood-vessels and to develop within them. On this account hemorrhage is a prominent feature with this tumor. Metastases are of common occurrence, especially in the wall of the

vagina and in the lungs. Occasionally the tumor starts directly as a metastasis in the lung or elsewhere without any original tumor having been formed in the uterus.

A chorionepithelioma may start from a uterine or rarely from a tubal pregnancy. It is frequently preceded by the formation of a hydatidiform mole in which condition the epithelium covering the edematous villi often shows marked hyperplasia.

MIXED TUMORS

The simple tumors arise from the cells which have reached the end of their embryologic development. The tumor cells are capable, therefore, of forming but one type of cell and these cells may undergo complete or incomplete histologic differentiation largely according to whether the tumor grows slowly or rapidly.

Mixed tumors on the other hand may arise in two ways, rarely from combinations of two different types of tumors, commonly from cells which have not attained full embryologic development, or from cells which have inherent in them the possibilities of developing into an embryo. The tumor cells may, therefore, undergo more or less complete embryologic development into two or more types of cells and these cells may differentiate more or less completely histologically; the degree of differentiation depends again largely on the rate of growth of the tumor. It is apparent from this statement that we may have a variety of mixed tumors, running from the simplest which contain but two types of cells to complicated new-growths which may contain examples of all the various kinds of cells which occur in the human body.

Mixed tumors are classified according to their complexity, that is, according to the nature of the germ cell from which they arise. It is often convenient, however, to name them according to the locality in which they occur, namely, mixed tumors of the kidney, mixed tumors of the parotid region, because experience has shown that certain varieties of mixed tumors arise most frequently in definite situations.

One series of mixed tumors arises from the ectoderm and its derivatives, a second from the mesoderm, a third from the entoderm, a fourth from all three layers. Whether combinations of ectoderm and mesoderm occur is exceedingly doubtful although often assumed.

Combinations of Tumors.—Combinations of two different types of tumors occasionally occur; for example, adenocarcinoma and sarcoma of the uterus; carcinoma and sarcoma of the thyroid; adrenal carcinoma and fibrosarcoma of the kidney. In the last instance the two different tumors in places grew separately while in other places they were intimately combined. The invasion

or spread of the fibrosarcoma along the stroma of the carcinoma could easily be followed.

Such combinations of two different kinds of tumors may sometimes of course be accidental; in other instances it certainly seems to be the effect of a primary tumor on its stroma, as in the case of the adrenal carcinoma and fibrosarcoma just mentioned. This view is favored by some of the recent experimental work with cancer, in which it was shown that after a number of transplantations the cancer had disappeared and its place had been taken by a fibrosarcoma.

1. **Of Ectodermal Origin.**—The neural canal is formed by an infolding of the ectoderm. The ependymal cells lining it are ciliated in early embryonic life; occasionally the cilia persist into adult life. From these ependymal cells are derived all the nerve cells and neuroglia cells of the central nervous system. Closure of the lower end of the neural canal takes place over the coccyx. The cells lining it should atrophy and disappear. Frequently they fail to do so; instead they remain as small gland-like formations on the surface of the coccyx. These groups of cells or fetal rests, of ectodermic origin, may differentiate like the epidermis, or like the cells of the neural canal. Sinuses and cysts lined with epidermis occur in this region. They are probably not to be regarded as real tumors. On the other hand we sometimes get true tumors here: (a) simple tumors composed of neuroglia tissue and (b) mixed tumors composed of nerve cells and fibers, neuroglia cells with their fibrils, and cysts of various sizes, some lined with epidermis, others with ependymal cells which may or may not be ciliated.

Similar tumors may occur also where closure of the upper end of the neural canal takes place, at the base of the nose.

Cell remains of the branchial cleft in the neck may differentiate into ciliated epithelium like that lining the trachea, or into an epidermis. Glandular and cystic tumors occasionally occur in this location in which some of the cavities are lined with ciliated epithelium, others with an epidermis. Such a new-growth may be considered a very simple form of mixed tumor.

Occasionally tumors of the breast occur in which the epithelial cells derived from the ectoderm have differentiated in part like the gland cells, in part like the epidermis. The result is a tumor composed of glands and cysts some of which are lined with cubical to cylindrical epithelium, while others are covered with a typical epidermis.

2. **Of Mesenchymal Origin.**—A more common group of mixed tumors is that derived from the mesenchyma which, under normal conditions, gives rise especially to fibrous and mucous connective

tissue, cartilage and bone cells, and to fat and smooth muscle-cells. A mesenchymal cell may, therefore, give rise to a tumor containing all these cells or any combination of them. The most frequent combinations consist of two or more of the first four, that is, of fibrous and mucous connective tissue, cartilage and bone cells. As the fibroblast, at least in certain situations, retains throughout life the inherent possibility of differentiating into any of these four types of cells, the question might be raised whether this combination of cells formed a true mixed tumor. For practical purposes it is, perhaps, as well so to regard it.

Other combinations which sometimes occur are of fat and mucous connective-tissue cells, and of fat and smooth muscle-cells.

The mesoderm differentiates into mesothelium and mesenchyma, and under normal conditions produces a variety of organs and tissues. Cells of intermediate stages are known as *myotomes*, *sclerotomes*, *nephrotomes*, etc. A mesodermic cell or any of its early derivatives which give rise to a tumor may be expected, therefore, to differentiate into a variety of cells, depending on the stage of development it had reached before it escaped from its normal relations and on its normal location in the embryo, that is, whether it lies in the region of the kidney, of the lung, or in the neck.

Tumor cells of mesodermic origin differentiate in various ways along the course of the genito-urinary system. The amount of differentiation depends on rate of growth.

In the kidney the tumor usually grows rapidly and the cells often form only glandular canals embedded in very cellular mesenchymal tissue which resembles in appearance that of a sarcoma. Sometimes striated muscles and fat-cells, cartilage, and bone are also formed. Similar tumors may develop in the pelvis of the kidney, urinary bladder, vas deferens, vagina, cervix uteri.

The origin and distribution of these tumors in and along the genito-urinary tract is supposed to be due to the great local movements which the cells forming these structures undergo in normal development and, therefore, to the ease with which some of the cells may be displaced out of their normal arrangement.

Somewhat similar tumors develop in the lungs. They contain striated and smooth muscle-cells, as well as gland and cyst-like formations.

Mixed tumors occur also in the parotid and other salivary glands and in the region of the lips. They commonly contain cartilage and epithelial structures, some of which may be in the form of glands and contain colloid material, also less often bone.

3. Embracing all Three Embryonic Layers.—A cell having

the inherent possibility of producing an entire embryo is in a position to give rise to a tumor of which the cells may differentiate into any or all of the cells which make up the human body. Cells with such possibilities exist in the ovary and testicle and they may be introduced from outside the body in the same way as happens when the monstrosity known as a *fetus in fetu* is produced.

If the tumor develops slowly the cells may undergo a large amount of differentiation, so that the results are easily recognized. Such a tumor is called a teratoma. If, however, the cells proliferate rapidly so that little or no cell differentiation has time to occur, the tumor is called an embryoma. All gradations between the two extremes necessarily occur.

Ovary.—Mixed tumors of the ovary usually grow slowly so that considerable differentiation of cells and tissues is possible. Ectodermic structures especially are formed, most commonly epidermis, hair, sebaceous and coil glands, and teeth, in addition to connective tissue, bone, etc. The product of the glands collects in the space lined with epidermis and distends it into a cyst until it may reach a diameter of five to ten cm. or more. The cavity is usually filled with thick greasy material and hairs. The solid part of the tumor remains as a projecting mass at one side of the cyst. From its surface grow the hairs which are gradually cast off and mix with the secretion of the sebaceous glands.

One or more, occasionally many teeth, are also often present. Examination of this solid part of the tumor often shows bone and cartilage, muscle, neuroglia and nerve tissue, and sometimes many other structures suggesting attempts to form various organs of the body. This cystic form of teratoma has commonly been called a dermoid cyst. The term is best reserved for simple cysts lined with epidermis occurring in other parts of the body and probably not to be classed as true tumors.

The more rapidly-growing teratomas of the ovary usually form more or less solid tumors containing numerous small cysts of various sizes lined with various kinds of epithelium, ciliated, pavement, etc., and containing multiple foci of cartilage, smooth muscle-cells, neuroglia tissue, less often striated muscle and nerve-cells. The more rapidly these tumors grow the more likely are they to give rise to metastases in the lungs and elsewhere. Rarely a carcinoma, usually of the epidermoid type, will start from a slowly-growing cystic form of teratoma.

Testicle.—Mixed tumors of the testicle are relatively frequent and usually grow in solid form, although multiple cysts are sometimes present. The dermoid cyst form of teratoma so common in the ovary is rare in the testicle. Various tissues may be found; fibrous and mucous connective tissue, cartilage, bone, smooth and

striated muscle-cells, neuroglia tissue, glands and cysts lined with epithelium of various types. As a rule, the slower the rate of growth, the greater the cell differentiation. Metastases from one of these teratomas are not frequent.

A more common tumor of the testicle is one which must be classed as an embryoma. It has been variously regarded in the past as a carcinoma or sarcoma. The microscopic picture is fairly characteristic. The tumor is composed of cells growing in large solid masses with little stroma between the masses. The cells are of medium size, with round nuclei surrounded by a moderate amount of delicate cytoplasm which is sharply limited as by a cell membrane.

Syncytial cells are sometimes present and occasionally masses of cartilage or other adult type of tissue may be formed.

Fetal Inclusions.—Occasionally teratomas occur in other parts of the body than in the ovary and testicle; for example, at the ends of the body, within the skull, in the mediastinum, retroperitoneally, etc. They frequently form solid tumors containing numerous small cysts. They may grow slowly so that the cells have opportunity to differentiate in various directions, that is, into cells characteristic of various tissues and organs (neuroglia tissue, smooth and striated muscle-cells, cartilage, bone, teeth, retina, and epithelial structures of many varieties), or they may grow rapidly and exhibit little cell differentiation, but on the other hand, a strong tendency to infiltrate surrounding tissues and to give rise to metastases.

Mixed tumors of this sort can be explained only on the supposition that some cell has been included in the body capable of developing all three of the embryonic cell layers. Such a cell could be either one of the early cells formed from the proliferation of an ovum, or a second ovum included among the developing cells of the first. The abnormalities due to inclusion of one fetus within another, often in the same regions where these teratomas occur, is a strong argument in favor of this latter view although the other, of course, cannot be excluded and may indeed occur also.

PART II
SPECIAL PATHOLOGIC HISTOLOGY
ORGANS OF CIRCULATION

PERICARDIAL CAVITY

Introduction.—The most important lesions of the pericardial cavity are of infectious origin and are all included under the term pericarditis.

Anatomy.—The pericardial cavity is lined with cuboidal mesothelial cells. They rest on a layer of connective tissue containing numerous elastic fibrils. The cavity contains, in health, twenty to fifty, rarely as much as 100 c.c., of a light yellow serous secretion.

Fat-cells.—Fat-cells occur normally in the epicardium. Under certain conditions they may be either increased or diminished in number. Variations within fairly large limits must be considered normal. If they pass beyond these limits the condition becomes pathologic.

In obese people the fat-cells increase greatly in number. They occupy not only the epicardial tissue, but extend into the myocardium, growing along the blood-vessels and infiltrating between the muscle-fibers. They may even make their appearance beneath the endocardium. The condition when extreme is called *adipositas cordis*, and is of some pathologic importance because it interferes with the perfect functioning of the heart.

In emaciation the fat-cells may be greatly reduced in number. As the fat is needed for nutrition the fat-cells atrophy until the fat is all removed from them and then, for the most part, they disappear. They are not fibroblasts filled with fat, but mesenchymal cells *sui generis*. They multiply as they are needed and disappear when not required.

When the fat-cells disappear the fibroblasts of the epicardium apparently produce a certain amount of mucin to take their place. At any rate, the collagen fibrils are often separated by a gelatinous fluid so that the fibroblasts resemble the mucous connective-tissue cells of the umbilical cord. To this condition the term gelatinous atrophy of fat tissue is sometimes incorrectly applied.

Circulatory Disturbances.—The blood-vessels in the wall of

the pericardium are hyperemic ordinarily under two conditions, when acute pericarditis, or chronic passive congestion has existed at the time of death.

Subpericardial echymoses occur under a variety of conditions; in death from strangulation; frequently in severe septicemias; in pernicious anemia; in eclampsia. They are significant of mechanical or toxic injury to the walls of capillaries and small blood-vessels, but otherwise are unimportant.

Occasionally as the result of rupture of the heart or from a mechanical injury such as a stab wound, the pericardial cavity may be distended by a large hemorrhage which interferes with or prevents the action of the heart.

In general edema from cardiac or renal disease the pericardial cavity may contain, as the result of transudation, a large amount of serous fluid in which loose gelatinous clots may form.

Pericarditis.—A variety of infectious agents may cause acute inflammation of the pericardial cavity. The most common are the diplococcus pneumoniae, the streptococcus pyogenes, the staphylococcus aureus, and the tubercle bacillus. They probably never lodge here primarily, but come from other lesions elsewhere, thus by direct extension or through lymphatics from the lung, mediastinum, or heart, or by the blood stream from any part of the body.

The injury caused is usually slight, simply degeneration or necrosis of the lining mesothelial cells. Even this is often only partial.

The inflammatory reaction on the other hand is usually abundant. It is called out chiefly to counteract the injurious agent and its toxins. The injured cells play an unimportant part.

The character of the inflammatory exudation depends on the nature of the infectious agent and may be serous, fibrinous, or purulent, or a combination of any two or of all of them. The exudation may be complicated by hemorrhage or undergo caseation.

The exudation of serum and polymorphonuclear leukocytes passes into the pericardial cavity from the congested vessels in its wall. Fibrin quickly begins to form between and on the surface of the lining mesothelial cells. It may build a layer of varying thickness parallel with the surface, or if there is little or no free fluid present and the visceral and parietal surfaces touch, it may, by the heart's action, be forced into delicate ridges and villi. The leukocytes lie in part in the meshes of the fibrin reticulum, but mostly collect in the free fluid in the cavity.

The mesothelial cells may be partly or entirely destroyed; they may remain *in situ* or be desquamated singly or in clumps.

Macroscopically, the fibrin forms at first a thin, easily removable layer on the pericardial surface and clouds or dulls its glistening appearance. Later it often forms a layer one to three or more mm. in thickness and may be smooth or deeply ridged and furrowed, or villous in appearance dependent largely on the amount of free fluid present to keep the two pericardial surfaces apart.

If the infectious agent dies out early the small amount of fibrin present may be dissolved and entirely disappear by absorption along with the serum present. More often the fibrin is abundant and organization of it gradually takes place. After about a week capillaries begin to grow into the fibrin from the subpericardial capillaries. They extend in at right angles to the surface, but form lateral anastomoses. At the same time the fibroblasts begin to proliferate. A few follow the blood-vessels, but most of them form a layer parallel with the surface. At this stage only the upper part of the fibrin can be stripped off. The deeper layer is too intimately bound down to the subpericardial tissue.

As the granulation tissue advances the fibrin gradually disappears, although small islands of it sometimes persist here and there for a long time and may act as foreign bodies and lead to the formation of giant-cells.

The subpericardial tissue beneath the new-formed granulation tissue usually contains a few polymorphonuclear and endothelial leukocytes, but occasionally is infiltrated with numerous lymphocytes, mostly of the plasma-cell type.

If little or no fluid is present, so that the visceral and parietal surfaces are united by fibrin, organization may result in complete obliteration of the pericardial cavity. Occasionally the fibrin layers are so thick that the process of repair ceases after a time. Under these conditions lime-salts may be deposited in the remaining fibrin. The calcified material may eventually be transformed into bone, as the result of invasion and metaplasia of adjoining fibroblasts.

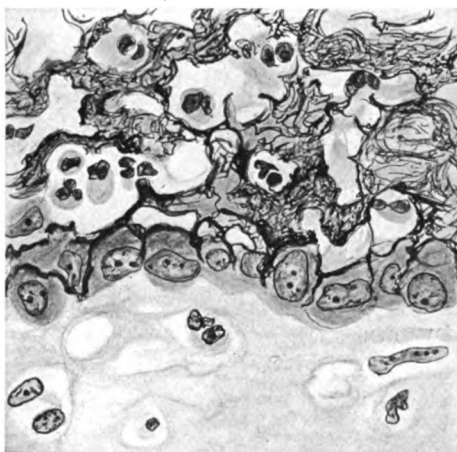
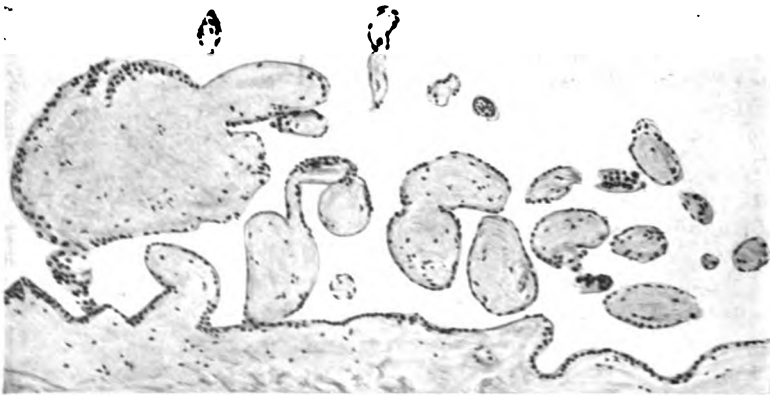

Fig. 323.—Acute pericarditis. Mesothelial cells still intact. Exudation of polymorphonuclear leukocytes and serum, from which fibrin has formed.

When much fluid is present in the pericardial cavity so that the ridges and villi of fibrin are kept apart, the granulation tissue necessarily spreads more irregularly since it extends only through the fibrin between and around the spaces. These spaces may disappear in time if the fluid is absorbed, unless desquamated lining mesothelial cells are present. If they are, they multiply until they cover over all the free surface of the



a



b

Fig. 324.—Pericardium. *a*, Acute fibrinous pericarditis; *b*, fibrous tags or adhesions resulting from organization of fibrin due to an acute pericarditis.

fibrin. In this way gland-like cavities and small cysts are often formed in the granulation tissue and persist later in the dense scar tissue which eventually results from the contraction of the collagen fibrils in the granulation tissue, and from the atrophy and disappearance of the blood-vessels.

Dense pericardial adhesions must interfere seriously with

the heart's action. Frequently, but not always, they lead to its hypertrophy.

Tuberculous Pericarditis.—The tubercle bacillus causes in the pericardial cavity two different types of lesions which are sometimes combined, in varying proportions, just as miliary tubercles and tuberculous pneumonia often coexist in the lung.

In the one type, miliary tubercles are formed in the sub-pericardial tissue and project to some extent into the pericardial cavity. They are often due, in part at least, to distribution of tubercle bacilli through the lymphatics.

In the other type the bacilli gain access from such miliary tubercles, or from lesions adjoining the pericardium, to the pericardial cavity and cause an abundant fibrinous type of inflammatory exudation. In the course of time organization of the fibrin begins and progresses. Wherever tubercle bacilli are enclosed in the granulation tissue thus formed they cause the production of miliary and conglomerate tubercles. As the process is always chronic and progressive a layer a centimeter or more in thickness is sometimes formed, composed of granulation tissue studded with tubercles and covered with a layer of fibrin and leukocytes.

ENDOCARDIUM

Anatomy.—The endocardium lines the cavities of the heart and forms the valves. It corresponds to the intima of the blood-vessels and is really the continuation into the heart of that structure in the large blood-vessels. It consists of a lining of endothelial cells which rest on a layer of connective tissue of varying thickness. This connective tissue contains elastic fibers and in places includes smooth muscle-cells, but no blood-vessels. Consequently all the cells forming the endocardium are nourished by imbibition.

Toxic Endocarditis.—The endocardium of the heart is exposed to the effects of toxins of various sorts circulating in the blood, and to disturbances of nutrition in the same way that the intima of the blood-vessels is, and reacts in the same way. Observation shows that certain parts of the endocardium, like certain parts of the vascular intima, are more sensitive to injurious influences than others. Thus, the endocardium of the valves is much more often affected than the endocardium lining the cavities, and the aortic valve more often than the mitral or other valves. Possibly the nature of the work which they perform has something to do with this.

Toxic endocarditis is a chronic process. The lesions at first are slight, but they tend to persist and progress or to recur. They are much more prominent in their late than in their early stage.

They affect most commonly the aortic valve, but may involve the mitral, much less often the pulmonary and tricuspid valves.

The nature of the toxic lesions in the endocardium is similar to that which occurs so commonly in the blood-vessels and is included under the term arteriosclerosis. It consists of injury to the subendothelial fibroblasts and of the accumulation of fat-droplets in the cytoplasm of these cells. The lesion is usually toxic in origin, but disturbances of nutrition may play a part.

If the fibroblasts containing fat undergo necrosis, endothelial leukocytes are attracted and digest the necrotic cells and incorporate the fat. The fibroblasts destroyed in this way may be replaced by regeneration and the process proceed no farther. Frequently, however, the lesion progresses. More fibroblasts are destroyed and a greater number of endothelial leukocytes are attracted. As they use up part of the nutrition which reaches the site involved other fibroblasts and even some of the leukocytes may undergo necrosis. From the fat derived from the necrotic leukocytes, fatty acid and cholesterin crystals are frequently formed. These crystals often act as foreign bodies and may lead to the formation of giant-cells by fusion of endothelial leukocytes. Lime-salts may be attracted and result in calcification of the necrotic material, or by regeneration of fibroblasts the affected area may in time be restored more or less perfectly to its former condition.

If the injury is severe the lining endothelium is often destroyed along with the subendothelial fibroblasts. In such instances the lesion is often complicated by the formation of fibrin on the surface. When this takes place on a valve it is commonly spoken of as a vegetation. It may be large or small. The fibrin may be formed at one site only or at several. Fibrin formation is likely to continue until endothelial cells growing in at the periphery cover over the whole surface. At the same time the fibroblasts at the base of the fibrin are actively stimulated to proliferate and gradually infiltrate and replace (organize) the fibrin. In this way a valve may be thickened, or its cusps united to each other. Contraction later may lead to stenosis or insufficiency of the valve or to both. The result is interference with the functional activity of the valves, which causes more work to be thrown on the heart. The walls of the cavities may weaken and dilate, to be followed by increase in the size of the muscle-fibers and consequent hypertrophy of the heart.

INFECTIOUS ENDOCARDITIS

Introduction.—Infectious endocarditis is more common than the toxic variety and, in its early stages, is much more important. The process may run a very rapid course and terminate fatally,

or persist for a long time, or undergo repair and result in more or less complete recovery. In infectious endocarditis there always occurs a toxemia and usually a septicemia.

Micro-organisms.—The organisms most commonly concerned in its production are the streptococcus pyogenes, the diplococcus lanceolatus, or the staphylococcus aureus, less often the gonococcus, and various other infectious agents, including the treponema pallidum. It is not always possible to identify every infectious agent which may occasionally produce endocarditis.

The number of organisms concerned in the production of a given lesion on a valve may be small or it may be very large. In many instances the infecting bacteria grow in solid masses, like colonies in a culture tube.

Source of Micro-organisms.—Acute infectious endocarditis is usually secondary to a local infectious process somewhere else in the body. Cultures from the blood have shown that a septicemia is of frequent, or even of constant, occurrence in connection with certain acute infections. Such a septicemia may persist occasionally for weeks or months. The blood may contain few organisms or many and they may be very virulent or almost innocuous. The original lesion may heal while the septicemia persists and gives rise to secondary lesions such as endocarditis, arthritis, abscesses, etc. A few common sequences of infection will make this point clear: (a) micrococcus lanceolatus; lobar pneumonia, septicemia, endocarditis; (b) micrococcus gonorrhœæ; urethritis, septicemia, arthritis, endocarditis; (c) streptococcus pyogenes; tonsillitis, septicemia, endocarditis, arthritis.

Site of Infection.—Statistics show that infectious organisms locate most often on the mitral valve; then follow in order the aortic, the tricuspid and the pulmonary valves. Occasionally two valves are affected at the same time (most frequently the mitral and aortic valves), rarely three or all four.

The lesion usually starts along the line of apposition of the valves, not at the free edge. It may start at one point and spread, or start at a number of points and by extension from these gradually coalesce. The lesion may remain sharply localized along the line of apposition or spread over both sides of the valves, along the chordæ tendinæ of the mitral and tricuspid valves, and even on to the endocardium lining the auricular and ventricular cavities.

Injury.—Most of the toxin emanating from the bacteria passes into the circulation causing a toxemia. It is carried all over the body and produces a certain amount of injury and reaction. Some of the toxin, however, diffuses into the tissue on which the bacteria are located and causes degeneration, and in

many instances necrosis. The injury thus produced may be slight and superficial or extend deep into the tissue. Sometimes the infecting organisms invade the tissue of the valve and even the adjoining myocardium or other adjoining tissues, causing extensive necrosis and diffuse suppuration or abscess formation. Perforation of a valve flap is a common result and severance of chordæ tendineæ sometimes occurs. These different effects depend on the nature of the infectious organism and on its degree of virulence.

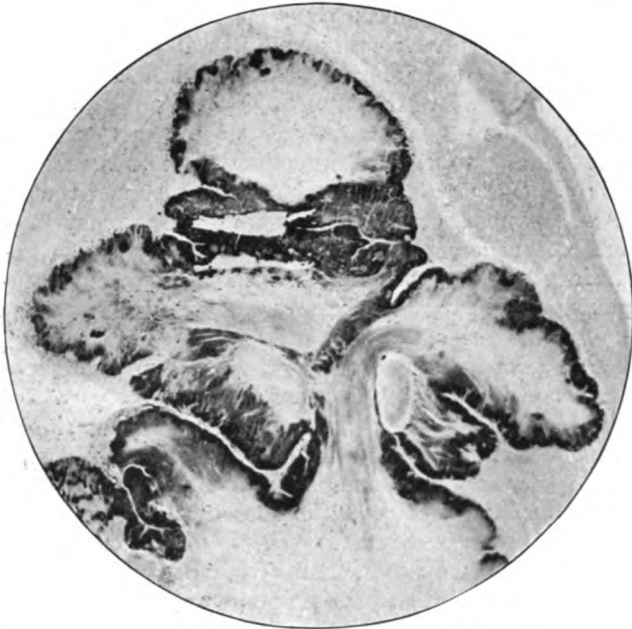

Fig. 325.—Heart. Acute vegetative endocarditis. Masses of living cocci at surface. M.

Local Reaction.—Often there is little or no reaction around the organisms on a valve. A vegetation may be composed of a solid mass of dead and living bacteria without admixture of fibrin or leukocytes, although both may, of course, be deposited on the free surface of the mass postmortem. Blood platelets are often deposited in great numbers in the same way. If, however, necrosis of the underlying tissue has occurred then many polymorphonuclear leukocytes usually migrate into the necrotic tissue, or line up in masses at its edge. Occasionally they incorporate in large numbers the bacteria present. If the infecting organism is not very virulent, many endothelial leuko-

cytes may be present in the exudation; occasionally some of them form large multinucleated cells by direct division of the nucleus and increase in the amount of cytoplasm. Occasionally an abundant infiltration with lymphocytes and plasma-cells occurs in the neighborhood of the necrotic tissue.

Sometimes the organisms on a valve may be few in number, while fibrin may be very abundant and form masses of various shapes and sizes.

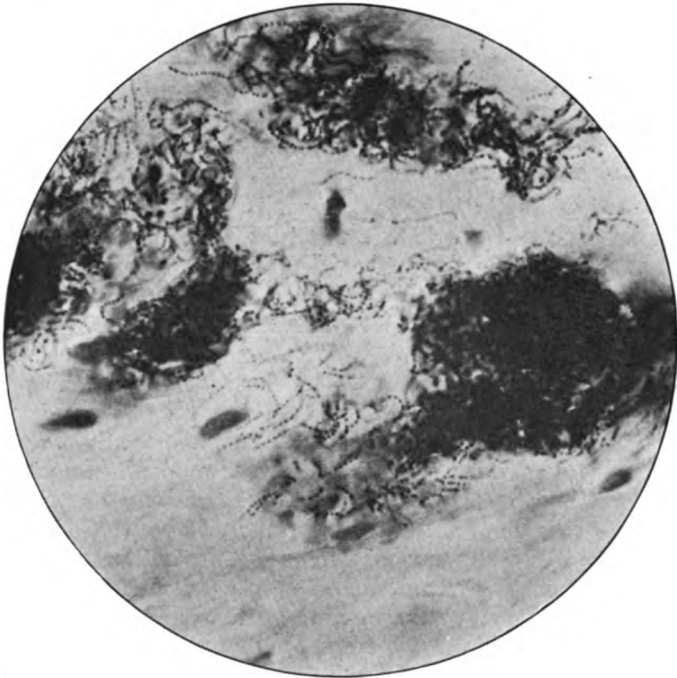


Fig. 326.—Acute endocarditis, due to the streptococcus pyogenes. M.

General Reaction.—The toxin which passes from the organisms on the valve into the circulation produces toxemia and, according to its strength and character, may cause much injury, especially to highly differentiated cells, throughout the body. As a result these cells may show various forms of retrograde change such as the accumulation of fat-droplets, colloid formation, or necrosis. Some of the toxins are eliminated through the kidney and may lead to marked lesions in the glomeruli or tubules. Necrosis of the liver cells around the hepatic veins is a common result.

Besides the toxemia two other possibilities are always threaten-

ing. Organisms may at any time be swept into the blood stream causing a septicemia, and are then liable at any time to produce other lesions such as abscesses, etc.; or large masses of organisms and fibrin may be broken off and be carried as septic emboli to block small vessels elsewhere in the body, and thus lead to septic infarctions or other lesions.

Gross Appearance.—The gross appearance presented by the lesion of acute endocarditis varies greatly. It may appear in the form of minute granulations, of large vegetations, of ulcerations and perforations, or as combinations of all these forms. Much depends on the nature and virulence of the infecting organism. The micrococcus lanceolatus usually causes vegetative endocarditis; the staphylococcus aureus the ulcerative form; while the streptococcus pyogenes and the gonococcus may produce either type of lesion.

Microscopically, the bacteria usually tend to grow in masses or colonies just as they do in a test-tube on an artificial medium. The surface adjoining the circulating blood shows the bacteria well preserved and multiplying. Farther back towards the tissue on which they rest they receive less nutrition and hence gradually die off.

Duration and Termination.—The duration of infectious endocarditis varies widely according to the type and virulence of the organism. If the organisms multiply rapidly and produce much toxin death may result in a few days. In other instances death occurs after days to weeks, chiefly as the result of secondary lesions produced in the kidneys by the elimination of the toxins in the circulation. In still other instances the organisms are only slightly virulent, but very persistent so that death follows only after many months as the result of a variety of lesions in the heart and often elsewhere in the body. With some organisms, such as the treponema pallidum and the tubercle bacillus, the duration is by nature chronic, because the organisms persist and do not produce a toxin strong enough to cause death.

Repair.—Repair takes place in endocarditis just as in pathologic processes elsewhere in the body, if the lesion persists a certain length of time or if the infecting organism dies out. Inasmuch, however, as no blood-vessels are present normally in the valves, repair involves regeneration of fibroblasts only, as in the cornea, unless the lesion has been extensive enough to involve directly or indirectly the capillaries in the adjoining tissues. Under these conditions an outgrowth of young blood-vessels may occur and granulation tissue be formed.

The process of repair includes the removal of the necrotic organisms by solution and absorption, the organization of fibrin,

usually by fibroblasts only, the regeneration of the connective tissue destroyed, and the growth of endothelial cells over the injured surface.

The common results of repair of the lesion of endocarditis are thickening, shortening and interadherence of valve curtains and chordæ tendineæ so that the normal function of the valves is interfered with. The valve orifice is narrowed and the curtains no longer meet in apposition. The physiologic results are incompetence of the valves, regurgitation of the blood, and increased work thrown on the heart.

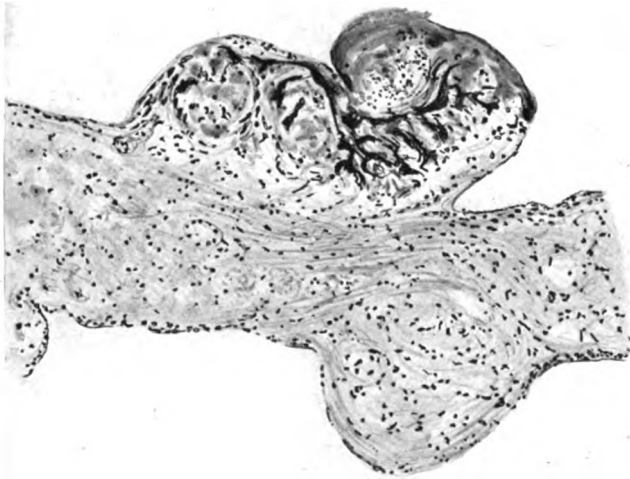

Fig. 327.—Heart. Fibrous mass containing fibrin on surface of valve as result of organization of fibrin due to acute endocarditis.

Frequently the process of repair is not perfect. The dead organisms and the fibrin may not be entirely removed. Under this condition they usually attract lime-salts which form masses of calcification.

Treponema Pallidum.—Endocarditis due to the *treponema pallidum* resembles more closely toxic endocarditis than it does the common forms of infectious endocarditis. This is due to the nature of the infectious agent and to the reaction to it. It does not grow in masses on the surface of the valves in the way that bacteria do, but infiltrates the subendothelial connective tissue and produces a slow chronic type of inflammatory reaction, consisting of more or less infiltration with leukocytes and reparative proliferation of fibroblasts. If necrosis occurs, infiltration

with endothelial and polymorphonuclear leukocytes follows, and much fibrin may form on the surface and lead later to organization, and an ingrowth of blood-vessels may occur as a result of necrosis.

End Results: Sclerosis of Valves.—It is apparent from the description of toxic and infectious endocarditis that both types of lesions may terminate in repair, and that both may present as the end result a sclerosis of the valve affected. The sclerosis shows as thickening and shortening of the valve curtains which may be interadherent. The chordæ tendineæ may present similar changes. The lesion may be complicated by calcification. The term chronic endocarditis is often applied to this end result, although sclerosis is preferable.

To state in a given instance whether a sclerosed valve owes its origin to a toxic or to an infectious process is not easy. Two points may help: the valve affected, and the other lesions present in the body. They must be taken into careful consideration. Sclerosis of the mitral valve is usually due to an infectious process, of the aortic valve to toxic endocarditis (arteriosclerosis). Lesions in early life are usually infectious in origin; late in life toxic in origin.

Physiologic Effect.—Injury to the valves of the heart may produce very serious functional disturbances although the original lesion may have healed. Stenosis or insufficiency of a valve throws increased work on the heart and usually leads to dilatation and hypertrophy. Chronic passive congestion of the various organs of the body is a common sequence.

MYOCARDIUM

Introduction.—Many of the various retrograde processes already described from the general point of view may affect the myocardium. Here we are concerned only with their appearance and significance in this tissue.

Albuminous Granules.—In certain acute infectious diseases the myocardium on section at postmortem examination sometimes appears cloudy. The same appearance may be produced by post-mortem changes, especially during hot summer weather. It may be that in these acute infectious processes, usually combined with high temperature, the cloudy appearance is due to rapid post-mortem changes.

In stained preparations of myocardium properly fixed within one to two hours after death from typhoid fever, lobar pneumonia, and similar diseases the striations are perfectly preserved, the sarcolemmal elements are distinct, and no albuminous granules can be demonstrated except those normally present in the muscle cytoplasm adjoining the nuclei. In myocardium poorly fixed, or preserved

after postmortem changes have begun, the sarcous elements (anisotropic segments) are fragmented and appear as granular débris.

In diphtheria and a few other infectious processes accompanied by much toxemia, necrosis of muscle-fibers often occurs diffusely or in foci. The necrosis is sometimes preceded by an accumulation of fine and coarse granules, apparently albuminous in nature and possibly all derived from the sarcous elements, in the fibers. Later, these granules may fuse into hyaline masses of irregular shapes and various sizes. Under these conditions the granules in the muscle-fibers have some significance.

In conclusion it seems reasonable to claim that cloudiness of the myocardium, unaccompanied by the presence of necrosis or fat, has little or no significance.

Hydrops.—Edema of the muscle-fibers shows itself most commonly in the cytoplasm around the nucleus: the fibers often appear hollow. At other times the edema appears as vacuoles separating the longitudinal striations.

Hydrops of the myocardial fibers is probably of not much significance, although sometimes marked. It is of common occurrence in connection with necrosis of muscle-fibers following embolism and thrombosis.

Fat.—Fat may occur in the myocardium in the form of fine to coarse droplets, usually very evenly distributed between the longitudinal fibrils. When the droplets are large the fibrils are often pushed apart.

Fat is of common occurrence in the myocardial fibers in general anemia from all causes. It may also appear focally as the result of lesions in branches of the coronary arteries, causing more or less complete occlusion of them and diminishing the local blood supply.

Fat appears frequently as the result of toxins which may be due to the immediate presence of bacteria in the myocardium as in infectious myocarditis, or to a toxemia due to absorption of toxin from bacteria or other infectious agents elsewhere in the body. Thus fat is present in large amount in those toxemias which produce necrosis of heart-muscle (toxic myocarditis) as sometimes occurs in diphtheria and in a few other infectious processes.

The fat makes its appearance in visible form because of diminished utilization (oxidation) of the fat normally brought to the muscle cytoplasm: The fat accumulates as the result of two different causes, (a) disturbance of nutrition and (b) toxemia. The accumulation of fat in the cytoplasm of the muscle-fibers has of itself little significance. It may in time unquestionably be utilized and removed. Its importance pathologically lies in the evidence its presence gives of disturbed cell metabolism and in its frequent association with necrosis.

Fat in the muscle-fibers causes more or less cloudiness and opacity, and a whitish to yellowish white appearance depending on the amount present. Congestion may completely mask it unless the blood is thoroughly washed from the cut surface with normal salt solution.

The fat may be distributed in the muscle-fibers fairly uniformly throughout the heart, or occur more or less focally or in certain localities, as, for example, in the papillary muscles of the left ventricle. It frequently accumulates in the muscle-fibers farthest from the arterial blood supply just as occurs so commonly in the liver. The result is a uniformly mottled or layered (so-called tiger lily) appearance. This mottled arrangement is due to two causes, to normal

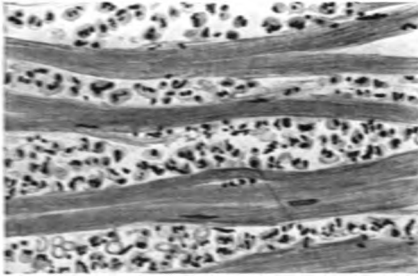


Fig. 328.—Heart. Arteriosclerosis, thrombosis, softening, rupture. Infiltration of necrotic muscle by polymorphonuclear leukocytes.

muscle-fibers around the small arteries, while the fibers at a short distance contain fat, and to the manner of distribution of the smaller arteries which run irregularly transversely to the muscle-bundles of the heart.

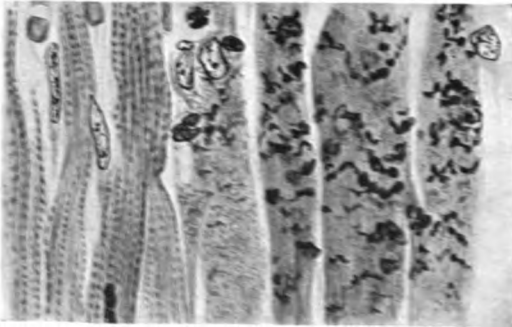


Fig. 329.—Heart. Necrosis of muscle-fibers.

Sometimes fat is abundant and prominent in the muscle-cells just beneath the epicardium when acute pericarditis is present. It is probably due to local diffusion of toxin from the adjoining infectious process. The fat containing fibers may appear as a yellowish white, opaque line 0.5 to one mm. wide.

Necrosis.—Necrosis of muscle-fibers in the myocardium may

occur from cutting off the blood supply completely by embolism or thrombosis followed by infarction, or partially as the result of narrowing of the lumina of arteries by thrombosis, or in consequence

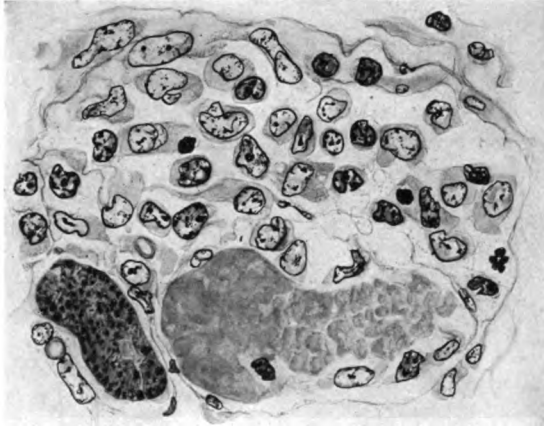


Fig. 330.—Heart. Necrosis of muscle-fibers. Invasion by endothelial leukocytes which have dissolved some of the fibers.

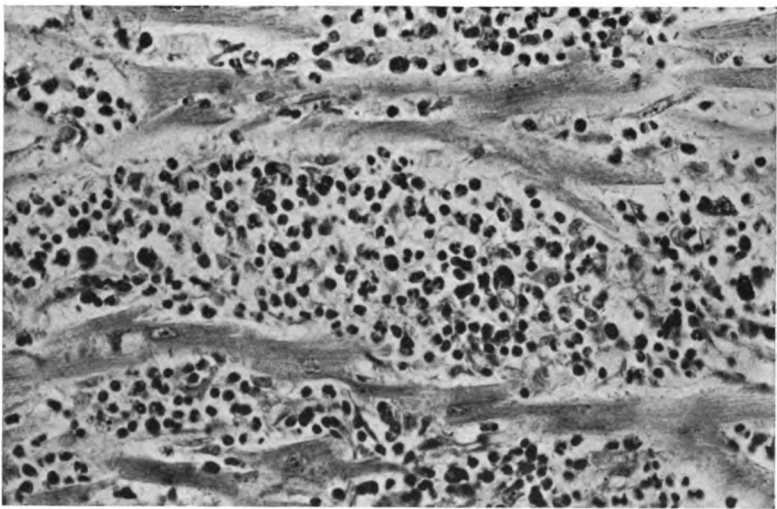


Fig. 331.—Heart. Infectious myocarditis. More than half of the cells are eosinophiles; the rest are lymphocytes. M.

of arteriosclerosis. It may also follow the effect of diffusible toxins (toxic myocarditis) or result from the immediate presence of infectious agents (infectious myocarditis).

The necrosis may affect large areas of muscle-fibers, or small groups of them, or single fibers here and there. The necrotic fibers may retain their form and striations, or become perfectly homogeneous. Sometimes the sarcous elements (anisotropic elements) fuse together irregularly, producing bizarre figures which in places suggest a hyaline reticulum or they fragment into small and large granules.

The necrosis may be produced suddenly as in an infarct or slowly as in toxic conditions. When produced slowly, the fibers may contain much fat in the form of small or large droplets.

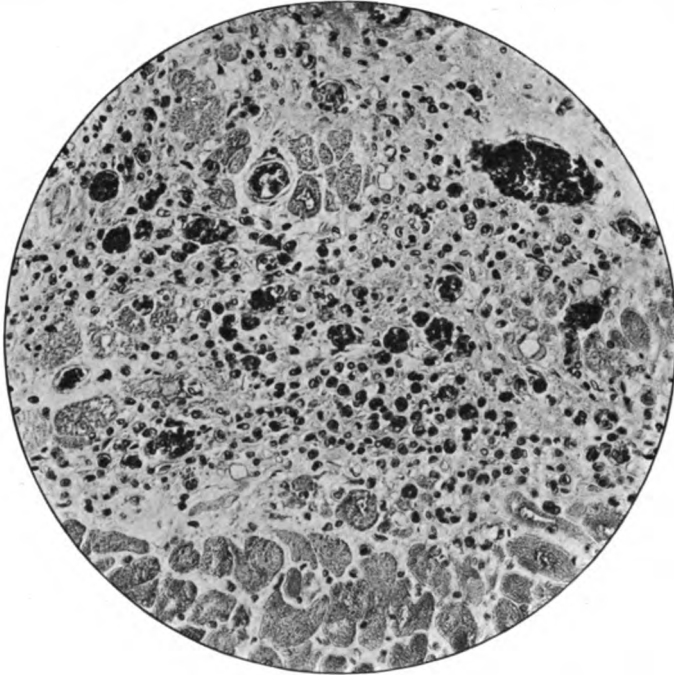


Fig. 332.—Heart. - Area of sclerosis due to necrosis and disappearance of the muscle-fibers. The fibroblasts and blood-vessels were not injured. M.

The necrotic fibers attract polymorphonuclear and endothelial leukocytes, sometimes the one, sometimes the other. The leukocytes invade the fibers and quickly dissolve and remove them, especially when the necrosis is diffuse and the intervening blood-vessels are uninjured. The process is often accompanied by a more or less extensive and diffuse infiltration with lymphocytes and occasionally with numerous eosinophiles. In infarctions the necrotic muscle is removed much more slowly, because it can be attacked only from the periphery.

Total destruction of myocardial tissue is followed by the formation of granulation tissue which eventually is reduced to scar tissue. When only the muscle-fibers in a given location are destroyed the blood-vessels and connective tissue left behind shrink together so that highly vascularized foci of connective tissue result; they are not new-formed although they suggest granulation tissue. In time by the gradual disappearance of many of the blood-vessels these foci may resemble scar tissue.

Calcification.—Calcification of muscle-fibers is rare, but sometimes occurs especially following poisoning by corrosive sublimate. It appears as yellowish white streaks in the papillary muscles and in the walls of the ventricles. In the fibers least affected a deposit of fine granules of lime-salts is present arranged like fat-droplets between the longitudinal fibrils. The granules may fuse into solid masses. Necrosis seems always to precede the lime deposit, but certainly, as a rule, necrotic muscle-fibers in the heart do not attract lime-salts. Probably fat in some form is the active agent when the deposition does take place.

When endocarditis is produced experimentally in rabbits through the agency of the streptococcus pyogenes, calcification of muscle-fibers is of common occurrence.

Atrophy.—Normally in old age and pathologically in emaciation from starvation, cancer, and other causes, the heart diminishes in size by disappearance of its fat-cells and by atrophy of its muscle-fibers. It may weigh less than half of what it should. The muscle-fibers become considerably more slender than under normal conditions owing to atrophy of the fibrils; many of those in the centers of the fibers seem to disappear. The longitudinal striations are distinct but delicate. The cross striations are hardly visible because the sarcous elements are very minute.

The pigment granules situated in the cytoplasm at the ends of the nuclei begin to appear towards the age of ten years and gradually increase in amount with age. When the heart undergoes atrophy the relative amount of pigment may be doubled, so that the heart seems more deeply pigmented than normally. On this account the term brown atrophy is often used, but it is extremely doubtful if there is any actual increase of pigment in the heart-fibers under these conditions.

The muscle-fibers sometimes undergo atrophy as the result of injury. This condition is best seen occasionally in the fibers adjoining the epicardium when there has been a severe pericarditis. The fibers in this situation, as already mentioned, are likely to contain numerous fat-droplets. Frequently many of the fibrils are partly to completely destroyed. After repair has taken place many of the remaining fibers are diminished to half the normal diameter

or even less. Occasionally the muscle nuclei show evidence of direct division. This fact seems to indicate that partial regeneration of injured heart muscle-fibers is possible just as in the case of skeletal muscle-fibers.

Disturbances of Circulation.—The terminal branches of the coronary arteries of the heart are end arteries, but the areas supplied by them are not absolutely cut off from each other; fine peripheral anastomoses exist between the separate areas.

Of the different arteries the descending branch of the left coronary is the most important.

The heart may be affected by general or by focal disturbances of circulation. The latter are much the more important. The general disturbances include both congestion and anemia.

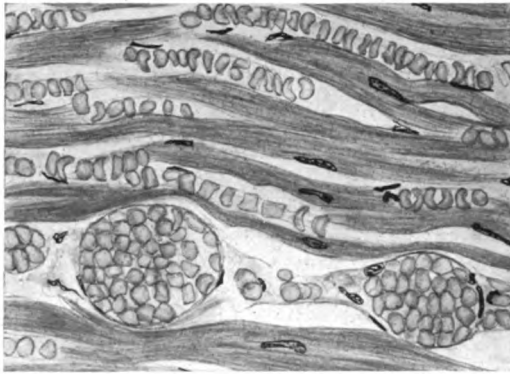


Fig. 333.—Heart. Chronic passive congestion.

Congestion leads to no changes in the muscle-fibers except that when congestion becomes chronic the fibers may become edematous and vacuolated.

General anemia is more important than congestion because it may affect the nutrition of the myocardium. In acute anemia from hemorrhage or other cause the myocardium appears pale but not cloudy. In chronic anemia much fat is usually present in the muscle-fibers in the form of fine to coarse droplets, but there is no increase of albuminous granules and no necrosis. Small hemorrhages may occur. Recovery from the condition probably can take place if the cause of the anemia is removed.

Local Anemia.—Local anemia is very much more important than general anemia because it usually results in destruction of muscle-fibers and thereby affects injuriously the action of the heart. It depends on interference with the circulation through the coronary arteries or their branches. Obstruction is usually caused by

an embolus or more often by thrombus formation. Arteriosclerosis frequently plays an important part as the lesion which most often leads to the formation of thrombi. Acute infectious lesions of the blood-vessels may, however, produce the same effect in the same way, by causing thrombus formation.

Local anemia may be produced suddenly or slowly, completely or only partially. The effect produced varies accordingly.

Complete local anemia results in infarction. It is usually produced suddenly by an embolus, or slowly by thrombosis. Partial anemia is generally due to thrombus formation, but may be due to arteriosclerosis alone.

When infarction has occurred the muscle-fibers and all the intervening connective tissue and blood-vessels undergo necrosis. Following the necrosis an inflammatory exudation takes place at the periphery of the infarction, and regeneration of fibroblasts and vascular endothelium starts up. In the course of time the necrotic material is dissolved and removed and the granulation tissue resulting from regeneration contracts and persists as scar tissue.

Infarcts occur most commonly in the papillary muscles and in the wall of the left ventricle, especially in the interventricular septum. They involve chiefly the central or deeper layer of the myocardium and rarely extend to the endocardium or pericardium. The occluded artery always lies outside of the infarcted area. At the edge of the infarction there is marked hyperemia and usually more or less hemorrhage. The abutting muscle-fibers contain much fat.

When local anemia is partial only, the amount of oxygen and nutrition supplied to the tissue is diminished. As a result many or all of the muscle-fibers degenerate and slowly disappear, or undergo necrosis and are removed by the action of the endothelial leukocytes attracted to them. The blood-vessels and fibroblasts being more resistant usually persist. The result is very vascular foci of connective tissue which resemble to some extent granulation tissue, but are not new-formed. In time, however, the blood-vessels atrophy and the connective tissue shrinks so that the resulting fibrous tissue closely resembles scar tissue.

Scleroses originating in this way are usually very irregularly distributed and may have muscle-fibers scattered singly or in smaller or larger groups all through them. The fibers are usually preserved also around the larger veins and beneath the endocardium, probably because nutrition reaches them by direct diffusion. Scleroses of this type are probably of more common occurrence than is generally supposed.

Ordinarily an infarct of the heart terminates in a small mass of scar tissue. Sometimes, however, if the infarcted area is large the

resulting softening of the necrotic tissue (myomalacia) in the process of repair may lead to rupture of the heart wall.

Rarely the scar tissue resulting from repair of an infarct is not strong enough to withstand the strain of the heart's action and gradually yields and forms an aneurysm. This aneurysm may rupture or a thrombus may form within it and undergo organization.

It is always possible that an infarct may involve the motor-exciting tract, His's bundle, and cause the Adams-Stokes syndrome.

Toxic Myocarditis.—*Occurrence and Cause.*—Following certain acute infectious diseases, especially diphtheria and scarlet

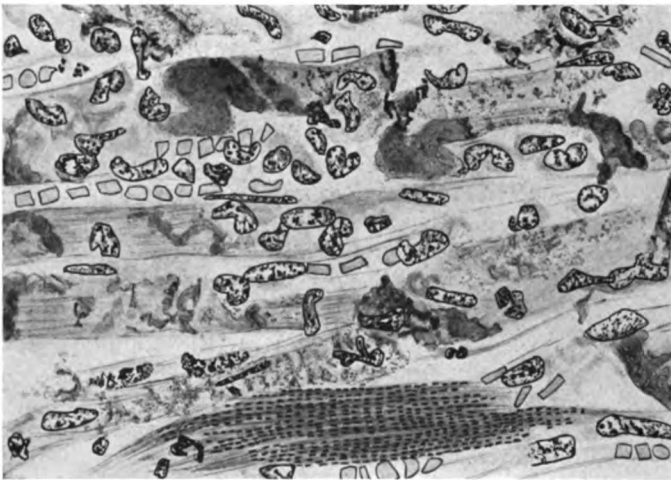


Fig. 334.—Heart. Acute toxic myocarditis. Necrosis of muscle-fibers; infiltration with endothelial leukocytes.

fever, but occasionally lobar pneumonia and other acute infectious processes, an infiltration of the myocardium with leukocytes and lymphocytes may occur, either alone or in combination with necrosis of the muscle-fibers. The lesion is rare except in young children, and is often accompanied by a similar lesion in the kidneys. It is due apparently to the action of soluble toxins emanating from the circulating blood and being absorbed through the lymph-spaces and vessels. Judging from the effects produced the toxins vary much in character and strength.

Injury.—In some instances the only injury produced is degeneration of the muscle-fibers as evidenced by the presence of fat-droplets. Occasionally, however, more or less extensive necrosis

of muscle-fibers is produced, often preceded by granular and hyaline changes. The necrosis may occur focally or diffusely and be slight or extensive in amount. The nuclei and striations of the muscle-fibers disappear, and sometimes the cytoplasm assumes a hyaline appearance.

Reaction.—The inflammatory reaction to the exuded toxin often consists of nothing but an accumulation of lymphocytes in the connective tissue, especially around the blood-vessels. The infiltration may be focal or diffuse and slight or very extensive in degree. Eosinophiles are usually present also in small quantities, but occasionally they outnumber the lymphocytes, at least in some places.

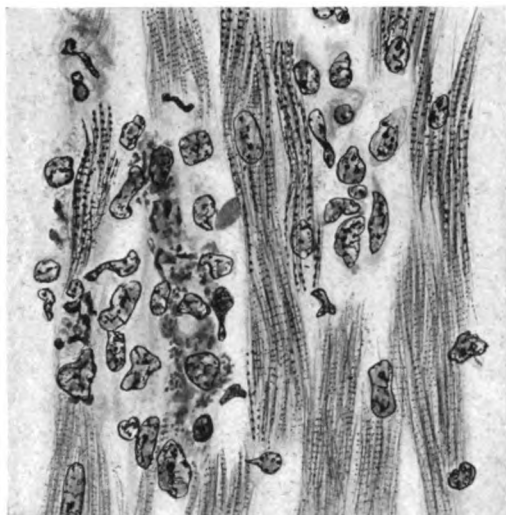


Fig. 335.—Necrosis of cardiac muscle-fibers. Exudation of endothelial leukocytes.

If any of the muscle-fibers undergo necrosis the reaction to them is different. They are invaded by polymorphonuclear or by endothelial leukocytes, or by both, and are gradually dissolved and removed. Sometimes the endothelial leukocytes will be found persisting for a long time in the spaces formerly occupied by the muscle-fibers.

The fibroblasts and vascular endothelium are not injured, or at least not destroyed, by the diffusible toxins, hence they remain after the muscle-fibers have disappeared.

Sometimes in typhoid fever the diffusible toxin leads to accumulations of endothelial leukocytes in considerable numbers in the lymph-spaces and vessels.

End Result.—After the necrotic cells have been removed the leukocytes gradually disappear, and the connective tissue shrinks and contracts. In this way vascular foci of sclerosis are formed, although there has been no new formation of connective tissue or blood-vessels.

Regeneration of muscle-cells in the affected areas does not take place, although it is probable that a general hyperplasia of muscle-cells may occur in young children following recovery.

Infectious Myocarditis.—*Introduction.*—Infectious myocarditis is the term applied to those forms of myocarditis in which the injurious agent is present in the lesions produced by it. As a rule, these lesions are focal in character.

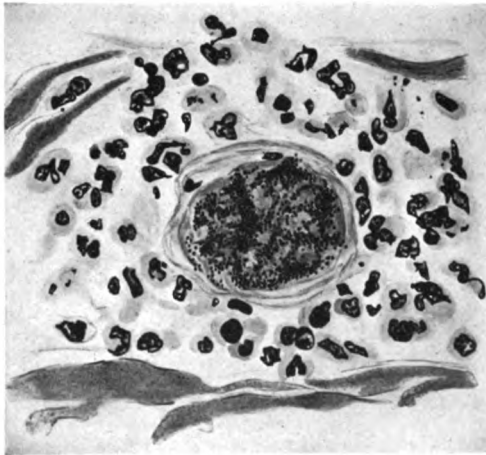


Fig. 336.—Heart. Mass of streptococci occluding small blood-vessel in heart. Necrosis of surrounding muscle-fibers and exudation of polymorphonuclear leukocytes.

Micro-organisms.—The injurious agents commonly present are the ordinary pus organisms, especially the staphylococcus aureus and the streptococcus pyogenes. Less often lesions are produced by such organisms as the tubercle bacillus, the gonococcus, the treponema pallidum, the trichinella spiralis.

Manner of Infection.—Most of these organisms reach the myocardium through the circulation. Sometimes they develop in the blood-vessels and completely occlude them. From the vessels they extend directly into the surrounding tissue, and in this way gain entrance to the lymphatics. The myocarditis may arise also by direct extension from an infectious endocarditis, less often from an acute pericarditis. Rarely the infection is due to invasion along

the lymphatics from the base of the heart, or to direct infection through a mechanical agent (stab wound of heart).

Injury.—The injury caused by the infectious agent depends on the nature of the latter. The pus cocci produce necrosis which may be focal or diffuse, according to whether the organisms remain closely grouped together or spread diffusely and rapidly. Sometimes the necrosis is very extensive and is produced so rapidly that only organisms are present in it. There has been no time for a leukocytic exudation to occur.

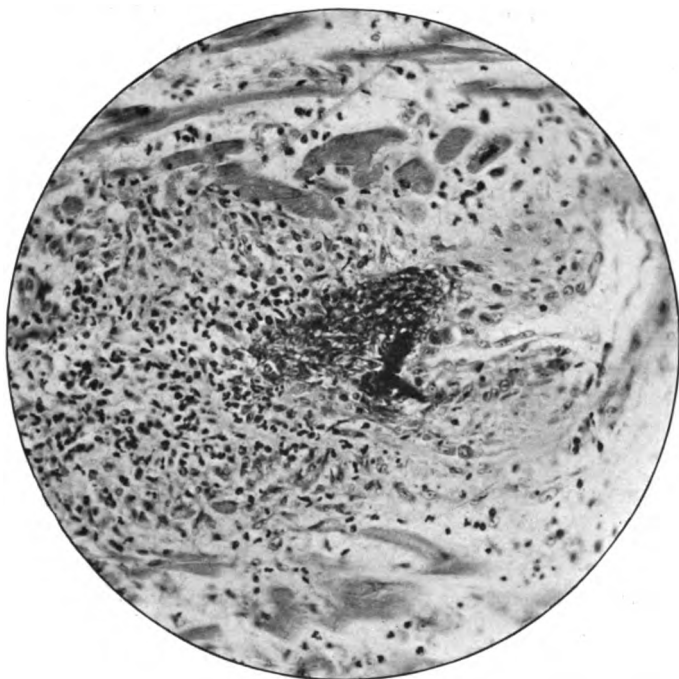


Fig. 337.—Heart. Acute infectious lesion in wall of blood-vessel. M.

As a rule the injury develops around organisms caught in the capillaries or incorporated by the lining endothelium of blood-vessels, especially of arteries. These infectious lesions of the arteries in the heart are fairly frequent and often prominent. If the organism is virulent it may produce necrosis of the vessel wall and extend into the surrounding tissue. Sometimes the wall is so weakened that it yields to the blood pressure forming what is known as an infectious aneurysm. Or the wall may rupture and give rise to hemorrhage. If the infecting organism is of mild virulence and dies out readily, the injury may be slight.

Reaction.—The reaction to the pus organisms consists of an active inflammatory exudation chiefly of polymorphonuclear leukocytes. The lesion may take the form of abscesses or of diffuse suppuration. The necrotic muscle-fibers are usually rapidly dissolved.

By extension of the inflammatory process the wall of the heart may be so weakened that it stretches and ruptures, so that the blood escapes into the pericardial cavity and accumulates there until by its pressure it stops the heart from beating.

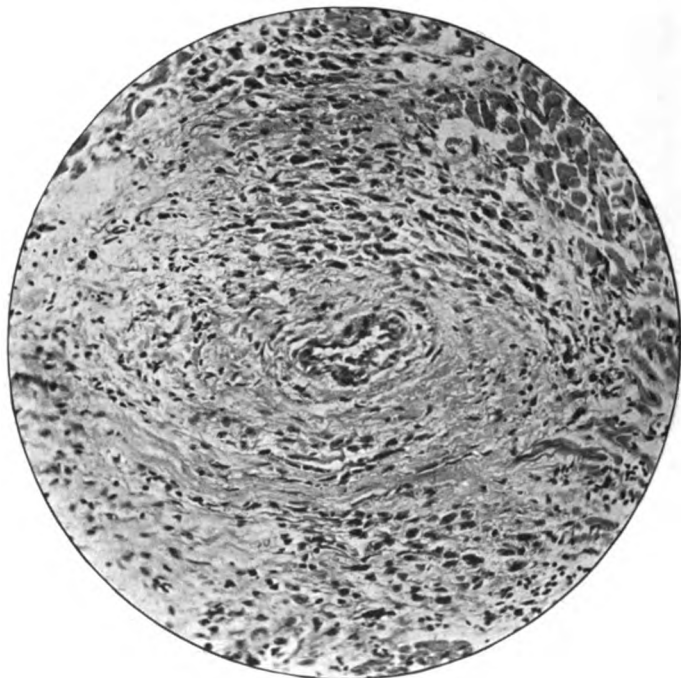


Fig. 338.—Heart. Acute articular rheumatism. Inflammatory lesion around artery. M.

When severe injury is produced in the walls of arteries the reaction consists of an exudation of polymorphonuclear and endothelial leukocytes in varying proportions; in addition lymphocytes are usually numerous. Much fibrin is formed both in the necrotic wall and often extensively outside of it in the loose perivascular tissue. In addition fibrin is frequently deposited in the lumen of the vessel as a thrombus which may partially or completely occlude it.

Repair.—Infectious lesions of the heart sometimes heal. This

is particularly true when the injurious agent is only mildly virulent and is destroyed as the result of the inflammatory reaction to it. The processes of repair are similar to those in other organs. The necrotic tissue is gradually dissolved through the action of the leukocytes and removed. The fibroblasts and vascular endothelium regenerate and form first granulation and then scar tissue.

Repair of the infectious lesions in the walls of the arteries demands a separate word, because they have not always been understood. They are often produced by organisms of slight viru-

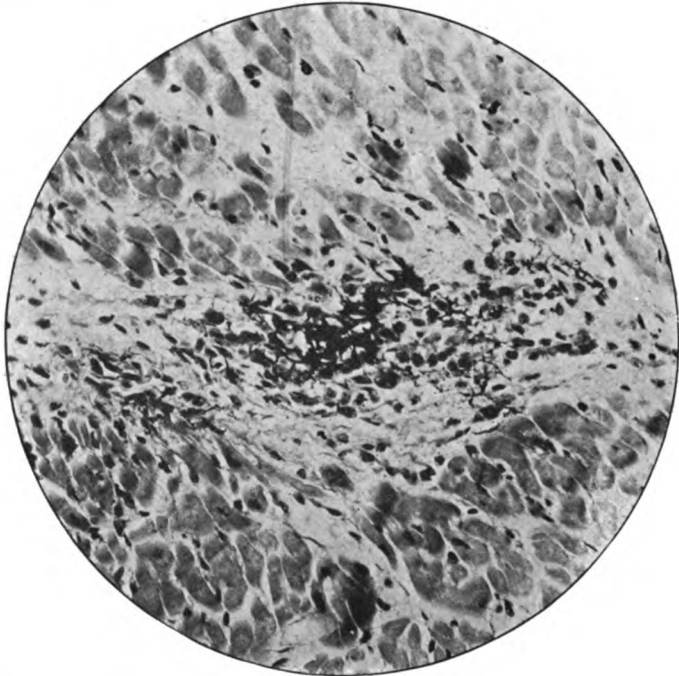


Fig. 339.—Heart. Acute articular rheumatism. Acute focal lesion in muscle.
M.

lence which die out so that repair is possible. The part of the wall destroyed is replaced by regeneration of fibroblasts. The smooth muscle-cells are not restored. If a thrombus has formed it becomes organized by fibroblasts and the lumen remains partly or entirely occluded. The lesions outside of the vessel walls are the most striking and prominent. This condition is due chiefly to necrosis of fibroblasts and to the large amount of fibrin often formed in this situation. The collagen fibrils left by necrosis of fibroblasts are very slowly attacked and dissolved by the action of endothelial

leukocytes which sometimes form multinucleated cells. In addition, the fibrin stimulates the neighboring fibroblasts which invade and organize it, thus producing an excess of fibrous tissue in that location. As a result of these two conditions clumps of fairly large cells and eventually masses of connective tissue are formed. These focal lesions have been considered characteristic of the clinical condition known as acute articular rheumatism. As a matter of fact they are characteristic of a certain type of infectious lesions of blood-vessels and chiefly of arteries. They may be caused by a variety of organisms, but chiefly by the streptococcus pyogenes. Occasionally all stages in the progress of the lesions may be found in one case. They are usually secondary to an infectious endocarditis, and cell changes similar to those described in the walls of the arteries may be found in the endocardium beneath the organisms. These infectious lesions of the blood-vessels are not limited to the heart, but may occur at the same time in the kidneys, liver, and other organs. The lesions known as periarteritis nodosa arise in this same way.

Necrosis of myocardial muscle-fibers frequently follows as a result of these infectious lesions of the blood-vessels in the heart, in consequence of the narrowing of the lumina of many of the vessels and cutting down of the blood supply.

Tuberculosis.—The inflammatory reaction to the tubercle bacillus in the myocardium is similar to that elsewhere in the body. The lesion is rare and occurs most often in the form of miliary tubercles. Occasionally large caseous nodules develop. By extension of these nodules the tubercle bacilli may reach the pericardium or endocardium, and cause a tuberculous pericarditis or tuberculosis of the parietal endocardium with thrombus formation.

Treponema Pallidum.—In congenital syphilis the treponema pallidum is frequently present in the myocardium. It does not invade it uniformly, but is extremely numerous in some places and absent in others.

It occurs between the muscle-fibers, between the collagen fibrils in the connective-tissue septa, in the walls of blood-vessels, especially arteries, and sometimes in the nerve bundles.

The direct injury produced by it is not evident. No necrosis is ordinarily present. On the other hand, the cells in the affected areas show the presence of considerable fat, an indication of faulty metabolism.

The reaction to the spirochetes is usually well marked. They lead to infiltration with endothelial leukocytes and lymphocytes and to proliferation of fibroblasts. As a result of this condition the connective-tissue septa are broadened and the walls of the arteries are thickened and their lumina narrowed. In instances of

extreme infection it is probable that these changes may result in the interruption of the blood supply and in the production of necrosis (gumma).

Recovery from the lesions described must leave behind a certain degree of diffuse sclerosis.

In acquired syphilis, infection of the heart is rare, but lesions of a character more or less similar to those in congenital syphilis sometimes result in the formation of gummas which are most likely to be situated in the septum between the auricles and ventricles.

Trichinella Spiralis.—In trichiniasis the embryos not infrequently emigrate from the vessels in the heart and try to invade the muscle-fibers. The attempt is always a failure, but results in focal lesions or necrosis of muscle-fibers and acute inflammatory exudation, which contains at first numerous endothelial leukocytes and eosinophiles. The embryos soon die or are killed and only a small focus of scar tissue is left as a mark of the injury produced.

Sclerosis.—As may be seen from a perusal of the preceding lesions, sclerosis of the myocardium may result from a variety of pathologic processes. The term chronic myocarditis is commonly applied to the condition, but is usually, at any rate, a misnomer, because sclerosis is an end product, the healed stage of some antecedent acute process and not itself an active process in any way.

Sclerosis most often results from:

1. Infarction following embolism or thrombosis.
2. Infectious myocarditis with destruction of all the cellular elements in the parts affected.
3. Syphilitic infection with or without the formation of gummas.
4. Necrosis due to slowly cutting off the blood supply with destruction of muscle-fibers only; contraction of the original connective tissue in the affected foci and gradual atrophy of the blood-vessels.
5. Toxic myocarditis with destruction of muscle-fibers only and similar contraction of connective tissue, etc.

New-Growths.—Tumors of the heart are not common or of much importance. Primary tumors are especially rare.

The most interesting primary tumor is the rhabdomyoma which starts in the wall of the ventricle. It is always congenital and is usually, perhaps always, associated with malformation of the central nervous system, especially with hypoplasia of the cerebral cortex, and often with malformation of the kidney. It occurs as a nodular mass of varying size and is sometimes multiple. The tissue may be composed of muscle-fibers exactly like the normal ones in the heart, but more often the cells are large and edematous, more or less spherical and contain fibrils in all stages of formation.

Other primary tumors which have been found here, especially in the auricles, are: fibroma, fibrosarcoma, myxoma, etc.

Metastatic tumors are more common: adrenal cancer, melanoma, chondroma, thyroid cancer.

Physiologic Effects.—Certain physiologic effects are produced by the cardiac lesions which have been described. It is perhaps valuable to refer to them briefly here so that the logical relation between lesions and physiologic effect may be borne clearly in mind.

Pericardial Cavity.—1. Fibrinous pericarditis with little or no serum present is usually attended with rubbing of the surfaces together; but they may become united.

2. The collection of a large amount of fluid (serum, pus, blood) in the pericardial cavity interferes with the action of the heart and may even stop it.

3. Organization of the fibrin resulting from pericarditis, often causes obliteration of the pericardial cavity and leads to more or less interference with the heart's action.

Endocardium.—1. Acute lesions of the valves may cause:

- (a) Vegetations.
- (b) Ulcerations and perforations of valve curtains.
- (c) Severance of chordæ tendineæ.

2. Repair of valve lesions may result in:

- (a) Thickening, shortening and interadherence of valve curtains and chordæ tendineæ.
- (b) Narrowing of valve openings (stenosis).
- (c) Lack of perfect closure of valves (insufficiency and incompetence).

These lesions may cause obstruction to the perfect flow of blood through the heart or leakage after it has passed the valves. The usual result is the production of abnormal sounds (murmurs) which to the trained physician are significant, in connection with other signs and symptoms, of the lesions producing them.

Myocardium.—1. Abundant ingrowth of fat-cells from the epicardium causes interference with muscular contraction.

2. Accumulation of fat in the muscle-fibers, especially when abundant, indicates serious interference with cell nutrition and activity, and possibly by its presence is mechanically disadvantageous.

3. Necrosis and disappearance of heart muscle-fibers from all sorts of causes mean so much loss of the heart's power which can be restored only by hypertrophy of the remaining muscle-fibers.

4. Destructive lesions involving in any way the bundle of His may lead to great functional disturbance and to the production of the Stokes-Adams syndrome.

BLOOD-VESSELS

Introduction.—The pathology of the blood-vessels can be best understood by taking up the lesions which occur in them, first

from the general and then from the special pathologic point of view. In addition, it is necessary to study the different varieties of early lesions and trace their development just as in the liver and kidney in order to get at an exact understanding of what takes place, and thus be in a position to interpret the late lesions and unravel their origin.

The same cause does not produce the same type of lesion throughout the vascular system. Hyaline formation is common in the arteries of the spleen under a variety of acute and chronic conditions. Nothing similar seems to occur in the aorta. Whether this difference is due to peculiarities of structure or of function or to some other cause is not evident.

In the aorta and larger arteries the intima and the muscle coat may undergo pathologic changes entirely independently of each other although both are often affected at the same time. In the smaller vessels the two structures are commonly involved together.

It is very important to study the vascular system both in the fresh condition and especially after fixation by two methods, formaldehyd and Zenker's fluid. The value of fixation in formaldehyd is that it permits the employment of certain chemical tests such as that for calcium and that it preserves, at least to a considerable extent, the fat in the tissues. This fat is best demonstrated in frozen sections stained with Scharlach R. and alum hematoxylin. After fixation in Zenker's fluid the various cells and intercellular substances can be sharply defined, particularly the elastic, collagen and fibroglia fibrils, and the smooth muscle-cells.

Anatomy.—One important point to bear in mind about the vascular system is that all parts of it, including heart, aorta, arteries, capillaries and veins, have in common the lining endothelial cells and a varying number of fibroblasts with their fibrils on which the endothelium rests. In many situations the fibroblasts produce, in addition to collagen fibrils, an abundance of elastic material which takes the form of fibers and membranes and may be variously distributed in the wall. The internal elastic lamina is, perhaps, the most important anatomic landmark in the arterial system, because so many lesions lie between it and the lining endothelium. To these two kinds of cells we have smooth muscle-cells added in the aorta, arteries and veins and striated muscle-cells in the heart. It follows from these anatomic conditions that certain lesions are likely to be common to all parts of the vascular system, while others will be limited to certain portions of it.

Another point of importance in the anatomy of the large blood-vessels is this, that the intima and an adjoining portion of

the media contain no capillaries. The cells composing these parts are nourished entirely by imbibition. This anatomic condition accounts for certain peculiarities in the repair of lesions, which will be spoken of later.

Injury.—Injury of blood-vessels may be caused by mechanical force, by disturbances of nutrition, by toxins of many kinds, or by the direct presence of injurious agents. It may be produced suddenly or slowly. The injury itself is shown chiefly by two forms of retrograde change, by an accumulation of fat in the cells injured and by necrosis. These two processes may be complicated by fibrin formation, by hyaline transformation, or by the deposition of lime-salts. The necrotic cells may preserve their form

for some time, or be masked by fibrin formation, or be dissolved quickly.

Fat.—The presence of fat in the different cells forming the walls of blood-vessels is the best guide we have as evidence that the functional activity of the lining cells is interfered with, owing to injury of some sort or other. If later the cells undergo necrosis the fat is set free and becomes a prominent feature in the lesions formed because its removal requires much time. In fact the reaction to the fat, at least

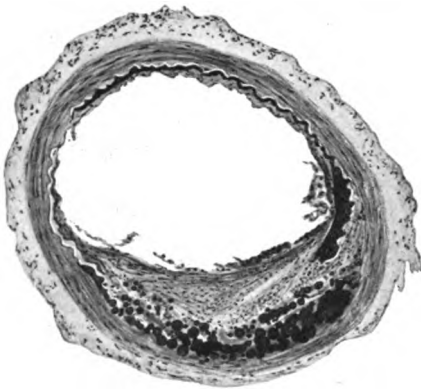


Fig. 340.—Artery. Cerebral meninges. Arteriosclerosis. Intima much thickened on one side. Fat, largely within endothelial leukocytes, abundant in deeper part.

in the intima, forms the most conspicuous feature in many lesions, especially those of a chronic type and is likely to lead one to overlook the real condition underlying it.

Under toxic and other unfavorable conditions fat may collect in the lining endothelial cells, in the muscle-cells, or in the fibroblasts. As a rule it collects most abundantly in the fibroblasts, especially in those situated in the intima, and in fresh tissue or in properly stained sections outlines even the most delicate cytoplasmic processes of these cells. The fat occurs usually in small to medium-sized droplets. An excellent way to study the condition is to strip thin layers from the intima of the aorta and mount them in water or stain them in Scharlach R. Fat is deposited also in very fine droplets between the collagen and elastic fibrils. Less often fat collects in the smooth muscle-cells.

Under favorable conditions cells containing fat can unquestionably utilize it later and return to a perfectly normal condition.

Fat is also commonly associated with the more serious lesions of blood-vessels, such as the hyaline change often present in the arteries of the spleen in diphtheria, for example, and necrosis from various causes.

In Zenker fixed tissues the endothelial leukocytes which were filled with fat appear with delicately reticulated cytoplasm owing

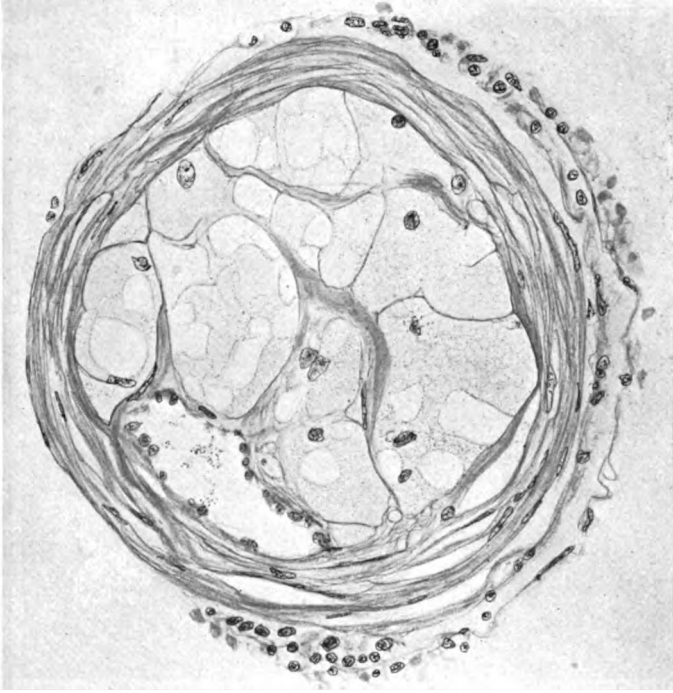


Fig. 341.—Artery. Brain. Endothelial leukocytes filled with fat-droplets accumulated in large numbers beneath lining endothelium. Secondary to cerebral hemorrhage and softening.

to the removal of the fat. These leukocytes often collect together in large numbers. They may be deposited in thin layers between the collagen fibrils or accumulate in large clumps with or without a slight collagen reticulum between them.

Necrosis.—Necrosis may involve the whole of the vessel wall or only a portion of it, or simply groups of cells in the intima or a single cell here and there. When necrosis is produced suddenly the cells contain little or no fat. When it occurs slowly, however,

much fat may accumulate in the cytoplasm owing to the inability of the cells to utilize it. In infectious lesions due to the pus organisms the necrotic cells are usually dissolved and disappear quickly, but under other conditions they may persist for a long time.

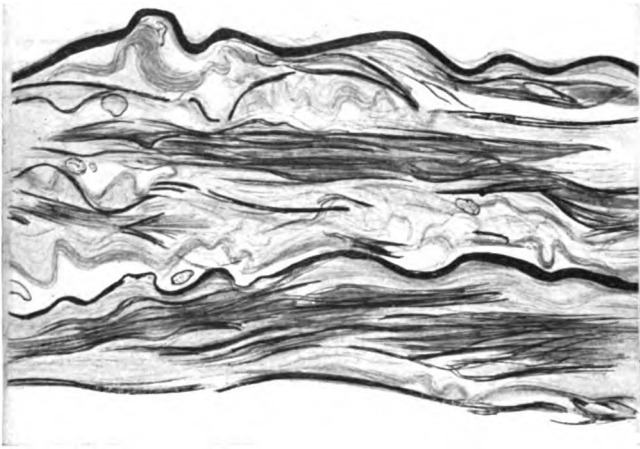


Fig. 342.—Aorta. Relative amounts of smooth muscle-cells and connective tissue between elastic plates under normal conditions.

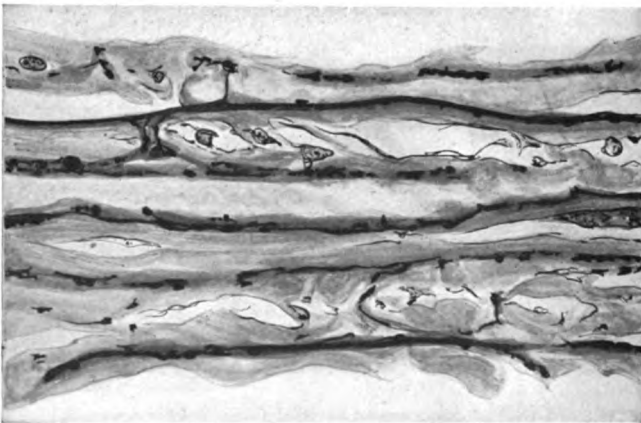


Fig. 343.—Aorta. Disappearance of smooth muscle-cells between elastic plates in sclerosed aorta.

Sometimes groups of the smooth muscle-cells in the walls of blood-vessels undergo necrosis. This condition is of much more frequent occurrence in the distributing arteries and in the aorta than in the small arteries. This necrosis of the muscle-cells may

occur independently, or in combination with the lesions which are so commonly found in the intima.

The necrosis may affect single smooth muscle-cells or small groups of them, or involve fairly extensive areas. The necrotic cells may contain many fat-droplets or few of them or none. In like manner they may contain small to coarse granules of lime-salts. Sometimes fat and lime-salts are demonstrable in the same cell at the same time. The necrotic cells may present a swollen hyaline or a granular appearance. They seem to disintegrate very slowly and to cause no inflammatory reaction around them.

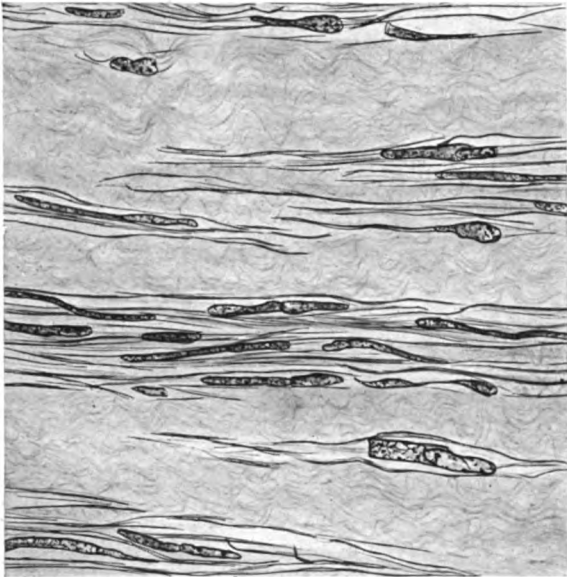


Fig. 344.—Artery. Disappearance of numerous smooth muscle-cells in the media. Relative increase of the connective tissue.

Neither the fat-droplets nor the granules of lime attract any leukocytes.

Hyalin.—Two different types of hyalin aside from amyloid frequently appear in the walls of blood-vessels.

The walls of the smaller arteries are sometimes transformed into hyaline material as the result of acute toxic action. The change is found most often in the arteries of the spleen, as the result of diphtheria and some other acute infections. The hyaline appearance seems to be due to necrosis and swelling of the vessel wall. Fat is always present.

Much the same picture is sometimes presented by vascular

lesions as the result of the long-continued action of toxic substances (the condition known as chronic arteriosclerosis).

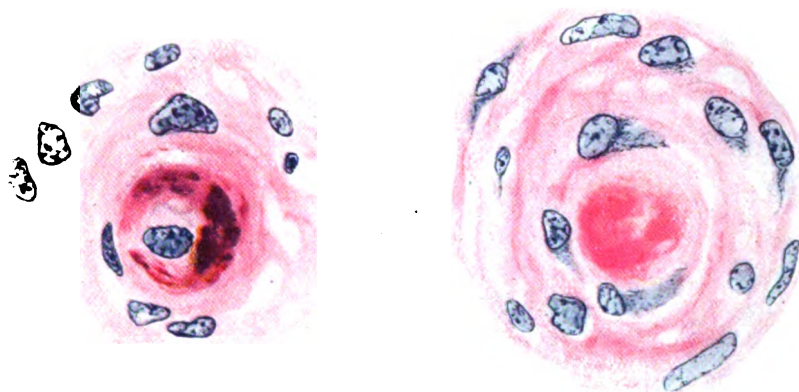


Fig. 345.—Artery. Kidney. Arteriosclerosis. Hyaline thickening of intima with occlusion of lumen.

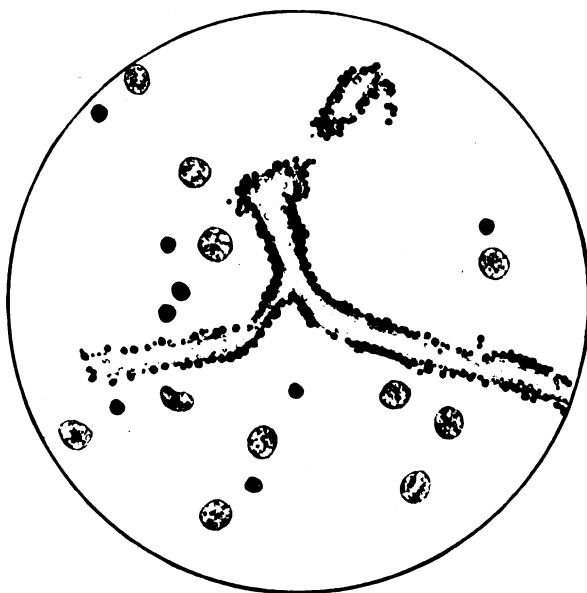


Fig. 346.—Hyalin forming in the walls of capillaries in the cerebellum.

The second kind of hyalin appears in the arteries and capillaries of the central nervous system. It is usually most marked in and

around the dentate nucleus of the cerebellum. The cause of the formation of this kind of hyalin is wholly unknown. The hyalin is deposited in the form of minute droplets which enlarge and fuse together, forming finally a complete sheath for the vessel. This form of hyalin often becomes calcified so that the larger vessels on section will project above the surface like ends of cut wires. Occasionally calcified masses are formed in this way.

Amyloid formation occurs very often in the walls of arteries and veins, but has been discussed elsewhere and does not require any further consideration here.

Lime-Salts.—Lesions of blood-vessels are very often complicated by the presence of lime-salts, probably owing in part at

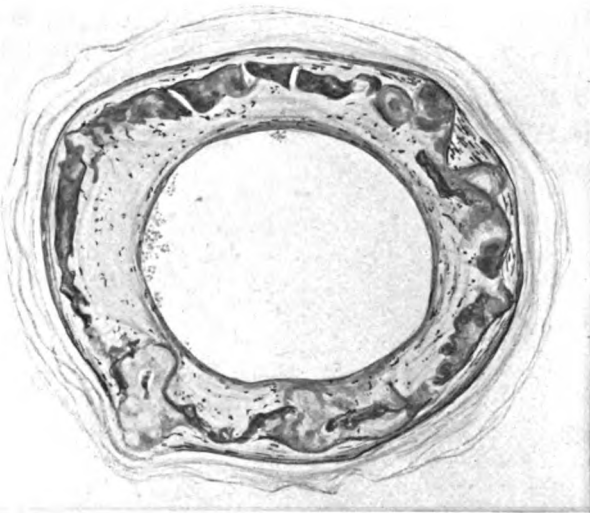


Fig. 347.—Artery. Calcification involving media and intima.

least to the frequent presence of fat and its decomposition products, some of which lead to the deposition of the lime. It is deposited only in necrotic material, frequently in the intima, less often in the muscle coat when the muscle-fibers have undergone necrosis.

Blood Pigment.—Blood pigment usually in the form of hemosiderin is sometimes found in blood-vessels as the result of hemorrhages into the walls, or because red blood-corpuscles were included in thrombi which later became organized. The hemoglobin is taken up by endothelial leukocytes, converted into hemosiderin and then very slowly digested and returned to the circulation.

Inflammatory Reaction.—The reaction following injury of the

cells in the walls of blood-vessels varies greatly as in other tissues from nothing to acute suppuration, depending on whether necrosis occurred slowly or suddenly, and whether it was the result of mechanical, nutritional, toxic or infectious causes. Necrosis of single cells in the intima may call out no leukocytes unless fat has accumulated in them. The necrotic cells may gradually dissolve and disappear. Any fat set free attracts endothelial leukocytes which take up the fat and very slowly dissolve it. If a group of cells containing fat die many endothelial leukocytes are attracted and gradually incorporate the fat, beginning at the periphery. This infiltration and accumulation of endothelial leukocytes as the result of the presence of fat set free by necrosis of cells is the most common and conspicuous lesion of arteries, and especially of the aorta. Free fat in the liver is quickly got rid of owing to the great vascularity of the tissue, but in the larger blood-vessels this is impossible. In the aorta this type of lesion is largely restricted to the intima, but in the smaller arteries it may extend through the whole wall into the adventitia. The endothelial leukocytes filled with fat may themselves undergo necrosis and set free their fat. In the fat thus collected together fatty acid and cholesterol crystals often form and the latter sometimes lead to the formation of foreign body giant-cells.

The accumulation of endothelial leukocytes filled with fat causes thickening of the intima which, as a result, is elevated and appears yellow and opaque.

Necrosis of the smooth muscle-cells, particularly in the aorta, may cause no reaction even where the cells contain fat-droplets or granules of lime or both, probably because the cells are so far from the circulating blood that their decomposition products exert no attraction on leukocytes.

The various steps in the process of repair of blood-vessels are best studied in the aorta, where they all occur on a large scale, but they can be followed perfectly well also in the arteries of the kidney, spleen, heart and meninges, and may even take place in the capillaries of the glomerular tufts of the kidney.

Necrosis due to infectious agents often involves the entire thickness of the wall and may call out an exudation of polymorphonuclear leukocytes alone or combined with endothelial leukocytes, lymphocytes and occasionally eosinophiles in varying proportions.

Fibrin is a frequent complication of the necrosis and exudation, whether the blood-vessel lesion is of toxic or infectious origin. The fibrin may be deposited in the vessel wall or outside of it, or within the lumen. It may appear as definite fibrin threads or form hyaline fibrinoid masses. It is useful in some respects, but is always a complicating and often a very injurious element.

A peculiar form of inflammatory reaction is found in blood-vessels not infrequently as the result of toxic substances of infectious origin diffusing along and through their walls. It occurs as an accumulation of leukocytes beneath the lining endothelium. In lobar pneumonia, in acute meningitis of various origin, in glanders, for example, polymorphonuclear leukocytes sometimes collect here in great numbers and may more or less occlude the lumen. In diphtheria and some other infectious diseases similar accumulations of lymphocytes may occur beneath the intima of veins, especially in the spleen.

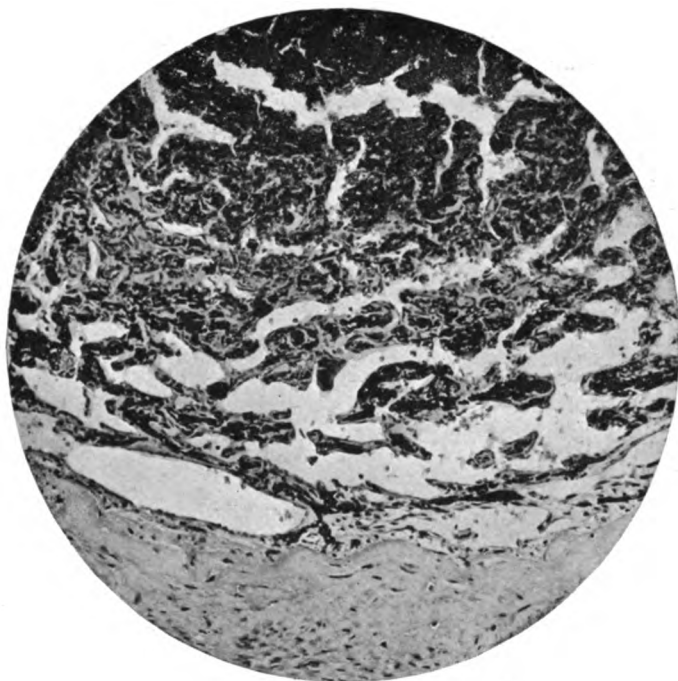

Fig. 348.—Artery. Thrombosis. Organization of fibrin which appears black. Numerous vessels formed by endothelium growing into cracks in the contracted fibrin and lining the walls of the spaces formed. M.

Regeneration and Repair.—Only the endothelial cells and the fibroblasts in the vessel walls regenerate; the smooth muscle-cells do not. The endothelial cells as a rule quickly replace any cells of their own kind which have been destroyed. They will grow over connective tissue or fibrin, but not over the broken down fatty (so-called atheromatous) material, occurring as the result of necrosis of cells filled with accumulated fat and frequently left

exposed to the blood stream in the form of erosions, especially in the aorta. They readily grow into fissures in fibrin resulting from contraction of this substance and thus line cavities which have been mistaken for newly formed blood-vessels. The fibrin between the cavities undergoes organization by fibroblasts.

Fibroblasts regenerate readily and replace those which have been destroyed when the process has been at all sudden. In lesions of slow origin, due chiefly or entirely to disturbances of nutrition or to toxic influences, there may be little or no regenera-

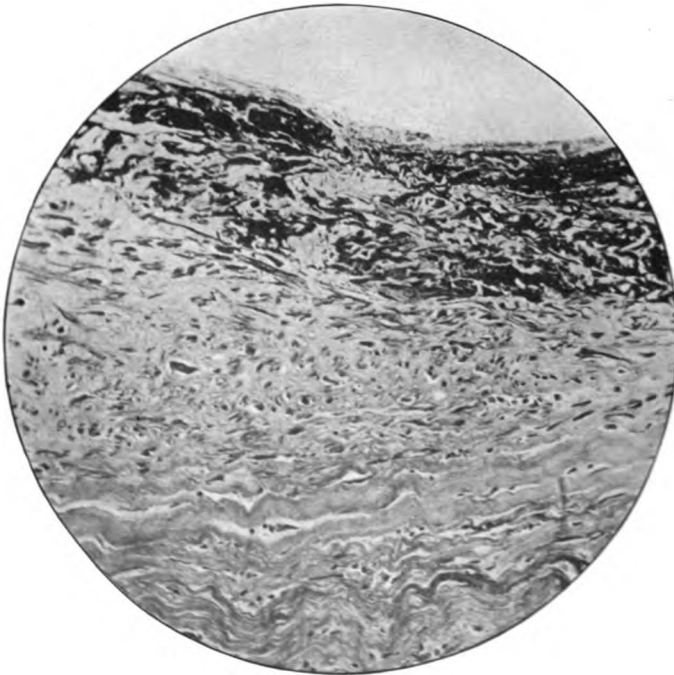


Fig. 349.—Aorta. Partially organized thrombus on intimal surface. Fibrin appears black. M.

tion owing to the lowered vitality of the surrounding fibroblasts. They are way below par as shown by the accumulation of fat within them. In other instances, where only cells here and there or in small groups have been injured and have undergone necrosis, regeneration takes place fairly well, especially on the intimal side near the source of nutrition. Regeneration of fibroblasts may in this way lead to a moderate amount of local thickening of the intima.

Fibrin and its organization by fibroblasts play an important

rôle in the repair of lesions of blood-vessels. The fibroblasts grow into any fibrin deposited in their neighborhood and replace it. They apparently utilize it as nourishment and flourish in it, producing numerous and prominent fibroglia fibrils. In this way the walls may be considerably thickened by organization of fibrin formed around or within them, and the lumen may be particularly or completely obliterated. Sometimes two or more layers of connective tissue can be made out on the surface of the aorta due to organization of separate deposits of fibrin.

All these fibroblasts have inherent in them the property of producing elastin in addition to fibroglia and collagen fibrils.




Fig. 350.—Organized thrombus in wall of artery. M.

Thus in the lumen they often lay down not only numerous elastic fibrils, but also elastic membranes.

Atheromatous erosions will persist a long time in the aorta with little or no attempt at repair, unless fibrin is deposited and stimulates the fibroblasts to replace it.

When perfect repair takes place the endothelial leukocytes gradually dissolve the fat which they have taken up and then disappear, probably by necrosis. The spaces they occupied are filled with serum which may in time be absorbed owing to contraction of the connective tissue. The intima as a rule remains permanently thickened.

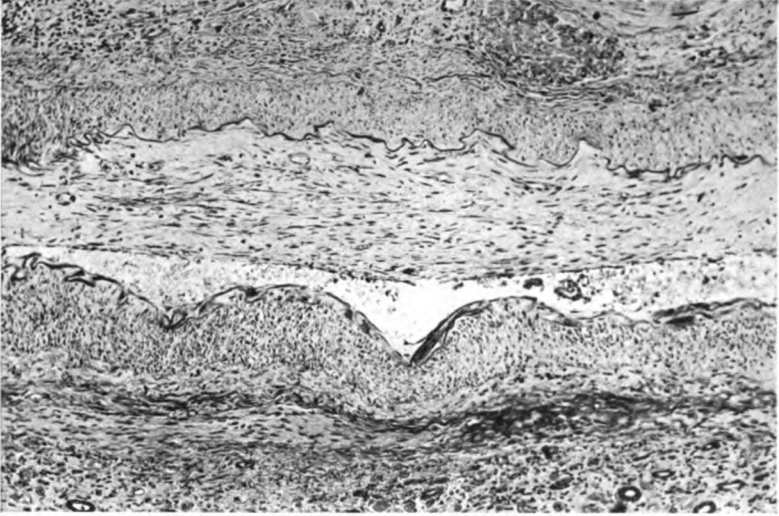


Fig. 351.—Organized thrombus in wall of artery in kidney. M.

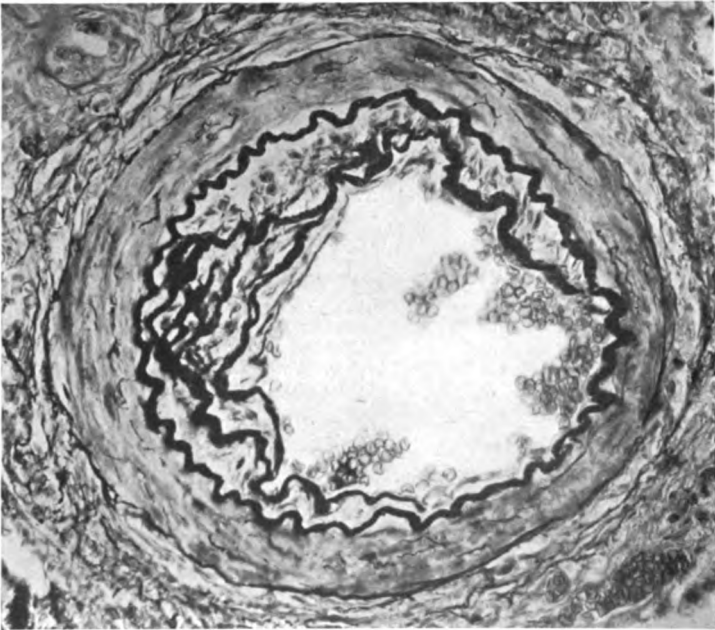


Fig. 352.—Artery. Kidney. Arteriosclerosis. Thickening of intima and formation of new elastic laminae. M.

It is noticeable that when toxic lesions have once started in the aorta, for instance, they often show a tendency to enlarge instead of healing and terminating in a small mass of scar tissue. Two factors may play some part in this besides the lowered vitality of the surrounding fibroblasts. The endothelial leukocytes attracted to the site may utilize much of the nourishment which reaches the part. In addition, regeneration of fibroblasts on the lumen side and especially organization of fibrin on the surface, results in removing the primary lesion farther and farther from the source of nutrition. As a consequence, many of the endothelial leukocytes themselves undergo necrosis. Possibly pressure due to contraction of the new-formed connective tissue on the mass of leukocytes, fat and débris also plays some part.

In the aorta and larger arteries injury and necrosis of the smooth muscle-cells are evidenced by the accumulation of fat and by the deposition of lime-salts; as a rule but little else can be made out. There is no reaction to the necrotic cells. When the necrotic cells are not calcified they gradually disappear and the connective tissue appears thickened and sometimes edematous. Beyond this sclerosis nothing else can be seen. Under other conditions the necrotic cells become calcified and the process may involve the intervening connective-tissue cells so that calcified plates are formed. Occasionally through the influence of the lime-salts adjoining fibroblasts organize the lime and are converted into bone cells and the calcified plate into bone.

Mechanical Lesions.—Blood-vessels are very often injured mechanically by compression, cutting, distension, etc. These lesions are of great importance surgically, especially incision and compression by ligatures. Thrombus formation within the injured vessel is of great value in effecting stoppage of hemorrhage, but later may prove more or less injurious by exciting organization by fibroblasts, with resulting permanent partial to complete occlusion of the lumen.

Rupture of a normal artery by sudden excessive distension is rare, but has occurred even in the aorta. On the other hand, the ordinary tension in the arterial system will lead to dilatation or rupture of vessel walls weakened by necrosis. Thus we may have aneurysms of acute or chronic infectious origin or due to long continued toxic action.

Lesions Due to Disturbances of Nutrition.—Vessels are often injured by having their blood supply partially to completely cut off. This may happen as the result of an embolus (fibrin, fat) or of a thrombus. The cells in the vessel walls may show by the presence of fat that they are functionally impaired, or they may undergo necrosis.

In cases of severe anemia the nutritional qualities of the blood may be so lowered that many of the cells in various vessels show the presence of much fat, and hemorrhages may occur from the smaller vessels as a result of weakening of the walls.

Lesions due to disturbances of nutrition are very often associated with those of toxic and infectious origin.

Toxic Lesions.—Toxic lesions of the blood-vessels, particularly of the arterial system, are of the greatest importance. They are to be found in all infectious processes which are at all severe. The

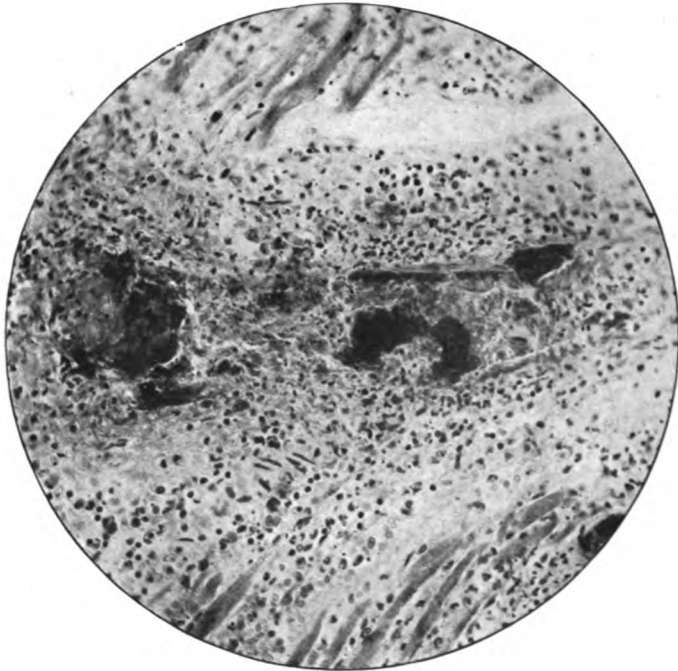


Fig. 353.—Heart. Infectious lesion of blood-vessel with necrosis of wall and inflammatory reaction. Masses of streptococci within lumen of vessels. M.

toxins are derived from the infectious agents in the local lesions or present as a septicemia in the circulating blood. Familiar examples are diphtheria, scarlet fever, lobar pneumonia, streptococcus septicemia, lead, etc. The injury to the vessels is usually evidenced by the presence of fat in the injured cells, less often by a hyaline change or by necrosis with both of which fat is always associated.

Injury of toxic origin tends to be more evenly distributed than that due to the immediate presence of an infectious agent, but

even this injury occurs in the vessels of some organs more than in those of others, and often shows a tendency to focal distribution. The reason for lack of perfectly uniform distribution is not evident. It does not seem to be dependent in any way on the vasa vasorum.

The best way to understand the toxic lesions of blood-vessels is to study them in young children who have died from various sorts of diseases, infectious and otherwise. The duration of the lesions found can usually be definitely estimated and the nature of the toxin surmised. In adults this information is not nearly so reliable because the lesions present may have existed there for years. No

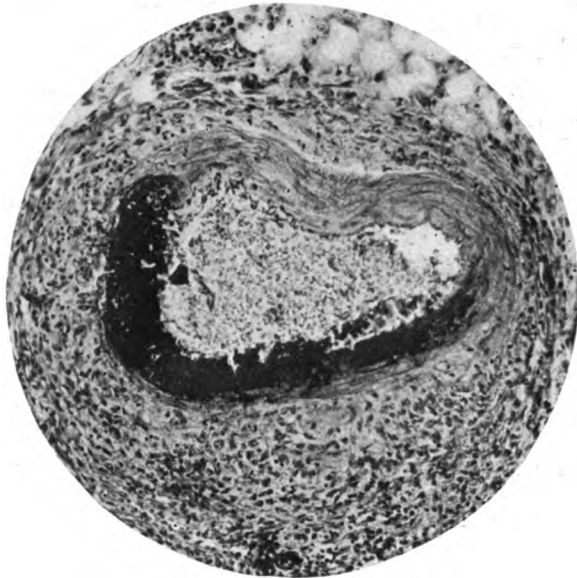


Fig. 354—Heart. Infectious lesion of artery. Necrosis, fibrin formation, polymorphonuclear and endothelial leukocytes, lymphocytes. M.

one can expect to reach old age without some of his vessels having been injured from a slight to a marked degree, not once but many times.

Infectious Lesions.—By the infectious lesions of blood-vessels is meant those which are due to the immediate presence of pathogenic micro-organisms of one kind or another. The lesions may be slight and even insignificant or so severe that complete occlusion or destruction of the vessel involved may be the final result. Their histologic structure and appearance vary greatly since they depend on the nature of the infecting micro-organisms and of these there

is a great variety. The severe acute lesions due to the so-called pus-cocci, terminating in complete destruction of the vessel wall and usually in abscess formation, are of frequent occurrence and the easiest to find. They are often very numerous and occur in a great variety of organs and tissues.

The most interesting lesions, at least from a histologic point of view, are those which are due to micro-organisms which die out readily after infection of the vessel wall is started, or are only mildly toxic and persist more or less indefinitely.

It is obvious that blood-vessels may be infected either on the outside from acute processes adjoining or surrounding them, or

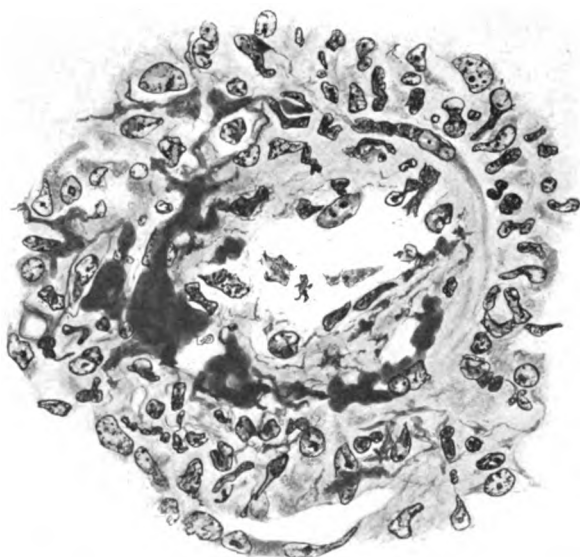


Fig. 355.—Artery. Kidney. Infectious lesion. Necrosis, fibrin-formation, polymorphonuclear and endothelial leukocytes.

from within in consequence of organisms having obtained access to the circulating blood and causing a septicemia. Some infectious agents invade the blood-vessels only from within, but most of them, like the streptococcus and the tubercle bacillus, may attack the vessels from either side.

The injury which may be produced in a vessel wall varies greatly, from changes so slight that they may be difficult to demonstrate, up to partial or complete necrosis. It may be followed by hemorrhage, by aneurysm formation, by inflammatory exudation and repair, or by complete destruction.

The inflammatory reaction to infections of the blood-vessels is the same as in other organs and tissues. It may be due (1) to the organism itself, (2) to the toxin derived from it, or (3) to the injured cells. It is sometimes easy to distinguish these three forms of reaction, but at other times it is not as they are often variously combined.

Collections of leukocytes sometimes occur beneath the lining endothelium of blood-vessels. They are usually due to toxins diffusing from organisms in the surrounding tissues and filtering through the vessel wall. Thus polymorphonuclear leukocytes

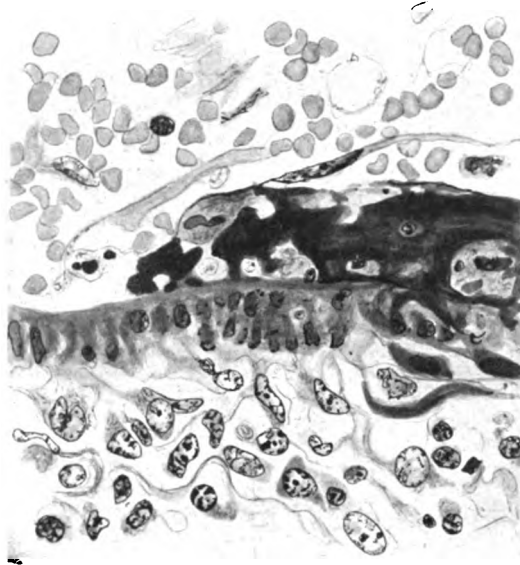


Fig. 356.—Artery. Kidney. Detail from infectious lesion in wall. Necrosis of muscle coat. Fibrin-formation beneath lining endothelium. Beginning leukocytic infiltration.

often accumulate in large numbers in this location, especially in arteries; for instance, in the lung in lobar pneumonia, in the meninges in acute infectious processes, and in many different organs and tissues in infections due to the glanders bacillus. Sometimes endothelial leukocytes and often lymphocytes may collect in the same situation. These three types of leukocytes may be combined in different proportions.

As the result of the inflammatory reaction to many organisms much fibrin is often formed from the exuded serum or from that circulating within the vessel. As in toxic lesions it is useful in

some respects, but is always a complicating and often a very injurious element. Unless many polymorphonuclear and endothelial leukocytes are attracted, and the fibrin is dissolved by ferments eliminated by them, it stimulates fibroblasts to proliferate. It does not of itself attract leukocytes. The fibrin may form in abundance in the wall of a vessel, in the perivascular tissue, or within the lumen as a thrombus which may partially or completely occlude it.

Hemorrhage.—Hemorrhage is a frequent complication of infectious lesions especially when the organism, as for instance the

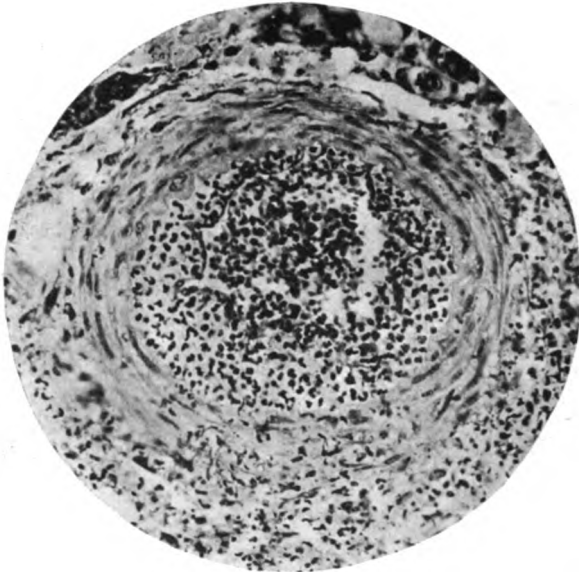


Fig. 357.—Glanders. Artery. Infection around vessel and invading it. Polymorphonuclear leukocytes have accumulated in large numbers beneath lining endothelium. M.

anthrax bacillus, is strongly toxic. Injury of the wall may cause hemorrhage so quickly that little else is seen but the blood around the vessel, and death may occur before much of any inflammatory reaction has had time to take place.

Repair.—Repair of infectious lesions in blood-vessels takes place as in other tissues. If only a part of the wall has been injured and little or no fibrin has been formed, almost complete restoration may take place. The necrotic cells and their fibrils are gradually dissolved by the action of polymorphonuclear leukocytes and absorbed. The hardest materials to dispose of are the elastic

and collagen fibrils. They become surrounded by endothelial leukocytes which often enlarge and may become multinucleated, forming foreign body giant-cells, just as they do around necrotic bone.

Infectious lesions due to a septicemia tend to be distributed more or less uniformly throughout the body. They may be few in number or very numerous. Acute generalized miliary tuberculosis furnishes a very good example of the distribution and varying number of the lesions which may be produced, because they all start as lesions of the blood-vessels, chiefly the capillaries, although we do not ordinarily think of them in that way.

Lesions of the vessels start wherever the micro-organisms find lodgment, and, as a rule, enlarge as long as the infectious agent

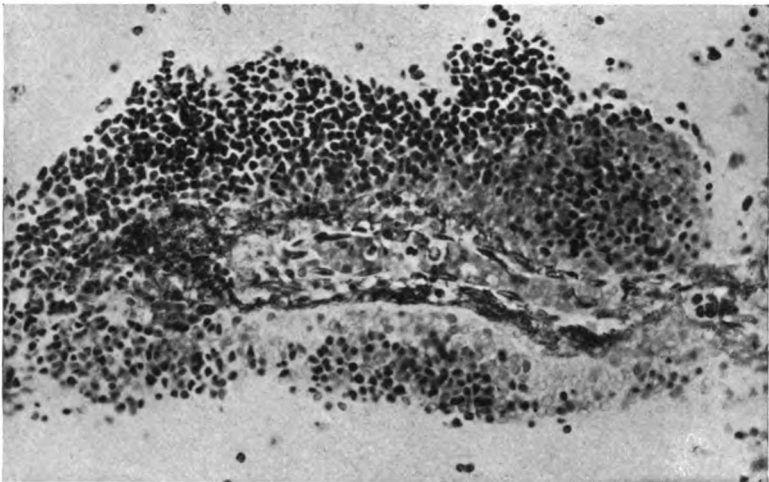


Fig. 358.—Hemorrhage from blood-vessel in brain. Due to the anthrax bacillus which is present in numbers in the vessel wall. M.

thrives and the patient lives. Some organisms develop and produce lesions in certain organs and tissues more readily than in others; thus the staphylococcus aureus in the kidney and heart, and the tubercle bacillus in the lung, liver and spleen. Some organisms infect only capillaries and sometimes only those in certain organs, while others like the leprosy bacillus may start in vessels of any character.

The streptococcus, perhaps more than any other of the pus-producing organisms, causes, when present in the circulation, a variety of lesions which may vary even in the same patient from simple necrosis followed by repair, because the cocci die out, to complete destruction of the wall and abscess formation.

Four cases will illustrate the different types of lesions which may be produced:

In the first, a girl eight years old, death occurred from acute purulent arthritis secondary to scarlet fever and diphtheria and due to the streptococcus pyogenes. Multiple acute infectious lesions of the blood-vessels were found in the heart, kidneys and liver. They all showed practically the same kind of histologic change, necrosis of a part of a vessel wall, with considerable fibrin formation and the accumulation of numerous polymorphonuclear

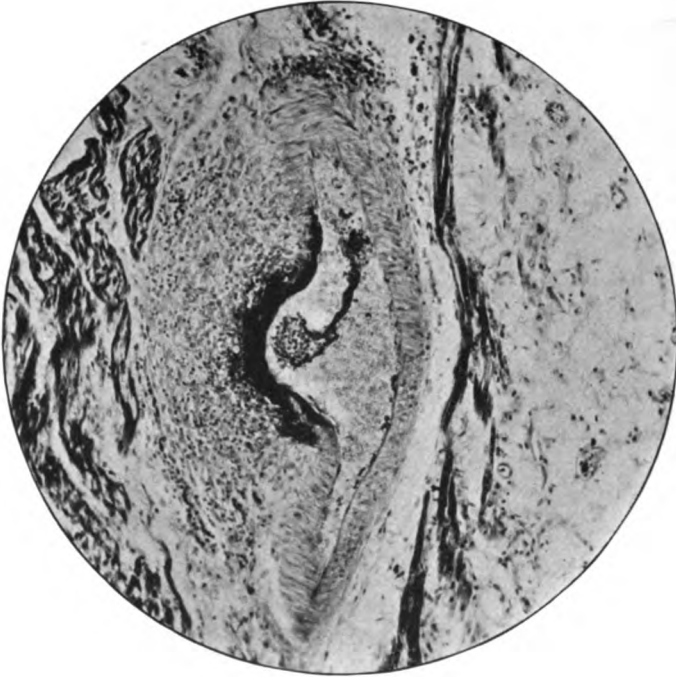

Fig. 359.—Artery. Heart. Acute infectious lesion; necrosis, fibrin-formation, leukocytic infiltration. Yielding of wall forming infectious aneurysm. M.

and endothelial leukocytes and some lymphocytes in the perivascular tissue adjoining the site of the injury. But little fibrin was deposited as a thrombus within the vessels. It was either in the wall or on the outside. In one of the arteries in the heart the injured wall is yielding to the blood pressure, forming an aneurysm of infectious origin.

The second patient was a male, nineteen years of age, who died from typical acute articular rheumatism of two weeks dura-

tion complicated at the end with lobar pneumonia. There was also a slight mitral endocarditis. Numerous lesions were found in the heart, in the walls of the arteries, and extending into the surrounding connective tissue. They were milder in type than in the preceding case and evidently in the stage of repair. Some showed considerable fibrin and numerous endothelial leukocytes. Strands of collagen fibrils left by necrotic fibroblasts were surrounded by them in places. Alongside some of the vessels focal cellular areas of connective tissue due to proliferation of the fibroblasts were present, and were surrounded and infiltrated by a few lymphocytes. These are the lesions considered characteristic

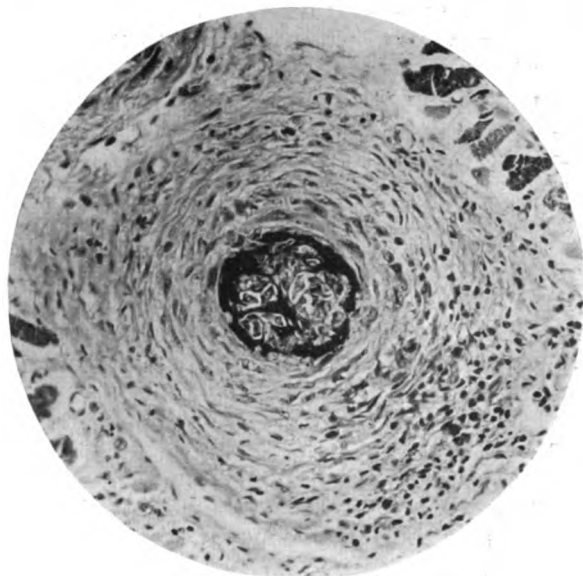


Fig. 360.—Artery in muscle. Periarteritis nodosa. (Case of Dr. W. T. Longcope). Lumen filled with fibrin; much increase of fibrous tissue in wall, largely as the result of organization of fibrin. M.

of acute articular rheumatism. They do not differ from those already described except in intensity.

In a third case, the patient, a woman aged thirty-three years, died from chronic infectious endocarditis of the mitral valve due to a streptococcus corresponding in type to that described by Poynton and Payne. The heart showed a number of infectious lesions in the walls of the blood-vessels and in the surrounding connective tissue. Some were acute and others healing. The important point is that all stages in the development of lesions corresponding to those described in the first two cases were present.

In the liver and kidney and in muscle-tissue from a case of periarteritis nodosa some of the lesions are acute and exactly like those described in case one. Others are in all stages of repair. The lesion is peculiar only in one respect; evidently much fibrin was formed within and outside of the vessels and it has led to marked proliferation of fibroblasts, so that the walls of some of the vessels are greatly thickened. Many are also completely occluded by thrombus formation.

These four cases illustrate very clearly the different types of infectious lesions produced in blood-vessels by an organism, usually some variety of streptococcus, which is not too virulent and which dies out quickly after causing an injury, thus giving opportunity for repair. It seems fair to conclude that the lesion often found in the heart in acute articular rheumatism is characteristic not of that disease, but only of an acute infectious process which has involved the walls of blood-vessels. Similar lesions may occur in the heart in other infections which have not presented the symptoms characteristic of acute articular rheumatism.

Special Infectious Agents.—Certain other micro-organisms, which more or less frequently infect blood-vessels, require brief separate consideration because the lesions which they cause differ in some respects from those already described. They are the bacilli of glanders, tuberculosis and leprosy and the treponema pallidum. In order to understand fully the lesions which they produce it is necessary to bear in mind the nature of the inflammatory reaction which each of these infectious agents brings about in the human body.

Glanders.—The blood-vessels are often infected in glanders. When they are involved from without the vessel wall may gradually undergo necrosis and polymorphonuclear leukocytes may collect in large numbers beneath the lining endothelium. The characteristic lesions are formed, however, within the vessels, most often in veins by the immediate presence of the bacilli. The cellular reaction of polymorphonuclear leukocytes around them together with the formation of more or less fibrin, lead to obstruction of the vessels and often to extension of the thrombotic process along them. Involvement of the surrounding tissue by direct extension and abscess formation is the usual termination. The interesting point is that the large multilobulated cells so characteristic of the glanders lesions are usually present in these thrombi.

Tuberculosis.—With a knowledge of the reaction of the body to the injurious effect produced by the tubercle bacillus, the tuberculous lesions of blood-vessels may be presented in a few words. Lesions in the capillaries are very common. They are due to the bacilli being taken up by the lining endothelial cells. The toxins

eliminated by them attract endothelial leukocytes which occlude the vessel and in time cut off the nutrition. Most miliary tubercles start in this way. In the terminal veins of the spleen the endothelial leukocytes sometimes collect in such large numbers as to distend and occlude them. They form what may be called endothelial-cell thrombi.

The larger blood-vessels, both veins and arteries, are most often infected from without by direct extension of the tuberculous lesions surrounding them. Such infections of the vessels can be found most often in the meninges and in the lung. The bacilli may invade the intima and give rise to miliary tubercles lying beneath the endothelial lining, or more commonly to the formation of thrombi consisting of fibrin or of endothelial leukocytes, or of a varying combination of these two elements. In the fibrinous thrombus the tubercle bacilli may develop in great numbers and later, by softening and rupture of the thrombus, be discharged into the circulation. Evidently fibrin under certain conditions is an excellent culture medium for the tubercle bacillus. Infection of the larger blood-vessels from the intimal side is rare but possible; miliary tubercles have been found even on the inner surface of the aorta.

Tuberculous lesions of the arteries and aorta have in rare instances caused weakening of the wall and aneurysmal formation.

The tuberculous lesions of blood-vessels may be summed up in a few words. They are very common in capillaries and lead to complete occlusion of them. They occur more or less frequently in the small veins and arteries especially in certain parts of the body, such as the lungs, for instance, and are dangerous because the tubercle bacilli may multiply in great numbers and by escaping into the circulation give rise to acute generalized miliary tuberculosis. Rarely they lead to the formation of an aneurysm in arteries or the aorta from which again large numbers of bacilli may be discharged into the blood.

Leprosy.—In leprosy the changes in the blood-vessels are not prominent. Bacilli are very often present in small to large numbers in the lining endothelial cells. They attract no leukocytes as tubercle bacilli would do and produce no visible effect of any sort. They do not even seem to invade the adjoining tissue. Another type of lesion is due to the presence of endothelial leukocytes filled with bacilli in the vessel wall which may in consequence be considerably thickened. The bacilli sometimes invade the fibroblasts near them. Such vessels may in time show much thickening of their walls, with narrowing of their lumina and disappearance of the smooth muscle-cells. The atrophy of leprosy nodules and scar tissue formation is probably dependent, in part at least, on sclerosis of the blood-vessels.

Syphilis.—Lesions of blood-vessels due to the immediate presence of the *treponema pallidum* occur frequently and at all stages of the disease. They are most important, however, during the tertiary stage because then they tend to be progressive, frequently causing complete obliteration of the lumen and necrosis (infarction, gumma) of the tissue supplied by the vessel affected. The infection may involve the vessel from without, starting in the adventitia, or it may begin in the intima. It consists of a low grade of inflammatory reaction, chiefly endothelial leukocytes and lymphocytes combined sometimes with polymorphonuclear leukocytes. Reparative proliferation of the fibroblasts is usually a prominent feature. Owing to extension of the infection the media generally becomes




Fig. 361.—Syphilis, acquired. Aorta. Area of necrosis in upper part of media. Intima thickened owing to fibrin-formation and organization. M.

involved in the process. As soon as necrosis is produced much fibrin is formed both within and outside of the vessel.

The lesions in the aorta do not differ in essential nature from those in other blood-vessels, but are usually more extensive. They may start in the intima or adventitia, but probably most commonly in the former and certainly as a rule extend to the media. More or less extensive necroses may be formed which often attract leukocytes in large numbers. These lesions are usually spoken of as miliary gummas. Fibrin often forms on the intimal surface and undergoes organization by fibroblasts.

Arteriosclerosis.—Arteriosclerosis is the term applied to the more or less chronic lesions of the aorta and arteries, or to the end

product of these lesions. It is the end result of the various toxic, nutritional and infectious lesions involving the arterial system. It corresponds to sclerosis of the liver, kidney and other organs. It is usually of toxic origin, but may be the result of infection (syphilis). The two forms may be and often are combined. Disturbances of nutrition may play an important part, more particularly in the smaller vessels (kidney, for example). It is by no means easy or always possible to state in a given case the nature of the origin of the chronic lesions in the aorta and in the arteries, but a knowledge of the way in which the different types of lesions develop and their usual distribution will help much.

Some pathologists prefer the term atherosclerosis because fat and its products, which so commonly complicate the lesions, often form, together with the cellular reaction to them, a more prominent feature than the primary lesion or the sclerosis. Moreover, the sclerosis is usually slight except when fibrin has led to organization or when the lesion is due to the *treponema pallidum*. On the whole, however, the older term, arteriosclerosis, seems to be preferable.

Arteriosclerosis is a very common and often prominent pathologic condition in people beyond middle age, but similar lesions sometimes occur in comparatively young people (sixteen years of age, for instance). Very often there are present all stages of the process from injury and necrosis with fat accumulation, to the resulting inflammatory reaction and repair, and to these there may be added the complications due to calcification, surface erosion, fibrin formation and organization. The result is a very confusing picture both in gross and microscopically. It can be understood only by analyzing it into its different elements and arranging them in the order of their development.

ORGANS OF RESPIRATION

LUNGS

Introduction.—Toxic lesions play no important part in the pathology of the lungs. There are no highly differentiated parenchymatous cells present in numbers like the liver cells in the liver and the muscle-fibers in the heart, which can be affected by toxins circulating in the blood or entering with the inspired air. The epithelium lining the bronchi and air-sacs plays a useful but insignificant part; it is only a surface covering.

The most important lesions of the lungs are those of infectious origin. They occur in the greatest variety. Here they are taken up only from the anatomic point of view. The different

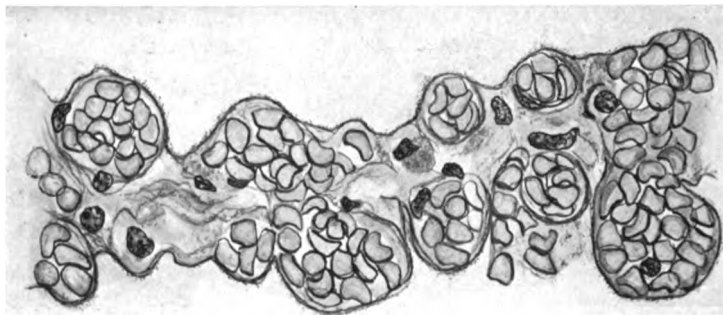


Fig. 362.—Lung. Chronic passive congestion. Dilated capillaries projecting from wall into alveoli on each side.

forms of inflammatory reaction occurring in them will be found discussed under the various infectious agents which cause them.

Disturbances of Circulation.—*Acute congestion* in the lungs is of little significance by itself. It is present in all acute inflammatory conditions, follows extreme exertion, and occurs as the result of sudden heart failure.

Chronic passive congestion is of more importance. It occurs most often in consequence of obstruction or leak in the left heart, especially when due to lesions of the mitral valve. The internal vascular pressure causes distension and elongation of the capillaries so that they project in loops from the alveolar walls into the air-sacs. Small hemorrhages from the distended capillaries are common. The red blood-corpuscles which are not expectorated

are taken up by endothelial leukocytes which occasionally fill some of the alveoli. They are sometimes called heart-failure cells. Some of the leukocytes invade the walls and settle around the blood-vessels and bronchi. They gradually transform the hemoglobin into hemosiderin. If carbon is taken up by the same leukocytes the hemosiderin is deposited around the carbon.

Chronic passive congestion leads to increased consistence of the lungs which are denser to the touch, and do not contract as under normal conditions. In color they appear dark red or brownish red. When the leukocytes containing blood pigment are numerous they may appear as orange colored specks.

Infarction.—An infarction in the lung is always hemorrhagic and is always due to an embolus. An embolus, however, does not always produce an infarction; it does it only under two conditions—when the embolus is infected or when there is chronic passive congestion in the pulmonary circulation. As the result of occlusion of a pulmonary artery the blood pressure in the affected area is at first much lowered, but is soon raised again owing to back pressure from the surrounding veins. Circulation ceases, stasis exists, and hemorrhage into the alveoli soon takes place, probably entirely as the result of injury to the cells of the vessels owing to lack of nutrition. Necrosis of all the cells in the infarcted focus is soon evident.

Infarctions of the lungs are always at the periphery of the lobes; they vary much in size and rarely may involve an entire lobe. As a rule they are multiple. They occur most often shortly before death, but if the patient survives, repair takes place. An inflammatory exudation at the periphery is followed by granulation tissue. The infarction is gradually invaded and absorbed and replaced by scar tissue.

A septic infarction quickly becomes invaded by the infectious agent present and is usually converted into an abscess or into a gangrenous focus. A bland infarction may undergo the same termination as the result of infection by way of the bronchi.

Fat embolism is not of great importance in the lungs unless the amount of fat is excessive so that at least one-third of all the blood-vessels are occluded. Under this condition small hemorrhages and edema may occur.

Edema.—Fluid containing more or less albumin often accumulates in the alveoli and smaller bronchi of the lungs. It may also distend the lymph-vessels. The causes of this accumulation of fluid are several, and the extent, distribution and composition of the fluid vary with the cause. The albumin contained in solution is precipitated in granular form by some fixatives (Zenker's fluid, boiling) but not by others (formaldehyd).

In generalized edema of the lungs, due to impairment of the heart's action, or to certain disturbances resulting in hydremia (chronic nephritis, pernicious anemia, etc.) the fluid escaping from the vessels everywhere tends to accumulate in the dependent parts of the lungs according to the position of the body, usually in the posterior inferior portions. The fluid collecting under these conditions contains a moderate amount of albumin and usually a few desquamated, swollen epithelial cells. When the accumulation of fluid is abundant the lungs are voluminous and heavy, the consistence is doughy, and on section a watery fluid mixed with more or less air in the form of small bubbles escapes from the surface.

The fluid present in edema is a good culture medium. On this account it is always liable to infection, which takes the form of so-called hypostatic pneumonia.

Localized edema is usually, perhaps always, of inflammatory origin. It is a serous exudation and contains a higher percentage of albumin than the fluid in generalized edema, and also a varying number of leukocytes. Fibrin may form in it. It is common in the early stage of lobar pneumonia and also in connection with atelectasis and hypostasis, probably as a result of their being infected. In certain tuberculous lesions, where the lymphatics are involved, localized edema may be present and may exhibit a gelatinous appearance owing to the large amount of albumin and numerous endothelial leukocytes contained in it.

Lesions of Mechanical Origin.—Two different forms of emphysema are recognized. (a) *Interstitial emphysema* is due to the escape of air from the lung into the interstitial tissue between the alveoli, especially into the connective-tissue septa between the lobules. The condition results from rupture of the alveolar wall in consequence of increased air pressure as in violent coughing, for example. The interstitial air may extend to the base of the lung and by this path eventually reach the wall of the thorax.

(b) *Alveolar emphysema* is a condition in which the air-sacs are much distended and often coalesce to form vesicles of considerable size, occasionally one to several centimeters in diameter, with thin walls. The cause of the dilatation in many instances is increased air pressure due to obstruction to expiration, but a similar condition may apparently arise simply from old age and atrophy of lung tissue. The elastic fibers in the alveolar walls diminish in number and many of the capillaries disappear, so that eventually obstruction to the flow of blood through the lungs is produced and causes chronic passive congestion in the venous circulation.

In spite of the atrophy of lung tissue alveolar emphysema

results in increase in the volume of the lungs and hence of the thorax, giving it the well-recognized barrel shape.

Carbon and less often certain other substances, such as iron in pulverized form, enter the lung and act injuriously. Their effect, so far as we know, is entirely mechanical. A description of the lesion they produce will be found under the heading "Carbon."

Atelectasis is the term applied to undistended or to compressed foci of lung tissue. The condition may be congenital, due to parts of the lung not having been inflated at the time of birth, or acquired, due to compression of lung tissue from without by fluid, tumor or other cause, or to obstruction of a bronchus by mucus, inflammatory secretion, foreign body, etc. Following the obstruction the air in the part affected is soon absorbed, the blood-vessels are distended and the part involved appears of a dark bluish-red color. It is always sharply limited to several or many lobules.

Atelectatic lung tissue on microscopic examination shows contracted alveoli with the lining epithelial cells prominent and more or less cuboidal in shape owing to contraction.

Lesions of Infectious Origin.—The infectious lesions are the most numerous, varied and important of the pathologic processes affecting the lungs. They are due to a great variety of micro-organisms among which the bacteria easily hold first place.

The lungs are open to infection through the bronchi as well as through the venous and arterial circulation, by direct continuity with the pleural and pericardial cavities and the surrounding tissues, and through the lymphatics.

The infectious lesions of the lungs are classified, for the most part, on an anatomic basis (lobar and lobular or focal pneumonia), although etiology, manner of infection, etc., sometimes play a part (tuberculous pneumonia, embolic pneumonia). The anatomic point of view will be followed here so far as possible, because the lesions have already been presented etiologically under the infectious agents. The anatomic lesions recognized are lobar pneumonia, lobular, focal or bronchopneumonia, abscess and cavity. They may be acute or chronic in their clinical course.

Lobular pneumonia is the term applied to inflammatory foci in the lung involving only part of a lobe. The foci are usually, but not always multiple. Other terms in common use are focal pneumonia and bronchopneumonia.

Manner of Infection.—In lobular pneumonia infection, as a rule, takes place through the bronchi and through the same channels the organisms may be distributed to other parts of the lung to start up other foci of infection. Infectious agents may also reach

the lung, however, through the circulation and give rise to lobular pneumonia. Lesions arising in this manner are sometimes called embolic pneumonia.

In generalized miliary tuberculosis the lesions in the lung, especially in children, although called miliary tubercles, are histologically often miliary foci of tuberculous pneumonia of embolic, that is vascular, origin.

An organism which reaches the lung through the blood may later spread through the bronchi.

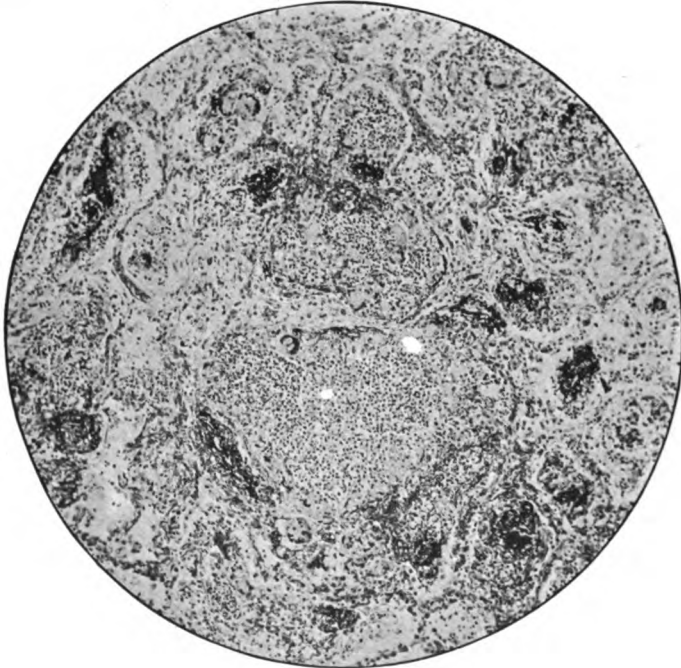


Fig. 363.—Lung. Focal pneumonia due to the blastomyces. M.

Etiology.—Lobular pneumonia, unlike lobar pneumonia, may be due to a great variety of micro-organisms. The most frequent one is, perhaps, the micrococcus lanceolatus followed by the streptococcus pyogenes, the staphylococcus aureus, the tubercle bacillus and many others which are found only occasionally, such as the glanders bacillus, actinomyces, oidium, etc.

Injury.—The injury in lobular pneumonia depends chiefly on the character of the infectious agent. It may be slight if due to the diplococcus lanceolatus, for example, or severe (necrosis) if due to the staphylococcus aureus or the glanders bacillus.

Necrosis is, perhaps, more likely to occur when infection takes place through the blood-vessels than when it comes through the bronchi.

Reaction.—The inflammatory reaction in the lung, like the injury, depends largely on the character of the infectious agent. It may vary from serum and a few polymorphonuclear leukocytes to an abundance of fibrin or to acute suppuration. Sometimes endothelial leukocytes play the more prominent part. Rarely giant-cells are formed by syncytial growth of the lining epithelium. Hemorrhage is a frequent complication. The walls of the alveoli and bronchi may remain intact or undergo necrosis and persist in caseous material or dissolve with abscess formation.

Lobular pneumonia begins in minute foci of inflammatory reaction around single organisms or small groups of them, and

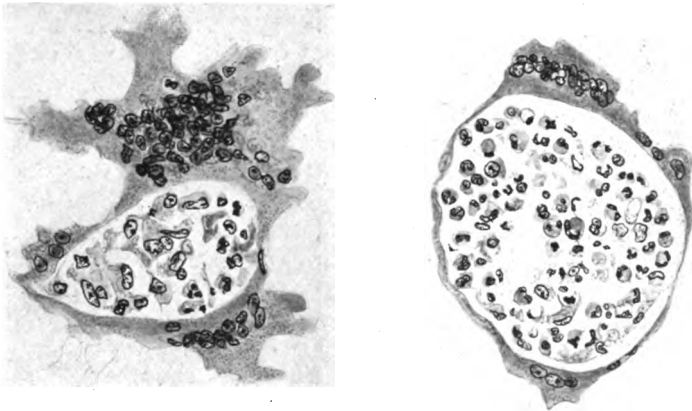


Fig. 364.—Lung. Pneumonia. Giant-cells formed by syncytial growth of alveolar epithelium.

tends to spread peripherally, through the walls of alveoli and along the bronchioles. Neighboring foci often become confluent. In this way and by direct spreading large foci are formed. Sometimes lobar pneumonia due to the diplococcus lanceolatus and to the bacillus mucosus capsulatus suggests this mode of formation.

The various lymphatics around the blood-vessels and elsewhere are often greatly distended by serum and leukocytes within them.

The exudation in acute lobular pneumonia usually undergoes resolution, but occasionally when much fibrin has been formed, organization takes place just as in lobar pneumonia. It is also of common occurrence in the chronic lesions due to the tubercle bacillus.

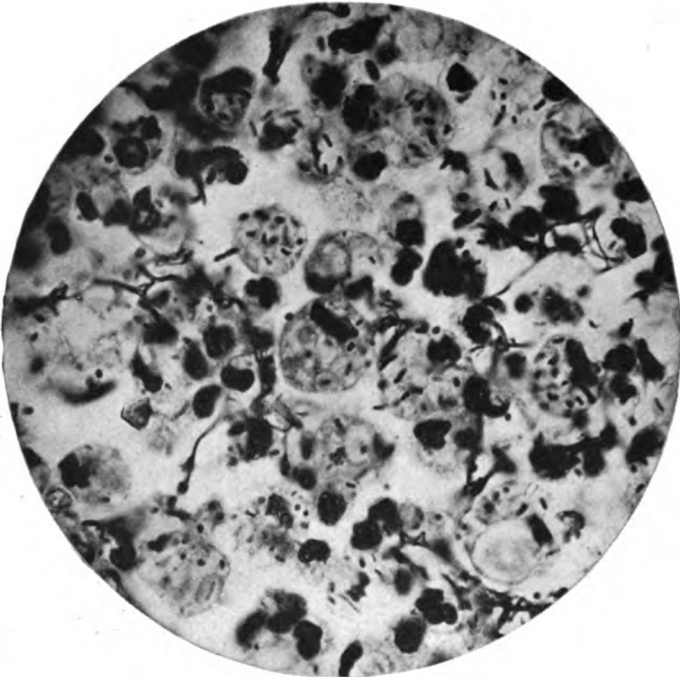


Fig. 365.—Lung. Lobar pneumonia. *Bacillus mucosus capsulatus*. Most of the bacilli are contained within the cytoplasm of polymorphonuclear leukocytes. M.

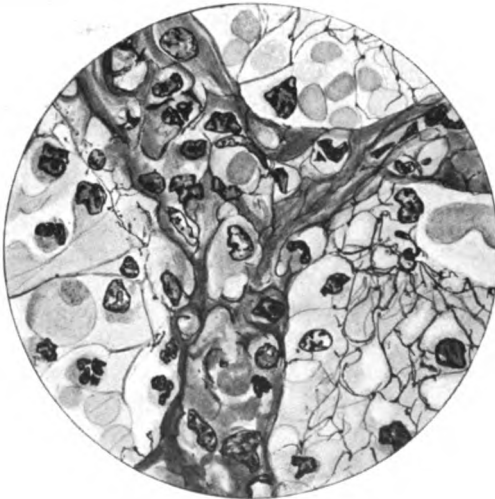


Fig. 366.—Lung. Lobar pneumonia. Necrosis of alveolar wall. Invasion with leukocytes.

Lobar pneumonia is due in most instances to the diplococcus lanceolatus. It may, however, be caused occasionally by the bacillus mucosus capsulatus and possibly, also, by the bacillus typhosus and a few other organisms.

Injury.—In the ordinary case of lobar pneumonia it is not easy to demonstrate any marked injury done to the lung tissue. The inflammatory reaction seems to be chiefly to counteract the organisms and their toxins. Some injury is, however, probably inflicted on the lining epithelial cells so that some of them are injured and destroyed, because mitosis of lining epithelial cells is occasionally found, indicating regeneration. In very toxic cases of lobar pneumonia, however, the injury is more severe

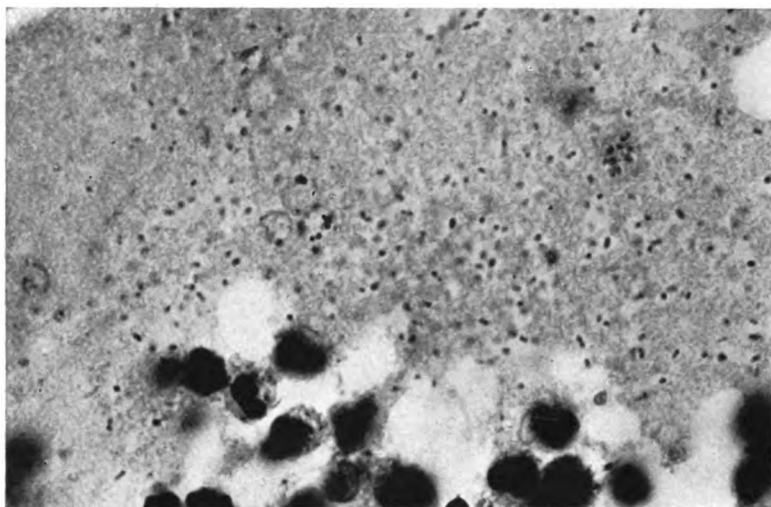


Fig. 367.—Lung. Lobar pneumonia. Diplococcus lanceolatus. The organism is abundant in the serous exudation. M.

and may affect the whole thickness of the alveolar wall, causing necrosis of all the tissue cells and thrombosis of the capillaries. This is of interest in connection with abscesses and organization which not infrequently complicate lobar pneumonia.

Exudation.—In lobar pneumonia due to the diplococcus lanceolatus the number and virulence of the infecting organisms, and the reactions to them, seem to vary considerably. The first noticeable change is engorgement of the capillaries in the walls of the air-sacs followed by an exudation of serum. In some instances serum is abundant, distending the air-sacs, and contains large numbers of diplococci. In other instances the organisms are less numerous and the serum less abundant. Coincident

with the appearance of the serum or immediately following it, polymorphonuclear leukocytes make their appearance in varying numbers, emigrating from the capillaries. They show a marked tendency to incorporate the organisms and often contain them in large numbers. Endothelial leukocytes also appear, usually in comparatively small numbers.

The exudation is almost invariably complicated by the formation of fibrin, usually in large quantities, but sometimes only a little appears, at least in the early stage of infection. The fibrin may be more abundant at first near the alveolar walls, or form out in the middle of the air-sacs. Strands of it may frequently be seen running through minute openings in the alveolar walls and connecting

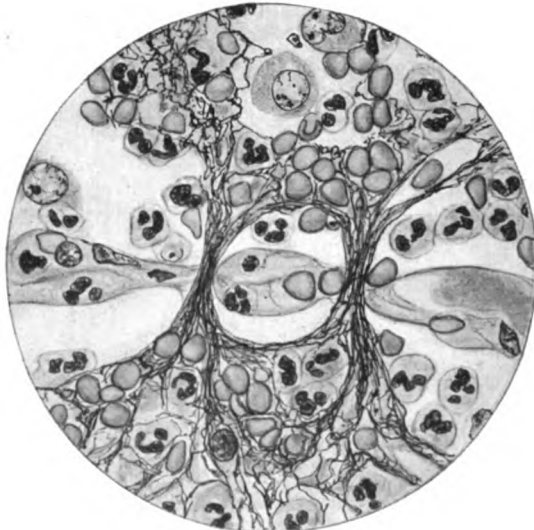


Fig. 368.—Lung. Lobar pneumonia. Fibrin passing through openings in wall between two alveoli.

with the fibrin in the adjoining air-cells. These points of contact with the walls are of interest because it is here that organization of the fibrin starts when resolution does not occur.

The exudation is usually complicated also by more or less hemorrhage from the engorged capillaries. The hemorrhage as a rule occurs in small foci, not diffusely. This early stage of lobar pneumonia characterized by congested vessels and beginning exudation is known as the stage of red hepatization.

As the exudation increases in amount and the fibrin meshwork thickens up the air-sacs are greatly distended, the alveolar walls stretched, and the capillaries compressed so that they

no longer appear engorged. As a result, the redness due to congestion and to some extent to hemorrhage fades and the lung passes into the stage known as grey hepatization.

This condition is followed ordinarily by the stage of resolution, a period during which the leukocytes increase greatly in number, the fibrin dissolves to a greater or less extent under the digestive action of the polymorphonuclear leukocytes, the air-sacs contract and active circulation returns to the capillaries.

Sometimes in the stage of resolution endothelial leukocytes make their appearance in large numbers in the alveoli and often incorporate the polymorphonuclear leukocytes in their cytoplasm. In the lobar pneumonia occurring in typhoid fever endothelial leukocytes are usually very numerous.

Bronchi.—In lobar pneumonia the exudation takes place not only into the air-sacs as already described, but also into the bronchioles and even into the larger bronchi. They are sometimes completely occluded by a dense network of fibrin in whose meshes are varying numbers of leukocytes.

Blood-vessels.—Another lesion not infrequently found in the larger blood-vessels is an exudation of polymorphonuclear and endothelial leukocytes beneath the lining endothelium. It may be only one or two rows of leukocytes in thickness or half a dozen, so that the lumen is much diminished in size. In severe lesions the wall of the blood-vessel may become necrotic.

Lobar pneumonia often does not involve the whole of a lobe. The process starts in one or more foci which rapidly enlarge and fuse. The abundant serous exudation at the beginning may aid in distributing the organisms.

Extension.—On the other hand, lobar pneumonia is never limited to one or more lobes of the lung. It always extends to the adjoining pleural cavity and may extend to the intercostal muscles, to the mediastinal tissues and the pericardial cavity, into the neck, through the diaphragm to the peritoneal cavity, and by extension of the organisms into the lymphatics and blood-vessels to any part of the body.

Lymphatics.—The lymphatics around the blood-vessels and bronchi, in the interlobular septa and beneath the pleura are usually more or less distended, sometimes greatly so, with serum, leukocytes and fibrin, so that those beneath the pleura stand out to the naked eye as white cords.

Gross Appearances.—The exudation distends the air-sacs, hence, except at the beginning and end of the process, the affected lobe is distended to its full capacity. It is firm and dense to the touch owing to the presence of much fibrin. It is distinctly red in the early and late stages on account of the engorgement of the

blood-vessels. On section the fibrinous masses project and the alveolar walls contract; hence the surface appears granular. After resolution begins and the fibrin diminishes in amount, the surface is less granular and on pressure the leukocytes well up on the surface as a purulent fluid. Sometimes the bronchi are filled with a fibrinous exudate as in diphtheritic bronchitis. The pleural lymphatics may be distended with a serofibrinous or fibrino-purulent exudate and stand out like a meshwork made of small cords. The pleural surface is covered with a thin or thick layer of fibrin which may be peeled off easily. In the beginning of the process the pleural surface may be simply clouded.




Fig. 369.—Lung. Lobar pneumonia. Organization. The alveoli are filled with plugs of granulation tissue which are replacing the fibrin formed from the exudation. M.

Organization.—Under certain conditions resolution is incomplete or more or less entirely lacking. The fibrin contracts and thickens up more or less, but the masses in the different alveoli usually remain connected. Sometimes the surface of the fibrin is covered over by epithelial cells. More often the fibroblasts from the alveolar walls grow out into the fibrin, working from the surface towards the center. Usually numerous capillary blood-vessels accompany or precede the fibroblasts. They gradually replace the fibrin from the surface towards the center. The new-

formed granulation tissue, as it gets older, is often infiltrated with numerous lymphocytes.

The organization starts out from the points where the fibrin touches the walls, hence, where it runs through the holes in the alveolar walls; also wherever the alveolar wall is destroyed and fibrin formation has taken place. The empty alveoli and the unoccupied portions of others often contain numerous endothelial leukocytes filled with fat droplets.

Organization occurs not only in the air-sacs but also in the bronchioles and smaller bronchi, which later may be partially to completely filled and occluded by granulation and scar tissue.

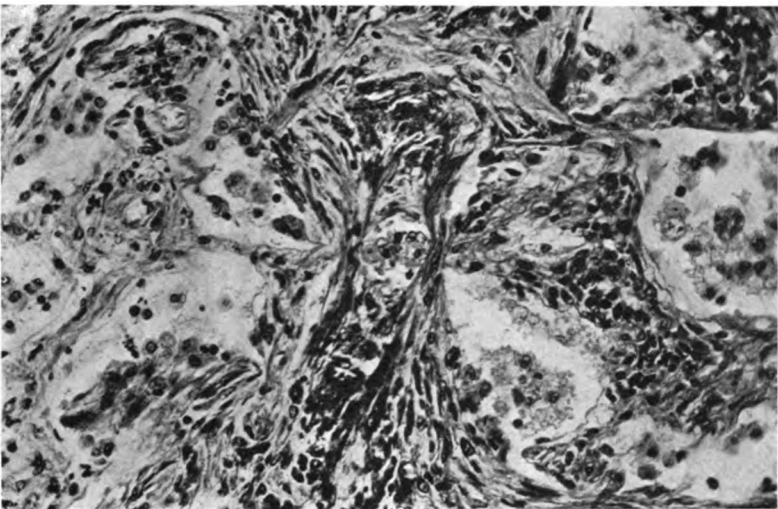


Fig. 370.—Lung. Lobar pneumonia. Organization. The organizing (granulation) tissue is extending through two openings in the alveolar wall, replacing the fibrin which was formerly there. M.

In time the newly-formed granulation tissue contracts. The alveoli and the remains of them are compressed to gland-like cavities lined with cubical epithelium. The new connective tissue may fuse so closely with the alveolar walls that it is difficult or impossible to recognize it after a time, especially if much or all the epithelium has been destroyed. The affected lung tissue may be reduced to dense fibrous tissue with few or no epithelial elements in it.

An organized lobe is usually more or less completely distended, as in the stage of exudation, but it is denser to the touch and does not crush readily. On section the surface is moist and smooth, not granular; it appears greyish or reddish grey and is

usually speckled with yellow due to endothelial leukocytes filled with fat in the remaining alveoli. If all the air-sacs were filled with granulation tissue and the epithelium killed the organized lobe will, in time, resemble dense fibrous tissue.

Abscesses are of frequent occurrence in the lungs, may be acute or chronic in duration, and like lobular pneumonia, may be due to a great variety of organisms. Infection may take place through the bronchi or the blood-vessels. The lesions may be small or extensive and may discharge their contents through the bronchi or rupture into a pleural cavity. They practically always

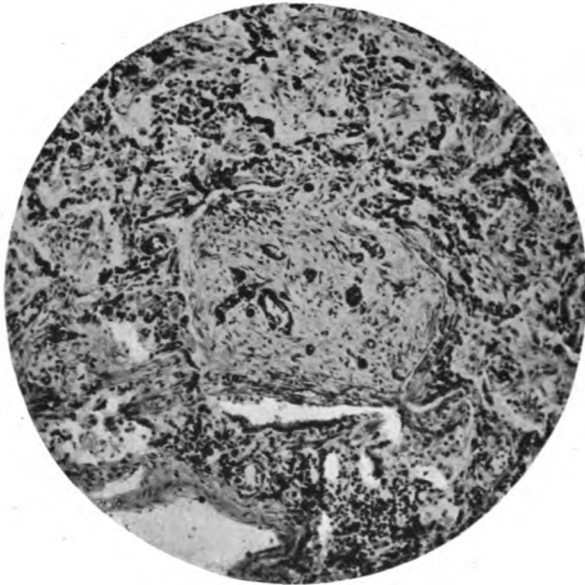


Fig. 371.—Lung. Lobar pneumonia. Organization. Bronchiole filled with a plug of granulation tissue which is attached to the wall at several points. M.

start as a lobular pneumonia in which necrosis and softening quickly take place. Acute abscesses are most often due to the staphylococcus aureus, but may be caused by a variety of other organisms such as the streptococcus pyogenes, the glanders bacillus, the actinomyces, the blastomyces, the ameba histolytica, etc. Chronic abscesses are most often caused by the tubercle bacillus.

Gangrene of the lungs is due to the action of putrefactive organisms usually in combination with pathogenic bacteria. They

cause necrosis and softening of the tissue and an inflammatory exudation. The lesion is really an abscess complicated with putrefaction. It may be embolic in origin secondary to a primary lesion elsewhere in the body, such as the uterus, or due to infection through the bronchi. Gangrene of bronchogenic origin is especially likely to contain acid-fast bacilli and spirochetes in addition to numerous other organisms.

Cavities in the lung may be due to dilatation of bronchi (bronchiectases) or follow an abscess. They are particularly common in tuberculosis, are often multiple, and may be of any size up to that of a lobe. They often contain trabeculæ due to the persistence of bronchi and blood-vessels within them.

Tumors.—The most important primary tumor is the carcinoma which occurs occasionally and arises usually from the cylindrical epithelium of a bronchus. Other primary tumors are rare, for instance, chondroma and osteoma.

Secondary tumors, on the other hand, are comparatively frequent, such as carcinoma of various types, fibrosarcoma, melanoma, etc. They usually reach the lungs through the circulation, but occasionally through the lymphatic system or by contiguity, especially from the mediastinum.

PLEURAL CAVITY

The commonest lesions of the pleural cavity and the most important are those due to infectious agents which gain access chiefly from the lung, but also to some extent from the pericardial and peritoneal cavities and from adjoining tissues. The pneumococcus, the streptococcus, the staphylococcus aureus and the tubercle bacillus are the organisms most frequently found. The inflammatory exudation varies greatly; serum, polymorphonuclear leukocytes and fibrin may be combined in any proportion; endothelial leukocytes, lymphocytes and red blood-corpuscles may be added to them. Putrefactive organisms from a gangrenous focus in the lung may complicate the condition.

Repair of a pleural exudation requires removal of the fluid and leukocytes by absorption or operative interference and organization of the fibrin. Capillary blood-vessels followed by fibroblasts invade and gradually replace the fibrin. They work from both the visceral and the parietal surfaces and eventually meet, if the fibrin is not too thick or if lime-salts are not deposited in it. The lime-salts may eventually be organized by fibroblasts which in consequence become transformed into bone cells.

In a tuberculous pleuritis the process of organization is complicated by the formation of tubercles wherever tubercle bacilli are surrounded by the granulation tissue.

Primary tumors are rare in the pleural cavity. Theoretically the most interesting of these is the carcinoma which arises from the lining mesothelial cells.

Secondary tumors are much more common.

A new-growth in the pleural cavity may appear in the form of small nodules, or as a thick layer covering more or less completely the entire surface. At the same time there always occurs a serofibrinous exudation which is often complicated by hemorrhage.

ORGANS OF DIGESTION

There are a few conditions such as postmortem changes which are common to the entire gastro-intestinal tract, while others, like ulcer, are peculiar to certain parts of it. On this account and in order to save space the subjects more or less common to all parts of the gastro-intestinal tract are presented first.

Postmortem Changes.—From the nature of its functions the gastro-intestinal tract is much more intimately in contact with various chemical substances and pathogenic and especially putrefactive micro-organisms than any other part of the body. During life it is capable of protecting itself from the action of most of these without trouble, but as soon as death occurs they become effective. On this account postmortem changes begin early and progress rapidly. Naturally some parts of the tract are more quickly affected than others. The nuclei of the lining epithelial cells soon lose their power of staining and this condition rapidly extends outwards until the epithelium in the glands and the other cells in the mucosa and finally in the muscle coats are involved in the same way. Desquamation of the lining epithelium and maceration of the mucosa quickly follow. Tissues fixed within an hour postmortem are usually in fairly perfect condition; after that length of time they rapidly deteriorate.

The gastric juice when present in any amount may cause softening of the wall of the stomach (*gastromalacia*) and be followed by rupture and escape of the gastric contents into the peritoneal cavity. The condition is most marked in the fundus along the greater curvature. The secretion also usually flows into the lower end of the esophagus after death, and by its digestive action causes loss of the lining epithelium on the surface of the folds of the mucous membrane. Rarely softening and rupture may take place as in the stomach.

Retrograde Changes.—The retrograde changes in the gastro-intestinal tract are not remarkable.

Atrophy of the glands in the stomach and intestine is often claimed, but difficult to prove. These organs exist under conditions varying from contraction to extreme dilatation. The walls vary in thickness accordingly. Under conditions of dilatation the glands may be shortened and even almost obliterated; the villi shortened and broadened. In consequence the mucous membrane

may appear greatly atrophied. The thickness of the muscle coat is some guide to the condition of dilatation and must always be taken into consideration.

Apparent atrophy may also be due to a previous necrosis of the surface of the mucosa, followed by only partial regeneration of the epithelial glands.

Amyloid is occasionally found in the walls of the blood-vessels, both in the submucosa of the stomach and in the villi in the intestine.

Plasma cells containing hyaline droplets are sometimes quite numerous in the mucous membrane of the stomach and less often in that of the intestine; their significance is not known.

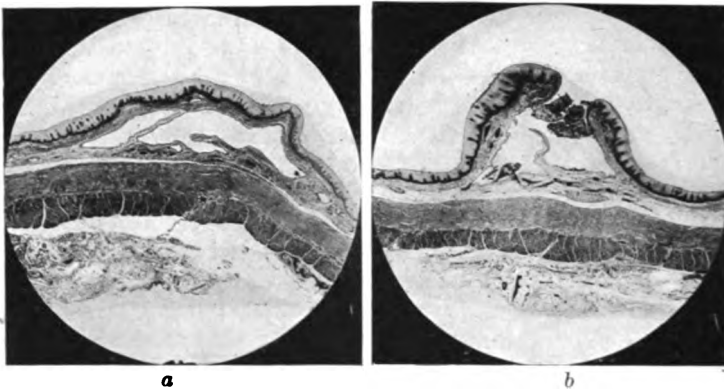


Fig. 372.—Dilatation of esophageal veins secondary to cirrhosis of liver; hemorrhage; death. *a* Dilated veins; *b*, ruptured varix with clot in opening.

Pigmentation is more common in the intestine than in the stomach. Endothelial leukocytes filled with hemosiderin granules are occasionally found, especially in the appendix, and probably point to previous hemorrhage, often perhaps of inflammatory origin.

Disturbances of Circulation.—Acute congestion accompanies many of the acute toxic, and infectious lesions and is often complicated by hemorrhage and occasionally by much edema and thickening of the gastro-intestinal wall. Lesions due to the anthrax bacillus usually show much hemorrhage.

Chronic passive congestion is a common sequence of cardiac insufficiency, but is most marked when cirrhosis of the liver causes obstruction of the portal circulation. It is often accompanied by increased secretion of mucus from the lining epithelium. A frequent result of obstruction to the portal circulation is marked dilatation

of the veins at the lower end of the esophagus and in the cardiac end of the stomach so that varices are formed.

Small hemorrhages may occur as the result of the congestion or of acute inflammation, but multiple minute hemorrhages are often found in the stomach without any good reason therefor being evident. Probably in some instances mechanical conditions such as vomiting or toxic or infectious lesions in the walls of the vessels are the underlying factors.

Large and often fatal hemorrhages arise from erosion of blood-vessels, especially of the varices formed in the neighborhood of the cardiac orifice, both in the esophagus and stomach in obstruction of the portal circulation by cirrhosis of the liver, and of arteries in ulcers of the stomach and duodenum, and of cancers of the stomach.

Obstruction of mesenteric arteries by thrombosis of arteriosclerotic origin, or more frequently by emboli, often but not always causes hemorrhagic infarction of the intestine and the lesion may be very extensive.

Obstruction of the lacteals or lymphatic vessels of the intestine occurs occasionally and may give rise to small cysts filled with fluid in the submucosa. More rarely, a number of vessels in a segment of the intestine or even in an extensive portion of it, may be involved in the same way so that a large, cystic, tumor-like mass is formed. The fat present in the fluid often attracts large numbers of endothelial leukocytes which become filled with it and occasionally fuse to form giant-cells around cholesterol crystals, or other products of fat metabolism.

ESOPHAGUS

The most important lesion of the esophagus is the carcinoma. Varices and ulcer are considered elsewhere. Cancer originates most often at the ends of the esophagus, usually the lower. It may grow rapidly in papillary masses or with more or less ulceration, or slowly in scirrhus form. Histologically the growth may be of the epidermoid or of the glandular type.

STOMACH

Anatomy.—The cells peculiar to the stomach and believed to be intimately concerned with the production of the hydrochloric acid in the gastric secretion are the parietal cells. They are few in the glands near the cardiac orifice, fairly numerous in those of the pyloric end, and abundant in the glands lining the fundus. These cells are irregularly angular in shape and show marked acidophilic staining properties. The other or chief cells lining the glands differ somewhat in the different parts of the stomach, but are in general cylindric in shape and in the cardiac end of the

stomach normally produce mucus, but the mucus has somewhat different chemical properties from that in the intestine. The cells at the base of the glands often contain zymogen granules.

Lesions of Toxic Origin.—Various injurious agents reach the stomach in food and drink or are swallowed with suicidal intent. Their action and consequently the effects which they produce varies greatly. The lesions may be inconspicuous or very striking. In the milder conditions there may be redness, swelling, increase of mucus secretion and sometimes slight hemorrhages. Strong injurious agents may produce intense congestion and marked swelling or necrosis of the surface which may be variously colored.

The commonest poisons are, perhaps, carbolic acid and corrosive sublimate. Others taken occasionally are mineral acids, alkalis, oxalic acid, phosphorus and arsenic. The gross appearances produced vary greatly and are often very striking.

Microscopically, the usual picture is more or less inflammatory exudation in which the polymorphonuclear leukocyte plays a prominent part, occasionally fibrin formation on the surface, and often more or less hemorrhage. The mucosa may be necrotic to a varying depth. Very often death occurs so quickly that there has been no time for an exudation to take place.

Lesions of Infectious Origin.—Infectious lesions of the stomach which can be definitely recognized as such are not common. Most pathogenic organisms which reach the gastro-intestinal tract on the inside pass through the esophagus and stomach and infect some part or other of the small or large intestine.

Very rarely diphtheria bacilli which have been swallowed infect the gastric mucous membrane and cause small patches of necrosis, which become covered with fibrinous membrane formed from the inflammatory exudation. The membrane may spread out laterally for some little distance over the adjoining normal mucosa.

Of more importance are the occasional infections which take place usually through some lesion already present, such as an ulceration, and invade the submucosa, spreading extensively in it and often involving the muscle coats. They may cause marked thickening of the stomach wall. The condition is called phlegmonous gastritis and is usually due to the streptococcus pyogenes.

Acute Gastritis.—While it is possible to divide some of the acute lesions of the stomach into two groups, the toxic and the infectious, others do not admit of such a division because we do not yet know enough about them. They are due to one cause or the other or possibly often to both, but for the present we are obliged to leave them unclassified, except on an anatomic or histologic basis. The mucosa shows more or less extensive infiltration with polymor-

phonuclear leukocytes often combined with necrosis of the mucosa and with fibrin formation. Therefore, acute inflammation is present, but the actual cause is not evident.

Ulceration.—Several different types of ulceration occur in the stomach. The most important is the chronic or so-called round ulcer; the others require study and consideration, however, because without much question it is from an occasional one of them that the chronic form arises.

Repair of lesions in the stomach may take place as readily as elsewhere in the body, but the hydrochloric acid present in its secretion is always capable of proving a disturbing factor, and may

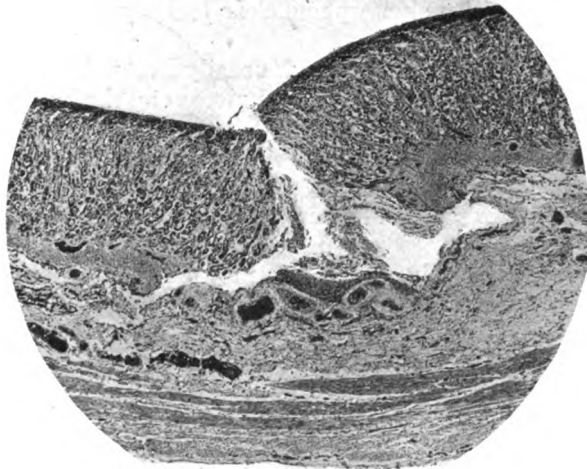

Fig. 373.—Stomach. Slit-like fissure in mucosa opening into more extensive lesion beneath. Case of Dr. L. J. Rhea. M.

become a distinctly injurious agent, preventing repair and causing enlargement of the original lesion.

1. Hemorrhagic erosion is the term applied to an ulceration following a miliary hemorrhage. The lesion is commonly multiple, is most frequent in the fundus, and is usually confined to the mucosa. It is due to ulceration following hemorrhage and necrosis. The inflammatory reaction may be very slight.

2. Acute ulcerations occur most often in the fundus and on the posterior wall, but also occasionally in the region of the pylorus. They are round or oval in shape, vary from a few millimeters to a

centimeter or over in size and have a smooth base and sharp edge. They are superficial but extend deeper than the erosions, often reaching to the submucosa. The edges are usually infiltrated with a few leukocytes and the adjoining tissue is hyperemic. The origin of these ulcerations is disputed, but is probably not always the same. It seems likely that they may follow a variety of toxic and other forms of lesions.

3. Fissures in the mucosa were found in one case examined postmortem by L. J. Rhea. They were recognized only by means of a hand lens. The patient had been operated on for persistent hemorrhage. Nothing was found at the operation except a few bleeding points which were cauterized. Microscopically, the lesions consist of narrow slits which extend through the mucosa and then spread out some distance in the submucosa, where the wall shows an infiltration with polymorphonuclear leukocytes and a deposit of fibrin on its surface.

4. The chronic or round ulcer is usually situated on the posterior wall of the stomach between the pylorus and the fundus and, as a rule, near the lesser curvature, but it may occur on the anterior wall or elsewhere. It is generally solitary but may be multiple. In two instances there were five, two in the stomach and three in the duodenum in one case, and four in the stomach and one in the duodenum in the other.

The ulcer is usually round, but may be more or less oval or irregular. Its edges are sharply defined and often slightly indurated. The base of the ulcer is almost always clean. The sides slope gradually towards the deepest point which may be in the center or at one side and often present, at least in part, a step-like arrangement corresponding to the layers of the stomach wall which have been eroded. As a rule the wall of the ulcer shows but little inflammatory infiltration, but in one instance it was thickly infiltrated with eosinophiles. The tissue lining the ulcer generally exhibits very little reaction on the part of the fibroblasts and vascular endothelium, but in other instances abundant granulation tissue containing numerous capillaries and vessels is present.

The two chief dangerous results to be feared from an ulcer are hemorrhage owing to erosion of a blood-vessel, and perforation from extension of the lesion through the wall of the stomach.

Repair by scar formation may take place, but in turn prove dangerous by causing stenosis if the ulcer is near the pylorus.

Chronic ulcers similar to those in the stomach and due to the same causes occur in the duodenum and also rarely at the lower end of the esophagus.

Tumors.—The most common and important tumor of the stomach is the carcinoma. It may grow in gland form or in solid

masses and either type of growth may give rise to colloid formation, partly as a secretion, partly as a retrograde transformation of the tumor cells. The carcinoma may grow rapidly and project in papillary, cauliflower-like masses into the lumen of the stomach, or it may undergo more or less extensive ulceration. Frequently it grows slowly in scirrhus type and forms a local induration, or spreads gradually until the entire wall of the stomach is involved and contracted to a small part of its normal dimensions.

In one instance the stomach by infiltration with a colloid carcinoma was transformed into a large sac with transparent walls three to four centimeters thick.

The next most common tumor of the stomach is the leiomyoma which, under rare conditions, grows rapidly and gives rise to metastases.

INTESTINE

Toxic Lesions.—Various toxic substances unquestionably reach the intestinal tract and act injuriously, but to distinguish the lesions caused by them with certainty from some types of infectious lesions is difficult or impossible, unless the clinical history or a bacteriologic examination throws light on the subject. Most of them have to be grouped, for the present at least, on an anatomic basis as acute enteritis and colitis of unknown toxic or infectious origin.

Corrosive sublimate is one definite toxic substance which sometimes causes an intense colitis and occasionally enteritis, apparently owing to the fact that it is passed along quickly through the gastro-intestinal tract until it reaches its lower end, where it causes necrosis of all the projecting portions of the mucous membrane and acute inflammatory exudation. In the small intestine the edges of the valvulæ conniventes in the lower part of the ileum may be affected in the same way.

Certain toxins in the circulation, especially in diphtheria, may cause proliferation of the endothelial cells in the lymph-nodules of the intestinal tract, just as in the spleen and elsewhere. The endothelial cells are often filled with the débris of ingested lymphocytes. In consequence of these changes the lymph-nodules often appear swollen and prominent.

Lesions of Infectious Origin.—A great variety of infectious lesions occur in the intestine. Some are very characteristic of the infectious agents which produce them; others have to be classed anatomically as acute enteritis or colitis, except in those instances where the micro-organism can be definitely determined by bacteriologic methods. This is the case, for example, with the dysentery group of organisms. The clinical history and the bacteriologic

results are much more important and characteristic than the pathologic appearances.

Most of the infectious lesions of the intestine have already been considered under the different infectious agents. They will, therefore, be mentioned but briefly here.

The inflammatory exudation in the intestine is commonly complicated by an excessive production of mucus by the epithelial cells when they have not been destroyed. On this account the term catarrhal enteritis is in common use. The point to bear in mind is that the actual inflammatory exudation is just the same as in any other organ, under like conditions.

The gross appearance presented by the intestine, but especially by the colon in acute dysentery, varies from a normal looking mucosa to one which is deeply injected and edematous with occasional small hemorrhages. If the process has existed long enough the surface of the mucosa, at least in the projecting parts, shows more or less necrosis: deep necrosis and ulceration do not occur, only superficial erosions.

In another type of infectious enteritis and colitis the necrosis of the mucous membrane along the edges of the *valvulæ conniventes* in the small intestine and on the surface of the folds in the colon is more extensive, and is covered with a fibrinous layer which also extends into the mucosa and binds the cells together. Later this diphtheritic membrane sloughs, often leaving more or less extensive ulcerations.

The etiology of diphtheritic enteritis and colitis of infectious origin has not been fully worked out. Probably some of the ordinary infectious organisms such as the *streptococcus pyogenes* are the usual causal agents.

Aside from the bacillary forms of dysentery, the most characteristic infectious lesions of the intestinal tract are due to the typhoid and tubercle bacilli, the *ameba histolytica*, and in rare instances the *balantidium coli*. Infections due to the *treponema pallidum* and the *actinomyces* sometimes occur. For a description of the lesions produced the section on infectious agents should be consulted.

Appendicitis.—Appendicitis is an acute infectious process more important from the anatomic than from the etiologic point of view. The common acute type of lesion is due to a Gram-positive coccus, probably the *streptococcus pyogenes*. It starts as a small area of infection in the mucosa. There is necrosis and loss of epithelium and an infiltration with polymorphonuclear leukocytes, together with fibrin formation. The process spreads rapidly, especially in the submucosa and in the muscular coats and may extend to the peritoneal covering. Other areas in the mucosa become in-

volved, but the intervening portions may appear normal or nearly so, although the lumen may be full of pus. A layer of fibrin is often formed on the peritoneal surface of the appendix.

The lesion may heal at this stage or continue. If it persists miliary abscesses are formed in the appendix wall and may perforate within the lumen or without and give rise to localized or general peritonitis.

The distal end of the appendix may be swollen, distended and occasionally gangrenous. The meso-appendix may show considerable involvement.

Repair under natural conditions depends on the severity of the lesion. The appendix may be restored practically to the normal condition or be reduced to a fibrous cord. All intervening degrees occur. Partial or complete stenosis of the lumen by scar formation may lead to physiologic disturbances and clinical symptoms. During repair the appendix is often infiltrated with numerous eosinophiles and the lymph-vessels filled with lymphocytes. The appearance presented by appendices in the various stages of repair is often spoken of as chronic appendicitis, but the term is not justified.

Pin worms filling the appendix may cause a mild type of chronic appendicitis but the condition is rare. So also is tuberculous inflammation, but the possibility of this condition must be borne in mind.

Tumors.—The epithelial tumors are the most important new-growths originating in the intestinal tract.

One group of them is difficult to classify. It is composed of epithelial, gland-like structures which occur both in the small and large intestine and may be multiple. They usually lie in the mucosa, but may be elevated on a stalk. The glands usually differ from those of the normal mucosa and may dip into the submucosa and into lymph-nodules, or even reach to the serosa. They are usually classed as polyps and regarded as benign structures, probably of congenital origin; but carcinomas unquestionably sometimes arise from them. Apparently related to these structures are other epithelial growths occurring in the small intestine and more often in the appendix. They have all the appearance of a carcinoma, both in structure and in the way they are disposed in the muscle and other coats. Those in the appendix frequently occur in young people and children and are found at operations for appendicitis. The tumors show no evidence of active growth and do not give rise to metastases, although malignant tumors may arise from them. They are probably best regarded as congenital anomalies analogous to the vascular and pigmented nevi of the skin.

Primary cancer of the intestine occurs most commonly in the rectum, in the ileocæcal region and in the papilla of the common

bile duct. The tumors closely resemble those in the stomach; the adenomatous type is the most common and colloid formation of frequent occurrence. Cancer often encircles the intestine and causes stenosis.

Of the other types of tumor the lymphoblastoma stands next to the carcinoma in frequency of occurrence and in importance.

PERITONEAL CAVITY

Infectious lesions of the peritoneal cavity are much like those in the pleural and pericardial cavities and the reaction may be serous, fibrinous, purulent or hemorrhagic in type. The exudation may be slight or abundant in amount and the coils of intestine glued together by fibrin or floating free in serum. The usual infecting agents are the ordinary pus cocci and the tubercle bacillus, and in addition, the colon bacillus and occasionally the gonococcus. Acute peritonitis is most often secondary to appendicitis, but it may follow lesions of the intestine, stomach, uterus, oviducts and other organs.

Organization of the fibrinous exudation usually results in multiple adhesions which may more or less completely obliterate the peritoneal cavity. Sometimes, as in the pericardial and pleural cavities, mesothelial cells left behind may line any cavities present in the adhesions and form gland-like cavities, or even cysts of all sizes so that a cystic tumor-formation is strongly suggested.

Tuberculosis of the peritoneal cavity is a common lesion. It may appear in the form of miliary tubercles or of a serofibrinous exudation, or of a varying combination of the two. The fibrin leads to organization just as in the pleural cavity.

Primary tumors of the peritoneal cavity are rare. The most important is a form of carcinoma arising from the mesothelial lining.

The secondary tumors are common and mostly carcinomatous in character following primary tumors in the stomach, intestine, gall-bladder, ovaries, etc.

LIVER

Introduction.—The liver is a large, important organ composed chiefly of parenchymatous cells which are easily injured. Fortunately, as a rule, they easily regenerate. The cells are liable to various retrograde changes. Lesions of mechanical origin are comparatively infrequent. On the other hand, toxic lesions are common. Lesions of infectious origin, outside of tuberculosis and syphilis, occur only occasionally. All three classes of lesions may terminate in sclerosis of the liver and, by contraction of the connective tissue around the bile ducts and blood-vessels, cause jaundice and ascites.

Metastatic tumors play a much more important rôle than primary new-growths.

Anatomy.—The structure of the lobule adopted in this book is the one generally used, which places the portal vessels at the periphery and the branches of the hepatic vein in the center.

Postmortem Changes.—A common microscopic postmortem change is the separation of the liver cells from each other. Whenever the hemoglobin is fixed in the red blood-corpuscles, the liver cells will usually be found well preserved.

If bacteria develop in the liver postmortem, the nuclei of the liver cells in their immediate neighborhood will usually be found to have lost their staining properties. Gas bubbles point to the

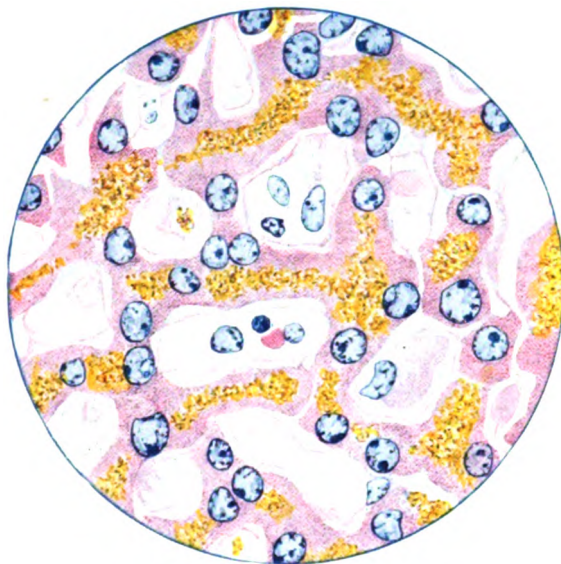


Fig. 374.—Brown atrophy of liver cells.

presence of *B. aërogenes capsulatus* which usually can be found in numbers in the surrounding tissues, without any evidence of inflammatory reaction having been produced.

Atrophy.—The liver may be atrophied as a whole from diminution in the size of its elements, or from disappearance of many of its cells without regeneration, as sometimes occurs in central necrosis, especially when complicated with chronic passive congestion.

In old age atrophy is often combined with apparent increase of pigment in the cells; hence the term brown atrophy. Around rapidly growing tumors the liver cells are often greatly compressed and atrophy as a consequence (pressure atrophy).

Albuminous Granules.—The albuminous granules often seem to be increased in number in the liver cells. Whether this appearance is of postmortem origin or due to changes of metabolism as the result of infection and high temperature is difficult to determine. Similar changes may occur focally at the edge of advancing lesions such as abscesses, or in the cells undergoing necrosis in central and focal necroses.

Occasionally from some unknown cause, the granules may be partially or entirely absent from the cytoplasm. When large patches of cells are thus affected the liver appears studded with light areas of various sizes. One such case followed severe injury

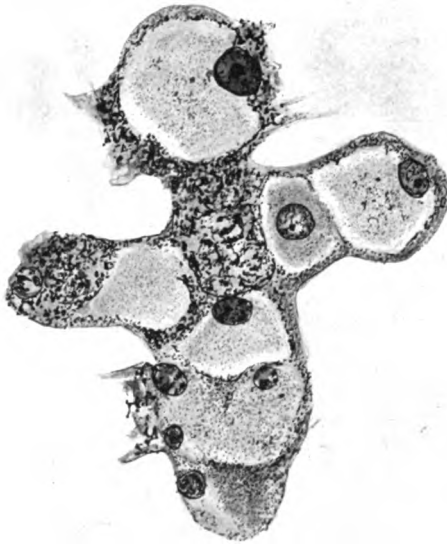

Fig. 375.—Liver. Loss of granules in liver cells; cause unknown.

resulting in death and may have been due to some form of coagulation, although the nuclei of the cells seemed fairly normal.

Hydrops.—Fluid may collect in liver cells and form vacuoles. This condition is of common occurrence in the early stages of central necrosis. The vacuoles in sections appear as if due to fat, but each contains a hyaline ball which stains like fibrin. At a later stage, threads and networks of fibrin may appear.

Fat.—Fat in liver cells is of common occurrence. It ordinarily appears in two distinct forms, as large drops and as small droplets; however, drops of intermediate sizes often occur.

The large drops of fat are associated with no impairment of the functional activity of the cells. The fat is simply in excess of the normal daily needs and is stored up in the cytoplasm of the cells, where it usually collects in large drops. This form of fat deposit is commonly termed fatty infiltration. It accompanies high living, especially indulgence in alcohol; but also occurs in tuberculosis of the lung owing to diminished oxidation. The large fat drops are usually grouped around the portal vessels, but may be located instead around the hepatic vein or in the midzonal region. Occasionally they are fairly evenly distributed throughout the whole lobule.

Fat in fine droplets is associated with impaired function of liver cells; hence it is found in many toxic and infectious processes and is present especially in the degenerating cells in central and focal necroses. The fat is not due to the transformation of albuminous material into fat as formerly taught, but is fat brought to the cells as under normal conditions and not used up owing to faulty metabolism. Hence the term, fatty degeneration, generally applied to the process is incorrect because it implies a wrong relation between the cells and the fat. On the other hand, the presence of small fat-droplets in cells where fat is not ordinarily present is, perhaps, the surest guide to the fact that the functional activity of the cell is impaired.

Glycogen.—Glycogen is present normally in the liver; the amount varies, depending on the stage of digestion. It is increased in amount in the livers of diabetics, occurring in granules and droplets in the cytoplasm of the liver cells and sometimes in the nuclei. As it requires special methods of fixation and staining it does not make itself evident in ordinary sections except when so abundant as to give the cytoplasm a vacuolated appearance.

Hyalin occurs in liver cells in alcoholic cirrhosis and forms an irregular, coarse meshwork. Later the cells undergo necrosis and are invaded by leukocytes. This form of hyaline change seems to be characteristic of the alcoholic type of cirrhosis.

In central and focal necroses of the liver the cells after necrosis appear homogeneous and hyaline, and stain deeply with acid dyes.

Necrosis.—Liver cells are easily injured in various ways, consequently necrosis is of frequent occurrence. It is most often of toxic origin as in central and midzonal necroses and around certain bacteria, but may be due to interference with the circulation as in the typhoid lesions and in miliary tubercles.

Necrosis may affect single cells, or small or large groups of them. It may be preceded by increase in the number and size of the albuminous granules, by the presence of fat-droplets, or of vacuoles containing fluid, or by hyaline degeneration as in alco-

holic cirrhosis. After complete necrosis the cells are usually homogeneous and stain deeply with acid dyes. They are removed by the digestive action of the polymorphonuclear and endothelial leukocytes.

Amyloid.—Amyloid is rare in the liver unless the kidneys and spleen are also involved. When much of this substance is present the organ is enlarged and firm with rounded edges. Smaller amounts may readily be overlooked. Focal deposits of amyloid in the liver are very uncommon but do sometimes occur.

The amyloid appears first in the walls of the arteries. Later, it is more or less uniformly distributed throughout the organ around the connective-tissue cells and fibrils, between the liver cells and

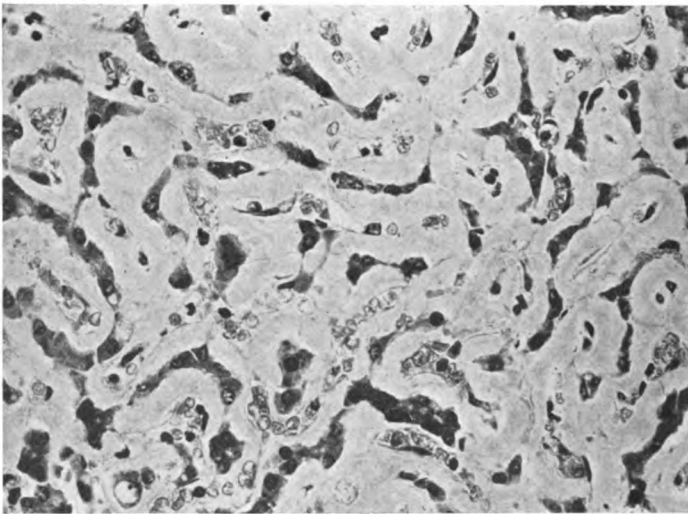


Fig. 376.—Amyloid formation in liver. Marked atrophy of liver cells from pressure. M.

the endothelium lining the sinusoids. The liver cells become more and more compressed and finally disappear. The lumina of the sinusoids are also gradually encroached upon.

By means of the anilin blue stain the collagen fibrils at first may be demonstrated in the midst of the amyloid, but later they disappear. On the side towards the liver cells the amyloid often presents a feathery appearance.

Pigments.—Various kinds of pigments occur in the liver. Here they need be mentioned only briefly.

1. The brownish yellow, finely granular pigment which occurs normally in the liver cells, especially in the center of the lobule, gives no iron reaction, and may be increased in amount with age.

2. Bile pigment from obstruction of bile ducts. In general bile stasis, it is located around the hepatic vein in the center of the lobule, chiefly in the dilated bile capillaries near the hepatic veins, but also in endothelial leukocytes between the liver columns and the walls of the sinusoids. Less often it is found as granules and small elongated masses in the cytoplasm of liver cells. When the bile stasis is focal, as in the different forms of cirrhosis, the inspissated bile may be in any part of the lobule or even in the bile ducts.

3. Blood pigment, hemosiderin, may be derived from extensive hemorrhage anywhere in the body, but is most abundant in pernicious anemia and especially in the condition known as hemochromatosis. It occurs as yellowish and brownish granules in the liver cells and bile duct epithelium, and as brownish masses in the endothelial cells lining the sinusoids and in endothelial leukocytes which migrate into lymph-spaces and vessels, especially in the periportal connective tissue.

4. Melanin, formed by the malarial parasites within red blood-corpuses, occurs as black granules in the endothelial cells lining the sinusoids and occasionally in endothelial leukocytes free in the sinusoids, and also collected in small numbers in the periportal connective tissue.

5. Carbon is occasionally carried to the liver by endothelial leukocytes which migrate with it, usually to the connective tissue around the portal vessels.

6. Argyria. Very rarely as the result of treatment with silver salts, precipitated silver is found in the liver, almost exclusively in the walls of the branches of the portal vein.

Regeneration.—Regeneration of liver cells is of common occurrence. A half or more of all the liver cells may be killed and they may all be regenerated in two weeks time (central necrosis, acute yellow atrophy.) In alcoholic cirrhosis mitotic figures occur alongside of other liver cells undergoing hyaline degeneration and necrosis. The finding of numerous mitotic figures, as sometimes occurs, in an otherwise normal looking liver suggests that there has been a previous fairly extensive necrosis of liver cells.

CIRCULATORY DISTURBANCES

Congestion.—Acute congestion of the liver leads to dilatation of the sinusoids around the hepatic veins, so that the centers of the lobules appear hyperemic and conspicuous and the liver as a whole may be enlarged. As a result of the distended sinusoids the intervening liver cells are narrowed and elongated. If the liver cells around the hepatic veins are infiltrated with fat the congestion is confined to the midzonal region because the cells containing fat are not easily compressible.

Chronic Passive Congestion.—Owing to cardiac and other lesions which interfere with the normal circulation congestion of the liver is a condition which often persists for months and years. It is usually taught that under these circumstances the liver cells around the hepatic veins disappear as a result of pressure and malnutrition, although in the adrenal and other organs back pressure does not cause important functioning cells to atrophy. In a certain proportion of livers, however, the liver cells do not disappear; they may be stretched and thinned, but remain otherwise perfectly preserved, even after years of cardiac insufficiency. The reason is that the liver cells disappear, not as the result of pressure, but of a complicating lesion, namely, toxic necrosis, a relatively common lesion of the liver as will be shown later. This form of necrosis affects the cells around the hepatic veins. Under ordinary conditions the liver cells are usually quickly regenerated, but in chronic passive congestion regeneration does not take place. This is due, perhaps, to the fact that the necrosis under these conditions is always of the hemorrhagic type.

In many livers the necrosis has occurred only a short time before death. It is then easy to demonstrate the necrotic cells in the midst of the hemorrhage which so distends the trabecular spaces (that is, the spaces normally filled by the columns or trabeculae of liver cells) that the sinusoids are compressed. If the liver cells, as often happens, have completely disappeared, then the trabecular spaces filled with blood are usually mistaken for dilated sinusoids, while the latter being compressed are entirely overlooked.

Gradually the blood in the trabecular spaces is removed by the action of endothelial leukocytes which become filled with pigment and remain behind for a long time: the sinusoids again dilate, the connective tissue contracts, and the liver shrinks. The result is a small, dense, indurated liver showing microscopically in each lobule a slight central sclerosis.

If the cells around the hepatic veins are infiltrated with fat the disappearance of liver cells may be confined to the midzonal region. Occasionally a liver will show disappearance of the liver cells in the centers of the lobules with a recent necrosis in the midzonal region.

Hemorrhage.—Two types of hemorrhage are found in the liver; in one the blood escapes passively and uniformly; in the other it is forced out under pressure.

Necrosis of liver cells in cases of chronic passive congestion is always complicated with hemorrhage which is usually limited to the areas affected, either the center of the lobule or the midzonal region. Very rarely it may be more extensive and involve entire lobules so that large hemorrhagic areas are formed.

In eclampsia, to be spoken of again, the hemorrhages vary greatly in extent, but they always start in the region of the portal vessels and the blood is driven under pressure into the liver cells, often disrupting them.

Infarction.—Infarctions in the liver from obstruction of branches of the hepatic artery are very rare.

Edema.—In edema the fluid collects between the liver columns and the walls of the sinusoids, causing more or less compression of the latter. In fixed tissue the only evidence of the edema is finely granular material, the coagulated albumin, left behind.

Edema may cause considerable enlargement of the liver, 1950 grams in one case.

MECHANICAL LESIONS

Bile Stasis.—When the outflow of the bile from the liver or any part of it is prevented the bile ducts and capillaries back of the obstruction become distended, often to a marked degree. If the obstruction affects the common bile duct a uniformly distributed general bile stasis occurs. If small bile ducts here and there are blocked then a focal bile stasis results. General bile stasis is usually caused by a calculus in the common bile duct or by a cancer involving it. Focal bile stasis is common in different forms of sclerosis of the liver, where it is due to constriction of bile ducts by contracted connective tissue; and in infectious processes extending along the bile ducts, where the inflammatory exudate present more or less prevents the escape of the bile.

When general bile stasis exists, unless the liver is hardened *in toto*, the bile quickly escapes from the dilated bile ducts and also from the bile capillaries near the portal vessels as soon as the organ is sectioned, and these vessels contract. As a consequence, on microscopic examination after fixation the bile is found, as a rule, only in the bile capillaries around the hepatic veins. In focal bile stasis, however, the bile ducts are occasionally found distended with bile.

On microscopic examination of the liver, in which general bile stasis has existed, the bile is found in masses distending the bile capillaries around the hepatic veins. It also occurs as a fine meshwork where secreted within the cytoplasm of the liver cells, being unable to flow out into the bile capillaries. It collects in the form of granules and small irregular, usually elongated masses, and mechanically or chemically often leads to necrosis of the affected cells. Occasional mitotic figures show that regeneration of the liver cells may take place. Microscopic evidence certainly favors the view that it is chiefly the liver cells around the hepatic

veins in the inner half or less of the lobule, which are concerned with the secretion of bile. The cells around the portal vessels never show the same changes.

If the obstruction is complete and persistent, the inspissated bile frequently breaks through the wall of the liver cells surrounding it and escapes into the lymph-space lying between the rows of liver cells and the walls of the sinusoids. Here the masses of bile are taken up by endothelial leukocytes, which migrate into the space, and are gradually dissolved. Frequently in small areas the endothelial leukocytes outnumber the liver cells.

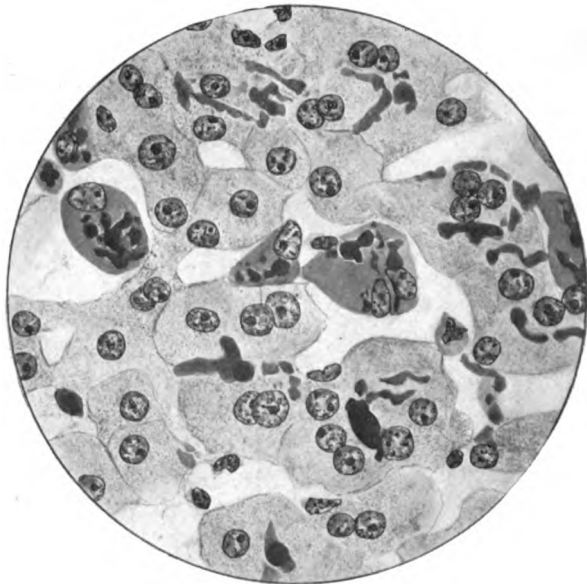


Fig. 377.—Liver. Bile stasis. Inspissated bile in dilated capillaries; also within endothelial leukocytes.

The presence of occasional pigmented endothelial leukocytes in the lymph-channels around the portal vessels indicate that a little, at least, of the dissolved bile enters the circulation in that way. On the other hand, the endothelial cells lining the sinusoids are usually pigmented only in the neighborhood of the hepatic vein, where the inspissated bile escapes from the bile capillaries and is dissolved by the action of endothelial leukocytes. This relation of escaping bile and pigmented endothelial cells suggests that a part at least, perhaps most, of the bile enters the circulation directly by osmosis through the endothelial cells lining the sinu-

soids. This view is favored by recent experimental work on dogs which shows that the bile does not enter the circulation through the thoracic duct.

Some of the masses of bile in the bile capillaries and in the cytoplasm of the liver cells may be set free by necrosis of the cells, but apparently no extensive necrosis of liver cells is caused simply by the bile being dammed back, and no sclerosis around the hepatic veins results.

On the other hand, no lesion of any sort is formed in the region of the portal vessels from simple uncomplicated bile stasis. If infection of the bile ducts occurs, however, a very different appearance is caused, as will be described later.

In focal bile stasis the cell changes due to the distention of the bile capillaries are similar to those already described, but may occur in any part of a lobule or throughout it in the areas affected.

As a result of general stasis of bile around the hepatic veins, the centers of the lobules appear yellowish green to dark green on section, in more or less well marked contrast to the lighter stained peripheries.

In focal bile stasis the affected areas stand out distinctly of a dark green color.

Hemochromatosis.—In the pathologic condition known as hemochromatosis, the liver cells often contain much pigment in the form of granules which give the reaction for hemosiderin. The cause of the pigmentation is not known. In addition, numerous endothelial leukocytes filled with blood pigment collect often in large numbers in the lymphatic spaces and vessels of the liver, chiefly around the portal vessels, but also to some extent around the hepatic vein, and irregularly throughout the lobule between the liver cells and the walls of the sinusoids. When this process is extensive it leads to the production of a large, smooth liver which weighed, in one instance from a woman, 2500 grams. In time, more or less of the pigment is changed and dissolved by the endothelial leukocytes which then disappear leaving dense fibrous tissue in places more or less free of pigment. By contraction of this fibrous tissue later, a certain amount of injury is probably caused to the liver cells. The end result is marked sclerosis of the liver characterized by more or less pigmentation. The nature of the lesion is not yet understood; it may be mechanical as here intimated or it may be toxic.

Carbon.—Very rarely carbon is transported to the liver, probably in endothelial leukocytes. It is carried by them into the lymph-spaces and vessels, especially around the portal vessels, in the same way that blood pigment is, in hemochromatosis. The result is the same, a sclerosis of the liver, due apparently to

mechanical causes. Very rarely this deposit of carbon with resulting sclerosis is sufficient to deserve the designation of cirrhosis.

TOXIC LESIONS

Introduction.—Lesions of toxic origin probably play a more important part in the pathology of the liver than in that of any other organ. The toxins are of various origins, but chiefly derived from bacteria, although some other substances such as alcohol seem to play an important rôle. They lead to a variety of retrograde changes in the liver cells of which the most marked and characteristic is necrosis. As a result necrosis of liver cells is an important lesion and may give rise to striking gross and microscopic pictures.

Necrosis may affect single cells, clumps of cells, or definite small and large areas of them. Hemorrhage frequently complicates the necrosis and masks the essential lesion.

Some necroses are recognized and named as such (central, midzonal, focal necroses): others occur in processes which are best known under clinical names and often pass unnoticed because secondary features are more prominent (acute yellow atrophy, alcoholic cirrhosis). Strangely enough these lesions, which are perfectly analogous to inflammatory lesions of other organs, are rarely classed under the term acute and chronic hepatitis where they rightfully belong.

Central Necrosis.—Necrosis of liver cells in a definite area surrounding the hepatic vein in every lobule is a common lesion. The term central necrosis has been applied to it. This form of necrosis is clearly toxic in origin and follows infection with a large variety of micro-organisms, but especially with the streptococcus pyogenes and the pneumococcus.

Necrosis around the hepatic veins is often very extensive, so that only a few rows of liver cells are left intact immediately around the portal vessels. In other cases the lesions are slight and may affect the cells uniformly around every hepatic vein, or only large or small areas of them on one or more sides of the vein. By their form and grouping they may suggest focal necroses, but unlike these lesions they never abut on the portal vessels.

This type of necrosis of liver cells is frequently preceded by hydropic degeneration. Small vacuoles, often many in number, form in the cytoplasm of the affected cells and suggest spaces occupied in life by fat, but in each vacuole is a minute hyaline ball; later fibrin threads and even occasionally fibrin networks appear. Then the albuminous granules disappear, and the cytoplasm becomes homogeneous and stains intensely with eosin.

The nucleus at first stains uniformly and deeply with nuclear dyes, and then disappears.

The necrotic cells soon separate from each other. As a result of the necrosis and accompanying it an acute inflammatory exudation, consisting of serum and polymorphonuclear or endothelial leukocytes or of both, takes place into the trabecular spaces. The leukocytes invade the necrotic liver cells and bring about their dissolution and disappearance.

Central necrosis is usually a terminal lesion, that is, it occurs shortly before death, but if the patient recovers the cells gradually disappear, regeneration of the liver cells as a rule occurs, and the trabeculae of liver cells are completely restored in from one to two weeks so far as can be judged from the study of similar lesions produced in animals by chloroform inhalation. Occasionally human

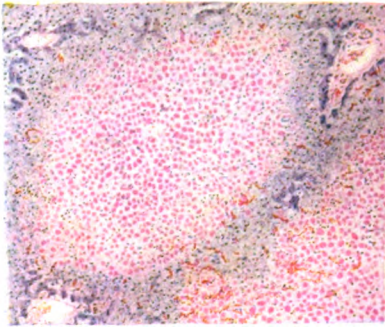


Fig. 378.—Extreme degree of central necrosis of liver.

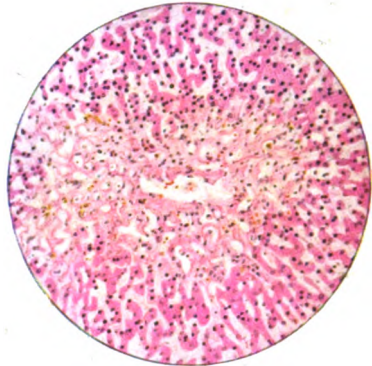


Fig. 379.—Healed central necrosis of liver without regeneration of liver cells.

cases come to autopsy in which active regeneration is evidenced by numerous mitotic figures in the liver cells at the edge of the necrosis.

Rarely this type of necrosis of liver cells is limited to a zone of varying width, sometimes narrow, sometimes broad, between the hepatic and portal vessels, the so-called midzonal necrosis. This type of lesion seems to be due, at least in some instances, to fatty infiltration of the liver cells around the hepatic vein, which in some cases, not in all, enables the cells better to resist the toxemia to which the others succumb.

The gross appearances of central necrosis are not striking; the degenerated areas appear yellow and opaque. Marked cases suggest fatty infiltration around the hepatic veins. If congestion is present the lesion may be entirely masked; washing off the blood usually renders it visible.

Central necrosis is followed by no reaction on the part of the connective-tissue cells. If, as rarely happens except in chronic passive congestion, regeneration does not take place, the center of the lobule collapses, the trabecular spaces are obliterated except for the presence of a few pigmented endothelial leukocytes, the

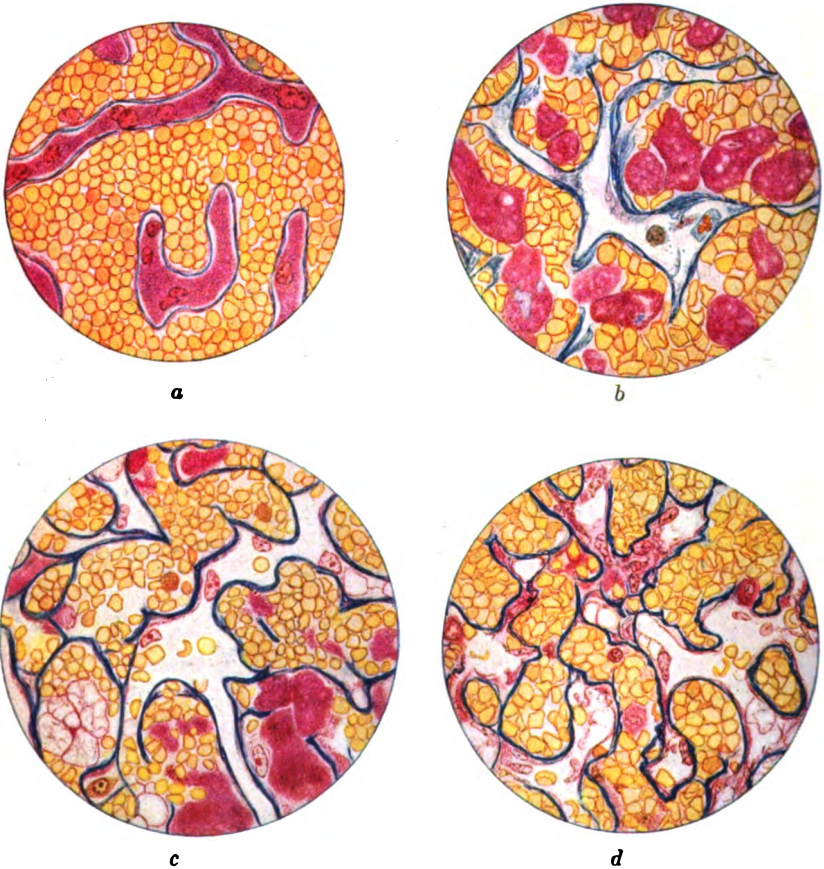


Fig. 380.—*a*, Simple chronic passive congestion of liver; *b*, central necrosis of liver complicated by hemorrhage in consequence of chronic passive congestion; sinusoids almost empty; *c*, sinusoids almost empty; necrotic liver cells beginning to disappear; *d*, sinusoids almost empty. Necrotic liver cells have disappeared. Their place is occupied by red blood-corpuscles.

lobules shrink, the connective tissue contracts and thickens up, and the liver as a whole may suggest a slight uniform cirrhotic process.

Fibrin sometimes forms in the trabecular spaces around the

necrotic cells. More often it appears in the sinusoids as thrombi secondary to the necrosis of the cells.

Central Necrosis with Hemorrhage.—In cases of congestion, especially of the chronic passive type, a necrosis occurring around the hepatic veins is usually complicated by a uniformly distributed hemorrhage into the trabecular spaces around the separated necrotic liver cells. As a result of the hemorrhage the distended trabecular spaces strongly suggest dilated sinusoids. This is particularly true when the necrotic cells have more or less completely disappeared. As a matter of fact the sinusoids are usually compressed as a result of the hemorrhage. Midzonal necrosis may be complicated with hemorrhage in the same way.

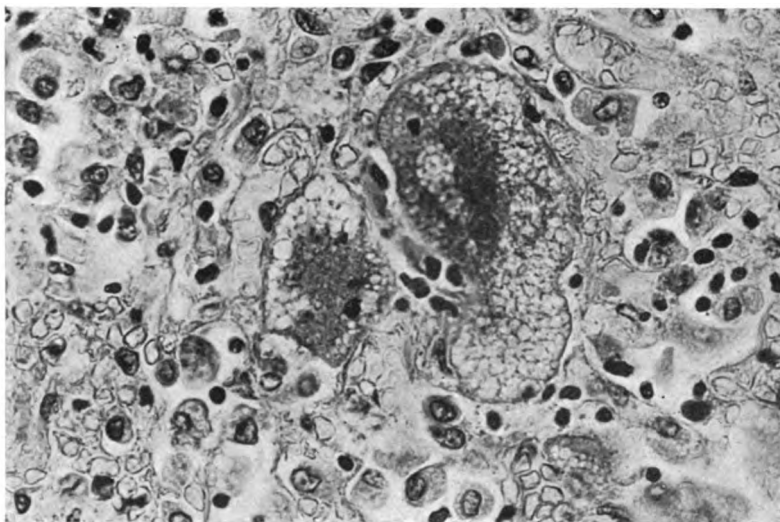


Fig. 381.—Liver. Acute yellow atrophy. Two or three liver cells containing fat present. Many endothelial leukocytes in spaces formerly occupied by liver cells. M. and B.

The hemorrhagic type of necrosis may be suspected, but is not readily recognized at the autopsy table. If the necrotic cells are still present the centers of the lobules on section are not depressed, and on washing off the blood the surface may appear yellowish and opaque. Microscopically, this form of necrosis has in the past been commonly overlooked.

Acute Yellow Atrophy.—In certain cases of central necrosis the process may be so extensive as to kill every liver cell over a large area. Only the bile ducts, the blood-vessels and sinusoids, and the connective tissue are left intact. If the patient lives for a

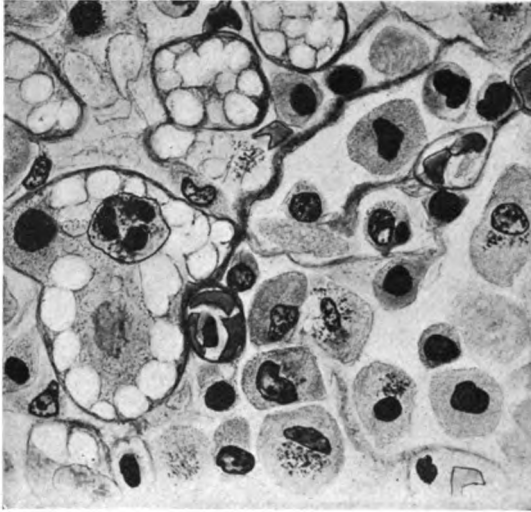


Fig. 382.—Acute yellow atrophy of liver. Several liver cells containing fat-droplets; many endothelial leukocytes, some with pigment in them.

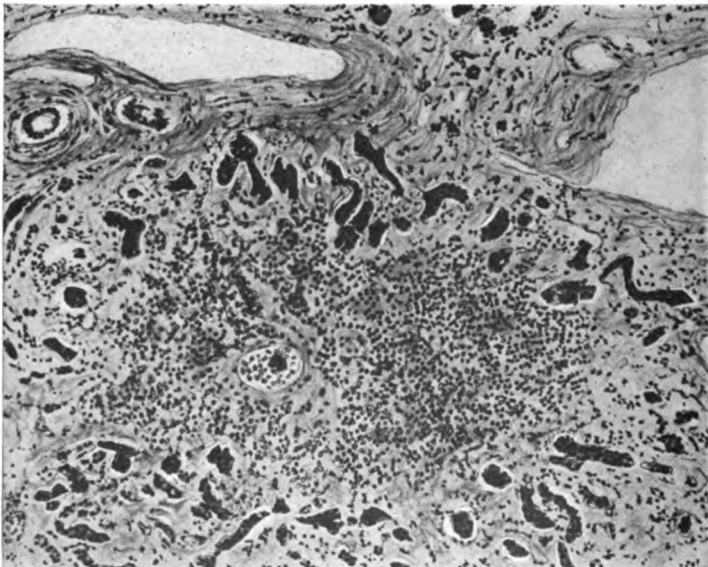


Fig. 383.—Healed stage of acute yellow atrophy of liver. Illustration shows one lobule; all liver cells gone. Proliferation of bile duct epithelium, but no liver cells formed. M. and B.

certain length of time (one to several weeks) the necrotic cells are rapidly invaded and removed by the action of leukocytes, especially of the endothelial type. The liver cells left in certain parts regenerate actively, but in the large areas where there are none only the bile-duct epithelium proliferates. It leads to prolongations of the bile ducts which stretch out towards the hepatic veins, but they do not produce liver cells. In these areas the form of the lobule and the arrangement of the vessels remain perfect but much shrunken. The connective-tissue cells show little or no proliferative activity.

This stage of the removal of the necrotic liver cells and of regeneration and repair following extensive necrosis gives rise to

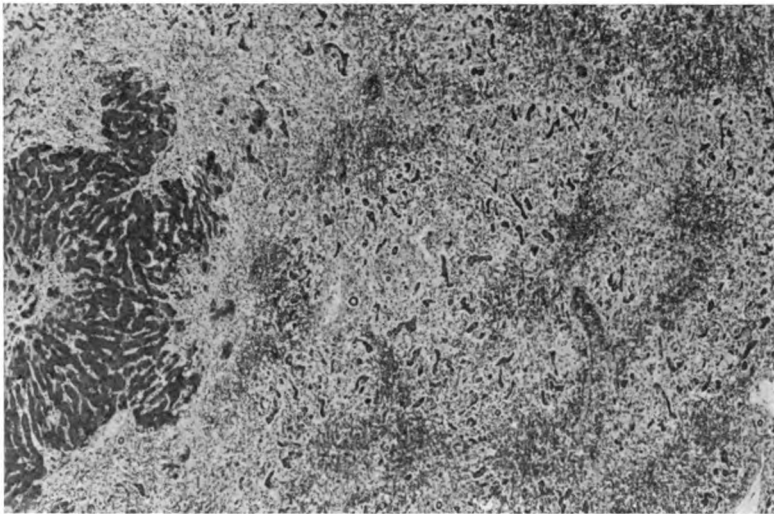


Fig. 384.—Liver. Healed stage of acute yellow atrophy. Regenerated liver cells on left. The rest consists of atrophied liver lobules with bile ducts at their peripheries. M. and B.

certain anatomic changes and to certain clinical symptoms dependent on them to which the term acute yellow atrophy is applied, yellow because the patients are always jaundiced, atrophy because the liver is much diminished in size.

The gross appearances of the liver found postmortem vary greatly, according to the length of time which intervenes between the liver-cell necrosis and the death of the patient. At the end of about one week the liver cells have to a large extent been dissolved and removed. Their place is occupied by a variable number of endothelial leukocytes. The liver has shrunken to one-half or even almost to one-third of its normal size (595 and 600

grams respectively in two instances). Here and there, especially around the portal vessels, single living liver cells and small groups of them may be found. In gross the liver is uniformly greatly diminished in size. Its edges are thin and its surface is delicately wrinkled. It is noticeably flaccid and can be easily rolled upon itself. Its color is yellowish red.

In case the patient lives two to four weeks or more, regeneration of the liver cells plays an important part and alters the gross appearance of the organ. In those parts of the liver where the hepatic cells remain uninjured around the portal vessels, the lobules may be completely regenerated and those parts of the liver distended up to their normal size again (or possibly even beyond that as the result of compensatory hyperplasia). In other lobules where only one or more cells remained uninjured, only small clumps of cells result from regeneration. In those areas where necrosis of all the liver cells took place, the shrunken lobules persist with a network of capillary-like vessels at the center around the hepatic veins, and small bile ducts stretching out towards them from the portal vessels at the periphery.

In consequence of these regenerative changes a liver at this stage of the process looks as though only a part of it had originally been injured and it weighs more than at the earlier stage (960 grams in one instance). The regenerated areas appear of an intense yellow hue due to bile staining of the regenerated liver cells. The atrophied portions are of a brownish or reddish color, owing to little else remaining than sinusoids filled with blood.

Toxic Cirrhosis.—If the patient makes a complete recovery the liver remains sclerosed in the atrophied portions, and when found postmortem is classified under the general term cirrhosis, of which condition it forms one interesting type. It represents the healed stage following extensive sudden necrosis of liver cells. The lesion is of acute toxic origin, hence the designation, toxic cirrhosis. In contrast with the other forms of cirrhosis, toxic cirrhosis is not a progressive chronic process, but an end product.

Chloroform Necrosis.—Central necrosis of toxic origin is readily produced in animals by subjecting them to chloroform narcosis for an hour or two. The same type of lesion affecting three-fourths of every lobule occurred in a woman who died three days after drinking four ounces of chloroform.

Alcoholic Cirrhosis.—In the chronic, progressive, alcoholic type of cirrhosis there occurs a peculiar form of necrosis of the liver cells, which seems to be characteristic of it. The cytoplasm of the cells first undergoes a degenerative change in consequence

of which an irregular, coarse, hyaline meshwork appears in it. This meshwork stains deeply with eosin and with phosphotungstic acid hematoxylin after fixation in Zenker's fluid. This degenerative change may attack single cells or small or large groups of them; it may occur focally or very diffusely. The affected cells may be situated in any part of the lobule, but lie most commonly, perhaps, in the region of the portal vessels, and sometimes are sharply limited to that location.

The affected cells and the nuclei within them are usually swollen. After the hyaline change has reached a certain degree of intensity the cells are surrounded and invaded by numerous polymorphonuclear or endothelial leukocytes (sometimes the one,

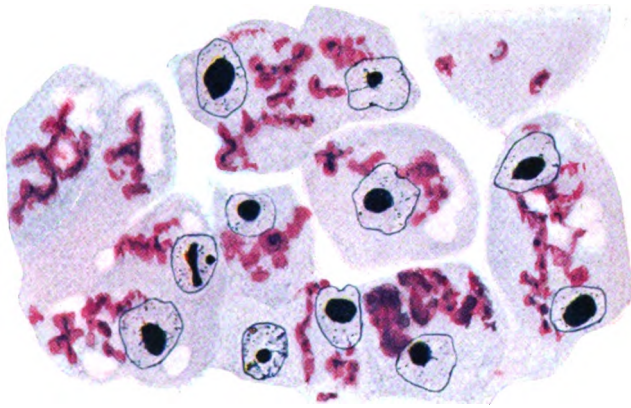


Fig. 385.—Liver. Alcoholic cirrhosis. Hyaline droplets appearing in cytoplasm of liver cells and fusing together.

sometimes the other), which dissolve the cells, the hyaline reticulum last, and thus bring about their disappearance.

Along with this hyaline change and destruction of the liver cells there occurs active regeneration as evidenced by occasional mitotic figures in adjoining liver cells. There is also more or less proliferative activity on the part of the fibroblasts resulting in increase of connective tissue.

These different processes of hyaline degeneration ending in necrosis, of leukocytic infiltration, of regeneration of liver cells, and of increase in the amount of connective tissue when extensive, diffuse, and acute, lead to considerable increase in the size and weight of the liver (2400 grams in one instance). The surface of such a liver is smooth and on section the cut surface is uniformly

even, the lobulation indistinct, and the consistence much increased so that the liver tissue tears with difficulty. In other cases the various changes are much less extensive and hence more chronic, because they do not cause death so quickly.

Even in the latest stages of alcoholic cirrhosis, however, it is usually possible to find liver cells undergoing the peculiar hyaline change which seems to be characteristic of this process. Still it is not possible to deny that this destructive hyaline change may cease entirely and leave nothing but the sclerosis as evidence of what has taken place.

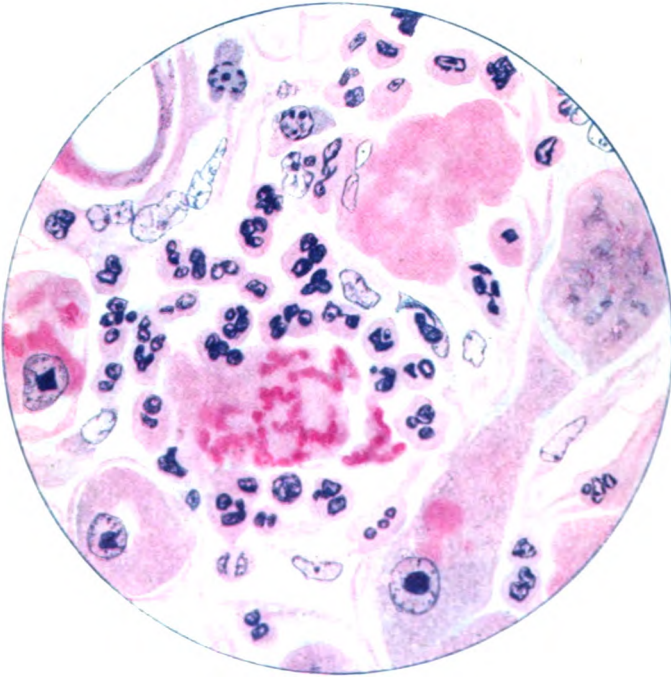


Fig. 386.—Liver. Alcoholic cirrhosis. Liver cells containing hyalin undergoing necrosis and attracting chiefly polymorphonuclear leukocytes.

The increase in the amount of connective tissue causes trouble later, when it contracts, by occluding bile ducts and blood-vessels here and there throughout the liver. Obstruction of the bile ducts results in focal bile stasis so that scattered areas appear dark green. In these areas the bile capillaries are often greatly distended and in places ruptured so that masses of inspissated bile have escaped into the lymph-spaces, between the liver trabec-

ulæ and the walls of the sinusoids. Here the masses are taken up by endothelial leukocytes and dissolved just as in ordinary generalized bile stasis due to obstruction of the common duct.

It is not at all uncommon to find all these different processes (hyaline degeneration, leukocytic infiltration, regeneration, proliferation of connective tissue, and focal bile stasis) present in one and the same liver section.

The obstruction to the general flow of blood through the vessels resulting in portal stasis and ascites needs no mention here.

This type of cirrhosis is very commonly complicated by fatty infiltration which leads to marked increase in the weight of the liver (3315 and 3580 grams in two instances, and greater weights are on record). As a rule, the clinician's diagnosis of hypertrophic cirrhosis proves to be of this nature. So far as can be determined from histologic observation, the presence of the fat interferes in no way with the degenerative process. Cells filled with one or more fat vacuoles undergo hyaline change like the others.

The cause of the increase of the connective tissue in this type of cirrhosis is not perfectly obvious. The primary injury affects the liver cells and is followed by more or less regeneration of them. We have seen clearly in the preceding type of cirrhosis (that following extensive central necrosis), that injury to the liver cells alone does not result in proliferation of fibroblasts. On the other hand we have, in alcoholic cirrhosis, around and invading each necrotic cell, an acute inflammatory exudate of leukocytes which must cause more or less stretching of the connective tissue. The injury which results in proliferation of fibroblasts seems, therefore, as in pigment cirrhosis, to be mechanical in origin, not toxic. On the other hand, the hyaline material set free by necrosis of the liver cell may have an injurious effect on fibroblasts as a result of which regeneration of them takes place.

If we leave tumors out of the question, the only other cause, besides direct toxic or mechanical injury to fibroblasts which stimulates them to proliferate, is the presence of fibrin and that plays no part in this form of cirrhosis.

Experimental Production of Alcoholic Cirrhosis.—No one has ever been able to produce cirrhosis of the liver in animals by the administration of alcohol, although the attempt has been made repeatedly. On this account many investigators have believed that the injurious agent in alcoholic beverages must be some contaminating substance.

Lead-salts given to rabbits and other animals in amounts just below the minimum fatal dose will produce in a few days a hyaline

lesion in the liver cells similar in all respects to that found in the alcoholic cirrhosis of man. Some of the cells undergo necrosis and are removed by the digestive action of leukocytes. Regeneration of liver cells is shown by mitotic figures. This observation suggests that the so-called alcoholic cirrhosis of man may possibly be due to lead. The source of the lead is not easy to determine, but it is known that acetate of lead has been used to sweeten sour wines. Further experimental work along these lines is in progress.

INFECTIOUS LESIONS

Introduction.—Infectious lesions in the liver due to the actual presence of the injurious agents are not so important as the toxic lesions, but they occur fairly commonly and are due to a considerable variety of micro-organisms. Some of these micro-organisms concerned can be grouped and considered together; others will have to be treated separately.

Infection of the liver may occur by direct continuity or by way of the hepatic artery, the portal vein, or the common bile duct; possibly also through the lymphatics. Infection with certain micro-organisms is common by one route, with other organisms by other routes. In pylephlebitis secondary to lesions of the appendix and intestines, the infectious thrombi may extend directly into the liver.

Abscess.—By whatever route the common pus-producing micro-organisms gain access to the liver, they usually cause, in the first place, necrosis of the liver and other cells in the areas affected. Along with the necrosis or following it there occurs an acute inflammatory exudation with softening of the destroyed tissues. The abscess thus formed usually continues to enlarge and may coalesce with others in the neighborhood. Such abscesses may break into the veins or into the peritoneal cavity. If the bacteria are killed off the abscess may be encapsulated by a wall of granulation tissue which gradually contracts and ends finally as scar tissue.

Infectious Cirrhosis.—When bile stasis exists from obstruction of the common bile duct, infection along the duct is not infrequent. Of greater importance, however, are cases of primary infection along the bile ducts. This condition apparently occurs most frequently in children. It is attended with fever, jaundice, and often rapid enlargement of the liver. In one acute case the etiologic agent was a Gram-negative bacillus, probably bacillus coli. The lesion consists of an inflammatory exudation in the bile ducts and in the periportal connective tissue. Where the lesion is acute the exudation consists of polymorphonuclear

leukocytes, serum, and fibrin. Where the process is less active the exudation consists chiefly of endothelial leukocytes, many of which are phagocytic and contain fragments of cells. Mitosis in endothelial leukocytes is found occasionally. Lymphocytes are present in relatively small numbers. Proliferative reaction on the part of the fibroblasts is well marked and evidently follows injury to the connective-tissue cells by the toxins from the bacteria.

The bile ducts are much distended by the inflammatory exudation into them, and in places the lining epithelium has been entirely destroyed. The connective tissue surrounding the bile ducts and portal vessels is greatly distended by the exudation which fills all the lymph-vessels and spaces so that the portal tissues

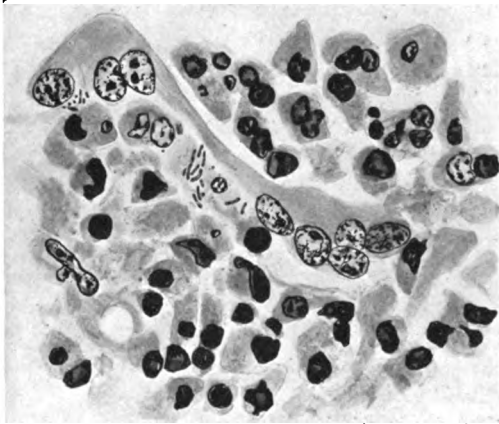

Fig. 387.—Liver. Infectious cirrhosis, early stage. Bacilli just outside of bile duct. Exudation of leukocytes within and outside of duct.

show up as broad bands. In many places the lesion is encroaching on the adjoining liver cells, which show first a marked granular degeneration of the cytoplasm and then necrosis. Invasion and dissolution by leukocytes follow. In this way the lesion spreads more or less irregularly towards the hepatic veins.

In those parts where the lesion is older and the exudation is less active the bile-ducts are dilated and appear much increased in number, as though a diffuse bile-duct adenoma were present in the liver. This appearance is probably due to contraction following marked dilatation and stretching of the ducts when the lesion was more acute.

In many places the inflammatory exudation in the smaller bile ducts leads to occlusion of them and to obstruction to the out-

flow of bile, which appears in the ducts above the point of obstruction in the form of yellowish green inspissated masses. The obstruction is focal only, however, not general, and this accounts for the moderate degree of jaundice produced.

This type of infection is likely to recur so that much destruction of liver cells and production of connective tissue may occur. In one case a typical coarsely lobulated liver was produced in a boy of fourteen in about six months by three attacks. The situation of the lesion chiefly around the portal vessels seems to be fairly characteristic. In two infants born jaundiced the common bile ducts were found obliterated, and the bile ducts throughout the liver were surrounded by a thick zone of fibrous tissue. This condition suggests strongly an intra-uterine infection extending along the bile ducts. This type of lesion resulting in sclerosis (infectious cirrhosis) corresponds to acute and chronic pyelonephritis in the kidney; often due to the colon bacillus.

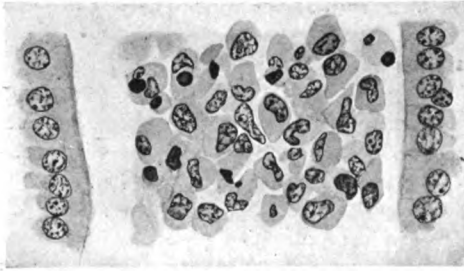


Fig. 388.—Liver. Infectious cirrhosis, early stage. Bile duct distended with endothelial leukocytes.

Tuberculosis.—Three different types of lesions, due to the tubercle bacillus, are recognized in the liver,—miliary tuberculosis, solitary tubercle, and bile-duct tuberculosis.

Miliary tuberculosis is the most common type of lesion. The tubercles may be easily visible to the naked eye, or so small that they are found only on microscopic examination. They may occur as part of a generalized miliary tuberculosis, or be found here practically alone. Tubercle bacilli which get into the circulation are more likely to be stopped in the liver than in any other organ. On the other hand, the miliary tubercles do not tend to enlarge into conglomerate tubercles and large caseous masses. In the miliary tubercles giant-cells are sometimes prominent; at other times they may be entirely absent. In these latter cases they may suggest focal necrosis, but the presence of an old tuberculous focus elsewhere in the body suggests their origin. Certainty

is obtained by demonstrating tubercle bacilli by the usual staining methods.

Occasionally miliary tubercles continue to spread until large tuberculous nodules, solitary tubercles, are produced. Such nodules may be single or multiple and may be difficult to differentiate in gross from early gummas.

In some cases of miliary tuberculosis where the infecting organisms are numerous, many tubercle bacilli may be carried to the lymph-spaces and vessels in the periportal connective tissue, and lead to a fairly diffuse tuberculous process around the bile ducts. Such a process may possibly result in sclerosis of the liver. Occasionally a similar infection may take place without much tuberculosis elsewhere in the liver and cause a well marked chronic tuberculous process. The bile ducts in the center may be destroyed or invaded, so that bile escapes into the softened centers of the tuberculous lesions and stains them. The process seems to extend chiefly around and along the bile ducts rather than through them, although the latter mode of extension is not impossible.

Syphilitic Cirrhosis.—Syphilitic infection of the liver is usually divided into two types, the congenital and the acquired. In the congenital type a diffuse lesion predominates, in the acquired a focal lesion, but the two types of lesions are often combined in the congenital form and may coexist to some extent in the acquired.

In congenital syphilis the treponemas cause a slight inflammatory exudation and much reparative proliferation of the connective-tissue cells lying between the liver cells and the walls of the sinusoids. As a result of the active and continued proliferation of the fibroblasts, due to efforts at regeneration, the connective tissue increases greatly in amount. This is shown by the fact that where the treponemas are most numerous the connective tissue is most abundant. Later, as the collagen fibrils contract the liver cells are compressed and more or less atrophy of them accordingly results. This diffuse type of lesion, resulting in primary increase of connective tissue and secondary atrophy of liver cells, is perfectly well recognized as characteristic of congenital syphilis. It is not infrequently complicated with focal lesions (miliary and larger gummas) due to occlusion of blood-vessels, necrosis of the liver and other cells in the area affected, and inflammatory infiltration with serum and polymorphonuclear or endothelial leukocytes.

In acquired syphilis the primary lesion is rarely or never distributed uniformly throughout the organ, but affects larger and smaller foci only and leads usually, perhaps always, to necrosis and inflammatory infiltration, forming the characteristic gummas

of this type of infection, which later may heal and contract, resulting in deep scars and more or less lobulation of the liver.

Actinomyces.—The actinomyces may reach the liver by direct extension through the diaphragm from the lung, perhaps the more common route of invasion, or through the circulation. It causes focal and conglomerate lesions consisting of an acute inflammatory exudation around the organisms, and of active proliferation of the adjoining connective tissue.

The actinomyces may occur in typical colonies surrounded by clubs. As a rule, however, growth is so free and unobstructed that the organism grows in loose or compact tangles of filaments without club-formation, or as single elements or threads extending through the exudation.

The leukocytes in the exudation are chiefly polymorphonuclear, but endothelial leukocytes are usually present also in varying proportions. They frequently contain the organism in the form of bacilli or short filaments; occasionally clubs are found in them. Little or no fibrin is present in the lesion. Regeneration of the surrounding connective tissue is usually very active, unless the inflammatory process is extending too rapidly.

Macroscopically the acute lesions appear as small focal and large conglomerate, soft, yellow, opaque areas resembling necrosis. On pressure a yellowish white creamy pus can be squeezed from them.

When the process is chronic in type the proliferated connective tissue forms a coarse sponge-like meshwork in which the holes are filled with pus surrounding the actinomyces colonies.

Malaria.—Malarial infection does not cause any marked changes in the liver beyond pigmentation. This is because the essential pathologic process takes place in the circulating blood.

The endothelial cells lining the sinusoids incorporate red blood-corpuscles in which the malarial organisms have lived and developed melanin. The result is that these endothelial cells very generally throughout the lobule contain small and large masses of melanin in their cytoplasm. In addition, an occasional endothelial leukocyte free in the blood contains similar masses of pigment. Evidently these cells are able gradually to dissolve the melanin because it does not accumulate to any great extent in the liver. Only a few endothelial leukocytes migrate with their pigment to the periportal connective tissue and lodge there. It is possible that in cases of long standing malarial infection this accumulation of endothelial leukocytes containing melanin might become a marked lesion and lead mechanically to one of the types of sclerosis.

Sclerosis (Cirrhosis) of the Liver.—To the clinician the term cirrhosis usually means a chronic, progressive, destructive lesion of the liver, combined with reparative activity and contraction

on the part of the connective tissue. This contraction of the connective tissue may lead to obstruction of bile ducts, causing more or less jaundice, and to interference with the flow of blood through the blood-vessels resulting in portal congestion and ascites.

The pathologist uses the term cirrhosis in a broader sense. He applies it to all sclerosed conditions of the liver, whether progressive or not, in which destruction of liver cells is associated with real or apparent increase of connective tissue.

As can be seen from the study of the different kinds of lesions described as occurring in the liver, a number of them may terminate in sclerosis of the organ. They may be summarized as follows.

Sclerosis of Mechanical Origin.—

1. Pigment cirrhosis occurring in hemochromatosis.
2. Carbon cirrhosis.

Sclerosis of Toxic Origin.—

3. Toxic cirrhosis following central necrosis and acute yellow atrophy.

4. Alcoholic cirrhosis.

Sclerosis of Infectious Origin.—

5. Infectious cirrhosis due to extension of bacteria along and around the bile ducts.

6. Syphilitic cirrhosis due to the treponema pallidum.

7. Tuberculous cirrhosis due to the tubercle bacillus.

Sclerosis of Tumor Origin.—

8. Primary scirrhus carcinoma of the liver.

Of two types of sclerosis, due respectively to carbon and to the tubercle bacillus, but one example of each has been reported so that they may practically be neglected. Sclerosis due to malignant disease is ordinarily classed under tumors, but deserves to be considered here because the clinical symptoms and gross anatomic appearance may be identical with sclerosis of other origin.

Toxic cirrhosis following central necrosis and acute yellow atrophy is of acute origin; all the other forms are steadily progressive, therefore chronic by nature.

The terms hypertrophic and atrophic cirrhosis cause the student and the clinician much trouble. This analysis of these several types of lesions shows that we may get a large, hypertrophied, smooth liver in at least three of them,—in infectious, pigment, and alcoholic cirrhosis. It is due in each instance to an extensive, diffuse, acute process. If the acute lesion ceases and healing takes place, or if the process is of moderate intensity and long duration, so that healing and scar tissue are more prominent than degeneration and exudation, the liver will diminish in size below the normal. The cirrhotic liver following central necrosis is necessarily at all stages below the normal weight.

Atrophic cirrhosis simply means a liver in which a large proportion of the liver cells have been destroyed and have disappeared, while the existing and new-formed connective tissue has been rendered unduly prominent.

The terms monolobular and multilobular cirrhosis are also extremely confusing. They state only a relation between masses of liver cells which rarely correspond to liver lobules and strands of connective tissue. They do not in the least explain the nature of the process. In infectious cirrhosis of bacterial origin the lesion is confined quite uniformly to the portal vessels; the same is true to a less degree of pigment cirrhosis. If, after old custom, the hepatic vein is taken as the center of the lobule, then the two types of cirrhosis may be said, perhaps, to deserve the term monolobular.

In syphilitic cirrhosis of the diffuse type the sclerosis spreads quite evenly throughout every lobule.

In cirrhosis following central necrosis, large groups of lobules are completely sclerosed, while other large groups may be perfectly normal or hyperplastic. The lesion is most irregular in distribution.

In alcoholic cirrhosis the distribution and intensity of the degenerative process vary greatly in different cases, and the increase of the connective tissue follows in the same lines. It often cuts into lobules in every direction. At other times it is fairly regular in its distribution. As a rule, however, the lobular arrangement is quickly distorted. Hepatic veins are hard to find. Sometimes the more normal areas are small, at other times large, so that on gross examination either term, mono- or multilobular, might be appropriate. It must also be borne in mind that regeneration of liver cells plays an important rôle in alcoholic cirrhosis and may lead to comparatively large areas of newly-formed liver cells, showing no lobular arrangement, containing no bile ducts, and sometimes regarded as adenomas.

It would seem much wiser to discard these terms which do not explain and serve only to confuse. They emphasize the wrong end of a pathologic process and represent only the result of forces acting against each other, the expanding efforts of regenerating liver cells, the contracting force of proliferated fibroblasts which tend to squeeze the surrounding liver cells into the smallest compass, namely, into spherical masses.

It has long been a much disputed point, chiefly with reference to the alcoholic type of cirrhosis, whether the number of bile ducts in certain cases is greatly increased or whether many of them are not compressed columns of liver cells. The type of necrosis following central necrosis shows that bile ducts may grow out to a considerable distance towards the hepatic vein. In

infectious cirrhosis a similar prolongation of bile ducts may occur. On the other hand, the diffuse form of syphilitic cirrhosis shows that liver-cell trabeculæ may be greatly compressed so as to resemble to some extent bile ducts. Therefore, it is theoretically possible that both true and apparent bile-duct formations may occur in alcoholic cirrhosis. As a matter of fact both probably do. If they are carefully studied after proper staining it will often be found that in some of the epithelial cells composing them hyaline material similar to that in the degenerating liver cells is present. Likewise in alcoholic cirrhosis complicated with fatty infiltration fat vacuoles will occasionally be found in the cells which look like bile-duct epithelium. The presence of fat vacuoles and of the hyaline material proves beyond question that the cells containing them are compressed liver cells and not bile-duct epithelium.

Entameba Histolytica.—Infection takes place through the portal circulation secondary to lesions of the intestinal tract. The organism causes large and small areas of necrosis, and abscesses which may be of large size. The lesion consists chiefly of necrosis and tissue solution. Inflammatory exudation is not prominent.

The amebæ may be few or many in number. They may occur alone or combined with various bacteria. There seems to be no reason to doubt that they are able alone, without the aid of bacteria, to cause the lesions associated with them.

It is often possible to find amebæ here and there in the sinusoids without any lesion around them. As soon as several are present, however, the neighboring liver and other cells undergo necrosis and dissolution without any marked inflammatory reaction being caused. The necrotic cells are gradually transformed into finely granular material. Polymorphonuclear and endothelial leukocytes may be attracted in small numbers, but likewise quickly undergo necrosis and solution. Fibrin is often present in the wall of the cavity formed in this way. Leukocytes of the lymphoblastic series are usually fairly numerous outside of the fibrin and in the periportal connective tissue. Occasionally the lymphatics contain amebæ and endothelial leukocytes. The connective tissue shows little or no evidence of regenerative activity. These lesions in the liver due to the *entameba histolytica* are frequently complicated by extensive central necrosis and by thrombophlebitis.

Macroscopically, the lesions appear as large and small areas of necrosis and as abscesses which are often very extensive.

Jaundice.—Jaundice is the name applied to the yellow hue acquired by the skin, sclera, and internal organs and fluids when they have been stained by bile pigments due to the presence of bile in the blood. When the bile is large in amount and persists for a long time the color may become brown or green. The

liver usually appears the most deeply stained, generally a dark green, because in addition to the diffuse bile staining, the lobules often contain masses of inspissated bile in their centers around the hepatic veins. The kidney comes next in intensity of color, because in addition to the general staining its cells contain granules of bile pigment which is being excreted through them.

Jaundice usually results from general or focal bile stasis in the liver and the escape of bile, as already explained, into the circulation. General bile stasis is due to the occlusion of the common or hepatic bile duct by calculus, cancer, gumma, cicatricial contraction and other causes. Focal bile stasis results from any cause which occludes branches of the bile duct, such as cirrhosis, tumor metastases, abscesses, infection of the bile ducts. In all these instances the stasis of the bile and the escape of the inspissated masses of it from the distended bile capillaries is readily demonstrated microscopically.

Jaundice may follow central necrosis of liver cells, especially the severer types of the lesion terminating in acute yellow atrophy. Two reasons may be assigned for the jaundice; in the milder lesions, owing to necrosis and dissolution of the liver cells, the bile capillaries are left open at their outer ends toward the hepatic vein so that the bile can easily escape; in the severer lesions single liver cells and small groups of them are left without connection with the bile ducts; the bile secreted by them necessarily escapes. Jaundice may occur in midzonal necrosis apparently from the same cause, a break in the continuity of the bile capillary system. In this group of lesions no inspissated bile is found.

The cause of the jaundice occurring in septicemias with the streptococcus pyogenes, pneumococcus, bacillus aërogenes capsulatus, malaria organisms, etc., is not evident in sections morphologically. Jaundice in lobar pneumonia may sometimes be the result of a septicemia; in other instances a small amount of inspissated bile may be found in the bile capillaries, but not outside of them. Although it is strongly denied by many investigators, the possibility still exists that in some instances of jaundice the bile pigment may originate from the blood pigment outside the liver and independently of any hepatic action.

Eclampsia.—In the clinical condition known as eclampsia, which sometimes complicates pregnancy, at least two different types of lesions may occur in the liver, hemorrhages and necroses. The hemorrhages are much the more common and are very characteristic. They occur around the portal vessels and beneath the capsule and spread out from these points. The individual hemorrhages are minute and affect only single cells or small clumps of them, but they are often grouped so as to form hemorrhagic

areas of considerable size. The hemorrhages sometimes extend as far as the hepatic veins in the centers of the lobules, but usually not beyond the midzonal region.

The hemorrhages show that the blood escapes under considerable pressure; the affected liver cells are usually much flattened and forced from the side on which the blood entered the trabecular space. Sometimes the blood seems to have been driven into the liver cells and to have disrupted them. No such evidence of pressure exerted by the escaping blood is shown in the hemorrhagic type of central necrosis. The evident pressure, therefore, suggests that the blood comes from the arterial circulation under much tension and is probably connected with the high blood tension and the convulsions of eclamptic origin.

A peculiarity of these hemorrhages is that fibrin forms almost immediately around the red blood-corpuses and injured liver cells, and by its presence greatly obscures the lesion. The fibrin is formed in greatest abundance close to the portal vessels and rapidly diminishes in amount away from this region so that the hemorrhages occurring in the midzonal region usually contain little or none. Fibrin may also form secondarily in the sinusoids within and adjoining the hemorrhagic areas and may even extend out into the portal blood-vessels.

Following the hemorrhage the injured liver cells undergo necrosis and are invaded and dissolved by endothelial leukocytes. The red blood-corpuses also may be engulfed and dissolved.

The necroses which occur in eclampsia are of two types, focal and central. In my experience the focal variety is the more common.

The focal necroses may be small or large, and are usually more or less midzonal in location, but may adjoin the hepatic vein or the portal vessels. The affected cells undergo first an increase in the size and perhaps in the number of the albuminous granules; this is followed by a hyaline change in consequence of which the cytoplasm of the cells stains intensely with acid dyes. They are then invaded and dissolved by endothelial leukocytes.

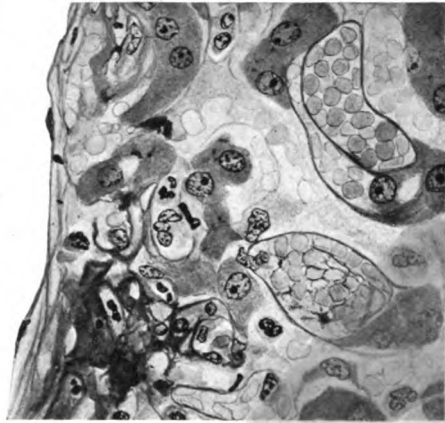


Fig. 389.—Lesion in liver in eclampsia. Blood driven by force into liver-cell columns. Much fibrin formation.

Necrosis of the central type may affect the larger part of every lobule. It usually occurs without the characteristic hemorrhages and unquestionably, in some cases at least, is of bacterial origin and due to infection following delivery. If chloroform has been used as an anesthetic another cause for the central necrosis is perfectly evident.

No relation between the necroses and the hemorrhages can be demonstrated, although the two types of lesions sometimes involve the same areas. Apparently the blood escapes through the walls of the sinusoids into the trabecular spaces at the points where the pressure is greatest, and not because of any especial preceding degeneration of the liver cells. The hemorrhages are, therefore, to be regarded as mechanical in origin.

The hemorrhages form a characteristic lesion of eclampsia. Some authorities regard them as diagnostic and believe that without the presence of these lesions a diagnosis of eclampsia should not be made. This view, however, does not seem tenable. No one believes that the hemorrhages or the focal or central necroses give rise to the symptoms of eclampsia; therefore they are not the pathologic basis of the disease, which must be sought elsewhere. They are frequent and characteristic complications, just as typhoid lesions may perhaps invariably be found in the liver if one will look for them: these latter form a characteristic lesion of typhoid fever, but are not essential to its existence.

In favor of this point of view it may be stated that lesions, identical with those in eclampsia in character and location, were found in small numbers in the liver of a man fifty-eight years old who died from pneumococcus septicemia, lobar pneumonia and acute meningitis.

Focal Necroses.—Focal necrosis is the term applied to necrosis of clumps of liver cells not lying in the center of the lobule around the hepatic vein. The foci involved may consist of only a few cells, or equal in size a miliary tubercle, or rarely be much larger. The lesions may be situated in any part of the liver lobule, but are most frequent near the portal vessels and in the midzonal region. The condition of focal necrosis is much less common than central necrosis.

Necrosis of single liver cells or even of very small groups of them is often found, especially in acute infectious diseases such as lobar pneumonia. They are most numerous in the livers of yellow fever patients, and in that disease tend to occur most frequently in the midzonal region.

The cause of focal necrosis is probably not always the same. The lesion seems to be sometimes of toxic, at other times of infectious, origin.

The focal lesions occurring in the liver in typhoid fever are discussed elsewhere. They do not arise as a primary necrosis of liver cells, but like miliary tubercles each is due to an accumulation of endothelial leukocytes around an organism. The liver cells undergo necrosis secondarily owing to local obstruction of the circulation.

The cause of the focal necroses in eclampsia is not evident. The lesions suggest a toxic origin.

The focal necroses which occur rarely in scarlet fever, diphtheria, and some other infectious diseases seem to be of infectious origin. They are often spherical in shape and of about the size of miliary tubercles, but sometimes are larger or smaller and irregular in form. They show a distribution similar to that of tubercles in the liver.

Attention has already been called to the fact that the lesions of central necrosis may sometimes closely simulate those of focal necrosis.

In the livers of apparently normal guinea pigs focal necroses are often found, sometimes in large numbers. It is important to bear this fact in mind, otherwise wrong conclusions may be drawn when this animal is used for experimental purposes. Necrosis of single liver cells and of small groups of them is often produced in the guinea pig and rabbit by the injection of various toxic substances.

GALL-BLADDER

Inflammation of infectious origin is fairly frequent in the gall-bladder and may be of a mucoid, fibrinous, purulent or gangrenous type. The wall may be congested and thickened. Obstruction may lead to marked dilatation. The inner surface may be ulcerated and the mucous membrane more or less completely destroyed. If the process becomes chronic the gall-bladder becomes thickened and later contracts into a small, dense, fibrous mass without a lumen or with its cavity filled with gall-stones.

Tumors of the gall-bladder are rare. The commonest is the carcinoma which usually invades and spreads in the adjoining liver tissue.

PANCREAS

Histology.—The pancreas is composed of glands, islets and ducts held together by a stroma of connective tissue and blood-vessels, in which occur relatively numerous sympathetic nerve-cell ganglia.

The glands or acini are lined with comparatively large cells which, in the non-secreting stage, contain numerous coarse zymogen granules in the cytoplasm on the side adjoining the lumen; these zymogen granules after suitable fixation stain deeply with acid dyes. The outer portion of the cytoplasm is strongly baso-

philic. The nuclei are round and each contains one or two relatively large, distinct nucleoli.

The islets (areas of Langerhans) are small spherical clumps of cells arranged in trabeculae which are separated by comparatively large capillaries. The islets have no lumina. The cells composing them are small and of three types; two, known as the A and B cells, contain fine granules in their cytoplasm, the third contains none. The granules of the A cells are preserved by alcohol, of the B cells by a chrome-sublimate solution. Both sorts of granules are dissolved by acetic acid.

The islet cells A and B develop independently from undifferentiated duct cells. The islets for the most part continue to be connected with ducts by a system of tubules and cell-cords composed of small polygonal cells of a low order of differentiation.

Experimental work has shown that both acini and islets may be formed from the ducts at any stage of existence. In regeneration of the pancreas, buds of cells spring from the ducts and develop, some into islets, some into acini. Transitions between islets and acini are never seen.

The islets vary in number in the different portions of the pancreas, being almost twice as numerous in the tail as in the head or body.

Postmortem changes, due chiefly to autodigestion, are frequent. They usually start in foci which enlarge and coalesce until the whole pancreas may be involved. Microscopically the nuclei in the affected areas do not stain and the cells shrink or dissolve a little so that the interglandular connective tissue seems increased in amount. These lesions of postmortem origin are readily distinguished from those occurring before death by the lack of any inflammatory reaction around them.

Retrograde Changes.—In various infectious and other diseases fat often accumulates in the form of small droplets in the cytoplasm of the epithelial cells, both in the acini and in the islets. Sometimes it is more abundant in one location, sometimes in the other.

An ingrowth of fat tissue (lipomatosis) between and often into the lobules is not infrequent, and in fat people is sometimes so extreme that the pancreatic tissue appears only in small islands scattered in fat tissue.

In general atrophy the cells of the pancreas diminish in size, but no pigment is found within them.

Necrosis is a common lesion in connection with the pancreas, but usually affects the fat and other tissues adjoining and between the lobules more than the epithelial structures themselves.

The secretion of the pancreas sometimes accumulates within the ducts and especially within the acini and causes dilatation. It usually appears more or less inspissated and often presents a lay-

ered appearance. Occasionally concretions of considerable size are formed. The epithelium surrounding them is often much flattened.

Hyaline Islets.—Hyalin is occasionally formed in the islets of the pancreas and is the most serious lesion affecting them because it results in the destruction of the islet-cells, and destruction of the islets is followed by the symptom-complex known clinically as diabetes.

The hyalin arises apparently in the same manner as amyloid, namely, as a secretion of the fibroblasts outside the walls of the capillaries in the islets. The hyaline deposit gradually causes considerable enlargement of the islets and by pressure on the epithelial cells causes them to atrophy and disappear. Some-

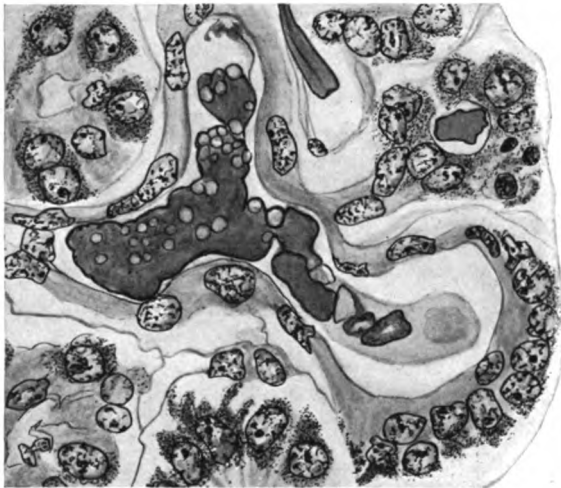

Fig. 390.—Pancreas. Concretions in dilated glands.

times the hyaline material gives the perfectly characteristic amyloid staining reaction with methyl-violet, at other times it does not. It is probably closely related, however, to amyloid even if not identical with it.

In rare instances calcification of the hyaline islets occurs.

In marked cases of hemochromatosis pigment is often deposited in the pancreas, but never to the same extent as in the liver. The pigment appears in the islet-cells, less often in the acinar epithelium and also in endothelial leukocytes which accumulate often in clumps in the stroma.

Circulatory Disturbances.—The circulatory disturbance of most importance is hemorrhage. It may arise as the result of rupture of an artery or of an aneurysm in consequence of arterio-

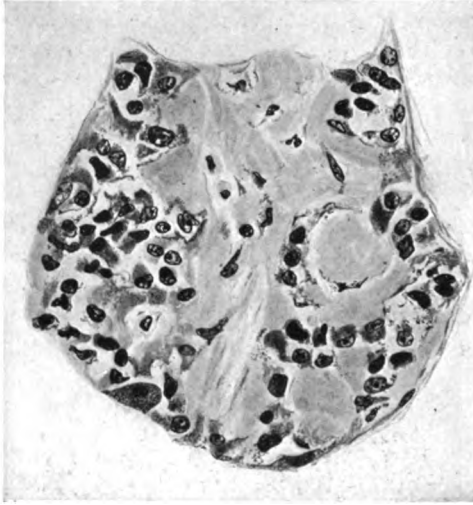

Fig. 391.—Pancreas. Diabetes. Part of an islet showing hyaline formation and atrophy of islet-cells.

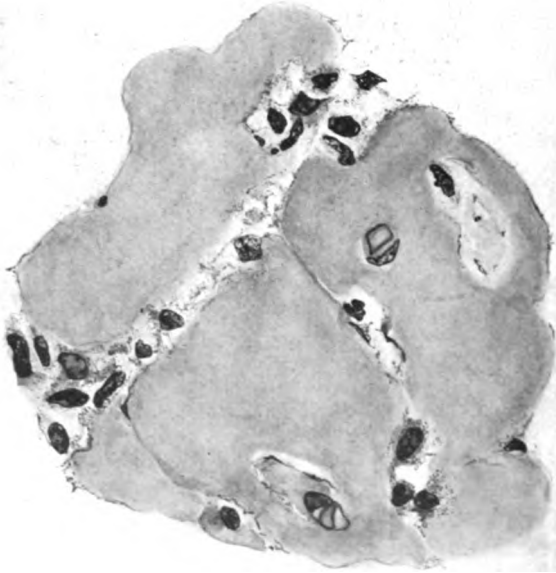


Fig. 392.—Pancreas. Diabetes. Part of an islet showing marked hyaline formation and almost complete disappearance of islet-cells. Hyalin gave typical reaction for amyloid. No amyloid in other organs.

sclerosis or follow injury or infection. It occurs most frequently in connection with necrosis due to escape of pancreatic secretion.

Lesions of Mechanical Origin.—The duct of the pancreas may be obstructed by pancreatic or by gall-stones, by cicatricial tissue, by new-growths, especially cancer, or very rarely by parasites. If the obstruction is complete, atrophy of the glands and sclerosis take place, but if it is only partial, dilatation of the duct or cyst formation may occur. The cysts may be large or small, single or multiple. In the tail of the pancreas they sometimes attain a large size. Obstruction of the duct is always likely to be complicated by infection extending in from the intestine.

Lesions of Toxic Origin.—Necrosis of epithelial cells occurring

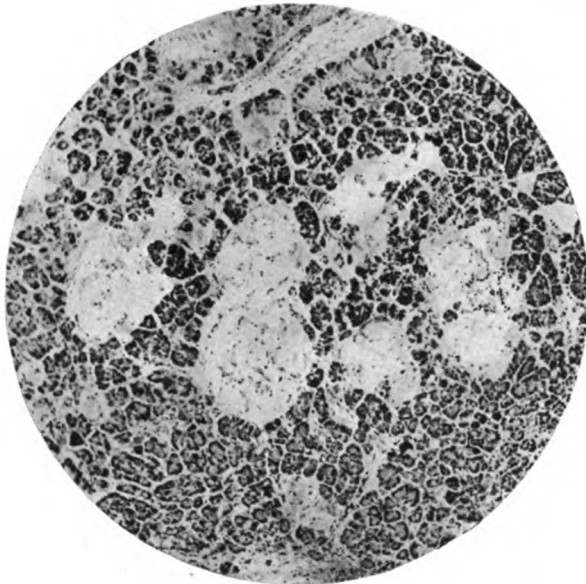


Fig. 393.—Pancreas. Diabetes. Extensive amyloid formation in islets. M.

in the glands of the pancreas as the result of toxins in the circulation is rare. Occasionally acinar cells singly or in clumps stain pink and show no basophilic properties; the nuclei are contracted and stain deeply. Possibly these cells are undergoing necrosis.

Focal and diffuse accumulations of polymorphonuclear leukocytes between the glands are not uncommon. Occasionally the glands are involved and many leukocytes appear within them. The cause of this form of lesion is not evident. No bacteria are present so far as can be determined histologically, although the lesion is likely to accompany a septicemia. In some instances it may be due to escape of pancreatic secretion which, for some reason, is not so toxic as usual and does not cause marked necrosis.

Acute Pancreatitis, Fat Necrosis.—The secretion of the pancreas sometimes escapes from the glands or ducts into the surrounding tissue and acts as an injurious agent. What leads to its escape is not fully understood. Perhaps sudden temporary obstruction of the ducts plays an important part, just as ligation of the common bile duct in rabbits causes escape of bile and necrosis of liver cells. The passage of bile and of intestinal contents into the pancreatic duct apparently favors the escape of pancreatic secretion and its injurious action, especially on fat-cells. Experimental work backs up clinical experience on this point.

The pancreatic secretion may escape in only small amounts and affect foci of cells, or escape in more or less abundance and

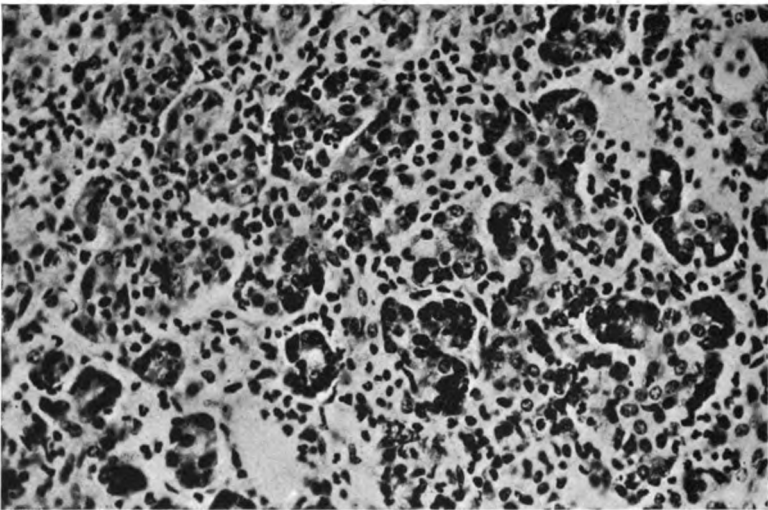


Fig. 394.—Pancreas. Extensive diffuse infiltration with polymorphonuclear leukocytes; cause not known. M.

involve a large part or the whole of the pancreas, and also some of the surrounding tissue. In rare instances the retroperitoneal tissues and the abdominal wall have also been more or less extensively affected by the necrotic process. When the foci are small and involve, as they usually do, fat-cells the term fat necroses is applied to them. When the pancreas is more or less extensively involved the term acute pancreatitis is employed. The latter process is usually complicated by fat necroses.

The pancreatic secretion spreads much more rapidly between the lobules in the loose connective tissue and around the fat-cells and blood-vessels than it does in the solid gland tissue; therefore, it produces most of its effect there. The fat-cells are rendered particularly conspicuous because of the changes which take place

in the fat contained in them. It is split up and from it are formed certain fatty acids which attract lime-salts from the tissue juices. These foci of necrotic fat tissue, usually called fat necroses for short, appear to the naked eye dry, opaque and yellowish white to white in color.

The escaped secretion causes necrosis not only of fat-cells, but also of all the other cells with which it comes in contact, epithelial, smooth muscle, etc. The walls of blood-vessels are frequently destroyed in part or entirely so that thrombi form within them or so that they rupture and allow the escape of blood. On this account hemorrhage is a common complication of extensive toxic

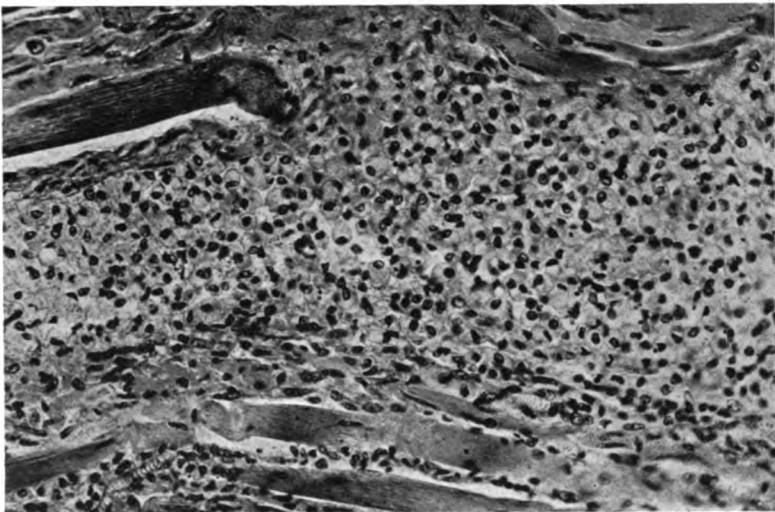


Fig. 395.—Acute pancreatitis. Extensive necrosis of fat tissue. Section from abdominal wall showing numerous endothelial leukocytes, filled with fat-droplets, lying between the muscle-fibers. M.

necrosis of the pancreas as is recognized in the clinical term hemorrhagic pancreatitis.

The necrotic epithelial cells of the pancreas undergo fairly rapid solution owing to the digestive action of the pancreatic secretion. As a rule the lobules of cells are attacked from the outside.

The reaction following the injury to the fat and other cells depends on the length of time which elapses after the pancreatic juice escaped before death occurred, or the tissue received for examination was removed at operation. At first, while the pancreatic secretion is strong, the inflammatory exudation consists of serum and of polymorphonuclear leukocytes which, like the tissue cells, are also often destroyed in large part by the ferments. Fibrin may be formed more or less abundantly. Later, endothelial

leukocytes surround the necrotic fat-cells and gradually incorporate the fat products. The leukocytes are often lined up around the necrotic fat-cells in such orderly fashion as to resemble cubical epithelial cells, and have often been mistaken for regenerating fat-cells. Occasionally they fuse to form foreign body giant-cells.

In time the endothelial leukocytes and also the lymphocytes and occasional eosinophiles attracted into the inflammatory process, disappear and the proliferated connective-tissue cells and their fibrils contract into scar tissue. This is one way in which,

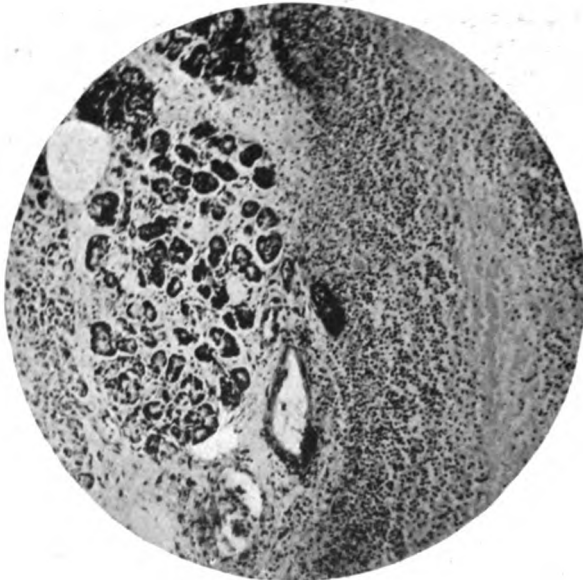


Fig. 396.—Pancreas. Acute pancreatitis with extensive necrosis of fat and gland-tissue. The blood-vessels are also involved. M.

if the pathologic process has been at all extensive and diffuse, sclerosis of the pancreas may arise.

Acute pancreatitis is a serious and often fatal process. Fat necroses on the other hand are of themselves of little significance. They usually occur in small, sharply defined foci one to three millimeters in diameter and may resemble, to some extent, miliary tubercles or minute metastases of a carcinoma. They may occur in and around the pancreas or be scattered here and there throughout the peritoneal cavity and have even been found within the thorax. Less often the foci, especially in and near the pancreas, are much more extensive.

Toxic necrosis of the pancreas and of fat-cells occurs most often in fat people and in those afflicted with gall-stones.

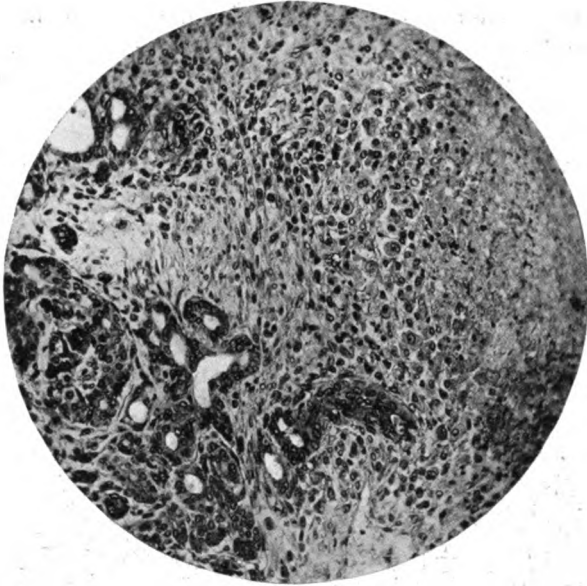


Fig. 397.—Pancreas. Acute pancreatitis in stage of repair. Endothelial leukocytes at edge of necrotic tissue. M.

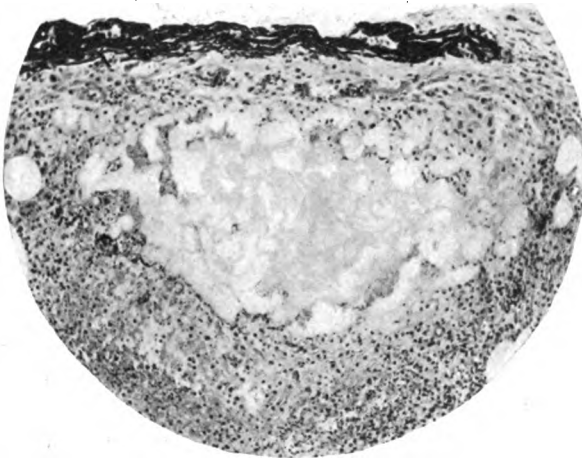


Fig. 398.—Fat necrosis in mesentery. Fibrin on surface. M.

Lesions of Infectious Origin.—Infectious lesions of the pancreas are comparatively rare. Bacteria may reach the organ by direct extension from lesions in the neighborhood, or through the pancreatic duct, especially if more or less obstruction is present, or through the blood-vessels as the result of a septicemia. The injury and inflammatory reaction may appear in the form of a diffuse process or as an abscess. Infection sometimes complicates pancreatitis of toxic origin.

Tuberculosis in the acute miliary form is not particularly rare if looked for, but chronic tuberculosis is fairly uncommon.

In congenital syphilis the diffuse interstitial type of lesion is the more common; in the acquired form gummas occasionally occur.

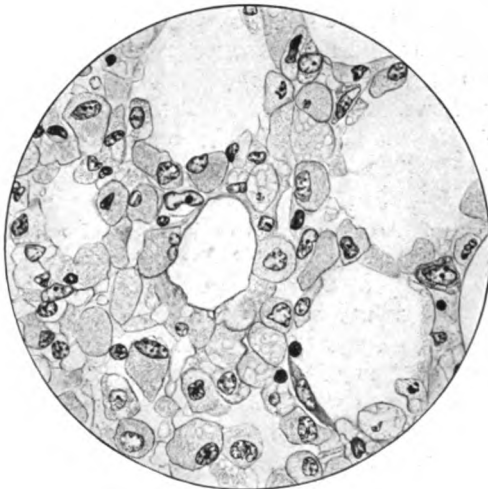


Fig. 399.—Fat necrosis. Endothelial leukocytes filled with fat-droplets around necrotic fat-cells.

Sclerosis.—The three types of lesions just described, mechanical, toxic and infectious, may all terminate in sclerosis of the pancreas. To determine from the end result the way in which it arose may be difficult or impossible. Perhaps in time the analysis of a considerable number of lesions in various stages of development may render this feasible. At present it is well to bear the possibilities in mind.

Tumors.—The islets of the pancreas vary, not only in number but also in size. They are usually round, but may be oval or elongated. Occasionally single islets may measure one or two or even up to four or five millimeters in diameter. The large islets are probably to be classed as adenomas.

The most common and important tumor is the carcinoma. It starts most often in the head, and is usually scirrhus in type; occasionally it is medullary and may attain a considerable size. The cells do not show any of the characteristics peculiar to the cells of the pancreas. In one instance the cancer grew in gland form and the cells were ciliated.

Physiologic Pathology.—The pancreas manufactures an external and an internal secretion. Each is of much importance physiologically.

The external secretion is produced by the acinar cells and

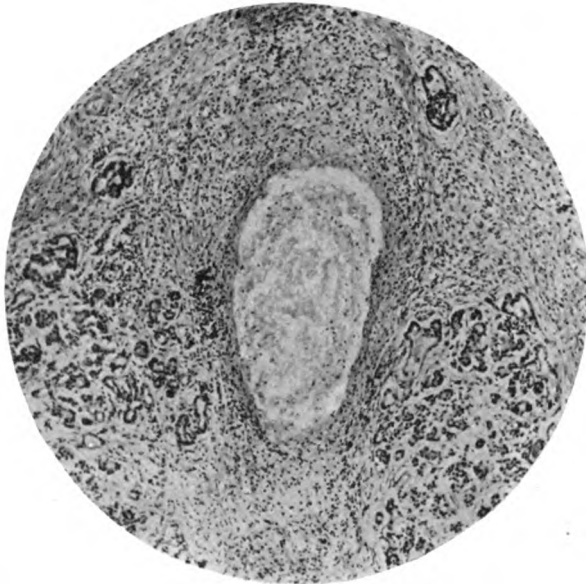

Fig. 400.—Pancreas. Acute pancreatitis in stage of repair. Area of necrosis in center. Considerable increase of fibrous tissue (sclerosis). M.

contains three ferments. It escapes into the duodenum through the pancreatic duct. Obstruction of the duct by calculus or other cause prevents the escape and action of the various ferments, and thereby interferes with their digestive functions.

The internal secretion is produced in the islets and passes directly into the circulation. It is even more important than the external secretion for the following reason.

It is believed that under normal conditions ingested carbohydrates are burnt up in the muscles by the combined action of two glycolytic bodies, one produced in the muscles and the other as the internal secretion of the islets in the pancreas. If the

production of the glycolytic body produced by the pancreas is interfered with, glycosuria results, and glycosuria is the most characteristic symptom of the constitutional disease known as diabetes mellitus. If the cells of the islets are injured or destroyed no ferment is produced.

The exact relation of the pancreas to glycosuria and to diabetes is not yet fully understood. Careful study of the pancreas from many cases of diabetes shows that in many of them the islets have been more or less completely destroyed, but they also show that in many other instances no demonstrable change is present. According to F. M. Allen every anatomic hypothesis of diabetes still requires to be assisted by assuming the existence of a certain proportion of functional cases without known anatomic basis.

Experimental Work.—Much experimental work has been done on the pancreas in animals. Some of the results obtained are briefly summarized here from Allen's recent monograph on the subject.

1. Total extirpation of the pancreas is followed by:

- (a) Great increase of nitrogenous loss.
- (b) Increased fat metabolism.
- (c) Rapid cachexia.
- (d) Poor absorption of food.
- (e) Lowered power of wound healing and resistance to infection.
- (f) Complete inability to utilize dextrose.
- (g) Diabetes gravis.

2. Extirpation of about nine-tenths of the pancreas leaving the remnant in communication with the duct is followed by diabetes which is relatively mild and apparently functional at first with no visible changes in the islets. In a few animals the condition is transient. Regeneration of acini and islets occurs and is followed by complete recovery. In the majority of the animals there is little or no regeneration although they are curable at first by the simple expedient of tying off the duct. If this is not done the diabetes persists and increases with time until there is a complete inability to utilize dextrose. Examination of the pancreas shows steadily progressive degenerative changes which involve all the islets and are typical for diabetes, namely;

- (a) A loss of cells.
- (b) Deficiency of cytoplasm of many of the persisting cells.
- (c) Degenerating, occasionally naked nuclei.
- (d) Later all islets disappear.
- (e) Acini all well preserved.

The visible changes in the islets correspond to the duration and severity of the diabetes.

These cell changes in the islets are unquestionably to be regarded as the result of the diabetes, not the cause of it.

URINARY ORGANS

KIDNEY

Introduction.—In order to understand the lesions of the kidney it is necessary, as with the liver and other organs, to study thoroughly each separate kind of acute lesion and to trace its later development; then only are we in a position to understand the various combinations of these lesions and to read backward with more or less certainty the lesions found in chronic nephritis and in sclerosed kidneys, and tell how they arose.

Of the different kinds of pathologic processes affecting the kidney, the toxic and the infectious are the most important, especially the toxic, but the two are often combined. In fact in the kidney perhaps more than in any other organ we get various combinations of lesions, one type complicating another and acute lesions on top of chronic and healed lesions. As a result of these combinations the various pathologic processes of the kidney are not easy to analyze and present in a simple, orderly array to the satisfaction of the pathologist and of the clinician.

In studying the lesions of the kidney it is important to bear in mind that it is composed of a large number of small units. Every unit consists of an afferent vessel, of a glomerulus composed of a knot of capillaries, and of a tubule. The blind invaginated end of the tubule is applied to the surface of the glomerulus. Its actual beginning is known as the capsular space. In addition to these four main structures of a unit there is an efferent vessel and a network of capillaries derived from it and surrounding the tubule. These vessels are of minor importance. A little connective tissue surrounds the vessels and tubule and extends in small amount into the glomerulus.

Of these different elements of the unit the glomerulus, where blood-vessel and epithelium are in close association, seems the most susceptible to the action of injurious agents.

If any one of the four essential parts of a renal unit is destroyed, the other three in time atrophy and cease to function. Each part is useless without the other three.

In order to understand the lesions of the kidney it is necessary to separate it into its units and study the effect of injurious agents on each part of a unit.

It has always been difficult to correlate the lesions found by the pathologist with clinical observations and urinary analyses. The difficulty lies in the lack of a common ground for comparison. The pathologist takes into account all the lesions in a kidney, both active and healed; the latter may give rise to no clinical symptoms and to no urinary changes. The clinician and the chemist, on the other hand, take into account only the lesions which cause symptoms and urinary changes; in addition, they recognize functional disturbances which a pathologist is unable to do. It is evident, however, that reform must come first from the pathologist. He must furnish, so far as possible, a clear-cut morphologic basis on which the clinician and chemist may build. This fundamental morphologic basic work has not yet been satisfactorily performed.

General disturbances of nutrition, such as anemia, and toxemias of all kinds tend to affect all the renal units to about the same degree. The result is more or less uniformly distributed or diffuse lesions throughout the kidney, although sometimes certain units are much more affected than others. When, however, infectious agents such as the staphylococcus pyogenes aureus are brought to the kidney and distributed according to the laws of chance, the result is focal lesions which may become the centers of extensive pathologic processes.

RETROGRADE CHANGES

Postmortem changes appear comparatively early in the kidney and on this account it is especially important to recognize them. They are evident first in the convoluted tubules and are fairly definite and characteristic.

The first noticeable change is that the nuclei stain uniformly and deeply; then a little later they do not stain at all and the cells often begin to desquamate. The cytoplasm of the cells may stain more deeply than is usual with eosin and the albuminous granules may appear increased in number. It is difficult to determine this latter point with certainty.

These postmortem appearances have frequently been mistaken for antemortem changes, and the condition diagnosed as marked tubular nephritis, although the kidney showed no evidence of any reaction to such an extreme injury.

Albuminous Granules.—The cytoplasm of renal epithelium is normally finely granular, owing to the presence of albuminous granules. These granules are most numerous in the epithelial cells lining the convoluted tubules, and fewest in those lining the

collecting tubules, especially in the pyramids. To prove conclusively whether or not an actual increase in the number of these granules takes place under certain pathologic conditions is not an easy matter. An increase or diminution is not of much significance.

In acute tubular nephritis the granules are sometimes much coarser than normal and show various stages of change into colloid droplets. In the amyloid kidney the granules often disappear to a large extent, while at the same time the cells swell and are filled with fine to coarse hyaline or colloid droplets.

Hydrops and Edema.—An accumulation of fluid within the cytoplasm of cells is termed hydrops, between cells and fibrils and within natural cavities edema.

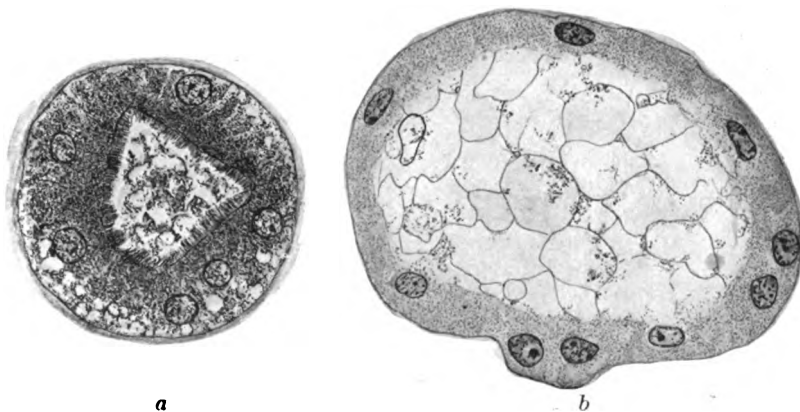


Fig. 401.—Kidney. *a*, Normal convoluted tubule showing ciliated border and granules in cytoplasm; *b*, edema of tubule; circular reticulum probably due to albuminous envelope of drops of fluid.

Hydrops of renal cells unquestionably occurs, but the vacuoles it forms cannot be recognized for certainty without ruling out the presence of fat by appropriate staining methods. Its significance is probably not great.

The presence of edema is much more definitely shown by dilation of tubules and capsular spaces, and by the separation of the fibrils and other intertubular structures.

Colloid.—Colloid frequently makes its appearance in the form of hyaline droplets in the cytoplasm of the epithelial cells lining the convoluted tubules and the capsular spaces in a variety of acute and chronic processes.

Colloid is not a definite chemical substance with a specific

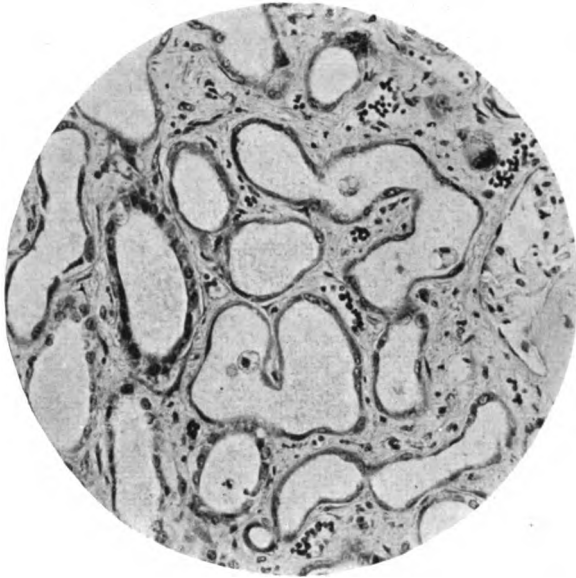


Fig. 402.—Kidney. Edema of tubules. M.

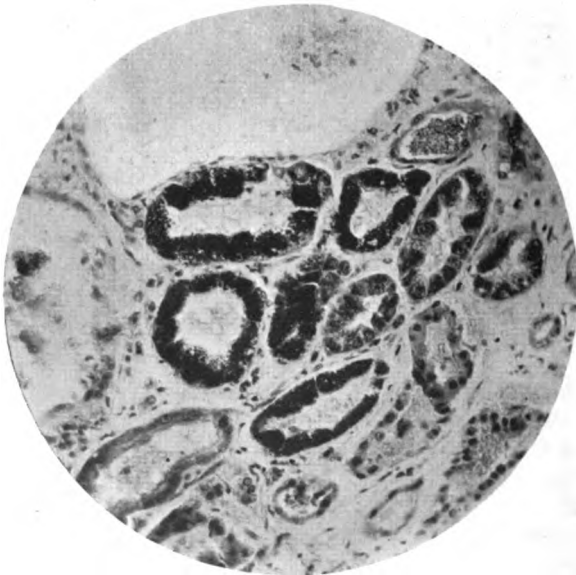

Fig. 403.—Kidney. Hyalin in epithelial cells lining some of the tubules
This variety stains deeply with acid dyes. M.

reaction. Sometimes it stains intensely, at other times lightly, with all gradations between. At times it is stained by basic, more often by acid dyes. It is recognized by physical rather than by chemical peculiarities.

Its relation to the albuminous granules is not easy to determine; sometimes it seems to arise directly from them by swelling and hyaline transformation; at other times the hyaline droplets seem to arise between the albuminous granules. One thing is certain; the cells containing the colloid are greatly enlarged; something has been added. This something may, however, be only fluid.

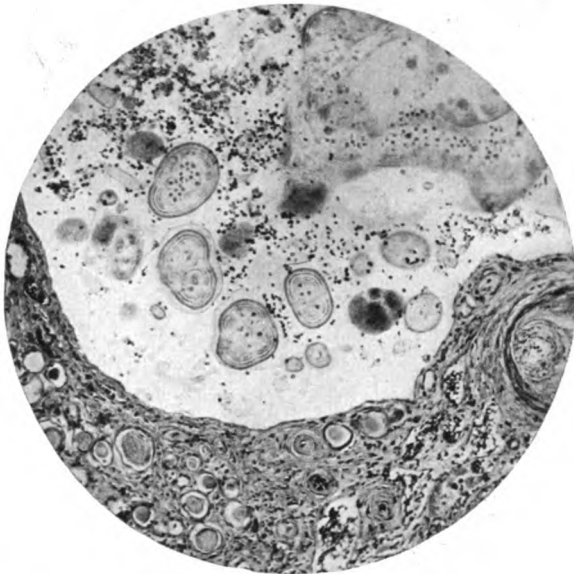


Fig. 404.—Kidney. Multiple concretions in a small cyst. M.

The larger colloid droplets are probably due to fusion of smaller ones, not to individual growth.

Occasionally small cysts occur filled with corpora amylacea probably derived from colloid material.

The appearance of colloid in renal cells is of much significance, because it represents a marked retrograde change. It occurs most often and abundantly in connection with acute tubular nephritis and with amyloid formation; to a less extent in the other forms of nephritis.

Fat.—Fat is not present in visible form in renal cells under normal conditions. Its appearance there is, therefore, of consider-

able importance because it signifies a definite retrograde change. Its presence is the best guide we have for revealing interference of some kind or other with the normal activity of cells.

Fat appears in the kidney as the result of diminished nutrition or because of injury done by toxins. Thus in general anemia fat may be present in the greatest abundance evenly distributed in all the epithelial cells of the convoluted tubules. Under favorable conditions it is conceivable that all this fat might slowly disappear

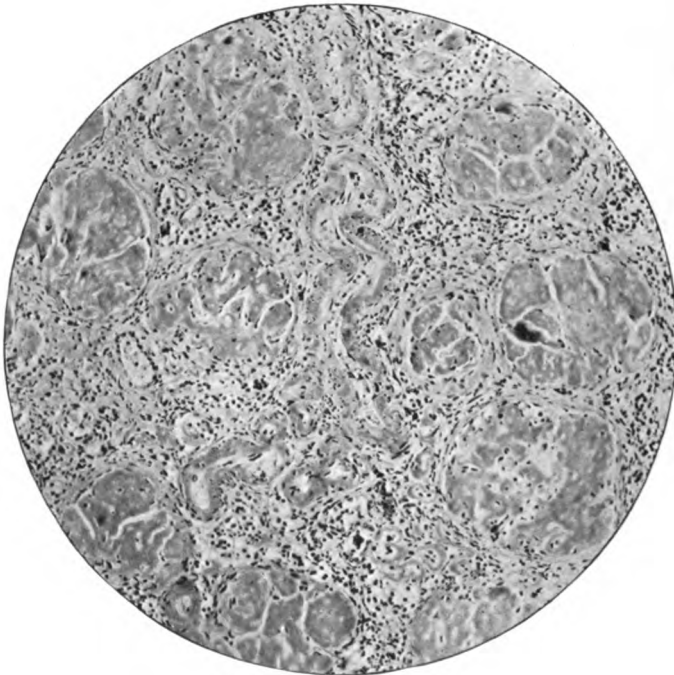


Fig. 405.—Amyloid infiltration of the glomerular tufts and of the arteries in the kidney. M.

and recovery take place. When the nutrition of the kidney is interfered with in various situations as the result of lesions in the blood-vessels, as in vascular nephritis, fat appears often only in the foci affected and is usually abundant in the blood-vessel walls as well as in the epithelial cells. In the various forms of nephritis due to toxins the amount of fat in the renal cells varies within wide limits and may be very unevenly distributed, although as a rule the cells of the convoluted tubules are more seriously

affected than any others. Sometimes much fat is present in the glomeruli.

Amyloid.—Amyloid is secreted in the kidney usually first in the walls of the smaller arteries and in the glomeruli. Later it appears in the walls of the veins and may occur more or less extensively around the tubules. Everywhere it lies in the closest relation with the cells and fibrils of the connective tissue, often where they are near the lining endothelium of blood vessels, but by no means necessarily so.

In the glomerulus amyloid usually appears first in the afferent vessel and then in the walls of the larger capillaries of the tuft.

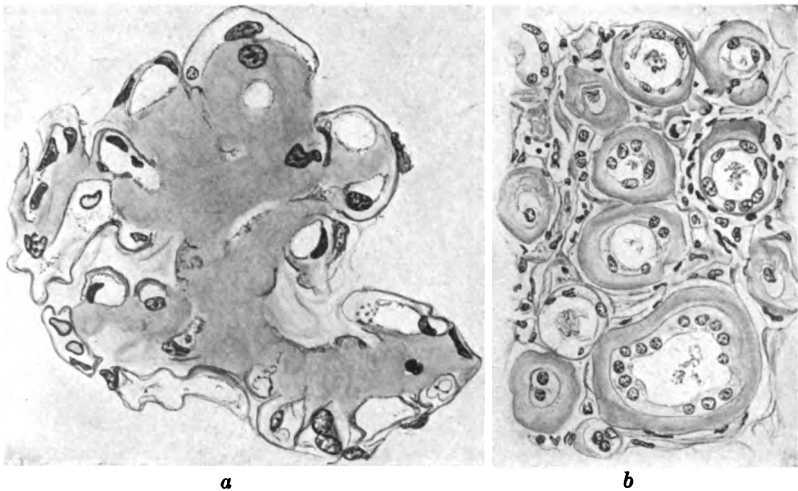


Fig. 406.—Kidney. Amyloid formation. (*a*) In lobule of glomerular tuft; *b*, around tubules chiefly.

It shows as a hyaline thickening of the connective-tissue backing of the capillary walls. This thickening spreads and increases until all the capillaries are involved. Often the afferent vessel and some of the capillaries are considerably dilated in the early stages of the process. The amyloid formation leads to noticeable enlargement of the glomerulus and obscuring of the normal lobulation. As the amyloid deposit increases, the lumina of the capillaries are narrowed to slits and finally obliterated, so that the lining endothelium disappears. No necrosis follows this slow closing of the vessels and no thrombi are formed within them.

At the same time that amyloid is being secreted in the walls

of the capillaries of the tuft, it is being formed in the blood-vessels elsewhere in the kidney. The arteries usually show the change before the veins. In the smaller vessels the whole wall is affected and is transformed into a thickened hyaline tube, from which the normal elements have disappeared as the result of pressure atrophy. In the larger arteries amyloid is sometimes most abundant in the intima, which becomes thickened; at other times in the muscle coat, where the gradual disappearance of the muscle-cells can be followed.

In the smaller veins the whole wall is transformed into a hya-

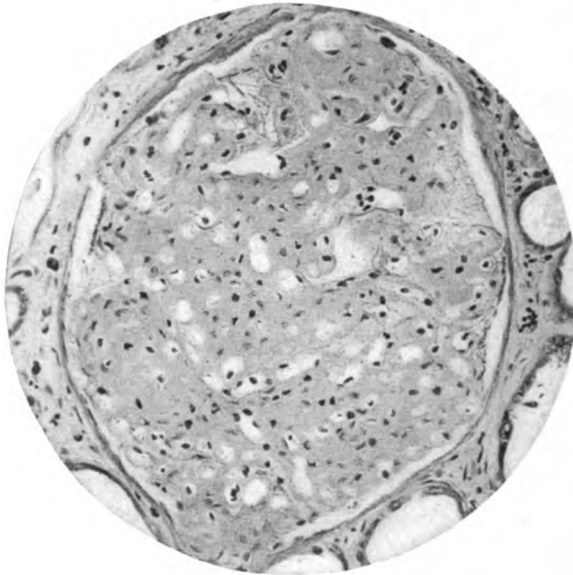


Fig. 407.—Amyloid infiltration of glomerular tuft in the kidney. M.

line tube of amyloid which gradually encroaches on the lumen and finally occludes it. This change is most marked in the pyramids of the kidneys, but may affect also many of the vessels in the cortex.

When amyloid secretion in the kidney is abundant it may gradually form also in the connective tissue around the tubules, and less commonly around the capsular spaces and lead to much thickening around these structures.

Tubules.—While amyloid is being formed in the glomeruli and blood-vessels, certain changes take place in the tubules. The epithelium in many of the convoluted tubules becomes swollen from

imbibition of fluid so that its cytoplasm appears lace-like, owing to the separation of the albuminous granules and their arrangement around vacuoles. This condition seems to precede the formation of hyalin which appears as faint droplets. The hyaline droplets

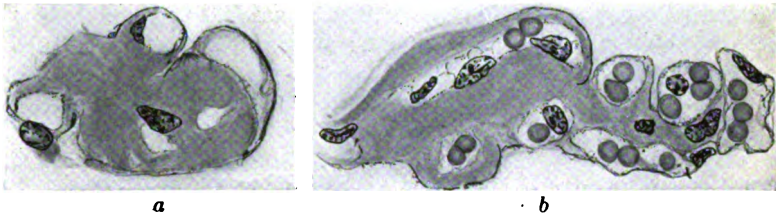


Fig. 408.—Kidney. Amyloid formation in glomerular tuft.

gradually increase in size and in density so that they tend to stain a little deeper with acid dyes than at first. As the hyaline droplets increase in number and size the cells filled with them become much enlarged and project into the tubule which they line.

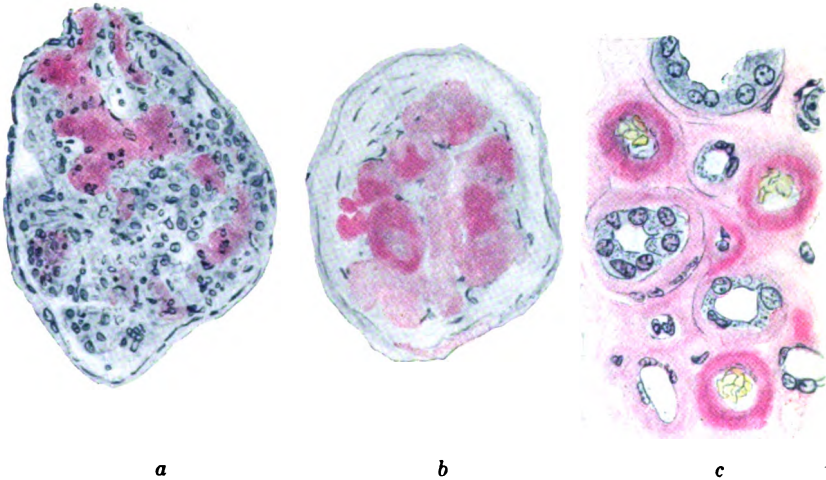


Fig. 409.—Kidney. Amyloid. *a*, Amyloid in vessels of glomerular tuft; *b*, in sclerosed tuft; *c*, around blood-vessels and tubules. Characteristic stain with methyl-violet.

In other places some of the tubules become dilated and the lining epithelium correspondingly thinned, owing to pressure.

Many of the tubules contain fluid, circular reticulum and much

granular material. Occasionally an epithelial cell filled with hyalin desquamates, or ruptures and allows the escape of the droplets into the lumen. All these materials gradually fuse into hyaline casts which are often abundant in the collecting tubules of the pyramids.

When amyloid forms in abundance around the tubules, the epithelial cells lose their differentiated character, and gradually atrophy and disappear just as liver cells do in the presence of amyloid.

The relation of the production of colloid in the epithelium of

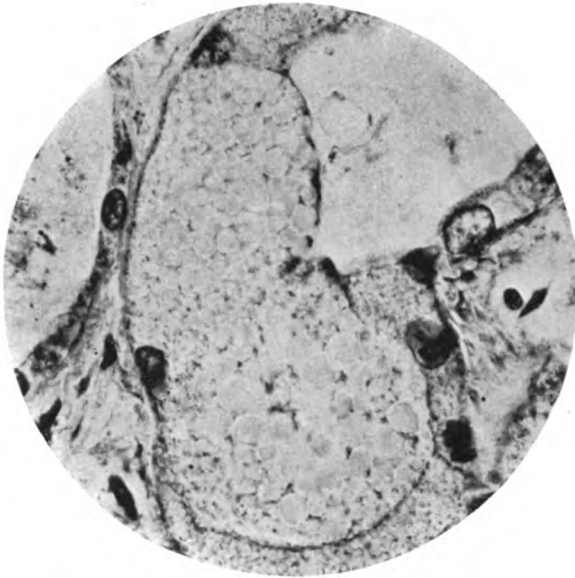


Fig. 410.—Kidney. Hyalin in epithelial cell lining a tubule. This variety stains faintly. M.

the tubules to the formation of amyloid in the glomeruli is not evident, but there probably is one, because more colloid is formed in the epithelial cells in the amyloid kidney than in connection with any other lesion affecting the organ.

Gross Appearances.—The amyloid kidney in its earlier stages is usually enlarged and may weigh more than double what it does normally. This increase in weight is evidently not due entirely or even largely to the amyloid, but to the fluid and colloid in the tubules. This is shown by the fact that in the late stages of the process when the kidneys sometimes show an extreme degree of

amyloid deposit they may weigh but little more than half what they should.

Amyloid formation frequently complicates other lesions of the kidney, especially vascular nephritis (arteriosclerosis) and glomerulo-nephritis, and is itself sometimes complicated by an ascending infectious nephritis.

Termination.—It is not easy to determine with certainty the effect which the presence of amyloid in the glomerular tufts and elsewhere exerts on the kidney. Certainly in the advanced stage of the process the tubules atrophy and disappear to a large extent and the kidney shrinks in size and is sclerosed. The amyloid may act mechanically only as it does in the liver, or interfere with the elimination of certain substances from the blood which thereby become injurious agents.

TOXIC NEPHRITIS

Toxins and Poisons.—Toxic nephritis is usually due to toxins derived from infectious agents, although inorganic and other poisons sometimes produce serious lesions in the kidney.

The toxins of infectious origin which most commonly affect the kidney are those derived from the streptococcus pyogenes, the diplococcus lanceolatus, the gonococcus, the diphtheria bacillus, the causal agent of scarlet fever, etc. The toxins reach the kidney through the circulation and, therefore, are ordinarily more or less uniformly distributed throughout it.

The toxins may arise from a septicemia, but usually originate in a focal lesion elsewhere in the body, commonly an endocarditis, less frequently a pneumonia, a pleuritis, or some other infectious process not so intimately associated with the circulating blood. The requirements outside of septicemias are two, a focal lesion where much toxin is produced and a toxin which is soluble and diffusible so that it may be taken into the circulation. Moreover, the toxin must be of a nature to affect the kidney; not all diffusible toxins do.

The inorganic substances which injure the kidney may be ingested accidentally (lead), or with suicidal intent (corrosive sublimate, cantharadin).

The toxins which injure the kidney may be strong and act intensely for a few days only, causing death quickly, or they may be weak and act mildly for days, weeks, months or years. We may accordingly have acute, subacute, or chronic lesions. We may also have recurrent injuries with regeneration and repair in the intervals.

Classification.—The toxic lesions of the kidney are best classi-

fied on an anatomic basis, *i. e.*, according to the part of the renal unit most affected. This classification gives four groups which form the type lesions; they are as follows:

1. Tubular nephritis.
2. Capsular glomerulonephritis.
3. Intracapillary glomerulonephritis.
4. Vascular nephritis (arteriosclerosis).

Each one of these varieties may occur practically in pure form, but the first three may be, and often are combined in varying proportions. Whether the first three can be recognized clinically as three distinct types is doubtful. While usually acute, they also occur in subacute and chronic form; vascular nephritis is always chronic.

Tubular Nephritis.—The term tubular nephritis is used when degeneration and necrosis of the renal epithelium occur as the result of the action of diffusible toxins excreted through the kidneys. The lesion is limited almost exclusively to the cortex and involves chiefly the cells lining the convoluted tubules. The lesion may be extensive and diffuse or occur in small scattered foci. It may exist by itself or complicate the different forms of glomerulonephritis. Necrosis of epithelial cells in connection with the infectious lesions of the kidney will be considered later.

Tubular nephritis may be caused by a variety of toxins and poisons, so that the resulting inflammatory reaction is not always the same. In rare instances the toxin is strong, acts quickly, and causes extensive necrosis of nearly all the epithelial cells lining the convoluted tubules. The lumina become filled with the necrotic desquamated cells which attract polymorphonuclear and endothelial leukocytes in varying numbers. Some tubules contain serum and networks of fibrin. In addition there may be some edema and lymphocytic infiltration of the connective-tissue stroma. Regeneration of epithelium from the cells not killed is very active. Mitotic figures are often numerous. The first cells formed are stretched out very thin to cover the walls of the tubules. Later the cells thicken up and gradually become differentiated like their predecessors.

When the necrotic cells occlude the tubules they cannot be washed out, but are incorporated piecemeal by the leukocytes and often also by the newly formed epithelial cells.

Lesions of this severe type commonly occur only after strong poisons. In the case pictured they followed abortion, perforation of the uterus, and streptococcus peritonitis. The kidneys were but little enlarged and, macroscopically, were not particularly striking. If the patient had survived the kidneys evidently

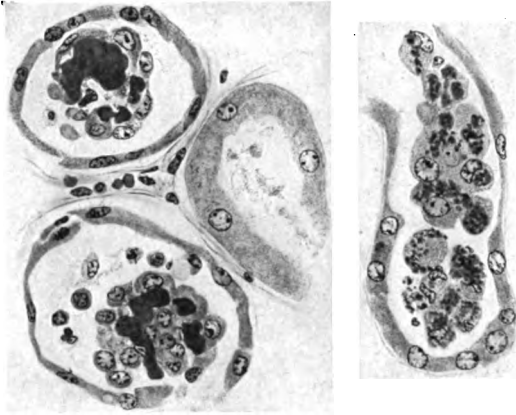


Fig. 411.—Kidney. Tubular nephritis. Necrotic desquamated epithelial cells being dissolved by endothelial leukocytes.

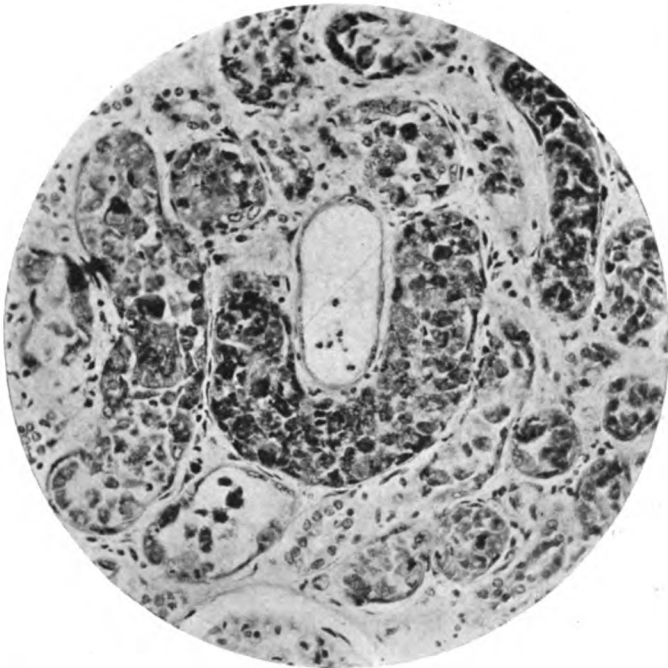


Fig. 412.—Kidney. Acute tubular nephritis. Tubules filled with necrotic desquamated epithelial cells. Regeneration occurring on the tubular wall outside of them. M.

could have been restored to the normal condition as shown by the active regeneration of the tubular epithelium. Similar lesions although rarely so extensive follow poisoning with corrosive sublimate.

The more common form of this lesion is less acute and extensive so far as necrosis is concerned, but the inflammatory reaction is usually much more marked; in fact, it often more or less com-

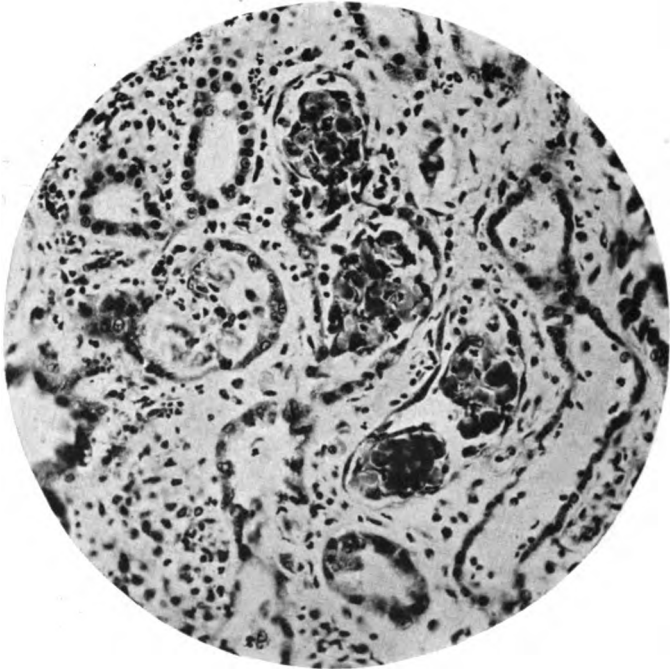


Fig. 413.—Kidney. Corrosive sublimate poisoning. Some of the tubules contain necrotic desquamated epithelial cells which are being surrounded and digested by endothelial leukocytes. M.

pletely masks the primary injury, especially if the process is seen in the later stages of repair.

This form of tubular nephritis follows such acute diseases as scarlet fever, diphtheria, typhoid fever and measles. It does not occur early in such a disease, but only after ten days to several weeks. It is characterized by hydropic and hyaline change and by necrosis of the epithelial cells lining the convoluted tubules. The necrosis is rarely extensive in any one place. It is moderate in degree and more or less scattered. But the process of degen-

eration and necrosis is continuous for some time. On this account the inflammatory reaction is usually prominent. It consists of serum, fibrin, and polymorphonuclear and endothelial leukocytes within the tubules which are often considerably dilated. Hyaline casts are also frequently present. In addition, the intertubular tissue is infiltrated with numerous lymphocytes, including plasma cells and often also with small numbers of endothelial leukocytes and an occasional eosinophile. The infiltration with lymphocytes is usually the most prominent and characteristic feature of the lesion. On this account the term acute interstitial non-suppurative nephritis has been applied to it.

Certain additional points in connection with this type of tubular nephritis deserve mention.

The toxin which causes it seems to pass, in part at least, through the glomerulus (usually without affecting it injuriously) because the epithelium at the beginning of the tubule and often within the capsular space is lifted up by a very active immigration of polymorphonuclear leukocytes.

When the lining epithelium of a tubule is destroyed and the lumen is distended and filled with endothelial leukocytes, an appearance resembling a beginning tubercle is presented. Sometimes polymorphonuclear leukocytes collect instead in the same location. The hyaline casts within the tubules often exhibit a marked attraction for leukocytes, as if some toxin were contained within them.

The lymphocytic infiltration seems to be due to diffusion of a certain amount of toxin in the intertubular tissue and to absorption of it along the lymphatics. In the later stages of repair the lymphocytes are grouped chiefly in and around the lymphatics which accompany the blood-vessels.

We have in this form of nephritis a type of lesion corresponding closely to the focal and diffuse necroses sometimes occurring in the heart after these same diseases, and also corresponding to the central and focal necroses of toxic origin in the liver; a necrosis of the important parenchymatous cells with little or no apparent injury to the surrounding endothelial cells and fibroblasts which are, therefore, left intact. The necrotic cells are invaded and dissolved

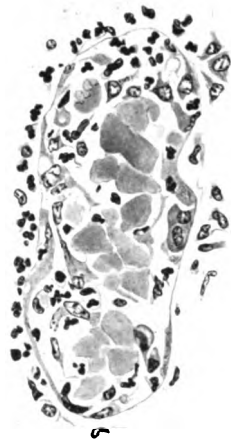


Fig. 414. — Kidney. Corrosive sublimate poisoning. Tubule contains desquamated necrotic epithelial cells and polymorphonuclear and endothelial leukocytes.

by the action of polymorphonuclear and endothelial leukocytes. The spaces formerly occupied by the parenchymatous cells are for a time filled with leukocytes, and the connective tissue in the heart and kidney is infiltrated with leukocytes, lymphocytes and sometimes with numerous eosinophiles. In this active stage the lesion resembles suppuration owing to the great number of leukocytes present, but there is no solution of the connective tissue and blood-vessels. In the kidney and liver the epithelial cells may and usually do regenerate; in the heart the muscle-cells do not.

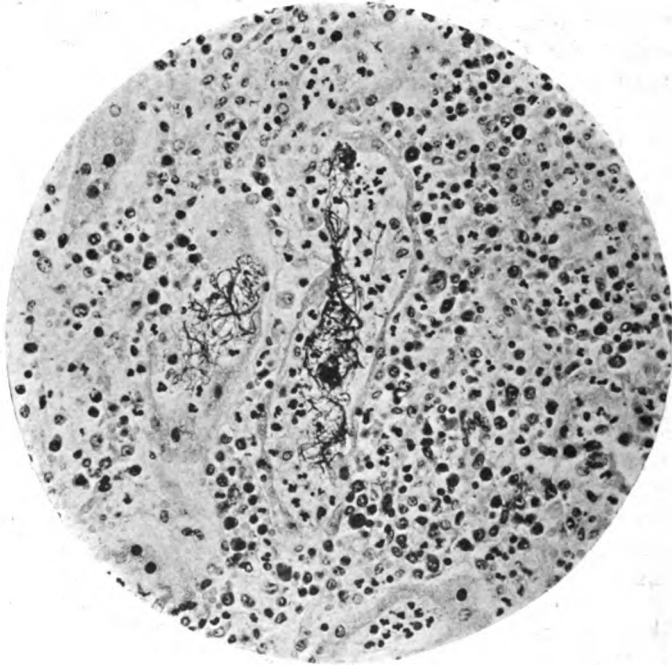

Fig. 415.—Kidney. Acute tubular nephritis occurring in scarlet fever. The tubules contain fibrin and polymorphonuclear leukocytes. The inter-tubular tissue is infiltrated with numerous lymphocytes and also with some polymorphonuclear and endothelial leukocytes. M.

Tubular nephritis following diphtheria, etc., is sometimes complicated by infectious lesions of the arteries; necrosis of the wall, fibrin deposit within and outside of the vessel, and infiltration with leukocytes and lymphocytes. The two types of lesions may overlap, but should be carefully differentiated from each other.

When these various processes of exudation and regeneration in the kidney are at all pronounced they are accompanied by more or less injection of the blood-vessels, especially of the smaller veins in

the midzonal region and in the cortex. From these dilated vessels small hemorrhages sometimes occur. These veins often contain

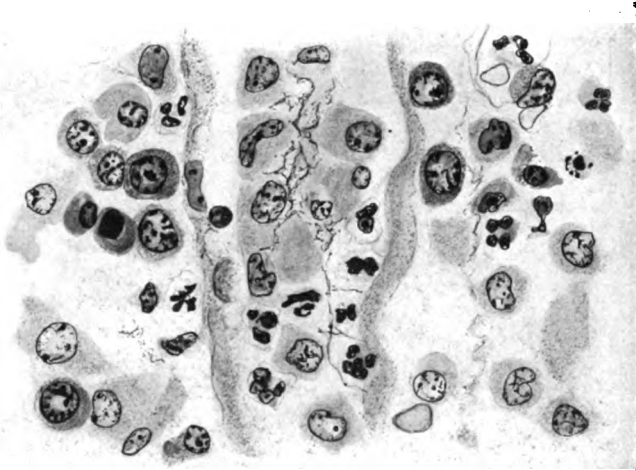


Fig. 416.—Kidney. Acute tubular nephritis. Polymorphonuclear and endothelial leukocytes and fibrin within the tubule. Similar leukocytes and numerous lymphocytes in the stroma.

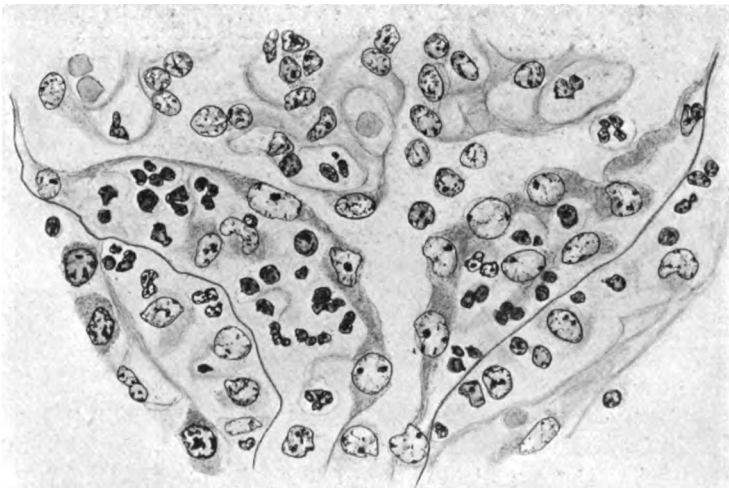


Fig. 417.—Kidney. Acute tubular nephritis. Accumulation of polymorphonuclear and endothelial leukocytes beneath epithelium of capsular space at beginning of tubule.

cells of the lymphocyte series in considerable numbers, and occasionally the cells may be found fixed in the act of emigrating.

On gross examination the slight forms of this lesion show nothing. When the process is marked, however, the inflammatory reaction leads to very noticeable enlargement of the kidneys which are sometimes two, three and even four times the normal size. When the capsule is incised it may separate spontaneously from the surface. If the lesions are focal they may appear on section of the kidney as greyish streaks and areas situated in the cortex and midzonal region and surrounded by injected blood-vessels. When the process is extreme and diffuse the cortex is swollen, soft, almost

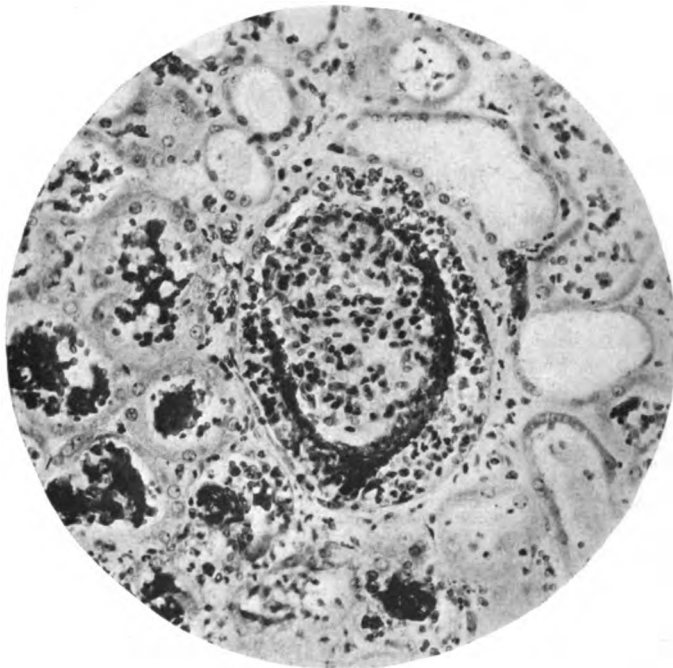


Fig. 418.—Kidney. Acute capsular glomerulonephritis complicated by hemorrhage. M.

diffluent and presents a mottled combination of grey and red; the normal markings are completely obscured.

This type of lesion is found most commonly in children from three to five years of age, but may occur at an earlier or later period of life.

Experimental.—Tubular nephritis in varying degrees of intensity may be produced experimentally by a number of different chemical substances, such as uranium nitrate, for instance. It may be produced in the rabbit by large doses of purgatin.

Capsular Glomerulonephritis.—This term is applied to an inflammatory reaction to toxins taking place within the capsular space around the glomerulus. The reaction may consist of several different elements, of an exudation of serum containing albumin, of an immigration of polymorphonuclear and endothelial leukocytes, and of a proliferation of the epithelial cells lining the capsular space. This reaction may be complicated by hemorrhage or by the formation of fibrin. According as one element or another predominates, the terms exudative or proliferative capsular glomerulonephritis

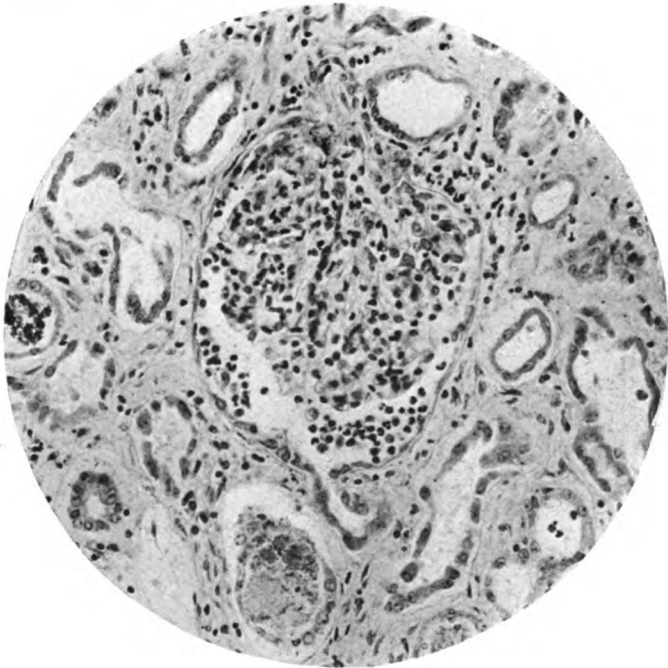


Fig. 419.—Kidney. Acute capsular glomerulonephritis. Numerous polymorphonuclear leukocytes in the somewhat dilated capsular space. M.

are used. When hemorrhage occurs it is usual to say acute hemorrhagic nephritis without reference to the real lesion which underlies it. The various types of reaction depend on differences in the character and strength of the toxins brought to the glomerulus and excreted from it.

Exudative Type.—When the reaction is exudative the fluid portion for the most part flows away with the urine. Only the fibrin which forms out of it and the cellular elements tend to remain. The capsular space is usually more or less widely dis-

tended, and the epithelial cells lining the parietal wall and covering the tuft occasionally contain hyaline droplets, similar to those which occur so frequently in the cells of the tubules. Within the dilated capsular space polymorphonuclear leukocytes may be present in small to large numbers according to the activity of the reaction. Many of these leukocytes pass into the tubules where some of them may undergo necrosis on their way to the pelvis of the kidney. Endothelial leukocytes are found in the exudation only in very small numbers; occasionally one of them will contain in its cytoplasm a polymorphonuclear leukocyte. Fibrin may occur as a delicate meshwork or in dense hyaline masses.

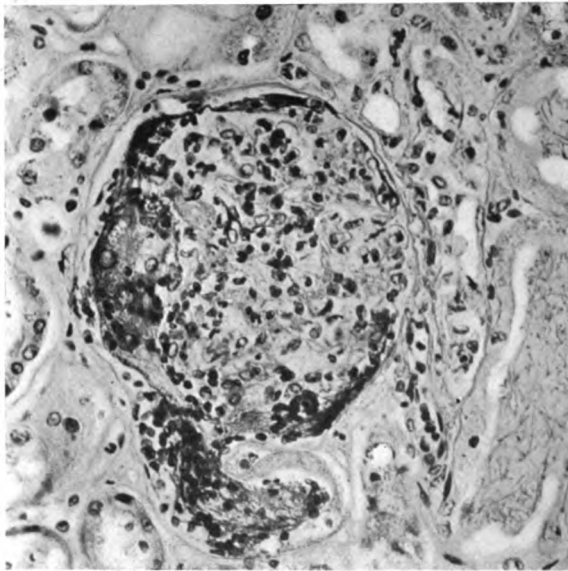


Fig. 420.—Kidney. Acute hemorrhagic nephritis. Red blood-corpuscles and fibrin within capsular space and beginning of tubule. Serum and fibrin in an adjoining tubule. M.

Both kinds of leukocytes emigrate chiefly from the capillaries of the tuft, but occasionally come from the vessels outside of the capsules. To find a leukocyte migrating into the capsular space from either source is difficult unless the tissue is fixed very quickly postmortem.

Lymphocytes and eosinophiles apparently are never attracted into the capsular space.

The exudative type of reaction is usually complicated by more or less proliferation and desquamation of the capsular epithelium, both from the parietal wall of the capsule and from the surface of

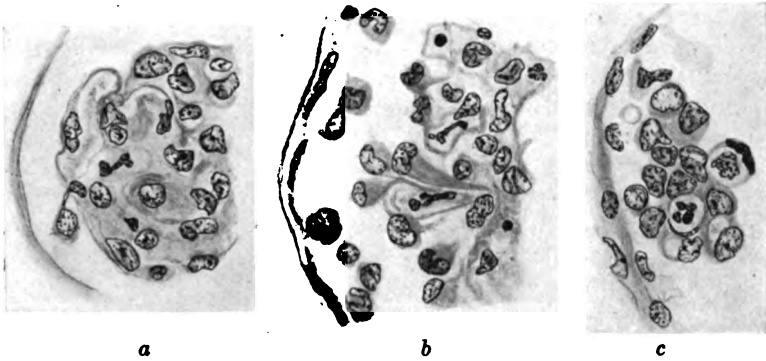


Fig. 421.—Kidney. Acute capsular glomerulonephritis. *a*, Emigration of endothelial leukocyte into capsular space; *b*, proliferation and desquamation of capsular epithelium; *c*, epithelial cells and two phagocytic endothelial leukocytes in capsular space.

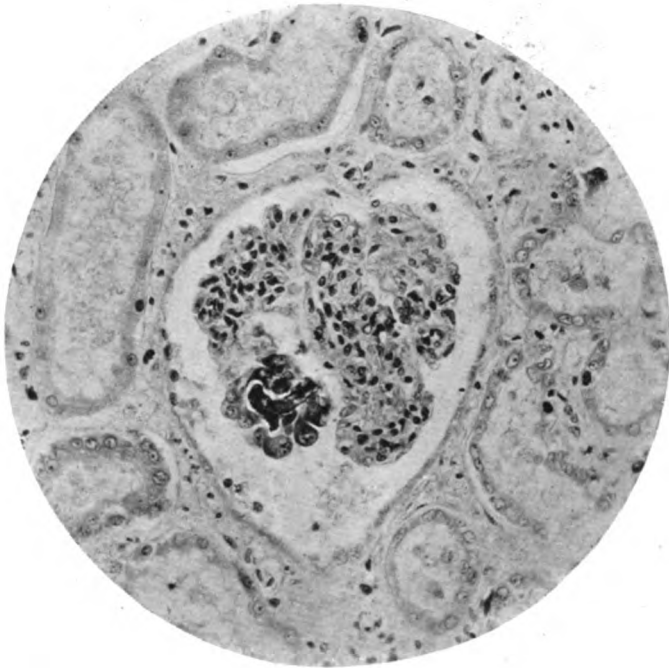

Fig. 422.—Kidney. Acute glomerular and tubular nephritis. Proliferation of capsular epithelium around a small mass of fibrin. M.

the tuft. The cells from the latter situation often present a tailed appearance, just as the cells do in the deeper layer of the pelvis of the kidney. After desquamation the cells tend to assume a more or less spherical shape with an excentrically situated nucleus, and resemble endothelial leukocytes; but they are smaller, are not phagocytic for other cells, and have the peculiarity of applying themselves to the surface of any fibrin formed in their neighborhood. These cells, like the polymorphonuclear leukocytes, often pass into the tubules, sometimes in large numbers. When nu-

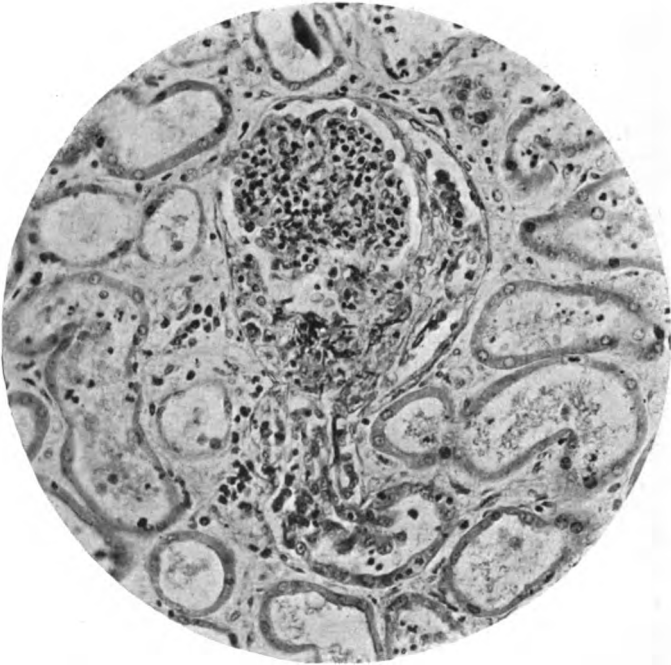


Fig. 423.—Kidney. Acute capsular glomerulonephritis. Numerous epithelial cells in dilated capsular space and in beginning of tubule, where one mitotic figure can be made out near its beginning. M.

merous and packed in the capsular space these cells become flattened.

Proliferative Type.—In many cases of capsular glomerulonephritis the reaction consists chiefly of proliferation and desquamation of the epithelial cells lining the capsular space. Mitotic figures are found in sufficient numbers (frequently two in a single section through a glomerulus) to account for all the cells formed. They occur in cells lining the parietal wall and covering the tuft,

and also in all layers of the masses of cells which collect together as the result of desquamation. These cells do not proliferate on account of injury to other epithelial cells adjoining them, as occurs in tubular nephritis where simple regeneration takes place, but because they are needed to counteract, probably by means of the production of an antitoxin, the toxins which filter through the wall of the tuft. They play the part acted elsewhere by the endothelial leukocyte. No analogous reaction, at least to anything

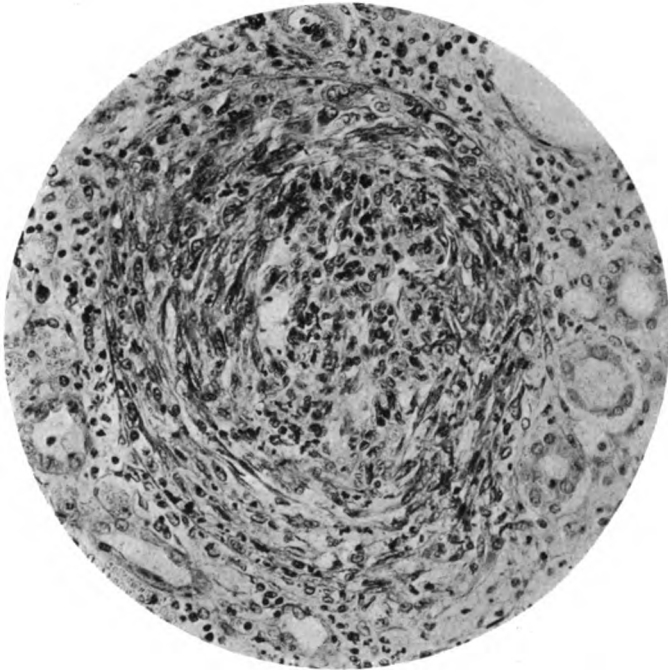


Fig. 424.—Kidney. Acute capsular glomerulonephritis; capsular space distended and filled with proliferated epithelial cells. One mitotic figure present along outer border of upper left quadrant. M.

like the same extent, on the part of epithelial cells seems to occur in any other part of the body.

These desquamated cells when numerous form a crescentic mass within the capsular space with the thin edge toward the base of the tuft where the vessels enter and leave, and with the thickest part usually opposite the beginning of the tubule which they more or less completely occlude. Frequently the mass of cells projects for some distance into the tubule. The cells when numerous appear flattened probably from pressure, although the polymor-

phonuclear leukocytes among them preserve their spherical and ameboid forms.

Fibrin is often associated with these cells in the form of delicate fibers and sheets which run everywhere between them, or as solid masses.

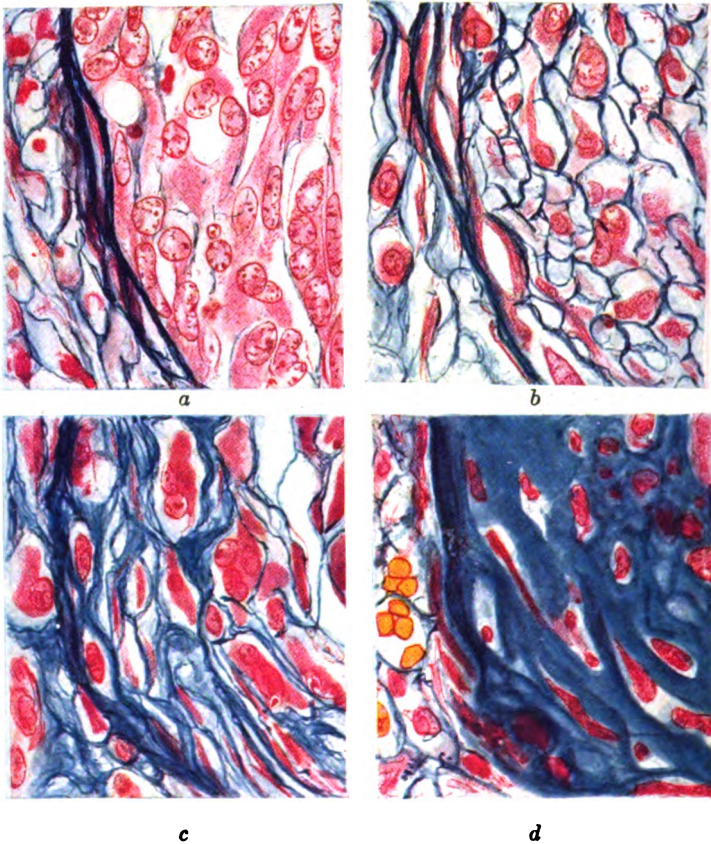


Fig. 425.—Kidney. Capsular glomerulonephritis. Four stages in the deposition of collagen fibrils between the proliferated epithelial cells in the capsular space.

It is possible to conceive of the leukocytes and proliferated epithelial cells disappearing entirely from the capsular space, when the purpose for which they are collected there is accomplished, and of the glomerulus regaining its normal function. As a rule, however, this return to the normal condition is prevented owing to the formation of fibrin. As soon as fibrin appears in the capsular

space it stimulates the fibroblasts in the tuft and in the capsule, wherever it happens to touch them, so that they proliferate and grow into it and organize it just as occurs elsewhere in the body when fibrin is formed. Collagen fibrils take the place of the fibrin. The epithelial cells which lined the surface of the fibrin thus come to line the connective tissue. In this way the capsular space may be divided into a number of small epithelial-lined cavities resembling glands. The process is analogous on a small scale to what takes place in the pleural cavity in the organization of a fibrinous

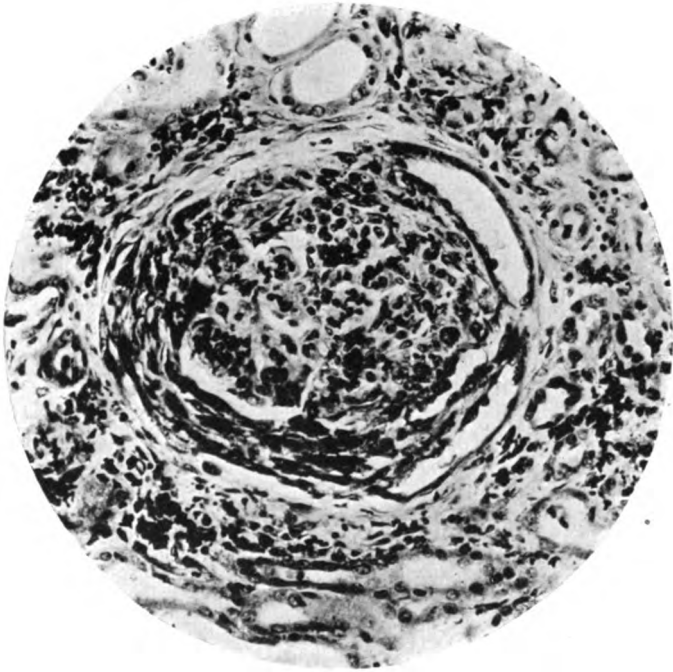


Fig. 426.—Kidney. Capsular glomerulonephritis. Proliferated capsular epithelium on one side; two gland-like cavities formed on the other by in-growth of fibroblasts. M.

exudate, with the resulting formation of solid and stringy fibrous adhesions and gland-like cavities. In time the epithelial cells more or less completely disappear and the newly-formed connective tissue contracts, squeezing the tuft in a strangle hold which destroys its power of functioning and obliterates the capsular space.

In other capsular spaces the connective tissue very early grows in between all the cells and no gland-like cavities result when organization takes place. In still other capsular spaces the fibrin has

been deposited irregularly in masses so that the resulting fibrous tissue affects only a small part of the capsular space; the rest is normal.

It is difficult to state the exact duration of the different types of reaction in the capsular space. When the reaction consists chiefly of an exudation of polymorphonuclear leukocytes the duration is a matter of days only. When it consists of proliferation of the capsular epithelium it is a matter of two to several weeks, possibly longer in certain instances. The important fact to bear in mind is

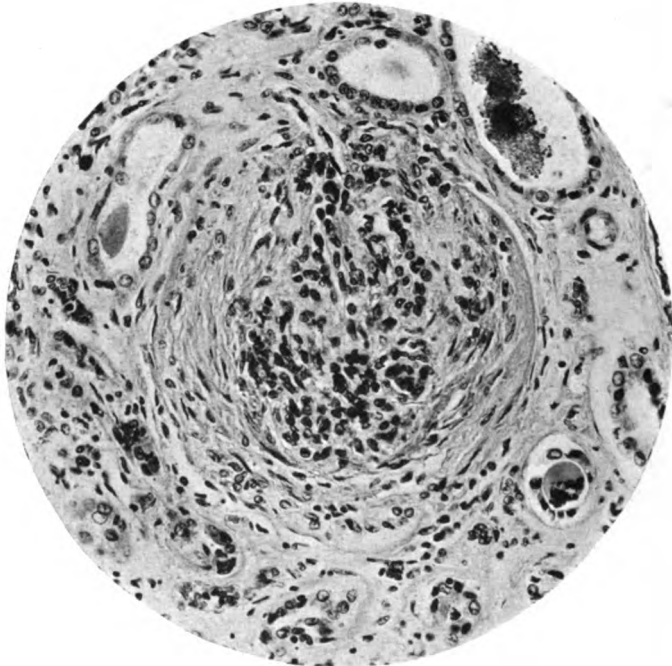


Fig. 427.—Kidney. . . Capsular glomerulonephritis; late stage showing ingrowth of fibroblasts and production of much collagen. The tuft shows a late stage of the intracapillary lesion. M.

that if the toxins requiring elimination do not kill the patient in the early stage, the process of repair is very likely to do so later.

While these changes are taking place in the capsular spaces, certain others may occur in other parts of the kidney.

The capillaries of the tuft often contain large numbers of leukocytes, but this condition will be considered under intracapillary glomerulonephritis.

The epithelium lining the convoluted tubules may show hy-

dropic and colloid degeneration and contain fat in greater or less abundance. Occasionally some of the cells undergo necrosis as in tubular nephritis.

The convoluted tubules are usually more or less distended with fluid and contain finely granular material (coagulated albumin as the result of fixation) and delicate circles. In addition, they may contain polymorphonuclear leukocytes, desquamated epithelial cells from the capsular spaces, fibrin, and hyaline and granular casts. Where the epithelial cells from the capsular space come in contact with fibrin they apply themselves to its surface. In other places the epithelium of the tubule may grow over the surface of fibrin and enclose it, apparently using it as a source of nutrition.

The tubules of the pyramids usually contain numerous hyaline and granular casts.

The connective-tissue stroma of the kidney, as a rule, shows more or less edema and may contain polymorphonuclear leukocytes and endothelial leukocytes in small numbers, especially around the glomeruli when exudation is abundant in the capsular spaces.

Occasionally small foci of lymphocytes, including plasma cells are present.

Intracapillary Glomerulonephritis.—This term is applied to the reaction to toxins acting within the capillaries of the tuft. Sometimes the reaction is limited sharply to these vessels; at other times more or less toxin passes into the capsular space and occasionally into the tubules and leads to a reaction there also.

The toxins which cause intracapillary glomerulonephritis are derived chiefly if not entirely from various infectious micro-organisms. Consequently they vary much in strength and character. Moreover, some act for a short time only, while others exert their influence over a long period. In consequence of these variations in the nature, strength and length of time of action of the toxins, the resulting lesions may differ much from each other.

It is usually not possible to demonstrate any definite injury caused in the glomerulus by the toxins, except so far as shown by the presence of fat-droplets in the cells. In certain instances, however, more or less necrosis is evident in the walls of the capillaries. It may affect the vessels throughout the tuft or be confined to a lobule or to part of one. It is usually accompanied by the formation of fibrin within the capillaries which may in consequence be occluded.

The reaction within the glomerulus may be evidenced by the formation of fibrin or by the accumulation of polymorphonuclear or endothelial leukocytes. Each of these elements may occur by itself or they may be variously combined. As a rule, fibrin occurs in the most acute lesions, polymorphonuclear leukocytes in

the less acute lesions, and endothelial leukocytes when the process is comparatively slow. The nature of the toxins probably plays some part, however. Occasionally eosinophiles are present.

Rarely the formation of fibrin within the capillaries of the glomerulus is the only striking evidence of a lesion in the kidney. The fibrin may occur in threads and networks, or in solid masses and more or less completely occlude the vessels. It is probably due to a strong toxin causing direct injury (necrosis) of the capillary wall. The injury is, however, not always evident. This type of lesion is

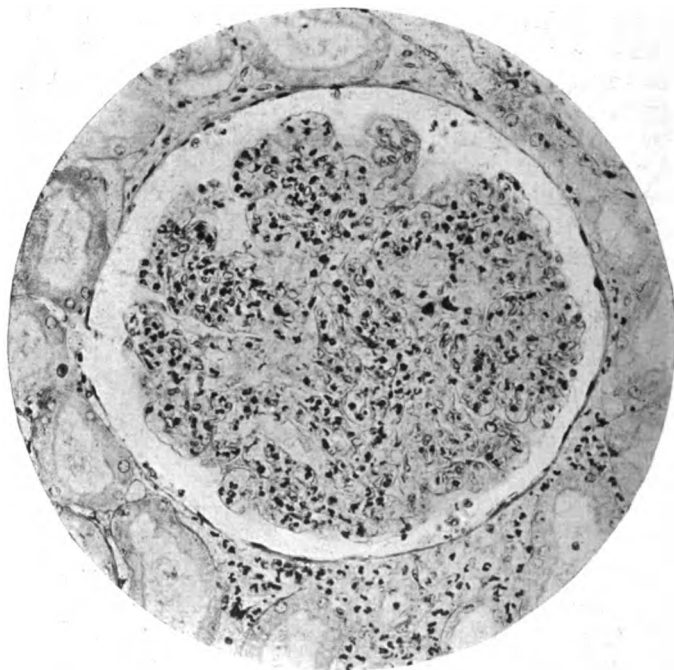

Fig. 428.—Kidney. Acute intracapillary glomerulonephritis. The capillaries contain many polymorphonuclear leukocytes. M.

relatively common in infections with the plague bacillus, but occurs occasionally also with other organisms, for example, the staphylococcus pyogenes aureus and the micrococcus lanceolatus. It can be produced experimentally in animals by the injection of diphtheria toxin.

A lesion easier to understand consists of the accumulation of polymorphonuclear leukocytes in large numbers within the capillaries, so that many or all of the vessels are distended and plugged with them. As a result, the glomeruli are considerably enlarged

and the number of nuclei appearing in a section through one of them may be several times as many as normal.

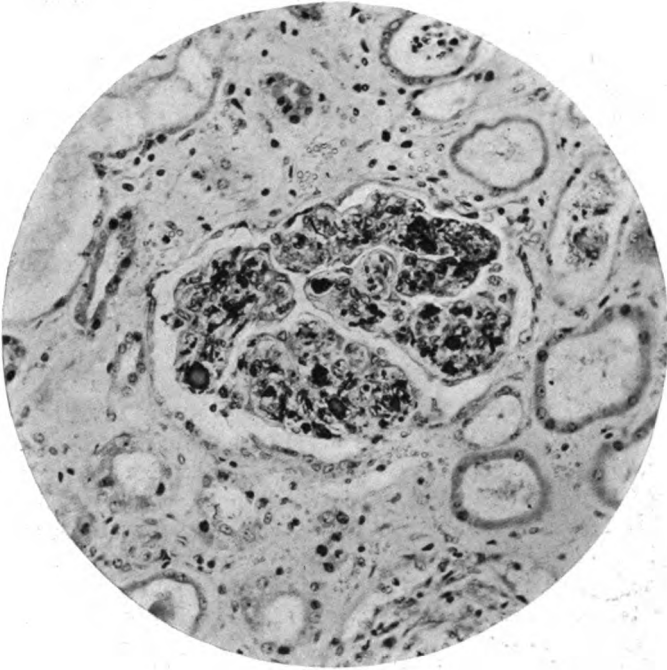


Fig. 429.—Kidney. Acute intracapillary glomerulonephritis. The capillaries are occluded with leukocytes and much fibrin. M.

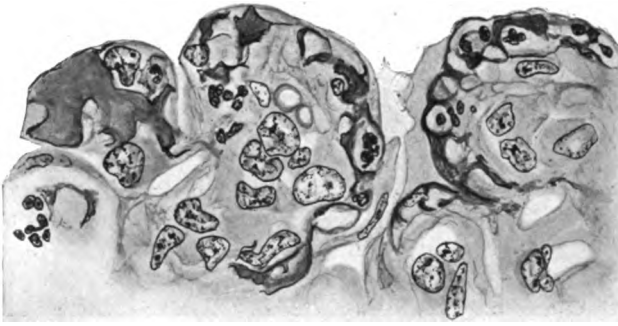


Fig. 430.—Kidney. Acute intracapillary glomerulonephritis. Capillaries of glomerular tuft occluded by fibrin and polymorphonuclear leukocytes.

This type of lesion is most common in connection with septicemia due to the streptococcus pyogenes.

Endothelial leukocytes often occur in various proportions in connection with the polymorphonuclear leukocytes. When the reaction within the glomerulus is not very acute and intense, however, the cell accumulation is limited almost entirely or even exclusively to the endothelial leukocytes. Some of these leukocytes are unquestionably brought by the blood stream. Most of them, however, are derived directly by proliferation and desquamation from the endothelial cells lining the capillaries. Mitotic figures are by no means uncommon in the earlier stages of the lesion.

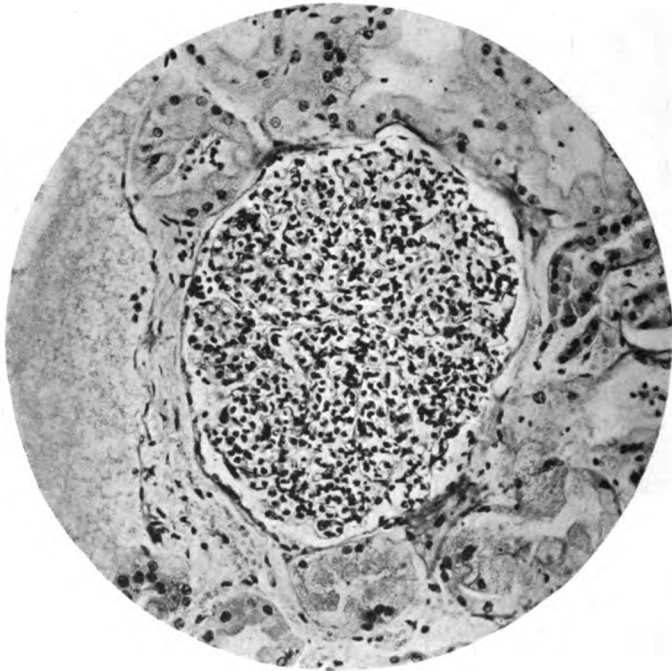

Fig. 431.—Kidney. Acute intracapillary glomerulonephritis. The capillaries are distended with polymorphonuclear leukocytes. M.

The endothelial cells and leukocytes distend and more or less completely occlude the capillaries, and many of them exhibit ameboid forms. Very rarely they show phagocytosis for polymorphonuclear leukocytes. Eosinophiles are often associated with them; one to four and even as many as ten may occur in a section through a single glomerulus.

As the result of the accumulation of endothelial leukocytes in the capillaries the glomeruli appear more or less enlarged and in stained sections they are seen to contain many more nuclei than

normally. Not infrequently a part of a lobule of the tuft will project from the capsular space into the beginning of the tubule. Usually the capsular space appears obliterated.

When the reaction is distinctly intracapillary in character, and the lesion is in its early stages, the normal lobulation of the tuft is usually more or less completely obscured, because the dilatation of the capillaries forces the lobules close together. As a rule, the epithelium lining the capsular space is not prominent, although the cells sometimes contain numerous hyaline droplets.

Repair.—When the toxins are strong and the reaction is intense so that the fibrin and leukocytes occlude the capillaries more or less completely, death may occur from uremia in a few days or weeks. When, however,

the toxins are mild and their action is prolonged, certain changes of a reparative nature gradually take place in the tuft. The fibroblasts forming the supporting walls of the capillaries are stimulated to increased activity, possibly to regenerative proliferation, so that the collagen fibrils are increased in amount at the base of the tuft and running through the center of each lobule.

As the connective tissue thickens and contracts the lobules are drawn apart so that at this stage, some-

times called subacute glomerulonephritis, the glomeruli are very distinctly and even prominently lobulated. Capillaries can be made out in them only here and there. As further contraction takes place the capillaries are completely obliterated and the lobules shortened and approximated, so that the tuft is finally reduced to a small spherical non-vascular mass of hyaline connective tissue containing a few fibroblasts. It has become a sclerosed glomerulus. This slow process of repair terminating in sclerosis of the glomeruli lasts sometimes for weeks and months.

The changes in the tubules vary according to the severity and duration of the lesion in the kidney, and especially according to the amount and character of the toxin which escapes through the glomeruli.

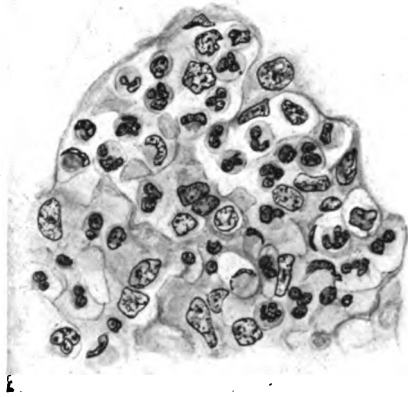


Fig. 432.—Kidney. Acute intracapillary glomerulonephritis. Numerous polymorphonuclear leukocytes within capillaries in a lobule of a glomerular tuft.

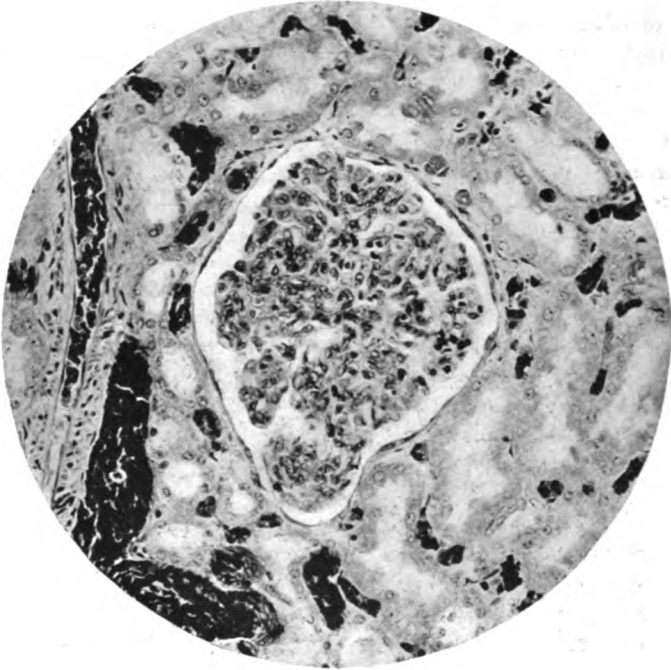


Fig. 433.—Kidney. Acute intracapillary glomerulonephritis. The capillaries are distended with endothelial cells and leukocytes. One lobule of the tuft is forced into the beginning of the tubule. M.

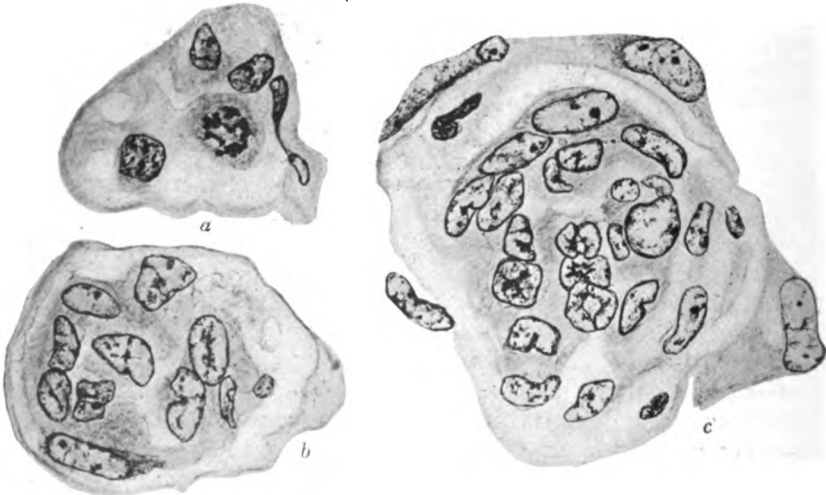


Fig. 434.—Kidney. Acute intracapillary glomerulonephritis. Proliferation of endothelial cells in capillaries of glomerular tuft. Mitotic figure in *a*.

As a rule, the tubules are more or less distended with fluid (edema) while the lining epithelium is flattened. In sections of fixed tissue the lumina contain granular material and circular reticulum (possibly the hardened albuminous covering of drops of fluid). The epithelial cells of the convoluted tubules, instead of being flattened may be swollen, and the cytoplasm may contain large numbers of hyaline droplets of all sizes.

If much toxin has escaped into the tubules, necrosis of epithelium may have occurred here and there. Polymorphonuclear

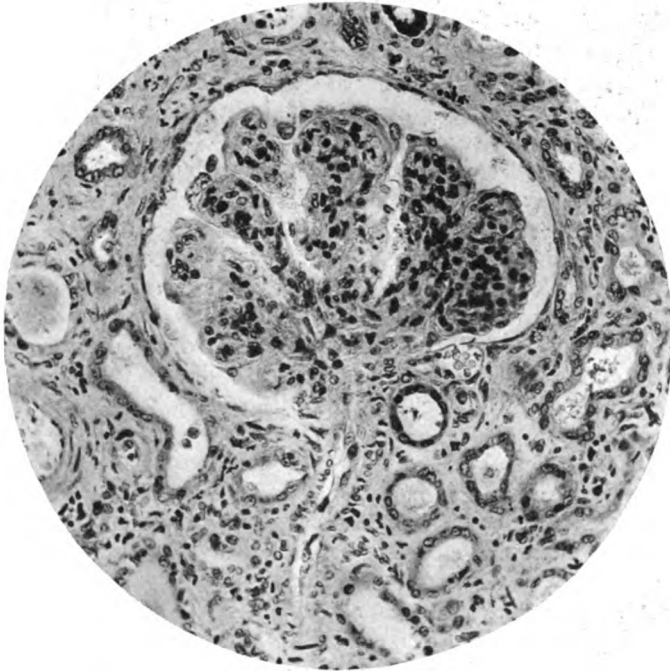


Fig. 435.—Kidney. Subacute intracapillary glomerulonephritis. Lobulation of the tuft is well marked. The capillaries are distended and occluded with endothelial cells and leukocytes. M.

leukocytes and red blood-corpuscles are occasionally numerous. Fibrin sometimes is present; rarely it is abundant. Fat occurs, especially if the process has lasted some time.

Many hyaline casts are sometimes present, particularly in the tubules of the pyramids.

In the late stages of intracapillary glomerulonephritis the tubules may show considerable atrophy. The lining epithelium is narrowed, less differentiated and less prominent.

The connective tissue may show little change beyond edema and in the late stages a moderate amount of increase. When, however, the glomerular process is acute and severe and is complicated by a certain amount of tubular nephritis, the connective tissue may be infiltrated with numerous polymorphonuclear leukocytes, especially around the capsules of the glomeruli, and may contain many small and large foci of lymphocytes.

Gross Appearance.—In the early stages of intracapillary glomerulonephritis the kidney is usually much increased in size. It may weigh up to double the normal, but very rarely more. The increase is due chiefly to edema, as the cellular increase caused by the leukocytic infiltration is comparatively slight. In the late stages of the process the kidney shrinks to normal or below, owing to diminution of the fluid, atrophy of the tubules, and contraction of the connective tissue.

The shape of the kidney remains symmetric throughout with this type of lesion; but the surface becomes finely granular in the contracted stage.

The color of the kidney is pale owing to obstruction of the capillaries in the tuft (large and small white kidney). The blood does not pass readily through these vessels; in consequence the veins are not distended. This condition combined with more or less edema causes pallor. Fat in epithelial cells of the convoluted tubules causes yellowish white to white specks in a greyish background.

On section the glomeruli in the early stages, when they are enlarged, may project above the cut surface as greyish points or dots.

Vascular Nephritis (Arteriosclerosis).—The primary lesion in vascular nephritis is located in the blood-vessels, especially in the smaller arteries of the cortex and in the capillaries of the glomerular tufts. The lesion is similar in character to that which occurs in the aorta and other blood-vessels in general arteriosclerosis and is a part of the same general process. It is a retrograde process characterized by the presence of much fat in the injured cells. The cells most affected are the fibroblasts beneath the lining endothelium. In addition, however, smooth muscle-cells if present are also often involved, and not infrequently the lining endothelium itself is ultimately affected. Fat set free by necrosis of any of these cells is taken up by endothelial leukocytes. Necrotic fibroblasts are replaced by regeneration in excess so that the vessel walls are thickened and the lumina narrowed. The elastic tissue is produced in increased amount by the fibroblasts. The muscle-cells may entirely disappear.

When the lining endothelial cells are destroyed, fibrin formation (thrombus) commonly occurs and produces partial to complete

occlusion of the part of the vessel affected. Later, the fibrin is invaded and replaced by fibroblasts. In this way irregular thickening and frequently occlusion of the vessels is produced. The process is chronic, lasting usually over many years; it is also frequently intermittent; but in suitable cases all stages in the development of the lesions can be found.

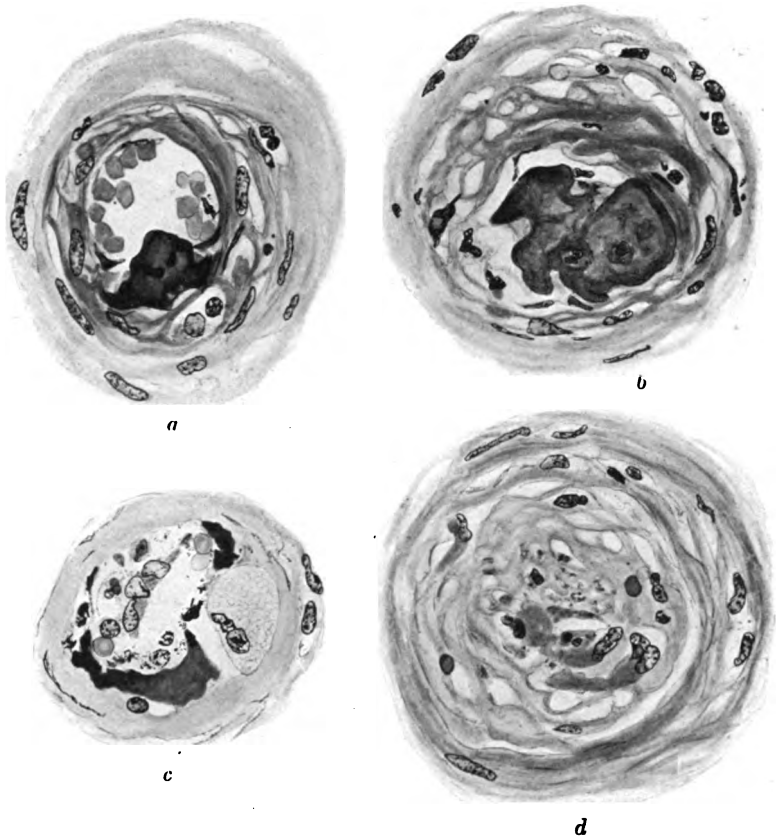


Fig. 436.—Arteries. Kidney. Vascular nephritis. *a*, Thrombus attached to wall; *b*, thrombus occluding lumen; *c*, thrombus attached to wall; endothelial leukocyte filled with fat-droplets in intima; *d*, lumen occluded by organization of thrombus.

As the result of occluded capillaries and arteries many glomeruli become in part or entirely sclerosed. Sclerosis of a glomerulus is followed by atrophy and disappearance of its subtending tubule, and by contraction and hence thickening of the surrounding connective tissue.

The primary vascular lesion is diffusely and irregularly distributed throughout the kidney and may in time affect many

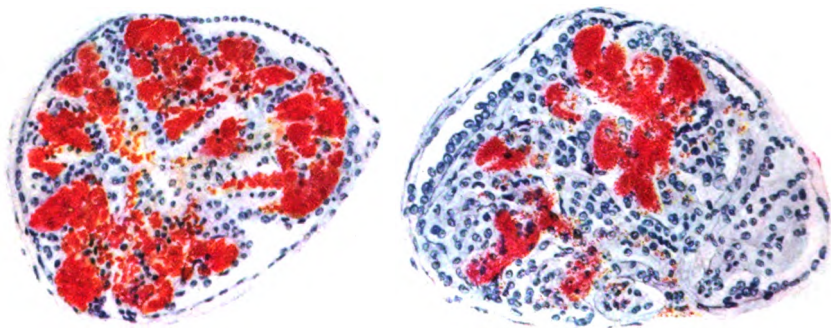


Fig. 437.—Kidney. Vascular nephritis. Accumulation of fat in glomerular tufts.

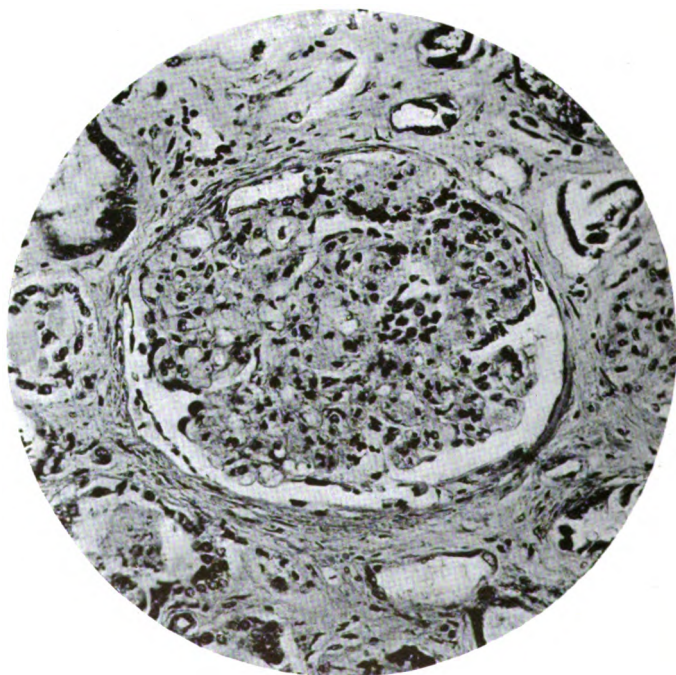


Fig. 438.—Kidney. Vascular nephritis. Numerous endothelial leukocytes filled with fat-droplets are present in the glomerular tuft. M.

glomeruli, thereby causing destruction of a large part of the kidney involved. It is evidently toxic in origin, but as it often leads, by

narrowing the lumina of vessels, to interference with the blood supply in adjoining parts of the kidney, secondary lesions due to lack of nutrition arise. It is probable that the two types of lesions cannot always be distinguished from each other.

The lesion in the arteries resembles in all essentials that found elsewhere in the body in general arteriosclerosis. It consists of degeneration of the cells as shown by the presence of numerous fat-droplets in them. In the larger vessels the fibroblasts of the intima are usually the cells most affected, but in the smaller vessels all the cells in the wall are generally involved. The smooth muscle-cells disappear. The vessel wall may appear in a Scharlach R. stain as if composed of fat, and by other stains swollen and hyaline. If the cells become necrotic the free fat is taken up by endothelial leukocytes which may elevate the lining endothelium to such an extent that the lumen of a vessel is almost completely obliterated. Necrosis of fibroblasts is slowly followed by regeneration in excess of the normal condition, so that the wall of the vessel is thickened and the lumen more or less narrowed. An abundance of elastic tissue is usually produced by these new fibroblasts.

If the lining endothelium is destroyed the lesion is usually complicated by the formation of fibrin which may appear in a small or large mass on one side of the lumen, or form a uniform layer around the inside of the vessel, or completely occlude it. Fibrin formation occurs much more commonly in the smaller arteries, and especially in the afferent vessels of glomeruli. The fibrin is gradually organized by fibroblasts and thus replaced by connective tissue.

The lesions in the capillaries of the glomerulus are similar to those in the arteries. One or several or all of the capillaries of a glomerulus may be affected. Both the endothelium and the fibroblasts may be injured and contain much fat. If the fibroblasts become necrotic the fat thus set free may be taken up by endothelial leukocytes which sometimes infiltrate the glomerulus in large

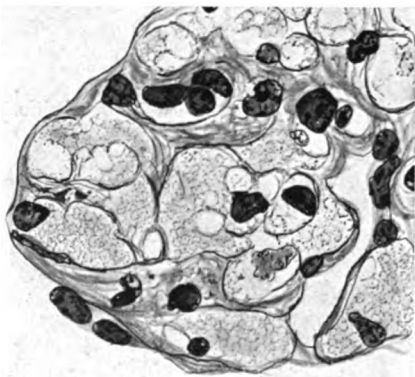


Fig. 439.—Kidney. Vascular nephritis. Endothelial leukocytes filled with fat-droplets in lobule of glomerular tuft.

numbers. Except for some increase in the connective tissue due to regeneration of the fibroblasts, such a glomerulus probably may be restored to its normal condition and function.

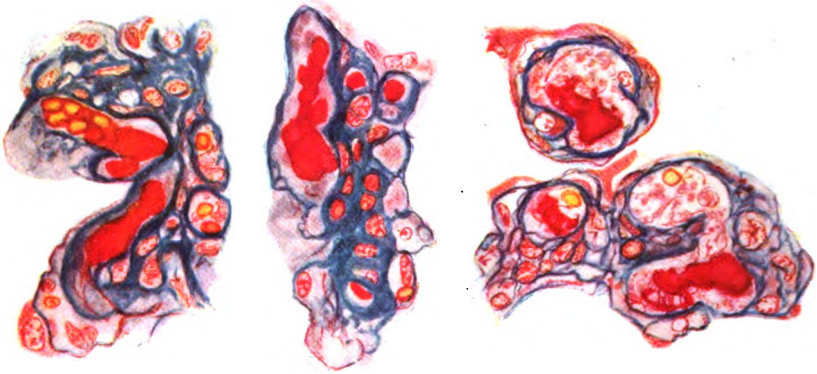


Fig. 440.—Kidney. Vascular nephritis. Fibrin thrombi forming in capillaries of glomerular tufts and enclosing red blood-corpuscles.

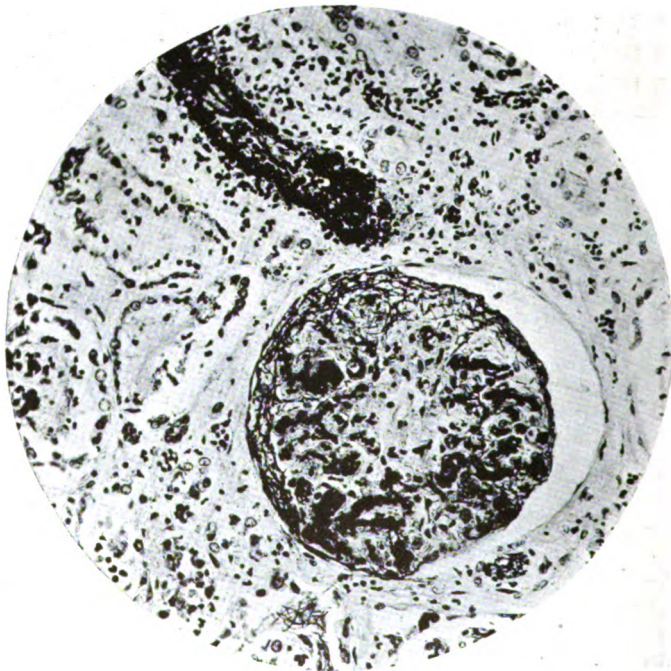

Fig. 441.—Kidney. Vascular nephritis (arteriosclerosis). Infarction of the tuft owing to thrombosis of the afferent artery. M.

If the endothelium is destroyed, fibrin usually forms, often involving the red blood-corpuscles present in the vessel, occludes the lumina of one or more capillaries, and leads to organization by fibroblasts. In this way one or more lobules or the whole glomerulus becomes non-vascular and transformed into a mass of fibroblasts; the collagen fibrils produced by them contract, most of the cells atrophy and disappear, and the glomerulus in part or entirely becomes sclerosed, that is, reduced to a shrunken hyaline mass of connective tissue.

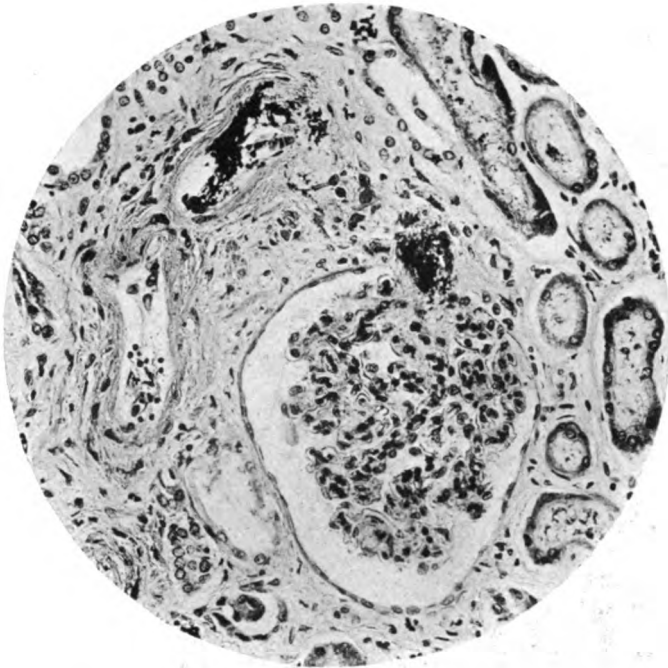


Fig. 442.—Kidney. Vascular nephritis (arteriosclerosis). The afferent artery is almost occluded by thrombus formation. M.

If the occlusion of the afferent vessel of a glomerulus, or of any of its branches, is produced suddenly infarction may take place; the back pressure of the blood causes marked distension, and hemorrhage into the capsular space and subtending tubule may occur. The infarction may lead also to fibrin formation in the capsular space and to leukocytic infiltration. Organization of the fibrin results often in partial to complete obliteration of the capsular space.

Sclerosed glomeruli often occur in clumps, perhaps because they

derive their blood supply from a common arteriole, which, if partially occluded owing to sclerotic changes, would supply them with less nutrition than they need.

Accompanying and following the changes in a glomerulus which result in its sclerosis, its tubule undergoes a retrograde change. The lining epithelial cells lose their differentiated structure; the cytoplasm shrinks, the cells become low and atrophic instead of more or less columnar, the tubule becomes smaller and smaller, and finally seems to disappear entirely.

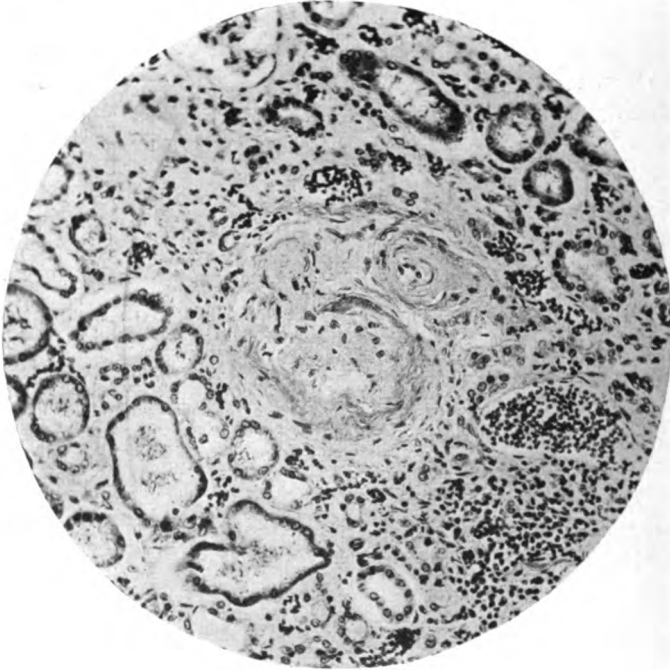


Fig. 443.—Kidney. Vascular nephritis (arteriosclerosis). Sclerosis of glomerulus following sclerosis of afferent artery. M.

Other tubules may be much dilated and their epithelium greatly thinned, probably as a result of more or less occlusion of the tubule lower down, owing to compression due to shrinking of the surrounding connective tissue or to the presence of casts.

Here and there the epithelium in the tubules contains much fat, but in other places it shows no trace of it.

The connective tissue in the arteriosclerotic kidney thickens up in the glomeruli and arteries as a result of regeneration when fibroblasts have undergone necrosis. It is newly-formed as the result

of the organization of fibrin deposited within the arteries, in the capillaries of glomeruli, and sometimes within the capsular spaces. It thickens up between the tubules and vessels owing to contraction wherever glomeruli have shrunken as the result of sclerosis and tubules have atrophied and disappeared.

Wherever a glomerulus has become sclerosed, its tubule atrophied or gone, and the surrounding connective tissue contracted and, therefore, apparently increased in amount, more or less infiltration of the connective tissue with cells of the lymphoblast series is usually present.

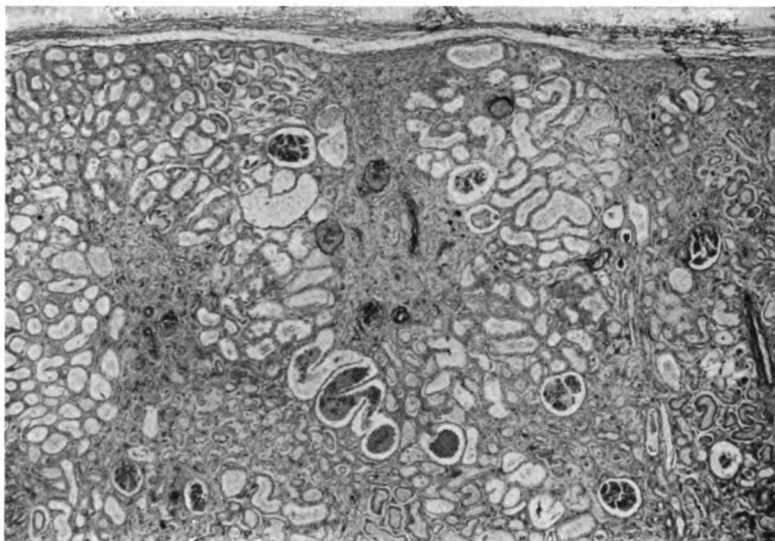


Fig. 444.—Kidney. Vascular nephritis. Sclerosed glomeruli and blood-vessels, atrophied tubules, contraction and relative increase of connective tissue, infiltration with lymphocytes. Dilatation of some of the persisting tubules. M.

Eosinophiles and mastcells are also occasionally found in small numbers.

Gross Appearance.—In the arteriosclerotic kidney the primary lesion located in the blood-vessels is followed by sclerosis of glomeruli and atrophy and disappearance of tubules. Hence the kidney gradually diminishes in size, often to less than half the normal condition. As the process is fairly uniformly distributed, in small and not in large foci, the shape of the kidney is usually not altered. The cortex on section is noticeably thinned and may measure only two or three mm. in thickness instead of five to six mm. The pyramids are correspondingly shrunken. The capsule usually

strips less readily than normally, leaving a finely granular surface where the depressions correspond to the atrophied areas and the projecting granules to the more normal parts. Small cysts are often present.

The veins are often more or less congested, but not necessarily so. The consistence of the kidney is increased because many glomeruli are sclerosed, the tubules are diminished in number, and the connective tissue contracted and hence thickened.

It is not usual to find a simple, uncomplicated arteriosclerotic kidney. Other renal processes are often combined with it in various degrees, such as pyelonephritis, amyloid formation and different types of glomerular lesions.

The arteriosclerotic kidney usually occurs at a more or less advanced age. At least it is not common before the age of forty. It arises as the result of toxins acting intermittently or continuously for many years. Occasionally, however, toxins of the appropriate character and strength will bring about the typical lesions of advanced arteriosclerosis in the aorta, kidney and other organs at a very early age, for example, in a boy of sixteen and a woman of twenty-two.

What the nature of these toxins is has not yet been determined. Lead poisoning and syphilis are two causes often blamed. In the different varieties of acute nephritis lesions of the blood-vessels, and especially of the capillaries of the glomeruli, are not at all uncommon. They probably account for many of the sclerosed tufts found even in small children. Probably in old people an arteriosclerotic kidney is the result of various toxins acting intermittently and continuously over many years.

INFECTIOUS LESIONS

Under this heading are included all the lesions due to the immediate presence of infectious organisms in the kidney. These lesions are frequent and important. When they are undergoing repair or are healed, the manner of their origin is often overlooked or not recognized.

In certain infectious processes, such as acute endocarditis or a septicemia, toxins and bacteria may both be brought to the kidney. As a result we may get diffuse toxic lesions such as tubular or glomerular nephritis, complicated by focal lesions of bacterial origin.

Classification.—The infectious lesions of the kidney are of various sorts, the causal agents many. The ideal classification of the lesions would be on an etiologic basis, but this is not always feasible because it is often impracticable or impossible to determine with certainty the exact nature of the infecting organism in

each instance. Moreover, the lesions produced by a number of different organisms may closely resemble one another. On this account an etiologic classification is ordinarily carried out with only a few organisms, such as the tubercle bacillus and the *treponema pallidum*. The lesions produced by many other organisms are usually grouped together and classified according to the nature of the pathologic process, that is, on an anatomic basis. These two types of classification are often combined (streptococcus abscess), and they may be modified by the manner of invasion of the kidney (tuberculous pyelonephritis).

The infectious lesions of the kidney will be considered under the following headings:

1. Abscess.
2. Infectious nephritis.
3. Infectious lesions of blood-vessels.

Mode of Invasion.—Infection of the kidney may take place rarely by direct continuity from lesions in the adjoining tissue; frequently through the blood-vessels (hematogenous infection); or less often through the tubules from the pelvis of the kidney (ascending pyelonephritis). In whatever way infection takes place the organisms, if not already there, as a rule soon gain access to the lumina of the tubules and to the lymph-spaces and vessels in the connective-tissue stroma and spread more or less rapidly through these channels. When the lesions are acute it is usually easy to determine the mode of infection, but when the process has existed for some time this may be impossible, for infection by continuity or through the blood-vessels may readily, by extension directly or through the tubules to the pelvis of the kidney, be converted into an ascending pyelonephritis. On this account the broader and more general term of infectious nephritis is preferable to pyelonephritis.

Injurious Agents.—The infectious agents which most commonly produce infectious lesions in the kidney are the staphylococcus aureus, the streptococcus pyogenes, the colon bacillus, and the tubercle bacillus. Other organisms which occur less commonly are the micrococcus lanceolatus, the bacillus mucosus capsulatus, the actinomyces, and the *treponema pallidum*.

Some of these organisms reach the kidney as a rule through the circulation (staphylococcus aureus, streptococcus pyogenes, tubercle bacillus), others chiefly by infection of the pelvis of the kidney from below (bacillus coli); at least one organism may reach the kidney in any one of the three ways mentioned (bacillus tuberculosis).

Some of these infectious agents, such as the staphylococcus aureus produce marked necrosis and solution of tissue (abscess

formation), while others, as frequently happens with the colon bacillus, for example, may produce only a diffuse inflammatory process. Various combinations of these two types of lesions may occur.

The organisms producing infectious lesions in the kidney are sometimes very numerous and occur in masses (streptococcus pyogenes and tubercle bacillus in the capillaries of a glomerulus, the staphylococcus aureus in the centers of beginning abscesses, the

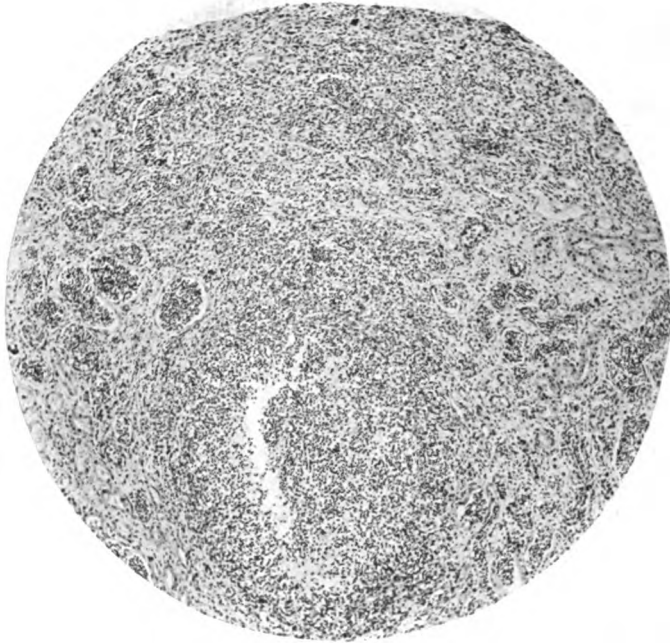


Fig. 445.—Kidney. Acute infectious nephritis (pyelonephritis). Tubules dilated and filled with polymorphonuclear leukocytes. Small abscess formed. M.

colon bacillus in ascending infections); at other times it is difficult to demonstrate them.

Organisms which reach the kidney through the blood stream are usually caught in the glomeruli and lead to an inflammatory reaction at that point. Less often they are detained in the capillaries into which the efferent vessel of the glomerulus breaks up. Certain organisms infect the walls of arteries and cause lesions there, while the *treponema pallidum*, at least in congenital syphilis, invades chiefly the connective-tissue stroma. To determine these

different points the lesions must be found and studied in their earliest stages.

Abscess.—A lesion starting in a glomerulus quickly extends to the capsular space and the subtending tubule. The tuft may be invaded by numerous polymorphonuclear leukocytes and the capsular space and tubule distended and filled with them. Necrosis usually follows quickly and the landmarks are soon destroyed. A miliary abscess starting in this manner may rapidly extend peripherally and involve all the surrounding structures. The infectious process also spreads along the tubule and often by direct extension to the surrounding tissue it gains access to the lymph-spaces and vessels. As these vessels and especially the tubules run chiefly in straight lines from the pelvis to the capsule the lesions naturally spread in the same direction. On this account they usually present a streaked or linear arrangement running towards the pelvis and converging as they approach it.

Abscesses of hematogenous origin are usually multiple, and when they are they may be expected to occur in both kidneys in accordance with the laws of chance regarding the distribution of numerous infectious organisms through the circulation. Abscesses frequently occur in the kidney, however, as the result of ascending infection of the tubules from the pelvis of the kidney. Under this condition multiple abscesses may occur in one kidney while none is present in the other. It must not be forgotten, however, that the pelvis of the affected kidney may have been infected from a single primary lesion of hematogenous origin.

Infectious Nephritis.—Infectious nephritis is the term applied to a diffuse inflammatory process in the kidney due to the immediate presence of organisms. It is most often caused by the colon bacillus and infection, as a rule, takes place from the pelvis of the kidney, which has been invaded from the urinary bladder by way of the ureter. The organisms invade the tubules and ascend along them to the cortex, but they rarely invade the capsular space of a glomerulus. They produce an acute inflammatory reaction which is combined with more or less necrosis of the epithelium lining the tubules. The exudation consists of polymorphonuclear and endothelial leukocytes in varying proportions and of serum and fibrin. They collect in the tubules and distend them. Frequently a similar exudation is present in the intertubular connective tissue and has mingled with it numerous lymphocytes and plasma cells. An inflammatory process such as this may extend in narrow or broad, gradually widening bands from the pelvis to the capsule of the kidney, or invade it more or less diffusely and extensively. Sometimes this fairly mild process is complicated by more or less extensive hemorrhage and by abscesses due to

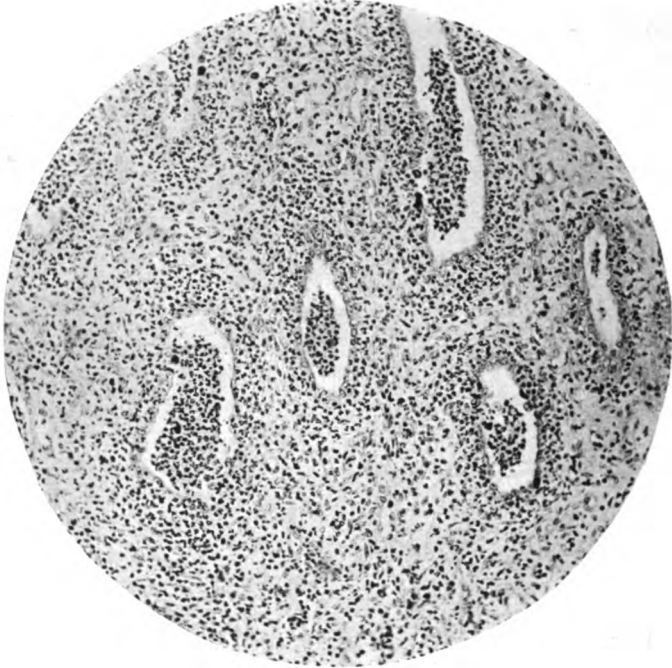

Fig. 446.—Kidney. Acute infectious nephritis (pyelonephritis). Collecting tubules in pyramid filled with polymorphonuclear leukocytes which are also numerous between the lining epithelial cells and in the intertubular tissue. M.

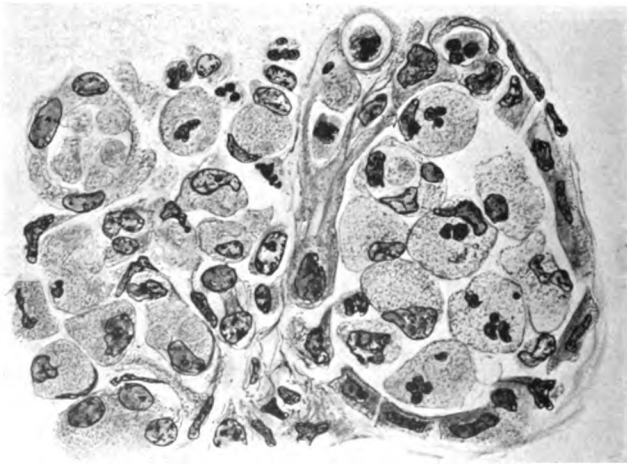


Fig. 447.—Kidney. Infectious nephritis. Numerous endothelial leukocytes within a tubule and in the adjoining stroma.

areas of necrosis of tubules and surrounding tissue, followed by softening. At other times the infectious organism is more virulent, and necrosis and softening are more extensive, so that abscesses and suppurating tracts form the most obvious lesions (suppurative nephritis, chronic pyelonephritis, surgical kidney).

Infectious nephritis may undergo repair at any stage of the process provided the infectious organism is killed off. This may happen in some foci and not in others, or it may occur throughout the kidney. Lesions in all stages of repair may frequently be

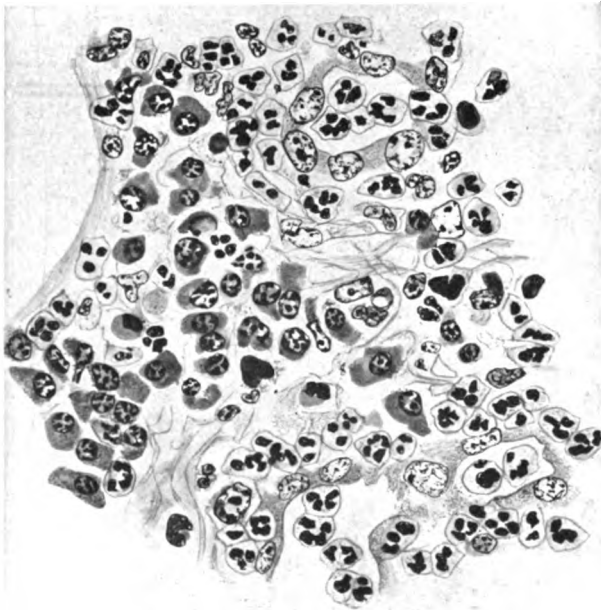


Fig. 448.—Kidney. Infectious nephritis. Stroma infiltrated with numerous polymorphonuclear leukocytes and plasma cells. A few leukocytes within the tubules.

found in the same kidney. The final result depends on the amount of injury done. Sometimes the tubules are completely restored by regeneration of the epithelium. At other times the tubules are narrow and the epithelium but little differentiated. Occasionally they are completely destroyed. The glomeruli may remain normal or be transformed into small masses of dense fibrous tissue. The intertubular connective tissue is usually more or less increased in amount, probably as the result of regeneration following injury, and as a rule contains a varying number of lymphoid cells.

When abscesses have been present they are gradually filled in and obliterated by granulation tissue. This process of repair is often complicated by the presence of large numbers of endothelial leukocytes filled with fat, which infiltrate the granulation tissue and fill the cavity of the abscess when it has not been obliterated. The fat has been derived from degenerating cells and leukocytes and when set free by necrosis has attracted the endothelial leukocytes. Sometimes these leukocytes fuse to form foreign body giant-cells around crystals of various sorts derived from the fat.

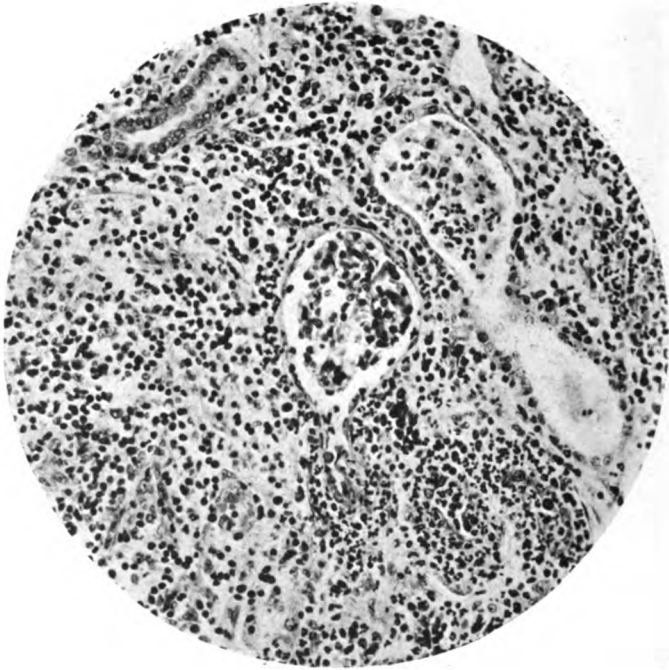


Fig. 449.—Kidney. Infectious nephritis. Many polymorphonuclear leukocytes in the tubules and between the lining epithelial cells and many lymphocytes in the intertubular tissue. M.

Infectious nephritis is probably more common than is generally supposed. It occurs both in children and in adults, and frequently terminates in repair. It very often complicates other lesions of the kidney especially vascular nephritis and amyloid formation.

Gross Appearance.—The gross appearance of the kidney of infectious nephritis varies greatly according to the character of the infectious organism and the duration of the process. In the acute stage the kidney may be enlarged and beset by numerous

long, wedge-shaped, grey to yellow, softer areas or strands of various sizes, with their bases at the capsule and their apices at the pelvis. The strands may be bordered by injected blood-vessels and contain more or less hemorrhage. Abscesses may be associated with this milder inflammatory process. They are filled with pus and often bordered by a yellow, opaque zone where the granulation tissue is infiltrated with endothelial leukocytes filled with fat.




Fig. 450.—Kidney. Infectious nephritis. Healed stage showing disappearance of tubules, sclerosis of glomerulus, and marked increase of connective tissue. M.

If repair takes place the wedge-shaped areas gradually contract, assume a greyish appearance, and appear more or less like scars according to the amount of destruction of tubules and new formation of connective tissue.

The final result of repair of infectious nephritis is a kidney containing depressed scars of various sizes. Such scars may occur in kidneys otherwise normal or complicate other diffuse processes, especially vascular nephritis.

Infectious Lesions of the Blood-vessels.—Infectious lesions of

the blood-vessels of the kidney, although not very common, are very definite and characteristic. They occur in arteries. The lesion consists of necrosis of the vessel wall, more or less extensive fibrin formation, and the accumulation of numerous polymorphonuclear and endothelial leukocytes, and of a varying number of lymphocytes. Thrombi may form within the lumen of the affected vessel, and later lead to invasion and replacement by fibroblasts (so-called organization). Lesions of this type occur not infrequently in connection with acute tubular and glomerular nephritis, and also in certain mild types of acute endocarditis.

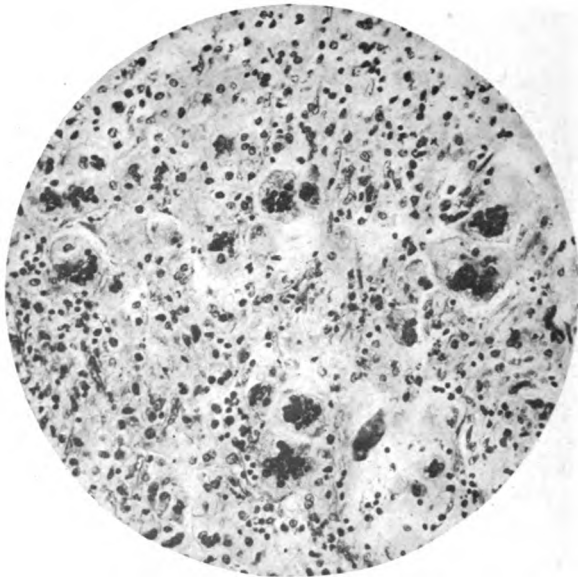


Fig. 451.—Kidney. Chronic infectious nephritis. Shows endothelial leukocytes filled with fat-droplets; also giant-cells formed by fusion of endothelial leukocytes, probably in consequence of the presence of products of fat metabolism. M.

Tuberculosis.—Three different types of gross tuberculous lesions of the kidney are recognized; (1) miliary tuberculosis; (2) tuberculous infarction; (3) tuberculous nephritis.

1. *Miliary tuberculosis* is the commonest form of tuberculous infection of the kidney. It is always of hematogenous origin and occurs in cases of generalized miliary tuberculosis. The number of tubercles in the kidney is always relatively less than in the spleen, liver and lungs, probably because the vascular endothelium is less phagocytic and the cells do not often catch and retain the bacilli. The lesions may start in the glomeruli or in the capillaries between

the tubules. The organisms lead first to an accumulation of endothelial leukocytes in and around the vessels in which they are situated. In the glomerulus the lesion spreads to the capsular space and the attending tubule, which become filled with endothelial leukocytes and fibrin. Necrosis begins and spreads as the vessels become occluded. The lesion spreads peripherally and along the tubules so that the landmarks are soon obliterated. Rarely tubercle bacilli develop in large numbers in the capillaries of the tuft, forming solid masses like colonies in a culture tube.

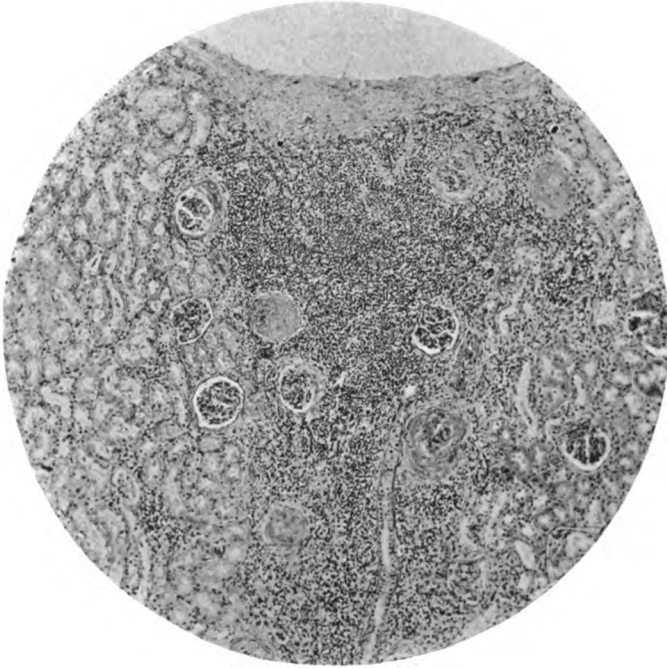


Fig. 452.—Kidney. Healed area of pyelonephritis. M.

Miliary tuberculosis is usually acute, because death occurs before the lesions have time to develop. When, however, they are very few in number they sometimes develop so as to involve a considerable area, tending to spread chiefly towards the pelvis, because the tubules run in that direction.

2. *Tuberculous infarction* is the term applied to a rare form of tuberculous lesion which is shaped like an infarct, and is due to a tuberculous lesion of an artery from which tubercle bacilli are distributed to all the vessels and capillaries supplied by that artery. The artery itself may have been originally infected directly from

the blood stream or from a miliary tubercle starting near it and extending into it.

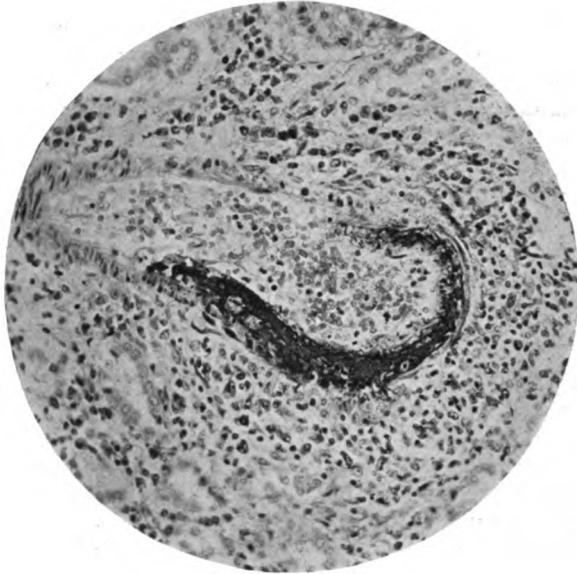

Fig. 453.—Kidney. Infectious lesion of artery: Necrosis, fibrin, polymorphonuclear and endothelial leukocytes, lymphocytes. M.

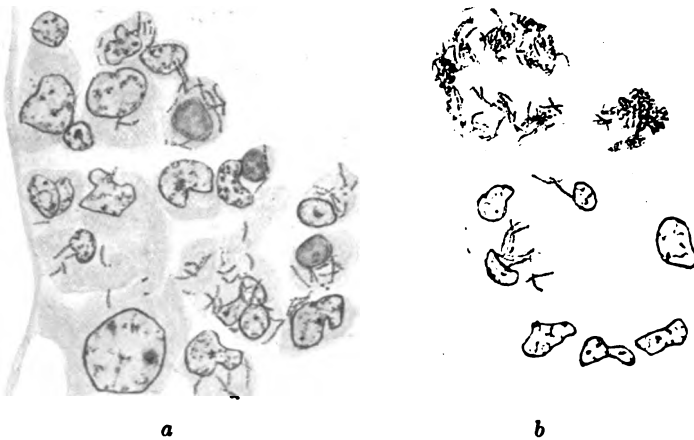


Fig. 454.—Tubercle bacilli. *a*, Within capsular space of glomerulus of kidney; *b*, within capillaries of glomerular tuft of kidney.

3. *Tuberculous Nephritis*.—This form of tuberculosis of the kidney is chronic in type and the most important, because it may

be the only serious lesion in the body. It is due to tubercle bacilli gaining entrance to the pelvis of the kidney and causing a pyelitis. From here they infect the tubules and the intervening lymph-vessels and tend to spread towards the cortex, causing necrosis and ulceration which start usually at the apices of the pyramids and gradually erode them. The lesion is analogous to tuberculosis extending along the bronchi of the lung. The process may result in the formation of numerous abscess cavities, some of which may reach the capsule of the kidney, or the whole kidney may be transformed into a sacculated cavity filled with cheesy or putty-like material.

The pelvis of the kidney may have been originally infected in one of three ways; (a) by direct extension of a lesion of hematogenous origin into the pelvis, or by bacilli being carried along a tubule from such a lesion in the cortex; (b) by extension of a tuberculous process from lower down in the genito-urinary tract to the pelvis by way of the ureter; (c) rarely by direct extension of a tuberculous lesion of an adrenal or other adjoining structure to the kidney and thence to the pelvis.

It has been claimed that tubercle bacilli sometimes pass through the glomeruli and lodge in the collecting tubules of the pyramids where they start an ascending pyelonephritis (excretion tuberculosis). If this were possible we ought to find evidences of such lesions just beginning in every extensive case of miliary tuberculosis, but we do not. The appearance described as excretion tuberculosis is without much question an early stage of ascending tuberculous pyelonephritis. The pelvis was probably infected from a hematogenous lesion present elsewhere in the kidney and overlooked.

Syphilis.—In congenital syphilis the *treponema pallidum* may be present in large numbers in the connective-tissue stroma of the kidney and to some extent within the tubules and between the epithelial cells lining them. The reaction to it is practically nil.

Infection of the kidney in acquired syphilis is doubtful; at least no one apparently has yet demonstrated *treponemas* in any lesion claimed to be syphilitic.

Sclerosis.—It is evident from this presentation of the various inflammatory processes of the kidney that sclerosis of the organ may result both from toxic and from infectious lesions. The term sclerosis includes both healed acute and recurrent lesions, and chronic (continuous) conditions.

If the various types of acute lesions have been fully analyzed and presented from the time of their inception to their termination either in restoration to the normal condition or in sclerosis, then we should be in a position to take a sclerosed kidney of

whatever origin and to read backwards, from the evidence presented there, the steps by which it reached its final condition. For this reason the lesions described are briefly summarized here.

The toxic lesions are much the more common and are of several varieties. They may affect the epithelium of the tubules or of the capsular spaces, the endothelium of the glomeruli, or the arteries and afferent vessels and capillaries of the glomeruli.

The toxic lesions are usually acute, but may be recurrent or chronic. They may terminate in complete recovery if the patient survives (tubular nephritis usually, perhaps always); or as the result of the process of repair, in sclerosis of the capsular space (capsular glomerulonephritis), of the glomerulus (intracapillary glomerulonephritis), or of the blood-vessels (vascular nephritis, arteriosclerosis). Destruction of any one of the essential parts of a renal unit (tubule, capsular space, glomerular tuft, afferent artery) results in atrophy and sclerosis, or disappearance of the others. Sclerosis of the kidney is the sum total of sclerosis affecting parts or the whole of many or all of its units.

Toxic lesions, especially those affecting the tubules and the glomeruli tend to be quite uniformly distributed; but in vascular nephritis the distribution is more irregular; groups of normal glomeruli may exist alongside of others completely sclerosed.

Infections of the kidney may give rise to abscesses and to diffuse inflammatory processes. Abscesses may terminate in localized sclerosis or scars. The diffuse inflammatory processes, especially when the infectious agent is of such a nature as not to cause extensive necrosis and diffuse suppuration, may closely simulate nephritis of toxic origin, but the lesions are likely to show an irregular focal distribution.

ABNORMALITIES

Certain abnormalities of the kidney, often microscopic in size, are important on account of the light which they throw on the tumors occurring in this organ. They are the following:

1. Small masses of fibrous tissue, sometimes including renal tubules, found in the pyramids. Occasionally they are multiple.
2. Bundles of smooth muscle-cells sometimes found in the capsule or beneath it in the renal tissue.
3. Fat cells in the same location.
4. Solid clumps of cells resembling usually the cells of the adrenal cortex and containing much fat and glycogen.
5. Small glandular structures composed of simple glands or having papillary projections in them, and lined with simple cubical to cylindrical epithelium.

New-growths.—Tumors of mesenchymal origin are rare in the kidney. The following have occurred:

1. Fibroma and fibrosarcoma.
2. Lipoma.
3. Leiomyoma, both slowly and rapidly growing types.

The most important new-growth of the kidney is variously named adrenal carcinoma, hypernephroma, and Grawitz's tumor. The cells of which it is composed are unquestionably to be regarded as epithelial in nature; but their origin is in dispute. According to the older and probably the better view they arise from displaced rests of adrenal cells. Such rests can be found within the adrenal and in its capsule, in the kidney and its capsule, along the ureter and elsewhere. These tumors are often rapidly growing and malignant, invading the renal tissues and blood-vessels and giving rise to multiple metastases.

URINARY BLADDER

Introduction.—The most important pathologic processes affecting the urinary bladder are:—the various lesions due to a variety of infectious agents; the epithelial new-growths; and the dilatation and frequent muscular hypertrophy of the bladder wall, due to mechanical obstruction to the outflow of the urine. Disturbances of circulation and lesions of toxic origin are not of much significance.

Retrograde Changes.—A rare lesion of the bladder is extensive amyloid formation in its wall. The amyloid is gradually deposited between the muscle-cells and by pressure atrophy brings about their complete disappearance. The process may affect a bladder otherwise normal, or one already the seat of a chronic cystitis.

Lesions of Mechanical Origin.—Obstruction to the outflow of urine by stricture, enlarged prostate, or other cause may throw increased work on the muscle-cells of the bladder wall as a result of which they undergo hypertrophy. Frequently bundles of the enlarged cells project like beams or trabeculæ into the lumen.

Dilatation may occur with or without hypertrophy of the muscle-cells. Frequently it affects small areas only so that the lesions appear in the form of diverticula which may be congenital and involve the entire thickness of the wall, or acquired and consist only of projections of the mucosa between bundles of muscle-cells.

Lesions of Toxic Origin.—Chemical substances eliminated through the kidneys are sometimes irritating in the bladder, such as cantharides, formaldehyd derived from hexamethylenamine, and ammonia from decomposition of urine. The am-

monia formation probably occurs only as a complication of certain infectious processes.

Lesions of Infectious Origin.—Various infectious agents may gain access to the bladder and cause different degrees and types of inflammatory reaction.

The most common path of entry is from below by way of the urethra, either by direct extension or owing to the passage of instruments. Infection also takes place from above through the ureter, and rarely by direct continuity from some lesion outside of the bladder.

The most common infecting agents are the colon bacillus, the ordinary pus-cocci, the gonococcus and the tubercle bacillus. Some organisms decompose the urine, setting free ammonia which adds to the injury already caused.

The injury ordinarily affects only the lining epithelium, but occasionally may extend to the underlying tissues. It consists of necrosis which may be very slight or more or less extensive, and present the appearance of a membrane.

The inflammatory reaction varies greatly, depending chiefly on the virulence of the infecting organism. It may consist only of a small number of polymorphonuclear leukocytes complicated by desquamation of epithelial cells. If the process is more severe the number of leukocytes may be greatly increased so that they will settle and form a thick layer in the urine. If the urine is ammoniacal the exudation of pus-cells is still more abundant, owing to the increased irritation, and the cells may swell in the ammonia and even disappear, rendering the urine slimy. Phosphates and carbonates may be deposited from the ammoniacal urine and incrust the mucous membrane.

In severe infections the lining epithelium may be more or less extensively destroyed with fibrin formation on its surface, or the whole wall may be involved and the process extend to surrounding tissues and organs. Congestion, hemorrhages and edema are of frequent occurrence.

The mildest type of infection is, perhaps, that due to the colon bacillus, but the organism is very persistent. The gonococcus also may be present in the bladder for years, causing a mild to moderate chronic cystitis.

Malakoplakia.—Rarely an organism, apparently of the colon type, gains access to the submucous tissue and causes a mild inflammatory reaction there, consisting chiefly of an accumulation of endothelial leukocytes which may collect in large numbers so that soft polypoid masses project into the cavity of the bladder, and suggest the presence of some form of tumor. The organisms are sometimes present in large numbers in the leukocytes which

are occasionally multinucleated and often contain other inclusions such as lymphocytes and red blood-corpuscles.

Tuberculosis.—Tuberculosis of the urinary bladder is usually due to infection from above by way of the kidney and ureter. As a rule, it appears first as miliary tubercles and small, shallow ulcerations around the ureter through which infection occurred. From there it spreads until the whole bladder is involved and the mucous membrane is more or less completely destroyed. Less

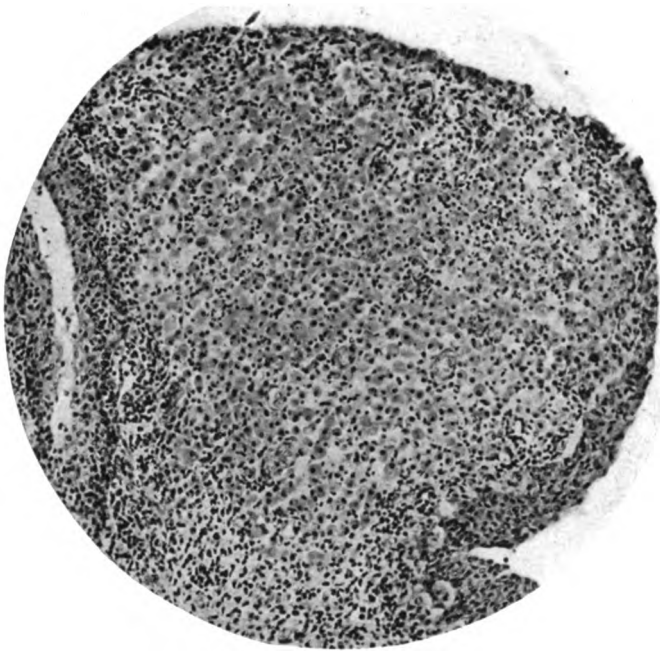


Fig. 455.—Urinary bladder. Malakoplakia. The submucosa is infiltrated with endothelial leukocytes, some of which contain numerous colon-like organisms. M.

often the tuberculous lesions appear elsewhere first, especially on the posterior wall of the bladder.

Tumors.—The epithelial tumors are the most important of the new-growths originating in the bladder. Several types of growth occur.

The papilloma may be single or multiple. The papillary projections are sometimes long and slender. The tumor is often regarded as benign, but should always be held in suspicion be-

cause it almost always terminates as a malignant infiltrating tumor, that is, as a carcinoma.

Other epithelial tumors show evidence of infiltration from the beginning and may project little above the surface. Epidermoid cancer sometimes occurs.

Mixed tumors containing various tissues of mesodermic origin sometimes arise in the bladder wall, but are rare.

URETHRA

The urethra may be injured mechanically by direct external violence, by the passage of small stones from the bladder, or most often by the introduction of a catheter or a sound. Any lesion produced heals readily as elsewhere, unless it becomes infected, but there is always danger of a narrowing of the lumen (stricture) as the final result of repair.

The most important lesion of the urethra is acute inflammation due to infection with the gonococcus. The process starts near the orifice, but extends to the whole urethra and is likely to become localized in the membranous portion, owing to the presence there of numerous folds in the mucous membrane. The organisms are found chiefly or entirely within polymorphonuclear leukocytes in the urethra and in the lumina of the glands emptying into it, but the toxins eliminated by them affect the cells in the surrounding tissues, causing injury and inflammatory reaction. Sometimes the organisms invade the urethral wall and cause ulceration of it or abscess formation adjoining it.

The acute stage of gonorrhoea lasts but a few weeks, but the infection tends to become chronic and persist for years. As a result connective-tissue increase is produced in the wall of the urethra and this later contracts causing stricture.

Stricture of gonorrhoeal origin is usually located in the membranous, less often in the cavernous part, may be single or multiple, and may extend for a few millimeters or several centimeters.

MALE GENITAL ORGANS

PENIS

The important lesions affecting the penis are three in number, two of infectious origin, the hard and soft chancres, and the third a new-growth, the carcinoma.

The hard chancre is always due to the *treponema pallidum* which is often present in large numbers in the lesion and in the exudation on the surface. The hard chancre starts as a minute papule which quickly becomes excoriated. The underlying tissue is infiltrated with endothelial leukocytes and lymphocytes. Polymorphonuclear leukocytes are less common except on the surface. The fibroblasts show considerable proliferative activity. As the result of the exudation and regeneration the lesion becomes thick and indurated. If it remains uncomplicated by other organisms it usually heals spontaneously in the course of a few weeks.

The soft chancre is due to Ducrey's bacillus which usually presents a fairly typical arrangement in the lesions which it produces. It tends to grow in parallel curving lines. The lesions are often multiple and appear as shallow ulcerations which are usually situated on the frenum or in the sulcus glandis. The bacilli are often present in large numbers

in the exudation of leukocytes on the surface. The underlying tissue shows a marked infiltration with plasma cells.

The carcinoma of the penis is of the epidermoid variety, and is almost always papillary in form so that it often suggests a benign papilloma, or the hyperplastic epithelial formation of inflammatory origin known as condyloma accuminatum which is frequently formed on the penis. The carcinoma often shows little invasion at the base before the tumor reaches a considerable size. It starts most often on the prepuce or glans, rarely from the epithelium lining the urethra.

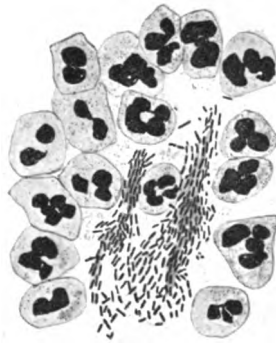


Fig. 456.—Chancroid or soft chancre. Ducrey's bacillus growing in characteristic manner surrounded by polymorphonuclear leukocytes.

TESTICLE AND EPIDIDYMIS

Infectious lesions and primary new-growths are the most important pathologic processes of the testicle and epididymis. Some involve the one organ more commonly and some the other. The infectious lesions arise most often by direct extension along the genital tract, less often through the circulation.

They may occasionally be due to the common pus organisms (*streptococcus pyogenes*, etc.) but are most often caused by the gonococcus and the tubercle bacillus.

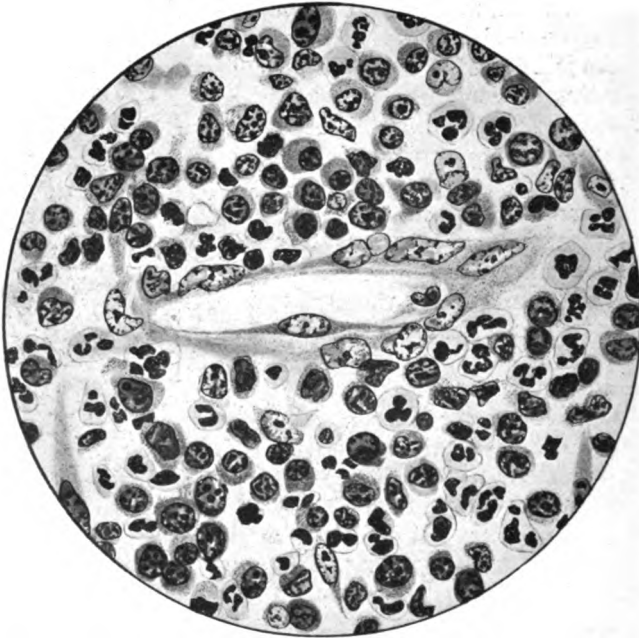


Fig. 457.—Soft chancre; characteristic cellular infiltration of tissue at base of ulceration.

The gonococcus frequently travels directly through the vas deferens to the epididymis and causes an acute exudation of polymorphonuclear leukocytes within the lumen and of serum and plasma cells in the surrounding tissues. Occasionally necrosis and abscess formation follow. The final result of repair may be complete obstruction of the duct so that spermatozoa can no longer escape into the vas deferens. Less often the infection spreads to the testicle and causes more or less diffuse inflammation or rarely abscess formation.

Tuberculosis almost always begins in the epididymis and extends to the testicle, but primary tuberculosis of the testicle sometimes occurs by hematogenous infection.

The lesion usually starts in the wall of the epididymis, but quickly extends to the ducts and causes an inflammatory exudation there. Once within the lumina the bacilli spread rapidly and involve the whole of the epididymis. The inflammatory exudation causes thickening of the wall and in time undergoes caseation.

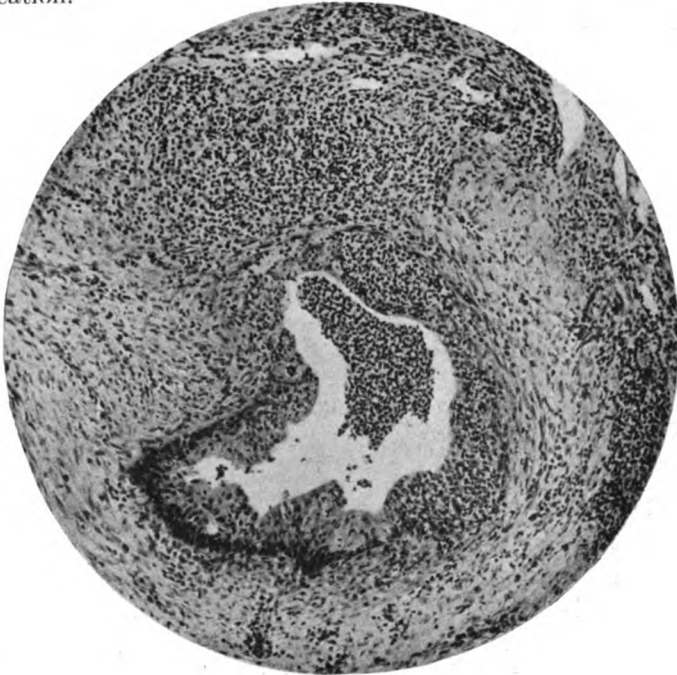


Fig. 458.—Epididymis. Acute epididymitis with beginning abscess-formation due to the diplococcus gonorrhœæ. M.

The process may spread rapidly through the tubules in the testicle, or more slowly by way of the lymphatics and result in more or less extensive areas of caseation.

Syphilis of the testicle is relatively frequent. It practically always begins in the testicle, not in the epididymis. In this respect it is the exact opposite of tuberculosis. The lesion produced may be only a diffuse inflammatory process. More often necrosis occurs so that the term gumma is applied to it. Repair results in a more or less diffuse sclerosis of the testicle or in localized foci of scar formation.

In mumps the infectious agent, which is still unknown, occasionally involves the testicle and causes an intense acute inflammatory exudation with much swelling. Histologically there is extensive necrosis which calls out an exudation of serum and polymorphonuclear leukocytes. Frank suppuration is rare.

In variola it is common to find numerous foci of necrosis in the testicle with a moderate to well marked inflammatory reaction around them. They do not go on to suppuration.

Sclerosis of the testicle is fairly common. It may be extensive or affect only small areas here and there. It is an end result due to repair, not a chronic orchitis due to the continuous action of an agent. To say what the acute lesion was which

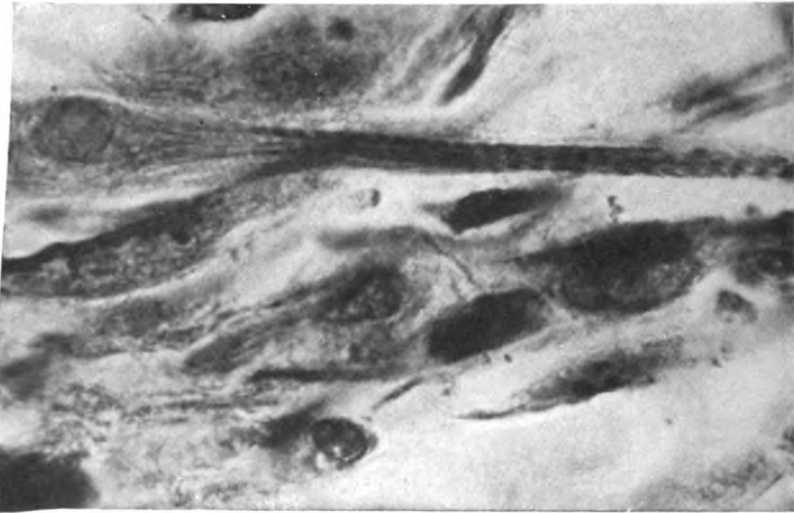

Fig. 459.—Rhabdomyosarcoma of testicle. M.

caused it is usually impossible. All of the lesions which have been described may heal, although some are more likely to than others. A full knowledge of the patient's previous history may solve the difficulty. Variola leaves its characteristic marks elsewhere and syphilis may.

In one instance a sclerosed testicle contained within dense fibrous tissue numerous cholesterol crystals surrounded by giant-cells, evidently the last remains of fat which owed its presence originally to an abscess.

Tumors.—The commonest tumor of the testicle is the embryoma. It appears most often as a cellular, rapidly-growing tumor with little stroma and fairly characteristic cells which show no

differentiation. This form of the tumor has often been classified in the past both as a carcinoma and as a sarcoma. When the tumor grows more slowly so that the cells have opportunity to differentiate, various recognizable types of cells and tissues may be formed: cartilage, bone, striated muscle-cells, neuroglia tissue, epithelial structures, etc. Dermoid cysts such as occur in the ovary are rare.

SEMINAL VESICLES

The *seminal vesicles* and the *vas deferens* are both exposed by their situation and connections to infections involving the genital tract. Of these the most important are gonorrhoea and tuberculosis.

PROSTATE

Introduction.—The most important lesions of the prostate are the infectious processes, including tuberculosis; primary carcinoma; and, most frequently of all, the condition known as hypertrophy of the prostate. Other lesions are of minor consideration.

The prostate develops only partially or not at all in the castrated, and castration in the adult sometimes leads to its atrophy. Evidently there is some close relationship between the prostate and the testicle.

In old age the prostate, instead of undergoing atrophy like other organs, gradually enlarges to a moderate degree; both the glands and the stroma share in the enlargement.

Two postmortem changes are worth noting; marked desquamation of the epithelium lining the glands is very common, and the smooth muscle-cells are often swollen or lumpy and hyaline in their centers.

The only **retrograde change** of any significance is the common formation of corpora amylacea in the adult. These bodies are regularly layered, are often colored brown or black and usually give an amyloid-like reaction with iodine. They vary considerably in size and may occur singly or in large clumps.

Blood pigment is sometimes found within endothelial leukocytes, both in the stroma and less often in the glands as the result of hemorrhage.

Hyaline granules and droplets occasionally occur in the epithelial cells lining the glands and may be very numerous.

The glands of the prostate are often more or less distended with secretion and with corpora amylacea. Whether the accumulation is sometimes natural, or is always due to occlusion of the ducts is not easy of determination and has not been settled. The secretion varies much in consistence, sometimes being thin and watery, at other times thick and dense, suggesting caseous

material. Occasionally it contains feathery or crystalline masses. In one instance the secretion was greenish in color and resembled thick pus. The epithelium lining the dilated glands is thin and flattened.

The secretion and corpora amylacea in the glands sometimes seem to exert a toxic influence, just as colloid does in the thyroid, attracting numerous endothelial and occasionally polymorphonuclear leukocytes into the lumina. These cells often attack and dissolve the bodies and sometimes form foreign body giant-cells around fragments of them.

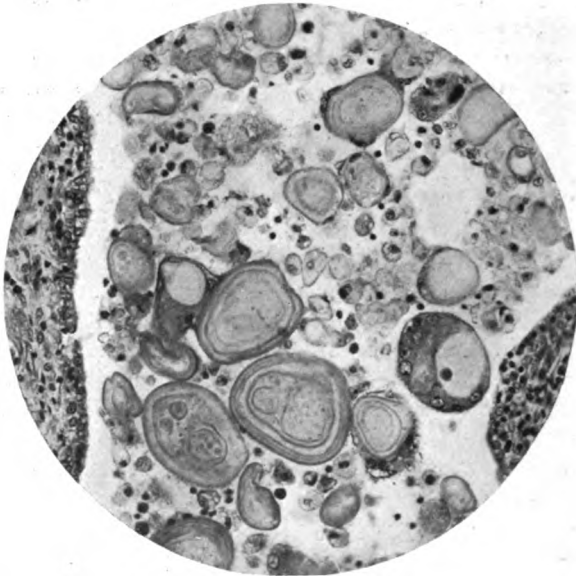


Fig. 460.—Prostate. Corpora amylacea within a dilated gland. Endothelial leukocytes are applied to the surface of some of them and in places are fusing to form foreign body giant-cells. M.

Lesions of Infectious Origin.—Infection of the prostate gland is relatively common. It takes place more often by direct extension from the urinary tract than metastatically through the circulation.

The lesions of embolic origin are most often due to the staphylococcus aureus and usually take the form of abscesses, which may enlarge, coalesce if multiple, and rupture into the bladder, urethra or rectum, cause diffuse suppuration of the pelvic tissues, or result in the escape of urine and its diffusion into the scrotum and subcutaneous tissues.

Infection by extension from the urinary tract frequently follows gonorrheal infection of the urethra, but is most common

as the result of the infections and injuries due to catheterization. The colon bacillus is the most frequent injurious agent under these conditions, but the staphylococcus aureus, the streptococcus pyogenes and other micro-organisms may gain entrance in the same way.

The infecting organisms cause an acute inflammatory exudation consisting chiefly of serum and polymorphonuclear leukocytes which accumulate in the glands and ducts, dilating them and thereby enlarging the prostate. The interglandular tissue is often destroyed and abscesses formed. The infection due to the colon bacillus and especially to the gonococcus may become chronic in form. The gonorrheal process is liable to be mild and the exudation of the so-called catarrhal type. The stroma often shows marked infiltration with lymphocytes which sometimes collect in masses. Eosinophiles are sometimes numerous both in the stroma and within the dilated lumina of the glands.

Tuberculosis.—Tuberculosis may start in the prostate by blood infection or by extension from elsewhere in the genitourinary tract. The lesion may begin as a miliary tubercle in the interglandular tissue, or as an exudation in a duct or gland according to the location of the invading organism. As the bacilli multiply and spread other tubercles are formed. These develop and fuse so that large caseous masses result. If the lesion starts in the stroma the bacilli usually gain access to the glands which become dilated with an exudation consisting for the most part of endothelial leukocytes. If the infection starts in the glands or involves them early it may remain practically confined to them. In one instance the organisms grew in them in great numbers, often in sinuous masses, causing but little inflammatory exudation and only in places involving the surrounding stroma.

Hypertrophy.—The most common, and from a mechanical point of view the most important, condition affecting the prostate is hypertrophy. This is a wholly vague clinical term meaning enlargement due to any cause. It is commonly restricted to chronic enlargements not due to tuberculosis or new-growth.

Simple accumulation of the secretion within the glands, occasionally with inspissation of it, and the formation of corpora amylacea apparently may cause more or less enlargement of the prostate. This enlargement is still more likely to occur if, owing to chemical changes in the secretion, a mild form of inflammatory reaction is excited and leukocytes are attracted into the glands, and lymphocytes into the stroma.

Enlargement of the prostate frequently results from chronic inflammation, evidently of infectious origin. The glands are dilated, often markedly so, by the accumulated exudation within

them and the interglandular tissue is edematous and contains many lymphocytes.

Enlargement is also caused by the accumulation of secretion within the glands and dilatation of them following an inflammatory process which has closed one or more of the many ducts of the prostate. The dilated glands under this condition may contain a clear watery fluid.

Occasionally the connective tissue is more or less increased in amount. An increase of the muscle tissue is asserted by some to occur. It is doubtful if this can be anything more than a hypertrophy of existing muscle-cells, because a hyperplasia of them apparently does not take place, and a leiomyoma would form a discrete nodule just as it does in the uterus or elsewhere.

Another type of enlargement of the prostate is due to a hyperplasia of the glands, a condition which is sometimes marked. It may be complicated by dilatation of some of the glands and by inflammation. The cause of the hyperplasia is not evident. It may be more or less focal or diffuse. The stroma between the hyperplastic glands contains smooth muscle-cells, as in the normal prostate, in addition to fibroblasts and blood-vessels. This point is much against the glandular hyperplasia being regarded as an adenoma, as advocated by some writers.

Glandular hyperplasia combined with more or less dilatation seems to cause the most marked examples of hypertrophy. In one instance the two lobes removed at operation weighed, after hardening in alcohol, 172 grams and measured 8.5 x 5 x 5.5 cm. and 8 x 5.5 x 4 cm. respectively. As a rule the weight of enlarged prostates does not go above 50 to 100 grams.

The consistence of the enlarged prostate is usually elastic. On section the cut surface may be smooth, or streaked with fibrous bands, or the glandular portions may project.

Tumors.—The most frequent and important tumor of the prostate is the carcinoma. It occurs especially in old men. Sometimes it causes little or no enlargement of the organ and may require microscopic examination to determine its presence. In other instances the prostate is much enlarged and the tumor may extend to the surrounding tissues and into the bladder.

Histologically the tumor cells are usually small, polymorphous and arranged in solid masses and cords which may be small or large. Occasionally the cells are arranged in gland-form. Rarely the cells are large as the result of considerable cytoplasm around the nuclei.

A marked peculiarity of cancer of the prostate is that early and numerous metastases in the bones are common and the stroma which is formed for them there from the osteal fibroblasts often reveals its nature by forming true bone (osteoplastic carcinoma).

FEMALE GENITAL ORGANS

UTERUS

The most important lesions of the uterus are the infectious processes and the tumors.

Anatomy.—The surface and the slightly spiral glands of the mucous membrane of the body of the uterus are lined with cylindrical epithelial cells which are to some extent ciliated. The glands often extend normally to some depth into the muscle wall. Between the glands are spindle-shaped fibroblasts surrounded by a small number of collagen fibrils.

The cervix and its glands are lined with tall cylindrical mucus-secreting epithelial cells and the fibroblasts between them are surrounded by fairly numerous collagen fibrils.

Menstruation.—At the time of menstruation certain changes occur in the uterus. A knowledge of these changes, especially of the hypertrophic condition of the uterine glands, is important, because if not understood and recognized the glandular hypertrophy may be misinterpreted in the examination of uterine curettings.

Turgescence of the mucous membrane begins eight days before menstruation and gradually increases. At the time of menstruation three well-characterized layers can be recognized in it:

1. The first or compact layer consists of the mouths of the glands with enlarged, swollen fibroblasts packed between them.

2. The second or spongy layer is composed of dilated glands with their walls thrown into folds. The glands are lined with vacuolated, swollen epithelial cells filled with mucus.

3. The third or basal layer consists of the lower ends of the glands which are not altered.

During menstruation the glands discharge their secretion, and hemorrhages occur all through the mucous membrane and also on the surface and into the glands. Parts of the surface or compact layer are cast off and small defects result in consequence.

After menstruation the mucous membrane gradually returns to its normal condition. The blood in the tissues is removed without pigment formation.

Disturbances of Circulation.—Congestion and hemorrhage occur physiologically during menstruation. Hemorrhage also

occurs under other conditions and clinically may be of much importance in calling attention to some new-growth within the uterus, to placenta prævia, or to some other abnormal condition. Occasionally in old women an agonal hemorrhage or apoplexia uteri is found.

Lesions of toxic origin do not occur except from the introduction of chemical substances into the uterine canal, either for the purpose of producing abortion or for medication or production of asepsis. More or less extensive necrosis of the surface and acute inflammatory exudation may result.

Lesions of infectious origin are common in the uterus. They most frequently follow instrumental production of abortion and the employment of forceps in labor, but may occur even in connection with normal labor. Streptococcus infections are the most dangerous because they are liable to extend to the lymphatics, which become dilated and filled with pus, and to spread into the broad ligament. The inner surface of the uterus may undergo more or less extensive necrosis. Placental remains and hemorrhages often complicate the condition. The inflammatory exudation on the surface and in the tissues varies according to the nature of the infecting organism and the degree of injury done.

Infection with the gonococcus often occurs by extension from the vagina, and while not particularly virulent, causes an abundant mucopurulent secretion and the inflammatory condition it produces is likely to persist.

Infection with the tubercle bacillus is comparatively rare. It may arise by blood infection, but usually results by direct extension from a chronic tuberculous process in an oviduct.

Hypertrophy of the uterine mucous membrane is a fairly common condition. The glands become elongated, more or less tortuous and present numerous small projections into the lumina. Some of the glands may be dilated into small cysts. The cause of the condition is not fully understood, but is evidently various.

Cysts due to distension of the glands of the cervix (ovula Nabothi) are of common occurrence and of little or no significance. More important lesions of the cervix are lacerations, inflammatory erosions and true erosions. A condition simulating erosion and usually so called seems to be of congenital origin, due to a part of the vaginal portion of the cervix being lined with cylindric instead of pavement epithelium.

Tumors.—The important tumors of the uterus are the carcinoma and the leiomyoma.

Benign polypi occur occasionally. In the body of the uterus they usually arise from a broad base at the fundus, and grow toward the cervix, conforming to the shape of the cavity which they

often completely fill and may distend. Externally they are covered with epithelium like the uterine mucosa. The proportions of glands and stroma vary considerably in different instances. Sometimes the glands are dilated into small cysts. Polypi of the cervical canal may project into the vagina.

The cause of the formation of these polypi is not known. They are probably best regarded as due to a local hypertrophy of the uterine mucosa, rather than as true tumor formations like the benign adenomas of many other organs.

The carcinoma occurs in several forms which are named according to the type of epithelium from which they arise, or the manner in which the cells are arranged, namely, malignant adenoma, adenocarcinoma, alveolar carcinoma, epidermoid carcinoma.

Not infrequently two or three of the types and rarely all four are found associated in a single tumor. To the clinician the location of the tumor, whether at the fundus or in the cervix, is of more importance than its exact histologic classification.

Cancer of the fundus may be localized in a small area and yet extend through the entire muscle wall. More often it quickly infiltrates and destroys the lining mucous membrane and invades the muscle wall more slowly. It may project into the uterine cavity and cause more or less distension of it.

Cancer of the cervix may arise from the mucous glands or from the covering epidermis. The epidermoid type of growth is occasionally complicated by an extreme infiltration with eosinophiles. In one instance metastases of one of these tumors into the lungs showed a similar infiltration with eosinophiles. The cause of the unusual infiltration is not evident.

The leiomyoma is the commonest tumor of the uterus. It may be single or multiple, small or large. It always starts in the muscle layer and may remain there or be forced into a sub-mucous or subperitoneal position. It is usually sharply circumscribed, but may grow diffusely and be poorly defined, being limited to a part of the uterine wall or involving practically all of it, and causing a uniform thickening and great enlargement of the uterus.

Occasionally the leiomyoma grows rapidly, infiltrates the surrounding tissue and may give rise to metastases. The cells usually retain a spindle shape, but occasionally become more or less spherical. Mitotic figures may be numerous and sometimes multiple so that true tumor giant-cells are formed.

The discrete leiomyoma occasionally, and the diffusely growing form of it frequently, are complicated by the presence of glands which resemble closely those in the uterine cavity, are surrounded by the same kind of fibroblasts, and bear the same relation to the

adjoining muscle layer. This form of leiomyoma is often called an adenomyoma. Cullen has clearly shown that in at least the great majority of instances these glands are directly connected with the uterine mucosa. They are probably to be explained, not as an ingrowth of the mucosa into the muscle wall, but as mucous membrane forced out of its normal situation by the growth of the leiomyoma which started near it and more or less completely surrounded portions of it. By the growth of the leiomyoma the mucous membrane continues to be stretched and dislocated, although certainly, as a rule, retaining its direct connection with the uterine mucous membrane.

OIDUCT

The most important lesions of the oviducts are of infectious origin. The gonococcus is the commonest etiologic agent. Next in importance is the tubercle bacillus.

Anatomy.—The mucous membrane of the oviducts is thrown into folds running lengthwise of the tube and is lined with ciliated cylindrical epithelium. In one instance a small portion of it was lined with pavement epithelium. The muscle coat directly adjoins the mucous membrane. Small gland cavities lined with ciliated epithelium and surrounded with a layer of smooth muscle-cells are frequently present beneath the mesothelial covering of the tubes. They are probably remains of the Wolffian duct and may be the starting point of some of the tumors usually considered to arise from the ovary.

Lesions of Infectious Origin.—The oviduct may be infected by direct invasion of organisms either from below through the uterus, from above through the fimbriated end and the peritoneal cavity, or metastatically through the circulation. Infectious processes rarely start primarily in it; it usually becomes secondarily involved, but the lesion in it is often more important than the primary one. Infection may be due to the ordinary pus organisms, but the most common infecting agent is the gonococcus.

Lesions due to the streptococcus pyogenes and similar bacteria usually run an acute course, and are generally secondary to uterine infections following abortion or labor, or to appendicitis and peritonitis. In one instance it followed pneumococcus infection of a corpus hæmorrhagicum.

Salpingitis is most often due to the gonococcus. The proportion is placed at seventy-five to eighty per cent. The process is essentially chronic and may persist for months or years. In the acute stage the lumen of the tube is filled with polymorphonuclear leukocytes many of which contain gonococci. In the later stages it may be difficult or impossible to demonstrate their

presence, although cultures often show them present when smears do not.

The mucous membrane is infiltrated, according to the duration of the infection, with polymorphonuclear leukocytes, plasma cells, eosinophiles and occasionally with endothelial leukocytes filled with fat-droplets.

Sometimes the various leukocytes infiltrate the muscle coat more or less extensively and the fibroblasts are usually stimulated to reparative proliferation, so that much thickening of the wall may be caused. The lining epithelium of the mucous membrane is occasionally destroyed in places.

Fibrin formation on the peritoneal surface of the tube usually leads to organization and the formation of fibrous adhesions with the surrounding structures, especially with the ovaries.

As the result of the infection and the inflammatory reaction to it the oviduct is often enlarged, its lumen dilated and its wall thickened. It may be much distorted in consequence of adhesions which tie it down at various points. The fimbriated end is often occluded. Repair of ulcerations within the lumen and organization of fibrin may cause adhesions between the folds of mucous membrane and more or less obliteration of the depressions.

Tuberculosis is an occasional lesion of the oviduct. The tube may become involved secondarily to a tuberculous peritonitis, but the infection usually starts from a miliary tubercle of hematogenous origin. The process starts and spreads in the mucous membrane, but the bacilli, as a rule, soon gain entrance to the lumen and give rise to an exudation. Rarely this may be so abundant that large, thin-walled tubes result, which suggest huge sausages. In one instance they weighed two pounds apiece.

Tubal pregnancy is fairly frequent and is the most common, perhaps the only, cause of hemorrhage in the oviduct and of rupture of its wall.

OVARY

The tumors of the ovary occupy the first place among the pathologic conditions affecting it.

Infections cause a diffuse inflammatory exudation or more often abscess formation, which may be surrounded with a thick wall of granulation tissue. The infections usually arise secondary to acute processes in the neighborhood, such as a gonorrheal salpingitis or an acute appendicitis, or by extension of a puerperal infection through the broad ligament.

Tuberculosis may arise by direct infection from a tuberculous peritonitis, or a salpingitis.

Cysts.—Several varieties of cysts occur in the ovary. Two

arise in connection with new-growths. Three are due to distension of preëxisting cavities and will be considered before the others.

1. The first variety of retention cyst is due to dilatation of gland-like cavities which are probably remains of the Wolffian duct. Many of the cells are ciliated.

2. The second variety is due to distension of ovarian follicles and is lined with non-ciliated epithelium.

3. The third results from softening and an accumulation of fluid in the center of a corpus luteum or fibrosum.

Tumors.—The epithelial tumors of the ovary are the most frequent and important. They are divided into three varieties according to their type of growth.

1. The *adenocystoma* is composed of glands and cysts lined with cylindric epithelium and filled with a thin to thick fluid containing pseudomucin. The tumors may attain a very large size and are usually benign.

2. The *papillary adenocystoma* is more likely to contain one cyst than many, does not attain a very large size and is filled with a thin, serous fluid. Papillary outgrowths may project from the wall at only one spot, or line the whole inner wall and fill the lumen of the one or more cysts present. Papillary outgrowths may also occur on the outside of the tumor and even mask the cyst formation. The epithelium lining the cysts and papillary projections is tall, cylindric and often ciliated. The stroma may be slight or abundant. This variety of tumor may give rise to metastases in the peritoneal cavity and must be regarded with greater suspicion than the adenocystoma.

3. The *carcinoma* gives rise to a solid tumor often of a peculiar yellow color and usually with an abundant dense stroma.

The *fibroma* is rare and usually small, but may occasionally attain a large size. In one patient each ovary contained a fibroma; one was very large, the other small; both caused symmetrical enlargement of the ovaries.

The *teratoma* is more common. It is usually cystic in form (dermoid cyst) but sometimes solid and may contain a great variety of histologic elements.

MAMMARY GLAND

The mammary gland is composed of ducts and glands lined with two layers of epithelial cells, the inner cubical, the outer long and cylindric with fibrils in the cuticle, in consequence of which they are usually regarded as smooth muscle-cells of epithelial origin. The ducts near their outlet, the nipple, are lined with epidermis.

The stroma of the mammary gland consists of abundant connective tissue in which occur occasional smooth muscle-cells.

Lesions of Toxic Origin.—Retained secretions in the ducts and glands sometimes lead to trouble. Fat often attracts endothelial leukocytes. Fat and cholesterol crystals formed from the fat may cause the endothelial leukocytes to fuse together into foreign body giant-cells. The lining epithelium is sometimes destroyed.

The irritation caused by these retained products of secretion seems to have some causal relation to the foci of epithelial proliferation so often found in cases of chronic mastitis.

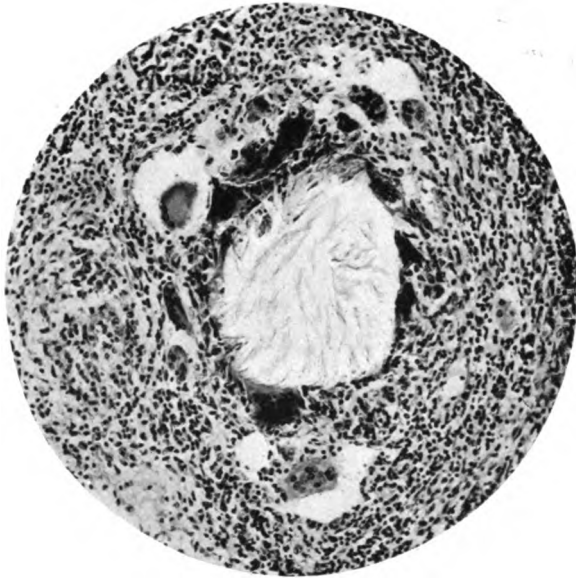


Fig. 461.—Mammary gland. Chronic mastitis. Giant-cell formation around masses of fat crystals formed from the glandular secretion. M.

Lesions of Infectious Origin.—The ducts and glands of the breast are sometimes infected with pus-cocci, most often during the nursing period. The process may spread more or less widely in the ducts and glands and cause diffuse inflammation, or more or less extensive abscess formation.

Tuberculosis occurs occasionally.

Tumors.—Several types of epithelial tumors arise in the mammary gland.

The most common is the *adenoma* which may grow in simple gland form, but more often has papillary or finger-like projections

of stroma into it, which stretch and distort the glands and often force their epithelial surfaces closely together.

Papillary growths within the ducts and glands are not infrequent and are always to be regarded with suspicion, because their tendency is finally to invade the surrounding stroma as full-fledged cancers. Sometimes they distend the ducts and glands and fill them with proliferated cells before invasion takes place. This type of tumor is frequently found in connection with chronic mastitis of toxic origin due to retained products of secretion.

Carcinoma of the mammary gland is the most common type of cancer with which women are afflicted. It may form large, rapidly-growing masses, or small, dense nodules; be sharply circumscribed or diffusely infiltrating, spreading slowly in the connective tissue and rapidly in the lymph-vessels and within the ducts. It may invade the overlying epidermis or the pectoral muscles beneath. Extension to the axillary lymph-nodes is of common occurrence and often takes place early. In one instance where a cancer one cm. in diameter was present in the nipple the axillary lymph-nodes showed extensive infiltration.

Colloid cancer sometimes occurs.

Cancer of the mammary ducts may be epidermoid in type and sometimes spreads in the deeper layer of the epidermis around the nipple, causing ulceration (Paget's disease of the nipple). An occasional tumor occurring in the breast is the osteochondrofibrosarcoma.

PLACENTA

The important lesions of the placenta are the hydatidiform mole and the chorionepithelioma. Infectious lesions are comparatively rare.

Infarcts of the placenta are common, due to fetal cells invading the veins and arteries in the uterine mucosa and causing obstruction or bringing about hemorrhages. As a result of disturbance of the maternal circulation the villi are no longer bathed in blood. They may necrose and become compacted together, or be driven apart by hemorrhage. The infarcts usually appear yellowish white and opaque and of varying size.

Hydatidiform mole is of importance owing to its relation to chorionepithelioma. It is due to edema of the mucous connective tissue of the chorionic villi which are sometimes greatly expanded. The epithelial covering often shows a markedly hyperplastic condition. The cause of the condition is not known.

The *chorionepithelioma* arises from the epithelium covering the villi and is, therefore, fetal in origin. It may grow on the surface of the uterus, but tends to invade and grow in blood-

vessels. Hemorrhage is, therefore, commonly associated with it. Metastases in the wall of the vagina and in the lungs are of frequent occurrence.

Retention of placental fragments in the uterus is of common occurrence. The villi may remain alive apparently for months. They may become infected and give rise to symptoms, or in rare instances may furnish the starting point for a chorionepithelioma.

BLOOD-MAKING ORGANS

BONE MARROW

Anatomy.—The function of the bone marrow is to produce red blood-corpuscles, blood platelets, and certain types of leukocytes required in the circulating blood, and to maintain them in the proportions needed during health and disease. In childhood all the marrow-spaces in the bones are utilized for this purpose, but later in life the process is gradually restricted to the flat and short bones and to the ends of the long bones, except when owing to hemorrhage or disease greater numbers of blood elements are needed; then all the marrow-space available may again be reoccupied. The marrow-space in the long bones not required in the production of red blood-corpuscles and leukocytes is filled up with fat-cells, except in old age when they are usually replaced by edematous or mucous connective tissue (so-called gelatinous tissue).

In fetal life the formed elements of the circulation are produced in the liver and spleen, but before birth the process is transferred to the bone marrow. Under certain conditions the function of producing the cellular elements of the circulation may apparently again be taken up, at least to some extent, by these organs.

Histologically the normal bone marrow contains, aside from arteries, veins, nerves, and a slight amount of connective tissue chiefly in the form of a reticulum, only numerous wide capillaries, and between them the parenchyma which consists of three different series of cells:

1. The myelocyte series of cells.
 - (a) Myeloblasts.
 - (b) Myelocytes (neutrophilic, acidophilic, and basophilic).
 - (c) Leukocytes (the polymorphonuclear leukocyte, the eosinophile, and the mastcell).
2. Erythroblasts, nucleated and non-nucleated red blood-corpuscles.
3. Megakaryocytes, blood platelets.

The origin of the different cells and other elements in the bone marrow and their relation to each other have been pretty thoroughly investigated and determined, and are generally accepted. To recognize the exact nature of each individual kind of

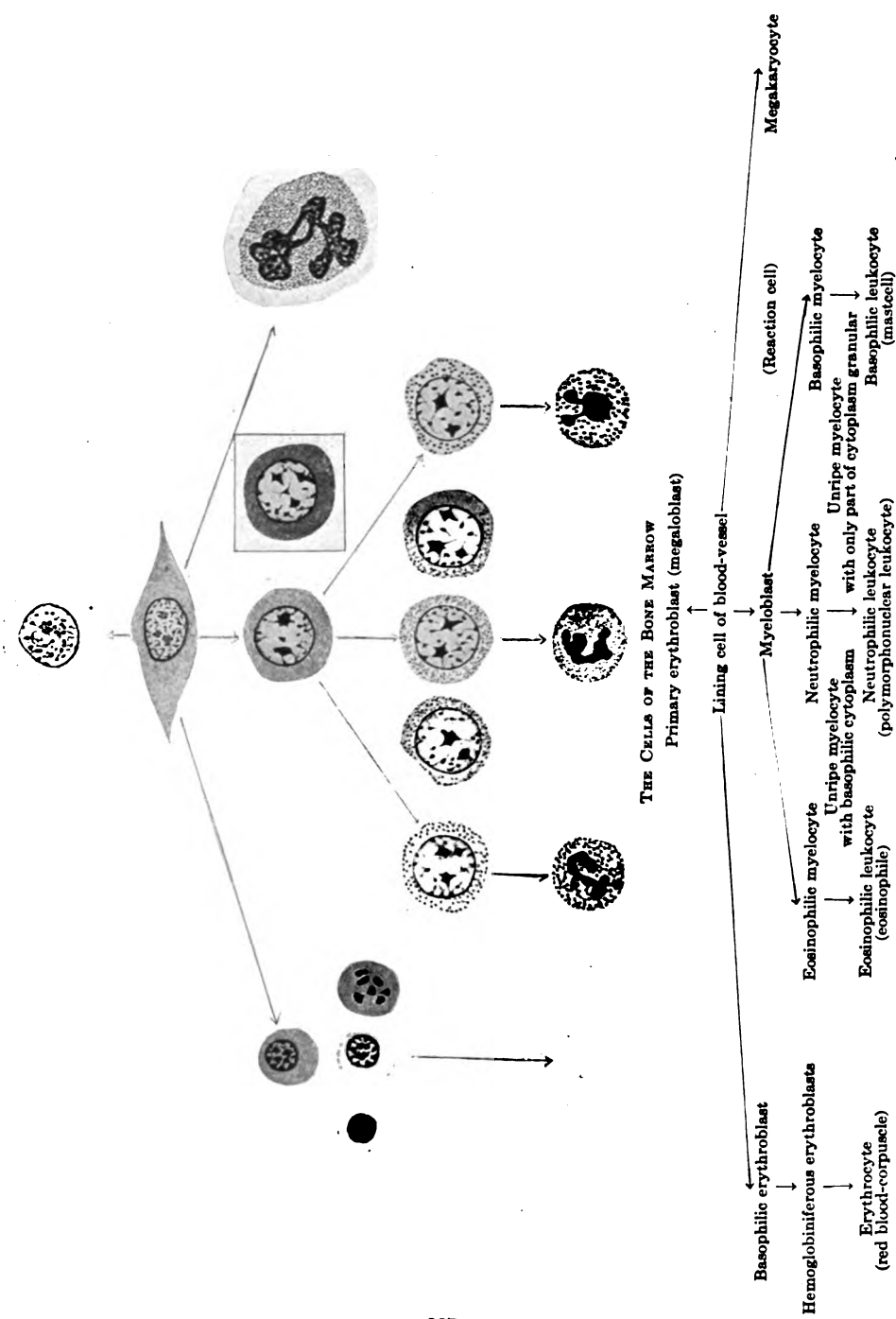


Fig. 462.—Bone-marrow cells (copied from Aschoff's "Pathologische Anatomie").

cell in a section of bone marrow, even when it has been well fixed and stained is, however, not an easy matter.

So far as can be determined lymphocytes do not exist in the normal bone marrow, but may be attracted into it from the blood and may be transformed into plasma-cells under a variety of pathologic conditions.

Regeneration.—Loss of blood leads to great activity on the part of the bone marrow owing to its effort to replace the red blood-corpuscles and leukocytes which have been lost. The same is true if they have been destroyed in any way as, for example, in malaria, where the organisms directly injure great numbers of red blood-corpuscles, and in various suppurative conditions where many polymorphonuclear leukocytes are killed by toxins.

In pernicious anemia the bone marrow always shows great proliferative activity, although the exact nature of the pathologic condition is not yet understood.

The erythroblasts and nucleated red blood-corpuscles are usually present in small clumps. Occasionally an endothelial cell containing brownish pigment granules or masses occurs among the other cells.

Lesions of Toxic Origin.—Many of the toxins which, under various pathologic conditions, obtain access to the circulation are counteracted or neutralized by substances already in the serum or manufactured as required by leukocytes. For the production of these substances an increased number of this or that kind of leukocyte is, therefore, often required. In this way toxins when not too strong lead to proliferation of cells in the bone marrow, and often to an increased number of one kind of leukocyte or of another in the circulating blood.

In many infectious processes the polymorphonuclear leukocytes are greatly increased in the blood (leukocytosis) and therefore, the myeloblasts proliferate in the bone marrow to produce more of them. In trichiniasis and some other infections the eosinophiles are greatly increased in the same way (eosinophilia), and the bone marrow likewise contains many of them in all stages of formation. To a less extent endothelial leukocytes may be produced in the capillaries of the bone marrow as well as elsewhere, and lymphocytes, which normally do not exist in the bone marrow, may invade it and proliferate there.

In the condition known as status lymphaticus lymphocytes may be present in great numbers in the bone marrow and even form lymph-nodules. Probably some toxic condition is responsible for the condition.

Lesions of Infectious Origin.—In the ordinary infectious lesions of the bone marrow the injury done to the marrow-cells is

of much less importance than that done to the surrounding bone tissue. The reason is obvious. If bone-marrow cells are destroyed over a limited extent they are easily dissolved and removed and their function taken over by the bone-marrow cells elsewhere, which readily proliferate if necessary; but the necrotic bone-tissue is dissolved and removed with great difficulty and has to be replaced by new trabeculæ of bone. The process of repair, therefore, occupies the whole field of the lesion, which is filled with granulation tissue and new trabeculæ. After repair has taken place the bone-marrow cells will again gradually grow in and occupy as much of the space as is available.

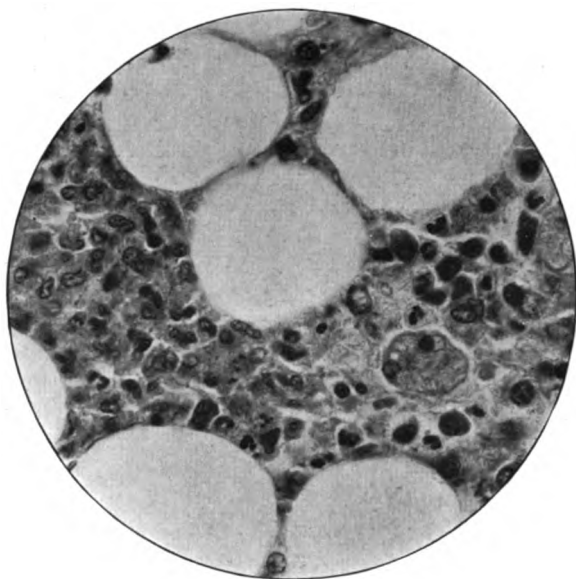


Fig. 463.—Typhoid fever. Part of focal lesion in bone marrow. M.

Acute osteomyelitis may cause the destruction of all the marrow-cells in a long bone, but this is not nearly so important as the killing of the bone-cells. The function of the marrow-cells is easily taken over by the marrow-cells elsewhere, while the necrotic bone has to be removed and replaced by the activity of the osteoclasts and the osteoblasts, unless the surgeon simplifies the process for nature by removing the dead shaft.

The commonest infectious lesions involving the bone marrow are abscesses due to the staphylococcus aureus, less often to the pneumococcus and certain other organisms.

In typhoid fever focal lesions like those in the liver and com-

posed of phagocytic endothelial leukocytes are quite frequent. In small-pox larger lesions due to necrosis are common and characteristic. The inflammatory reaction consists chiefly of endothelial leukocytes which collect around the lesions, and where the latter have involved fat-cells become filled with fat-droplets.

Tuberculous lesions are fairly common and may occur as acute miliary tubercles or as large caseating masses.

Tumors.—Two different types of tumors originate from bone-marrow cells. The more frequent and important is the myeloblastoma, of which the cells tend to differentiate like those of the myelocyte series. Metastasis readily takes place into the circulating blood, where it is known as myelogenous leukemia. Secondary tumor nodules may form in various organs, beneath the periosteum of the vertebral column, etc. Sometimes they exhibit more or less of a green color; the condition is then called chloroma.

The other tumor is the myeloma and is of rarer occurrence. The type-cell from which it arises is not known. The tumor is strikingly characterized clinically by causing in some way or other the presence of albumose in the urine.

The bone marrow is frequently involved by secondary tumors. The lymphoblastoma when present anywhere in the body is likely to give rise to metastases in the bone marrow, whether lymphatic leukemia exists or not. Likewise carcinomas of the prostate and of the breast commonly produce early metastases in the bone marrow, and the stroma is often of an osteoid type owing to its origin from osteal cells.

SPLEEN

Introduction.—The functions of the spleen are not fully understood. Complete removal of it does not cause death; on the contrary, it is a procedure recommended for the cure of certain pathologic processes occurring in the organ.

Enlargement of the spleen is always an important clinical sign. It may be due to a variety of causes. To be satisfied to call it hypertrophy of the spleen or splenomegaly is shirking one's duty and neglecting one's opportunity. Clinician and pathologist alike should strive to ascertain in each individual instance the cause of the enlargement, and thus be able to name the process accurately. The enlargement may be of circulatory, toxic, or infectious origin, or due to a retrograde change or to a new-growth. The hypertrophied organ may weigh many kilos.

Anatomy.—The anatomic structures of the spleen recognizable to the naked eye are the capsule with its inward prolongations, the trabeculæ; the blood-vessels; the lymph-nodules (Malpighian

bodies); and the pulp. The lymph-nodules and the pulp together form the parenchyma, the important and characteristic part of the spleen. In addition the spleen contains nerves, but no lymph-vessels. The lymph-nodules are more prominent in youth, the trabeculæ in old age.

The capsule and trabeculæ are composed of fibroblasts together with a few smooth muscle-cells, and contain numerous elastic fibers which increase in number with age. The arteries have well-defined walls. At first they run in the larger trabeculæ. As they get smaller they leave the trabeculæ and are surrounded with masses of lymphoid tissue, the lymph-nodules, into which they finally ramify in the form of numerous capillaries before passing outside to the veins of the pulp.

The terminal veins of the spleen begin as dilated structures, lined with long narrow endothelial cells which run lengthwise of the vessels and have prominent oval nuclei. The cells rest on short, delicate fibrils which stain deeply with phosphotungstic acid hematoxylin and which sharply define the walls of the veins. The terminal veins combine into pulp veins which enter the trabeculæ and unite to form the splenic vein.

The arteries are end arteries; the veins do not anastomose.

The lymph-nodules have the same structure and contain the same kind of cells as the cortical masses with germinative centers in the lymph-nodes.

That part of the pulp which lies between the walls of the terminal and pulp veins is small in amount. It contains a few lymphocytes, and occasionally endothelial cells and fibroblasts. Under pathologic conditions other cells may be present in varying numbers, such as plasma-cells, eosinophilic myelocytes, and rarely neutrophilic myelocytes.

The cells which increase most in the spleen under pathologic conditions are polymorphonuclear leukocytes, endothelial leukocytes which are usually very phagocytic, lymphocytes; plasma-cells, eosinophiles, and myelocytes.

The function of the spleen is partly to produce lymphocytes for the blood. In addition it seems probable that under pathologic conditions the endothelial cells and leukocytes may multiply and produce antitoxins to counteract toxic substances brought to them. Under these conditions they may incorporate red blood-corpuscles, leukocytes and lymphocytes in order to obtain nutritive substances needed. The most striking example of this function is seen in typhoid fever. In some infections, such as diphtheria and scarlet fever, proliferation of endothelial cells in the lymph-nodules is usually a prominent lesion.

Retrograde Changes.—*Fat* is often present in the endothe-

lial cells which proliferate in the lymph-nodules in diphtheria, scarlet fever, etc. It also occurs in abundance in the hyaline areas which are often present in the walls of the arteries in acute infectious processes, and also in chronic arteriosclerosis. In a case of diabetes mellitus in which lipemia was present the pulp contained large numbers of endothelial leukocytes filled with fat so that the spleen in consequence weighed 400 grams.

Amyloid is commonly present in the spleen when it is formed elsewhere in the body. It may be confined practically to the lymph-nodules and blood-vessels (sago spleen), or, as more often happens,

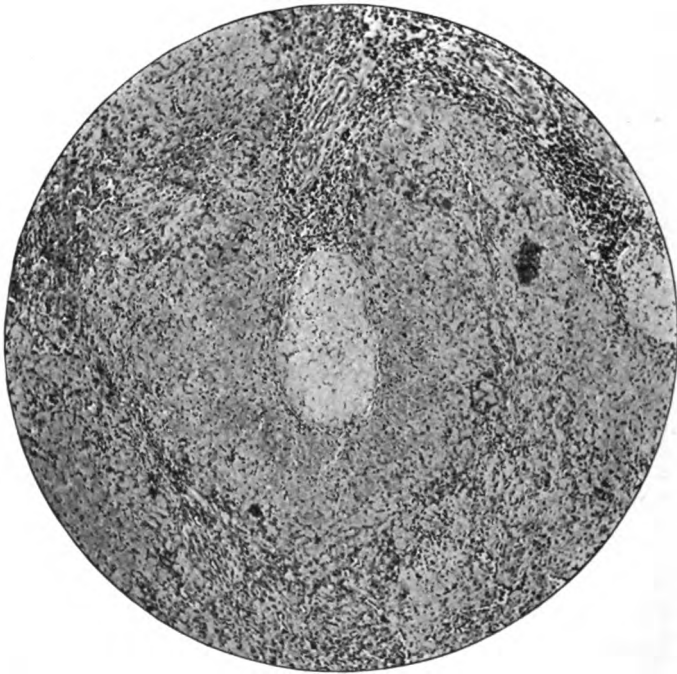

Fig. 464.—Amyloid infiltration of a lymph-nodule in the spleen. M.

may be more or less generally diffused throughout the pulp. It causes a gradual thickening of the reticulum so that the included cells atrophy and disappear, just as in the liver, and the blood sinuses of the pulp become compressed and narrowed. As a result of the amyloid formation the spleen may be considerably enlarged (400 grams and over). It is dense to the touch and on section dry and translucent.

Hyaline material is found occasionally in the spleen in two different situations, in the walls of the arteries in acute infectious

processes and in chronic arteriosclerosis in the same locations in which fat occurs, and in the lymph-nodules. It may appear in the latter location as a thickening of the reticulum, due to a fibrinoid change, or as hyaline connective tissue following endothelial hyperplasia.

Hyalin is sometimes found in small globules in the cytoplasm of plasma-cells which have undergone retrograde change.

Spiculated bodies have been found in the spleen in a few instances inclosed in endothelial leukocytes and giant-cells. They may be quite numerous and occur in foci or diffusely scattered. The lesion resembles miliary tuberculosis, but no necrosis is produced. The bodies seem chemically to be of a fibrinoid character. They are evidently not the cause of the lesion, which is probably of infectious origin, but a secondary formation.

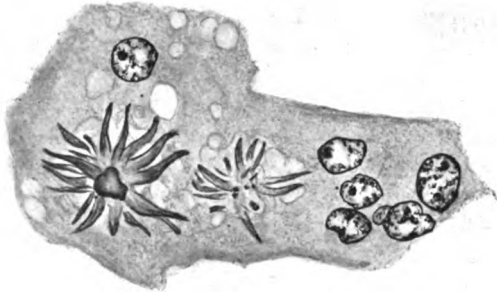


Fig. 465.—Repair. Foreign body giant-cell containing spiculated spherical bodies, probably of a fibrinoid character.

Blood pigment is of frequent occurrence. It is usually found in endothelial leukocytes which take up red blood-corpuscles and transform the hemoglobin into hemosiderin. The pigment is always present following typhoid fever. The leukocytes are at first in the blood sinuses, but usually emigrate from the vessels and collect in clumps, especially around the trabeculæ and arteries, where they gradually digest the pigment.

Spherical bunches of *bright orange-colored hematoidin crystals* are often formed in infarcts, and as organization occurs may be taken up by endothelial leukocytes. Small foreign body giant-cells may be formed occasionally by fusion of two or more leukocytes.

In hemochromatosis endothelial leukocytes filled with pigment are found in the spleen, but usually not in large numbers.

Melanin due to the malarial parasites occurs in red blood-corpuscles, where it is formed by the organisms, and also more

abundantly in the endothelial leukocytes free in the veins and also collected in the intervascular tissue everywhere. In chronic malaria the connective-tissue stroma of the spleen is increased in amount and packed with endothelial leukocytes filled with pigment. As a result of the pigment the spleen may be colored a dark gray or even greenish black. In the acute stage the spleen may be enlarged to 900 grams or more; later it may contract to less than the normal weight.

Carbon is occasionally found in small amounts in the spleen. It is inclosed in endothelial leukocytes which tend to collect in small clumps, usually around the arteries and trabeculæ.

Disturbances of Circulation.—*Acute congestion* of the spleen occurs in many acute infectious processes, but especially when a septicemia is present. Under these conditions it is usually combined with an accumulation of leukocytes. The organ is enlarged and soft (so-called acute splenic tumor), on section of a dark to grayish-red color, and on scraping yields much pulp.

Chronic passive congestion is more likely to occur uncomplicated by infection. It is due to general or local obstruction of the venous circulation, most often caused by lesions of the heart. The spleen under these conditions is usually somewhat enlarged, dense in consistence, and of a dark to bluish-red color (cyanotic induration). The connective tissue shows a moderate increase everywhere in the organ.

Banti's disease seems to be a symptom-complex resulting from partial occlusion of the splenic or portal vein and marked obstruction to the outflow of blood from the spleen. Swelling of the spleen and much increase of the connective tissue of the organ result in consequence.

Infarcts of the spleen due to occlusion of arteries are frequent and usually of the anemic variety, although hemorrhagic infarcts sometimes occur. They are in general wedge-shaped and cause slight bulging of the capsule. Organization of an infarct usually proceeds rapidly at first. The edge is deeply congested and leukocytes migrate in numbers into the necrotic tissue. Later the process of repair slows up and the removal of the necrotic tissue and replacement by scar tissue take a long time. Hematoidin crystals in bunches are generally formed in considerable numbers in the infarct and at its border, and are often taken up by endothelial leukocytes which sometimes fuse to form giant-cells around them. Other leukocytes of the same type may be filled with hemosiderin pigment.

Lesions of Mechanical Origin.—The blood sinuses of the spleen are susceptible of great distension by the accumulation of blood-corpuscles and leukocytes within them. If the distension

persists for any length of time the mechanical injury done the fibroblasts causes them to proliferate. In this way an increase of collagenous fibrils and reticulum is produced. If the organ contracts later the increased amount of connective tissue persists as a sclerosis. Such a sclerosis may be moderate in amount as in chronic passive congestion, abundant as in Banti's disease owing to mechanical obstruction of the splenic vein, or very marked as in certain chronic infectious diseases, especially malaria and kala-azar.

Lesions of Toxic Origin.—Toxins of various sorts are brought to the spleen by the circulating blood, but there is no abundant parenchyma as in the liver to be affected by them. Certain toxins, as in diphtheria and scarlet fever, cause marked proliferation of the endothelial cells lining the reticulum of the lymph-nodules. The lymphocytes may be largely incorporated and digested by these cells. The process may be interpreted in two ways: (a) The endothelial cells proliferate to produce an antitoxin to neutralize the toxin brought by the circulation; the lymphocytes are utilized as nutrition; (b) the lymphocytes are injured and destroyed by the toxin and are then taken up by the endothelial cells which proliferate in sufficient numbers to perform the work required of them (process of repair). The first view seems the more likely, because when the toxin is strong enough to produce a fibrinoid change of the reticulum or necrosis of the lymphocytes, the endothelial cells proliferate but slightly or not at all.

Other toxins cause accumulations of polymorphonuclear leucocytes in the blood sinuses, sometimes in great numbers. In typhoid fever endothelial leukocytes collect abundantly in the same way in the blood sinuses and are filled with many red blood-corpuses. Toxins from other infections do not cause so great an accumulation of them.

Certain toxins bring about abundant collections of lymphocytes, usually in the form of plasma-cells, in the spleen. They are generally situated around the trabeculæ and blood-vessels. Rarely they collect in numbers beneath the lining epithelium of the larger veins and project it in festoons into the lumen.

A variety of toxic conditions may cause eosinophiles to accumulate in considerable numbers in the spleen.

Lesions of Infectious Origin.—It is not easy or even always possible to separate the toxic from the infectious lesions of the spleen. In fact, the two are very often combined. In septicemias due to the staphylococcus aureus, the streptococcus pyogenes, the anthrax bacillus, etc., cultures will necessarily show the organisms present, although they may be confined entirely to the circulating blood. When focal lesions are present, however, the relation of

the infectious organism to the process is definitely evident. These lesions require no especial consideration here, but should be sought in their proper place under the causal agents.

Abscesses may be caused by a variety of organisms (staphylococcus aureus, streptococcus, typhoid bacillus) the identity of which has to be determined in each specific instance.

The *malarial parasites* may produce all degrees of enlargement of the spleen up to a weight of about one kilo, dependent on the duration and severity of the infection and the variety of the organism present. As a result of the enlargement due partly to distension of the blood sinuses by red blood-corpuscles, but chiefly to the great accumulation of endothelial leukocytes filled with red

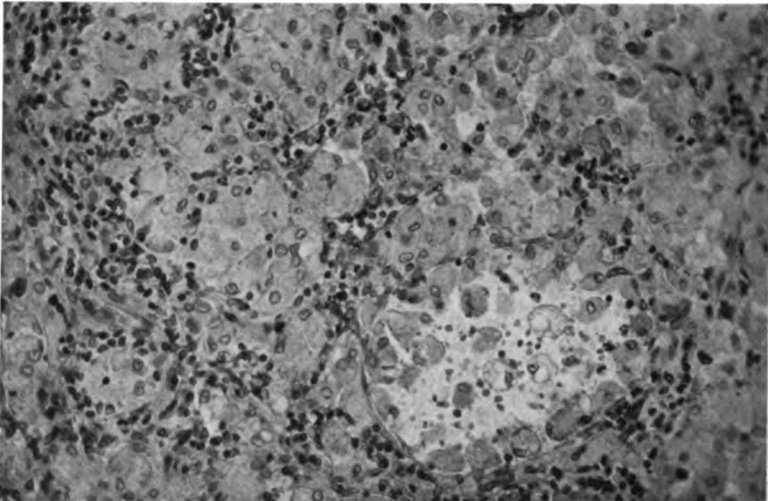


Fig. 466.—Spleen. Gaucher's type of splenomegaly. M.

blood-corpuscles, parasites and pigment, the connective-tissue cells proliferate and produce more intercellular substance. Later, when the organ contracts the amount of stroma is relatively much increased and the organ is dense and firm (sclerosed).

In *Gaucher's type of splenomegaly*, where the spleen is greatly enlarged and the blood sinuses distended with proliferated endothelial cells and leukocytes, a parasite of some sort or other is probably the cause of the lesion.

Infection with the *tubercle bacillus* shows most often in the form of miliary tubercles which may be exceedingly numerous. Occasionally conglomerate tubercles of various sizes are formed and rarely large caseous masses.

Syphilitic infection is rare in the spleen, although in congenital syphilis the spirochetes may be very numerous, especially in the walls of the arteries.

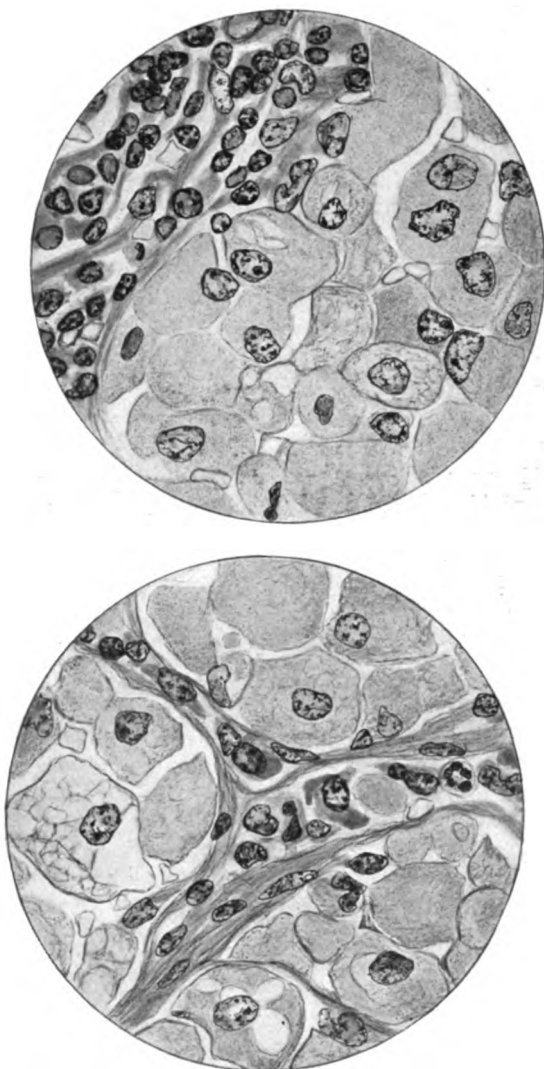


Fig. 467.—Spleen. Gaucher's type of splenomegaly.

Tumors.—The lymphoblastoma may be primary in the spleen. Occasionally it is scirrhus in type and has been called primary

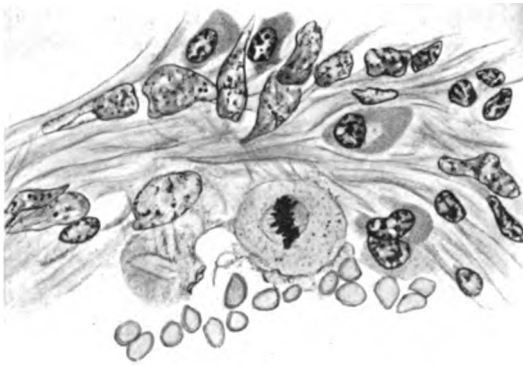


Fig. 468.—Spleen. Gaucher's type of splenomegaly. Mitosis of endothelial cell lining blood sinus.

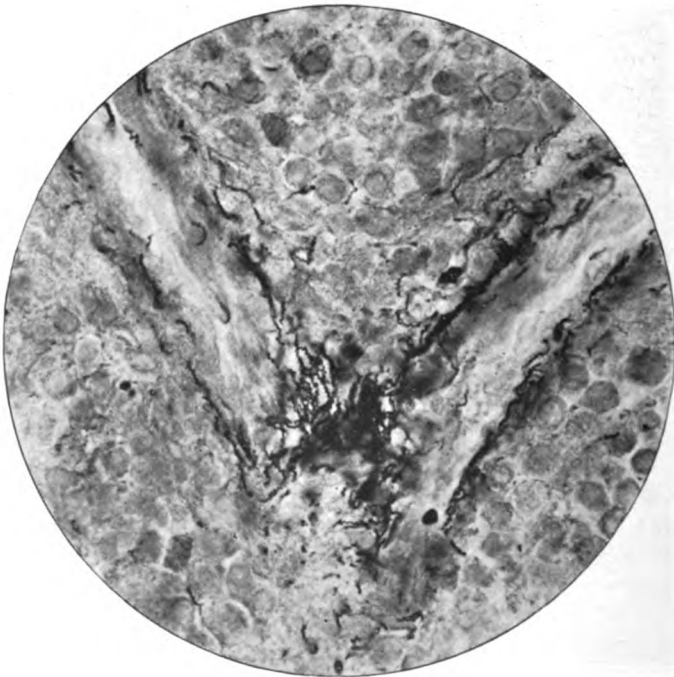


Fig. 469.—Syphilis, congenital. Spleen. Many *treponemata pallida* in walls of arteries. M.

Hodgkin's disease of the spleen. The tumor may cause great enlargement of the organ. Other primary tumors are rare. Among them the lymphendothelioma deserves mention because it is pretty generally agreed that lymph-vessels do not exist normally in the spleen.

Of the secondary tumors the most important are the lymphoblastoma and the myeloblastoma. Both may cause great and usually uniform enlargement of the spleen. Metastatic cancer, as a rule, occurs in separate nodules.

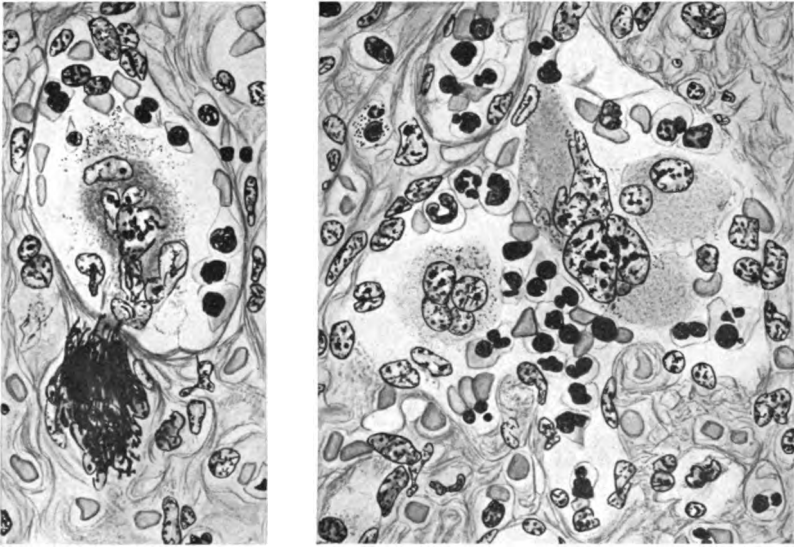


Fig. 470.—Spleen from a case of polycythemia. Several large cells (megakaryocytes?) with multiple or large lobulated nuclei; also numerous nucleated red blood-corpuscles.

Hypertrophy of the spleen, or splenomegaly, is a term in common use, especially clinically. It is useful and justifiable only when an accurate diagnosis of the actual condition present cannot be made. Many pathologic processes result in more or less, occasionally extreme, enlargement of the spleen, for instance, amyloid formation, various infections including malaria and kala-azar, primary and secondary tumors. The tendency is to restrict the term splenomegaly to those forms of chronic enlargement of which the nature is not yet fully understood. The use of the term should be discouraged, because it means only that the spleen is enlarged, and the cause therefor not known.

One rare form of enlargement of the spleen is associated with marked increase of the red blood-corpuscles in the circulating

blood (polycythemia, Vaquez's disease). They may number up to eight or even up to fifteen millions per cubic millimeter. The bone marrow is red and hyperplastic.

It is possible that the condition is the result of a tumor arising from a type-cell, the erythroblast, and should be called an erythroblastoma. The condition would be analogous to the two forms of leukemia due to growth of tumor-cells (lymphoblastoma and myeloblastoma) in the circulating blood. Histologically the spleen shows fairly numerous large cells with multiple or with large lobulated nuclei, and nucleated red blood-corpuscles in the blood sinuses, while the connective-tissue stroma, which is considerably increased in amount, is infiltrated with large numbers of eosinophiles and also with fairly numerous endothelial leukocytes and lymphocytes.

LYMPH-NODES

Lymph-nodes are composed of the following anatomic structures:

1. The parenchyma arranged cortically in masses containing germinative centers, and in the medulla in narrow branching prolongations called medullary cords.
2. The lymph sinuses running between the parenchyma, on the one hand, and the capsule and its inward projections, on the other.
3. The capsule and its septa, the trabeculæ, within the lymph-node.
4. Blood-vessels.
5. Nerves.

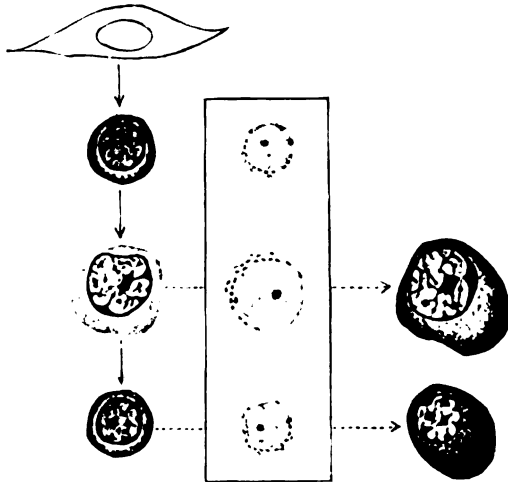
The parenchyma is composed chiefly of cells of the lymphocyte series and they are the important and characteristic cells of the lymph-node. Under normal conditions they consist of two types of cells, *lymphoblasts*, occurring in the germinative centers, and *lymphocytes*, forming the remainder of the parenchyma.

Under pathologic conditions both types of cells can give rise to plasma-cells, but most of the latter arise from lymphocytes. They are present in large numbers in many inflammatory processes. All these cells possess the power of migration and of proliferation.

Next to the cells of the lymphocyte series the most important cells in lymph-nodes are the endothelial cells. They line the blood-vessels, the lymph sinuses and the reticulum of the parenchyma. Those lining the sinuses and the reticulum play a much more important part in pathologic conditions than those lining the blood-vessels. They may increase greatly in number, desquamate from the walls of the sinuses and from the reticulum

and form endothelial leukocytes. As a rule, they exhibit marked phagocytic properties for other cells.

The capsule and trabeculae are composed of fibroblasts, among which are occasional smooth muscle-cells. Fibroblasts also form the reticulum in the lymph sinuses and in the parenchyma and strengthen the walls of the vessels.



THE CELLS OF A LYMPH-NODULE

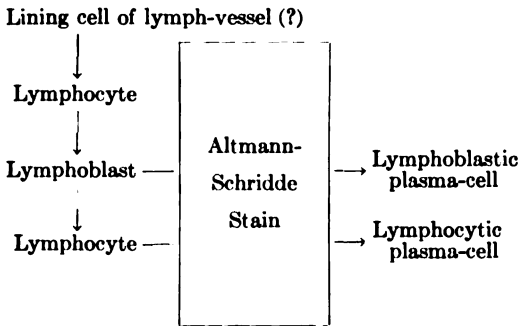


Fig. 471.—Lymphocyte series of cells. (Copied from Aschoff's "Pathologische Anatomie.")

It is a function of lymph-nodes to produce lymphocytes for the blood and to counteract the unfavorable influences of various toxic substances and pathogenic micro-organisms brought to them. In doing this all the three important types of cells may, under different conditions, play an important part. Sometimes only the lymphocytes are affected; at other times chiefly the endothelial

cells of the sinuses or in the germinative centers. Occasionally the fibroblasts seem most stimulated.

The lymph-nodules occurring in various tissues lack lymph sinuses. They correspond in structure to the cortical masses of parenchyma containing the germinative centers.

Lesions of Mechanical Origin.—Certain substances reach the lymph-nodes through the lymphatics and seem to act only mechanically. The commonest of these is *carbon*, but hemoglobin and various pigments are among the substances which may act in much the same way. If they are not carried there by endothelial leukocytes they are taken up by these cells which then migrate into the parenchyma of the node or occasionally into the fibrous and fat tissue outside of it, and settle down more or less permanently, according to whether or not they can digest what they have taken up. The accumulation of large numbers of the phagocytic leukocytes causes the disappearance of the lymphocytes of the parenchyma and some increase of the connective-tissue stroma.

Lesions of Toxic Origin.—Toxic substances reach lymph-nodes chiefly through the lymphatics, to a less extent through the blood-vessels. The distribution of the resulting lesions varies accordingly. Toxins reaching a lymph-node through the blood affect chiefly the lymph-nodules; those arriving through the lymphatics produce their greatest effect in the lymph sinuses.

The toxic lesions in the lymph-nodules may show proliferation of the endothelial cells lining the reticulum, with phagocytosis of many or all of the neighboring lymphoblasts, which are gradually digested. Sometimes the connective-tissue reticulum is bathed in serum and transformed into hyaline fibrinoid material.

Toxins arriving through the lymph sinuses may cause only a hyperplasia of lymphocytes or of endothelial leukocytes or an accumulation of polymorphonuclear leukocytes. Various combinations of these cellular elements also occur and the endothelial leukocytes are often phagocytic for the others. If the toxin is very strong, fibrin may be formed from the serous exudation and hemorrhage may take place. It is also possible for more or less extensive necrosis to be produced.

The toxic substances are of the greatest variety—bacterial toxins of all sorts, degenerative products derived from necrotic cells, etc. The character and amount of the exudation depend on the strength and nature of the toxic substances.

Lesions of Infectious Origin.—Lesions of infectious origin are exceedingly common in lymph-nodes and may be caused by a great variety of organisms. They frequently complicate toxic lesions.

Infectious lesions tend toward a more or less focal distribution, but are often diffuse owing to the numerous large lymph

sinuses in a lymph-node. They may cause only an accumulation of serum and polymorphonuclear leukocytes within the sinuses, with few or many endothelial leukocytes and lymphocytes in addition, or may produce more or less extensive necrosis and abscess formation. There may be hemorrhage in addition. Much depends on the nature of the infecting organisms. In buboes due to the plague bacillus the lymph sinuses are often greatly distended by the masses of bacilli within them. The inflammatory exudate may be slight. In anthrax infections hemorrhage is common. With the staphylococcus aureus abscesses are usually formed; with the streptococcus they are not so frequent. The typhoid bacillus causes a great accumulation of endothelial leukocytes. In inguinal buboes small abscesses surrounded with a wall of granulation tissue are common. Certain types of lesions often suggest certain infectious agents; in the same way lesions in certain lymph-nodes suggest certain agents; thus, inguinal buboes point to Ducrey's bacillus, or the treponema pallidum, but it does not pay to place too much reliance on such evidence.

The tuberculous lesions of lymph-nodes are of several types, but will be found discussed under that infectious agent.

Tumors.—The characteristic primary tumor arising from lymph-nodes is the lymphoblastoma. Its cells may closely resemble the cells of the lymphocyte series or depart more or less widely from them, especially in being somewhat larger. The tumor may grow very rapidly and give rise to metastases in various organs and in the circulating blood, or grow slowly in scirrhous form, with an abundant stroma which is often infiltrated with numerous eosinophiles.

Secondary tumors in lymph-nodes are of common occurrence, especially carcinomas. The likelihood of the occurrence of this form of metastasis is so well understood clinically that it is customary to remove the regional lymph-nodes when a cancer is operated on, whether they appear involved or not.

ORGANS OF THE CENTRAL NERVOUS SYSTEM

Under this heading are included not only the brain and the spinal cord, but also their coverings—the pia-arachnoid and the dura, and the dural endothelium lining the space between the two membranes.

BRAIN AND SPINAL CORD

Introduction.—The lesions of the brain and cord are more difficult than the lesions of any of the other organs to present from the biologic point of view. This difficulty is due to our lack of knowledge of the early stages of many of the pathologic processes affecting them. We study these processes largely in the late stage of repair, that is, when the end result, sclerosis, is all that is left to mark the site of the various lesions.

In the study of most organs it is the nature of the lesion which interests us. In the central nervous system the location of a lesion and the symptoms depending upon the location have been more important than the nature of the lesion, and have received the most attention. This is not true of any other organ. A solitary tubercle in one part of the brain or cord causes entirely different symptoms from those produced by a similar nodule situated in some other part. The reason for the variety of symptoms is that the nerve-cells and fibers in different locations perform different functions. On account of this important effect of the location of the lesion and the variety of symptoms which may be caused by the same lesion, the number of symptom-complexes arising from the lesions of the central nervous system is probably much greater than the actual number of pathologic processes producing them.

The pathologist's point of view in regard to the central nervous system is first to ascertain the number and character of the injurious agents affecting it, and the nature of the lesions which they cause, and then to trace the secondary degenerations which follow in nerve-fibers when nerve-cells have been destroyed, or nerve-fibers have been cut or injured at any point.

Lesions of the brain and cord are usually complicated by the presence of many endothelial leukocytes which are attracted by the myelin set free whenever necrosis of nerve-cells and especially of neuraxes has taken place. The leukocytes filled with fat and myelin infiltrate the surrounding tissues, and particularly

the walls of blood-vessels, often in great numbers and remain there until they have digested the material they have incorporated. Endothelial leukocytes are also often attracted in the same way by red blood-corpuscles which have been set free by hemorrhage.

Anatomy.—For the anatomy and histology of the central nervous system a good text-book on normal histology should be consulted. Here only a few points of interest can be briefly emphasized.

The brain and cord are composed of a great number and large variety of nerve-cells or units called neurons. Each neuron consists of a cell-body which possesses an axis-cylinder process or neuraxis with its terminal arborization, and usually also cytoplasmic processes known as dendrites. Some of the neuraxes are of great length.

A peculiarity of the central nervous system is that it possesses in its stroma, in addition to the blood-vessels and connective tissue of other organs, another supporting tissue, of epiblastic origin, formed by the neuroglia cells and their fibrils. The neuroglia cells react to injurious agents of various sorts much as fibroblasts do, but there is one marked difference between these two types of cells. Fibrin stimulates proliferation of fibroblasts, but has little or no effect on neuroglia cells. On this account fibrous tissue is prominent in certain types of lesions in the brain, for instance in the periphery of solitary tubercles and in the walls of old abscesses, while neuroglia tissue is relatively or actually increased wherever nerve-cells or fibers have disappeared, as in scleroses of all sorts of origin.

The brain is practically a solid organ. All the blood and lymph-vessels within it are comparatively small. There are no large communicating spaces outside of the meninges and ventricles that offer easy routes for the spread of infection. On this account tuberculous lesions starting in brain tissue grow uniformly peripherally and form solitary tubercles which may reach a large size. They do not spread irregularly unless they reach the meninges or a ventricle; then they may extend rapidly.

The following observations in regard to changes which take place when a nerve-cell or its neuraxis is injured seem to be definitely established:

If the body of a nerve-cell is destroyed the neuraxis and its termination degenerate and disappear.

If a nerve-fiber is injured or severed the distal portion and its termination degenerate. There also occurs an ascending degeneration of the neuraxis, at least as far as the first node of Ranvier.

When an axis-cylinder process has been destroyed the nerve-

cell is able in time to reproduce it again. Regeneration always takes place from the proximal end of the nerve-fiber, that is, from the undestroyed portion adjoining the nerve-cell, or from the cell-body itself, if the whole fiber has been destroyed.

If a nerve-fiber is destroyed and regeneration does not take place, as following an amputation, the cell-body undergoes certain alterations.

These generally accepted facts in regard to the neuron have been established by the study of the embryologic development of the central nervous system, by observation of appropriate clinical cases, and by much experimental work. They are of

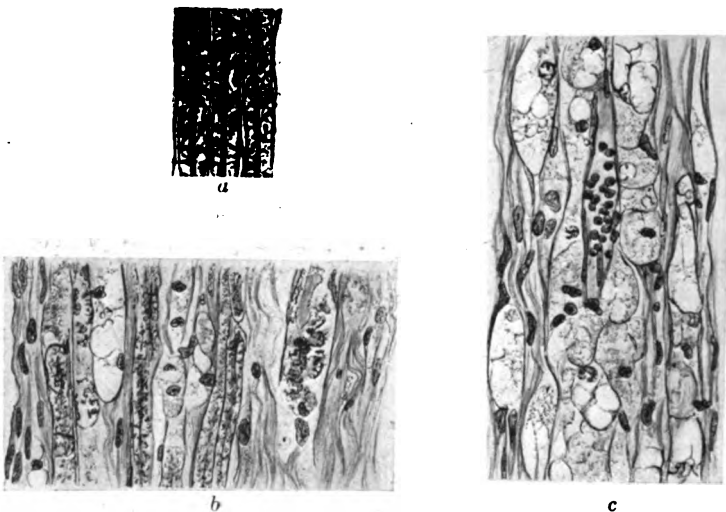


Fig. 472.—Nerve of rabbit following section and suture. *a*, Normal; *b* and *c*, endothelial leukocytes in nerve filled with myelin and fat.

great importance for the clear understanding of the various lesions of the central nervous system.

Retrograde Changes.—Various changes are found in the central nervous system in connection with the lesions occurring in it. Those affecting the nerve-cells and their processes are the most important.

Much work has been done on the ganglion cells by means of the Nissl staining method which renders the chromatophile granules or tigroid bodies in the cytoplasm noticeably prominent. The changes obtained by experimental work on animals are more trustworthy than those observed in man, because it is always difficult to determine to what extent the alterations found are

due to postmortem changes. The tigroid bodies may dissolve and disappear (chromatolysis), the cell-body swell, and the nucleus become peripherally located. These are the three principal changes aside from necrosis.

The presence of *fat* in nerve-cells is always a sure guide to disturbances of metabolism. In the cell-body it must be distinguished from the pigment granules, which are also stained by osmic acid, but less intensely. In the nerve-fibers fat is of frequent occurrence in a variety of conditions, but especially

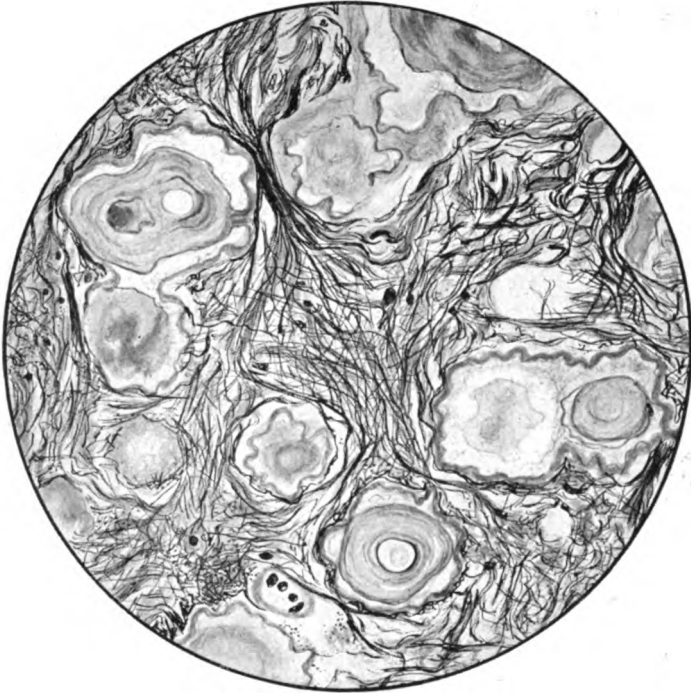

Fig. 473.—Cerebellum. Calcified corpora amylacea surrounded by neuroglia fibers.

in acute infectious processes, such as diphtheria and acute epidemic cerebrospinal meningitis, when it may be wide-spread in the brain, cord and peripheral nerves. It also occurs focally in the brain and cord around fat emboli, trichinæ, abscesses, etc. When the nerves undergo complete degeneration the fat and the myelin are taken up by endothelial leukocytes and slowly digested.

Necrosis of nerve-cells is most common in focal lesions due to cutting off nutrition by thrombus or embolus, or to infection as

in anterior poliomyelitis. It probably occurs also to some extent as the result of strong diffusible toxins, but is not demonstrable with the same certainty.

Necrotic nerve-cells sometimes undergo *calcification* and persist indefinitely in the lesions where they occur. Lime-salts occur normally in the pineal gland and are also deposited in corpora amylacea, in the walls of hyaline blood-vessels, and in necrotic parts of brain tumors. Occasionally the lime-salts incite adjoining fibroblasts to organization and as a result bone-cells are formed.

Hyalin occurs frequently in the central nervous system in the small, concentrically layered balls known as corpora amylacea, and normally as the ground substance of the brain and in the pineal body. It is also occasionally formed abundantly in the walls of blood-vessels, especially in the cerebellum, and often undergoes calcification, so that rarely large concretions may result, or stiff blood-vessels which project from the cut surface like ends of wire.

Disturbances of Circulation.—Excess or insufficiency of blood in the brain may have serious consequences owing to the importance of the organ. Congestion is of frequent occurrence, being caused, for instance, by sunstroke, alcohol, and various acute infectious processes, especially when located in the meninges. It may give rise to more or less edema of the brain tissue. Chronic passive congestion does not seem to cause any serious disturbance.

Sudden anemia leads to loss of consciousness, but when the anemia arises slowly the brain accommodates itself more or less successfully to the condition.

The more important lesions of circulatory origin are two in number, hemorrhage and local anemia or infarction.

Hemorrhage may take place into the brain or cord substance, into a brain cavity, or into the meninges. It may be miliary in size and produce little or no effect, or so large that death results immediately. If the hemorrhage is of any size it exerts pressure on the surrounding tissue and causes more or less anemia. It is often accompanied or followed by multiple miliary perivascular hemorrhages.

Hemorrhage usually takes place from arteries, rarely from veins, and certainly, as a rule, from vessels which are weakened as the result of chronic degenerative changes (arteriosclerosis) or acute toxic or infectious lesions. Sometimes it occurs in tumors, especially gliomas.

If the hemorrhage does not cause death, it is followed by the processes of repair which begin at the periphery and slowly

work toward the center. The blood clots, the fluid contents are squeezed out and absorbed. The hemoglobin to a large extent escapes from the red blood-corpuscles. Part of it gives rise to hematoidin crystals while the rest is transformed by endothelial leukocytes into hemosiderin and gradually digested. Granulation tissue composed of blood-vessels and connective tissue slowly invades and organizes the fibrin, but it is rarely abundant and it never fills up the cavity completely. The amount of connective tissue formed is small, unless there was much fibrin to organize. The surrounding neuroglia tissue proliferates to some extent, but not abundantly. The final result is a cyst filled with fluid, and often traversed by delicate strands composed of neuroglia and connective tissue and capillary blood-vessels. The walls of the cysts in the earlier stages of formation are infiltrated with endothelial leukocytes containing hemosiderin and fat.

Local anemia or *infarction* of the brain is fairly common, particularly in old age, and is always serious, but especially so when it involves important nerve-cell centers or fiber tracts. The lesion is usually due to thrombosis on top of arteriosclerotic changes in the blood-vessels, but is also often the result of embolus. If the vessel is but partly occluded only the more highly differentiated nerve-cells may undergo necrosis and disappear, just as the muscle-fibers do under similar conditions in the heart. The result is more or less sclerosis although there has been no increased production of neuroglia fibers.

When the vessel is completely obstructed and all the tissue-cells are killed they are dissolved and the fluid portions absorbed. Myelin and other fatty substances are taken up by endothelial leukocytes which often accumulate in large numbers around the lesions, and especially in the adventitia and intima of the blood-vessels in the neighborhood of the focus.

But little reaction on the part of the blood-vessels and connective tissue occurs, because no fibrin is ordinarily formed and, therefore, they are not stimulated. Regeneration of the neuroglia tissue takes place only to a limited extent, not enough to fill up the cavity which remains as a cyst filled with clear serous fluid. The brain tissue does not ordinarily collapse and neuroglia tissue does not contract to any extent; therefore, the scars of most other organs are here replaced by cysts.

Lesions of Mechanical Origin.—The brain and cord may be affected mechanically in a variety of ways, by trauma, by hemorrhage or by pressure.

1. *Trauma* is of common occurrence. It may be caused directly by a blow, a fall, a bullet, or indirectly by contrecoup. It frequently leads to hemorrhage.

2. *Hemorrhage* may take place within the brain, disrupting it, owing to rupture of a blood-vessel usually as the result of arteriosclerotic changes, or in the meninges from laceration as a result of trauma, or in consequence of so-called hemorrhagic pachymeningitis. Hemorrhage always causes pressure.

3. *Pressure* may be exerted on brain and cord tissue from within or from without.

(a) Internal pressure may be due to tumor, hemorrhage, abscess, solitary tubercle, gumma, internal hydrocephalus.

(b) External pressure may be exerted by inflammatory exudations (meningitis due to various organisms), tumors (dural endothelioma), abnormalities (cholesteatoma), hemorrhage.

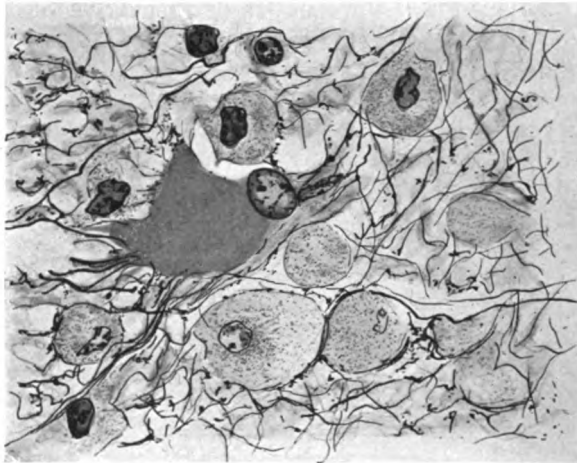


Fig. 474.—Brain. Softening due to arteriosclerosis. One large neuroglia cell with numerous fibrils; several endothelial leukocytes filled with fat-droplets.

4. *Caisson disease* is the term applied to mechanical lesions of the central nervous system, due to sudden expansion of gases in the tissues in consequence of too rapid lowering of external air pressure following compression.

Lesions of Toxic Origin.—Toxins of various sorts, but especially of infectious origin, cause retrograde changes in the neurons of the central nervous system. They reach the cells through the circulation or by direct diffusion from lesions in the meninges. The changes are shown by alterations in the cell-bodies and by the presence of fat not only there, but also in the nerve-fibers. If the fat is not too abundant it will in time be used up and disappear so that recovery can take place, as after diphtheria. It seems

probable that under certain conditions more or less extensive diffuse necrosis of nerve-cells must take place, just as occurs in some of the other organs, as, for instance, the liver, heart, and kidney.

The neuroglia cells may also be affected by toxins, especially those diffusing from infectious processes in the meninges, as in acute epidemic cerebrospinal meningitis.

Lesions of infectious origin are of frequent occurrence within the brain tissue, and may be due to a variety of organisms. The infectious agent may be brought by the circulation, or reach the tissue by direct extension from a lesion in adjoining tissues, such as the meninges or the middle ear or mastoid cells, or be introduced mechanically on a foreign body, such as a bullet, or it may extend along the lymphatics from the nares.

The infectious lesions of the brain and cord demand persistent study until they are entirely cleared up, because on a thorough knowledge of them depends the understanding of the secondary degeneration of nerve tracts which follows them.

The pus-cocci and especially the staphylococcus aureus produce focal inflammatory lesions which, as a rule, quickly undergo softening and abscess formation. The lesions may occur singly and reach a considerable size, or be multiple and cause death quickly. They are often complicated by hemorrhage which may completely mask the underlying process. Occasionally the infecting organism dies out and repair takes place, usually with the production of much fibrous tissue in the wall, probably owing to the stimulation of the fibroblasts by the new-formed fibrin.

Sometimes infectious processes in the meninges extend along the blood-vessels into the brain tissue, for instance, in meningitis due to the anthrax bacillus.

An organism, not yet named, which has been identified with *acute anterior poliomyelitis* causes that symptom-complex and, perhaps, others not yet definitely recognized. The organism is exceedingly minute and is found not only in the cord and brain, but also elsewhere in the body. It is possible to infect monkeys with it and to transfer the infection from one animal to another.

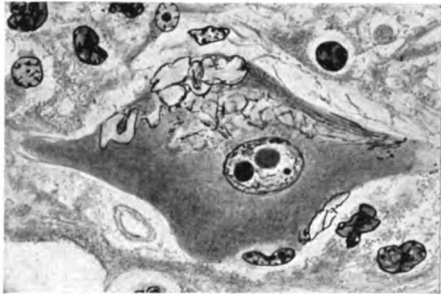


Fig. 475.—Anterior poliomyelitis. First stage in necrosis of ganglion cell.

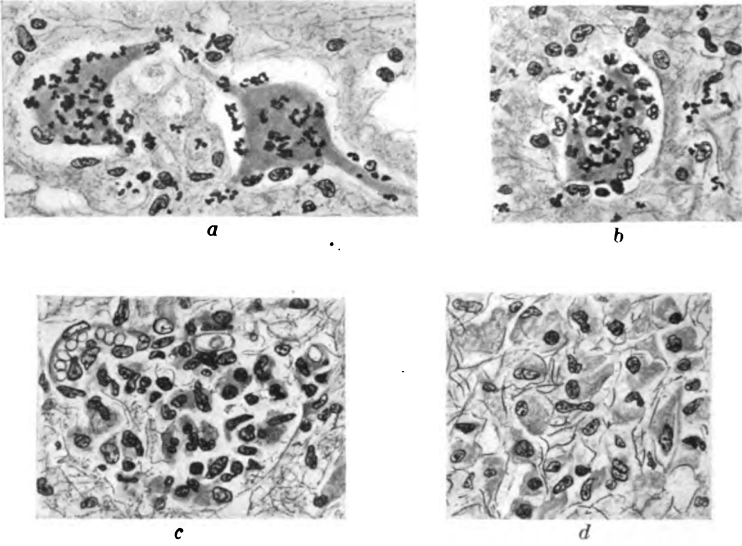


Fig. 476.—Anterior poliomyelitis. *a* and *b*, Necrotic ganglion cells being invaded by polymorphonuclear leukocytes; *c*, endothelial leukocytes in space formerly occupied by ganglion cell; *d*, last stage in repair; a few endothelial leukocytes still remaining in neuroglia mesh-work.

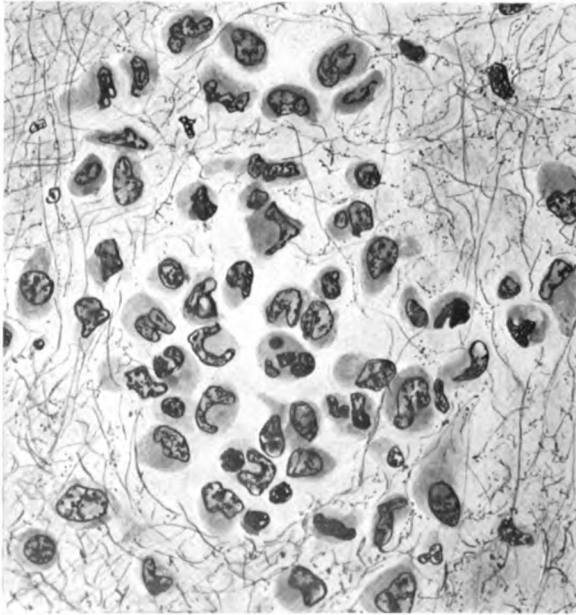


Fig. 477.—Anterior poliomyelitis. Endothelial leukocytes in space formerly occupied by a ganglion cell.

In acute anterior poliomyelitis the infecting agent, through the toxin which it eliminates, causes necrosis of the ganglion cells which are then invaded by polymorphonuclear or endothelial leukocytes or by both dissolved and removed. As a result of the toxin and of substances derived from the necrotic nerve-cells considerable infiltration with lymphocytes takes place. They often accumulate in fairly large numbers around the blood-vessels, along the paths of absorption.

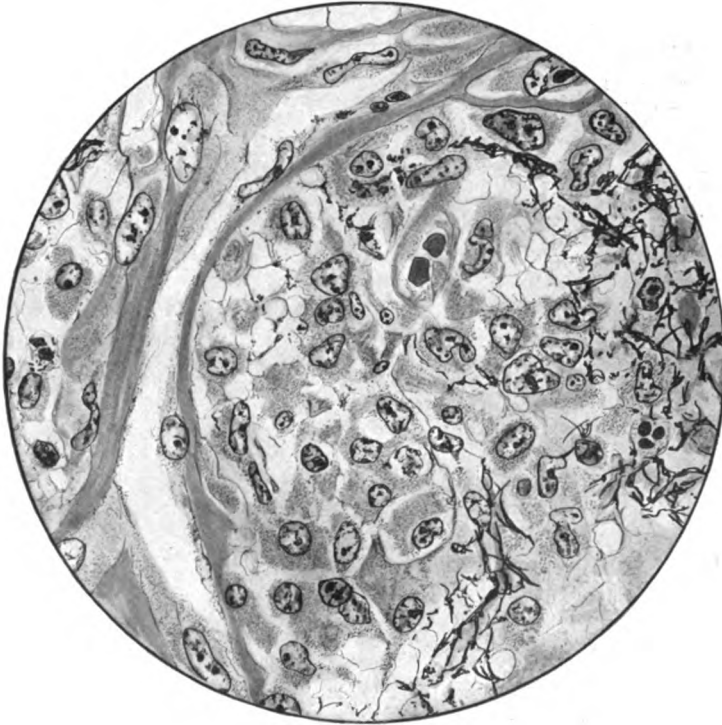


Fig. 478.—Syphilis, acquired. Brain. Infiltration with numerous endothelial leukocytes.

The extent and severity of the lesion evidently depend on the number of organisms present and the strength of the toxin secreted. Sometimes one side of the cord is injured more than the other. The lesion may affect only a small portion of the cord or extend its entire length, or even involve parts of the brain or possibly occur there only.

Tuberculosis of the brain and cord substance may occur as miliary tubercles, as conglomerate tubercles, and as the solitary

tubercle. They represent simply different stages in the development of the lesion caused by the tubercle bacillus.

Miliary tuberculosis is probably not so rare as is generally supposed, but the tubercles when very small are not visible to the naked eye because they do not stand out in contrast with the surrounding nerve tissue. The conglomerate tubercles on the other hand are more conspicuous and are occasionally found in considerable numbers (ten to over thirty in three different cases) located chiefly in the cortex.

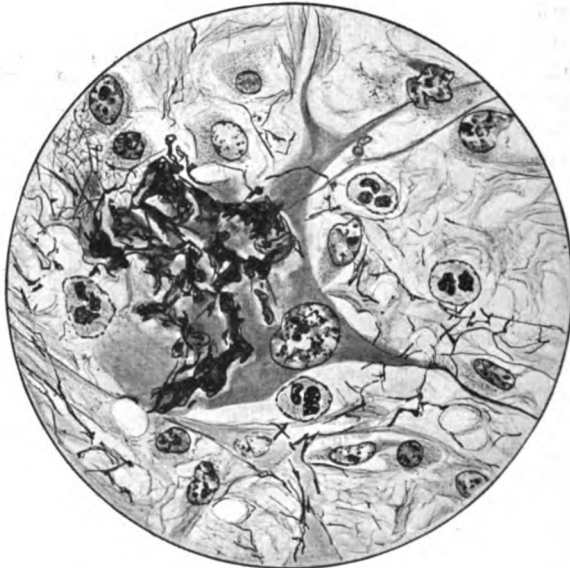


Fig. 479.—Syphilis, acquired. Brain. Neuroglia cell extending around masses of fibrin in neighborhood of gumma.

The solitary tubercles, which are only large conglomerate tubercles, may reach the size of a hen's egg and are sometimes multiple.

Tuberculosis often extends along the blood-vessels into the surface of the brain from lesions in the meninges.

Syphilitic infection of the brain and cord may take two distinct forms. The *treponema pallidum* may excite focally a fairly active inflammatory process which may be complicated by necrosis (gumma formation) owing to involvement and occlusion of the blood-vessels. In the other form the treponemas are spread more or less diffusely in the gray matter of the brain or cord or both, and slowly cause very slight injury and inflammatory reaction. The

process in this respect resembles the milder type of reaction in the liver and other organs in congenital syphilis. There occurs as a result of the infection a gradual increase of neuroglia tissue (sclerosis) and an atrophy and disappearance of ganglion cells, followed by loss of nerve-fibers in the brain and cord and a relative increase of neuroglia tissue in their place. This type of lesion causes at least the two syndromes known clinically as general paresis and locomotor ataxia, and perhaps some others.

In *trichiniasis* the *trichinella spiralis* sometimes emigrates from the blood-vessels in the brain and causes small focal inflammatory lesions there just as in the heart, liver, and pancreas. The parasites soon die and nothing is left of the lesion finally but an area of sclerosis.

Sclerosis.—Sclerosis of the central nervous system corresponds to the same condition in the liver (cirrhosis) and kidney (chronic nephritis), but it is evidenced by relative or actual increase of neuroglia tissue instead of connective tissue. It follows a great variety of lesions of circulatory, mechanical, toxic, and infectious origin. It is an end result. How it arose in an individual instance often cannot be determined. It follows destruction of ganglion cells (acute anterior poliomyelitis), or of nerve-fibers (injury of spinal cord, hemorrhage in white matter of brain).

Owing to the anatomic structure of the central nervous system scleroses are not distributed irregularly as in most other organs, but occur at the site of original injury and then follow secondarily certain definite nerve-fiber tracts. These secondary degenerations are very important clinically and have been carefully studied in the laboratory, chiefly by means of the myelin sheath and the neuroglia stains. One method shows absence of nerves, the other relative or absolute increase of neuroglia tissue where nerve-fibers or cells have disappeared. Both methods are useful.

Simple degeneration and disappearance of nerve-fibers does not cause actual increase of neuroglia cells and fibrils. They

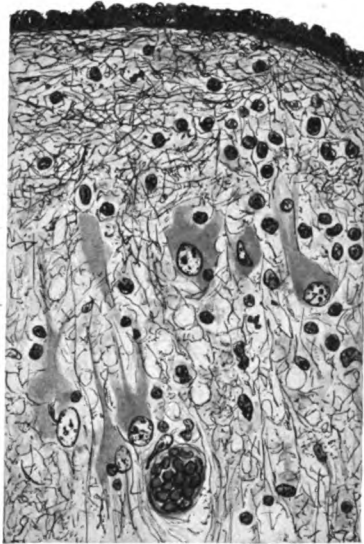


Fig. 480.—Syphilis, acquired. Brain. Gliosis in neighborhood of gumma.

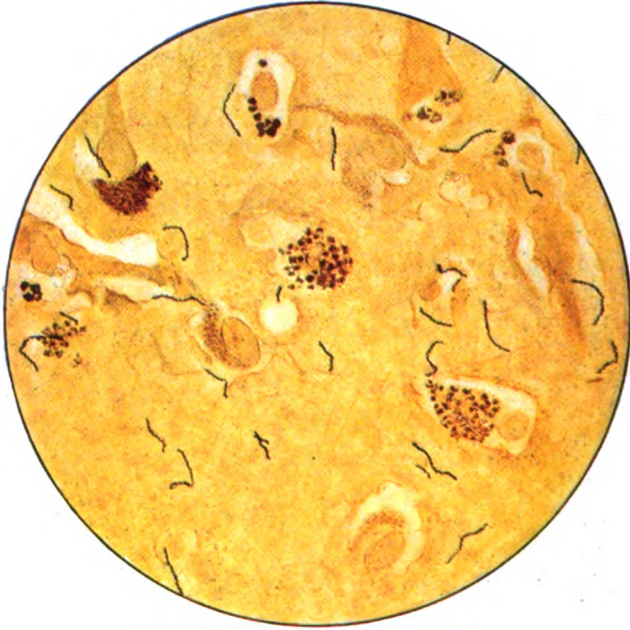

Fig. 481.—*Treponemata pallida* in the cortex of the cerebrum in general paresis. From a stained preparation received from H. Noguchi.

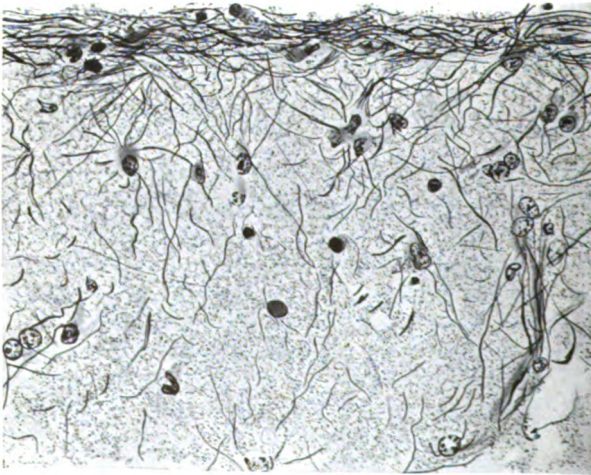


Fig. 482.—Cerebrum. Sclerosis. From a case of general paresis.

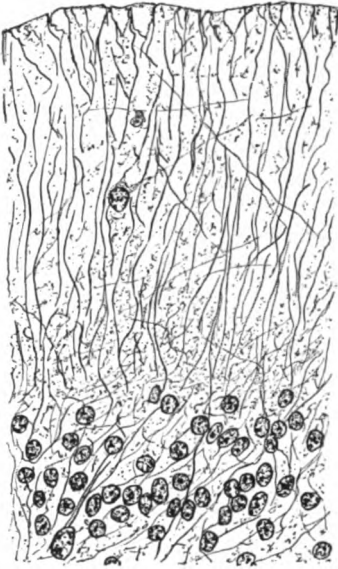


Fig. 483.—Cerebellum. Gliosis in a boy four years old.

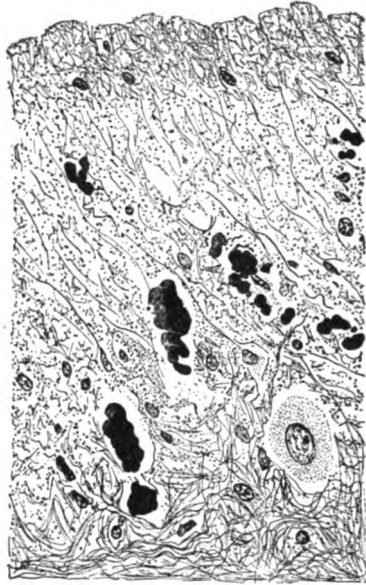


Fig. 484.—Cerebellum. Sclerosis. Increase of neuroglia tissue; hyaline formation.

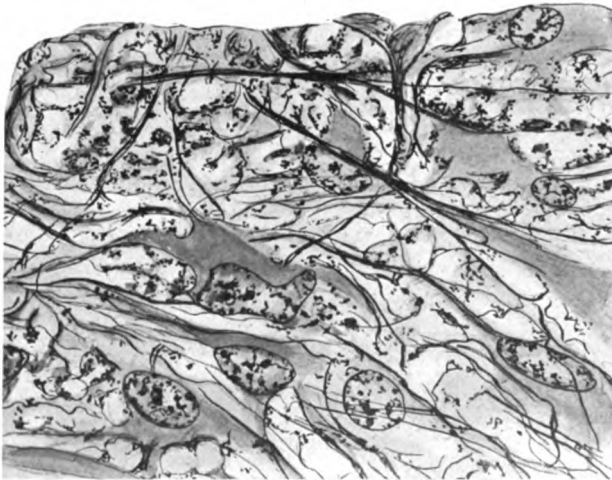


Fig. 485.—Spinal cord. Gliosis in a case of Gower's combined system disease.

are simply brought into closer apposition and therefore appear increased in number. On the other hand, when neuroglia cells have been injured by toxins, active regeneration occurs; mitotic figures are occasionally numerous and new fibrils are produced. Such an actual increase sometimes occurs, for instance, as the result of toxin diffusing into the brain substance in epidemic cerebrospinal meningitis.

Tumors.—The two important primary tumors of the central nervous system are the glioma and the dural endothelioma. The first arises within it, the other on its surface, but owing to the rigidity of the surrounding walls is pressed into the brain or cord depending on its location. These two types of new-growths will be found fully described in the section on tumors.

Other primary tumors are of rare occurrence. Metastases from new-growths arising elsewhere in the body are more common.

The cholesteatoma is not a new-growth, but a tumor-like mass of cornified epithelial cells produced by displaced epiblastic cells which in their normal location would have formed part of the epidermis.

PIA

The lesions involving the pia are more numerous and important than those affecting the dura and are limited chiefly to infectious processes.

Edema of the pia is of frequent occurrence, but is of little significance beyond its frequent indication of atrophy of brain tissue.

Infection of the meninges, known as meningitis, is of common occurrence and may be caused by a variety of organisms. The diplococcus intracellularis meningitidis, the cause of acute epidemic cerebrospinal meningitis, holds first place, but other common infectious agents are the diplococcus lanceolatus, the streptococcus pyogenes, the tubercle bacillus, etc.

The exudation consists of serum and polymorphonuclear leukocytes. Much fibrin may be formed and red blood-corpuscles, due to hemorrhage, sometimes complicate the lesion as in meningitis caused by the anthrax bacillus. Endothelial leukocytes are sometimes fairly numerous especially in the later stages of infection and often show marked phagocytosis.

The epidemic type of lesion is apparently the only one which sometimes undergoes recovery. All the others are probably fatal.

The fibrin in the lesion when not dissolved leads to organization, a process which sometimes causes obliteration of the foramen of Magendie with the consequent production of internal hydrocephalus.

Tuberculosis occurs as miliary tubercles, or as a serofibrinous or purulent exudation, especially at the base of the brain. Infection sometimes extends along the blood-vessels into the cortex of the brain.

Syphilis very rarely appears as a diffuse exudative process with the formation of miliary gummas. More commonly the infection is localized in and around the blood-vessels in some particular area. The process may heal naturally, or as the result of treatment, and leave only scars to mark the sites of the lesions.

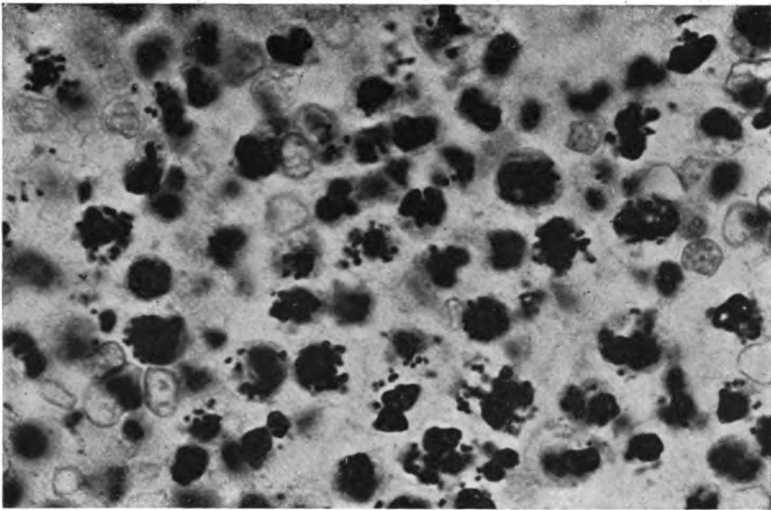


Fig. 486.—Spinal cord. Epidemic cerebrospinal meningitis. The diplococcus intracellularis meningitidis is present in large numbers in the cytoplasm of polymorphonuclear leukocytes. M.

DURA

There is practically just one pathologic process identified with the dura, the so-called chronic internal hemorrhagic pachymeningitis. The lesion is due apparently to a variety of causes, not to a single one. It consists of hemorrhage from the vessels along the inner surface of the dura, followed by organization of the fibrin formed. The condition is generally chronic, recurring repeatedly so that quite a thick membrane may be formed in time consisting of vascular connective tissue, usually containing numerous endothelial leukocytes filled with blood pigment. The hemorrhages may be minute and multiple or very extensive.

DURAL ENDOTHELIUM

The dural endothelium lines the cavity between the dura and the pia-arachnoid. Under a variety of pathologic conditions it proliferates and forms small whorls. Adjoining fibroblasts tend in time to grow in between the endothelial cells so that it looks as if the endothelium had formed collagen fibrils.

The chief importance of the dural endothelium lies in the fact that the fairly common tumor, known as dural endothelioma, arises from it.

ORGANS OF LOCOMOTION

BONES

Introduction.—The bones of the body are liable to a variety of lesions of mechanical and infectious origin. They are subject to numerous disturbances of development and metabolism. In addition several forms of tumors arise from them.

In order to understand bone repair, and especially the lesions due to disturbances of development and metabolism, an exact knowledge of how bone is formed and grows is necessary. Here only the briefest statement in regard to the origin and growth of bone is possible. For further details a good histology should be consulted.

Bone is different from all other tissues in having an abundant intercellular substance in which lime-salts are deposited. If the bone cells are killed this calcified intercellular substance immediately becomes a huge foreign body which demands removal. At the same time the adjoining periosteal and endosteal cells set about forming new bone to replace that destroyed, but this new bone has to be within or outside of the old bone, not in its place, because its removal requires a long time.

In studying bone lesions it is helpful to bear in mind that bone cells and cartilage cells are simply somewhat highly differentiated fibroblasts. The fibroblast produces collagen and fibroglia fibrils. It is capable of producing also mucin, chondromucin or osseomucin, that is, of becoming a mucous connective-tissue cell, a cartilage cell, or a bone cell. It may do so under pathologic conditions almost anywhere.

Elastic fibrils are often present, sometimes in large numbers in cartilage and bone and are easily stained and made prominent. Collagen fibrils are also present, but the homogeneous substance between them usually renders them invisible, although they may be demonstrated by special technical methods.

If a fibroblast has turned into a cartilage cell it is rarely or never converted into a bone cell. Instead, the cartilage cell degenerates and disappears and an adjoining fibroblast turns into a bone cell to take its place.

Anatomy.—In the fetus the skeleton is first laid down in cartilage, except in the calvarium and in some of the bones of the face where fibrous tissue takes its place. Bone begins to develop in

cartilage by an ingrowth of fibroblasts (periosteal buds) accompanied by blood-vessels from the outside into the cartilage where, as the endosteal cells, they proceed to form bone. The cartilage undergoes certain retrograde changes as bone begins to develop within it.

First the embryonic cartilage changes into hyaline cartilage; the cells enlarge, become vesicular and in the diaphysis of the long bones arrange themselves in columns. Calcification of the matrix follows. Capillary vessels invade the cartilage at different points and lead to the disappearance of the cartilage cells adjoining them. In this way primary marrow-spaces are formed. Then the end-

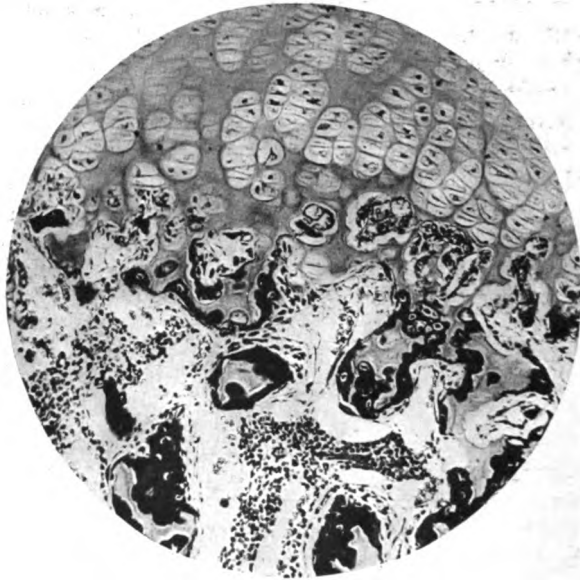


Fig. 487—Line of ossification where cartilage is replaced by bone. M.

osteal cells accompanying the blood-vessels form a layer of bone cells on the surface of the columns of calcified cartilage matrix left behind. The bone trabeculae formed in this way are later replaced by others consisting entirely of bone.

The ingrowth of periosteal buds and the formation of bone take place at certain points called centers of ossification. At the same time the fibroblasts on the outside of the cartilage take on the function of periosteal cells and deposit bone on the outside of the cartilage. Long bones have three centers of ossification; one in the center of the diaphysis and one in each end. The epiphyseal line at each end of the diaphysis where, up to adult

life, bone is being constantly formed to replace newly formed cartilage, is the important center in most lesions due to disturbances of development and of metabolism, because the lengthening of the bones depends on growth at this line.

Membranous bone is formed by the fibroblasts directly without the necessity of getting rid of any cartilage.

The osteal cell sometimes assumes an intermediate form between fibroblast and bone cell which has long been known as osteoblast. The osteoclasts which are constantly at work here and there dissolving bone are endothelial leukocytes, often fused together to form giant-cells. They are of exactly the same origin and nature as the foreign body giant-cells which occur in many locations under various pathologic conditions.

Atrophy.—Bone atrophies by disappearance of bone cells and of the intercellular substance over which they have charge. Three forms of atrophy are recognized.

In *lacunar absorption* the bone disappears through the action of osteoclasts which probably through chemical action hollow out spaces in the bone. This type of bone absorption is going on all the time under normal conditions even in the fetus, but is as steadily counterbalanced by the formation of new bone except in old age. Under pathologic conditions this type of absorption may be greatly increased.

Bone may also undergo atrophy through the formation of *perforating canals* due to ingrowths of blood-vessels.

A third type of atrophy is known as *halisteresis*. The lime-salts are first dissolved out of the periphery of the bone leaving the osteoid material as a zone around the undecalcified portion. The osteoid material contains contracted flat bone cells and persists for awhile, but later also disappears. In this form of atrophy the collagen fibrils in the osteoid material are often rendered prominent.

Although the form of bone atrophy known as halisteresis is generally described and recognized, its existence is somewhat doubtful. The same picture is often presented by bone in the stage of formation. It is possible that halisteresis is a wrong interpretation of the actual condition present.

Disturbances of Development and of Metabolism.—There is a series of bone changes due to disturbances of development and of metabolism. The more common ones will be considered here briefly.

Rickets is the name given to a pathologic condition affecting the growing skeleton and characterized by deficiency of ossification, and by increased proliferative activity on the part of the osteogenetic and chondrogenetic cells. It appears in young chil-

dren chiefly between the ages of six months and two years, rarely later.

The exact cause of the condition is unknown, but the lesions probably result from a deficiency of one or more substances which are lacking in the nutrition supplied and which are necessary for bone formation.

The histology of the bone lesions is quite complicated. It is best studied in the long bones where the relations of the normal structures are comparatively simple and definite.

The pathologic changes seem to be dependent on two different factors, and the second may be due to the first.

1. Diminished activity of the normal process of ossification as a result of which much osteoid tissue is formed. This is the most characteristic lesion of rickets and occurs in all the bones, but is most abundant at the ends of the diaphysis adjoining the growing layer of epiphyseal cartilage, where ossification of the columns of cartilage cells is delayed. It is claimed that osteoid tissue may also be formed in extreme cases of the disease by absorption of lime-salts already deposited (halisteresis).

2. Increased proliferative activity of the osteogenetic and also of the perichondral cells.

Increased activity of osteogenetic cells may occur within the bone or on the outside. Proliferation of the endosteal cells may result in the replacement of the marrow over considerable areas by fibrous and osteoid tissue. On the outside of bones the activity of the periosteal cells forms flat deposits of osteoid material, which are most common at the ends of the diaphyses, and also on the calvarium where they cause the prominent angular squaring of the skull so often noticeable.

Abnormal activity of the perichondral cells results in much increase of the growing cartilage, so that it often projects markedly beyond the adjoining bone and forms also a much thicker zone than usual. The rachitic rosary of the chest and the enlargement of the bones at the ends of the diaphyses are due to this excess of cartilage formation and to the delayed calcification. The hypertrophied cartilage zone contains many more blood-vessels than normally and they are quite irregularly disposed. The cartilage instead of being replaced by bone produced by endosteal cells is claimed to be transformed by the cartilage cells themselves into osteoid material. These changes at the epiphyseal line are most pronounced where growth is most rapid, namely, at the junction of rib and cartilage, at the lower end of the femur, the upper end of the humerus, etc.

The bone deformities found in connection with rickets are due to mechanical influences of body weight and muscle pull acting

on the soft bones. They result in bends, especially of the bones of the lower extremities, in buckles and sometimes in fractures. The chicken breast is due to the yielding of the ribs.

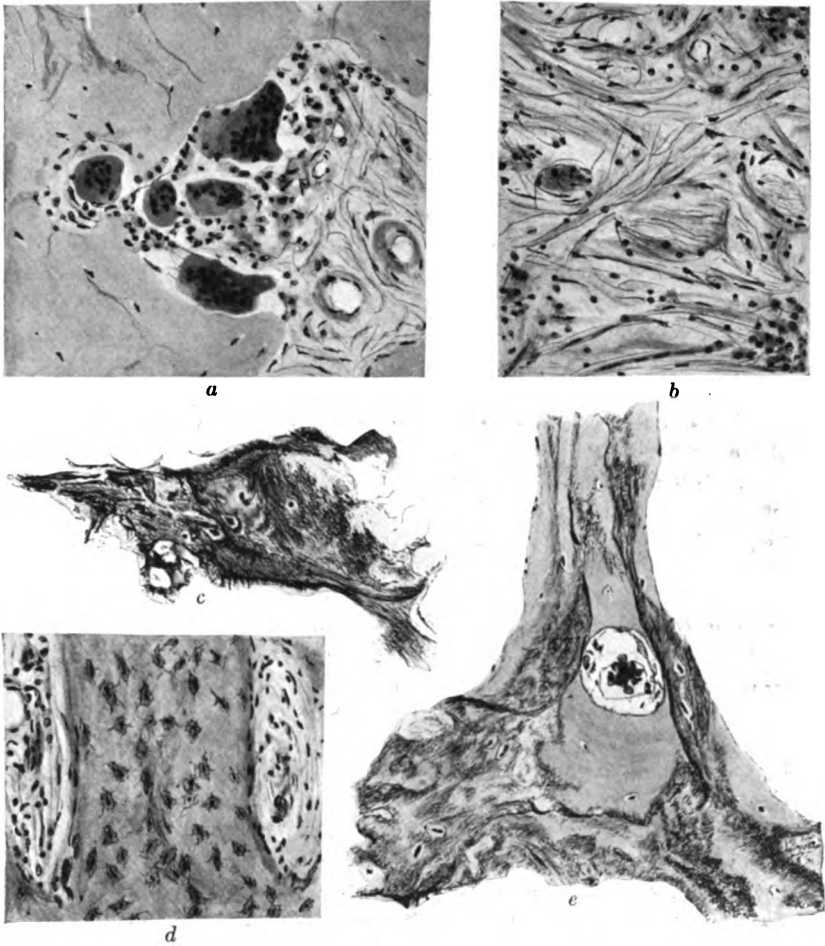


Fig. 488.—Ostitis deformans. *a*, Absorption of bone by osteoclasts; *b*, fibrous tissue filling bone marrow spaces; *c* and *e*, fibrillated bone tissue; *d*, newly-formed osteoid bone.

Rickets heals by the osteoid tissue taking up lime-salts, while the process of ossification of the cartilage gradually assumes its normal course.

The pathologic process known as *osteogenesis imperfecta* is of congenital origin, but its cause is unknown. That the centers of growth are unaffected is shown by the normal length of the bones. The condition is due to some disturbance in the process of ossification. The osteal fibroblasts do not differentiate properly and fully into bone cells. As a result but little bone is formed; it is thin and porous and breaks readily so that even in utero multiple fractures are produced in all parts of the skeleton. In the healing of these fractures, on the other hand, plenty of lime salts are deposited so that the fractures result in local thickenings of the bones. The calvarium may remain entirely membranous.

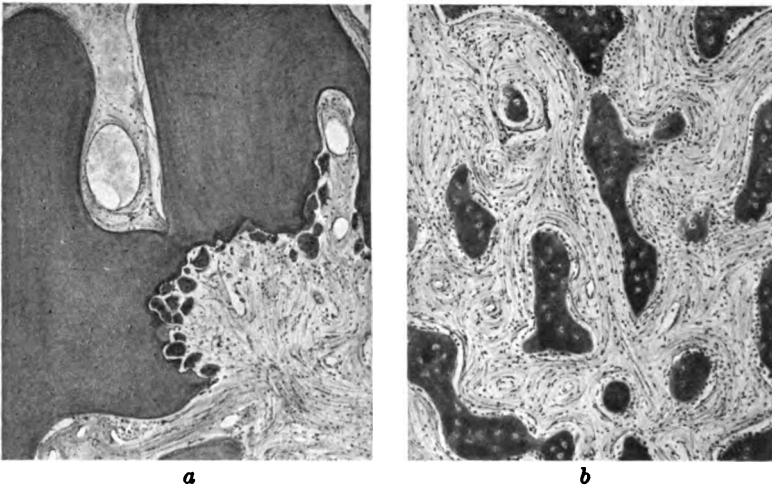


Fig. 489.—Bone. Osteomalacia following pregnancy. *a*, Removal of old cortical bone by osteoclasts; *b*, new-formed cortex composed of young trabeculae, with numerous fibroblasts between them.

Fracture of the bones although of secondary origin constitutes the most characteristic sign of the condition. The fractures often number dozens; in one instance over a hundred were counted.

Ostitis deformans (Paget) is the name applied to a process usually affecting the entire skeleton, occurring in adult life (after the age of forty) and characterized by extensive absorption of bone, and especially by excessive production of bone substance, which is mostly free of lime-salts. The lack of lime-salts leads to curves and bends and the excessive formation of bone substance to thickening. The skull is often greatly thickened, two to three centimeters and over, and usually presents a uniform appearance with no differentiation into cortex and diploë.

The endosteal cells often proliferate and fill up many of the marrow-spaces so that solid masses of fibrous tissue result. Frequently the osteoid material shows marked fibrillation.

Osteomalacia is the term applied to a general softening of the bones all over the body. The process is due to removal of lime-salts and to the production of more or less osteoid material. It may occur under a variety of conditions such as rickets in the young and as a result of retrograde changes in the aged, but the term *osteomalacia* is applied specifically to a form of excessive softening of the bones which occasionally follows pregnancy. A slight degree of the same process occurs normally in this condition.

Histologically the bones show active removal of the old trabeculæ by means of numerous osteoclasts and much production of fibroblasts: some of these differentiate into bone cells so that numerous young trabeculæ are formed, but only a small amount of lime-salts is deposited in them. Between the new trabeculæ are masses of undifferentiated fibroblasts.

As a result of these changes deformities of the bones occur, chiefly bends and especially fractures. The changes affect most markedly the pelvis and the bones adjoining it, namely the lumbar vertebræ and the femora.

Lesions of Mechanical Origin.—Bones are very commonly the seat of lesions of mechanical origin, such as fractures of various sorts, bullet wounds, etc. If the injuries are not infected repair depends on the amount of bone tissue needed to reunite the parts or to fill in the loss of substance, and on the amount of necrotic bone and other tissues which have to be removed. New formation of bone usually plays the more prominent part:

The injured tissue leads to an acute inflammatory exudation which in time brings about the removal of all necrotic material. At the same time the periosteal and endosteal cells proliferate rapidly and fill in the space between the separated bone surfaces, and also extend for some distance outside of the affected area. The new-formed tissue is at first vascularized connective tissue, but trabeculæ of young bone are soon formed by some of the fibroblasts differentiating into bone cells. This young bone tissue is commonly called a callus. It is always formed in considerable excess of ultimate needs, but later is built over again and reduced in size after sufficient calcification has taken place to render the bone rigid. Some of the fibroblasts in a young callus may differentiate into cartilage cells if excessive mobility of the fracture is present.

In infected fractures, etc., the necrosis and the inflammatory exudation are usually very prominent and may greatly interfere with the process of repair or entirely prevent it.

Lesions of toxic origin, except in connection with infection, do not seem to occur in bone outside of that produced by phosphorus. In match factories the vapor of this element sometimes affects the periosteum of the jaws, especially the lower one, when exposed by the presence of carious teeth. Under this condition the vapor causes injury followed by sclerosis of the bone and sometimes by the formation of dense osteophytes. The extensive necrosis of the jaw which sometimes occurs is not due to the action of the phosphorus itself but to a secondary infection by bacteria.

Lesions of infectious origin are frequent in bone. They may start as a periostitis owing to infection from without, or as an osteomyelitis due to infection of hematogenous origin within the bone. Either type of lesion may be produced secondary to the other by extension of the process through the cortex of the bone.

The most common infecting agent is the *staphylococcus aureus*, but other organisms such as the streptococcus pyogenes, the pneumococcus, and following typhoid fever the typhoid bacillus, sometimes cause lesions. In addition, the lesions due to the tubercle bacillus and the treponema pallidum belong in this group although requiring separate consideration.

Infectious lesions of bone may extend widely beneath the periosteum, or through the marrow spaces and cause more or less extensive necrosis (sequestrum) of the bone. Destruction of the marrow in a bone is of little consequence, but necrosis of the shaft of a long bone is of grave importance, because of the great difficulty of getting rid of the dead bone by natural means. It forms a massive foreign body and remains for months and years after the infection has ceased, and of itself becomes an injurious agent. Nature attempts to dissolve and remove it and at the same time to form a new shaft around it. The proper treatment is surgical removal so that the periosteum left behind may form a new shaft.

Tuberculosis of bones nearly always begins as tuberculosis of the marrow with secondary involvement of the bone substance, rarely by direct extension from some tuberculous focus on the outside. The first lesion is a miliary tubercle which gradually enlarges so that one or more caseous masses are formed. The bone tissue involved is killed and may be dissolved and disappear, or it may persist in the caseous material as a sequestrum. Sometimes softening of the caseous material takes place so that an abscess results.

Tuberculosis of bones usually starts in spongy bone, in the marrow of the epiphyses of long bones, in the diaphyses of short

bones, in the bodies of the vertebræ, etc. It may extend to the periosteum and into the surrounding tissues.

Syphilis.—Bone lesions are of frequent occurrence in acquired syphilis, occasionally during the secondary stage, but most often during the tertiary. They may start in the bone marrow or in the periosteum and are characterized in general by more or less new formation of bone.

The lesion begins as a focal or diffuse inflammatory process with more or less exudation and much increase of connective tissue owing to the prominence of the process of repair. As the connective tissue arises from osteal cells it is natural that some of them should differentiate into bone cells. The result is the formation of much new bone which may show as a sclerosis within the bone or as thickening (periostitis, osteophytes) on its outer surface.

If blood-vessels become occluded as the result of the inflammatory process necrosis occurs. It may be slight or extensive and involve any tissue within the focus of inflammation, or extend outside of it according to the distribution of the vessels affected. These lesions are readily recognized as gummas. The simple inflammatory lesions are not so easily identified unless the presence of spirochætes is demonstrated, or the clinical history renders their nature fairly obvious.

When necrosis occurs the bone involved undergoes softening and absorption. The erosions of bone caused by lesions of the periosteum are particularly noticeable and more or less characteristic, owing to the new bone regularly formed at their edges, where necrosis has not occurred, by the reparative tissues as already described.

The bone lesions due to syphilis do not seem to have any foci of predilection. They may occur anywhere in any bone and in the epiphysis or diaphysis. They are usually described as favoring bones covered by skin. They certainly are more easily recognized here clinically but *x*-ray examination often discloses them in various other unsuspected locations.

Macroscopically the syphilitic lesions appear greyish and gelatinous and may show more or less extensive areas of caseation.

In congenital syphilis the most characteristic and constant lesion occurs along the line of ossification in the bones. The process of ossification of the cartilage is delayed. As a result the columns of calcified cartilage matrix extend much farther than normally and become prominent. Bone marrow forms in between them. Macroscopically instead of the normal sharp narrow line of ossification there exists a broad yellowish white zone which fades out on the side towards the diaphysis.

Frequently there occurs also an increase of blood-vessels and

connective tissue (granulation tissue) extending into the cartilage along the upper border of the line of ossification and giving it a jagged appearance.

In consequence of the lesion at the line of ossification, with the resulting lack of firm union, the epiphysis is sometimes separated from the diaphysis in utero or at the time of birth.

The bone lesion peculiar to congenital syphilis is pretty generally distributed throughout the body, but as in rickets is most marked where most rapid growth is taking place, namely, at the lower end of the femur, etc.

A less constant bone lesion found in congenital syphilis is periostitis ossificans, as a result of which osteophytic deposits may be formed at the ends of the diaphysis and in time extend along the shafts of the bones.

Tumors.—Bone is built up from fibroblasts (osteal cells) which are capable of differentiating into bone or cartilage cells. Tumors sometimes arise from these fibroblasts and their cells may differentiate in the same way. Other types of tumors may originate within bone from the cells of the bone marrow: they are discussed under that heading.

The tumors arising from osteal cells may grow rapidly or slowly and may differentiate into bone cells or cartilage cells, or remain as fibroblasts. Frequently all three types of cells and also mucous connective-tissue cells are formed so that one type of mixed tumor results. The tumors may arise within the bones from endosteal cells or on the outside from the periosteal cells. They may grow slowly and remain small, or proliferate rapidly and reach a large size. The osteoid substance may remain as such or become calcified.

OTHER ORGANS

ADRENAL GLANDS

Introduction.—More or less complete destruction of the adrenal glands is of great importance pathologically because of the physiologic disturbances which follow. They are included under the clinical term, Addison's disease. Destruction of the adrenal glands is due more often to tuberculosis than to any other cause; on this account tuberculosis occupies the most prominent position among the lesions affecting them. Perhaps next in importance are the primary tumors. Other lesions are of much minor significance.

Anatomy.—The cortex and the medulla of the adrenal glands originate separately, the cortical cells from the mesoblast, the medullary cells from the sympathetic nervous system. The cortex is composed of epithelial cells which form three layers known as *zona glomerulosa*, *zona fasciculata* and *zona reticularis* respectively. Fat (lipoids) is present in these cells normally, most abundantly in the *zona fasciculata*. The cells of the *zona reticularis* contain brownish pigment granules which increase in number with age.

The medulla is composed of polymorphous cells with delicate cytoplasm containing granules which can be fixed by chrome salts. On this account the cells have been named chromaffine cells.

The medulla also contains typical ganglion cells of the sympathetic nervous system.

The stroma of the adrenal glands contains numerous blood-vessels of capillary type and but little connective tissue, especially in the cortex.

Macroscopically the organs show three layers; a yellow cortical layer composed of the two outer zones; a brown layer due to the pigment in the *zona reticularis*, and a greyish white center which is the medulla.

Physiology.—The function of the cortical cells of the adrenal glands is not known, but they seem unquestionably to be necessary for the maintenance of life. It is thought that they may neutralize certain toxins produced normally in the body.

The chromaffine cells of the medulla produce the chemical substance known as adrenalin which possesses certain characteristic physiologic properties.

Disturbances of Circulation.—Hemorrhages are fairly frequent in the adrenal glands and occasionally may reach the size of a hen's egg. They take place as a rule in the medulla, or extend to it, and split the gland apart so that the cortex remains on the outside. The large hemorrhages usually follow trauma or thrombosis, while the small ones are generally the result of infection. Infarction is of rare occurrence.

In one instance small foci of endothelial leukocytes filled with blood pigment and surrounded by lymphocytes were found in the cortex, evidently as the result of previous hemorrhages.

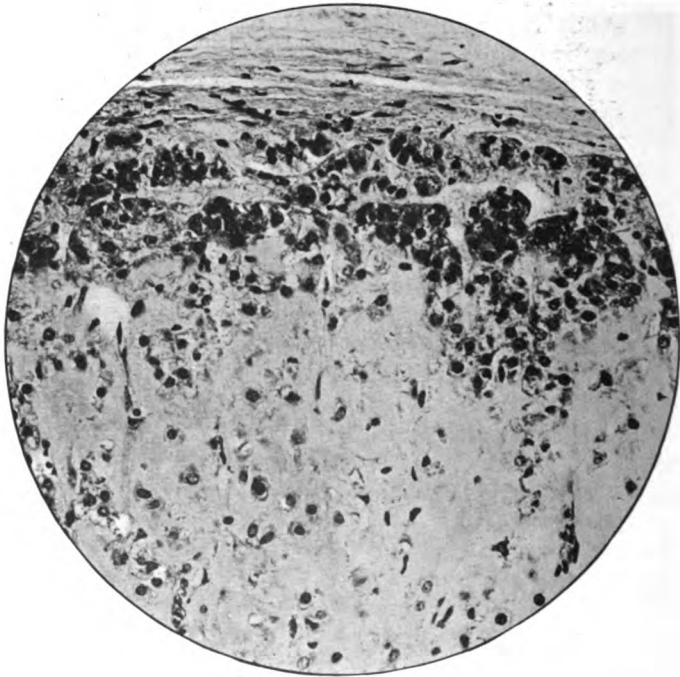


Fig. 490.—Amyloid infiltration of the cortex of the adrenal gland. M.

Retrograde Changes.—Amyloid formation is the most important retrograde change and occurs, as a rule and often abundantly, when amyloid is deposited elsewhere in the body. It appears in the cortex and spreads toward the capsule causing atrophy and disappearance of the epithelial cells.

Calcification is rare; it may take place in old hemorrhages; in one instance it occurred extensively in the medulla in and between necrotic cells.

Lesions of Toxic Origin.—The adrenal glands are composed

chiefly of parenchyma, that is, of the epithelial cells of the cortex and the chromaffine cells of the medulla. In spite of this fact

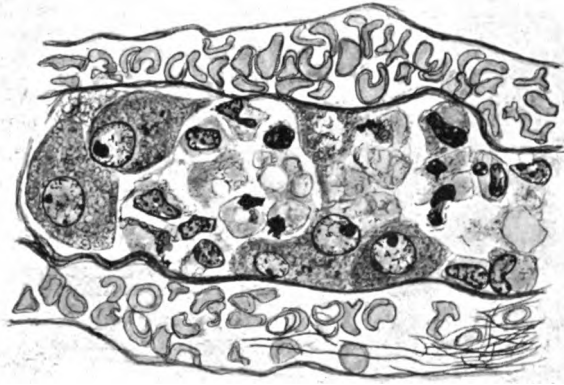


Fig. 491.—Adrenal. Accumulation of endothelial leukocytes following necrosis of cortical cells.

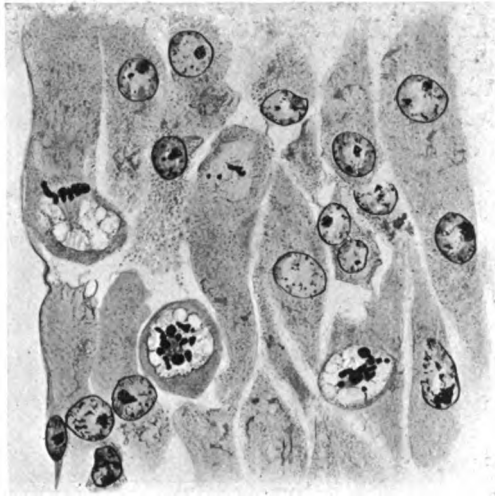


Fig. 492.—Adrenal gland Active regeneration following toxic necrosis. Three mitotic figures present; also a part of a fourth.

lesions of toxic origin are infrequent. Possibly they are not always recognized when present.

Necrosis of the cortical cells sometimes occurs, especially in

diphtheria, and is usually most marked in the zona fasciculata. The lesion resembles very closely that seen in central necrosis of the liver. The necrotic cells are invaded chiefly by endothelial leukocytes and gradually dissolved. In one instance necrosis was followed by such marked regeneration that one to three mitotic figures could often be found in one oil immersion field.

Occasionally following necrosis of the cells small cysts are left containing serum, fibrin and a few endothelial leukocytes.

Extensive necrosis and calcification of the medulla occurred in one case of measles in a child.

A more common lesion of toxic origin that is found in the adrenal gland is focal accumulations of lymphocytes, most often in and adjoining the medulla.

Lesions of Infectious Origin.—Infectious lesions due to the common bacteria occur rarely in the adrenal glands, either by extension from similar processes in the neighborhood or embolically through the circulation. Abscesses may be formed and healing may result in scar formation. In one instance acute infectious lesions were found in the walls of some of the smaller arteries.

The most common and important infectious lesion is that due to the *tubercle bacillus*. Miliary tubercles are not rare when present in other organs. In chronic tuberculosis the process may spread rapidly and form large caseous masses, or very slowly so that scar tissue becomes the most prominent feature and the tuberculous lesion back of it may be difficult to demonstrate.

In *congenital syphilis* spirochætes are often very numerous in the adrenal glands although there may be little or no inflammatory reaction around them. Gummas are rare. In acquired syphilis the adrenal glands are seldom affected.

Tumors.—Primary tumors of the adrenal glands are more common and important than those of metastatic origin. They are of two types, corresponding to the two different sources of origin of the parenchymatous cells of the cortex and medulla. From the cortical cells arise adenomas and carcinomas, from the medulla, neuroblastomas. They will be found discussed at some length in the chapter on tumors.

Pathologic Physiology.—More or less complete destruction of the adrenal glands produces the symptom-complex called *Addison's disease*, namely, anemia, marked loss of strength, nervous and intestinal disturbances and bronzing of the skin. Death is likely to be sudden. Some of the symptoms seem to be connected with the action of adrenalin, but others may be dependent on the function of the cortical cells. The cause of the bronzing is not understood; possibly the pigment is derived from a substance which should be converted into adrenalin.

THYROID GLAND

Introduction.—The pathology of the thyroid gland is more interesting and striking from the chemical, physiologic and clinical points of view than it is anatomically. The organ gives rise to a very important secretion. Diminution or excess of this secretion causes serious symptoms of two different types which are recognized clinically as separate diseases. On account of this fourfold point of view, anatomic, chemical, physiologic and clinical from which investigations have been carried on, the pathology of the thyroid gland is complicated by a variegated nomenclature.

The pathology of the thyroid gland will be presented here from the anatomic point of view, but brief reference will of necessity have to be made to the other aspects of the subject, concerning which much still remains to be cleared up.

Anatomy.—The thyroid gland is ductless. It is composed of follicles lined with epithelial cells which are usually cubical, but occasionally cylindrical and sometimes, especially in old age, flattened. The follicles are generally round and separate from each other, but occasionally may be elongated and branching, or communicating with each other. The epithelial cells secrete a hyaline material known as colloid which distends the follicles to some extent, and is characterized by the presence of iodine in intimate combination with an albuminate.

The stroma of the thyroid gland contains numerous blood-vessels and a moderate amount of connective tissue.

Disturbances of circulation play little part in the pathology of the thyroid gland. Congestion is sometimes a prominent feature. Occasionally more or less extensive hemorrhages take place into the follicles. The red blood-corpuscles attract endothelial leukocytes which incorporate them and gradually transform the hemoglobin into hemosiderin. The leukocytes filled with pigment may remain within the follicles or migrate into the stroma and collect around the blood-vessels.

Arteriosclerosis of the blood-vessels is sometimes marked and by diminishing the blood supply may lead to atrophy and disappearance of many of the follicles.

Retrograde Changes.—Various retrograde changes take place not only in the thyroid gland, but also in the primary epithelial tumors arising from it.

Fat is normally present to some extent in the follicular epithelium so that an increase cannot readily be determined unless excessive. On the other hand, endothelial leukocytes filled with fat sometimes accumulate within the follicles and less frequently in the stroma. Cholesterol crystals may be formed from fat set

free by necrosis of cells and leukocytes in which it has accumulated and cause the formation of foreign body giant-cells from the endothelial leukocytes attracted to the place.

The epithelial cells lining the follicles may be compressed and flattened when an excess of colloid is present. Occasionally the cells are small, apparently from atrophy, so that they seem to be mostly nucleus.

The cytoplasm of the cells is ordinarily homogenous, but sometimes it becomes filled with fine, acid-staining granules or even hyaline droplets which cause the cells to enlarge to two or three

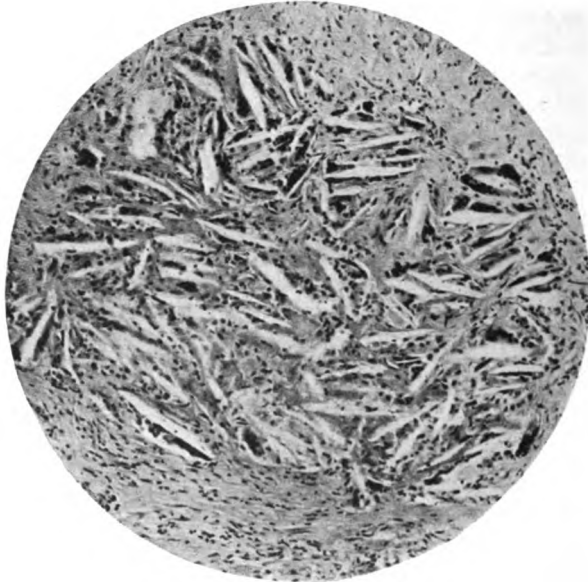

Fig. 493.—Thyroid gland. Chronic inflammation. Foreign body giant-cells around cholesterol crystals. M.

times their normal dimensions. This change in the cells may occur diffusely or in small or large foci.

The *colloid material* varies considerably in its physical properties. Usually it is rather thick and homogeneous, but at other times it is thin and watery. Occasionally it contains denser globules and masses. Rarely some of the material suggests a crystalline structure. Frequently it collects in considerable quantities in the follicles, so as to distend them into cysts of various sizes.

The chemical composition of the colloid material sometimes seems to undergo a change because it occasionally attracts

leukocytes and lymphocytes in considerable numbers and may lead to giant-cell formation.

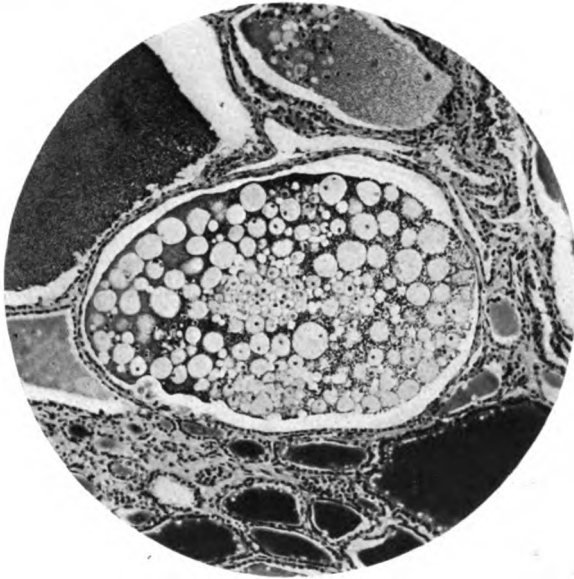


Fig. 494.—Thyroid. Numerous endothelial leukocytes present in colloid in distended follicle. M.

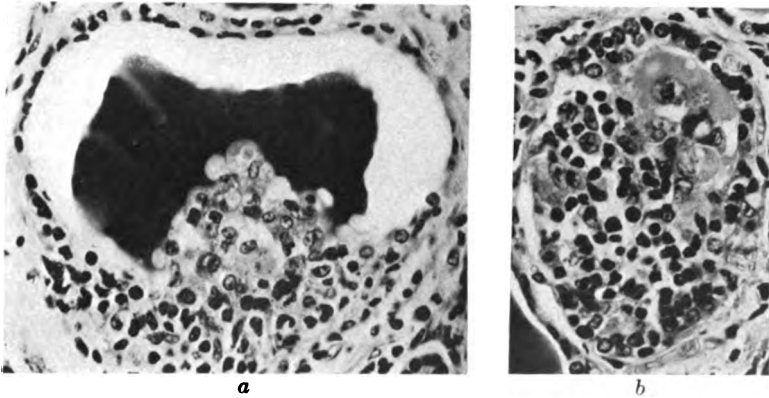


Fig. 495.—Thyroid gland. Removal of colloid by endothelial leukocytes. *a*, Early stage of process; *b*, late stage. M.

The stroma of the thyroid gland may undergo swelling and hyaline transformation, but the condition is rare.

Calcification may take place in the stroma and in the walls of sclerosed arteries.

Lesions of Toxic Origin.—Toxins in the circulation seem to produce little effect on the epithelium of the thyroid gland. On the other hand the colloid material, probably owing to some chemical change, sometimes attracts endothelial leukocytes into the lumina of the follicles in considerable numbers. They incorporate and digest the colloid. The lining epithelium is often secondarily destroyed. Giant-cells may be formed by fusion of the endothelial leukocytes. Lymphocytes are also occasionally

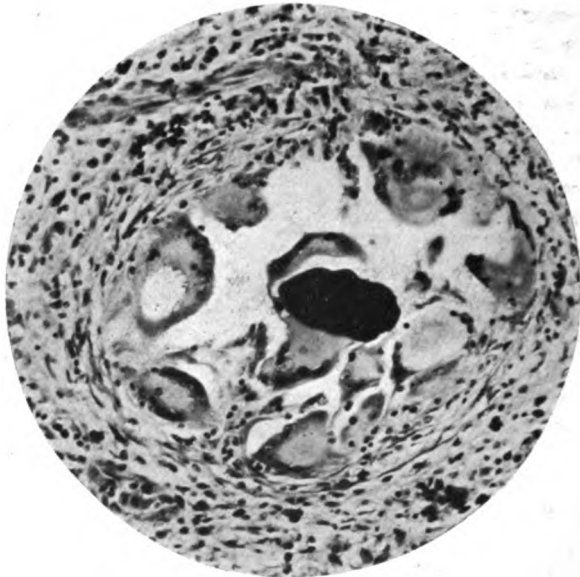


Fig. 496.—Thyroid gland. Giant-cells formed around colloid. Disappearance of epithelium. Increase of connective tissue. M.

and polymorphonuclear leukocytes rarely attracted in like manner into the follicles. As a result of the destruction of the epithelium more or less extensive areas of sclerosis may be formed, in which many lymphocytes and sometimes fairly numerous eosinophiles are present.

Very rarely the epithelium without any evident cause for it undergoes a slow form of necrosis, tends to stain deeply with eosin and finally disappears leaving only dense fibrous tissue in its place.

Lesions of Infectious Origin.—Bacterial invasion of the thyroid gland occurs occasionally, more often by direct extension

from the neighboring parts than by way of the circulation. The resulting lesion may be a diffuse suppurative process or abscess formation. In two instances abscesses were caused by the micrococcus lanceolatus and the bacillus mucosus capsulatus respectively.

Miliary tuberculosis is not infrequent when present in other organs, but chronic tuberculosis is rare, as is also syphilis.

Sclerosis.—Sclerosis of the thyroid gland may be brought about by toxic or infectious processes. To determine at a late stage of sclerosis the manner of its origin may be difficult or impossible. We can decide or guess only when the active process is still in progress or when the study of early lesions in other instances makes the end result understandable.

Any marked destruction of follicles with its accompanying sclerosis results in diminishing the amount of colloid produced and in that way brings about the physiologic effects due to diminished secretion.

Follicular Distension (Struma Colloides).—The follicles of the thyroid gland under certain conditions become distended with colloid secretion. They may even be dilated into cysts. The lining epithelium may at the same time be flattened as the result of pressure. This accumulation of colloid is usually diffuse. The result is more or less marked enlargement of the thyroid gland. Colloid may collect also in the follicles of the epithelial tumors arising from the thyroid gland.

Increased accumulation of the colloid secretion within the follicles does not signify increased supply to the circulation; in fact the reverse is likely to be the result.

Follicular Hyperplasia (Struma Parenchymatosa).—Under other conditions the epithelium undergoes a varying degree of hyperplasia. Sometimes it is marked. New glands are formed from the old ones and papillary projections appear within them. In this way also marked enlargement of the thyroid gland may be produced. Colloid may be present in more or less abundance or be entirely absent, but its absence does not mean diminished supply to the circulation. On the contrary it is often associated with an increase which causes certain physiologic disturbances.

Adenoma (Struma Nodosa).—Adenomas of the thyroid gland may occur singly or in multiple form. Occasionally they are quite numerous. They may be small or on occasion attain the size of a man's head. They are definitely encapsulated and the adjoining tissue often shows evidence of pressure. The thyroid gland tissue itself may be normal, distended with colloid or hyperplastic.

Thyroid adenomas are rare in children, but develop in number

and size with increasing age. The adenomas themselves may resemble normal thyroid tissue, or be composed of follicles distended with colloid, or of the so-called hyperplastic type, containing little or no secretion. Various combinations of these types also occur.

Retrograde changes are common in the adenomas, especially sclerosis and calcification which begin in the center where nutrition is poorest and spread peripherally.

Carcinoma.—The most important tumor of the thyroid gland is the carcinoma. It may resemble normal thyroid tissue so per-

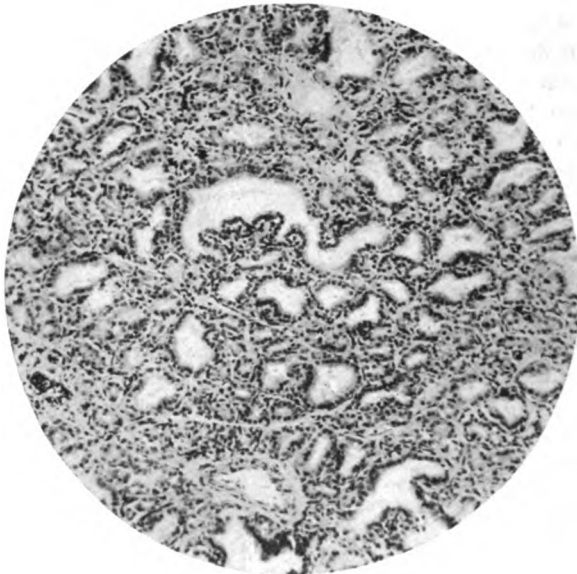


Fig. 497.—Thyroid gland. Glandular hyperplasia from a case of exophthalmic goiter. M.

fectly as to be distinguished from it with difficulty, and yet give rise to multiple metastases of similarly normal appearance in various organs. Or it may grow in solid masses or in papillary form within cysts with little or no colloid secretion, so that its tumor character is readily recognized. Considerable variation in the type of growth is not infrequent; the cells may be in gland-form in some parts of the tumor and in solid masses in other parts; or the cells may in places be compressed so as to appear spindle-shaped and suggestive of some form of mesenchymal growth. Carcinoma frequently complicates the two types of goiter already described.

Tumors of mesenchymal origin are rare.

Hypertrophy, Goiter.—It is evident from the preceding discussion that enlargement of the thyroid gland may arise from at least four different types of lesions: colloid distension of follicles, hyperplasia of follicles, adenoma, carcinoma. To say definitely before a microscopic examination has been made which lesion is present is not always possible. On this account the vague term hypertrophy is useful provided one clearly recognizes that it discloses lack of exact knowledge. The tendency in the clinical use of the term is to restrict it to enlargement due to two causes, namely, to colloid distension and to hyperplasia of the follicles.

Diagnosis.—In making a diagnosis of a lesion present in a thyroid gland it is important to have an accurate knowledge of the clinical history of the patient and a description of the gross appearance of the organ, because a small mass of tissue removed at operation will usually not of itself tell the whole story. It may look like normal thyroid tissue and yet prove to be an adenoma or a cancer. The ideal would be to have the whole thyroid gland for examination. This is possible only with autopsy material. With surgical material we have to do the best we can with the tissue received and the history and clinical description available.

Physiologic Pathology.—Diminution in the amount of colloid secretion furnished to the circulation, such as follows from destruction of the follicular epithelium with the resulting sclerosis of the organ (spontaneous athyreosis), causes the symptom-complex known as myxedema. It is produced operatively if the entire thyroid gland is removed for goiter as has frequently occurred in the past (cachexia strumipriva). It occurs in animals if the thyroid gland is removed experimentally (cachexia thyreopriva). If the animals are young marked general disturbances of the growth of the hair, persistence of the thymus, and hypertrophy of the hypophysis result; in adult animals the chief symptoms are loss of appetite and emaciation terminating in death.

Cretinismus, which is endemic in certain parts of the world, but also occurs elsewhere sporadically, is regularly combined with disease of the thyroid gland, usually colloid goiter but sometimes atrophy. The symptoms present are probably the result of diminished colloid secretion in the circulation in early life, causing disturbances of metabolism and hence of development.

Increase in the amount of colloid secretion in the circulation causes a different set of symptoms which can be produced experimentally in animals by the administration of thyroid extract, and have been produced in the same way accidentally in man. The symptoms are lowering of the blood pressure often combined

with increased rapidity of the heart's action, and disturbances of proteid, fat and lime metabolism.

A symptom-complex known as *exophthalmic goiter* (*Basedow's disease*) and characterized by three prominent symptoms, namely, goiter, exophthalmos and tachycardia, seems to be due unquestionably to increase of colloid material in the circulation. The enlarged thyroid is usually of the type called parenchymatous goiter.

INDEX

- ABNORMALITIES of kidney, 584**
Abscess in tuberculosis, 197
 in typhoid fever, 178
 of appendix, 487
 of bone-marrow, 609
 of kidney, 573, 575
 of liver, 508
 of lung, 476
 of spleen, 616
Acquired syphilis, 214
Actinomyces, 209
Actinomycosis, 209
 of liver, 512
Acute anterior poliomyelitis, 631
 miliary tuberculosis, 199
 yellow atrophy of liver, 501
Adamantinoma, 385
Adamantoblastoma, 384
Adamantoblasts, 384
Addison's disease, 654
Adenocarcinoma, 364
Adenocystoma of coil gland, 375
 of ovary, 394, 602
 of sebaceous gland, 374
Adenoma, 358, 359
 cells of, 362
 malignant, 360, 364
 of adrenal gland, 397
 of breast, 377
 of coil gland, 374
 of hypophysis, 400
 of intestine, 388
 of kidney, 392
 of liver, 389
 of mammary gland, 603
 of ovary, 394
 of pancreas, 391
 of prostate, 393
 of stomach, 387
 of thyroid gland, 398, 659
 of uterus, 393
Adenomyoma, uterine, 600
Adipositas, 89
 cordis, 411
Adrenal carcinoma, 585
 gland, adenoma of, 397
 anatomy, 651
 carcinoma of, 397
 hemorrhages in, 652
 infections of, 654
 lesions of, 651
Adrenal gland, physiology, 651
 syphilis of, 654
 toxic lesions, 652
 tuberculosis of, 654
Adrenalin, 651
Agar-agar, experimental injection of, 30
Albuminous degeneration, 88
 granules, 86
 in kidney, 532
 in liver, 490
 in myocardium, 422
Alcoholic cirrhosis of liver, 504, 514
 experimental production of, 507
Alveolar emphysema, 466
Amebiasis of liver, 515
Amebic dysentery, 238
Amputation neuroma, 67
Amyloid, 102
 effect of, 107
 formation, 105
 in syphilis, 229
 gross appearance of, 107
 in adrenal glands, 652
 in bladder, 585
 in kidney, 537
 in liver, 492
 in spleen, 612
 in stomach, 480
 occurrence of, 105
 origin of, 103
 properties of, 102
Anemia of brain, 628
 of myocardium, 428
Angioma, 309, 310
Angiosarcoma, perithelial, 272
Anthrax bacillus, 150
 meningitis, 156
Aorta, diseases of, 439. See also
 Blood-vessels
 necrosis of, 442
 repair of, 446, 447
 rupture of, 451
 sclerosis of, 440
 syphilis of, 227, 462
 tuberculosis of, 461
Appendicitis, 486
Appendix, epithelial tumors of, 388
Argyria, 119
 of liver, 493
Arteries. See Blood-vessels

- Arteries, tuberculosis of, 460
 Arteriosclerosis, 440-444, 462
 chronic, 444
 of kidney, 564
 Artery, rupture of, 451
 Ascites, 94
 Atelectasis, 467
 Atheromatous erosions of aorta, 447, 449
 Atherosclerosis, 463
 Athyrosis, 661
 Atrophic cirrhosis of liver, definition of, 513
 Atrophy, 82
 of bone, 643
 of fat-cells, 84
 of liver, 489
 acute yellow, 501
 of myocardium, 427
 physiologic, 83
 pressure, 83
 Autogenous pigments, 112
 Autonomy in tumors, 252
- BACILLUS æROGENES capsulatus**, 161
 anthracis, 151
 bronchisepticus, 183
 coli communis, 179
 diphtheriæ, 146
 Friedländer's, 156
 glanders, 158
 lepræ, 203
 mallei, 158
 mucosus capsulatus, 156
 of rhinoscleroma, 157
 pertussis, 182
 tuberculosis, 184
 typhosus, 162
- Balantidium coli, 239
 Banti's disease, 614
 Barrel-shaped thorax, 467
 Basedow's disease, 662
 Bile as foreign body, 54
 in circulation, 117
 pigments, 117
 in liver, 493
 stasis, 117, 495
 Bile-ducts, carcinoma of, 390
 tuberculosis, 200
 Bilirubin, 117
 Bladder, amyloid in, 585
 carcinoma of, 393
 dilatation of, 585
 diverticula of, 585
 hypertrophy of, 585
 infections of, 586
 lesions of, 585
 papilloma of, 392, 587
 toxic lesions, 585
 tuberculosis of, 587
 tumors of, 587
- Blastomyces, 230
 Blastomycosis, 230
 Blisters, 94
 Blood, constituents of, 21
 pigment, 113
 in liver, 493, 497
 in prostate, 593
 in spleen, 613
 in vessel walls, 445
 plasma, 24
 platelets, 21
 Blood-corpuscles, red, 21
 as foreign bodies, 55
 diapedesis of, 40
 regeneration of, 65
 white, 23
 Blood-making organs, lesions of, 606
 Blood-vessels, anatomy of, 439
 blood pigment in, 445
 calcification of, 445
 diseases of, 438
 inflammatory reaction, 445
 fat in, 441
 glanders of, 460
 hyalin in, 110, 443
 infectious lesions of, 453
 injury of, 440
 leprosy of, 461
 lime salts in, 445
 mechanical injury of, 451
 necrosis of, 441
 nutritional disturbance of, 451
 of kidney, infections of, 579
 organization of fibrin in, 58
 repair of, 447
 syphilis of, 225, 462
 toxic lesions of, 452
 tuberculosis of, 460
 Boils, 129
 Bone, actinomycosis of, 213
 anatomy of, 641
 as foreign body, removal of, 54
 atrophy of, 643
 disturbance of metabolism, 643
 fracture of, 647
 infectious lesions of, 648
 injury of, 647
 lacunar absorption of, 643
 lesions of, 641
 necrosis of, 77, 648
 regeneration of, 64
 repair of, 75
 syphilis of, 228, 649
 toxic lesions of, 648
 tuberculosis of, 648
 tumors of, 650
 Bone-cell tumor, 295
 Bone-marrow, anatomy of, 606
 in typhoid fever, 177
 infections of, 608
 lesions of, 606
 regeneration of, 608

- Bone-marrow, toxic lesions of, 608**
 tumors of, 610
Brain, anatomy of, 625
 anemia of, 628
 calcification in, 628
 congestion of, 628
 fat in, 627
 hemorrhage, 628, 630
 hyalin in, 628
 infarction of, 629
 infections of, 631
 lesions of, 624
 necrosis in, 627
 pressure on, 630
 sand, 400
 sclerosis of, 635
 syphilis of, 228, 634
 toxic lesions of, 630
 trauma of, 629
 trichiniasis of, 635
 tuberculosis of, 633
 tumors of, 638
Breast, adenoma of, 377
 carcinoma of, 379
 epithelial tumors of, 375
 mixed tumors of, 407
 papilloma of, 379
Bronchiectasis, 477
Bronchopneumonia and the streptococcus, 135
 in whooping-cough, 183
Buboes, 146
- CACHEXIA strumipriva, 661**
 thyroopriva, 661
Caisson disease, 630
Calcification, 120
 in tuberculosis, 196
 of adrenal glands, 652
 of blood-vessels, 445
 of central nervous system, 628
 of endocardium, 416
 of myocardium, 427
 of thyroid, 658
Calor, 35
Cancer. See Carcinoma
Capillary hemangioma, 310
Capsular glomerulonephritis, 549
Carbon in body, 118
 in liver, 493, 497, 513
 in lymph-nodes, 622
 in spleen, 614
Carbuncle, 129
 anthrax, 153
Carcinoma, 358, 359, 363
 adrenal, 585
 colloid, 368
 epidermoid, 364, 369
 of adrenal gland, 397
 of bile-ducts, 390
 of bladder, 393
Carcinoma of breast, 379
 of epiphysis, 400
 of esophagus, 387, 481
 of gall-bladder, 391, 519
 of hair-matrix, 371
 of hypophysis, 400
 of intestine, 388, 487
 of kidney, 392
 of liver, 390
 of lung, 392, 477
 of lymph-nodes, 623
 of mammary gland, 604
 of nipple, 383
 of ovary, 395, 602
 of pancreas, 391, 529
 of penis, 589
 of prostate, 393, 596
 of rectum, 388
 of stomach, 387, 484
 of thyroid, 398, 660
 of uterus, 393, 599
 of vocal cords, 392
 papillary, 360, 364
 simplex, 364
Cardiac lesions, physiologic effects of, 438
Cardinal signs of inflammation, 34
Cartilage, repair of, 78
Cartilage-cell tumor, 291
Cartilage-cells, regeneration of, 64
Caseation, 97
 in syphilis, 98
 in tuberculosis, 97, 195
Catarrhal inflammation, 48
Caustic potash, experimental use, 29
Cavernoma, 314
Cavernous hemangioma, 314
Cavities in lung, 477
Cells, blood, 21
 connective-tissue. 25
 endothelial, 26
 hydrops of, 94
 postmortem changes in, 80
 regeneration of, 60
 tumor, differentiation of, 271
Centers of ossification, 642
Central necrosis of liver, 498
 nervous system, calcification in, 628
 fat in, 627
 lesions of, 624
 necrosis of, 627
 sclerosis of, 635
 syphilis of, 228, 634
 toxic lesions of, 630
 trauma of, 629
 tumors of, 638
Cerebrospinal meningitis, 138
Cerebrum. See Brain
Cervix uteri, cancer of, 599
 lesions of, 598
Chancre, 221, 589
Chloroform necrosis of liver, 504

- Chloroform, use in experimental necrosis, 29
 Chloroma, 334, 338, 610
 Cholesterin in tissues, 93
 Chondroblastoma, 291
 Chondroblasts, 64
 Chondroma, 291
 Chondromucin, 291
 Chondrosarcoma, 291
 Chordoblastoma, 400
 Chordoma, 400
 Chorionepithelioma, 405, 604
 Chromatin in cell necrosis, 96
 Chromatophores, 340
 Chronic tuberculosis, 192
 Circulation, injurious agents within, reaction to, 49
 normal, 20
 Circulatory phenomena in acute inflammation, 35
 Cirrhosis of liver, 512
 alcoholic, 504, 514
 atrophic, definition of, 513
 hypertrophic, definition of, 513
 infectious, 508
 monolobar, 514
 multilobar, 514
 syphilitic, 511
 toxic, 504
 Classification of tumors, 274
 Cloudy swelling, 88
 Coagulation necrosis, 97
 Coil gland, epithelial tumors of, 374
 Colitis, 485, 486
 Collagen fibrils, 26
 Colliquation, 98
 Colloid, 107
 carcinoma, 368
 in kidney, 533
 in thyroid, 656
 Colon bacillus, 179
 Concretions in pancreas, 521
 Congenital syphilis, 215
 Congestion of brain, 628
 of gastro-intestinal tract, 480
 of heart, 428
 of liver, 493
 of lungs, 463
 of spleen, 614
 of thyroid, 655
 of uterus, 597
 Conglomerate tubercle, 193
 Connective-tissue cells, 25
 regeneration of, 64
 tumors, 276
 Constituents of normal tissues, 24
 Cord. See *Spinal Cord*
 Cornification, pathologic, 125
 Corpora amylacea in prostate, 593
 Corrosive sublimate, effect on intestine, 485
 effect on kidney, 541, 544
 Corrosive sublimate, effect on stomach, 482
 Cretinism, 661
 Croton oil, experimental use of, 29
 Croupous inflammation, 43
 Cysts, dermoid, 257
 follicular, of enamel organ, 385
 of Nabothian glands, 598
 of ovary, 601
 simple, 257
 DEGENERATION, albuminous, 88
 fatty, 90
 Zenker's, 111
 Dendrons, 625
 Dermoid cyst, 257, 602
 Diabetes, relation of pancreas to, 530
 Diapedesis of red corpuscles, 40
 Differentiation of normal cells in tumor diagnosis, 269
 of tumor cells, 271
 Digestion, organs of, lesions of, 479
 Dilatation of bladder, 585
 Diphtheria, 146
 bacillus, 146
 of stomach, 482
 Diphtheritic inflammation, 45
 Diphtheroid inflammation, 44
 Diplococcus gonorrhœæ, 143
 lanceolatus, 136
 Displaced fetal cells as cause of tumors, 255
 Diverticula of bladder, 585
 Dolor, 35
 Dropsy, 94
 Dura, lesions of, 639
 Dural endothelioblastoma, 321
 endothelioma, 321
 endothelium, lesions of, 640
 Dysentery, amebic, 236
 ECLAMPSIA, liver in, 516
 Edema, 94, 95
 of heart muscle, 423
 of kidney, 533
 of liver, 495
 of lungs, 465
 of pia, 638
 Elastic fibrils, 26
 Emboli, organization of, 58
 Embryo of testicle, 410
 Embryoma of testicle, 592
 Emigration of leukocytes, 36
 Emphysema, alveolar, 466
 interstitial, 466
 Emphysematous gangrene, 99
 Enamel organ, epithelial tumors of, 384
 Endocarditis, 415
 due to *treponema pallidum*, 421

- Endocarditis, infectious, 416**
 streptococcus, 136
 syphilitic, 421
 toxic, 415
Endocardium, 415
 effects of lesions on, 438
 repair of, 420
Endothelial cell tumor, 309
 cells, 26
 of blood-vessels, reaction to injury, 50
 regeneration of, 64
 leukocytes, 23
 fat in, 92
 in inflammation, 37
 in reaction to mild injurious agents, 49
Endothelioblastoma, 309
Endothelioma, dural, 321
Endothelium, dural, lesions of, 640
Entamoeba histolytica, 236
 in liver, 515
Enteritis, 485
Eosinophiles, 24
 in inflammation, 39
 in reaction to mild injurious agents, 49
Epidemic cerebrospinal meningitis, 138
Epidermoid carcinoma, 364, 369
Epididymis, gonococcus infection of, 590
 tuberculosis of, 591
Epididymitis, 590
 gonorrheal, 146
Epiphysis, epithelial tumors of, 400
Epithelial cell tumor, 358
 pearls, 365
 tumors of adrenal, 396
 of bladder, 392
 of esophagus, 387
 of gall-bladder, 391
 of gastro-intestinal tract, 387
 of genito-urinary tract, 392
 of intestine, 388
 of kidney, 392
 of liver, 389
 of ovary, 394
 of pancreas, 391
 of prostate, 393
 of respiratory tract, 391
 of skin, 369
 of stomach, 387
 of thyroid gland, 397
 of uterus, 393
Epithelioblastoma, 358
Epithelium, regeneration of, 62
Erosions in aorta, 448
 of cervix, 598
Erysipelas, 133
Erythroblastoma of spleen, 620
Erythroblasts, 65
Erythrocytes, 21
 as foreign bodies, 55
 diapedesis of, 40
 regeneration of, 65
Esophagus, carcinoma of, 387, 481
 epithelial tumors of, 387
Exogenous pigments, 118
Exophthalmic goiter, 662
Expansion, tumor-growth by, 259
Exudation, acute inflammatory, varieties of, 41
 hemorrhagic, 47
 in lobar pneumonia, 471
 of lymph in inflammation, 40
 pleural, 477
 organization of fibrin in, 56
 pneumonic, organization of fibrin in, 57
 purulent, 46
 serous, 42
- FALLOPIAN tube. See Oviduct**
Fat, 88
 as a foreign body, 54
 characteristics of, 89
 composition of, 89
 deposit, increase of, 89
 embolism of lung, 465
 in blood-vessel walls, 440
 in brain, 627
 in endothelial leukocytes, 92
 in kidney, 535
 in liver, 490
 in myocardium, 423
 in nerve-cells, 627
 in pancreas, 520
 in spleen, 611
 in thyroid gland, 655
 in tissues, gross appearance of, 93
 labile, 89
 necrosis, 98
 of pancreas, 524
 normal distribution of, 89
 stabile, 89
Fat-cell tumor, 301
Fat-cells, atrophy of, 84
 in heart, 411
Fatty degeneration, 90
 infiltration of liver, 491
Female genitals, lesions of, 597
Fetal displacements as cause of tumors, 255
 inclusions as cause of tumors, 256
 forming mixed tumors, 410
 rests as cause of tumors, 255
Fetus in fetu, 409
Fibrin as a foreign body, 56
 formation in acute inflammation, 40
 in tissues, 108
 organization of, 56

- Fibrin, organization of, in blood-vessels, 58
 in pleural exudation, 56
 in pneumonic exudation, 57
- Fibrinous exudation, 42
- Fibroblastoma, 277
 giant-cells in, 280
 histologic structure, 278
 rate of growth, 278
 stroma of, 280
 type-cell, 277
- Fibroblasts, 25
 in tumor formation, 276
 regeneration of, 64
- Fibroglia fibrils, 26
- Fibroma, 277, 282
 of ovary, 602
- Fibrosarcoma, 277, 286
- Fluid in tissues, 94
- Focal necrosis of liver, 518
- Foreign bodies, bile as, 54
 bone, 54
 fat, 54
 fibrin, 56
 giant-cells, 52
 lime salts, 59
 red blood-corpuscles, 55
 removal of, 51
- Fractures, 647
 compound, repair of, 77
 simple, repair of, 76
- Friedländer's bacillus, 156
- Furuncle, 129
- GALL-BLADDER, carcinoma of, 391
 colon bacillus infection, 181
 epithelial tumors of, 391
 in typhoid fever, 178
 lesions of, 519
- Gangrene, 98
 emphysematous, 99
 of lung, 476
- Gangrenous appendix, 487
- Gas bacillus, 161
- Gastric ulcer, 483
- Gastritis, acute, 482
- Gastro-intestinal tract, anthrax of, 155
 epithelial tumors of, 387
 lesions of, 479
 post-mortem changes, 479
- Gastromalacia, 479
- Gaucher's type of splenomegaly, 616
- Genitals, female, lesions of, 597
 male, lesions of, 589
- Genito-urinary tract, epithelial tumors of, 392
- Giant-cell sarcoma, 273
- Giant-cells, foreign body, 52
 in fibroblastoma, 280
 in tuberculosis, 187
- Glanders, 158
 of blood-vessels, 460
- Glioblastoma, 348
- Glioma, 348
- Glomerulonephritis, capsular, 549
 intracapillary, 557
- Glycogen, 99
 in liver, 491
- Glycosuria, pancreas and, 530
- Goiter, 661
 exophthalmic, 662
- Gonococcus, 143
 infection of epididymis, 590
 of oviduct, 600
 of prostate, 595
 of uterus, 598
 special pathology, 146
 toxin of, 144
- Gonorrhoea, 143
 urethra in, 588
- Gout, uric acid deposit in, 124
- Granulation tissue, 72
 healing by, 71
- Granules, albuminous, 86
- Granuloma coccidioides, 234
- Grawitz's tumor, 585
- Gumma, cerebral, 634
- HAIR-MATRIX, epithelial tumors of, 371
- Hairy tongue, 125
- Haliteresis, 643
- Hard chancre, 221
- Healing by first intention, 70
 by granulation tissue, 71
 of wounds, 70
 primary, 70
 secondary, 71
- Heart, atrophy of, 427
 disturbances of circulation in, 428
 fatty, 411
 hydrops of, 423
 muscle. See *Myocardium*
 rhabdomyoma of, 343
 sclerosis of, 437
 tuberculosis of, 436
 tumors of, 437
- Hemangio-endothelioblastoma, 310
- Hemangio-endothelioma, 310
- Hemangioma, 310
 capillary, 310
 cavernous, 314
- Hematoidin, 113
 in spleen, 613
 in tissues, 55
- Hemochromatosis, 115
 of liver, 497
- Hemoglobin as foreign body, 55
 infarct, 113
- Hemoglobinemia, 113
- Hemoglobinogenous pigments, 113

- Hemoglobinuria, 113
 Hemorrhage, cerebral, 628
 in adrenal glands, 652
 in brain, 630
 in infectious lesions of blood-vessels, 456
 into brain, 628
 of liver, 494
 of pancreas, 521
 of stomach, 481
 uterine, 598
 Hemorrhagic exudation, 47
 Hemosiderin, 113
 in liver, 493, 497
 in tissues, 55
 in vessel walls, 445
 Hodgkin's disease, 333, 619
 Hot water, experimental use of, 29
 Hyalin, 108
 in blood-vessels, 110, 443
 in central nervous system, 628
 in liver, 108, 491
 in muscle-cells, 111
 in pancreas, 521
 in plasma cells, 109
 in prostate, 593
 in spleen, 612
 in stomach, 480
 Hyaline connective tissue, 111
 substances, 99
 Hydatidiform mole, 604
 and chorionepithelioma, 406
 Hydrops, 94
 of cell, 94
 of heart muscle, 423
 of kidney, 533
 of liver, 490
 Hypernephroma, 585
 Hypertrophic cirrhosis of liver, definition of, 513
 Hypertrophy of bladder walls, 585
 of prostate, 595
 of spleen, 619
 of thyroid gland, 661
 of uterine mucosa, 598
 Hypophysis, adenoma of, 400
 carcinoma of, 400

INFARCTION of brain, 629
 of liver, 495
 in lung, 465
 tuberculous, of kidney, 581
 Infarcts, hemoglobin, 113
 in myocardium, 429
 of placenta, 604
 of spleen, 614
 uric acid, 124
 Infections of adrenal glands, 654
 of bladder, 586
 of bone, 648
 of bone-marrow, 608

 Infections of brain, 631
 of intestine, 485
 of kidney, 572
 of liver, 508
 of lymph-nodes, 622
 of mammary gland, 603
 of ovary, 601
 of oviduct, 600
 of pancreas, 528
 of peritoneal cavity, 488
 of prostate, 594
 of spleen, 615
 of testicle, 590
 of thyroid gland, 658
 of uterus, 598
 Infectious agents, reaction to, 33
 endocarditis, 416
 lesions of blood-vessels, 453
 of lung, 467
 of stomach, 482
 myocarditis, 432
 nephritis, 573, 575
 Infiltration, tumor growth by, 259
 Inflammation, 17
 catarrhal, 48
 circulatory phenomena in, 35
 croupous, 43
 definition of, 17
 diphtheritic, 45
 diphtheroid, 44
 experimental production of, 28
 exudation of lymph in, 40
 fibrin in, 40
 four cardinal signs of, 34
 injurious agents, 27
 of gall-bladder, 519
 pseudo-diphtheritic, 44
 reaction in, 32
 to injurious agents within the system, 49
 to mild injurious agents, 48
 the injury produced, 31
 tissues used in study of, 30
 tuberculous, 191
 Inflammatory exudation, varieties of, 41
 Injurious agents, 27
 mild reaction to, 48
 nature of action, 28
 used experimentally, 28
 within the circulation, reaction to, 49
 Injury, 31
 reaction to, 32
 Interstitial emphysema, 466
 Intestine, adenoma of, 388
 actinomycosis of, 213
 amebic dysentery, 238
 carcinoma of, 388, 487
 epithelial tumors of, 388
 infections of, 485
 lesions of, 485

- Intestine, pigmentation in, 480
 toxic lesions of, 485
 tumors of, 487
 typhoid lesions in, 168
- Intracapillary glomerulonephritis, 557
- Involucrum, 131
- Irritants, 27
- JAUNDICE, 515**
- KARYOLYSIS, 96**
- Karyorrhexis, 96
- Keloid, 286
 recurrence of, 266
- Kidney, abnormalities of, 584
 abscess of, 573, 575
 adenoma of, 392
 albuminous granules, 532
 amyloid in, 537
 carcinoma of, 392
 cells, regeneration of, 63
 colloid in, 533
 edema of, 533
 fat in, 535
 hydrops of, 533
 infections of, 572
 lesions of, 531
 mixed tumors of, 408
 nephritis, tubular, 542
 vascular, 564
 retrograde changes, 532
 sclerosis of, 584
 syphilis of, 583
 tuberculosis of, 580
 tuberculous infarction of, 581
 tumors of, 585
- LACUNAR** absorption of bone, 643
- Larynx, papilloma of, 391
- Lead in tissues, 119
- Leiomyoblastoma, 305
- Leiomyoma, 305
 of stomach, 485
 of uterus, 599
- Leprosy, 203
 of blood-vessels, 461
- Leukemia, lymphatic, 326
 myelogenous, 336
- Leukocytes, 23
 endothelial, in inflammation, 37
 migration of, 36
 polymorphonuclear, in inflammation, 37
 regeneration of, 65
- Lime salts as foreign bodies, 59
 in blood-vessels, 445
 in tissues, 119
 organization of, 59
- Lipoblastoma, 301
- Lipochrome, 112
- Lipoma, 301
- Lipomatosis, 89
 of pancreas, 520
- Liquefaction necrosis, 98
- Liver, abscess of, 508
 actinomycosis of, 213, 512
 acute yellow atrophy of, 501
 adenoma of, 389
 albuminous granules in, 490
 ameba in, 239
 atrophy of, 489
 bile stasis in, 496
 carbon in, 497, 513
 carcinoma of, 390
 cells, regeneration of, 62
 circulatory disturbances, 493
 cirrhosis of, 512
 alcoholic, 504, 514
 infectious, 508
 monolobular, 514
 syphilitic, 511
 toxic, 504
 colon bacillus infection, 181
 congestion of, 493
 edema of, 495
 entameba in, 515
 epithelial tumors of, 389
 fat in, 490
 fluid in, 95
 glycogen in, 491
 hemochromatosis of, 497
 hemorrhage of, 494
 hemosiderin in, 493
 hyalin in, 108, 491
 hydrops of, 490
 in eclampsia, 516
 in typhoid fever, 173
 infarction, 495
 infectious lesions of, 508
 lesions of, 488
 malarial infection, 512
 miliary tubercle of, 189
 necrosis of, 491
 central, 498
 hemorrhagic, 501
 pigmentation of, 492, 497, 513
 postmortem changes in, 489
 regeneration of, 493
 sclerosis of, 512
 syphilis of, 227, 511
 toxic lesions of, 498
 tuberculosis of, 199, 510
- Lobar pneumonia, 467, 471
 and pneumococcus, 136, 138
 bacillus mucosus capsulatus in, 156
- Lobular pneumonia, 467
 and meningococcus, 143
- Lung, abscess of, 476
 actinomycosis of, 213
 anthrax of, 155

- Lung, carcinoma of, 392, 477
 cavities in, 477
 circulatory disturbances, 464
 congestion of, 464
 diphtheria of, 150
 edema of, 465
 gangrene of, 476
 glanders in, 161
 in typhoid fever, 177
 infarction of, 465
 infectious lesions of, 467
 mechanical lesions of, 466
 mixed tumors of, 408
 tuberculosis of, 201
- Lutein, 112
- Lymph, exudation of, in inflammation, 40
 normal, 27
 spaces, 27
- Lymphangio-endothelioblastoma, 319
- Lymphangio-endothelioma, 319
- Lymphangioma, 319
- Lymphatic leukemia, 326
- Lymphatics in tuberculosis, 191
- Lymph-nodes, carbon in, 622
 cells of, 620
 function of, 621
 infections of, 622
 lesions of, 620
 toxic lesions, 622
 tuberculosis of, 201
 tumors of, 623
- Lymphoblast tumor, 326
- Lymphoblastoma, 326
 of lymph-nodes, 623
 of spleen, 617
- Lymphoblasts, 620
- Lymphocyte tumor, 326
- Lymphocytes, 23, 620
 in inflammation, 38
 in reactions to mild injurious agents, 49
 in tuberculosis, 190
- Lymphocytoma, 326
- Lymphoma, 326
- Lymphosarcoma, 326
- Lymph-vessels, 27
 tumor, 319
- MALAKOPLAKIA, 586**
- Malaria, effect on liver, 512
 spleen in, 616
- Male genitals, lesions of, 589
- Malignancy of glioma, 353
 of tumors, 268
- Malignant adenoma, 360, 364
 pustule, 153
- Mammary gland, adenoma of, 377, 603
 carcinoma of, 379
 epithelial tumors of, 375
- Mammary gland, infectious lesions of, 603
 lesions, 602
 papilloma of, 379
 toxic lesions of, 603
 tumors of, 603
- Marrow. See *Bone-marrow*
- Mast-cells, 24
 in inflammation, 40
- Medullary cancer of breast, 383
- Melanin, 112
 in liver, 493
 in spleen, 613
- Melanoblast tumor, 340
- Melanoblastoma, 340
- Melanoblasts, 112
- Melanoma, 340
- Melanotic sarcoma, 340
- Meninges, lesions of, 638, 639
 syphilis of, 228
- Meningitis, 638
 anthrax, 156
 cerebrospinal, 138
 in typhoid fever, 177
- Meningococcus, 138
- Menstruation, uterine changes in, 597
- Mesenteric lymph-nodes in typhoid fever, 172
- Metastasis of glioma, 355
 of lymphoblastoma, 331
 of tumors, 266
- Micrococcus intracellularis meningitidis, 138
- Miliary tubercle, 189, 190
 tuberculosis of kidney, 580
 of liver, 510
- Mitosis of tumor cells, 261
- Mixed tumors, 406
 of ectodermal origin, 407
 of mesenchymal origin, 407
 of ovary, 409
 of testicle, 409
- Monolobular cirrhosis, 514
- Mucin, 101
- Mucus, 101
- Multilobular cirrhosis, 514
- Mumps, testicle in, 592
- Muscle-cells, hyalin in, 111
 regeneration of, 65
 tumor, 305
- Muscle-fibers, fluid in, 95
 regeneration of, 67
- Muscle, repair of, 78
 striated, tumor of, 343
- Myelin as foreign body, 54
- Myeloblast tumor, 334
- Myeloblastoma, 334, 610
- Myelogenous leukemia, 336
- Myeloma, 338, 610
- Myocarditis, infectious, 432
 syphilitic, 436
 toxic, 430

- Myocarditis, tuberculous, 436**
Myocardium, albuminous granules in, 422
 anemia of, 428
 atrophy of, 427
 calcification of, 427
 congestion of, 428
 effect of lesions on, 438
 fat in, 423
 infarcts in, 429
 inflammation of. *See Myocarditis.*
 necrosis of, 424
 repair of, 434
 sclerosis of, 437
 syphilis of, 436
 trichiniasis of, 437
 tuberculosis of, 436
 tumors of, 437
Myotomes, 408
Myxoblastoma, 288
Myxoma, 288
Myxosarcoma, 288
- NECROBIOSIS, 96**
Necrosis, 96
 caused by staphylococcus pyogenes aureus, 127
 coagulation, 97
 demonstration of, 32
 fat, 98
 focal, of liver, 518
 liquefaction, 98
 of aorta, 442
 of blood-vessels, 441
 inflammatory reaction, 446
 of bone, 77, 648
 of brain, 627
 of cord, 627
 of liver, 491, 494
 central, 498
 chloroform, 504
 focal, 518
 hemorrhagic, 501
 toxic, 498
 of myocardium, 424
 effect of, 438
 of pancreas, fat, 524
 tuberculosis, 189, 195
Necrotic tissue, removal of, 52
Nephritis, infectious, 573, 575
 toxic, 541
 tuberculous, 582
 tubular, 542
Nephrotomes, 408
Nerve-cell, injury of, 625
 regeneration of, 66, 625
 tumor, 355
Nerves, normal, 27
Nervous system, central, lesions of, 624
 repair of, 78
Nervous system, syphilis of, 228
Neuroblastoma, 355
Neurocytoma, 355
Neuroglia cell in repair, 78
 regeneration of, 65
 tumor, 348
Neuroma, 355
 amputation, 67
Neuron, regeneration of, 625
Neurons, 625
Neutrophilic leukocytes, 23
Nevi, pigmented, 341
New growths. See Tumors
Nipple, cancer of, 383
 Paget's disease of, 604
Noma, 99
Nomenclature of tumors, 275
Normal circulation, 20
Notochord tissue, 400
Nutrition of blood-vessels, disturbances of, 451
- ODONTOBLASTOMA, 387**
Odontoblasts, 385
Oidiomycosis, 234
Oidium, 230, 234
Ophthalmia, gonorrhoeal, 146
Organization of fibrin, 56
 of lime salts, 59
Osseomucin, 64
Ossification, 119
 centers of, 642
Osteoblastoma, 295
Osteoblasts, 64
Osteoclasts, 64
Osteogenesis imperfecta, 646
Osteoma, 295
 durum, 300
 spongiosum, 300
Osteomalacia, 647
Osteomyelitis, 130, 648
 bone-marrow in, 609
Osteophytes, 649
Osteosarcoma, 295
Ostitis deformans, 646
Ovary, adenoma of, 394
 carcinoma of, 395
 cysts of, 601
 infections of, 601
 mixed tumors of, 409
 teratoma of, 409
 tumors of, 602
Oviduct, infections of, 600
 lesions of, 600
 tuberculosis of, 601
- PACHYMENINGITIS, 639**
Paget's disease of bone, 646
 of nipple, 604
Pancreas, adenoma of, 391

- Pancreas, carcinoma of, 391**
 colon-bacillus infection of, 182
 concretions in, 521
 epithelial tumors of, 391
 experimental work, 530
 extirpation of, effect of, 530
 fat in, 520
 necrosis of, 524
 functions of, 529
 hemorrhage of, 521
 hyalin in, 521
 infections of, 528
 lesions of, 519
 obstruction of ducts of, 523
 pigmentation of, 521
 postmortem changes in, 520
 retrograde changes, 520
 sclerosis of, 528
 secretions of, 529
 syphilis of, 528
 toxic lesions of, 523
 tuberculosis of, 528
 tumors of, 528
Pancreatitis, acute, 524
Papillary carcinoma, 360, 364
Papilloma, 358, 359
 cells of, 362
 of bladder, 392, 587
 of breast, 379
 of larynx, 391
 of skin, 369
Parasitism in repair of foreign bodies, 53
Parotid gland, mixed tumors of, 408
Pearls, epithelial, 365
Penis, carcinoma of, 589
 chancere of, 589
 lesions of, 589
Periarteritis nodosa, blood-vessels in, 460
Pericardial cavity, 411
Pericarditis, 411, 412
 physiologic effect of, 438
 tuberculous, 415
Pericardium, effect of lesions on, 438
Perichondrium, 64
Periostitis, 648
Perithelial angiosarcoma, 272
Peritoneal cavity, lesions of, 488
Peritonitis, 488
Petrifaction, 118
Phlegmon, 135
Phosphorus necrosis of bone, 648
Physiologic atrophy, 83
Pia, lesions of, 638
Pigmentation, 111
 in gastro-intestinal tract, 480
 in lymph-nodes, 622
 of liver, 492, 497, 513
 of pancreas, 521
 of spleen, 613
 of thyroid, 655
- Pigmented nevi, 341**
Pigments, 111
 autogenous, 112
 bile, 117
 blood, 113
 carbon, 118
 exogenous, 118
 hemoglobinogenous, 113
 in prostate, 593
 lead, 119
 silver, 119
 tattooing, 119
Pitting, 40
Placenta, infarcts of, 604
Placental fragments, retention of, 605
Plasma, blood, 24
 cells, hyalin in, 109
 in inflammation, 39
Platelets, blood, 21
Pleural cavity, lesions of, 477
 exudation, organization of fibrin in, 56
Pleuritis, 477
Pneumococcus, 136
 septicemia, 137
Pneumonia, bacillus mucosus capsulatus and, 156
 lobar, 471
 and pneumococcus, 136, 138
 lobular, 143, 467
Pneumonic exudation, organization of fibrin in, 57
Poisoning, stomach in, 482
Poisons, effect on bladder, 585
 on intestine, 485
 on kidney, 541
 on liver, 498
 on stomach, 482
 on uterus, 598
Poliomyelitis, acute anterior, 631
Polymorphonuclear leukocytes, 23
 in inflammation, 37
Polypi, uterine, 598
Postmortem changes in cells, 80
 in gastro-intestinal tract, 479
 in kidney, 532
 in liver, 489
 in pancreas, 520
 in prostate, 593
Pressure atrophy, 83
 on brain, 630
Primary healing, 70
 stage of syphilis, 214
 syphilis, lesion of, 221
Prostate, adenoma of, 393
 carcinoma of, 393, 596
 corpora amylacea, 593
 hypertrophy of, 595
 infections of, 594
 lesions of, 593
 pigmentation of, 593
 retrograde changes in, 593

- Prostate, tuberculosis of, 595
tumors of, 596
- Psammmocarcinoma of ovary, 395
- Psammmoma, 273
- Pseudo-diphtheritic inflammation, 44
- Pseudoleukemia, 326
- Purulent exudation, 46
- Pustule, malignant, 153
- Pyelonephritis, 575-577
- Pyknosis, 96
- REACTION** to infectious agents, 33
to injurious agents within the circulation, 49
to injury, 32
to mild injurious agents, 48
- Rectum, carcinoma of, 388
- Recurrence of tumors, 266
- Red blood-corpuscles, 21
as foreign bodies, 55
- Regeneration of blood-corpuscles, 65
of bone cells, 64
of cells, 60
of connective tissue in tuberculosis, 190
of endothelial cells, 64
of epithelium, 62
of fibroblasts, 64
in tuberculosis, 189
of leukocytes, 65
of liver cells, 162, 493
of muscle cells, 65
of muscle-fibers, 67
of nerve-cells, 66
of neuroglia cells, 65
of parts of cells, 66
- Repair, 51
epithelium, 62
foreign body giant-cells, 52
healing of wounds, 70
liver cells, 62
neuroglia cells in, 78
of blood-vessels, 447
infectious lesions, 456
of bone, 75
of cartilage, 78
of central nervous system, 78
of endocardium, 420
of fracture, 76
of kidney cells, 63
of muscle, 78
of myocardium, 434
organization of fibrin, 56
lime salts, 59
parasitism in case of foreign bodies, 53
regeneration of, 60
muscle-fibers, 67
nerve-cells, 66
parts of cells, 66
removal of foreign bodies, 51
- Repair, removal of necrotic tissue, 53
- Respiration, organs of, diseases of, 464
- Respiratory tract, epithelial tumors of, 391
- Rests, fetal, and tumors, 255
- Retrograde metamorphosis of tumors, 264
processes, 79
amyloid, 102
caseation, 97
colloid, 107
cornification, 125
fat, 88
fibrin, 108
fluid, 94
glycogen, 99
hyalin, 108
mucin, 101
necrosis, 96
petrification, 119
pigments, 111
postmortem changes, 80
- Rhabdomyoblastoma, 343
of cardiac muscle-cell type, 343
of skeletal muscle-cell type, 346
- Rhabdomyoma, 343
of heart, 437
- Rhinoscleroma, bacillus of, 157
- Ricketts, 643
- Round-cell sarcoma, 272
- Rubor, 34
- Rupture of aorta, 451
of artery, 451
- SAGO spleen, 612
- Salpingitis, 600
gonorrhoeal, 146
- Sarcoma, giant-cell, 273
melanotic, 340
round-cell, 272
spindle-cell, 272
- Scar, 75
tissue, 75
- Scirrhus cancer of breast, 383
- Sclerosis of brain, 635
of cord, 635
of kidney, 583
of liver, 512
of myocardium, 437
of pancreas, 528
of testicle, 592
of thyroid gland, 659
of valves of heart, 422
- Sclerotomes, 408
- Sebaceous gland, epithelial tumors of, 374
- Secondary healing, 71
stage of syphilis, 214
syphilis, lesion of, 223
- Secretions, pancreatic, 529
- Seminal vesicles, lesions of, 593

- Septicemia, anthrax bacillus, 155
 bacillus aërogenes, 162
 glanders bacillus, 160
 gonococcus, 146
 of *bacillus mucosus capsulatus*, 157
 pneumococcus, 137
 staphylococcus, 131
 streptococcus, 135
 Sequestrum, 131
 Serous exudation, 42
 Silver in tissues, 119
 Skin, epithelial tumors of, 369
 glanders in, 161
 Solitary tubercle, 193
 Spiculated bodies in spleen, 613
 Spinal cord, anatomy of, 625
 fat in, 627
 hemorrhage into, 628
 infections of, 631
 lesions of, 624
 pressure on, 630
 sclerosis of, 635
 syphilis of, 634
 toxic lesions of, 630
 trauma of, 629
 tuberculosis of, 633
 tumors of, 638
 Spindle-cell sarcoma, 272
 Spirochete. See *Treponema*
 Spleen, abscess of, 616
 amyloid in, 612
 anatomy of, 610
 congestion of, 614
 enlargement of, 616
 fat in, 611
 function of, 610
 hyalin in, 612
 hypertrophy of, 619
 in typhoid fever, 175
 infarcts of, 614
 infections of, 615
 malarial infection of, 616
 pigmentation of, 613
 retrograde changes in, 611
 sago, 612
 syphilis of, 617
 toxic lesions of, 615
 tuberculosis of, 200, 616
 tumors of, 617
 Splenomegaly, 619
 Gaucher's type, 616
 Staphylococcus *pyogenes aureus*, 126
 experimental injection of, 30
 forms of lesion caused by, 129
 injury by, 127
 reaction to, 127
 toxin, 126
 Stasis, bile, 495
 Stomach, adenoma of, 387
 amyloid in, 480
 atrophy of glands of, 479
 carcinoma of, 387, 485
 Stomach, epithelial tumors of, 387
 hemorrhages of, 481
 infectious lesions of, 482
 inflammation of, 482
 lesions of, 481
 postmortem softening of, 479
 toxic lesions of, 482
 tumors of, 484
 ulceration of, 483
 Streptococcus infection of blood-
 vessels, 457
 pyogenes, 131
 toxin of, 132
 Stricture of urethra, 146, 588
 Stroma of tumors, 262
 Struma colloides, 659
 parenchymatosa, 659
 Subpericardial ecchymoses, 412
 Suppuration, 46
 Swelling, cloudy, 88
 Syphilis, 213
 acquired, 214
 amyloid formation in, 229
 congenital, 215
 lesions of, 217
 of adrenal glands, 654
 of aorta, 227, 462
 of blood-vessels, 225, 462
 of bone, 228, 649
 of brain, 228, 634
 of central nervous system, 228
 of cord, 634
 of endocardium, 421
 of kidney, 583
 of liver, 227, 511
 of meninges, 228
 of myocardium, 436
 of pancreas, 528
 of pia, 639
 of spleen, 617
 of testicle, 591
 pathologic histology, 221
 primary, lesion of, 221
 reaction in, 218
 repair in, 220
 secondary, lesion of, 223
 tertiary, lesion of, 223
 treponema pallidum, 216
 TATTOOING, 119
 Teratoma of ovary, 409, 602
 of testicle, 409
 Tertiary stage of syphilis, 215
 syphilis, lesion of, 223
 Testicle, embryoma of, 410
 in mumps, 592
 in variola, 592
 lesions of, 590
 mixed tumors of, 409
 sclerosis of, 592
 syphilis of, 591

- Testicle, teratoma of, 409
 tuberculosis of, 591
 tumors of, 592
 Thrombi, organization of, 58
 Thrombus formation in tuberculosis, 194
 Thyroid gland, adenoma of, 398, 659
 anatomy of, 655
 calcification of, 658
 carcinoma of, 398, 660
 colloid in, 656
 congestion of, 655
 fat in, 655
 follicular distention, 659
 hypertrophy of, 661
 retrograde changes in, 655
 toxic lesions of, 658
 infections of, 658
 sclerosis of, 659
 Tiger-lily appearance of heart muscle, 424
 Tissues, normal, constituents of, 24
 Tongue, hairy, 125
 Tonsillitis, 135
 Toxic cirrhosis of liver, 504
 endocarditis, 415
 lesions of blood-vessels, 452
 of central nervous system, 630
 of liver, 498
 of pancreas, 523
 myocarditis, 430
 nephritis, 541
 Toxin, diphtheria, 148
 of actinomycosis, 212
 of anthrax, 152
 of bacillus *aërogenes capsulatus*, 162
 mucosus capsulatus, 156
 of blastomyces, 231
 of colon bacillus, 180
 of diplococcus *lanceolatus*, 136
 of glanders bacillus, 158
 of gonococcus, 144
 of leprosy bacillus, 204
 of meningococcus, 139
 of oidium, 235
 of pneumococcus, 136
 of staphylococcus *pyogenes aureus*, 126
 of streptococcus *pyogenes*, 132
 of syphilis, 217
 of tubercle bacillus, 186
 of typhoid bacillus, 164
 of whooping-cough bacillus, 183
 Toxins, effect on bone-marrow, 608
 lymph-nodes, 622
 spleen, 615
 Trauma, 31
 of brain, 629
 of cord, 629
Treponema pallidum, 213
 description of, 216
 Treponema pallidum, endocarditis
 due to, 421
 in blood-vessels, 462
 in heart muscle, 436
 in kidney, 583
 lesion produced by, 217
 location of, 217
 reaction to, 218
 Trichina, 243
Trichinella spiralis, 243
 in myocardium, 437
 Trichiniasis, 243
 diagnosis of, 250
 of brain, 635
 of myocardium, 437
 Tubal pregnancy, 601
 Tubercle bacillus, 184
 experimental injection of, 30
 conglomerate, 193
 miliary, 189, 190
 solitary, 193
 Tuberculosis, 184
 abscesses in, 197
 acute miliary, 199
 bacillus of, 185
 calcification in, 196
 caseation in, 195
 chronic, 192, 199
 early miliary lesions, 186
 giant-cells in, 187
 necrosis in, 195
 of adrenals, 654
 of bladder, 587
 of blood-vessels, 460
 of bone, 648
 of brain, 633
 of cord, 633
 of epididymis, 591
 of heart, 415, 436
 of kidney, 580
 of liver, 199, 510
 of lungs, 201
 of lymph-node, 201
 of oviduct, 601
 of pancreas, 528
 of peritoneal cavity, 488
 of pia, 639
 of prostate, 595
 of spleen, 200, 616
 of uterus, 598
 reaction, 186
 regeneration of fibroblasts, 189
 thrombus formation in, 194
 toxin of, 186
 ulceration in, 197
 Tuberculous infarction of kidney, 581
 inflammation, 191
 nephritis, 582
 pericarditis, 415
 Tubular nephritis, 542
 Tumor, a sign of inflammation, 35
 cells, 261

- Tumor cells, differentiation of, 271
 Tumor-like formations, 256
 Tumors, 251
 cause of, 253
 characteristics of, 252
 classification of, 274
 color of, 265
 combinations of types, 406
 connective-tissue, 276
 consistence, 266
 definition, 251
 differentiation of cells, 266
 functions of, 253
 gross characteristics of, 264
 heterogeneous, 269
 malignancy of, 268
 manner of growth, 258
 metastases, 266
 mixed, 406
 morphology of, 252
 multiplicity of, 269
 nomenclature of, 275
 of bladder, 587
 of bone, 650
 of bone-marrow, 610
 of brain, 638
 of gall-bladder, 519
 of heart, 437
 of intestine, 487
 of kidney, 585
 of lung, 477
 of lymph-nodes, 623
 of mammary gland, 603
 of ovary, 602
 of pancreas, 528
 of peritoneal cavity, 488
 of pleural cavity, 478
 of prostate, 596
 of spleen, 617
 of stomach, 484
 of testicle, 592
 of uterus, 598
 origin of, 254
 recurrence, 266
 retrograde metamorphosis of, 264
 shape of, 265
 simple, 276
 size of, 264
 stroma of, 262
 structure of, 260
 type cells, 270
 Turpentine as an injurious agent, 29
 Type cells of tumors, 270
 Typhoid bacillus, 162
 fever, 162
 abscesses in, 178
 bacillus, 163
 Typhoid fever, bone-marrow in, 177
 distribution of lesions, 166
 gall-bladder in, 178
 intestinal lesions, 168
 liver in, 173
 lung in, 177
 meningitis in, 178
 mesenteric lymph-nodes in, 172
 reaction, 164
 spleen in, 175
 toxin, 164
 ULCER, gastric, 483
 Ulceration of stomach, 483
 tuberculous, 197
 Urethra, lesions of, 588
 stricture of, 146
 Uric acid in circulation, 124
 Urinary bladder. See *Bladder*
 organs, lesions of, 531
 tract, colon infection of, 181
 Uterus, adenoma of, 393
 adenomyoma of, 600
 carcinoma of, 393, 599
 congestion of, 597
 gonorrhoea of, 598
 infections of, 598
 leiomyoma of, 599
 lesions of, 597
 placental fragments in, 605
 polypi of, 598
 toxic lesions of, 598
 tuberculosis of, 598
 tumors of, 598
 VALVES of heart, diseases of, 415
 sclerosis of, 422
 Vaquez's disease, 620
 Variola, testicle in, 592
 Vas deferens, lesions of, 593
 Vascular endothelium, regeneration
 of, 64
 nephritis, 564
 Vegetation of cardiac valves, 416
 Veins. See *Blood-vessels*
 tuberculosis of, 460
 Vocal cords, carcinoma of, 392
 WHITE blood-corpuscles, 23
 Whooping-cough, 182
 Wounds, healing of, 70
 ZENKER's degeneration, 111

