



# CARE OF PATIENTS

UNDERGOING

## GYNECOLOGIC and ABDOMINAL PROCEDURES

BEFORE, DURING, AND AFTER OPERATION

BY

**E. E. MONTGOMERY, A.M., M.D., LL.D., F.A.C.S.**

Professor of Gynecology in Jefferson Medical College; Gynecologist to Jefferson and St. Joseph's Hospitals; Consulting Surgeon to the Philadelphia Lying-in Hospital, the Jewish Hospital, the Kensington Hospital for Women, and the American Oncologic Hospital


*ILLUSTRATED*

PHILADELPHIA AND LONDON

**W. B. SAUNDERS COMPANY**

1916

34



1452

Copyright, 1916, by W. B. Saunders Company

---

PRINTED IN AMERICA

---

PRESS OF  
W. B. SAUNDERS COMPANY  
PHILADELPHIA

**TO THE MANY LOYAL AND DEVOTED WOMEN WHOSE  
FAITHFUL SERVICE HAS MADE GOOD SURGERY POSSIBLE  
THIS BOOK IS RESPECTFULLY DEDICATED.**



## PREFACE

---

EVERY surgeon, in preparing for an unusual operation, has found it difficult to decide just what instruments and materials should be selected. To the novice in the operating room, nurse, or intern every operation is an unusual one, and without special instruction in preparation for various operations important instruments and articles will be overlooked. The surgeon, too, harassed with the care of many patients, will not infrequently find that in his selection he has omitted some things which would have greatly expedited his work.

While convalescing from an operation last summer the writer decided to prepare for his assistants some typewritten instructions which, as the work progressed, he found it necessary to extend, until this little book is its outgrowth. He has endeavored to present a chart which, if intelligently followed, will greatly accelerate the work of the surgeon, add to the comfort of his patients, and redound to the credit of his assistants. His own experience assures him that this book will prove valuable to the young gynecologist by making easy his early steps alone in the field of pelvic and abdominal surgery.

He takes this opportunity to express his appreciation of the courtesy and generous co-operation of the publishers; to

thank Mr. J. V. Altener and Miss S. L. Clark for their work in the preparation of the illustrations; Messrs. Charles Lentz and Sons and Miss Clara Melville for the loan of instruments, and Miss Nellie M. Gandley for the work of transcribing.

If this book, as it passes from his hands, by lessening the anxiety of the surgeon, promotes better work, facilitates the labor of nurses and interns, but, above all, adds to the comfort and satisfaction of the patients, the author will feel well repaid for his efforts.

E. E. MONTGOMERY.

1426 SPRUCE ST., PHILADELPHIA, PA.

*September, 1916.*

# CONTENTS

---

GENERAL PART		PAGE
On Admission.....		11
Preparation of the Field for Operation.....		12
The Incision.....		15
Closure of the Wound.....		21
Dressings.....		25
Clinic Work.....		26
Care of Patient During Operation.....		27
After-care.....		29
Catheterization.....		32
Nourishment.....		34
Shock.....		36
Nausea and Vomiting.....		41
Hemorrhage, External and Internal.....		42
Tympanites.....		45
Abdominal Pain and Tenderness.....		48
Peritonitis.....		49
Sepsis.....		52
Phlebitis.....		56
Ileus.....		58
Fecal Fistula.....		60

## ABDOMINAL AND PELVIC OPERATIONS


Shortening Ligaments.....	62
Salpingectomy—Salpingo-oöphorectomy.....	67
Ovariectomy.....	73
Hysterectomy—Panhysterectomy—Subtotal Hysterectomy.....	77
Intestinal Resection and Anastomosis.....	82
Gastric Operations.....	86
Gastropexy.....	87
Gastrostomy.....	91
Gastro-enterostomy.....	92



	PAGE
Gall-bladder Operations.....	97
The Spleen.....	103
Operation Upon the Kidney.....	105

#### VAGINAL OPERATIONS

Dilatation and Curetment.....	116
Trachelorrhaphy.....	119
Amputation of Cervix.....	123
Anterior Colporrhaphy.....	128
Vesicovaginal Interposition of Uterus; Watkins' Operation.....	130
Vaginal Hysterectomy.....	132
Perineorrhaphy; Posterior Colporrhaphy; Rectovaginal Interposition of Levator Ani Muscles.....	138
—————	
INDEX.....	147



# CARE OF GYNECOLOGIC PATIENTS

---

## GENERAL PART

### ON ADMISSION OF THE PATIENT

**Nurse's Duties.**—On admission of a patient, the nurse should record the temperature, pulse, and frequency of respiration; secure a specimen of urine for examination, and, if her condition is in any way unsatisfactory, should notify the intern at once.

**Intern's Duties.**—Every operative patient should have the urine examined, an ordinary blood-count made, and her blood-pressure taken. A careful history should be written, and on his visit the attention of the visiting surgeon directed to her. A supranormal temperature, anemia, or the apparent appearance of recent hemorrhage should indicate a complete blood-count. If she has a vaginal discharge, a smear should be taken for examination and cultures made. In septic conditions it is wise to order cultures made from the blood and institute measures to secure vaccines.

When the date for operation has been decided, the patient should be ordered a purgative for the morning preceding (the best, *Ol. ricini*, fʒij) and a soap-and-water enema for the night before. The diet for the day before should

have as little waste material as possible and only hot water on the morning of operation, unless it is to take place late in the day, when the patient may be given a little bouillon, clear soup, or a cup of tea or coffee without milk.

#### PREPARATION OF THE FIELD FOR OPERATION

The field for operation should be prepared by the removal of the hair, either by shaving or with a depilatory. The latter is less objectionable in that the skin is uninjured and no opportunity is thus afforded for skin infection. The following prescription forms a very satisfactory depilatory:

Calcii caustici pulveri.....	10.0
Sodii sulphid.....	3.0
Amyli.....	10.0

Pulverize separately, mix, and keep in a bottle dry. When desired to be used, mix with enough water to make a paste and spread on the surface about  $\frac{1}{8}$  inch thick with a wooden spoon or glass spatula. When applied over the vulva the mucous surface should be previously painted with some sterile oil as a protection.

The entire abdominal surface should be deprived of hair, the surface bathed with soap and hot water and afterward with alcohol. After the surface has had time to dry it should be painted with an alcoholic solution (3.5 per cent.) of iodine and have a sterile dressing kept in place with a bandage. This painting should be repeated the evening before the operation and again after the patient is brought to the operating-table. After the last painting has become dry, the

entire surface should be sponged with a gauze pad wet with alcohol to remove the superfluous iodine and prevent its injuring any coils of intestine which may escape and come in contact with the skin surface. This precaution may save the patient from desquamation of the intestinal endothelium which would most certainly cause subsequent adhesions and their unfortunate sequelæ.

Should the patient suffer from a condition which requires immediate attention, and the requisite time for preparation cannot be taken, the abdomen should be shaved, then be washed first with gasoline, subsequently painted with iodine solution, and then again washed with alcohol before opening the abdomen.

The preparations for abdominal incision, indeed, for any operative procedure, demand the utmost cleanliness on the part of the surgeon and his assistants. Every avenue for the entrance of infection must be rigidly controlled. The operator and his assistants must diligently wash their hands and arms with soap and hot water, using the nail-brush for a period of ten minutes, even though they expect to wear rubber gloves. Gloves are worn to protect the patient, not the wearer, from infection. They must not be an excuse for neglect of surgical cleanliness, otherwise it were better not to use them. A glove may be easily torn or punctured during the operation, then neglect in cleanliness may mean grave danger to the patient. The purpose of wearing the gloves is defeated when the surgeon uses the fingers of the bare hand to press in place the fingers of the first glove he puts on.

The surgeon and all his assistants who have anything to do

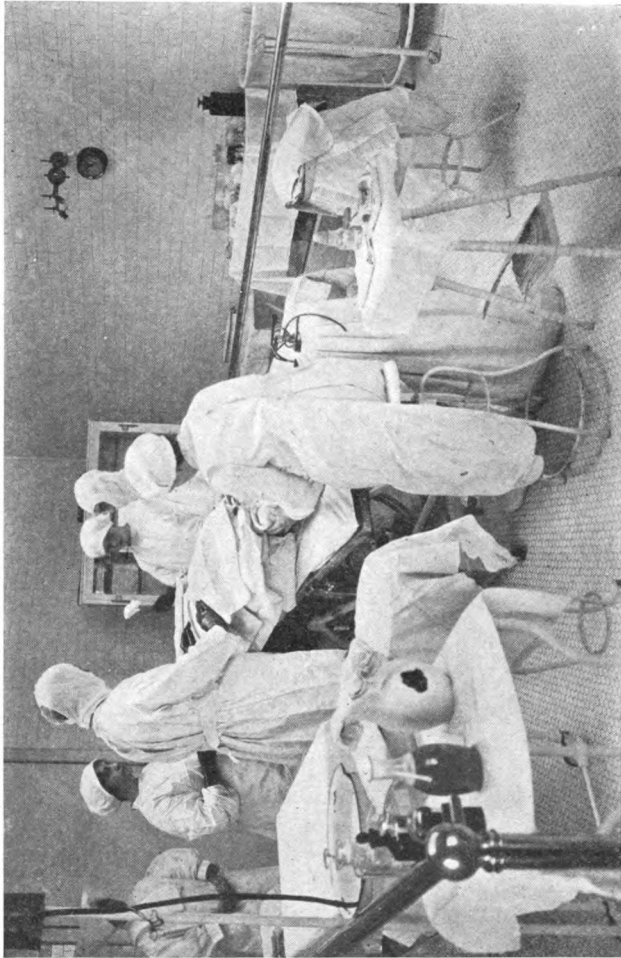


Fig. 1.—General ensemble Patient prepared for abdominal operation.

with handling instruments, ligatures, sutures, or dressings must be gowned, masked, and gloved. Such preparations

should be preliminary to any manipulation of the material to be used in the operation. The instruments, suture and ligature material, the dressings, gowns, and all the paraphernalia for the operation should be carefully protected from exposure until needed.

Consideration must be given to every step of the procedure, and the effect of any misstep appreciated. The better prepared the operator, the more accurately he has planned the procedure, the greater the efficiency of his staff, the better will be his ultimate results (Fig. 1).

### THE INCISION

The treatment of the great majority of visceral conditions within the abdomen demands an incision. The situation of the incision will depend upon the particular structure involved. An incision for drainage may be made directly over the position of an abscess, whether it arises from a suppurating appendix, gall-bladder, or from a local infection, as in cellulitis. The most frequent incisions will be limited to the median line, above or below the umbilicus. In pelvic surgery, either the median or the transverse, known as the Pfannenstiel, will afford ready access to the affected viscera. If the appendix is the sole cause of the procedure, and especially if it has been the seat of recent inflammation, a right-sided incision over the semilunaris muscle, or by splitting the abdominal muscles, is generally preferred, although the appendix is readily reached through a median opening.

**Instruments.**—See Fig. 2.

Chromic and plain catgut, assorted sizes, sterile sheets, towels, and gowns.

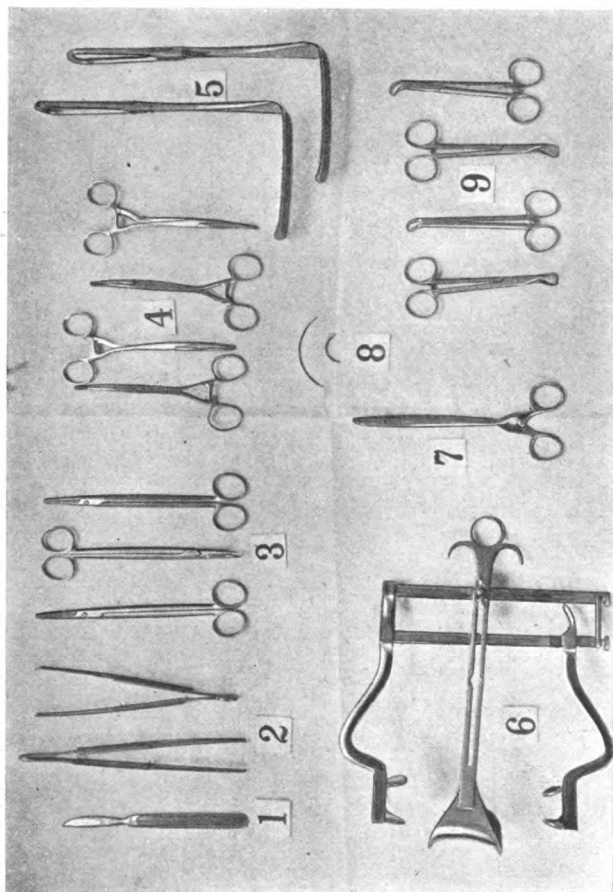


Fig. 2.—Instruments for abdominal incision: 1, Scalpel; 2, tissue forceps; 3, scissors, straight and curved; 4, hemostatic forceps; 5, retractors; 6, retractor, self-retaining; 7, needle-holder; 8, needles; 9, towel clips.

The above-named instruments are for the mere incision. A more extended list will be named in the individual operations.

The **median incision** is one in the median line below the umbilicus. The operator stands to the patient's left, with his assistant to her right. The cleft of the vulva and the umbilicus are landmarks for the incision. With the thumb and index-finger of the left hand he makes the tissues tense,

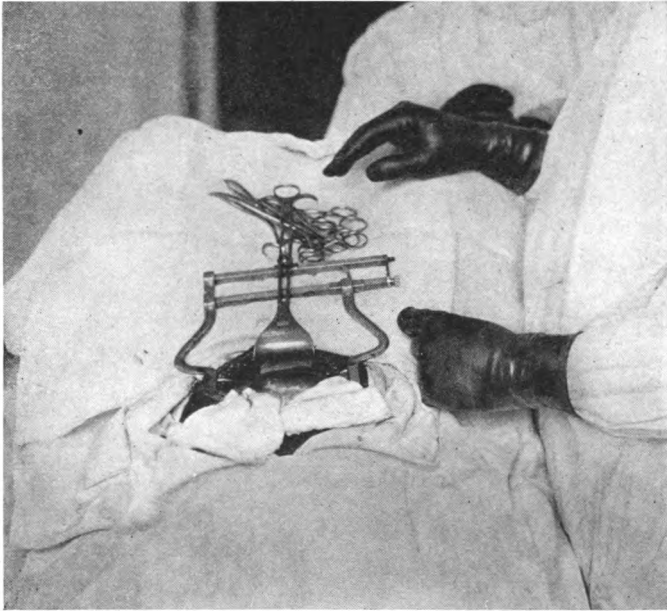


Fig. 3.—Median incision. Combination retractor in place. Intestines walled back with gauze.

while, with the scalpel in the right, the incision is carried through the skin and superficial fascia in the first upward sweep of the knife; the second sweep divides the aponeurosis, and if over the rectus muscle the latter is separated from its fellow, and by holding up the tissues with the left hand the



deep fascia and the peritoneum can be opened without danger to the subjacent coils of intestine. As soon as the peritoneum is opened the intern and surgeon each insert a finger, incise the peritoneum the length of the wound, and, if desirable, extend the latter. The nurse hands a long folded gauze pack, by which the surgeon walls back the intestines, exposing the pelvic viscera. The median incision is em-

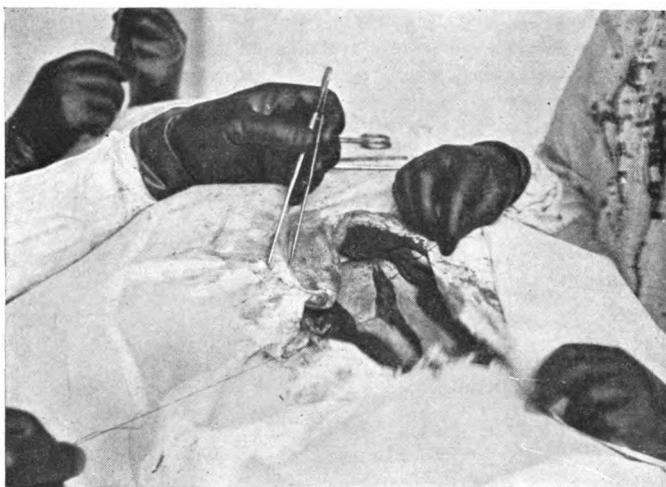


Fig. 4.—Wound in process of suture. Peritoneum closed. Aponeurosis being sutured.

ployed for the investigation of the abdominal contents when the condition is so obscure that pathologic lesions cannot otherwise be determined (Fig. 3). Such operations should be rare. It is also employed in the treatment of inflammatory conditions of the pelvis, for the removal of fibroid growths, for the extirpation of the uterus for cancer, and the excision of ovarian growths.

**Pfannenstiel Incision.**—This incision can be employed for the removal of small fibroids, cancer of the body of the uterus, to shorten the ligaments, separate adhesions, remove the appendix, and for other local conditions when suppuration and active infection are not present. The large amount of connective tissue opened, which can be protected

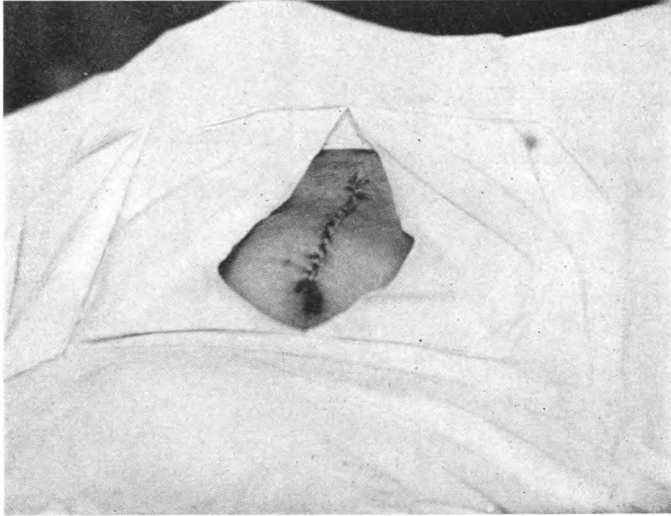


Fig. 5.—Wound closed.

with difficulty, makes its employment undesirable in suppuration and acute infections (Fig. 6).

The operator, with scalpel in left hand, the abdomen made tense by pressing its surface upward, with the right makes a slight curved incision convex upward across the lower part of the abdomen, cutting through the skin, superficial fascia, and aponeurosis to the muscle. As the aponeurosis is

opened, two fingers of the right hand are inserted, drawing toward the umbilicus, while the incision through the fascia is completed. Usually the apices of the pyramidalis muscles are firmly attached to the under side of the fascia and should be cut, which permits the necessary exposure of the recti muscles. Two fingers are pressed against them and the tissues lifted up, when the peritoneum can be opened verti-

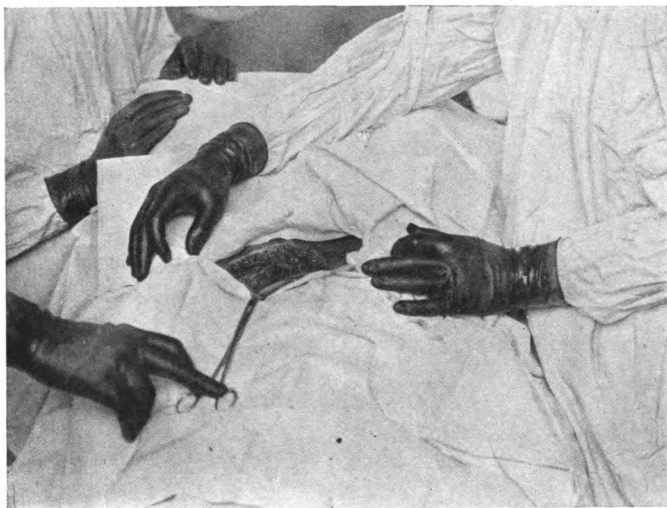

Fig. 6.—Pfannenstiel incision.

cally. The intern and surgeon each inserting a finger, the peritoneum is cut the length of the wound. The structures thus lifted up, the peritoneum can be opened without danger to the intestines without the need of forceps. The intestines are packed back with gauze. The packing should be with a piece of folded gauze of good length, so that there will be no possibility of it being overlooked when the operation is com-

pleted. The nurse in charge of the gauze should know just how many pieces have been issued, and see that they have

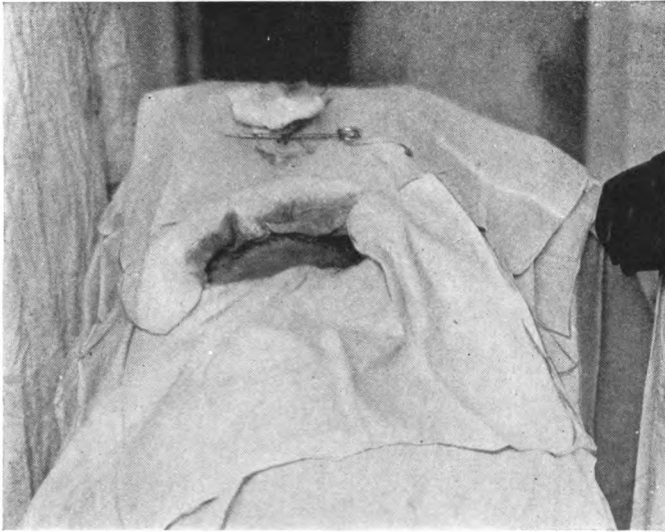


Fig. 7.—Wound closed.

been counted before the wound is closed (Fig. 7). No gauze should be placed in or left in the abdomen except by the operator himself.

#### CLOSURE OF THE WOUND

In order to avoid repetition, the closure of the wound and the detail of after-treatment will be considered at once for all procedures. The intra-abdominal manipulation having been completed, and gauze pads and instruments all accounted for, the final step in the procedure, the closing of the wound, is in order. The skin surface should be wiped dry and clean towels placed about the wound, especially

where there has been soiling of the surface with discharges from the cavity during the course of the operation. The edges of the peritoneum may be seized with hemostats and thus made more readily accessible. The nurse hands the surgeon a long curved needle threaded with a No. 1 chromic catgut suture, with which he begins at the upper angle of the wound and picks up the peritoneum of each side, passes a suture, ties with three turns of the gut, and cuts one end of the suture short; then proceeds to use the suture, continuously closing the peritoneum, so opposing its inner surface that no raw edge is inverted to come in contact with intestine or omentum and thus afford opportunity for the occurrence of adhesions. Three ties are made with catgut at its completion at the lower end of the wound. This precaution is necessary to ensure against the knot slipping and becoming untied, which would prove disastrous in a wound closed with continuous suture. The wound is wiped dry and all bleeding vessels secured. The nurse now hands a round-pointed needle threaded with No. 1 chromic catgut, with which one or more sutures are taken in the recti muscles to ensure their being held in contact. A cutting-edged needle here might injure a vessel, which would cause an accumulation of blood beneath the muscle, or the subsequent united aponeurosis affording a collection which if infected endangers the future healing and resistance of the wound. With the same sized chromic catgut, but with a long curved cutting-edged needle, the surgeon picks up the aponeurosis or deep fascia at one angle of the wound, ties a knot with three turns,

and with a continuous suture closes this structure through the length of the wound, keeping in mind that it is the most important resisting structure of the wall. This suture is ended with a three-tie knot. The continuous suture is objected to by many for the reasons (1) that if infection occurs it will follow the suture through the entire wound; (2) that if any portion of the suture is injured or broken the structures separate its entire length. Considering these objections valid, for a time I discontinued this method of suturing and substituted the interrupted suture, but when infection occurred the catgut was slow in being absorbed or in disintegrating, and had to be fished out before the wound would heal, and it is much easier to catch one suture than many. The suture properly secured is unlikely to break, and where ordinary precautions are preserved the instances in which such sutures are infected or break are infrequent. The many knots incident to closure by interrupted sutures are a great source of danger. In thick and fat abdominal walls it is better that the fatty or superficial fascia should be united with sutures, as the procedure obliterates dead space in which blood or liquefied fat may serve as a nidus for infection and cause discomfort as well as danger to the future welfare of the patient. These sutures should be interrupted and of plain catgut. Finally, with a No. 0 chromic catgut suture the skin edges are brought together by a continuous suture. The precaution should be exercised that strong traction is not made on this suture, as the skin is strangulated and may cause infection or even slough.

### DRAINAGE

The question of drainage is not so momentous a one as it was twenty years ago, and the cases in which it is considered necessary are comparatively infrequent. The dependent position of the pelvis makes the vagina the choice outlet for drainage in woman. Drainage through this canal has the additional advantage of not weakening the abdominal wall, so that danger of hernia is decreased. The retro-uterine incision into the vagina ensures the lowest part of the abdominal cavity being the seat of the drain, and is consequently most effective. A vent in this situation affords a further advantage, that in extensive adhesions, or where the peritoneum of the pelvis has been much injured in the operation, or by previous inflammation the contact of the intestinal coils with such raw surfaces can be prevented by packing the pelvis with iodoform gauze. One end of the gauze pack is carried into the vagina and is withdrawn through it when its purpose has been served. The best drain is the split rubber tube, which should be secured to the vaginal incision. Even where the pelvis is packed with gauze, especially where drainage is desired, the gauze should be supplemented by the employment of split rubber tubes. The gauze alone soon becomes clogged with exudate and serves as a tampon rather than a drain. The vaginal drain, with the patient in a semisitting position, favors the most effective drainage of the peritoneal cavity. The cases are now rare when drainage through the abdominal walls has to be considered for pelvic conditions. In appendiceal abscess and

inflammation in the upper abdomen it would not, of course, be considered wise to afford escape through the vagina. In general peritonitis it may be desirable to have several openings for the escape of the infectious material, for it should not be overlooked that the tendency is for the drain to be walled off as a foreign body, and its area of action consequently becomes very much diminished. The action of the drain is greatly promoted by placing the patient in a semi-sitting position with the employment of a continuous instillation of water by the rectum, known as the Murphy drip.

#### DRESSINGS

The treatment of wounds has been of late years much simplified, and it is recognized that nature will do her work well when the wound is properly protected. Care has been exercised during the operation to protect the wound surfaces from contact with infectious material, and when, as in inflammatory conditions, it has been impossible to prevent such contact, it is a good plan after closing the peritoneum with a continuous suture to paint the wound with a 3.5 per cent. solution of iodine and dry the surface before closing it. Collections of blood in the wound are prevented by ligation of bleeding vessels and the method of suturing. With the completion of the skin suturing, the wound and surrounding skin surface are sponged with a 50 per cent. solution of alcohol, and the edge of the wound painted with a 3.5 per cent. iodine solution, after which it is covered with sterilized fluff gauze and a sterile gauze and non-absorbent cotton pad is



held in place by strips of plaster or, better, by pieces of tape which are secured to plaster on either side of the abdomen and tied across the dressing. The latter method is preferable, as it affords easy access to the wound without the discomfort incident to pulling off the plaster, or the accumulation of a large quantity of the latter when it is cut at the side of the pad and new pieces covered over the cut ends. In addition to being neater in appearance and more comfortable, it has the advantage of being economic, which is a matter of importance in the work of a large hospital. The dressing is completed by the application of a well-adjusted abdominal binder, which is pinned over the covered wound. This bandage not only keeps the dressing in contact with the wound, but affords comfort and support to the patient in change of position.

#### CLINIC WORK

In the clinic of a large hospital, where the cases follow each other in rapid succession, it is important that each person be so drilled that he or she will understand what is expected at each successive step and be ready to discharge the duties promptly and without confusion. Supplies of dressings, sterile gowns, gloves, and other accessories should be accessible, but should not be uncovered and exposed in a room which is occupied by a number of attendants and observers. After each operation the table covering should be changed and the operator and assistants change their gowns and gloves. Where a number of operations are done on the same patient, especially when plastic operations are done

about the vulva and vagina, not only the operator and intern but also the nurses should change their gloves before proceeding to the abdominal section, for it stands to reason the handling of the needles and instruments by the operator and nurses will necessarily lead to the soiling of the gloves of the nurses, when to handle sutures and ligatures with these soiled gloves for the subsequent abdominal operation would be prejudicial to the good healing of the wound, even did no more serious result follow. All soiled pieces of gauze should be removed from the room before beginning operation upon another patient and the vestiges of blood should be mopped up. While there may be no danger to the succeeding patient from the blood on the floor of a former one, it is unseemly that an operating room should have the appearance of a shambles. As the gauze used in the operation must be accounted for, it is evident that it is unwise to have the count confused by some left from a former operation. Perfect order, surgical cleanliness, and conscientious consideration of the interests of the patients should characterize the course of all the participants of a clinic, whether the individuals treated therein be rich or poor.

#### CARE OF THE PATIENT DURING THE OPERATION

The room in which the operation is done should be appropriate for the purpose, well lighted and heated. The patient should be protected from drafts, and the abdominal viscera when the cavity is opened should be packed back with gauze. In a protracted operation the gauze or covering

should be moistened with warm salt solution, and this saturation should be repeated from time to time, so that there will be no opportunity for the surface to become dried or chilled from the continued exposure. The moistening of gauze packs which have been in place for some time will save the intestinal endothelium from injury. The anesthetist keeps the patient's pulse, temperature, blood-pressure, and general appearance under observation, and is prepared to institute restorative measures whenever they seem to be indicated. It is important that the danger-line should be anticipated rather than to institute restorative measures only when the patient is beginning to succumb. Strychnin, ergone or some aseptic ergot, and atropin should be at hand for use hypodermically, and in all cases where a serious condition is possible, apparatus and material for hypodermoclysis or intravenous injection should be ready. In operations on patients who are previously much enfeebled by disease, or where the operation is likely to be greatly prolonged, the condition of the patient may be favorably maintained by employing continuous hypodermoclysis during the operation. A needle beneath each breast, or inserted through the chest muscle into each axilla, connected by a Y-tube with a saline reservoir, may, under the care of a nurse and watched by the anesthetist, be stopped temporarily or allowed to continue according to the exigencies of the case. Should the vitality flag in spite of these measures, or in cases where they have not been instituted, resort should be had to intravenous injection of a saline solution, using a 1 per cent. solution of either sodium

chlorid or sodium citrate, to which may be added 1 dram of adrenal chlorid or 5 grains of caffein citrate. This procedure may be employed while the operation progresses, and  $\frac{1}{2}$  pint to 1 quart of the solution thrown in. In patients suffering from shock the amount of anesthetic should be kept at a minimum, and it is better that the patient should feel the procedure, and thus through stimulation of her nerve-centers promote reaction.

#### AFTER-CARE

The bandage having been applied to maintain the dressing in place, the patient should be covered with blankets and protected from exposure while being transported to her room. When much shocked, artificial heat should be maintained by a hot blanket, and have hot-water bottles placed about her and be kept covered. Common sense should be exercised in the use of these measures, not because the patient has undergone an operation, but because they are needed. I have seen patients on the hottest days in summer subjected to the application of hot-water bottles and other methods of maintaining heat, when heat abstraction was indicated. A patient with a pulse of good volume and bathed with perspiration calls for reduction of covering and withdrawal of artificial heat rather than its application. When heat is maintained by the application of hot-water bags and bottles, they should be watched, that the restless patient does not displace the blanket and come in contact with the hot-water receptacle. Such applications should never be made without the bag or vessel having been wrapped, or at least placed external to a blanket. The nurse

should know just where each one of them is, and should investigate from time to time to see they have not been displaced. It must be understood that the resistance of a patient in shock is much reduced, so that she would be burned from an exposure that otherwise would not affect her. Should a burn occur, the nurse should not attempt to conceal it from the physician, however willing the patient may be to co-operate in the deception. Be sure it will come to his knowledge some time, and he will thereafter fail to have any confidence in the nurse. The patient in bed, the room should be darkened, and ventilation afforded without placing her in a draft. The members of the family and all others than the necessary attendants should be requested to leave the room. Even when the patient is sleeping, with pulse and breathing good, she should not be left without skilled attention, for without warning she may have an attack of vomiting, and if without skilled attention may by inspiration draw the vomitus into the trachea, to cause a subsequent attack of pneumonia. The nurse keeps a record sheet on which she should register, in severe cases at least every four hours, the temperature, pulse, respiration, and any symptoms which may have a practical bearing on the subsequent course of the convalescence. The continuous retention of one position becomes extremely irksome to a patient who has been unaccustomed to lying in bed, and the nurse should study to make this imprisonment as endurable as possible. Much may be done for her comfort and distraction by frequently changing her position, placing a pillow beneath the limbs or under a shoulder, turning her on one side, and placing the limbs semiflexed

with a pillow between the knees, or the under limb extended while the upper one is flexed and rests on a pillow. Bathing the face, shaking up the pillow beneath the head, holding her hand, and in general showing that the nurse has sympathy for her charge and is anxious to alleviate her discomfort, has a wonderful effect in making her satisfied with the situation. Never let the patient be uncomfortable when her distress can be obviated. In some hospitals there seems to be a feeling that the patient should not have anything under her head for some hours after the operation, but this is like many other misconceptions. The patient may at once have a pillow unless she has lost so much blood as to render it desirable to keep the head low in order that the blood can enter it without increased cardiac effort. In ordinary cases to make the patient go without a pillow is an unnecessary punishment. The patient will not infrequently ask for water and more often for broken ice. The latter should be withheld, for its administration leads to dryness and cracking of the lips and tongue, when her condition is truly uncomfortable. It is better that the patient should be given hot water by the tablespoonful, and if this is well-borne and unattended by nausea or vomiting, she can have a cup of weak tea, quite hot, without milk and with but little sugar.

The nurse not only watches the heart action, the respiration, and the condition of the skin, but later the performance of other functions, as evacuation of gas by bowel and the desire to pass urine. As the bowels have been freely evacuated, the patient has taken but little water prior to the operation, and her skin has possibly acted freely during and after it, the secre-

tion of the kidneys will necessarily not be very active, and the patient may not express any desire to urinate for some hours subsequently. Ordinarily this need occasion no anxiety for the first twelve or fourteen hours unless there has been some operation affecting the bladder, making it undesirable to have the latter distended, when either a retention catheter will have been introduced or directions given that the patient shall be catheterized at frequent intervals.

#### CATHETERIZATION

As a general rule the employment of the catheter should be avoided, for even with the most careful aseptic precautions its frequent use irritates the mucosa of the urethra, causing a urethral hyperemia or subacute cystitis, and the neglect to cleanse the parts may result in a severe urethritis or cystitis which may be more aggravating than the condition for which the operation was done. The patient without previous training in the use of the bed-pan may find it difficult to pass urine while in the recumbent position. An attempt should be made by the nurse to awaken the desire by suggesting the evacuation. When the bed-pan is placed it should be warm and have some hot water in it, as the heat favors the evacuation. Running water from a faucet, hot water allowed to trickle over the vulva, or poured from one vessel to another, or quite hot water thrown against the meatus from a fountain-syringe through a medicine-dropper substituted for the nozzle are methods which may be employed to stimulate the flow. Occasionally a sensitive patient will be able to accomplish the

act if placed on the pan and left alone. The nurse must study her patient and be resourceful. Should the patient pass no urine within eighteen hours, the catheter should be introduced even though there is no discomfort. The instrument, whether rubber or glass, should be perfectly clean, and where its use is required at intervals should be kept in a bichlorid solution and rinsed in hot water before its use. The nurse should wash and disinfect her hands. The vulva should be carefully washed and the labia held apart during the introduction of the instrument so that it is not brought in contact with the labia. As it enters, the external end of the instrument is kept closed with the finger so that its introduction will not allow the urine to be discharged before the receptacle is at hand. When the bladder is emptied, the finger is placed over the catheter end as it is withdrawn to prevent the vulva being soiled by urine retained in it. The vulva should be cleansed after the completion of the procedure. Where the introduction of the catheter shows that no urine has been secreted, the action of the kidneys unless contra-indicated should be stimulated by the administration of water by the mouth, the Murphy drip, and by hypodermocleisis. The surgeon or the intern will have been notified and these measures employed at his suggestion. Hot-water bags or an electric pad over the back will often prove useful. Digitalis, caffeine, and sodium benzoate may be administered internally. Continued suppression may indicate that the entrance of urine into the bladder is blocked, as can readily occur in some operative procedures. I had the misfortune to tie and cut both ureters in the removal of the



uterus for advanced cancer. The complete failure to secrete any urine for two days demonstrated to me that it was necessary to investigate the cause. The operation had been done under spinal anesthesia, and repeating it, I opened the abdomen to find both ureters neatly tied. I released and transplanted them into the bladder, when the patient recovered and died a year later from a recurrence of the disease. I saw in consultation two patients, one of whom had a large abdominal cyst emptied by tapping, which proved to be a cyst of one kidney. She had passed no urine for sixteen days when I was called to see her, and with my approval an opening was made through the back into the remaining kidney. She recovered and lived two years, when she died after a second tapping. The other patient had had one kidney removed and passed no urine subsequently until after she had the remaining kidney opened. It was found that some loose tubercle matter from the renal pelvis had floated into and blocked the orifice of the ureter. This patient died despite the drainage. These are exceptional cases, but they demonstrate the importance of being alert for the recognition of adverse conditions.

#### NOURISHMENT

While it has been demonstrated that acetonuria is a consequence of starvation, yet there need be no anxiety about the feeding of the patient in the first twenty-four hours after operation. In the majority of cases the disturbance of the secretions, as a result of the worry, nervous shock, and administration of the anesthesia, is so great that food if taken

would be unfitted for nutrition and be a source of irritation. The patient is generally satisfied with liquids. As water composes the greater part of the tissues of the body, it is safe to begin with a tablespoonful of hot water every half-hour or hour, and if this is well borne, cold may be substituted. If addicted to tea, a cup of the latter may be given hot with a small quantity of sugar. Albumen-water, orange-juice, or grape-juice diluted with Vichy, broths, hot or cold raisin tea, or cornmeal gruel may be given during the first twenty-four hours. In uncomplicated cases the patient may have, at the end of this time, a poached egg on soft toast and a cup of coffee, and gradually assume the ordinary diet. The inclination of the patient and the condition of the digestive tract should be carefully studied and the food directed accordingly. The occurrence of nausea and vomiting or the presence of tympanites should be an indication for withdrawing food, possibly lavage, and the employment of saline or glucose solution by the rectum. It is worse than useless to administer food to a patient who is constantly vomiting, or whose stomach is distended with gas, or into which the contents of the small intestine are being regurgitated. The absorptive power of the stomach is slight, and the material only decomposes and adds to the toxemia of the patient.

While the nurse understands that she is to make the patient as comfortable as conditions will permit, she should not forget that she is on guard to watch for danger signals, the occurrence of which should be made known to her superiors, the intern and surgeon in charge. The usual symptoms which

may be of moment in the order of their occurrence are shock, nausea and vomiting, hemorrhage (external and internal), tympanites, abdominal pain and tenderness, peritonitis, and sepsis.

### SHOCK

The appearance of shock is favored by prolonged operation, the exposure of the contents of the peritoneal cavity to evaporation of its moisture or to being chilled, to the administration often of an unnecessary amount of anesthetic, to traction on the viscera, and to extensive tearing up of peritoneal structures. The susceptibility to shock varies in different individuals. One may be shocked without any apparent cause, while another will go through a most severe operation without any such manifestation. The aim in treatment should be prophylactic. The bodily heat should be maintained; the amount of anesthetic be limited to the lowest amount compatible with the performance of the operation; the intestines should be protected from chilling and evaporation; and, where the operation is likely to be prolonged or the condition of the patient enfeebled, shock should be anticipated by the employment of continuous hypodermoclysis, the early administration of strychnin, atropin, or ergone hypodermically, and if necessary the intravenous injection of a solution of sodium chlorid or sodium citrate. These procedures may be employed during or following the operation, according to the exigencies of the case, and subsequently demand a careful and competent anesthetist who can give warning of danger, the need of stimulation, and the character and quantity required.

Shock is indicated by increased frequency and diminished volume of the pulse, the latter frequently being imperceptible at the radius. The face and lips become pale and bloodless, the skin is covered with a perspiration which from the evaporation and diminished heat formation causes the surface to be cold and clammy. The pupils are dilated, and if the patient is conscious complains of faintness, of inability to see, and is quite restless, rolling her head from side to side. The occurrence of nausea preceding an attack of vomiting will not infrequently cause the pulse to become feeble and for a time even imperceptible, but it comes on rather suddenly and is not accompanied by the other symptoms mentioned. Shock occurs during an operation or immediately following it, and under rest, stimulation, promotion of bodily heat, the patient recovers. The baneful effects of shock may be obviated and overcome by the position of the patient—elevating the foot of the bed so that the blood shall have easy access to the brain without undue heart action. In profound shock the extremities should be bandaged as far as the trunk, so that the quantity of blood for the vital centers—the brain, heart, and lungs—should be greater while the tissues can wait. Measures to combat shock should be instituted promptly. As water composes the greater portion of the body, it should be introduced promptly and its quantity effectively maintained. This may be accomplished by continuous rectal instillation, hypodermoclysis, or intravenous injection. The bodily heat must be maintained by artificial measures, as hot blankets, hot-water bags or bottles, or electric pads. Where hot water

is employed, care should be exercised that the receptacles are accurately stoppered, that they are securely wrapped, and brought directly in contact with the skin surface. Marked restlessness and continued uneasiness of a patient who is semiconscious should be an indication for investigating carefully the condition of the receptacles, for a severe burn is easily made under such circumstances, and the injury always seems an unforgivable offense to the patient and her friends. The successful treatment of shock often demands the best therapeutic judgment to assure that the right drug and in proper quantity is given. Vital forces are enfeebled and sleeping nerve action must be awakened. Depressing measures must be discontinued, as it is better that the patient feel some pain than that the anesthetic should be maintained. If ether or chloroform has been given, oxygen should be substituted; sweating and leakage of the skin should be obviated by the administration of atropin,  $\frac{1}{150}$  to  $\frac{1}{100}$  grain; flagging of the pulse, a pinched expression of the face should be combated by strychnin sulphate,  $\frac{1}{30}$  to  $\frac{1}{12}$  grain hypodermically. Hypodermoclysis of a 1 per cent. sodium chlorid or sodium citrate solution at a temperature of  $105^{\circ}$  F. into the loose tissue beneath the breasts, in the axillary spaces, or in the buttocks is valuable. The utmost asepsis must be employed in its administration, for the introduction of infection but adds to the danger. When the pulsation in the extremities fails, the blood-pressure is subnormal, the pupils are dilating, no time should be lost in the **intravenous administration of a saline solution.**

**Instruments.**—See Fig. 8.

The arm of the patient from the hand to the axilla should be washed with gasoline and then painted with a 3½ per cent.

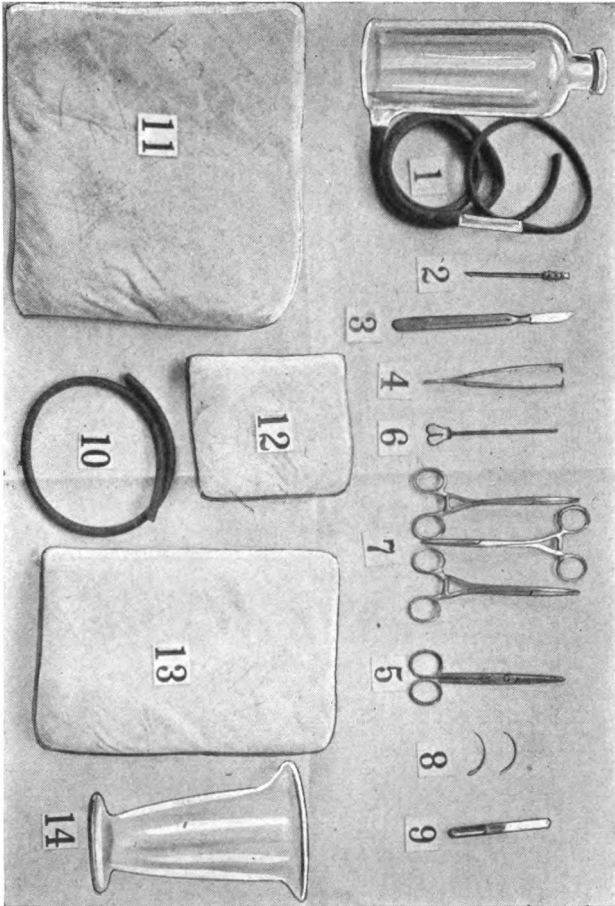


Fig 8—Instruments for intravenous injection of salt solution. 1. Graduated glass bottle with rubber tube attached; 2. canula blunt, 3. scalpel, 4. tissue forceps (toothed), 5. scissors; 6. grooved director, 7. hemostatic forceps, 8. needles, 9. chromic catgut No. 0, 10. rubber tube to compress the arm; 11. package of sterile gauze, 12. package of gauze sponges, 13. sterile towels, 14. graduate glass.

solution of iodine. A rubber tube is placed around the upper arm to control the return of blood by the veins, and the median

basilic or cephalic vein, according to its size, should be exposed by an incision. The vein is separated from its fascia, a grooved director passed beneath it, a ligature tied on the distal end, the rubber tube about the arm removed, a second ligature thrown about the proximal side of the vessel, the front of the vein picked up with forceps and a transverse cut made into it through which the canula is connected with the receptacle, and with the solution at the temperature of 102° F. running, is introduced, and ligature previously placed about it, tied with one turn of the ligature. The fluid, a 1 per cent. salt solution to which may be added adrenalin chlorid solution, 1 fluidram (1:1000), or caffein citrate, 4 grains, is allowed to run into the vein slowly, taking care that the heart shall not be flooded, until a quart of the solution has been introduced. The canula should be withdrawn by the intern, while the surgeon ties the knot to prevent any bleeding and closes the wound with sutures. It is just as well before closing to cut the vein across between the sutures, as it removes unpleasant traction, and with ligatures on the vessel the intermediate portion is of no value. The wound should be washed with alcohol, dried with sterile gauze, brushed with an iodine solution, and a dressing of sterile gauze applied, secured by a sterile bandage.

**Hypodermoclysis.**—The injection of salt solution beneath the skin is practised to sustain the strength of the patient, prevent shock, and promote elimination. As has been mentioned, it is often employed where the condition of the patient is bad and an operation is likely to be prolonged. The surgeon should be provided with a graduate glass with a nipple

opening at the bottom to which a tube can be attached, and through a needle at the tube end plunged into the loose cellular tissue the fluid can be transmitted. It is better to have a **Y** in the tube to which two tubes with needles affixed can be secured, and thus the fluid introduced under both breasts or into both axillæ at the same time. During an operation the amount of the flow and quantity to be introduced can be under the direction of the anesthetist. The apparatus and the fluid employed as well as the skin through which the punctures are made should all be aseptic. Failure to exercise these precautions will be likely to result in infection and suppuration.

The intravenous injection, or repeated hypodermoclysis, may be followed and supplemented if demanded by the continuous Murphy drip. The patient must be kept quiet. The administration of morphin in small doses,  $\frac{1}{16}$  to  $\frac{1}{12}$  grain, at intervals of three to four hours will act as a stimulant and relieve the nerve irritation.

### NAUSEA AND VOMITING

Nausea is very common after abdominal operations, whether with general or local anesthesia. The reflex effect of opening the abdomen and disturbing the viscera will not infrequently cause nausea and vomiting, even when the anesthesia is secured by spinal injections. It is much more constant and prolonged when a general anesthetic, as ether or chloroform, is given. Nausea and vomiting after the administration of ether is generally to be expected, and its continuance may be shortened by allowing the patient to take a



good draft of warm water or precede the water by a solution of sodium bicarbonate,  $\frac{1}{2}$  to 1 dram, in one-half glass of hot water. The patient vomits with greater ease when she has something in the stomach, and the act washes off the irritating mucus and promotes the elimination of ether. When there is reversed peristalsis, and the bile and contents of the duodenum are being regurgitated into the stomach, a Seidlitz powder may be given, dissolving the sodium bicarbonate in one-half a glass of water and dropping the tartaric acid dry on it, and if given while effervescing will often speedily quiet the nausea. It distends the stomach and a part of it passes through the pylorus. If it is vomited, it washes out the stomach, neutralizes the secretion, and leaves the patient more quiet following its use; if it is not vomited, it passes into the intestines and causes peristalsis to become normal and carries the vitiated secretions down. The accomplishment of an evacuation, whether gas or fecal, frequently relieves the patient from further discomfort. The continuation of nausea and vomiting after the first twenty-four hours should be regarded as a symptom demanding consideration, as it is frequently a premonitory indication of peritonitis and will be discussed when that complication is considered.

#### **HEMORRHAGE, EXTERNAL AND INTERNAL**

Bleeding from the uterus or vagina is recognized by the appearance of blood at the vulva and may demand careful attention. Severe hemorrhage may follow failure to secure the vessels of the cervix and vagina and should demand instant

measures for its control. The bleeding may be overcome by the introduction of gauze packing and the employment of a pad secured by a bandage externally. The elevation of the foot of the bed, making the supply to the bleeding vessels more difficult, will often be effective, but severe hemorrhage should demand ligation. I have seen extensive pelvic hematoma formed by dissection back of the blood where efforts at its control by tampons have been essayed.

Internal hemorrhage is generally a result of faulty application of ligatures to vessels during an abdominal operation. The ligation of a short thick stump may be followed by its shrinking to such an extent as to permit a vessel to retract and hemorrhage occur in the stump until the effect of the ligature is overcome, the tissue slips out of its control, and bleeding occurs unrestrained into the peritoneal cavity. That such a hemorrhage is progressing would be indicated by the appearance of a gradually weakening pulse in a patient who has been put to bed after an operation with a pulse of good volume and otherwise in good condition. The breathing will be sighing, the patient restless, rolling her head from side to side, complaining of failing vision, with delirium, dilated pupils, the skin covered with cold, clammy perspiration, the lips pale, and the extremities becoming cold, while the pulse has possibly disappeared from the wrist. These are the symptoms of shock, but the latter does not appear at such a time unless for cause, and in the great majority of cases the cause is internal hemorrhage. Such symptoms occur in cases which have not undergone operation, but in such is due also to internal hemorrhage, and

in the majority of women suffering from such symptoms the condition should be attributed to a complication of the course of an ectopic gestation sac or termination of an abnormal pregnancy by tubal abortion. The occurrence of such symptoms should lead the nurse to call for the aid of the intern or surgeon. While waiting, she should remove the pillow from beneath her head, prepare for the administration of salt solution per rectum, by hypodermoclysis, and by intravenous injection. The operating room should be prepared so that not a minute of time shall be lost when the attendant is secured. Stimulants should not be given, however, unless the operator is ready to reopen the wound. Any promotion of the activity of the circulation would endanger the driving out of a clot which has formed in the vessel when the circulation is enfeebled, and the only hope for the recovery of the patient, outside of ligation, is that the clot may so firmly plug the vessel that the regained force shall not drive it out and reproduce the bleeding. The desperate condition of a *living* patient should not deter the surgeon from resort to measures to secure the vessel and thus afford her chance for life.

Some two years ago, when operating before a section of students at Jefferson, a nurse came to the intern assisting me and said something which I did not catch about a patient who had been admitted. He gave directions to call another intern. Soon she came back, and I then told him to go, that I would complete the operation with the aid of the student assistant. When I went into the ward, after I had completed the operation, I found him practising artificial respiration on a patient

who seemed to be dead. He suspended it with the remark, "It is too late." I could not distinguish the pulse at the wrist, nor could I hear the heart beat, but imagined that I noticed a movement as if an effort at respiration. I introduced the tube of an oxygen tank into her nostril and directed that the intern should open a vein and begin an intravenous injection. Soon there was a distinct gasp, and we continued the measures, having preparations made to open the abdomen. She was wheeled into the operating room, and after hasty preparation the abdomen opened. A ruptured tube was picked up, ligated below the gestation sac, and removed, the blood hastily scooped out from the cavity, and the wound closed. The intravenous injection was continued during the operation, and at its end the patient was breathing normally and had a pulse of good volume. Barring a slight phlebitis, she recovered without difficulty and left the hospital at the end of a month in fair condition. This case has been recounted to impress the importance of not giving up a patient as hopeless so long as life can be recognized. It cannot be too strongly impressed on all parties in charge of such a patient that stimulants can only be used with safety when it is certain that the bleeding vessel is secured. Any additional force to the circulation prior to this but endangers the patient through driving out the clot.

#### TYMPANITES

The distention of the alimentary canal by gas is an indication of peritonitis or decomposition of the intestinal contents with the formation of gas and toxins. It may occur

either in the upper or lower portion of the tract, or the entire canal may seem to be affected, when the abdomen is greatly distended. It is generally accompanied by reversed peristalsis and regurgitant vomiting. The vomitus is likely to be a dark-brown material, extremely offensive, and sometimes such as to lead the observer to believe it fecal. The pressure of the distention against the diaphragm interferes with the action of the heart and lessens the ability of the patient to breathe deeply, so that oxygenation is greatly obstructed. The countenance presents evidence of toxemia, and the patient, unless timely relief is secured, will surely succumb. The administration of nourishment but adds to the distress and danger. It only increases the material to be infected and undergo decomposition, adding to the distention and toxemia. The distention may be attacked from below or above, according to its situation, or relief may be afforded by securing evacuation from both ends of the canal; by the rectal tube, or enema from below, and the use of the stomach-tube or lavage from above. In all cases where the patient is so distended, and is constantly spitting up mouthfuls of offensive material, nothing affords such quick relief and changes the appearance of the patient as the introduction of the stomach-tube. Its entrance into the stomach will often be followed by the forcible discharge of gas and a large quantity of foul-smelling material. The nurse should have ready 2 or 3 gallons of water at a temperature of 105° F. in which has been dissolved sodium bicarbonate, forming a 2 per cent., or sodium chlorid (1 per cent.) solution, and after the tube anointed with glycerin has been passed into the

stomach, the patient encouraged not to resist, and the contents of the stomach have been syphoned off, then the solution is poured in until the stomach is well distended, when it is again syphoned out; and repeated until the water returns clear. As these symptoms generally indicate peritonitis, it is better that the removal of the tube shall be followed by the administration of morphin hypodermically, beginning with  $\frac{1}{6}$  to  $\frac{1}{4}$  grain, and the patient be subsequently kept moderately under the drug in doses of  $\frac{1}{6}$  to  $\frac{1}{12}$  grain every three hours. Nothing, not even water, should be allowed to enter the stomach. The patient will be thirsty, and should be allowed to rinse her mouth with water flavored with lemon-juice. Wetting the lips with glycerin and rosewater will allay the dryness and thirst. The tissues should be supplied with the necessary water by the Murphy drip into the rectum and by hypodermoclysis. A pint of sodium chlorid or sodium citrate (1 per cent. solution) may be introduced beneath each breast twice in the twenty-four hours. When the distention affects the lower part of the abdomen, enemas frequently afford the necessary relief. An enema of soapsuds alone, or combined with turpentine or asafetida, will often cause a free discharge of gas and complete relief. An enema containing an ounce each of magnesium sulphate, water, and glycerin, hence called a triplex enema, will often be efficient. I have learned by experience to rely upon 1 ounce of alum dissolved in 1 quart of water at a temperature of 105° F., slowly injected with a gravity syringe, as an effective stimulant of peristalsis. Usually the passage of gas brings about the desired effect and the

patient is subsequently comfortable. Many surgeons place great reliance on eserin salicylate,  $\frac{1}{80}$  to  $\frac{1}{60}$  grain, every hour for three or four doses or until gas escapes per rectum, but it has always seemed to me inconsiderate to apply the whip when uncertain as to the character of the obstruction, and from personal experience, after a recent operation which was followed by tympanites, I should hesitate still more before resorting to it. I was uncomfortably distended, and after the second injection of eserin there was a large discharge of gas, but with it a state of collapse attended with profuse perspiration, in which I felt myself nearer death than I had ever previously experienced. Instances have been recorded where such injections have stimulated so violent peristalsis that in the face of obstruction the intestine has been torn and death resulted.

#### ABDOMINAL PAIN AND TENDERNESS

Pain and tenderness are natural consequences of every abdominal operation. They vary in degree in different persons and according to the character of the operation and the subsequent reaction. An ordinary uncomplicated case of a patient sane and well balanced may go through convalescence with apparently slight distress. The amount of pain will depend to some degree upon the character of closure of the wound. Under the old method of through-and-through suture the traction of the sutures on the skin was provocative of severe pain until their removal. But where the wound is closed with sutures in layers the traction on the skin is slight, and unless infection has occurred the distress is not great. Marked


pain and tenderness in such cases is indicative of some complication, as infection in the wound or within the peritoneal cavity, and in the latter may be caused by peritonitis. The patient should be encouraged to bear the discomfort of the operation without resort to anodynes, and the latter resorted to only for the relief of restlessness which proves more distressing than would the drug by which it may be overcome.

### PERITONITIS

A limited amount of peritoneal inflammation is a consequence of every abdominal operation and is necessary to the reparative process. The aim of the management must be to so conduct the treatment of the patient that this inflammatory process shall not transcend the benevolent status and become dangerous. The technic of the operation has been conducted with the purpose of limiting the introduction of infection and thus avoiding grave inflammation. The source of the infection may be faulty technic, permitting its introduction from without, or the extent of the peritoneal injury may be so extensive that the resulting adhesions will cause stasis and the transudation through the intestinal wall of microorganisms which result in development of extensive inflammation. Severe loss of blood, prolonged operation, profound anesthesia, intestinal stasis are all causes of diminished resistance which greatly favor the development of peritonitis. The presence of peritonitis is indicated by increased abdominal pain and tenderness, nausea and vomiting continuing or coming on after the first twenty-four hours subsequent to operation, rapid



breathing and frequent pulse, with an anxious appearance of the face which soon becomes pinched and worn. The abdomen is distended either in the lower or upper part, or both, according to the seat and severity of the attack. The patient lies on her back with the limbs drawn up and dreads any movement. The abdominal distention soon leads to a toxemia from the shallow breathing and consequent insufficient oxygenation, and from the absorption of the toxic products formed in the intestinal tract. Such a patient will be consequently vomiting small quantities of dark-colored, foul-smelling material, which affords no opportunity for rest and yet without relief of the distention. It is futile to attempt nourishment of such a patient, for anything introduced into the stomach is at once infected and rendered unfit for nutrition if the digestive forces were not entirely suspended by the infective process. The contractile power of the intestine is soon lost and the nutrition of the patient rapidly becomes precarious. The early practitioners treated these cases by splinting the intestines by the administration of opium or its derivatives; later, the plan was to administer saline purgatives and thus make the intestine, as Tait suggested, through free watery evacuations, serve as a drainage-tube for the peritoneal cavity. When the intestine was blocked by a twist, or through a paralysis from distention, the treatment was ineffective, resulting only in reversed peristalsis, obstinate vomiting, and rapid loss of strength. Ochsner pointed out that in cases of peritonitis the most effective treatment was to empty the tract by enemas and lavage and secure rest by the use of morphin hypoder-



mically, giving neither medication nor food by the mouth, and supplying the much-needed water for the system by the continuous instillation of salt solution, known as the Murphy drip. The efficacy of this treatment with drainage was still further facilitated by placing the patient in a half-sitting (Fowler's) position, especially when a vaginal incision and a vaginal drain had been instituted. The rest and deprivation will often establish resolution and ensure recovery. Where there is evident suppuration, and the patient the victim of suppurative peritonitis, a vaginal incision, indeed, other incisions in the most dependent portions of the abdomen as well, the insertion of a split rubber drain sutured in place, the employment of the Fowler position, and the continuous Murphy drip will promote the thorough irrigation of the peritoneal cavity, and often mean the difference between recovery and dissolution. Too great anxiety should not be exercised as to evacuation of the bowels or resort to nourishment through the stomach. Mental and physical rest, through the employment of morphin, the maintenance of the support by the salt solution drip, and the promotion of drainage by position and vents, should be regarded as the proper method of treatment. The introduction of food through the stomach should be undertaken with the greatest care and in small quantities until it has been demonstrated that the material can be safely disposed of. Not infrequently the improvement will be indicated by the discharge of a large quantity of gas and fecal matter per rectum and the gradual subsidence of the abdominal distention. Vomiting no longer occurs and suitable food is assim-

ilated when administered by the stomach. Occasionally the salt solution per rectum is not retained. Under such circumstances the instillation should be suspended, a larger dose of morphin given hypodermically, and after it has quieted the irritation the flow can be renewed, or it may be given for a series of three hours and the patient be allowed to rest an equal period. Patients may be able to take it thus intermittently, when they would not retain it without the period of rest. If the condition of the patient demands, the solution may be administered by hypodermoclysis, a pint of the solution beneath each breast, or into the loose tissues of the axilla or buttocks, twice in the twenty-four hours. In the employment of the drip or hypodermoclysis, when a drain does not exist the excretion of the urine should be watched to make sure that the balance between imbibition and excretion is maintained, for I have seen patients become quite dropsical when excretion was deficient. The result in peritonitis will depend upon the virulence of the infection and the resistance of the patient. Naturally, the prompt and judicious treatment of the case will effectually promote the resistance.

#### SEPSIS

Like peritonitis, this condition is an indication of the spread of infection. It may be local, as in the wound, or become general, when it is known as systemic, and may have no palpable localization. It is against this general distribution that all our efforts at asepsis are directed. In spite of all our precautions, some infectious microorganisms do come in con-

tact with every wound, and our study is to so do the work that no favorable soil is afforded for their cultivation and development; not only that a favorable soil may not be afforded, but that the powers of resistance of the patient may be maintained so unimpaired that she will be able to withstand the onslaught of microorganisms present. Accurate diagnosis; well-calculated operative procedures; thorough preparation; carefully instructed assistants who are prepared for every move of the surgeon so that nothing shall be left to chance; the administration of anesthesia adapted to the exigencies of the particular case, and in quantity only sufficient to meet the necessary requirements; rapid, skilful, yet well-directed operation are all factors in favoring resistance and ensuring against sepsis. Prolonged operation, deep anesthesia, and exposure of the intestines to cold and prolonged evaporation are prolific causes for the development of septic infection. The presence of sepsis is manifested by rise of temperature, quickened pulse, loss of appetite, and a sense of anxiety and discomfort. The temperature gradually rises and the variation may be marked between morning and evening. The temptation is great to combat this rise by the administration of some antifebrile agent, as one of the coal-tar preparations, but such a course is a mistake, for the rise in temperature is not only an indication of the development of the infection, but also a gage of the resistance of the individual forces to the invasion, and should not be handicapped. A careful investigation should be instituted for points of localization, so that the operator may be ready to assist by the drainage of pockets through which the infection

is being developed and disseminated. The abdominal wound should be inspected, and if very tender or swollen, or if it presents indication of a collection of blood or serum, a vent should be afforded. The possibility of such an occurrence is one of the arguments against the continuous suture for closing, as when a wound has to be reopened or a vent secured for drainage the cutting of a suture weakens the entire wound and endangers its opening. This danger, however, can be obviated by making an incision at the side of the wound and thus avoid cutting the sutures. Such trap drains afford escape for the pent-up collection and ensure rapid recovery of the wound with the least possible danger of subsequent weakness. The recovery is favored by keeping the wound covered by a moist dressing, preferably several thicknesses of gauze wet with a 2 per cent. sodium bicarbonate solution, covered with paraffin paper, and over this a hot-water bottle. This procedure promotes liquefaction of clots in hematoma and the separation of sloughs when the condition is a plain infection of the wound. The development of infection prevents disintegration and absorption of the catgut sutures, and they usually have to be pulled out before the wound will heal. In tubercular wounds the sinuses which form between the layers sometimes become lined with an adventitious membrane and refuse to heal until the wound above is split open and the tract cureted and cauterized with carbolic acid or iodine and resutured. The time spent in cleansing and cauterizing such sinuses is generally time lost, and the cure of the condition is best ensured by immediate opening and closure of the wound. Where the

examination of the wound fails to disclose any localization, a vaginal examination should be made. Not infrequently there will be some thickening between the uterus and rectum or about the uterus to indicate local exudate and infection. Here again incision and drainage will promote recovery. Not infrequently the collection will be found within the peritoneal cavity and manifests itself at some dependent portion—the pouch of Douglas—and incision and drainage result in rapid subsidence of the symptoms. Drainage is most effectively accomplished by the insertion of a split rubber tube, which should be maintained in place by a suture to the side of the vaginal incision. It may or may not be supplemented by a packing with iodoform gauze. The latter, alone, soon becomes filled with the exudate and no longer acts as a drain, but rather as a tampon. Where careful examination fails to disclose localization, the spread of the infection must be prevented by absolute rest, elimination promoted by the introduction of large quantities of water, best through the continuous instillation of salt solution per rectum, or where this is not retained, the employment of hypodermoclysis. The intestinal tract should be swept free by an occasional saline purge. Increased resistance is ensured by a carefully chosen nutritious diet and the maintenance of the forces of the patient. There are no specific remedies, so they should be chosen and prescribed for effect or to meet special indications. Efforts should be at once instituted to ascertain the cause of the infection and secure means to combat the particular organisms. Where the infection has become localized the organism may be iso-

lated and cultivated from the secretions, or in general infection the attempt should be made to make cultures from the blood. Very frequently such attempts will be unsuccessful, not because the organisms have not entered the blood, but because they attach themselves to the sides of the vessels and are not found in the general blood-current. Where a culture can be secured a vaccine can be made from it and be utilized to promote the development of immunity to the further progress and growth of the organism within the tissues of the patient. The employment of the autogenous vaccine is certainly a more scientific procedure than the use of stock vaccines and bacterins which are prepared by manufacturers and so loudly proclaimed to the profession.

#### PHLEBITIS

The occurrence of inflammation of the veins producing thrombus, and later possible embolus, is another expression of sepsis. The saphenous vein, probably most frequently the left, is the situation in which it occurs with the greatest frequency. The veins of other parts of the body may be involved, but in abdominal conditions the veins of the legs are the ones in which it generally originates. The first indication will be pain felt over the saphenous vein in the groin or in the calf of the leg. In some cases the vein will stand out like a cord and the presence of the thrombus will be apparent to the touch. With the blocking of the veins, especially the femoral and iliac, there is swelling of the foot and leg, which from its milky glossiness and its former frequent oc-

currence in the puerperium is known as "milk leg." This swelling of the leg is due to the blocking of the return circulation, and will continue for a long time subsequent to the cessation of the active inflammation or until the compensatory circulation has become established. Here, again, rest is absolutely indicated. The leg should be kept raised, covered with cotton, and bandaged with moderate pressure. An ice-bag should be kept on the affected groin and retained until the acute inflammation has subsided. Motion and manipulation of the affected parts is scrupulously avoided for fear of detaching portions of the clot, which may be carried to some more important vessel to block its caliber, instituting another thrombus. The occurrence of pulmonary thrombus is most frequently the cause of a fatal result, the cases of recovery therefrom being exceptional and very infrequent. One has no assurance with the occurrence of phlebitis as to the time of its termination and the possible result. In the majority of instances it will be limited to the vessels in which it originates, and the patient recovers with a leg which swells when it is dependent and is painful from the swelling when much walking is done. Often it will be necessary for a time to have the leg bandaged when going about or wear a rubber stocking. In the acute stage, when the leg is painful, relief may be expedited by enveloping the leg in cloths wet with a saturated solution of magnesium sulphate, covering this with paraffin paper, and supporting it with a moderately tight bandage. In the later stages massage will be beneficial in reestablishing the circulation and overcoming the tendency to swell when



dependent. Massage should not, however, be used until it is evident that the clot filling the vessel has become organized, for otherwise there would be danger of portions being separated and carried to remote points to spread the infection, and possibly be the inevitable cause of a fatal result.

### ILEUS

Obstruction of the intestines subsequent to operation is called ileus, and usually occurs some days or weeks after the procedure. The condition is the result of adhesions constricting, bending, or twisting the caliber of the gut so that nothing passes through it. The condition may be intermittent or continue until relieved by operative procedure, or the patient dies. Ileus has been described as adynamic or paralytic when due to paralysis of the muscular coats of the intestines; dynamic or hyperdynamic when it arises from tonic contraction of the muscular fibers; and mechanical when produced by muscular obstruction. It is characterized by pain, tenderness, and distention of the abdomen, nausea and vomiting, and inability to secure the passage of anything through the intestines. The vomitus is first the contents of the stomach, anything that has been administered, and the regurgitation of bile, and later the contents of the intestines above the point of obstruction. It is prone to occur when there has been a protracted operation and the intestines have been subjected to prolonged exposure and drying. Extensive adhesions broken up with more or less injury of the peritoneal surface of the intestines, wide-spread areas of infec-

tion which cannot be completely disinfected, especially when situated within the postuterine pouch, cases of marked enteroptosis, especially of the descending colon and sigmoid, may be considered as favoring its occurrence. This is particularly true when the descending colon and sigmoid are supplied with a mesentery which permits great freedom of movement. Intermittent ileus is due to a condition which causes the obstruction, and under favorable circumstances again allows the passage of the contents of the gut to pass through. The latter results not infrequently from an adhesion on the convex surface of a coil of intestine, and then the peristaltic motion of the intestines causes a twist of this fixed loop on itself closing the canal. Later a change of position, or reversed peristalsis, may undo the twist and the difficulty is apparently overcome. Such cases should be viewed with suspicion, for the patient may at any time have another attack. I have known such adhesions to be the cause of death years after the original operation. Distention of the gut from this condition leads to its softening, occasional rupture, and if not to death, to the formation of a fecal fistula. As has been previously mentioned, the character of the vomitus should be made known to the physician, for no case of ileus can be permitted to go long without relief. Lavage will often afford relief temporarily if the obstruction is not overcome by cessation of the cause of obstruction. Where it is known that there existed some condition which might cause partial or temporary obstruction the lavage may be followed by pouring into the stomach 2 ounces of magnesium sulphate dissolved in an equal quantity of

water. When this is followed by continuous vomiting of the intestinal contents without evacuation per rectum, reopening of the abdomen should not be deferred. When the condition of the patient is bad, and the adhesions are extensive and difficult to correct, the better plan of procedure is to draw out a loop of the intestine above the obstruction, open and empty it, after which a tube for drainage should be placed in each end and fastened into the wound so that the canal shall be effectually drained. After the patient has improved, a few days later, the obstruction can be released and the proper measures employed to ensure the regular passage through the intestine. Ileus may be overcome by simple release of an adherent bowel, or it may require an extensive operation, even the resection of the ileum or colon in order to secure future action. The condition of the patient may demand that a temporary expedient, such as drainage of the intestine, be employed until the vitality is sufficiently restored to permit the operation to be completed. In separating adhesions it should not be forgotten that the intestine is often so softened that it will tear like wet paper, and thus cause the soiling of the abdominal cavity with fecal material.

#### FECAL FISTULA

Fistulous openings of the intestine through the abdominal wall or into the vagina are complications which sometimes occur after abdominal operations, and may be caused by previous openings in the intestine, through which pus had drained, or weakened places in the wall from injuries during the opera-

tion. As has been seen, such openings may follow ileus and be engendered through softening and rupture of the bowel. A fecal fistula is not infrequently suspected when there is a foul-smelling discharge from an infected wound, especially where the intestine has been wounded, or a previous fistulous opening existed through which there has been drainage into the bowel from a suppurating sac. A collection of blood or serum beneath the muscle infected with the colon bacillus affords a discharge which will have the odor of the contents of the bowel, and with the flakes of blood and sloughing membrane readily leads to an incorrect diagnosis of fecal fistula. The occurrence of a fistula should not be considered an indication for hasty action, as unless there is a flexion and such obstruction of the intestine as to make the passage of its contents difficult, the fistula will close without operative interference. When it is evident that interference will be necessary to ensure relief from the offensive soiling of the person, the abdomen should be opened, the intestine set free from its adhesions, and if constricted the contracted portion should be excised and an anastomosis performed. Under no circumstances should an attempt be made to close an enteric fistula, whether abdominal or vaginal, without exposing the constricted intestine. The fact that the fistula has not healed is evidence that the fecal contents have difficulty in passing the obstruction, and indicates the necessity for opening the abdomen to set free the imprisoned structures.

## ABDOMINAL AND PELVIC OPERATIONS

### SHORTENING THE ROUND LIGAMENTS

**Instruments.**—See Fig. 9.

This operation generally involves the round ligaments, although the broad ligaments and uterosacral ligaments may be subjected to shortening. The term here will be confined to the round ligaments, and the procedure to the one known as the Montgomery modification of the Gilliam operation. The abdomen is opened by either the median or Pfannenstiël incision, and after the packing back of the intestines and the separation of the wound with the self-retaining retractor the ligaments are under view (Fig. 10). The operator picks up the round ligament with tissue forceps about  $1\frac{1}{4}$  inches from the uterine cornu, and with a needle threaded with No. 1 chromic catgut passes a suture beneath it. The two ends of this suture, about 6 inches long, are grasped with a hemostat by the intern and dropped. The operator passes a ligature under the other ligament and threads its two ends into the eye of the modified Deschamp needle, which the nurse has handed him, grasps the round ligament with a hemostat just external to the insertion of the ligature, which is handed to the intern to hold tense, while the operator with tissue forceps picks up the anterior fold of peritoneum in front of the round

ligament, cuts a small opening in it, through which he carries the Deschamp needle threaded with the two ends of the tem-

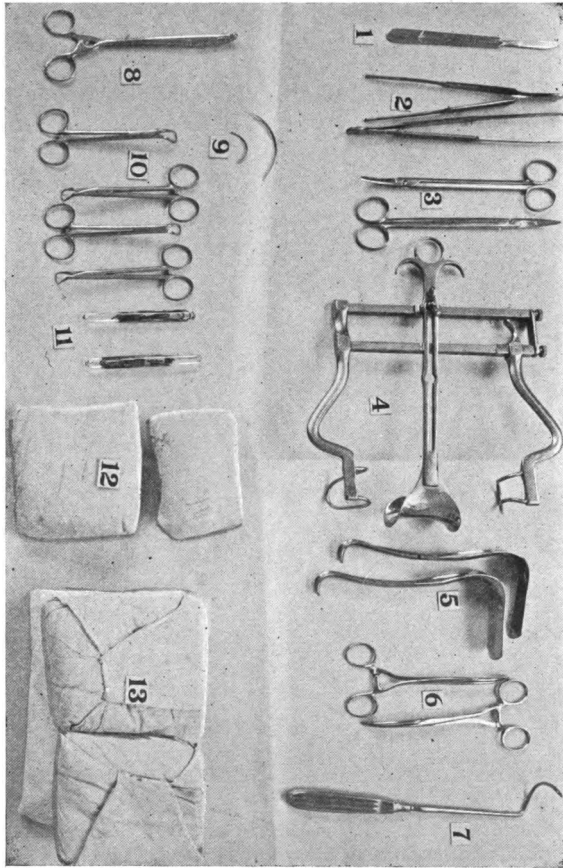


Fig. 9.—Instruments for shortening the round ligaments: 1, Scalpel; 2, tissue forceps (3); 3, scissors (curved and straight, latter pointed); 4, combined retractor (self-retaining); 5, long blade retractors (2); 6, hemostatic forceps (6); 7, Montgomery's modification of Deschamp's pedicle needle; 8, needle-holder; 9, needles (short and long, 2 each); 10, towel clips (4); 11, tubes of chromic catgut, Nos. 0, 1; 12, sterile gauze (packs and pads); 13, sterile gowns, sheets, and towels.

porary ligature outwardly beneath the round ligament until its point reaches the position of emergence of the ligament, when he drives the instrument through the abdominal wall,

bringing it out upon the aponeurosis, at the same time holding back the skin and superficial fascia (Fig. 11). The intern removes the forceps from the round ligament and places them

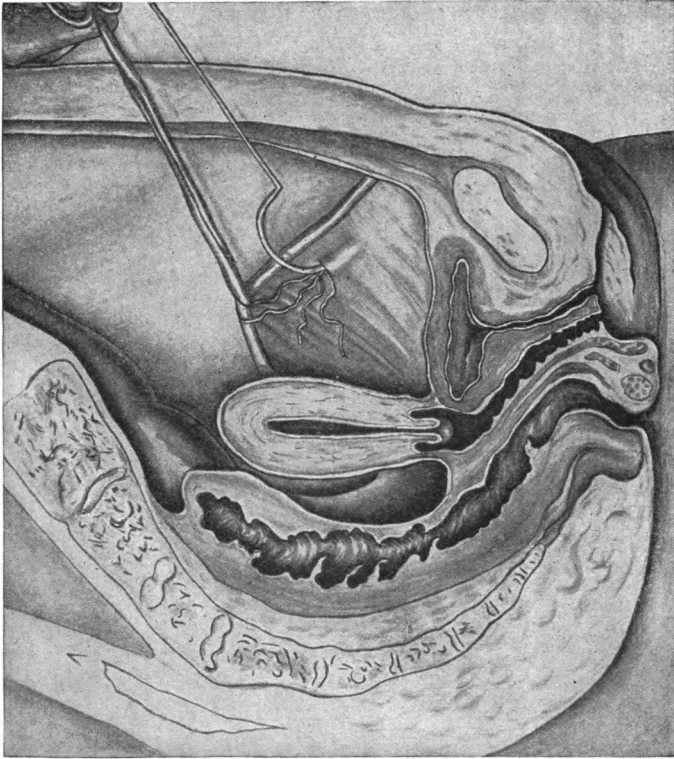


Fig. 10.—Montgomery's method of shortening the round ligaments. Round ligament fixed with hemostat while temporary ligature is carried beneath anterior leaflet of broad ligament with a Deschamp needle. (Montgomery, "Practical Gynecology.")

on the ends of the temporary suture as soon as it has been unthreaded from the needle. The intern takes the forceps from the suture and applies them to the round ligament,

while the operator threads the needle and then opens the broad ligament, and carries the suture through the tissues as described for the first ligament. The last ligature thus

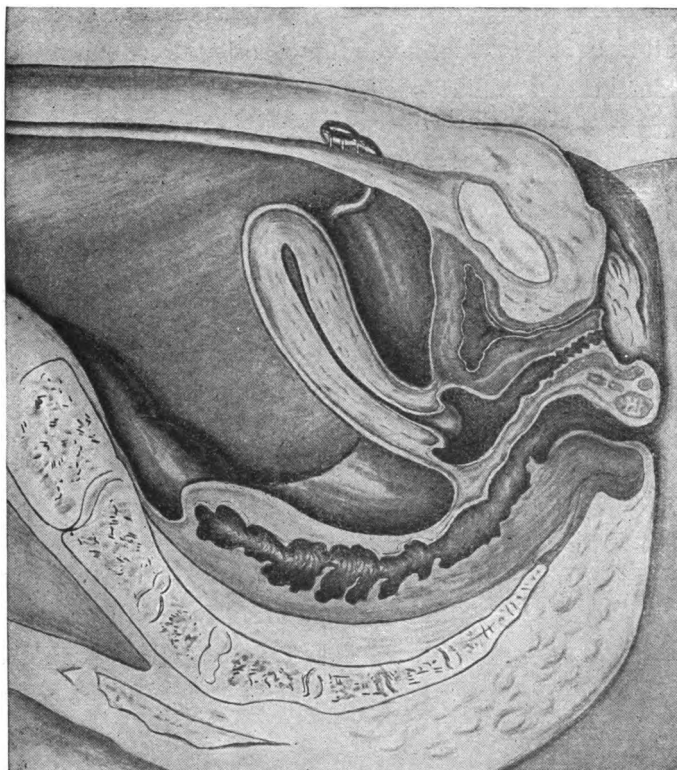


Fig. 11.—Montgomery's method of shortening the round ligaments. Loop secured on the aponeurosis. (Montgomery, "Practical Gynecology.")

brought through is grasped by the operator and drawn tense. The intern pushes back the skin and superficial fascia, while the operator inserts a sharp-pointed scissors along the suture



and, slightly separating the points, opens the fascia so that the loop of round ligament is easily drawn through. The superficial fascia is pushed back, exposing the glistening surface of the aponeurosis, to which the ligament loop is fastened by a suture on either side, each suture taking up the distal and proximal ends of the loop. These sutures tied, the temporary suture is withdrawn, and the ligature of the other side is similarly treated. All packing is now removed, and the nurse asked to make known whether all gauze packs or sponges are in sight. The pelvis carefully inspected, the appendix may be brought up, inspected, and if deemed desirable, removed. (In the great majority of cases its removal is wise.) If it is to be removed, the operator passes one blade of a hemostat beneath its base, clamps it, and hands this to the intern, while he grasps the meso-appendix with another, and then cuts through the latter between the forceps and the appendix. A ligature of chromic catgut is tied about this below the forceps, which the intern is directed to loosen slowly, and the knotting is completed. A ligature is thrown around the base of the appendix below the forceps, which the intern removes and applies higher up. The ligature is tied firmly and the appendix cut across, leaving a ligated stump. The appendix and infected scissors are taken away. The stump is carbolized, the superfluous acid removed with a gauze pad, and then with a round-pointed needle the peritoneum above the stump is picked up by a purse-string suture, into which the stump is pushed and the ligature tied, shutting it off from the peritoneal cavity. During this procedure gauze is kept about the appendix, the

forceps grasp it just above where it is cut off, and the stump is immediately squeezed with a gauze pad, accomplishing the operation without any danger of infection. Through the abdominal incision the gall-bladder and the epigastric region may be explored with the hand.

### SALPINGECTOMY—SALPINGO-OÖPHORECTOMY

**Instruments.**—See Fig. 12.

The median incision should only be employed for two reasons: First, the presence of infection may render the transverse incision difficult to protect from contact with the affected tissue or hands. Second, the exigencies of the procedure may require more room for manipulation than can be secured with the transverse incision with proper regard for the future of the patient.

The intestines and the general cavity must be carefully walled off, and this may have to be done before the separation of the intestines and omentum, for these structures may serve to form part of the wall of the abscess collection. Gauze pads should be applied beneath the retractor on either side to protect the abdominal incision from the infective material. In recent inflammation the coils of intestine and the omentum may be sponged away from the bladder, tubes, ovaries, and uterus, but in old cases the aid of scissors may be required to complete the separation. Adhesive bands should be cut with scissors, and with care not to injure intestines. The section of the bands affords an opportunity to reach less firm adhesions which can be readily separated

with the finger or the point of closed blunt scissors. As the structures are separated they are walled back. The fun-




Fig. 12.—Instruments and preparations for tubal operations: 1, Scalpel; 2, tissue forceps (toothed); 3, scissors (straight and curved, points blunt); 4, retractor (self-retaining); 5, long-bladed retractors (2); (6) hemostatic forceps (12); 7, needle-holder; 8, curved needles (long and short, 3 each); 9, intestinal needles (straight and curved, 2 each); 10, double tenacula (2); 11, fixation forceps (2); 12, intestinal clamps (2); 13, long forceps for sponge-holders; 14, tubes of chromic catgut, Nos. 0, 1, 2; 15, sterile silk for intestinal suture; 16, sterile gauze (iodoform packs and pads for sponges); 17, towel clips (4); 18, sterile gowns, sheets, and sponges.

dus reached, the fingers should hug it closely, and thus secure a line of cleavage which will permit separation, and after-

ward permit the posterior surface of the broad ligament to be followed, setting free the infected tubes and ovaries. By pressing the uterus downward and drawing upward upon the intestines, bands of adhesions may be cut without injury to the viscera. Pus, blood, and inflammatory exudate should be kept wiped away as the operation proceeds, so that infection shall not be distributed through the abdomen. Not infrequently openings will be found in the intestine through which drainage has taken place. Even where no such discharge has occurred, careful inspection should be made to see that no softened points exist where perforation was about to occur. Openings in the intestine should be pared and closed at once. The opening should be raised up, its edges pared or freshened with curved scissors, and then sutured with a round-pointed curved needle threaded with sterile silk, and the intestine folded over this line of suture with a fine chromic catgut suture. Where the ovaries and tubes are broken down with infection, they should be removed, but an ovary or part of one should always be retained if possible to maintain the balance of internal secretions. Ragged omentum should be tied and the ends cut off. The intestine must be carefully inspected for injuries and also to ensure separation of the coils, so that subsequent obstruction may not occur. Where the intestine is severely injured, has been the seat of extensive inflammatory thickening, so that its permeability is threatened, it may be wise to resect it. Last year I had a patient in the ward who had some years previously undergone an abdominal operation, and as a

result came into the house suffering from obstruction. The abdomen opened disclosed a knuckle of small intestine coiled about a section of the descending colon so that its caliber was completely closed. I was able to separate the intestines so that the canal was no longer obstructed, but the descending colon formed so large a loop, loosely attached, with a mesocolon so long as to permit a volvulus to recur readily, that I decided to remove the redundant portion. It was separated from its mesocolon and about 18 inches of the intestine removed. The procedure was as follows: The amount of intestine was estimated by bringing the surfaces together, showing the amount that could be spared. Intestinal clamps were applied at these points, and after the mesocolon had been tied and severed in sections between the points, the intestine was divided between forceps, the surrounding surfaces previously protected with gauze pads. The peritoneum of the cut ends retracting, the muscle and mucous membrane were tied, closing the open end, carbolized, and after squeezing off the superfluous acid the peritoneum was sutured over the end. The ends of the intestine were then overlapped and a lateral anastomosis done. With a fine chromic catgut (No. 0) suture the surfaces were united for a distance of 6 cm., then, having pushed their contents back, clamp forceps were applied and the surfaces carefully protected with gauze pads, each portion of the intestine opened the length of the suture, and the raw edges of the adjacent portions sutured with a continuous silk suture. This was continued around the remaining edges of the opening, and when the

intestinal communication was complete the catgut suture was resumed, completing the external row of suturing. The clamps were removed and the patency of the communication determined, the cavity carefully examined, and all foreign bodies removed.

The removal of the tube alone is *salpingectomy*. The removal of tube and ovary is *salpingo-oöphorectomy*. The ligation of the pedicle in the latter operation, where the broad ligament is infected and filled with exudate, may be attended with some difficulty as the broad ligament is shortened and held down. Sometimes it is better to incise the peritoneum and draw out the infected tube from its sheath. The assistant must be ready with a hemostat to seize any bleeding vessels. The application of a ligature is difficult and is likely to cut out. The better plan is to suture the surfaces with a continuous suture of catgut which should not be drawn so tight as to cut through. In cases of extensive pelvic infection there is quite frequently extensive oozing and the possibility that collections may form to become infected from the surrounding tissue, or from its relation to the coils of intestine, so that it is preferable that vaginal drainage shall be employed. A split rubber drain may be carried through the pelvis into the vagina, and when the pelvic peritoneum is much broken it may be supplemented by gauze packing, one end of which is carried into the vagina. The gauze thus used keeps the intestines from coming in contact with the injured surfaces until the peritoneum has had opportunity to re-form. It is wise to employ

such drainage when the intestine has been injured and sutured, especially where there has been a previous drainage into the intestine, for the intestinal wall in such instances is not very resisting and may break down. If no vent has been provided, the pelvis is infected by the drainage of fecal matter, which, if nothing worse occurs, will make its exit through the abdominal wound, infecting its full length.

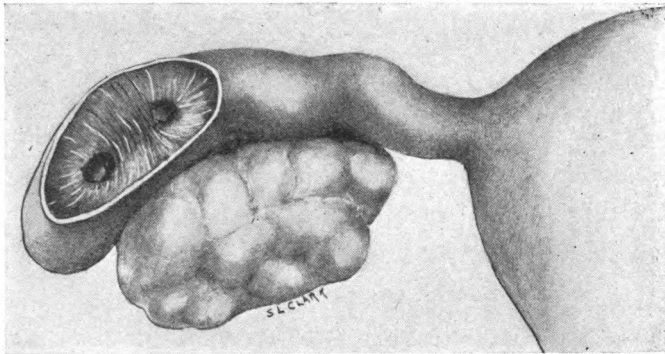


Fig. 13.—Salpingostomy.

The rule of surgical procedure should be to remove structures which are in so diseased a condition as to ensure continual infection where retained, but in chronic conditions where infective processes have subsided and result in closure of the abdominal end of the tube, it should not be sacrificed, but should be opened. Unless the fimbria can be set free by separating adhesions about the abdominal end of the tube, a fistula should be formed by a longitudinal incision on its convex border. The circular fibers hold open the incision

and evert its mucosa. This procedure is known as *salpingostomy* (Fig. 13).

### OVARIOTOMY

This is the term employed for the removal of tumors of the ovary (Fig. 14).

For **instruments** and **preparations**, see Fig. 15.

These tumors may attain to a very large size, may be single or multiple; the contents may be thin, or thick and viscid,

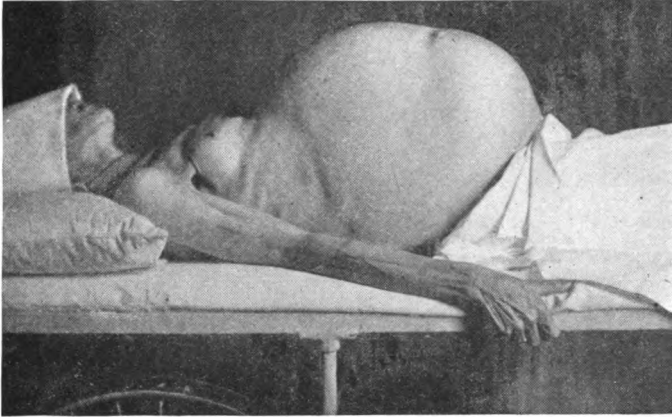


Fig. 14.—Woman with large ovarian cyst.

with fatty matter, teeth, hair, and bones. The growths may be benign or malignant. Unless the tumor is of enormous size it is better to make the incision large enough that the sac can be turned out without being opened. This is particularly true in the dermoid growths, in which the contents



are frequently fatty acids, so irritating that contact of the

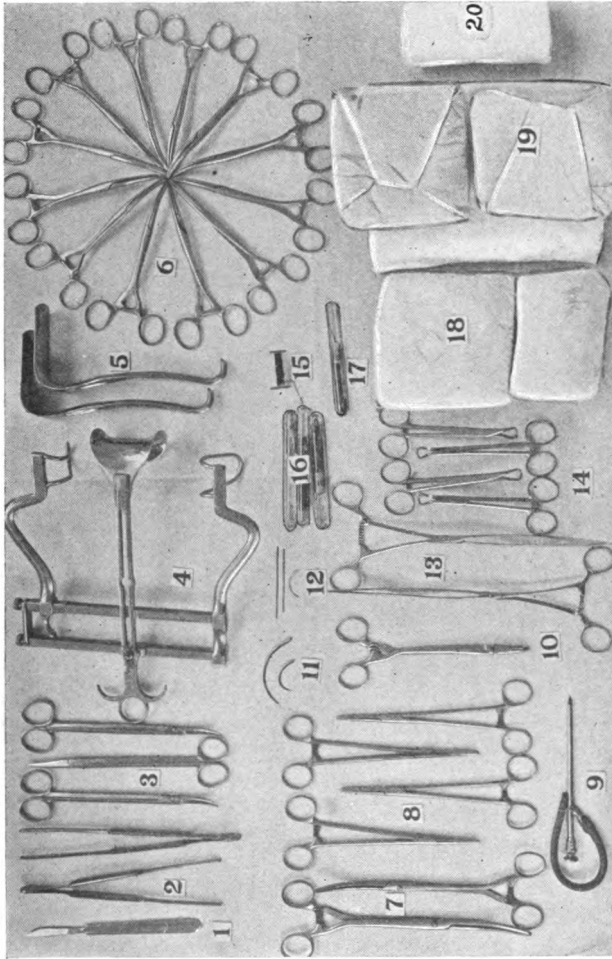


Fig. 15.—Instruments and preparations for ovariectomy: 1, Scalpel; 2, tissue forceps (toothed); 3, scissors (3); 4, combined retractor (self-retaining); 5, long retractors (2); 6, hemostatic forceps (12); 7, pedicle forceps (2); 8, Ochsner forceps (4); 9, ovariectomy trocar and canula; 10, needle-holder; 11, long and short curved needles (3 each); 12, intestinal needles (straight and curved, 2 each); 13, intestinal clamps (2); 14, towel clips (4); 15, sterile silk; 16, chromic catgut, Nos. 0, 1, 2; 17, plain catgut, No. 1; 18, sterile gauze, packs, and sponges; 19, sterile gowns, sheets, and towels; 20, iodoform gauze.

fluid with the peritoneum is sure to set up inflammation and be followed by peritonitis. In malignant growths, the soiling

of the peritoneum with the contents may be followed with secondary implantation and the recurrence of the disease. In a unilocular cyst a short incision may be succeeded by puncture and evacuation of the cyst and the withdrawal of its sac through a small opening. The intern should be directed to place his hands on either side of the upper abdomen and press the sac of the tumor into the incision, and under no circumstances to let up on the pressure. The operator with a knife punctures the cyst, when with cyst or Ochsner forceps he seizes its edges at the puncture and draws it out. The sac thus forms its own funnel and the soiling of the cavity is prevented. When the tumor is removed unopened, it should be held by the intern and not be allowed to drag on its pedicle; the latter should be clamped with large and strong forceps and be cut between the forceps and the tumor (Fig. 16). As the tumor is withdrawn, adhesions of the intestines must not be overlooked. These adhesions when recent are easily separated, but old adhesions may be so firm as to require the employment of scissors to separate them. They may be so intimate as to require a portion of the cyst wall to be removed with them to save the intestine from injury. The secreting surface should be removed from all such portions. The tumor may not always have a pedicle and may have to be enucleated. The tumor may be intraligamentary, and in its development spread out the broad ligament, causing the ureter to lie over a portion of its surface. The situation of the ureter should be determined in all intraligamentary growths. Such a tumor may have so

spread out the uterus upon its surface as to require the removal of the organ to secure the extirpation of the growth. In the removal of the unopened tumor I would advise that a pair of forceps be applied to its pedicle. This is tied with chromic catgut. The operator, having such a suture threaded in a needle, passes it through the pedicle and ties it in two

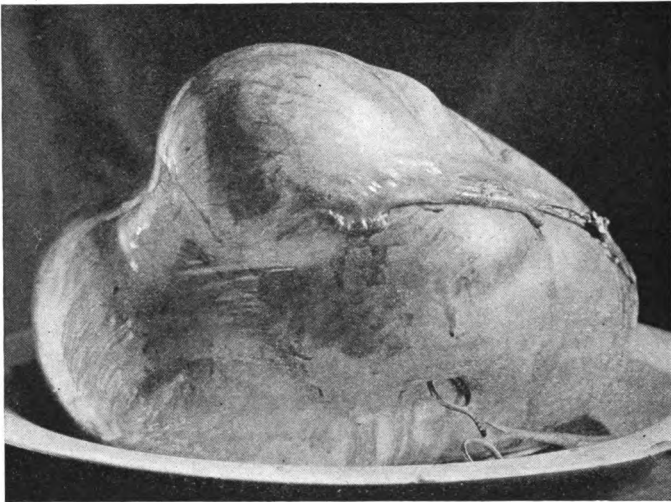


Fig. 16.—Ovarian tumor which was removed without puncture.

portions, and finally carries one of the ligatures around the stump and ties again. The peritoneum is sutured over the stump with fine chromic catgut suture to prevent a coil of intestine becoming adherent to the raw surface. The peritoneum is carefully inspected for bleeding points and for injuries, all of which should be covered in.

**HYSTERECTOMY—PANHYSTERECTOMY—SUBTOTAL  
HYSTERECTOMY**

Hysterectomy is indicated for cancer of the cervix and body, for fibroid growths, and in inflammatory cases where the uterus is so infected that it cannot be retained without prejudice to the health and even life of the affected individual. It means the removal of the organ in whole or part. The partial removal is known as *hysterectomy subtotal* or *supravaginal*, and should not be practised when the uterus or any portion of it is invaded by malignant disease. The entire removal of the organ is known as *panhysterectomy*, and may or may not be accompanied by the removal of the ovaries and tubes.

For **instruments and preparations**, see Fig. 17.

The median abdominal incision is preferable, inasmuch as it affords more room. The intestines are packed back and the myoma screw inserted, by which the uterus and growth are drawn up. This instrument should not be used in malignant disease of the body. The uterus is drawn toward the umbilicus, the anterior surface exposed, and the self-retaining retractor inserted. The intern makes traction on the uterus, when the operator with tissue forceps picks up the peritoneum above the bladder and incises it outwardly on each side to the round ligament. The round ligaments are tied and cut; a ligature is passed through the broad ligament between the ovary and uterus in fibroids, and external to the ovary in cancer, tied and cut; the mass is then raised up, the uterine arteries exposed, clamped, and cut.

In partial hysterectomy the uterus is cut across at this point, leaving the stump of the cervix (Fig. 18). The uterine

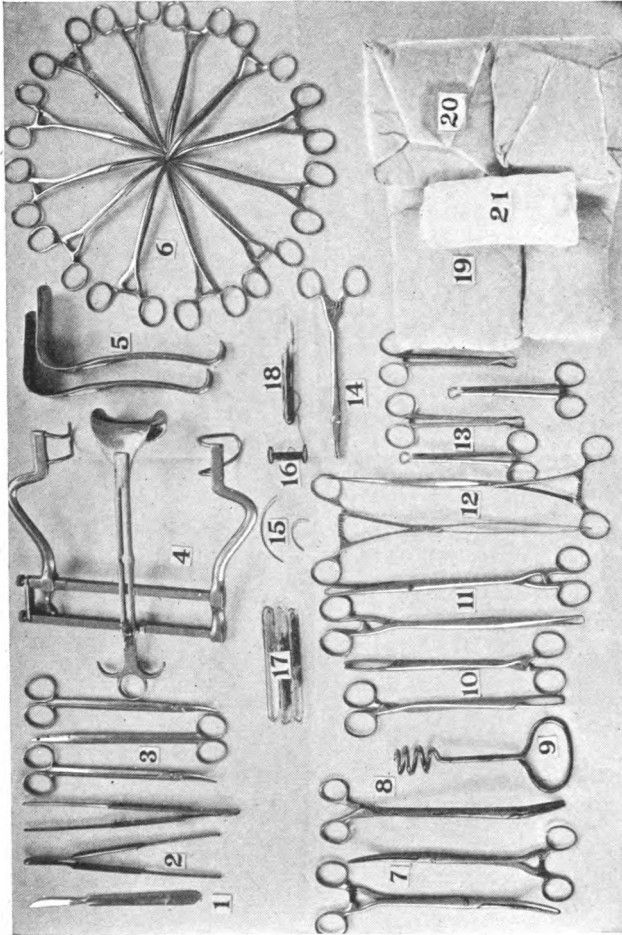


Fig. 17.—Instruments and preparations for abdominal hysterectomy. 1, Scalpel; 2, tissue forceps; 3, scissors (3); 4, combined retractor (self-retaining); 5, long retractors (2); 6, hemostatic forceps (12); 7, pedicle forceps (2); 8, right-angled clamp forceps (2); 9, myoma screw; 10, fixation forceps (2), 11, double tenacula (2); 12, intestinal clamps (2); 13, towel clips (4); 14, needle-holder; 15, curved needles (long and short, 3 each); 16, sterile silk; 17, catgut, chromic, Nos. 0, 1, 2; 18, catgut, plain, No. 1; 19, sterile gauze packs and sponges; 20, sterile gowns, sheets, and towels; 21, iodiform gauze.

arteries are tied. The nurse hands a curved needle, armed with catgut ligature, which is passed through the posterior

peritoneum, carried alongside the stump through the peritoneum in front near the round ligament; then with a hemostat the intern holds the stump of the broad ligament so that the

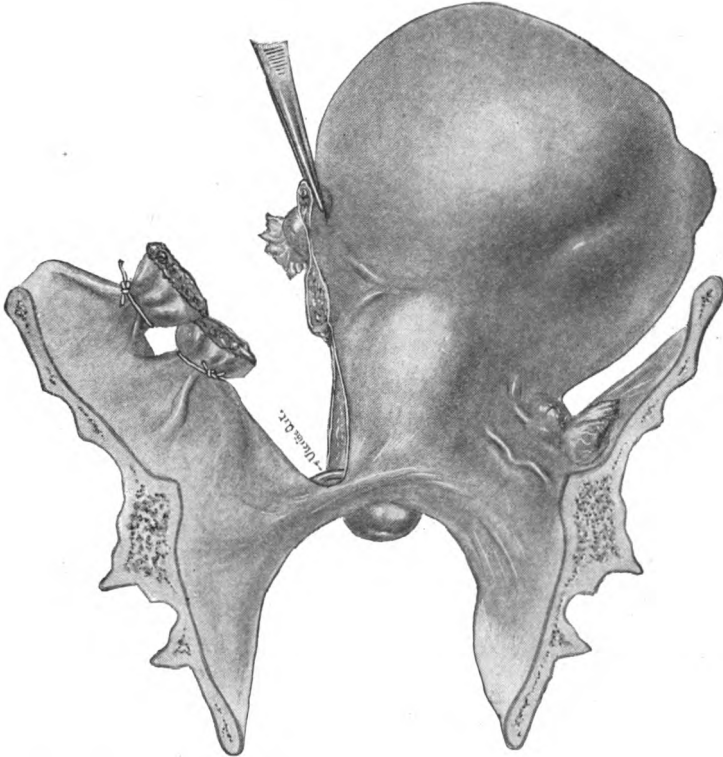


Fig. 18.—Exposing the cervix in subtotal hysterectomy. (Montgomery, "Practical Gynecology.")

ligature is tied over it, thus ensuring against hemorrhage by a second ligature, and making the stump of the ligament support the cervix and vagina against subsequent prolapse

(Fig. 19). The same course is followed on the other side, and the intervening peritoneal edges closed with a continuous suture.

**Panhysterectomy.**—Following the course indicated above, the uterosacral ligaments are clamped and cut, which permits the uterus to be raised, attached to the vagina alone.

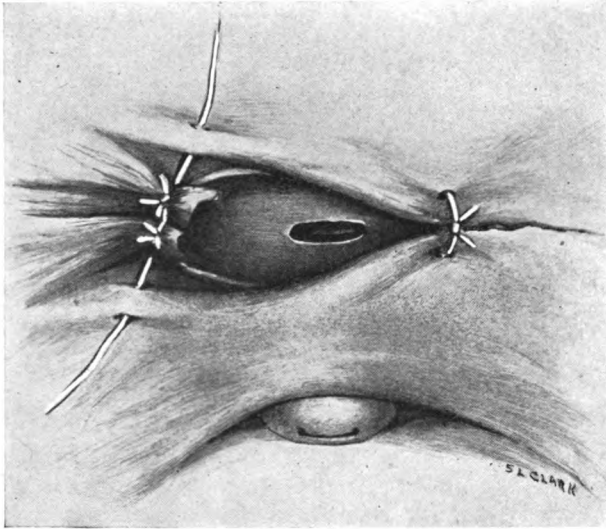


Fig. 19.—Stumps of the broad ligament sutured to the cervix. Peritoneum closed over them on the left side.

The latter may be opened behind, in front, or on the side, and separated from the cervix. When the operation is done for malignant conditions it is important to guard against reimplantation of the disease, so that the vagina should be carefully mopped out, clamped below the cervix, and the canal cut across below the clamps. I think an equally effective

procedure is to open the vagina in front, push a gauze pad through the opening into the vagina, which is subsequently to be withdrawn through the vulva, pack some gauze over the cervix, and complete the section. The tissues are thus protected from contact with diseased tissue. Sutures are passed on either side of the pelvis, picking up the perito-

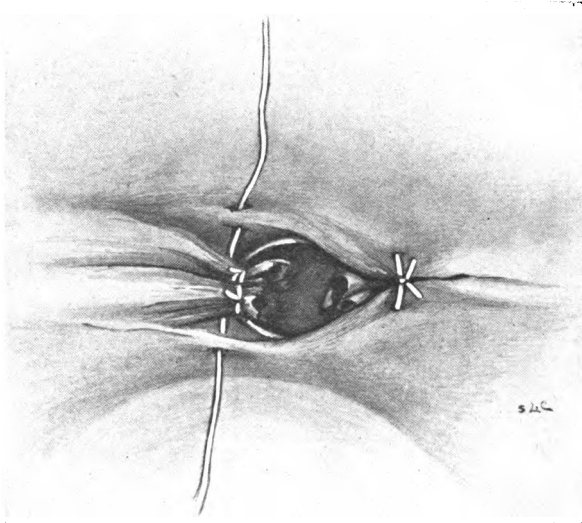


Fig. 20.—Method of fixing stumps in panhysterectomy.

neum, posteriorly carried forward along the edges of the vagina and including the vesico-uterine peritoneum. The stumps of the broad ligaments are drawn inward and the ligature suture tied over each. The intervening peritoneum is secured by a continuous suture (Fig. 20).



**INTESTINAL RESECTION AND ANASTOMOSIS**

Excision of a portion of the intestine may be demanded for injuries during the progress of an operation for inflammatory conditions, or extensive adhesions in ovarian or uterine neoplasms where the destruction of the intestinal walls or the injuries to vessels have been so extensive as to imperil the future vitality of the intestine.

The primary purpose of the operation may have been to resect the intestine for obstruction from malignant disease; for volvulus; for intussusception, or strangulation from constricting bands, or from hernia; for redundant condition of the descending colon or sigmoid; for prolapsus of large portions which are frequently an intussusception of the sigmoid and colon through the anus. Resection and anastomosis have of late been suggested by Lane for intestinal stasis and toxemia, where he partially or completely removed the colon.

For **instruments** and **preparations**, see Fig. 21.

The abdomen is opened in the median line, whether the procedure is primary or secondary. In the latter the intestinal work follows the removal of the inflammatory structures or growths, as the case may be. The intestine affected is raised, its contents pressed or milked downward where there is no opening, but where one exists it is brought out of the wound and the intestine emptied through it, exercising care that the contents do not enter and soil the peritoneal cavity. Clamps are applied to the intestine beyond the points at which excision is proposed and a pair of forceps at each end of the portion of the gut to be removed. The intestine

is cut between forceps at either end of the proposed resection,

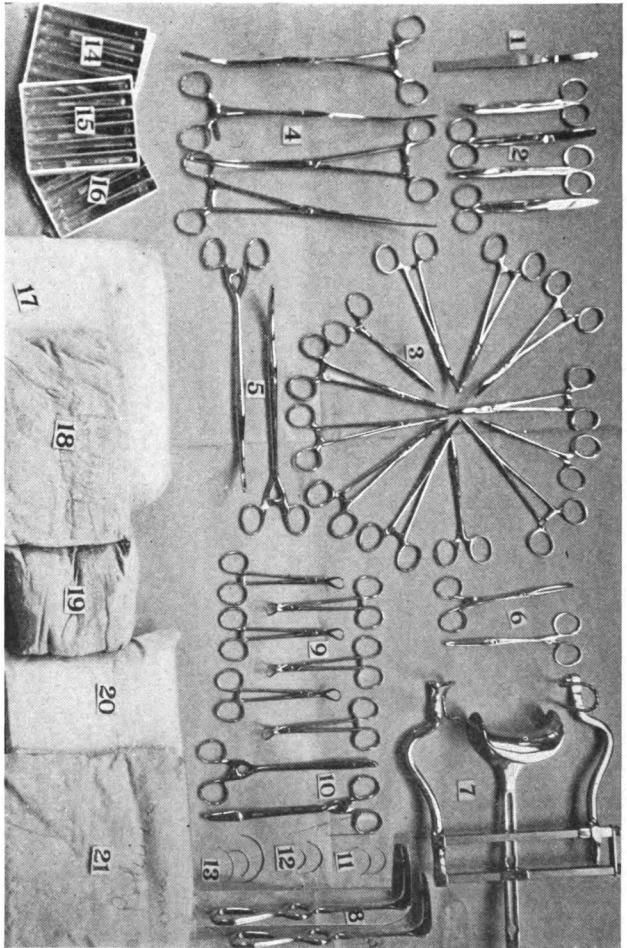


Fig. 21.—Instruments and preparations for intestinal anastomosis: 1, Scalpel; 2, scissors, curved and straight, sharp and blunt pointed (4); 3, hemostatic forceps (12); 4, intestinal clamps (4); 5, heavy curved forceps (2); 6, tissue forceps, toothed (2); 7, combination retractor (self-retaining); 8, long retractors (2); 9, towel clips (6); 10, needle-holders (2); 11, intestinal needles (4); 12, round-pointed needles (2), 13, long curved needles, cutting edges (3); 14, tubes chromic catgut, Nos. 0, 1, 2; 15, tubes plain catgut, No. 1; 16, tubes silk, Nos. 0, 1, 2; 17, packages of gauze sponges; 18, gauze rolls for packing; 19, packages containing dressings, gowns, and gloves; 20, plaster strips and tapes; 21, abdominal binder.

and the excised portion separated from its mesentery or mesocolon, as the case may be, and the vessels clamped as

the separation proceeds. Care is exercised to make this separation hug closely the bowel, so that large branches shall not be injured, and thus imperil the vitality of extensive portions of the intestine. The nurse hands a suture ligature of chromic catgut No. 1, threaded in a round-pointed needle, and the mesentery is secured with a continuous suture occasionally interlocked by passing the needle and suture beneath the preceding loop. After tying the end of the suture, the surface should be inspected to make certain that all bleeding is controlled. The proximal and distal ends of the resected gut are carefully cleansed when cut. The muscle and muscle layer of each are now seized with forceps, drawn out from the peritoneum, tied with silk, having the forceps slowly loosened as the knot is tied, the external portion carbolized, dried, and the peritoneum sutured over it. The intestinal clamps are placed some 3 inches from the distal and proximal ends of the intestine, the contents having been pushed beyond the clamps before they are applied. The intestinal ends are overlapped and the peritoneal surfaces sutured for a space of 3 to 4 cm. An incision is made in each end the length of the sutured portion, when the field having been protected by gauze, the edges of the incision are united by a continuous, occasionally interlocked silk suture, tied on the inner surface. When the opening is completely closed the catgut suture is resumed, uniting the peritoneal surfaces over the silk suture (Fig. 22). The clamps are removed, the certainty of the communication established by pressing the gas and contents of the upper intestine downward through the opening.

The wound in the mesentery is closed by a continuous catgut suture. The same course is pursued in resection for non-traumatic conditions. When done because of strangulation, the precaution must be exercised to make certain that the resection has extended beyond the devitalized portion.

In operations for carcinoma or prolapsus of the rectum it may be necessary to loosen the peritoneum, and resect the

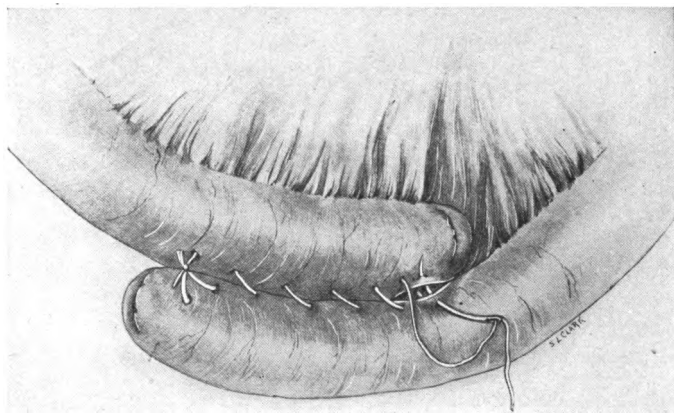


Fig. 22.—Intestines united by lateral anastomosis.

bowel below the latter, where it is not feasible to apply clamps to the lower portion. The sphincter should have been previously divulsed and the wound cleansed from below. Where the bowel is opened a gauze pad should be pushed into the lower segment, to be withdrawn by the anus, and the pelvis carefully protected from soiling by gauze packing. The resection may be so low in the pelvis as to make even an end-to-end anastomosis difficult. In such cases the better pro-

cedure is to draw the proximal portion of the intestine through the anus. Its ends should have been ligated temporarily to ensure protection of the pelvis from soiling. The abdominal wound should be temporarily packed with gauze while the end of the intestine is being stitched to the skin about the anus. The hands are washed, or the gloves changed when they are worn, and the peritoneum sutured in the pelvis about the intestine, following which the abdominal wound is closed. The intussuscepted portion of the intestine sloughs and is discharged through the anus. It is better to fasten a rubber drain through the anus into the intestine for a few days to prevent gaseous distention of the lower bowel.

#### GASTRIC OPERATIONS

Operations on the stomach consist in measures for its support in prolapsus; its exploration for removal of foreign bodies and the treatment of ulceration; its resection in cancer and extensive ulceration, and its drainage in narrowing of the pyloric opening or in marked prolapse and dilatation. The incision should generally be made above the umbilicus, in the median line or through the left rectus. The incision should be a free one, for a large incision can be closed more expeditiously and with less injury to the structures than when the operation is done through a small and insufficient opening. As it is quite impossible to absolutely predict in advance the character and extent of an operation, it is a matter of prudence to be provided with all the necessary paraphernalia for any emergency.

For instruments and preparations, see Fig. 23.

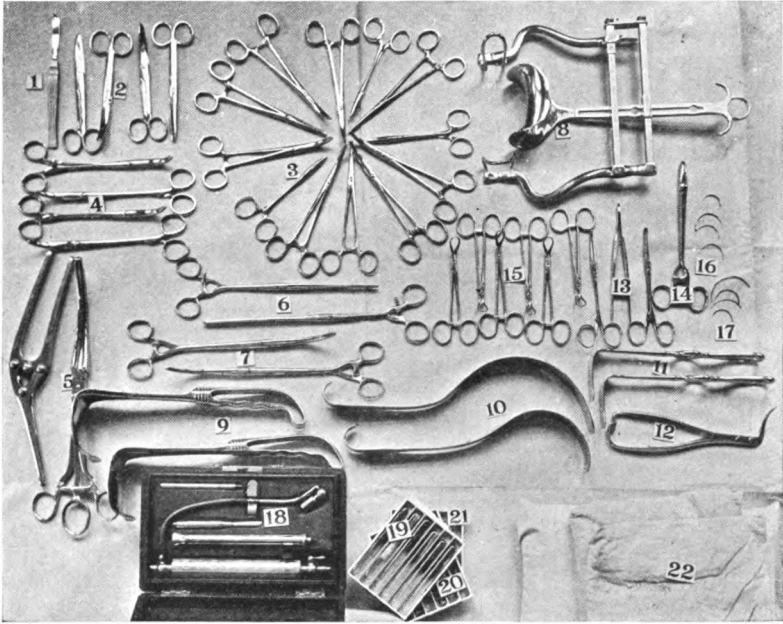


Fig. 23.—Instruments and preparations for gastric procedures: 1, Scalpel; 2, scissors, curved and straight, sharp and blunt pointed (4); 3, hemostatic forceps (12); 4, long hemostatic forceps (Bland's) (4); 5, large gastro-enterostomy clamps (2); 6, small gastro-enterostomy clamps (2); 7, large clamp forceps (2); 8, combined retractors (self-retaining); 9, broad blade retractors (2); 10, abdominal retractors (2); 11, small retractors for holding open the stomach (4); 12, ligature carriers (right and left); 13, tissue forceps, toothed (2), serrated (1); 14, needle-holder; 15, towel clips (6); 16, needles, curved, round-pointed (4); 17, needles, long and curved, cutting edge (4); 18, Paquelin cautery; 19, tubes of silk for sutures, Nos. 0, 1, 2; 20, tubes of catgut, chromic, Nos. 0, 1, 2; 21, tubes of catgut, plain, Nos. 1, 2; 22, packages containing sterile gowns, sponges, packs, dressings, towels, sheets, cover pad, and abdominal binder. Plaster in strips with tapes attached for retaining dressings.

**Gastropexy.**—In gastroptosis the stomach is supported by folding the gastrohepatic omentum, as suggested by Beyea, or attaching the great omentum to the anterior ab-

dominal wall. The patient is placed in the dorsal position, with the upper part of the table slightly elevated, or the table may be broken about the middle of the back, or a sand pillow or inflated rubber pillow placed under the patient, so that the upper abdomen is more prominent. A median

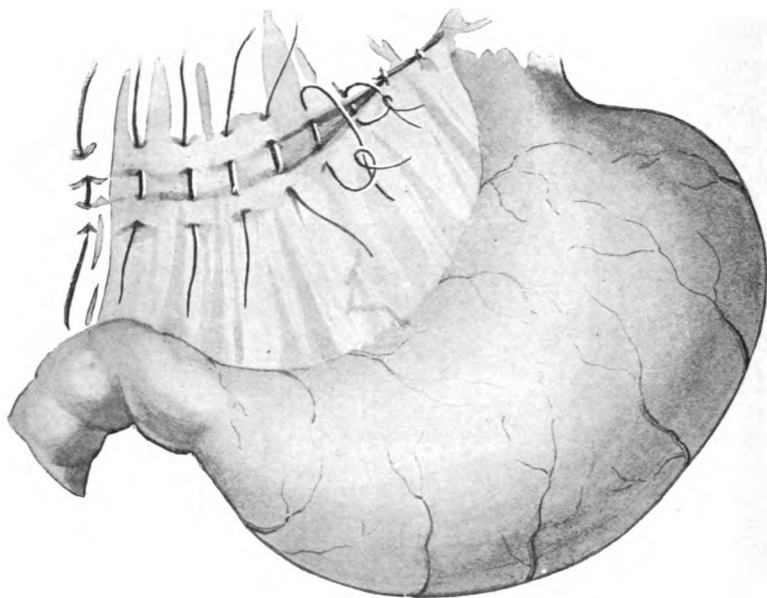


Fig. 24.—Beyea's operation for gastroptosis—the first layer of sutures (Moynihan).

incision from the ensiform cartilage to just above the umbilicus is made through all the tissues above the peritoneum. The latter is held with tissue forceps by the operator and intern and opened between them. The operator then, with blunt straight scissors, incises the peritoneum the length of

the wound, protecting the abdominal contents with two fingers of the other hand. He raises up the stomach, transverse colon, and omentum, and with a pack handed him by the nurse walls off the small intestine. The intern and a nurse hold the wound open with a broad retractor on either

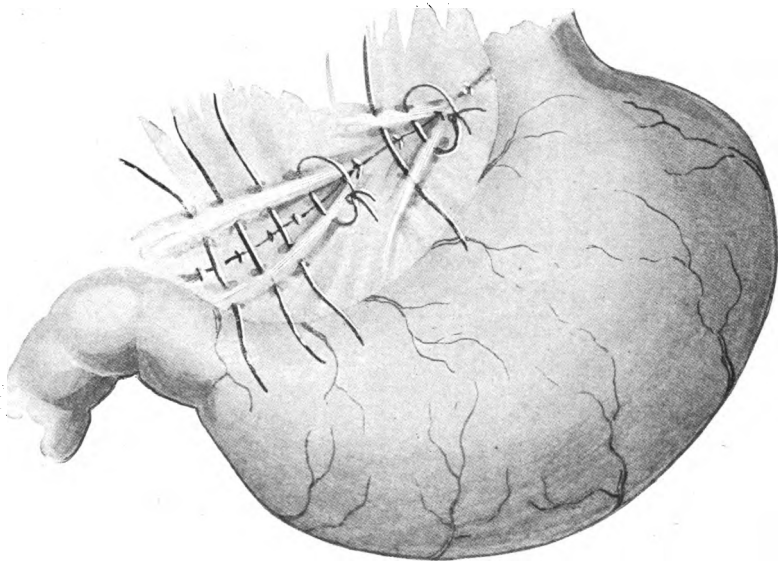


Fig. 25.—Beyea's operation for gastroptosis—the first layer of sutures completed; the second and third being introduced (Moynihan).

side (Figs. 24, 25). The operator carefully examines the stomach, pylorus, and gall-bladder, after which he shortens the gastrohepatic omentum by inserting three rows of sutures, using No. 1 chromic catgut, threaded in a curve-pointed needle, exercising great care not to include large vessels in the sutures.



The Coffey operation consists in stitching the omentum to the anterior abdominal wall, this forming a sort of shelf on which the stomach shall rest (Fig. 26). The omentum just below the colon is secured by interrupted sutures to either side and to the wound as it is closed, exercising the precau-

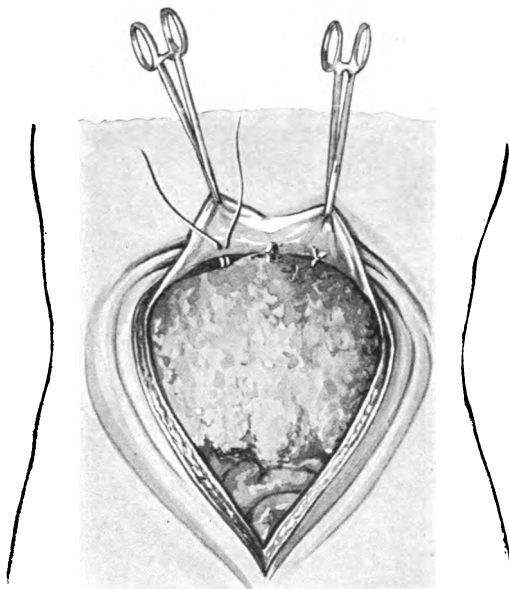


Fig. 26.—Gastropexy; Coffey's operation. The suture of the omentum to the anterior abdominal wall (Moynihan).

tion that there shall remain no opening through which a loop of the small intestine may be forced and become strangulated. Where the omentum is very heavy and fat this operation may very wisely supplement the Beyea procedure to take the drag from the gastrohepatic sutures.

**Gastrotomy.**—Probably the most frequent cause for surgical interference with the stomach is occasioned by gastric or duodenal ulcers. These ulcers may render life unendurable through the severe pain, or endanger it by profuse hemorrhage or rupture, and the escape of the stomach contents into the peritoneal cavity. Persistent ulceration associated with nature's efforts at repair through cicatrization may result in contraction and pyloric obstruction. The recognition of an ulcer of the stomach does not necessarily demand resort to surgery, for many patients under a carefully directed medical regimen recover, but in numerous instances delays are dangerous, and it may be questioned whether in the majority of instances recovery would not be expedited by early surgical interference.

For **instruments** and **preparations**, see Fig. 23.

The incision has been made. The stomach is drawn out and carefully examined. The ulcer is most frequently found near the pyloric end and the lesser curvature, although it may affect the greater curvature, the anterior or posterior walls. It consequently may be readily accessible or be so situated that the stomach has to be opened to reach it. The procedure is known as "gastrotomy." The operation is done for exploration of the stomach where a hardness or induration is situated upon its posterior wall, to explore the mucosa for ulceration where there is a history of hematemesis without presenting any evidence of cicatrization, and for the purpose of removing foreign bodies. A perforation is best treated by searing its surface with a thermocautery knife

and suturing the opening with a double row of sutures. An accessible ulcer attended with induration may be wisely made a perforation with the cautery, and then closed as in ordinary perforation. In suturing these openings the first row of sutures should be silk, while the second may be chromic catgut. The inaccessible ulcer requires an incision of the stomach through its anterior wall which may be longitudinal or vertical. Retractors are inserted and the cavity inspected. The abdomen is carefully protected from soiling by gauze packing. An ulcer may be inverted through the opening, be cauterized with the cautery, and sutured from within with silk sutures, ensuring the contact of a thick layer of peritoneal surfaces. The gastric incision is then closed by continuous or interrupted silk sutures, and this line of suture covered by a row of chromic catgut suture which may be continuous. All gauze packing is effectually removed before closing the wound. The nurse in care of gauze pads must keep an account of the pads used, and in this as in all abdominal procedures be certain that all pads used are in sight.

**Gastro-enterostomy.**—The term employed for a communication between the stomach and the small intestine (Fig. 27). It may be called a gastroduodenostomy when the first part of the small intestine, or a gastrojejunosomy when the second part is utilized.

The operation may be an anterior or posterior gastro-enterostomy. The latter is the one most frequently preferred.

*Anterior gastro-enterostomy* is made between the stomach and the jejunum. A coil of the latter has its contents pressed

out and is grasped by one of the clamp forceps, generally with the blades covered with rubber. The other pair is placed upon a fold of the anterior surface of the stomach near its greater curvature. The point of the forceps is directed across the stomach or toward its lesser curvature. A roll of gauze is placed between the two pairs of forceps, and with a No. 1 chromic catgut suture the long diameter of the intestine is sutured to the transverse diameter by a continuous suture for

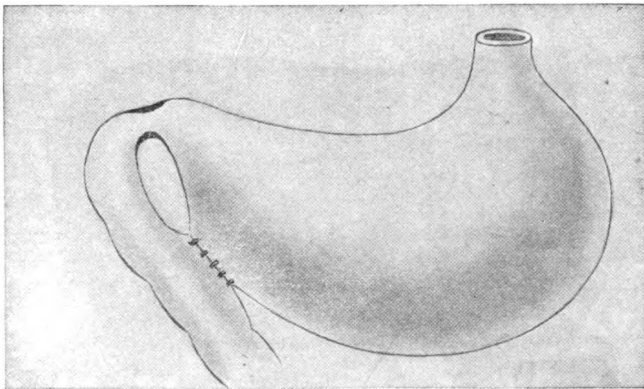


Fig. 27.—Gastroduodenostomy. Kocher's method. (Keen's "Surgery.")

about 3 to 4 cm. With the surfaces carefully protected an incision  $\frac{1}{2}$  to 1 cm. from the sutured line is made into the stomach and intestine. The purpose of making it so low in the former is to make sure there will be no undrained portion. The raw edges of stomach and intestine are united with a continuous suture of silk (Fig. 28), which should interlock about every third or fourth turn, and should completely encircle the opening. When the opening is thus closed the clamps

may be removed and the second row of suture (catgut) be resumed until it completely covers the silk suture. As these cases sometimes suffer from a vicious circle, the contents of the jejunum, consisting of food which still passes the pylorus, the bile, and pancreatic secretion, enter the stomach at the com-

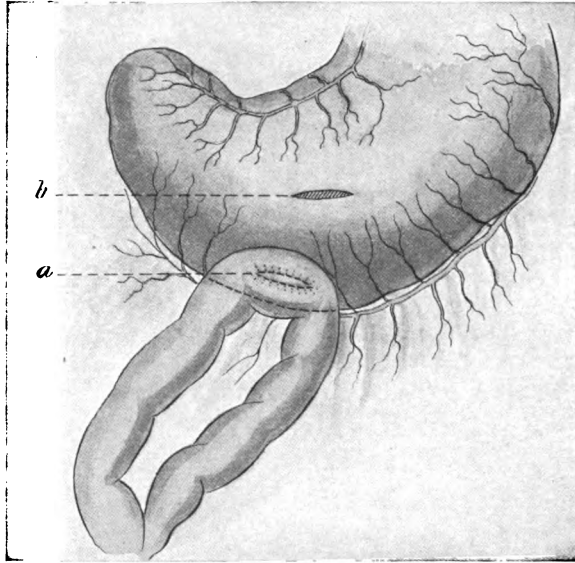


Fig. 28.—Anterior gastrojejunostomy. Showing the correct position (a) and the incorrect position (b) for the anastomosis. (Keen's "Surgery.")

munication and are vomited, this condition has been met by making an anastomosis between the surfaces of the jejunum, so that the contents of the latter will not reach the communication with the stomach.

*Posterior gastro-enterostomy* is the operation of preference, the *anterior* being done where it is not feasible (Fig. 29). The

latter is done when the mesocolon is too short to permit carrying the stomach through it, or the posterior wall is fixed by adhesions or is the seat of cancer. In the posterior procedure the colon and omentum are turned upward, an opening through the mesocolon avoiding large vessels, and a portion of the

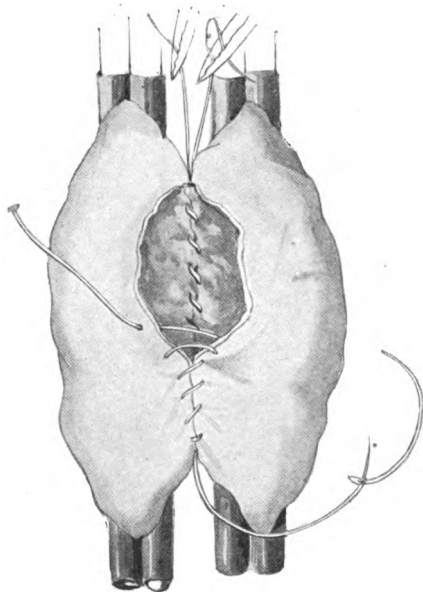


Fig. 29.—Posterior gastro-enterostomy. The inner suture nearly completed. The mucosa being turned outward, not inward (Moynihan).

posterior wall of the stomach drawn through and clamped. A loop of the jejunum is also secured with another clamp in its course from left to right.

Mayo emphasizes the importance of avoiding a reverse turn in uniting the intestine. As in the anterior operation, a pad of gauze is placed behind the forceps, the peritoneal sur-

faces sutured with chromic catgut, the desired length being 3 to 4 cm., an incision is made into each fold while the abdomen is carefully protected from soiling. The edges of the united flaps, including the mucous membrane, are sutured by continuous silk (No. 1) suture, and this suture is continued, occasionally interlocking it, until the union of the stomach and intestine is completed by closure of the opening. The clamps are removed and the catgut suture resumed and continued, completing the second line of suture. The opening in the mesocolon is closed about the anastomosis. Neglect of this precaution has occasionally led to a hernia of the small intestine through the opening and to a serious obstruction.

*Gastroduodenostomy* and *pyloroplasty* are methods employed in pyloric obstruction, but it is unnecessary to more than mention them here, as they do not require additional technic.

*Gastrogastrostomy* may be employed in hour-glass contraction.

*Pylorectomy* and *partial gastrectomy* are required in gastric carcinoma, when the disease is so circumscribed as to afford a reasonable probability of recovery, or rendering more comfortable the remaining span of life for the sufferer. As the supply of blood to the stomach comes from the celiac axis the extent of the structure removed will depend upon the vessel destruction. The field involved is carefully inspected for evidences of transmission to the lymphatic nodes in this region, and when such have occurred the advisability of a radical operation is questionable. The gastric branches in the gastrophatic and large omentum are tied and cut through the length

of the proposed resection. The wall of the stomach is clamped by the stomach forceps well external to the disease, while a second large pair of forceps is applied close to the disease structure, and the incision with scalpel or scissors made between them. The same course is followed upon the pyloric side. The surfaces are carefully protected by gauze from soiling during the resection and the surfaces carefully sponged upon its completion.

The operator closes the open surfaces first with a continuous silk suture, bringing the peritoneal surface in contact, and reinforces this with a suture of chromic catgut externally. Where but a small portion of the stomach has been resected, an anastomosis may be made between the lower end of the gastric incision and the pylorus, but in all cases where the tension would be great the wounds should be closed and communication established between the most dependent portion of the stomach and the jejunum.

### GALL-BLADDER OPERATIONS

Operations on the gall-bladder are most frequently occasioned by obstruction of the bile tracts by concretions known as gall-stones. They most frequently form and accumulate in the gall-bladder. They may vary in number from one to several hundred, and in size from the calculus as large as the end of a thumb to the millet-seed size in great numbers. They may be rough, strawberry-like, or perfectly smooth where they attain to considerable size, and where many are packed together they are faceted. They may exist in large numbers in






Fig. 30.—Instruments and preparations for gall-bladder operations: 1, Scalpel; 2, scissors, straight and curved, sharp and blunt pointed (4); 3, hemostatic forceps (12); 4, long hemostatic forceps, Bland's (4); 5, tissue forceps, toothed and serrated (2); 6, forceps for seizing gall-stones; 7, glass syringe (2 to 4 oz.); 8, gall-stone scoop; 9, long probe; 10, retractor (self-retaining); 11, retractors, long and curved (2); 12, towel clips; 13, needle-holder; 14, needles, curved, long and short, round pointed and cutting edged (8); 15, bottle and tube for drainage; 16, rubber tubing; 17, gauze wrapped with rubber tissue; 18, right-angled tube for common duct drain; 19, tubes of silk, Nos. 1, 2; plain and chromic catgut, Nos. 0, 1, 2, for sutures and ligatures; 20, packages containing sterile packs and sponges, dressings, gloves, gowns, sheets, and towels; abdominal binder and plaster strips with tapes attached.

the gall-bladder and produce no characteristic symptoms. The patient frequently complains of a sense of discomfort and burning, which is attributed to dyspepsia. When the concretions enter the cystic duct in their course toward the intestine the patient may suffer violent attacks of colic attended with nausea and vomiting. Where the calculus passes into the common or hepatic ducts, not only does the patient suffer severe pain, but becomes profoundly jaundiced, and is affected by more or less morbid toxemia. Infection of the gall-bladder may result from coli bacillus, the bacillus of la grippe, or typhoid, and be favored by the continued irritation of the gall-stones. The gall-bladder may be thickened and contracted or greatly distended, forming a large sac, the walls of which are fragile, rupturing in the efforts at separating it, or even under manipulation prior to operation for purposes of diagnosis.

The patient prepared for abdominal operation is placed upon a table which is broken so that the chest lies above the break. This position can be accomplished by a sand-bag or inflated rubber bag under the back. The incision may be made in the median line, parallel with the ribs, or in the right semilunar muscle, **S** shaped as suggested by Bevan, as the operator may prefer. The grid-iron opening, in which the various muscles are split and held apart, may be utilized where a large opening will not be required. A vertical opening will generally be most satisfactory, as an opportunity is afforded for the extension of the incision when required. The abdomen opened, the self-retaining retractor is placed, the intestine

walled off, and the condition of the gall-bladder and its relations determined by sight and touch.

The exigencies of the conditions found may require resort to one of the several procedures. Cholecystotomy is opening of the gall-bladder for the evacuation of gall-stones and inflammatory collections. Such an opening may be at once closed. In cholecystostomy the opening is maintained for a length of time for drainage, as in infections of the gall-bladder

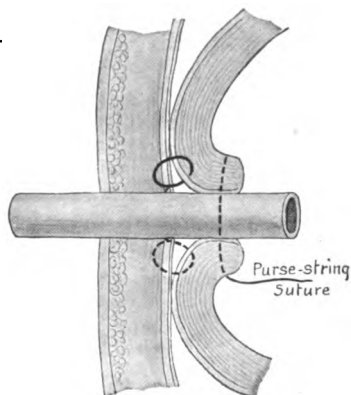


Fig. 31.—Sectional cut showing the gall-bladder and tube in position. (After Binnie.)

and bile-ducts, and for inflammation of the pancreas (Fig. 31). Cholecystectomy is done when the changes in the gall-bladder from inflammation and gangrene render its retention dangerous. Choledochotomy is done when the common duct has to be opened, as for the removal of impacted gall-stone. Choledochostomy when this opening has to be maintained for a length of time. Choledochectomy when a portion of the common duct has to be removed. The condition of the bile-

ducts may further require choledochoplasty, as for the closure of a biliary fistula, or cholecystogastrostomy, cholecystoduodenostomy, cholecystojejunostomy, cholecystoileostomy, and cholecystocolostomy, respectively a communication between the gall-bladder and stomach, duodenum, jejunum, ileum, or the colon, as the changes of the structures may demand. Adhesions of the omentum and intestines to the gall-bladder are carefully separated and the intestines walled off from the field by gauze packing, while the exposure is made complete by retractors held by the intern or nurse. When the gall-bladder is distended it can be drawn out by hemostats and cut between them, and its contents, whether bile, pus, or calculi, evacuated without danger of soiling the peritoneal cavity. While the intern holds the opening, the operator should pass his hand along the common and hepatic ducts and endeavor to coax any calculi which have entered them back into the gall-bladder to secure their evacuation. Where the gall-bladder is not easily brought up it may be partially separated from the liver, or where this is not sufficient, the abdomen about it should be packed with gauze to absorb the discharges which may follow its opening. The removal of small stones and the detritus or sand may be facilitated by syringing out the tract with warm salt solution. The removal of large calculi, or those impacted, may be facilitated by the employment of the scoop or forceps. The impaction of a large stone in the common duct may demand the incision of the duct for its delivery. The operator should never neglect to make certain that no calculi remain in the common and hepatic ducts, for otherwise relief will be in-

complete and the surgery be justly censured. Where the gallstones have been completely evacuated and the gall-bladder shows no evidences of inflammation and thickening, the gall-bladder wound can be closed by a double row of sutures. In the majority of cases demanding operation it will be advisable to insert a drain; a section of  $\frac{3}{8}$ - to  $\frac{1}{2}$ -inch rubber tubing is inserted into the bladder, the opening sutured about it with chromic catgut, and the latter carried into the tube to insure its remaining. Unless there has been extensive perivesical inflammation no drainage of the tube will be required. When the calculus has required the incision of the common duct, accompanying infection or contraction may demand that the common duct shall be drained, or the condition of the gall-bladder may demand the removal of the latter. In these instances drainage of the abdomen may likewise be required. The drain for the common duct should be a right-angled rubber tube, constructed in one piece, sutured into the common duct.

The abdomen may be drained by a separate rubber drain or by cigarette drains of gauze and rubber tissue, or the field, when there have been extensive adhesions, may be walled off by sterile or iodoform gauze and the ends brought out of the wound about the tube. When the bladder only is drained, the tube may be brought out through the wound, or when more closely related to the peritoneal surface, through a stab wound just over the bladder. It is unnecessary to suture the bladder to the peritoneum, as traction on the tube draws it into the stab wound. Care should be exercised that the bladder does not come next the skin surface, otherwise the continuity of

mucosa to the skin prevents the closure of the fistulous tract. When gauze is used for drainage unenveloped by rubber tissue it should be left for five or seven days before removal or until it can be easily withdrawn. It is a filthy method of drainage and is followed by extensive adhesions, so that it is better avoided. The rubber drain after the wound is closed may be inserted into a flat bottle buried within the dressings, or be connected with another tube, the end of which is carried into a bottle suspended from the side of the bed. The end of the tube should be immersed in a 5 per cent. solution of carbolic acid to prevent the aspiration of germ-laden air into the abdomen through the tube. Traction on the tube from time to time after the end of a week will soon bring about its withdrawal, when the sinus, unless the canal is obstructed, will promptly close.

#### THE SPLEEN

The spleen may become injured by falls, blows, or stab wounds, and in severe cases may demand its removal. The instances in which the removal of the spleen is indicated are infrequent. In addition to the already indicated injuries, the spleen is removed for malignant disease, marked material enlargement, splenic enlargement, and when the organ is very movable (Fig. 32).

*Operation.*—The incision is generally made in the median line, although in large tumors the incision through the left semilunaris may afford more ready access to the pedicle, and additional room may be secured by cutting across the rectus. The wound opened and vessels secured, the extent of adhesions

should determine the course, those to the diaphragm and pan-




Fig. 32.—Instruments and preparations for operations on the spleen. 1, Scalpel; 2, scissors, long, curved, sharp and blunt pointed (2); 3, hemostatic forceps (12), 4, large forceps (2), 5, retractor (self-retaining), 6, long retractors, broad blades, 7, pedicle needle; 8, needle-holder, 9, needles, curved, long and short (6), 10, tubes of silk, No. 2; plain and chromic catgut, Nos. 0, 1, 2, 11, sterile rubber tubing and tissue; 12, packages containing sterile long gauze packs (4), gauze sponges, dressings, gowns, sheets, and towels; 13, strips of plaster and pieces of plaster with tapes attached

creas generally affording the greatest difficulty. The omental adhesions may be separated between ligatures. The spleen

raised and carefully delivered through the wound. Great care must be exercised that the friable organ is not torn. Traction upon the vessels of the pedicle may cause severe shock. Where they are not securely tied, a vessel may retract, causing a quickly fatal hemorrhage. As the spleen is raised and brought out of the wound, the intestines are packed back with gauze to keep exposed the pedicle of the spleen. It is very important to make certain that every vessel is ligated, and they should be tied with No. 1 chromic catgut, but not so tight as to endanger cutting through the vessels. It is unwise to tie a large pedicle in mass, for the retraction of a vessel is not infrequently attended with a fatal hemorrhage. Where adhesions are broad the chain-interlocking suture should be employed. In adhesion to the pancreas, the removal of a portion of the latter may be necessary. Wherever possible, peritoneum should be sutured over denuded areas. All gauze packs should be removed and the wound closed without drainage unless extensive areas have been denuded, when either a wick or gauze packing should be employed.

#### OPERATIONS UPON THE KIDNEY

Surgical relief may be demanded for traumatic or diseased conditions of the kidney. The latter are the more frequent, and vary from mobility, interfering with the comfort and safety of the patient, to extensive destructive conditions which demand incision and drainage or complete extirpation.

The position of the incision depends upon its purpose. In



all procedures for disorders unattended by marked increase in size the oblique lumbar incision is preferable (Fig. 33).

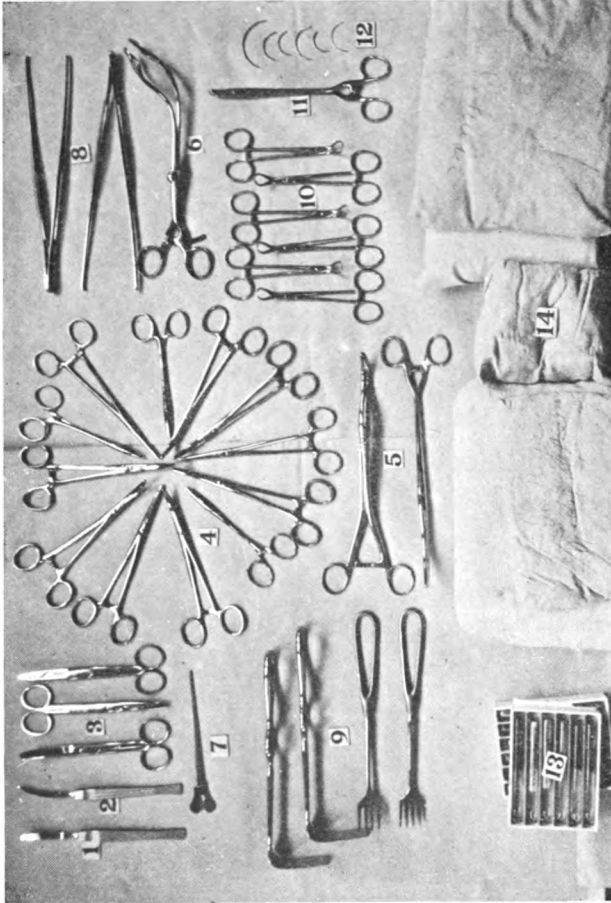


Fig. 33.—Instruments and preparations for renal surgery: 1, Scalpel; 2, bistoury; 3, scissors, curved and straight, pointed and blunt (3); 4, hemostatic forceps (12); 5, large compression forceps (2); 6, large fenestrated forceps (1); 7, grooved director; 8, long tissue forceps, toothed (2); 9, retractors, forked and plain (4); 10, towel clips (6); 11, needle-holder; 12, needles, long and short curved (6); 13, tubes of silk, No. 2; plain and chromic catgut, Nos. 0, 1, 2; 14, packages containing sterile gowns, gloves, sponges, packs, dressings, sheets, and towels.

A table with an arrangement for breaking it. Where the latter arrangement is not present, there should be provided sand

pillows or a rubber cushion (Edebohls). The patient should lie in a semiprone position on the left side where the right kidney is the one affected, over the break or pads, so that the ribs and crest of the ileum shall be widely separated. The field after previous preparation is painted with  $3\frac{1}{2}$  per cent. iodine solution and enveloped with sterile sheets and towels held in place by towel clips.

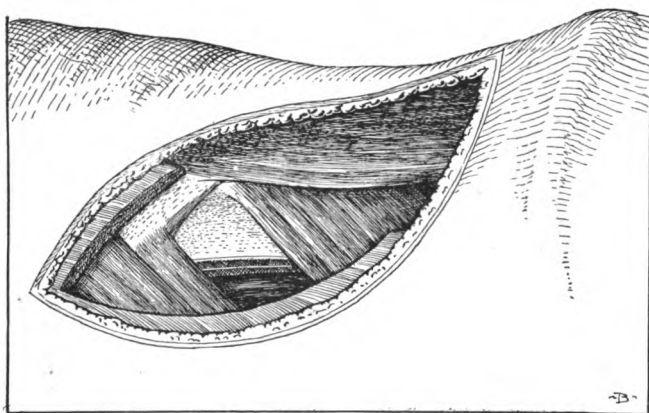


Fig. 34.—After section of latissimus dorsi. Cross showing position of incision of the aponeurosis of the transverse muscle. (Greene and Brooks.)

An oblique incision is made outward and downward, from the point where the twelfth rib emerges from beneath the erector spinæ muscles to a point one fingerbreadth above the crest of the ileum. This incision carried through skin, superficial fascia, and latissimus dorsi (Fig. 34). The oblique can be drawn forward and the fascia of the transversalis cut, thus exposing the fascia directly over the kidney. The ilio-inguinal and the iliohypogastric should be pulled aside; where this is

impossible, the nerves should be cut and sutured at the close of the operation. I have seen relaxation of the abdominal muscles of the affected side follow the operation and lead to the diagnosis of hernia. This relaxation or paralysis is due to innervation following cutting the iliohypogastric nerve.

In movable kidney the incision described admits anchoring of the kidney. It is called "nephropexy." The enveloping perineal fat is opened, the kidney separated from it, and the surrounding structures, especially the colon and peritoneum, by blunt dissection, and is then drawn out of the wound by a finger thrust beneath the kidney, or the investing fatty capsule may be seized with a hemostat near the lower pole and raised, when the organ can usually be easily drawn out. Should there be difficulty, a pair of concave-bladed fenestrated forceps, by which the organ can be seized and drawn up without danger of injury by compression, should be used. There should be no difficulty in the delivery of a freely movable kidney. Thus delivered, the capsule is opened, a grooved director passed under it, and the capsule divided the length of the convex border. It is then pushed forward and backward toward the kidney pelvis, exposing about one-half the kidney surface. Two sutures are introduced in the folded capsule on each of the anterior and posterior surfaces, parallel to the long axis of the kidney. These sutures are passed through the muscle and aponeurotic layers, but not through the skin, and tied. They carry the kidney into the incision. The muscle and fascia are closed with chromic catgut sutures, turning the raw surface of the quadratus lumborum muscle in contact with the

raw kidney surface. The skin may be closed by a continuous catgut suture.

**Nephrotomy.**—With the preparation indicated, and through a similar incision, the kidney may be opened for the removal of

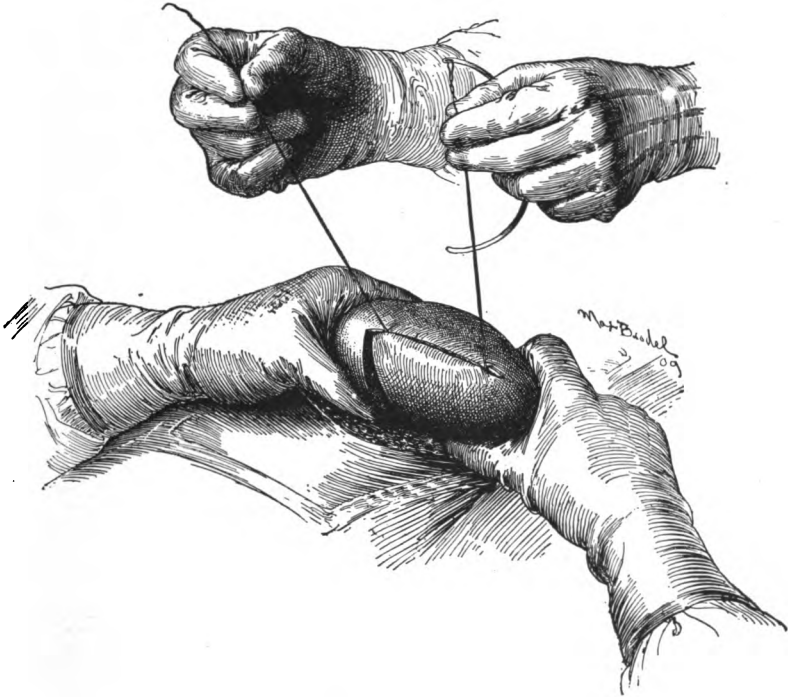


Fig. 35.—Opening kidney with silver wire. (Ernest K. Cullen, in "Surg., Gyn., and Obst.")

a calculus, the evacuation of a pus collection, or the exploration of its pelvis and calices. The kidney may be opened, extending through its convex border, but the incision with a knife is

often attended with frightful hemorrhage. Cullen and Derge advocate doing nephrectomy with a silver wire (Nos. 3 or 4). The wire is threaded into a long, round-pointed or liver needle, and carried the distance desired for the opening (Fig. 35). The capsule of the kidney is incised over the desired course; the two ends of the wire are drawn upon by a sawing motion until the opening has been accomplished and without much bleeding. The direction of the incision should be determined by the distribution of the vessels and its purpose. The position of the renal incision for the removal of a calculus will depend upon its size and situation. If it occupies the calices of the kidney, the incision should be either longitudinal or vertical. If it is situated in the pelvis, and especially when small, the opening should be through the membranous wall, exercising care not to injure the vessels. Where it is desirable to maintain drainage, the opening in the kidney may be sutured to the abdominal wall, thus constituting a nephrostomy. The cavity may be packed with gauze or have a rubber tube sutured in. When the opening is in the membranous structure of the pelvis the drainage should consist of a small roll of rubber tissue.

**Nephrectomy.**—The degeneration may be so extensive as to demand the removal of the entire kidney. The kidney is brought up in the manner described. The condition demanding the operation may be revealed by the incision into its structure. Its pedicle is exposed, the ureter divided between ligatures, the arteries and veins either ligated or clamped and cut, releasing the kidney. If the vessels have been clamped they should now be ligated, and preferably after isolation

rather than en masse. The cavity is carefully inspected, and then, after insertion of drainage or the employment of gauze packing, the wound is partially closed.

*For Large Renal Tumors.*—When the kidney is occupied by growths of considerable size, or is greatly enlarged by pus collections and accompanying inflammatory changes, the oblique

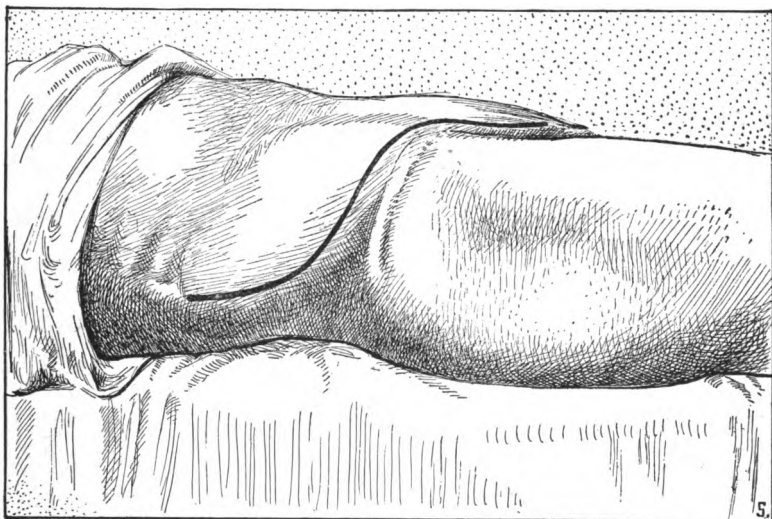


Fig. 36.—Lumbar iliac incision for nephro-ureterectomy. (Greene and Brooks, after Pierre Duval.)

lumbar incision is insufficient. The incision may extend from the lower end of the oblique incision described, around the crest of the ileum, and downward in the corresponding flank to the edge of the rectus muscle. This incision is the one usually recommended for nephro-ureterectomy (Fig. 36). The majority of the operations for removal of the kidney

will not require so extensive an incision. An alternative procedure is to open the abdominal wall external to the rectus muscle corresponding to the affected side, exposing the peritoneum without opening it, and then push it from the abdominal wall outwardly until the kidney within its perineal fat is exposed (Fig. 37). If the surrounding structures are

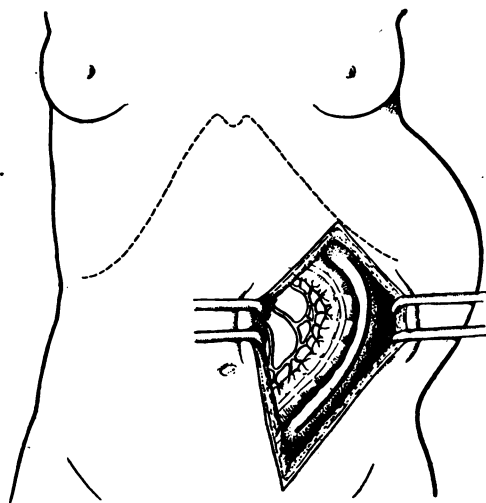


Fig. 37.—Abdominal incision for removal of kidney. (Hartmann.)

not too extensively involved in the inflammation or infiltration, it may be completed as a retroperitoneal operation.

In the majority of large tumors of the kidney, whether from inflammatory or neoplastic changes, the mass will project into the abdominal cavity, and so ultimately connect with the enveloping peritoneum that it will have to be removed with the kidney. In the latter cases the condition of the circulation of

the adjacent portion of the colon must be determined. When the peritoneum is dissected off only the outer surface of the colon is exposed and its circulation is unaffected. The peritoneum pushed back exposing the kidney, the intestine is walled back with gauze and retractors are employed to maintain the exposure. The kidney is separated from its bed, the ureter is exposed, ligated with a double ligature, and cut be-

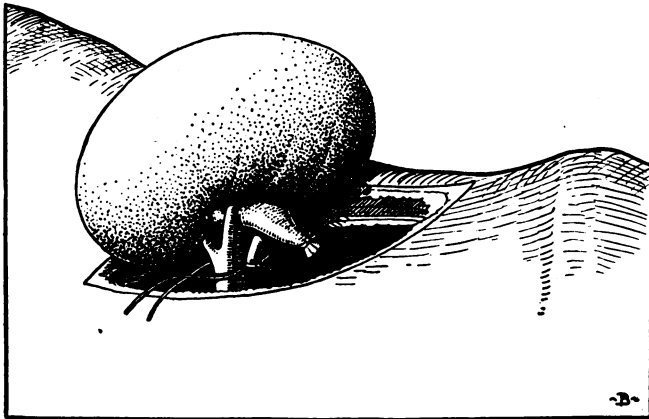


Fig. 38.—Nephrectomy. (Greene and Brooks, after Berger and Hartmann.)

tween them. The vessels are isolated if possible and ligated separately with chromic catgut, and upon completion of the ligation the kidney mass is removed (Fig. 38). If the ureter is infected, especially with tuberculous disease, it should be removed throughout its entire length. The retention of such a focus endangers the extension. The employment of the prolonged oblique incision affords the best exposure. The dissection should be accompanied without traction on the ureter,



for where thickened by inflammation it is easily broken and the spread of infection is thus endangered and its complete removal rendered difficult. If it becomes healthy near the bladder, a ligature can be applied and the ureter cut externally. When the disease involves the lower portion, its vesical orifice should be excised and the opening closed with a double row of chromic catgut sutures. The treatment of the wound will be considered later.

Where it has been necessary to open the peritoneum, it should be closed or gauze packing should be employed, to prevent contact of the peritoneal-covered intestines with the raw surfaces. When the peritoneum can be left a closed sac, the wound, which is usually a large one, should be drained with a series of split rubber tubes, ropes of gauze covered with rubber tissue, or iodoform gauze packed in the pelvis. The muscle and fascia should be accurately closed with chromic catgut sutures except where vents for drainage are necessary. In dressing the wound a considerable quantity of gauze should be applied and this covered with pads of cotton and gauze. The dressing should be changed as soon as there is an indication of its being soiled. Saturated dressings should not be allowed to remain, as they afford ready entrance for infection.

## VAGINAL OPERATIONS

AFTER the removal of the hair from the lower abdomen and a hot bath, the nurse washes the abdomen and genitalia with soap and hot water and administers a vaginal douche of a solution of mercuric bichlorid (1 : 2000) or iodine (Lugol's solution,  $\frac{1}{2}$  dram to 1 quart of hot water). These douches should be given three times in the twenty-four hours preceding operation, and in the intervals the vulva kept covered with a sterile gauze pad. When the patient comes to the table for operation she should have the vagina and the external parts, including the buttocks and the inner surface of the thighs, thoroughly scrubbed with tincture of green soap and hot water. For this purpose the fingers should be wrapped with sterile gauze. The superfluous soap should be washed away with hot sterile water, and, finally, the parts scrubbed with a 50 per cent. alcohol solution, dried, and painted with 3.5 per cent. solution of iodine. The patient is placed on her back, with legs flexed and supported by leg-holders. The feet and legs are covered with sterile dressings and the vulva isolated with sterile towels, which should be held in place by towel clips.

The principal operations done on, or through, the vagina are dilatation and curetment, excision of growths, plastic operations on the anterior and posterior vaginal walls, repair

of the cervical canal, known as "trachelorrhaphy," amputation of the cervix, closure of the fistulous openings between the vagina and bladder, or the vagina and rectum, and hysterectomy.

#### DILATATION AND CURETMENT

The patient has been prepared as directed for vaginal operations, the perineum retracted and held back by a weighted speculum; two tenacula are inserted in the anterior lip and held with the left hand of the operator. The direction of the canal having been previously determined by careful bimanual examination, the graduated bougies, of which there are two on each central handle, are introduced, beginning with the smaller size, one after another, until the desired dilatation has been accomplished (Fig. 40). The intern hands the bougies, with the smaller instrument directed toward the cervix. The nurse connects the curet to the douche-bag and is ready to open it as soon as the dilatation is completed. The douche fluid washes away the scrapings and mucus as the instrument is carried by long sweeps over the anterior, posterior, and lateral walls of the uterine cavity, and is finally carried across the fundus from one opening of the fallopian tube to the other. The nurse has ready a small pledget of sterile absorbent cotton which she has saturated with iodoform solution, and the operator carries this to the fundus, and as it is withdrawn the contents are squeezed off, the ether evaporates with the temperature of the body and leaves a coating of iodoform. In some instances the

cervical glands are filled with secretion and have been con-

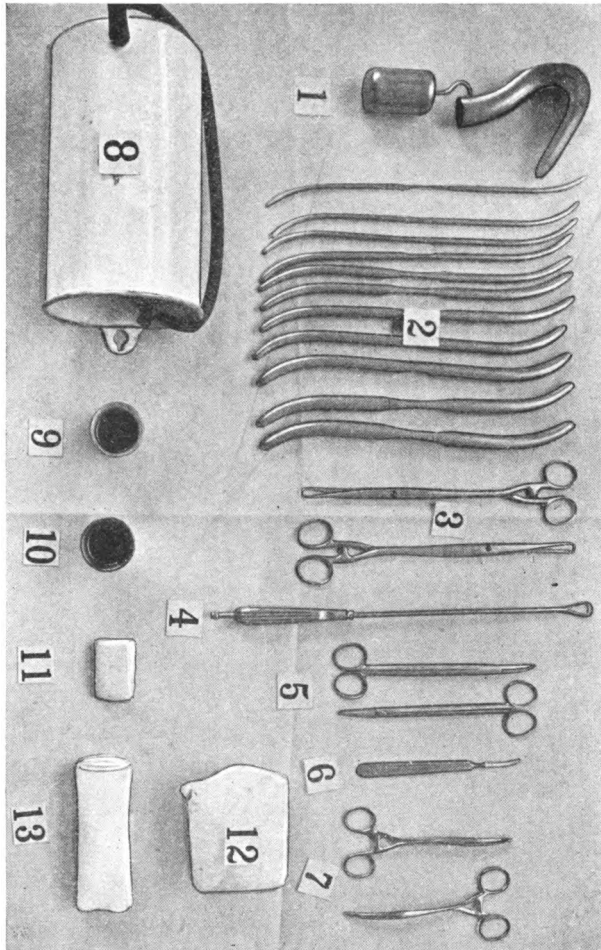


Fig. 39.—Instruments and preparations for dilatation and curetment: 1, Weighted speculum (Edebohls' or Heineberg's); 2, set Pratt's dilators or graduated bougies; 3, double tenacula (2); 4, sharp-pointed curet; 5, scissors, curved and straight (2); 6, sharp-pointed bistoury; 7, hemostatic forceps (2); 8, douche can; 9, saturated solution of iodoforn in ether; 10, solution (3.5 per cent.) iodine in alcohol; 11, package sterile absorbent cotton; 12, sterile gauze pads; 13, iodoforn gauze (10 per cent.); sterile sheets, towels, and gowns.

verted into cysts by closure of the ducts by inflammation. These cysts are opened with a bistoury, and the cavity painted

with tincture of iodine to set up sufficient inflammation to obliterate the cavity. When the cureting follows an abortion the bleeding may be free, and it is then better to swab the uterine cavity with an iodine solution and pack it with iodo-

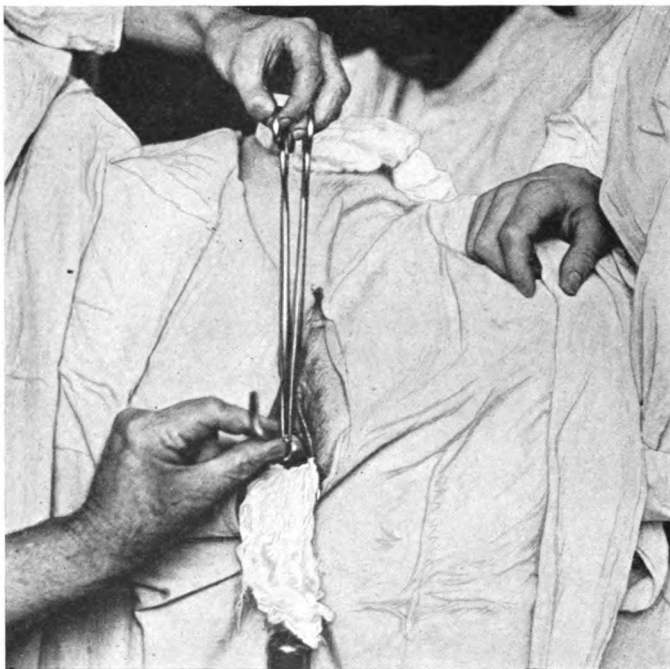


Fig. 40.—Dilatation of cervix by graduated bougies.

form gauze. In recent uterine inflammation, or following an abortion, or at the site of a flexion the wall of the uterus may be softened and be readily perforated by the bougie. This accident does not necessitate opening the abdomen, but the curet should be used without the douche and no irritant medi-

cation be made to the canal. The uterus should be packed with gauze and care should be exercised that it does not project through the perforation.

### TRACHELORRHAPHY

This is the designation given to the operation designed by Emmet for the various lacerations of the cervix.

The patient is brought to the end of the operating-table, with her feet supported in leg-holders and enveloped in sterile coverings. The vulva is isolated with sterile sheets and towels held in place with towel clips. The vagina has been cleansed as in all vaginal operations, and the cervix is exposed by the weighted speculum. The intern, standing to the right of the operator, who sits at the foot of the table, holds with his right hand a double tenaculum in the anterior lip, and with his left makes traction when necessary upon the speculum. A nurse to the right, with her left hand holds a tenaculum placed in the posterior lip, and with her right mops the blood from the field of operation. The denudation may be made on one or both sides, according to the extent and character of the laceration. Even in bilateral laceration, unless the tears be deep, it is better for the future drainage of the canal that the repair be limited to one side, especially to the side in which it has been most extensive. Where the repair is to be confined to one side, the cervix should be drawn to the opposite side, and if deep and the uterus fixed, it may be necessary to employ a lateral retractor to expose the apex of the tear. If it is decided to confine the denuda-

tion to the right side of the cervix, the assistants should

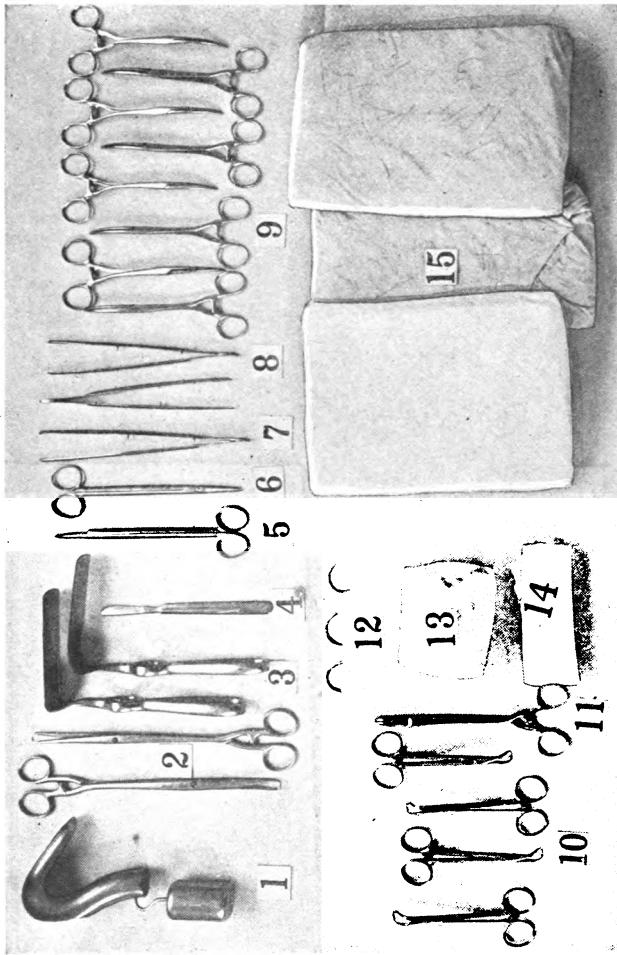


Fig. 41.—Instruments and preparations for trachelorrhaphy: 1, Speculum, Edebohls'; 2, double tenacula (2); 3, vaginal retractors; 4, scalpel; 5, scissors, sharp pointed, curved on flat; 6, scissors, straight; 7, tissue forceps, long (toothed); 8, long forceps for sponge- or mop-holders; 9, hemostatic forceps (8); 10, towel clips (4); 11, needle-holder; 12, needles, round-pointed, curved, flattened at eye on curved side; 13, sterile gauze; 14, iodoform gauze; 15, sterile gowns, sheets, and towels.

reverse their hands in holding the tenacula. The uterus should always be curetted as a preliminary to the operation.

Beginning on the posterior lip, the operator seizes the tissue near the point for the new os and outlines the portion to be removed by an incision from the inside of the canal and another on the vaginal side (Fig. 42). The tissue or flap thus outlined is lifted toward the apex of the tear and left in position while the denudation on the anterior lip is followed in the same manner. When the operation is bilateral a similar course is pursued on the other side of the cervix, tak-

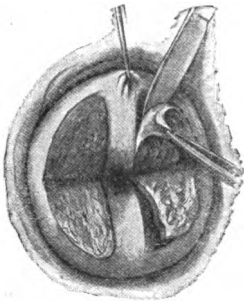


Fig. 42.—Denudation for trachelorrhaphy. (Montgomery, "Practical Gynecology.")

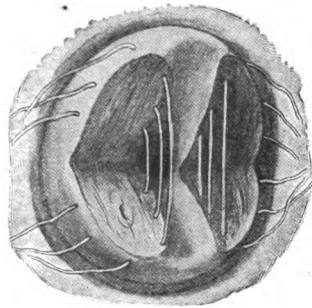


Fig. 43.—Bilateral laceration of the cervix and sutures introduced for union of denuded surfaces. (Montgomery, "Practical Gynecology.")

ing care to preserve a central undenuded portion on each lip for the future cervical canal. The denudation completed (Fig. 43), the nurse hands a needle threaded with No. 1 chromic catgut, and the first suture is introduced from the vaginal side of the anterior right lip of the cervix, and brought out on its inner surface within the denudation at the margin of the cervical membrane; the left suture is introduced from the posterior lip and brought out on the anterior. These sutures



are situated on either side of the new os and temporarily secured with forceps; the tenacula are removed, and these sutures are used as retractors. Their introduction and employment thus ensures the union of the lips at a uniform length, otherwise it would be difficult to ensure their being properly brought together. The other sutures are introduced on either side to ensure the proper coaptation of the lips, each suture being carried to the margin of the cervical flap, but none entering it. A suture entering the cervical




Fig. 44.—Wound closed. (Montgomery, "Practical Gynecology.")

mucosa prejudices the result in two ways: first, by approximating the two mucous surfaces it diminishes the surface for union; and, second, its presence acts as a seton which may result in a cervicovaginal fistula, an abnormal opening which will be a source of annoyance subsequently. The sutures in place, the surfaces are separated, all blood-clots removed, and the sutures tied without undue pressure, just securely enough to ensure proper apposition (Fig. 44). If tied firmly the included tissue will slough out and the laceration recur,

or the increased cicatricial tissue will be a source of irritation. The nurse hands a section of iodoform gauze, about 4 inches long, cut from a fold of yard-wide roll, and this is packed against the cervix.

#### AMPUTATION OF THE CERVIX

The cervix is amputated when the laceration has existed for some time, is accompanied by hypertrophy, eversion of the mucous membrane, or glandular degeneration and erosion.

The patient prepared for a vaginal operation and the vulva isolated with sterile dressings, the perineum is retracted with a weighted speculum (Fig. 46). The cervix, after the uterus is cureted, is held by a tenaculum in each lip, and with a scalpel the operator encircles the opening of the cervical canal, cutting through the mucosa and part of the muscular layer. The tenaculum is removed from the posterior lip, and with tissue forceps the surgeon holds it while with the knife he outlines and removes a flap extending from one side of the cervix to the other, following the junction of the cervical and vaginal mucosa. He then removes the tenaculum from the anterior lip, and, after placing it on the posterior, has it held by the intern while he follows the same course in removing a flap from the anterior lip. In both instances the denudation is at the expense of the internal surface. The removed tissue should include all eroded and diseased structures unless the posterior lip is too extensively eroded (Fig. 47). The important consideration

is to secure an unobstructed canal for uterine drainage. The

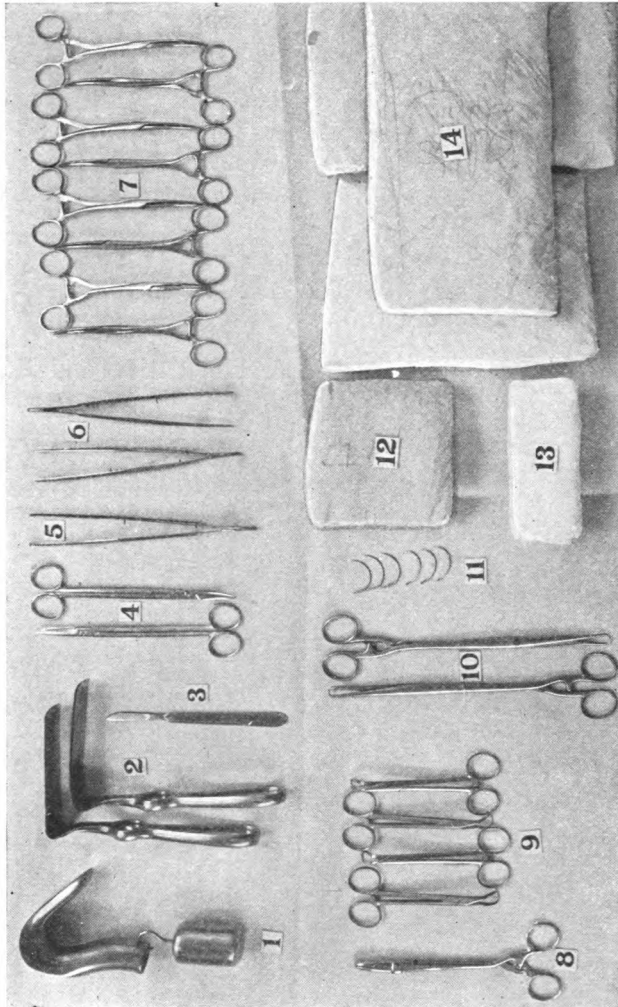


Fig. 45.—Instruments and preparations for amputation of the cervix: 1, Weighted speculum; 2, vaginal retractors (2); 3, scalpel; 4, scissors, curved and straight; 5, long tissue forceps (toothed); 6, long forceps for sponge-holders; 7, hemostatic forceps (8); 8, needle-holder; 9, towel clips (4); 10, double tenacula (2); 11, needles, round, pointed, curved, flattened at the eye on curved side; 12, sterile gauze sponges; 13, iodoform gauze; 14, sterile gowns, sheets, and towels.

cervical and vaginal membranes are generally united by two

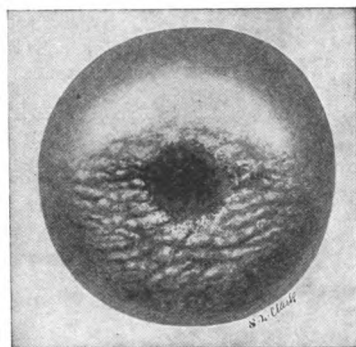


Fig. 46.—Surface before operation.

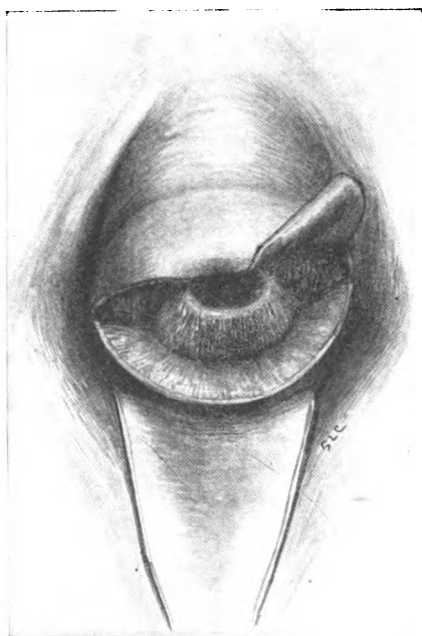


Fig. 47.—Amputation completed. Surfaces ready for suture. ("Keen's Surgery.")

or three sutures anteriorly and posteriorly, but a better method is to employ the Bonney method of suturing, which consists in passing a suture in the center of the vaginal mucosa in front, tying a knot, cutting one end short, and then inserting the point of the needle into the cervical canal, bringing it

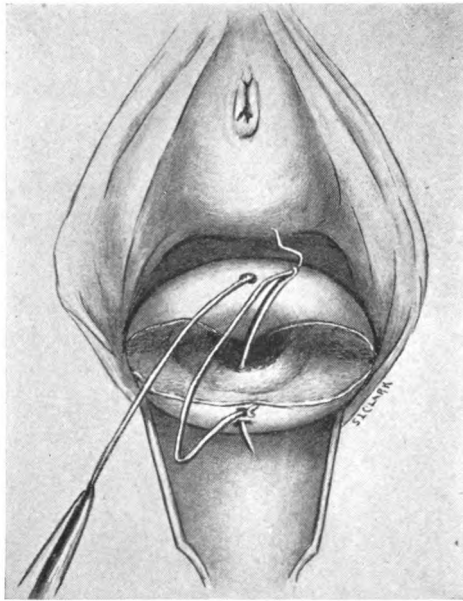


Fig. 48.—Bonney suture.

through the anterior wall and securing it temporarily with a hemostat; the posterior flap is treated similarly. (Fig. 48). Traction on these sutures inverts the vaginal surfaces. A lateral suture is inserted on either side and tied. The anterior suture is then tied to the ends of the suture on the pa-

tient's right, while the posterior is secured to those on the left. These ends are then secured with a hemostat and pulled to the right or left until sutures have been introduced to hold the cut surfaces in union when the ends are cut. By

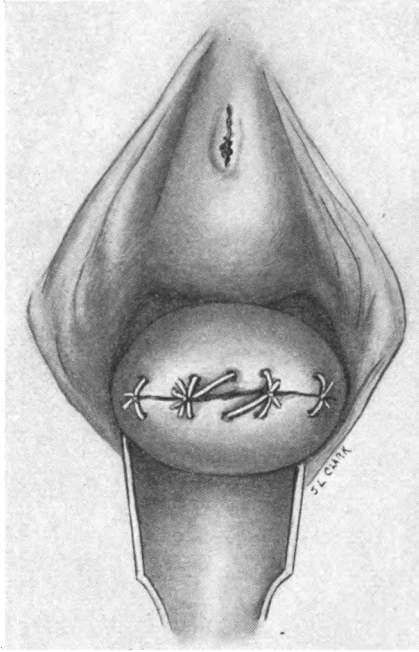


Fig. 49.—Sutures in place and wound closed.

this method the vaginal surfaces are smoothly inverted and there is no suture to mar the external appearance of the os (Fig. 49). The blood is sponged away, the surface of the wound painted with dilute iodine solution, and a compress of iodoform gauze inserted.

**ANTERIOR COLPORRHAPHY**

This procedure is indicated for sagging or prolapse of the anterior vaginal wall, and is usually a part of the measure employed to correct prolapsus of the uterus. This operation may or may not be preceded by curetment of the uterus and amputation of the cervix. When the latter has not been done, the cervix is seized with two double tenacula, which are held by the intern standing to the left of the operator. The latter, sitting at the end of the table, picks up the vaginal mucosa just above the cervix with tissue forceps, and divides the vaginal wall in the median line to the base of the urethra, or even near the external meatus. Each side is held with tissue forceps and the connective tissue is opened with scissors. The Bland forceps are applied to the vaginal wall on each side of the incision, those on the left held by the intern and on the right by the nurse, when the operator separates the bladder from the vaginal flaps by blunt dissection to the extent required for the contraction of the vagina. The bladder is pushed back from the cervix in the same manner. Occasionally it may be necessary to cut through the connective tissue to start the separation from the cervix. When an amputation of the cervix is done it is better that the excision of the vaginal wall should precede the suturing of the cervical flaps. In hypertrophic elongation of the cervix it may be desirable to remove a considerable portion of the cervix, and the previous suturing would but handicap the second procedure. In these cases it may be desirable to anchor up the cervix, which can

be done by cutting through the base of each broad liga-

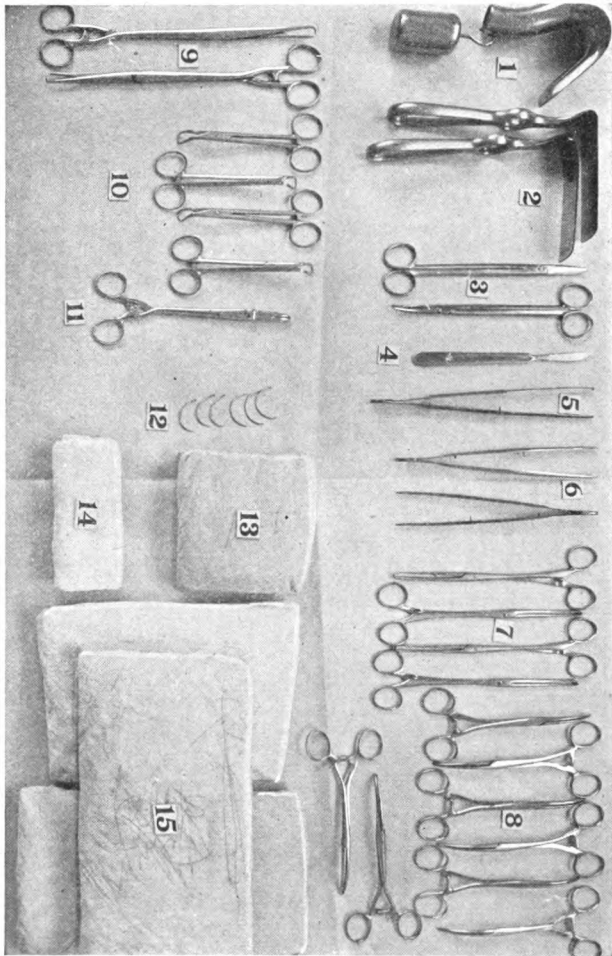


Fig. 50.—Instruments and preparations for operation of anterior colporrhaphy: 1, Speculum (Edebohls); 2, vaginal retractors (2); 3, scissors, sharp and blunt; 4, scalpel; 5, long tissue forceps (toothed); 6, long forceps for sponge-holders; 7, hemostatic forceps (4 Bland's); 8, hemostatic forceps (8); 9, double tenacula (2); 10, towel clips (4); 11, needle-holder; 12, needles, cutting edge, flattened on curved side; 13, package of gauze sponges; 14, package of iodiform gauze; 15, packages of sterile gowns, sheets, and towels.

ment and uniting these sutures in front of the remaining portion of the cervix. The vaginal walls may be brought



together by a stitch at the side of the cervix, one end of which is cut short and the other carried through the anterior wall of the cervix, as in the Bonney suture, already described. In the ordinary operation the bladder is anchored at a higher level on the anterior surface of the cervix by two or more sutures taken in the connective tissue of the bladder at the base, which when tied folds its wall. The redundant portion of the vaginal flaps are removed by a curved incision on either side and the vaginal walls united by interrupted chromic catgut sutures. The first suture is placed near the cervix and the others in succession below until the anterior wall is closed. These sutures may be tied as they are introduced. The surface is cleansed with an alcohol solution (50 per cent.) and the edges of the wound painted with iodine solution (3.5 per cent.), dried, and if the procedure completes the series of operation, a pledget of iodoform gauze is placed against the cervix.

#### **VESICOVAGINAL INTERPOSITION OF THE UTERUS; WATKINS' OPERATION**

The preparations and instruments designated in the preceding operation are sufficient. The initial method of procedure is the same. The cervix should be amputated where it is long, large, or ulcerated. Where it is inclined to sag down, the lower part of the broad ligaments should be cut and secured in front of the cervix. The vaginal incision is made as in the procedure of anterior colporrhaphy, but the bladder is pushed off from the anterior surface of the

broad ligament, the peritoneum opened, and the fundus brought through the opening. The vesical peritoneum is secured by several sutures to the posterior surface of the

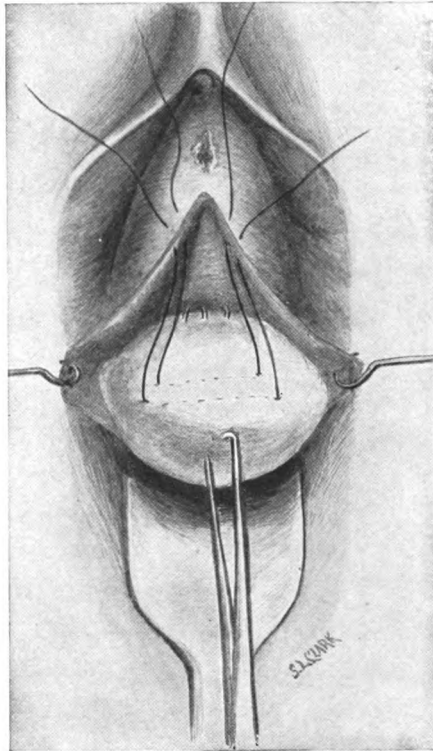


Fig. 51.—Vesicovaginal interposition of the uterus (Watkins' operation).

uterus; two sutures are passed through the left side of the vaginal incision, through the anterior surface of the fundus, and brought out through the right side of the vaginal wall at the level of introduction (Fig. 51). These sutures lift the

fundus under the base of the bladder and upper part of the urethra. It is important that the sutures are properly placed, otherwise a small sac forms in which the urine will collect and cause dribbling and want of complete control. The superfluous portion of the vaginal flaps are now cut away, retaining sufficient to cover without tension of the surface of the uterus. The sutures are introduced transversely, securing with each a portion of the anterior uterine wall. The operation completed, the uterus lies between the vagina and bladder, rendering a recurrence of the protrusion of the bladder impossible. The subsequent cleansing and packing of the vagina is followed as in the previous operation.

#### VAGINAL HYSTERECTOMY

Removal of the uterus through the vagina may be done for cancer, either of the body or cervix, when the abdominal walls are very thick and fat; for fibroid growths of moderate size, where the vagina is roomy; for prolapsus with laceration of the cervix or ulceration of the vaginal walls. It should not be elected for cancer when the condition is favorable for abdominal section, as the latter affords better opportunity of getting well beyond the disease, nor for fibroids of a size that will make them difficult of delivery (Figs. 52, 53).

The patient is prepared for vaginal operation with the vulva isolated by sterile sheets and towels. The latter secured by clips to the skin, and if the clip is in the way at the vulva the towel can be secured by a stitch to the perineum. The cervix is exposed with the speculum and drawn down by

a double tenaculum. A number of tenacula are applied to the cervix in such a manner as to close the os and thus prevent

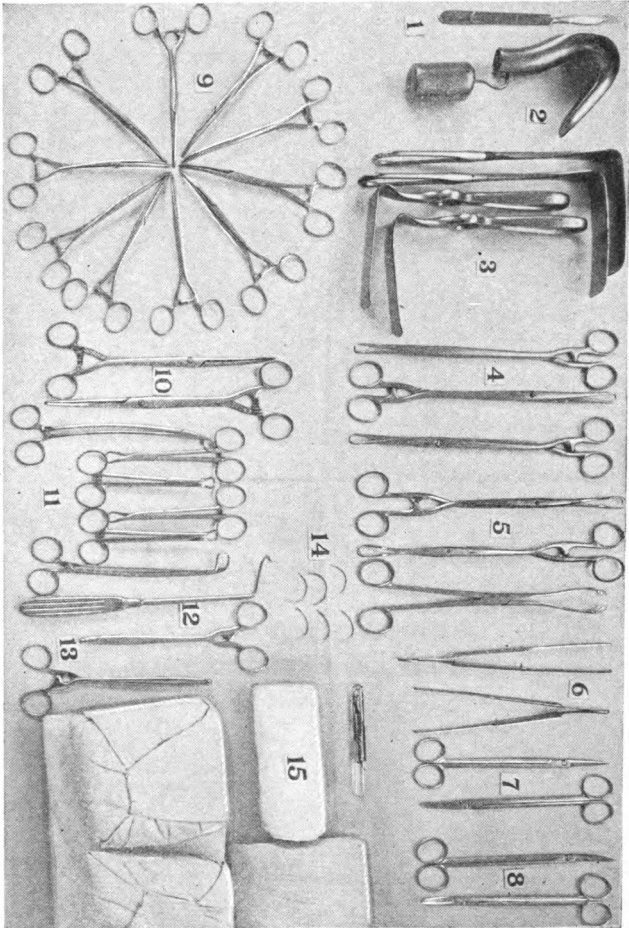


Fig. 52.—Instruments and preparations for vaginal hysterectomy: 1, Scalpel; 2, speculum (Edebohls); 3, vaginal retractors (4); 4, double tenacula (3); 5, fixation forceps (3); 6, tissue forceps (toothed); 7, scissors, straight; 8, scissors, curved; 9, hemostatic forceps (10); 10, heavy hemostatic forceps (2); 11, towel clips (6); 12, ligature carrier; 13, needle-holders; 14, needles, curved (6); flattened on the curved surface near the eye; 15, catgut, packages of gauze pads, sheets, gowns, towels, and iodiform gauze.

the soiling of the vagina and the wound with the secretions or discharges. The instruments thus applied serve as trac-

tors, and if necessary the assistant on each side can still further aid in the exposure by the use of a vaginal retractor. The operator, holding the cervix with the tenacula, sweeps around it with the scalpel, severing it from the vagina, and then with a gauze-wrapped finger pushes the vagina and bladder back in front and the vagina laterally and posteriorly.

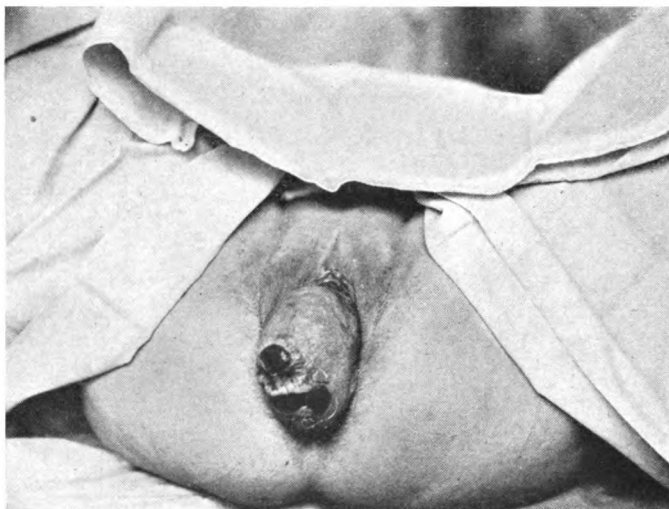

Fig. 53.—Procidentia with gravity sores on the cervix.

The nurse hands the surgeon a needle in grasp of needle-holder, threaded with No. 1 chromic catgut; while the intern holds the cervix firm with the fixation forceps he passes the ligature from above downward against the finger which has been placed beneath the under side of the lower part of the broad ligament, and when tied this ligature secures the uterine artery of that side. The vessel of the other side is

secured in the same way, and when the tissue is cut between the ligature and cervix the organ is easily brought to a lower level. If the vesico-uterine fold of the peritoneum has not already been opened, it should be now, and the fundus brought down, the carrier again threaded, the upper portion of each ligament is tied, and before cutting is secured by a strong hemostat. The ligatures are cut short to prevent any possibility of being pulled on, and thus possibly permit the retraction of a vessel which would be difficult to again secure. The uterus is cut away from the remaining tissue, the intern being ready with a hemostat to secure any spurting vessels. The uterus removed, careful inspection is made for any bleeding vessels, and ligatures substituted for clamps except the two on the upper portions of the ligaments. The assistant on either side draws upon the broad ligament with the forceps, while the operator applies another hemostat to the peritoneum covering the bladder, a suture is passed through the inner (which is the upper) surface of the left broad ligament, then gathers up the peritoneum of the lower margin of the bladder and carries the needle downward through the upper surface of the right ligament (Fig. 54). A second suture is carried backward through the left ligament, gathers up the peritoneum of the posterior vaginal wall, and passes forward in the right ligament. These two sutures when tied close the peritoneum from the vagina and ensure that any bleeding occurring shall be outside the abdominal cavity. A third suture, carried from the left ligament, picks up the bladder wall near its base, and backward,

through the right ligament tied, supports the bladder on the ligaments. The stumps are then sutured so that the end of one overlaps the other, and the ligaments are made to support the bladder and rectum. The vault of the vagina is exposed by a retractor held by the intern beneath the sym-

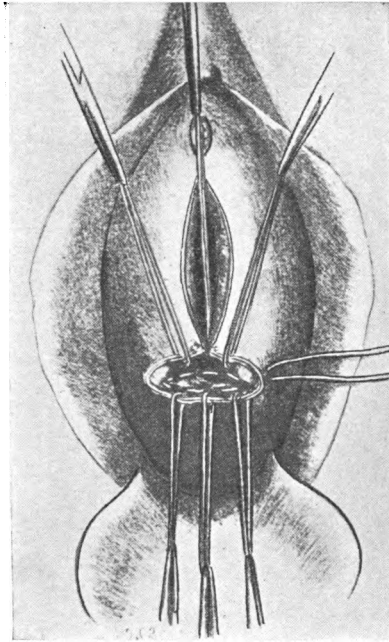


Fig. 54.—Uterus removed and sutures introduced for closing the peritoneum.

physis, and the surgeon sutures the lateral points of the vaginal vault to the ligamental stump and closes the upper part of the vagina by anteroposterior sutures. The raw surface on the anterior wall, made by excision of the protruding vagina, is closed by transverse sutures, which pick

up also the vesical wall, and this portion is closed in a vertical line with interrupted chromic catgut sutures (Fig. 55). The method of closing here described is particularly applicable to the cases in which the operation has been done for prolapsus, and presupposes that a flap has been removed from

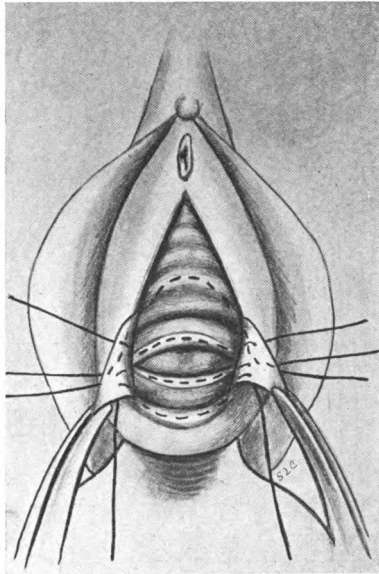


Fig. 55.—Sutures introduced closing the vagina.

the anterior vaginal wall in the separation of the vagina from the cervix.

In cases in which the vagina is not so distorted, the stump of each broad ligament may be secured outside the peritoneum by passing a purse-string suture through the anterior and posterior peritoneal folds around the one stump and tying



it over the other. This ligation secures against hemorrhage. The vaginal surfaces should then be united by interrupted catgut sutures. The operation thus performed leaves no raw surface within the peritoneal cavity nor within the vagina, and the recovery is rapid. The vagina is sponged free of blood, the line of incision painted with the diluted iodine, and a pledget of iodoform gauze packed against the vault. The packing holds the vault at a higher level, allows the ligaments to contract, and by cicatrization ensures a longer and more fixed vagina.

**PERINEORRHAPHY; POSTERIOR COLPORRHAPHY; RECTO-VAGINAL INTERPOSITION OF THE LEVATOR ANI MUSCLES**

This procedure is generally supplementary to other operations. It is rare that the surgeon would confine the procedure to the perineum only. It may terminate repair operations on the cervix, and particularly should follow anterior colporrhaphy and the removal of the uterus for prolapsus. The procedure may be required for relaxation of the floor or for extensive laceration through the sphincter and the rectovaginal septum. The procedure then involves not only the support afforded by the pelvic floor, but also the restoration of the control of the contents of the intestine, whether liquid or gas.

The preparation of the patient will depend upon the extent and purpose of the operation. The bowel should be always effectually evacuated, especially when laceration extends through or into the sphincter. The patient should

have been restricted in her diet to food with little waste material, as meat broths, and should not take any milk

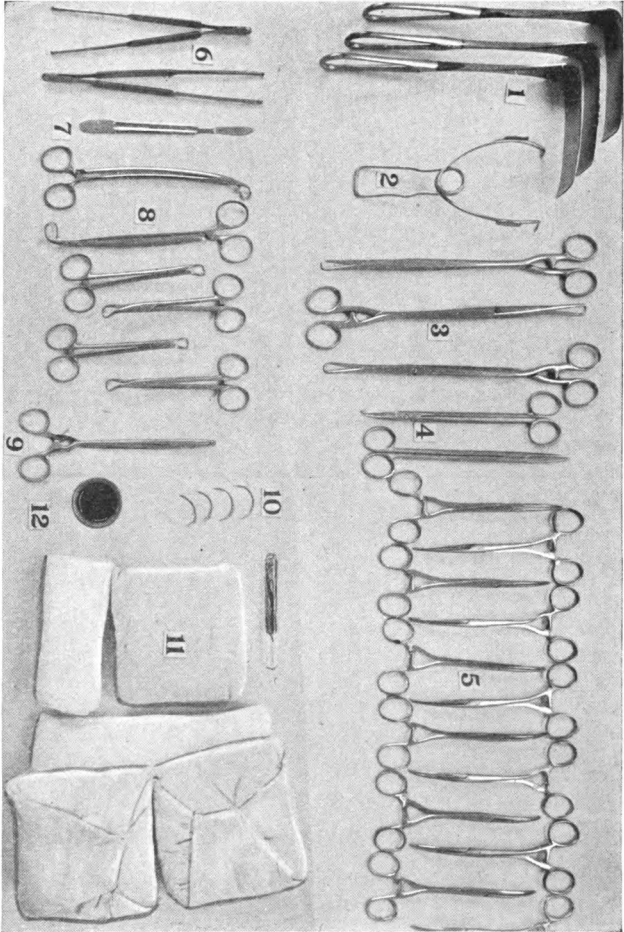


Fig. 56.—Instruments and preparations for perineal operations: 1, Retractors (3); 2, double retractor (Bland's), 3, double tenacula (2); 4, scissors, curved and straight; 5, hemostatic forceps; 6, tissue forceps (long, toothed); 7, scalpel; 8, towel clips (6); 9, needle-holder; 10, needles, slightly curved, flattened on the curve (4); 11, tubes of calgut and packages of gauze pads, iodiform gauze, sterile gowns, sheets, and towels; 12, iodine solution (3.5 per cent.).

after the purgative has been administered. The evening preceding the operation she should be given an enema of

soapsuds and the vulvar hair should be removed as well as that about the anus. This is best done with a depilatory, as thus any possibility of injury and infection of the skin is avoided. When the operation is done for relaxation and eversion of the posterior wall and to ensure subsequent

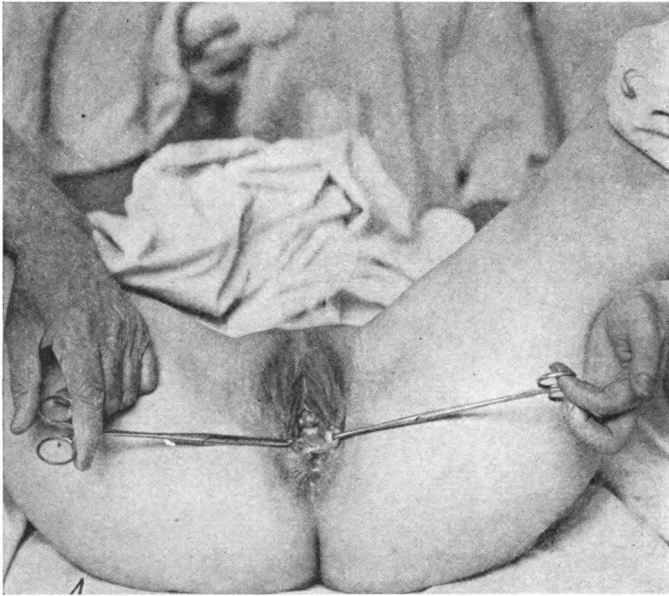


Fig. 57.—Incomplete laceration of the perineum.

effectual support, the vulva is separated by the employment of the Bland retractor (Fig. 57). This instrument has two blades, separated by a spring with a tenaculum point projecting from each blade. The instrument is introduced into the vulva, with the blades closed, and placed with a point against the remains of the hymen, known as the caruncula,

on either side the vulva, and the pressure released when the vulva and orifice of the vagina is widely separated. A double tenaculum picking up the summit of the vaginal eversion, the outlines of the denudation are indicated. The action of the instrument lifts the vaginal wall away from the rectum, and an incision can be easily made from the tenaculum above to the margin of the commissure posterior and carried outward to the end of the retractor on either side, which outlines flaps for excision that can be quickly lifted with the scalpel and removed. This dissection exposes the rectum above and the muscular layer below, while on either side can be exposed the edges of the separated levator ani muscles. With a curved needle armed with No. 1 chromic catgut suture, held in a needle-holder, the surgeon lifts the edge of the vaginal wall on the left side, passes the needle through the belly of the levator ani, carries it downward through the fascia covering the rectum, upward on the other side, beneath the levator ani, and clamps the ends of this suture with a hemostat. Traction on this suture lifts up the levator ani and renders the subsequent sutures more easily placed. Three sutures are generally sufficient to ensure the approximation of the muscles. The retractor should be removed before these sutures are tied (Fig. 58). After tying the sutures the vaginal wound is closed by superficial sutures. The result is, the levator muscles are brought in front of the rectum, thus effectually preventing the reformation of rectocele and overcoming the tendency to prolapse. The ease with which the bowels can be evacuated

is enhanced. This procedure brings the posterior segment of the pelvic floor in contact with the anterior and supports it. In cases where there is a weakened condition of the upper vaginal floor, and the peritoneum has been pushed down between the rectum and vagina, tight lacing or constipation may lead to a protrusion or hernia of the upper vagina, which will cause the patient to feel the rectocele is

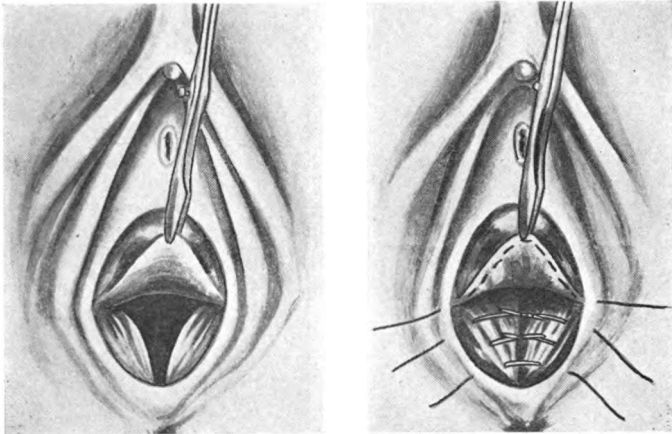


Fig. 58.—Rectovaginal interposition of the levator ani muscles.

recurring. Where such a condition is possible, it is wise to cut through the vaginal wall, push back the peritoneum, and make a wider approximation of the levators. The cicatrization thus produced is the most effective resistance to further trouble.

**Complete Laceration.**—In this form of laceration the most important consideration is the restoration of the function of the sphincter (Fig. 59). The Bland retractor should

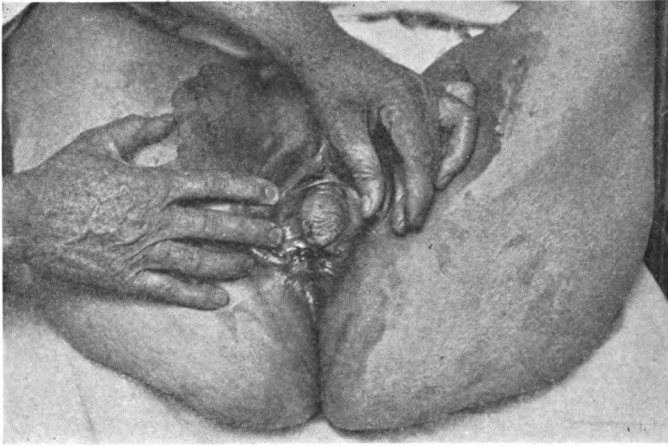

Fig. 59.—Complete laceration associated with cystocele.


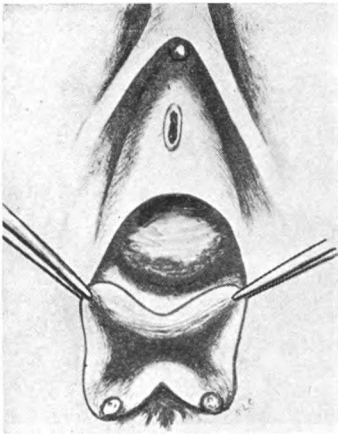


Fig. 60.—Suture of the ends of the sphincter muscle.

be placed with a point at the extremity of the tear at either side, and will thus render tense the line of the septum, which should be split and anterior and posterior flaps formed. The posterior flaps are sutured, preferably by the Lauenstein suture, to form the anterior wall of the rectum. The ends

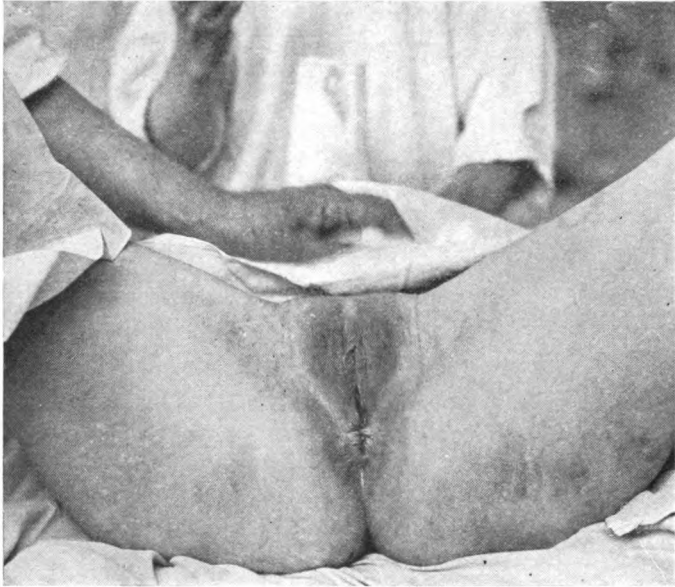



Fig. 61.—Operation completed.

of the torn sphincter which have been exposed by the dissection are united by two chromic catgut sutures (Fig. 60), and then the levator ani muscles and the vaginal wall and skin surfaces united, as in the previous operation (Fig. 61). The surface should be cleansed with alcohol and water and the line of incision painted with the diluted iodine. A sterile

pad should be kept over the vulva and the surface irrigated after the evacuation of the urine, and particularly when the bowels have been moved.

The procedures described present the principal operative measures performed upon and through the vagina, and afford the principles which should govern any operation on this tract.





# INDEX

ABDOMINAL hysterectomy, 77  
operations, 62  
pain and tenderness, 48

After-care, 29

Amputation of cervix, 123

Anastomosis, intestinal, 82

Anterior colporrhaphy, 128  
gastro-enterostomy, 92

CATHETERIZATION, 32

Cervix, amputation of, 123  
repair of, 119

Cholecystectomy, 100

Cholecystocolostomy, 101

Cholecystoduodenostomy, 101

Cholecystogastrostomy, 101

Cholecysto-ileostomy, 101

Cholecystojejunostomy, 101

Cholecystostomy, 100

Cholecystotomy, 100

Choledochectomy, 100

Choledochoplasty, 101

Choledochostomy, 100

Choledochotomy, 100

Colporrhaphy, anterior, 128  
posterior, 138

Curetment, 116

DEPILATORY, 12

Dilatation, 116

Drainage, 24

Dressings, 25

FECAL fistula, 60

Field, preparation of, 12

Fistula, fecal, 60

GALL-BLADDER operations, 97

Gastrectomy, partial, 96

Gastric operations, 86

Gastroduodenostomy, 96

Gastro-enterostomy, anterior, 92  
posterior, 94

Gastro-gastrostomy, 96

Gastropexy, 87

Gastrotomy, 91

HEMORRHAGE, 42

Hypodermoclysis, 40

Hysterectomy, abdominal, 77  
subtotal, 77  
vaginal, 132

ILEUS, 58

Incision, 15

median, 17

Pfannenstiell, 19

Instruments, 16

for amputation of cervix, 124

for anterior colporrhaphy, 129

for dilatation and curetment, 117

for gastrotomy, 91

for hysterectomy, abdominal, 78  
vaginal, 133

for intestinal anastomosis, 83

for intravenous injection, 39

- Instruments for operations on Fallo-  
pian tube, 68  
on gall-bladder, 98  
on kidney, 106  
on spleen, 104  
for ovariectomy, 74  
for perineal operations, 139  
for salpingectomy, 68  
for shortening round ligaments, 63  
for trachelorrhaphy, 120
- Intern, duties of, 11
- Intestinal anastomosis, 82
- Intestines, resection of, 82
- KIDNEY operations, 103
- LACERATION, complete, of perineum,  
142
- Levator ani muscles, rectovaginal  
interposition of, 138
- Ligaments, round, shortening of, 62
- NAUSEA, 41
- Nephrectomy, 110
- Nephropexy, 108
- Nephrotomy, 109
- Nourishment, 34
- Nurse, duties of, 11
- OPERATIONS, after-care, 29  
cervix, amputation of, 123  
repair of, 119  
Fallopian tube, 67  
gall-bladder, 97  
gastric, 86  
kidney, 105  
renal tumors, 111  
levator ani muscles, 138  
ligaments, shortening of, 62  
Montgomery's modification, 62
- Operations, ovary, 67  
pelvic floor, 138  
perineum, complete laceration of,  
142  
spleen, 103  
uterus, 77-132  
dilatation and curetment, 116  
vaginal, 114  
Watkins', 130
- Ovariectomy, 73
- PAIN, abdominal, 48
- Panhysterectomy, 77, 80
- Partial gastrectomy, 96
- Patient, care of, after operation, 29  
during operation, 27  
on admission, 11
- Pelvic floor, repair of, 138  
operations, 62
- Perineorrhaphy, 138
- Perineum, complete laceration of, 142
- Peritonitis, 49
- Phlebitis, 56
- Posterior colporrhaphy, 138  
gastro-enterostomy, 94
- Pylorectomy, 96
- Pyloroplasty, 96
- RECTOVAGINAL interposition of leva-  
tor ani muscles, 138
- Round ligaments, shortening of, 62
- SALPINGECTOMY, 67  
Salpingo-oöphorectomy, 67  
Salpingostomy, 72  
Sepsis, 52  
Shock, 36  
Spleen, 103  
Subtotal hysterectomy, 77  
Supravaginal hysterectomy, 77

- TENDERNESS, abdominal, 48  
Trachelorrhaphy, 119  
Tyimpanites, 45
- UTERUS, dilatation and curetment of,  
116  
vesicovaginal interposition of, 130
- VAGINAL hysterectomy, 129  
operations, 114  
Vomiting, 41
- WATKINS' operation, 130  
Wound, closure of, 21

